HC 16VS 9

Missing
113-364

From A. G. Eycleshymer
Department of Anatomy,
St. Louis University,
St. Louis, Mo.

BOSTON MEDICAL LIBRARY
IN THE
FRANCIS A. COUNTWAY
LIBRARY OF MEDICINE

AUTHORS.

BEVAN, ARTHUR DEAN.

GERRISH, FREDERIC HENRY.

KEILLER, WILLIAM.

McMURRICH, JAMES PLAYFAIR.

STEWART, GEORGE DAVID.

WOOLSEY, GEORGE.

A

TEXT-BOOK OF ANATOMY

BY

AMERICAN AUTHORS.

EDITED BY

FREDERIC HENRY GERRISH, M. D.,

PROFESSOR OF ANATOMY IN THE MEDICAL SCHOOL OF MAINE, BOWDOIN COLLEGE.

SECOND EDITION, REVISED AND ENLARGED.

ILLUSTRATED WITH 1003 ENGRAVINGS IN BLACK AND COLORS.



LEA BROTHERS & CO.,
PHILADELPHIA AND NEW YORK.
1902.

Entered according to Act of Congress in the year 1902, by
LEA BROTHERS & CO.,
in the Office of the Librarian of Congress, at Washington. All rights reserved.

WESTCOTT & THOMSON,
ELECTROTYPERS, PHILADA.

PRESS OF
WILLIAM J. DORNAN, PHILADA.

PREFACE TO THE SECOND EDITION.

Two years have sufficed to exhaust the very large first edition of this work, and have brought to those responsible for its existence an early and gratifying sense of professional approval. The test of success is comprehensive, and may be fairly construed as including the execution of the book, about which misgivings were pardonable, and its plan, about which there was a reasonable degree of confidence. In their work as teachers of anatomy the authors had long felt the need of a text-book presenting the essential facts of human structure, and judiciously avoiding the unimportant and exceptional. Between the extremes, represented on the one hand by pocket manuals, with their flavorless condensation, and on the other hand by encyclopedias of universal inclusiveness, there is room for a work of convenient size, sufficient to contain in systematic array those portions of anatomical knowledge which are necessary to the intelligent study of physiology, surgery and internal medicine. The logical limits of this field excluded the much greater collection of facts having no known practical bearing, or only the rarest application.

The authors have unceasingly endeavored to facilitate the work of both student and teacher. Both are tested in every examination, and particularly in those conducted by State Licensing Boards. Accordingly, from the vast accumulations of anatomical science those portions have been selected which are likely to be of actual service to the student in his subsequent study, and to the practitioner in his clinical work. Emphasis has been laid upon the most important facts, obscurities have been clarified, the greatest amount of help has been given in the parts which are most difficult to learn, and everything has been illustrated by all available methods. In short no effort has been spared to promote facility of acquisition and permanence of the knowledge gained.

The arrangement of the book is along familiar lines, the ordinary divisions of systematic anatomy having been followed in the main. Each author has set forth his subject in such manner as experience has shown him to be profitable. Great relative stress has been laid upon visceral structure, without neglect of other branches; surface anatomy has received attention more in proportion to its usefulness than is usual, and the pictorial and diagrammatic illustrations (thanks to the remarkable liberality of the publishers) are phenomenally abundant and of striking artistic excellence. Wherever practicable the names of the parts have been engraved directly upon them, a method which has the great advantage of conveying at a glance their shape, position, extent and relations.

It is believed that the plan of giving directions for dissection in a separate chapter will prove a marked convenience to the student.

These characteristics of the work may fairly be credited with its adoption in a

large number of medical schools, and its extensive use by students and practitioners on both sides of the Atlantic. The early opportunity for revision, created by this demand, has been faithfully utilized, every section having been critically examined for possible improvement. Such changes have been made as were rendered necessary by the progress of anatomical science, and new matter has been added wherever desirable and consonant with the general scope of the work. Particular attention has been bestowed upon relational anatomy. Instead of the schematic device previously employed for showing the relations of the principal arteries, a series of horizontal sections at different levels has been prepared, the various parts being labelled directly with their names wherever feasible. By this plan greater precision is attained, and the facts are presented in a manner especially promotive of prompt comprehension and enduring retention. These same transections will be found equally useful in regard to the relations of other structures—nerves, muscles, etc.

In matter of illustration, a number of figures have been replaced with others seemingly better adapted to their purpose, and new pictures have been liberally added. The chapter on Osteology, for example, has been enriched with a series of drawings displaying the areas of attachment of muscles to bones, which should prove useful. The addition of new engravings brings the total above one thousand, a very large proportion being in two, three, or four colors.

It is hoped that the improvements in this edition, of which a few have been mentioned, will still further increase the favor already bestowed on the work.

F. H. G.

Portland, Maine, September, 1902.

LIST OF AUTHORS.

ARTHUR DEAN BEVAN, M. D.,

Professor of Anatomy in Rush Medical College in affiliation with the University of Chicago; Surgeon to the Presbyterian and St. Luke's Hospitals, Chicago, etc.

FREDERIC HENRY GERRISH, A. M., M. D.,

Professor of Anatomy in the Medical School of Maine, Bowdoin College; Consulting Surgeon to the Maine General Hospital, Portland; Fellow of the American Surgical Association; sometime President of the American Academy of Medicine, etc.

WILLIAM KEILLER, F. R. C. S. (EDIN.),

Professor of Anatomy in the Medical Department of the University of Texas, Galveston: sometime Lecturer on Anatomy in the Edinburgh Medical School, etc.

JAMES PLAYFAIR McMURRICH, A. M., PH. D.,

Professor of Anatomy in the University of Michigan, Ann Arbor; sometime Professor of Biology in the University of Cincinnati and Associate Professor of Animal Morphology in Clark University, etc.

GEORGE DAVID STEWART, M. D.,

Professor of Anatomy in the University and Bellevue Hospital Medical College, New York City; Visiting Surgeon to Bellevue Hospital, etc.

GEORGE WOOLSEY, A. B., M. D.,

Professor of Anatomy and Clinical Surgery in the Cornell University Medical College, New York City; Visiting Surgeon to Bellevue Hospital; Fellow of the American Surgical Association, etc.

CONTENTS.

INTRODUCTORY.

By F. H. Gerrish.

	PAGE
Definition	17
Names and Delimitations of Surface Parts	21
The Systems of Organs and their Functions	29
Organs removing Waste Matters	30
The Vascular System	30
Organs Supplying Nourishment	31
Organs of Internal Secretion	32
Organs of Motion	32
Framework Organs	32
Organs of Relation	32
Organs of Reproduction	33
The Order of Topics	33
Methods of Study	33

ELEMENTARY TISSUES.

By F. H. Gerrish.

	PAGE
Cells.	
Cell-reproduction	39
Classes of Tissues.	
The Epithelial Tissues	41
The Sustentacular Tissues	45
White Fibrous Tissue	46
Yellow Fibrous Tissue	47
Areolar Tissue	47
Adipose Tissue	49
Gelatinous Tissue	50
Adenoid Reticular Tissue	50
Neuroglia	50
Cartilaginous Tissues	51
Osseous Tissue	52
Dentinal Tissue	56
The Liquid Tissues	57
The Lymph	57
The Blood	57
The Muscular Tissues	58
Plain Muscular Tissue	58
Cross-striped Muscular Tissue	59
Cardiac Muscular Tissue	61
The Nervous Tissues	62
Membranes	64
Serous Membranes	66
Serous Membranes Proper	68
The Lining Membrane of the Vascular System	68
The Lining Membrane of Certain Cavities in Sustentacular Tissues	69
The Lining Membrane of the Cavity of the Cerebro-spinal Axis	69
Synovial Membranes	69
Articular Synovial Membranes	70
Vaginal Synovial Membranes	70
Bursal Synovial Membranes	71
Mucous Membranes	71
Cutaneous Membrane	74
Glands	75

EMBRYOLOGY.

By J. P. McMurrich.

	PAGE
Spermatogenesis	77
Oögenesis	78
The Early Stages of Development	79
The Umbilical Cord and the Placenta	83
Organs Derived from the Endoderm	86
The Teeth and Salivary Glands	86
The Branchial Clefts and the Structures Derived from them	87
The Trachea and Lungs	88
The Intestine and Mesenteries	88
The Liver and Pancreas	90
Organs Derived from the Mesoderm	91
The Skeleton	91
The Heart and Blood-vessels	93
The Diaphragm	97
The Lymphatic Vessels, the Spleen, and the Suprarenal Capsules	98
The Muscular System	98
The Excretory and Reproductive Organs	98
Organs Derived from the Ectoderm	103
The Nervous System	103

THE BONES.

By G. Woolsey.

PAGE

General Considerations 113

The Spine 115

The Cervical Group of Vertebræ 116
The Thoracic Group of Vertebræ 118
The Lumbar Group of Vertebræ 119
The Sacral Vertebræ 120
The Coccyx 123
The Spine as a Whole 124
Ossification of the Vertebræ 125

The Thorax.

The Sternum 127
The Ribs 129
The Costal Cartilages 131
The Thorax as a Whole 131

The Bones of the Upper Limb.

The Clavicle 133
The Scapula 135
The Humerus 138
The Ulna 142
The Radius 144
The Carpal Bones 145
The Scaphoid 146
The Semilunar 146
The Cuneiform 147
The Pisiform 148
The Trapezium 148
The Trapezoid 149
The Os Magnum 150
The Unciform 151
The Metacarpal Bones 151
The Phalanges 152

The Bones of the Lower Limb.

The Hip-bone 152
The Ilium 153
The Ischium 155
The Os Pubis 156
The Pelvis 157
The Femur 159
The Patella 163

PAGE

The Tibia 163
The Fibula 166
The Tarsal Bones 168
The Astragalus 168
The Calcaneum 168
The Cuboid 169
The Scaphoid 169
The Cuneiform 171
The Internal Cuneiform 172
The Middle Cuneiform 172
The External Cuneiform 172
The Metatarsal Bones 172
The Phalanges 173
The Foot as a Whole 175
Homologies of the Bones of the Two Extremities 176

The Skull.

The Bones of the Cranium.

The Occipital Bone 177
The Parietal Bone 180
The Frontal Bone 181
The Temporal Bone 184
The Sphenoid Bone 188
The Ethmoid Bone 192

The Bones of the Face.

The Maxilla, or Superior Maxillary Bone . 193
The Palate-bone 196
The Vomer 197
The Inferior Turbinate Bone 198
The Nasal Bone 198
The Lachrymal Bone 198
The Malar Bone 199
The Mandible, or Inferior Maxillary Bone . 200
The Hyoid Bone 202
The Skull as a Whole 203
The Sutures 203
The Exterior of the Skull 203
The Interior of the Cranium 209
General Morphology of the Skull . . . 212
Various Forms of the Skull 213

THE ARTICULATIONS.

By G. Woolsey.

General Considerations 215
Kinds of Joints 216
Kinds of Movement 217
The Articulations of the Trunk and Head . 217
The Articulations of the Vertebral Column 217
The Articulations and Ligaments between the Atlas, Axis, and Occipital Bone 220
The Articulations of the Thorax . . . 223
The Temporo-mandibular Articulation . 226
The Articulations of the Upper Extremity . 228
The Sterno-clavicular Articulation . . 228
The Scapulo-clavicular Articulation . . 229
The Shoulder-joint 230
The Elbow-joint 233

PAGE

The Radio-ulnar Articulations and Ligaments 235
The Wrist-joint or Radio-carpal Articulations 236
The Carpal Articulations 237
The Carpo-metacarpal and Intermetacarpal Articulations 238
Metacarpo-phalangeal and Interphalangeal Articulations 239
The Articulations of the Pelvis 240
The Articulations of the Pelvis with the Last Lumbar Vertebra 240
The Sacro-coccygeal and Intercoccygeal Articulations 240
The Sacro-iliac Joint 240
The Symphysis Pubis 242

PAGE
The Articulations of the Lower Limb . . . 242
The Hip-joint 242
The Knee-joint 246
The Tibio-fibular Union 250
The Ankle-joint 251
The Tarsal Joints 253
The Tarso-metatarsal and Intermetatarsal Articulations 255
Metatarso-phalangeal and Interphalangeal Articulations 256

THE MUSCLES.

By F. H. Gerrish.

General Considerations 259
The Nomenclature of Muscles 262

The Muscles of the Upper Limb.

Movements of the Upper Limb 265
Muscles Moving the Shoulder 267
Muscles Moving the Arm 272
Muscles Moving the Whole Forearm 277
Muscles Moving the Outer Part of the Forearm 280
Muscles Moving the Whole Hand 283
Muscles Moving the Fingers 286
Muscles Moving the Thumb 294

The Muscles of the Lower Limb.

Muscles Moving the Thigh 303
Muscles Moving the Leg 315
Muscles Moving the Whole Foot 322
Muscles Moving the Digits of the Foot . . 330

The Muscles of the Trunk.

The Muscles of the Back 339
Muscles in the Third Layer of the Back 339
Muscles in the Fourth Layer of the Back 341
Muscles in the Fifth Group of the Back 343
The Muscles of the Abdomen 345
The Muscles of the Thorax 348

The Muscles of the Neck.

Muscles of the Front and Side of the Neck 351

The Muscles of the Head.

Superficial Muscles of the Head 356
Muscles of Mastication 356
Muscles of Expression 358

THE FASCIÆ.

By F. H. Gerrish.

The Superficial Fascia 365

The Deep Fasciæ.

The Fasciæ of the Head 366
The Temporal Fascia 366
The Masseteric Fascia 366
The Buccinator Fascia 366
The Cervical Fascia 367
The Outer Cervical Fascia 367
The Middle Cervical Fascia 368
The Inner Cervical Fascia 368
The Thoracic Fascia 369
The Pectoral Fascia 369
The Clavi-coraco-axillary Fascia . . . 370
The Intercostal Fasciæ 370
The Fasciæ of the Shoulder 370
The Subscapular Fascia 371
The Supraspinous Fascia 371
The Infraspinous Fascia 371
The Deltoid Fascia 371
The Fascia of the Arm 371
The Fascia of the Forearm 371
The Posterior Annular Ligament . . . 372
The Fasciæ of the Hand 372
The Anterior Annular Ligament . . . 372
The Palmar Fascia 372
The Dorsal Fascia of the Hand 373
Fascial Sheaths of Tendons in the Hand 373
The Fasciæ of the Back 374
The Vertebral Fascia 374
The Lumbar Fascia 374
The Fasciæ of the Abdominal Cavity . . . 375
The Transversalis Fascia 375
The Iliac Fascia 376
The Pelvic Fascia 376
The Obturator Fascia 376
The Recto-vesical Fascia 377
The Fasciæ of the Perineum 378
The Fasciæ of the Hip and Thigh 379
The Fasciæ of the Leg 380
The Fasciæ of the Foot 381
Synovial Bursæ 382

THE BLOOD-VASCULAR SYSTEM.

THE HEART.

By F. H. Gerrish.

Descriptive Anatomy of the Heart 385
The Pericardium 393
The Situation and Relations of the Heart 394
The Physiological Anatomy of the Blood-vessels 395
The Arteries 396
The Capillaries 398
The Veins 398

THE ARTERIES.

By A. D. Bevan.

	PAGE
The Pulmonary Artery	400
The Systemic Arteries	401
The Aorta	401
The Arch of the Aorta	402
The Thoracic Aorta	403
The Abdominal Aorta	404
The Brachio-cephalic Artery	405
The Common Carotid Artery	406
The Left Carotid Artery in the Thorax	406
The Common Carotid in the Neck	407
The External Carotid Artery	409
The Internal Carotid Artery	417
The Subclavian Artery	419
The Axillary Artery	426
The Brachial Artery	429
The Ulnar Artery	431
The Radial Artery	435
The Branches of the Thoracic Aorta	441
The Branches of the Abdominal Aorta	442
The Common Iliac Arteries	447
The Internal Iliac Artery	448
The External Iliac Artery	452
The Femoral Artery	453
The Popliteal Artery	459
The Posterior Tibial Artery	460
The Anterior Tibial Artery	463

THE VEINS.

By G. Woolsey.

	PAGE
The Pulmonary Veins	468
The Systemic Veins	469
The Veins of the Heart	469
The Superior Vena Cava and its Tributaries	470
The Brachio-cephalic Veins	471
The Veins of the Head and Neck	471
The Venous Sinuses of the Cranium	477
The Veins of the Upper Extremity	481
The Superficial Veins of the Upper Extremity	482
The Deep Veins of the Upper Extremity	484
The Veins of the Thoracic Wall	484
The Veins of the Spine	486
The Inferior Vena Cava and its Tributaries	488
The Veins of the Abdomen	488
The Common Iliac Veins	490
The Portal System of Veins	491
The Veins of the Pelvis	493
The Veins of the Lower Extremity	495
The Superficial Veins of the Lower Extremity	495
The Deep Veins of the Lower Extremity	496
The Fœtal Circulation	497

THE LYMPHATIC SYSTEM.

By F. H. Gerrish.

	PAGE
The Lymph-vessels	499
Lymph-nodes and other Lymphadenoid Structures	502
The Nodes of the Head and Neck	505
The Nodes of the Upper Limb	508
The Nodes of the Lower Limb	509
The Nodes of the Thorax	510
The Nodes of the Abdomen	512

THE CEREBRO-SPINAL AXIS.

By F. H. Gerrish.

	PAGE
General Considerations	513
The Cavity of the Cerebro-spinal Axis	515
The Walls of the Cerebro-spinal Axis	519
A Diagrammatic Description of the Brain	521
The Prosencephalon—The Region of the Lateral Ventricles	524
The Cerebrum	524
The Surface of the Cerebrum	524
The Callosum	532
The Fornix	535
The Anterior Commissure	537
The Septum Lucidum	537
The Caudate Nucleus	539
The Lenticular Nucleus	540
The Claustrum	540
The Amygdaloid Nucleus	541
The Velum Interpositum	541
The Thalamencephalon—The Region of the Third Ventricle	546
The Thalami	547
The Internal Capsule	552
The Mesencephalon—The Region of the Aqueduct	553

PAGE
The Epencephalon—The Region of the Upper Part of the Fourth Ventricle . 555
The Pons 555
The Cerebellum 557
The Metencephalon—The Region of the Lower Part of the Fourth Ventricle . 561
The Oblongata 562
Internal Structure of the Oblongata . . 564
The Lemniscus 567
The Fourth Ventricle 568
The Spinal Cord (The Myelon) 569
The Membranes of the Cerebro-spinal Axis . 576
The Membranes of the Brain 576
The Membranes of the Spinal Cord . . 579

THE NERVES.

By W. Keiller.

The Cerebro-spinal Nerves . . 581
The Cranial Nerves 583
The First or Olfactory Nerve 585
The Second or Optic Nerve 586
The Third or Oculo-motor Nerve . . . 589
The Fourth or Trochlear Nerve . . . 592
The Fifth or Trifacial Nerve 592
The Sixth or Abducent Nerve 604
The Seventh or Facial Nerve 604
The Eighth or Auditory Nerve 608
The Ninth or Glossopharyngeal Nerve . 610
The Tenth, Vagus Nerve, or Pneumogastric 611
The Eleventh or Spinal Accessory Nerve 615
The Twelfth or Hypoglossal Nerve . . 615
The Spinal Nerves 617
The Ventral Primary Divisions 622
The Cervical Nerves 622
The Cervical Plexus 622
The Brachial Plexus 625
Branches given off above the Clavicle 625
Branches given off below the Clavicle 626
The Musculo-cutaneous Nerve . . 627
The Median Nerve 627
The Small Internal Cutaneous Nerve 631
The Internal Cutaneous Nerve . . 631
The Ulnar Nerve 631
The Circumflex Nerve 632
The Musculo-spiral Nerve 633
The Thoracic Nerves 638
The Lumbar Nerves 641
The Lumbar Plexus 641
The Iliohypogastric Nerve 642
The Ilioinguinal Nerve 643
The Genitocrural Nerve 643
The External Cutaneous Nerve . . 643
The Anterior Crural Nerve 643
The Obturator Nerve 645
The Accessory Obturator Nerve . . 645
The Sacral and Coccygeal Nerves . . . 646
The Sacral Plexus 647
The Pudic Nerve 650
The Great Sciatic Nerve 650
The Internal Popliteal Nerve . . . 651
Posterior Tibial Nerve 651
External Popliteal or Peroneal Nerve 655
Fourth and Fifth Sacral and the Coccygeal Nerves 657
The Sympathetic Nerves . . 658
The Sympathetic in the Neck 661
The Thoracic Portion of the Gangliated Cord 663
The Lumbar Portion of the Gangliated Cord 665
The Sacral Portion of the Gangliated Cord . 666

THE ORGANS OF THE SPECIAL SENSES.

THE SKIN 669

By W. Keiller.

Nails and Hairs 673
The Sebaceous Glands 676
The Sweat-Glands 677

THE TONGUE 678

By F. H. Gerrish.

Other Organs of Taste 680

THE NOSE 681

By W. Keiller.

The Nasal Cartilages 682
The Nasal Fossæ 682
Cavities Opening into the Nasal Fossæ . 684

THE EAR 686

By F. H. Gerrish.

The Internal Ear or Labyrinth 686
The Membranous Labyrinth 686
The Osseous Labyrinth 690
The Middle Ear or Tympanum 692
The External Ear 695

THE EYE 698

By W. Keiller.

The External or Fibrous Tunic 700
The Sclerotic 700
The Cornea 700
The Middle or Vascular Tunic 701
The Choroid 702
The Ciliary Zone 702
The Iris 703
The Inner or Nervous Tunic 704
The Vitreous 707
The Lens 707
The Aqueous 707
The Muscles of the Eyeball 708
The Superficial Appendages of the Eye . . 709
The Eyelids 709
The Conjunctiva 711
The Lachrymal Apparatus 712

THE ORGANS OF DIGESTION.

By F. H. Gerrish.

PAGE

General Considerations 713

The Mouth 716
The Lips 717
The Cheeks 717
The Hard Palate 717
The Soft Palate 718
The Teeth 720
Sets of Teeth 721
The Gums 725
The Tongue 725
The Extrinsic Muscles of the Tongue . 727

The Pharynx 728
The Tonsils 730

The Gullet 731

The Abdominal Cavity 732
Regions of the Abdomen 732

The Stomach 733
Tunics of the Stomach 735

The Small Intestine 737
Tunics of the Small Intestine 737
The Duodenum 740
The Jejuno-ileum 743

The Large Intestine 744
Tunics of the Large Intestine 744
The Cæcum 746
The Appendix 747
The Colon 748
The Ascending Colon 748
The Transverse Colon 749
The Descending Colon 749
The Sigmoid Colon 749
The Rectum 752
The Anal Canal 754

Glands Accessory to the Alimentary Tube 754
The Salivary Glands 755
The Parotid Gland 755
The Submaxillary Gland 756
The Sublingual Gland 756
The Pancreas 757
The Liver 759
Physiological Anatomy of the Liver . . 759
A Typical Lobe 759
Arrangement of the Vessels 760
The Form of the Liver 761
The Surfaces of the Liver 762
Borders of the Liver 765
The Extremities of the Liver 765
Tunics of the Liver 765
Supports of the Liver 766
Vessels of the Liver 766
The Bile-ducts 767
The Gall-bladder 767

The Peritoneum 769
Mesenteries 770
Omenta 770
Ligaments 771
General View of the Peritoneum 771
Retroperitoneal Fossæ 775

THE ORGANS OF RESPIRATION.

By F. H. Gerrish.

Physiological Anatomy 777
The Trachea 779
The Bronchi 780
The Bronchia 781
Minute Anatomy of the Lungs 782
Gross Anatomy of the Lungs 785
The Pleuræ 788
The Larynx 790
The Cartilages of the Larynx 791
The Ligaments of the Larynx 792
The Muscles of the Larynx 794
The Lining of the Larynx 797

THE URINARY SYSTEM.

By F. H. Gerrish.

The Kidneys 799
The Excretory Apparatus of the Kidneys . 807
The Ureters 807
The Bladder 808
The Urethra 810
The Female Urethra 810
The Male Urethra 812

THE DUCTLESS GLANDS.

By F. H. Gerrish.

The Spleen 817
The Thyroid Body 820
The Thymus 822
The Suprarenal Capsules 823
The Parathyroids 824
The Carotid Glands 824
The Coccygeal Gland 824

THE ORGANS OF GENERATION.

By G. D. Stewart.

The Male Organs of Generation.	PAGE
The Testicles	827
The Vas Deferens	833
The Seminal Vesicles	834
The Ejaculatory Ducts	835
The Scrotum	835
The Spermatic Cord	838
The Penis	838
The Prostate Gland	844
The Bulbo-urethral Glands	846
The Muscles of the Male Perineum	846
The Anal Group	847
The Genito-urinary Group	847

The Female Organs of Generation.	PAGE
The Ovaries	848
The Fallopian Tubes	853
The Uterus	855
The Vagina	862
The Vulva	864
The Mons Veneris	864
The Labia Majora	864
The Labia Minora	865
The Interlabial Space	866
Erectile Organs	867
Glands	868
The Muscles of the Female Perineum	868
The Mammary Glands	869

RELATIONAL ANATOMY.

By F. H. Gerrish.

Plane Sections	873
Surface Anatomy	883
Normal Skiagraphs	896

PRACTICAL ANATOMY.

By F. H. Gerrish.

Directions for Dissecting	909
Division of the Cadaver	911
The Thorax and Upper Limb	912
Thoracic Cavity	912
Front of the Arm	912
Front of the Forearm	912
The Palm	912
Back of Thorax and Upper Limb	913
Back of the Arm	913
Back of the Forearm	913
Back of the Hand	913
The Abdomen and Lower Limb	913
The Abdomen	913
Abdominal Cavity	914
Abdomen Proper	914
The Pelvic Cavity of the Male	914
The Pelvic Cavity of the Female	914
The Male Perineum	914
The Female Perineum	915
Front of the Thigh	915
Inner Side of the Thigh	915
Front of the Leg and Dorsum of the Foot	915
Outer Side of the Leg	915
Back of the Hip	916
Back of the Thigh	916
Back of the Leg	916
The Sole	916
The Head and Neck	916
Cranial Region	916
Inside of the Cranium	917
Back of the Neck	917
Side of the Neck	917
The Face	918
Temporal and Zygomatic Fossæ	918
Mandibular Region	918
Deep Parts of the Neck	918
Prevertebral Region	918
The Orbit	918
The Back	919

A

TEXT-BOOK OF ANATOMY.

INTRODUCTORY.

By F. H. GERRISH.

Definition of Anatomy, and Divisions of the subject.—Names and Delimitations of Surface Parts.—The Systems of Organs, and their Functions.—The Order of Topics.—Methods of Study.

ANATOMY is the science of organization. It treats of the structure of organized beings. Not all of the beings in the world can properly be said to have a structure. We may speak of the structure of a flower, however simple, but we never associate the idea of structure with a crystal. The flower has petals, and calyx, and stamen, and other parts, each differing in look, texture, strength, and use from all the rest. The crystal is of the same material and appearance throughout: it is a mass which is equally dense, equally strong, equally colored in one part as in another—it is homogeneous; that is to say, its physical qualities are evenly distributed. The flower is easily seen to have organs, each of which has its own peculiar office; the crystal has no organs whatever. The one is organized—it has a structure; the other is not organized—it has no structure. Therefore we may study the anatomy of a flower, but there is no anatomy of a crystal for us to study.

Let us here draw a distinction between the words *organized* and *organic*. The first relates to anything which has organs—parts which are differentiated from each other; the second is applied to things which result from the vital activity of organized beings. Thus, caseine, which exists in milk and is the characteristic material in cheese, is organic, for it is a result of the activity of a living creature; but it is not organized, having no structure, one portion being exactly like every other. Many things—for example, water—are neither organized nor organic; they are inorganic.

All organized beings belong to one or the other of two great groups—plants and animals. The distinction may not be essential; indeed, there are creatures upon the dividing-line between these groups whose nature is not yet determined—perhaps they are plants, perhaps they are animals. But, although it may be impossible to give a definition which shall include all of either group without taking in some belonging to the other, these terms are not in the least likely to mislead us. The study of the structure of plants is called *vegetable anatomy*, and is thus distinguished from *animal anatomy*, which has to do with the organization of the members of the other group of creatures.

Physiology is often used, carelessly, synonymously with anatomy, but they are absolutely distinct. Anatomy is the science of structure; physiology is the science of function. Anatomy teaches us what organs a plant or animal has; physiology teaches us to what use these organs are put. Anatomy shows what

an organ is; physiology shows what an organ does. Anatomy may be, and usually is, studied upon the dead creature; physiology can be studied only upon the living—it requires organization in action.

Of all animals, the human was the first whose anatomy was studied with great care. Naturally, men were more interested to know what they could about their own bodies than about those of other creatures; and when they did investigate the structure of the members of lower orders, it was to be expected that they would institute comparisons between the organs of the latter and those in themselves which seemed to correspond. Thus it came about that they called the science of the structure of all other animals *comparative anatomy*, to distinguish it from the science of their own organizations, which is *human anatomy*. If they had begun their study of animal structure at the other end of the scale, taking first animals of the simplest organization and working up gradually through a series, each member of which was more elaborately constituted than its immediate predecessor, until they reached man, the term comparative anatomy would not be used in the sense in which it is generally employed. But, although we recognize the defects of their method, we must confess that in the same circumstances we would doubtless have done precisely as they did. Now-a-days, however, the student is counselled to begin with simple and easily understood structures, in order to prepare himself for the readier comprehension of the more complex, and finally of the most intricate. The study of the anatomy of the lower animals is an admirable—indeed, the best—preparation for that of human anatomy. One who is familiar with the structure of one animal in the great group in which man belongs, as the cat, for example, will find human anatomy immensely simplified. But comparative anatomy, as a separate branch, has no right to a place in the course of study in a medical school, and only occasionally and incidentally will it be referred to in this book.

Human anatomy is subdivided, according to the means employed in its study, into two great parts: *gross* or *macroscopic anatomy*, in which no aids to vision are employed, and *minute* or *microscopic anatomy*, in which the assistance of optical instruments is used.

According to the method pursued in its study gross anatomy is subdivided into *systematic* and *relational*. Systematic anatomy, called also *descriptive anatomy*, regards the body as made up of systems or sets of organs. For example, considering the human being from this point of view, we find that it has a nervous system (brain, spinal cord, nerves, etc.), a circulatory system (heart, blood-vessels, etc.), a digestive system (stomach, intestines, etc.), an osseous system (bones, etc.), a muscular system (muscles, etc.), a respiratory system (lungs, windpipe, etc.), an excretory system (kidneys, bladder, etc.), a reproductive system (ovaries, testicles, etc.). Knowledge of the various organs comprised in each of these systems is essential to the practitioner of medicine and surgery. But if he knows each of these systems only in a separate and unassociated way, he is far from being equipped anatomically as he ought to be. He still needs to learn how each part of every system is related to each part of every other system, and particularly what are the relations of each object to all of the other objects in its neighborhood or region. In other words, he must know his anatomy not only from the systematic point of view, but from the *relational*. Other names given to this method of study are *regional anatomy*, because by it the body is divided into regions for investigation; *topographical* (from the Greek word meaning "place"), a term used by civil engineers to designate a survey in which the position of every part of the territory involved is determined relatively to every other part; *surgical*, because operations cannot safely be performed without knowledge thus acquired; *medical*, because it is necessary to accurate diagnosis of disease of internal organs.

Systematic anatomy is made possible by *dissection*, by which is meant the careful and delicate cutting apart of the various structures, so that they can be observed and studied. It is practised upon the dead body. Much of relational

anatomy also can be acquired in this way; but a very modern method has revealed a multitude of facts in this connection which were previously unknown, and are incapable of demonstration by dissection alone. This new method is that of *plane sections.* The sections are made in the following manner: a body is frozen so hard that a saw, in cutting through it, encounters no more resistance in bone than in muscle. Cuts with a saw are made in any direction which one chooses, but the most common are the horizontal, the vertical sidewise (also called "coronal" or "frontal"), and the vertical fore-and-aft (known also as "sagittal"). The cut having been made, the saw-dust is very carefully cleared away from the surfaces, and the relations of the parts which have been brought to view are studied. As an elevation of temperature above the freezing-point will impair the fixity of the specimens, and as it is manifestly out of the question to maintain such a degree of cold permanently or to study the specimens comfortably during its continuance, it is usual to photograph them, or immerse them in a preservative fluid in flat vessels covered with plain glass, or to adopt both of these devices for continuing the study. Students are not expected to do this work, which involves great labor, skill, and, for interpretation of the appearances of the sections, a high degree of anatomical knowledge; but they can avail themselves of the results of this method by studying the actual sections or casts of them in their medical schools, or, what is sometimes better because more intelligible, pictures of sections made from photographs and labelled in detail.

Minute or *microscopic anatomy* deals with those features of structure which are too small to be recognized by the unaided eye. It can be studied only with the assistance of a microscope. A branch of microscopic anatomy is *histology* (the name coming from the Greek word for "texture"), which is the science of the tissues. But the name histology has been much used synonymously for microscopic anatomy, the whole getting its designation from a part, as in many other cases in our language. Histology is sometimes called *general anatomy,* because the tissues are distributed to all parts—are general to the various organs.

A homely illustration will serve to make the difference between these various subdivisions of anatomy clear. We may use the word "anatomy" with reference to artificial structures, as, for instance, the anatomy of a steam-engine or of a watch or of a house. Let us, then, regard a house from the points of view successively of the systematic anatomist, the topographic anatomist, and the histologist. The first of the trio considers the house as made up of sets of organs, a series of apartments devoted to alimentary purposes, as the kitchen and dining-room; another set used for sleeping—the bed-chambers; one for study—the library, and so on; a system of tubes conveying water to various parts of the establishment; another lot bearing illuminating gas to every room; a third supplying steam or hot air for raising the temperature; and still another carrying off liquid waste materials; large, vertical pipes by which injurious products of combustion are conducted away; a quantity of wires adapted to the conveyance of electricity for various purposes within the house, and a set of rods designed to keep electricity out of it. Thus he finds whatever organs go to compose a house, and describes each set by itself, so that a person who desires to know about any system of apparatus—as, for example, that used for heating or that for sewerage—can learn about it by consulting the record of the investigator's observations.

The topographic anatomist approaches the question of the structure of the house in an entirely different way. He examines the building by such means that, without actually cutting it into slices, he is able to make drawings which show just what these plane sections would display if they were made. He does not concern himself with any separate system of rooms or rods or pipes or wires, but he studies the relations which obtain between all of the objects which he sees in each of his imaginary sections. For example, he observes that the parlor is related to the cellar below, to a bed-chamber above, to a library behind,

to a corridor at one side, and a roofed piazza on two sides. He notes the electric wires, the gas- and steam- and water- and waste-pipes within the walls of the room, the chimney which projects into it, and the relations which these sustain to the room itself and to each other. He proceeds thus until every region of the house is investigated and mapped out, and when he has done all this one can get from his records a complete idea of the relations of every piece of the structure to every other.

Finally comes the histologist, who, disregarding systems of organs and heedless of the relations between various parts, looks only at the structural materials entering into the composition of the house; in other words, its tissues. He finds that the house is made up of stones, bricks, boards, beams, nails, slates, and many other things, which present to the eye definite forms by which they are recognizable. It may be that some one kind of these structural elements varies in shape and in other respects in different parts, as, for instance, the bricks, which are of one form, size, and smoothness in the outside wall, different in all of these respects in the inner wall, and unlike either of the other kinds in the fire-places; but they are all readily seen to belong in the same category.

Each of these three methods of considering the house has its uses; each alone is seen to be inadequate to convey a comprehensive idea of the building. An architect employs all of them: he is, as regards houses, a systematic anatomist, a relational anatomist, and a histologist; he knows what the organs of a building are, how they stand in space with reference to each other, and of what textures they are constructed. For exactly the same reason every practitioner of medicine must be a human anatomist in all three of these ways. He finds one disease affecting a given system—as, for example, the alimentary—and therefore has to know the organs of this system as a continuous series; he meets with another disease involving, not a set of physiologically associated organs, but a number of parts which are related to each other in a geographical way, occupying a limited region, and consequently he needs to be acquainted with the organs or parts of organs belonging to half a dozen different systems. In either case he may be unable to appreciate the condition of affairs if he is ignorant of the tissues entering into the composition of the structures which are invaded.

The body may be considered anatomically from still other points of view. If it is in a state of health, the study of its structure is *normal anatomy;* if it is in a condition of disease, *pathological* or *morbid anatomy.* When the organization is studied with especial reference to function, we pursue the method of *physiological anatomy.* The consideration of the plan or model upon which organs are formed constitutes *morphological anatomy;* and as the discussion of such matters is attended necessarily with more or less of speculation, the synonyms *philosophic* and *transcendental anatomy* are often employed. The object which the investigator has in view determines the division of the subject. Thus, if he studies the body with the purpose of representing it in a pictorial or plastic way, it is *artistic anatomy;* if his only intent is to acquire knowledge which will be especially serviceable in the practice of the healing art, it is *applied* or *clinical anatomy. Practical anatomy* is a name employed to indicate the study of the body by dissection.

It will be understood, however, that we confine ourselves to human anatomy solely; that we regard it only in its normal aspects; that, unless otherwise specified, the adult condition is assumed; and that we consider anatomy chiefly with a view to the interest which it must have for the student who desires to fit himself for the work of the medical profession. This will involve the study of systematic, relational, and microscopic anatomy, and in the treatment of many topics all three of these methods will go along hand in hand. Frequently the physiological anatomy will be presented at the opening of a section, because it is so much easier to understand a machine if we enter upon its study with a distinct idea of the work which it is capable of performing, than if we have no notion of its function.

The following tabulation will aid in recalling the principal points which have been made:

- Anatomy
  - Vegetable
  - Animal
    - Comparative (all lower animals)
    - Human (man)
      - Gross, or Macroscopic
        - Systematic, or Descriptive.
        - Relational, Topographic, or Regional.
      - Minute, or Microscopic (Histology)

NAMES AND DELIMITATIONS OF SURFACE PARTS.

At the outset of anatomical study it is important to have the clearest possible conception of the limits set by nature or by convention to the various parts which will be referred to constantly in the following pages, and also to have for each of these parts a name which shall be used for that and for nothing else. All parts, even the minutest, have technical names, which are Latin in form, and almost all parts which are visible without dissection, and those which are brought into view by accident, have, besides the scientific, vernacular appellations—names given by non-medical people who never had a thought of knowing anatomy. The scientific name of a part is understood in every land where medicine is cultivated; the vernacular designation in one language is generally different from that in every other, and frequently essentially so. Thus, what we call "head" in English is "tête" in French, "kopf" in German, "testa" in Italian; and the anatomist who is acquainted with no modern language but his own can understand only that one of these words which belongs to his native tongue. "Caput," however, means the same thing to English, French, German, and Italian, for all scientific men are supposed to know something of Latin, the language of scientific nomenclature. Only a small proportion of the names applicable to anatomical parts is included in the vocabulary of the common people, but anatomists generally use these in their writings; for the suggestion of pedantry which inevitably would come from the invariable employment of the technical terms instead of the existing vernacular words would be almost intolerably offensive. Unfortunately, however, quite a number of these vernacular titles are used by anatomists with different significations from those which they have to the unscientific; and hence it seems necessary to explain what meaning we shall attach to these words, which have been familiar to us from the cradle.

It may seem to some readers needless to undertake this enumeration and definition. But a large observation of medical students through many years has demonstrated that it is highly desirable to do exactly this thing. People of much more than ordinary intelligence and education rarely have any idea of the difference between the meaning which many a word has to medical men and that which is attached to it generally. When a surgeon hears through a non-medical source that a person has broken a leg or an arm, he simply gathers the impression that a fracture is supposed to have occurred in a lower limb in the one case and in an upper limb in the other case; but if leg or arm is mentioned by a medical man, he knows that the third segment of the lower extremity is meant in the first instance, and the second segment of the upper extremity in the second. "Wrist" to the laity means anywhere from the upper level of the palm to nearly halfway up the forearm; "hip" is used instead of "thigh," mention of the latter, for some inexplicable reason, being at present considered even more indelicate than that of "leg," for which polite usage has substituted "limb." These few selections from a considerable number will serve, it is hoped, to justify the attempt which is here made in the interest of precision of language and of thought.

In order to understand the application of the terms intended to designate the relation in space which different parts of the body sustain to each other, it is necessary to know what is regarded as the *anatomical position*. This is the erect attitude, with the palms of the hands turned to the front, and the soles of the feet horizontal—that is, facing downward.

To the anatomist "head" (*caput*) means all of the mass which is balanced

on the neck, the front and lower portions being "face" (*facies*), the upper and back "cranium," the dividing-line between the two parts starting at the so-called root of the nose in the mid-line, and extending on each side beneath the overhanging brows and downward and backward to the ear. But "head," in common parlance, means at some times all that we have included, as in decapitation; at others only the cranium, as in the use of the word headache. "Face" with the people embraces the anatomical face and also the anterior portion of the cranium: a beautiful face would be considered desecrated if its picture showed nothing above the eyeballs. And yet "face" is often used in a more restricted sense than the anatomical, as when one speaks of faceache, meaning pain in the cheek region only.

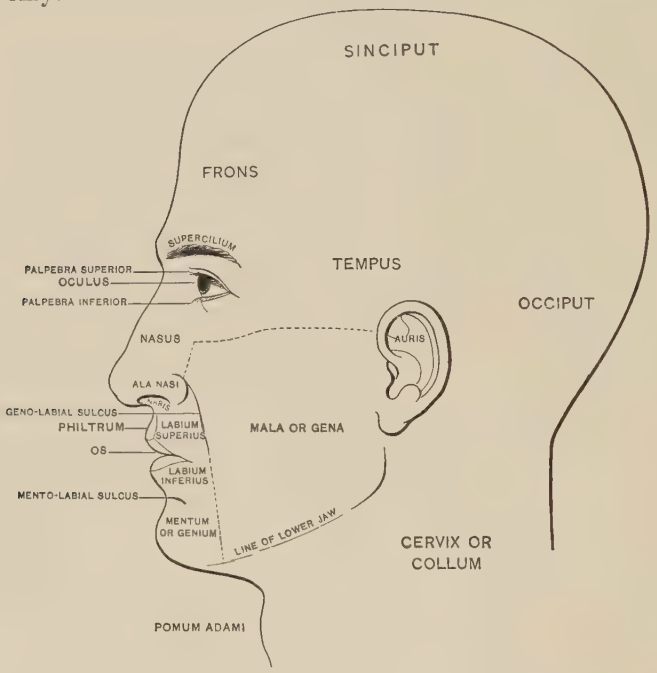

FIG. 1.—Side view of cranium and face. (F. H. G.)

The cranium is subdivided (Fig. 1) into an anterior part, the "forehead" (*frons*); an upper, the "crown" (*vertex* or *sinciput*); a back, the *occiput;* and, on each side, the temple (*tempus*). There are no surface-markings by which these are absolutely delimited. At the lower portion of the temporal region is the flaring part of the ear, known by anatomists to be the least important division of the organ of hearing (*auris*), but thought by people commonly to be about all of it, and consequently named "ear." The forehead terminates below at the "nose" (*nasus*) in the middle line, and on each side of this, in an arched border, usually covered with short, crisp hairs, and called the "brow" (*supercilium*). In the face immediately beneath each brow is an "eye" (*oculus*), that is, an eyeball or globe, shielded above by an "upper lid" (*palpebra superior*) and below by a "lower lid" (*palpebra inferior*), their edges fringed with short hairs, the "lashes" (*cilia*). Between the eyes and in the middle of the face, below their level, is the projecting part of the nose, which is all that is generally recognized as nose. This has on each side below an opening, presenting downward, the "nostril" (*naris*), guarded on the outer side by a flaring projection, the "wing of the nose" (*ala nasi*). What is commonly called the "bridge of the nose," a prominence caused by the nasal bones, has no technical designation. At a short distance beneath the nose is a transverse slit, to which, as well as to the cavity of which it is the opening, is given the name "mouth" (*os*). Above this aperture is the "upper

lip" (*labium superius*), and underneath it the "lower lip" (*labium inferius*). Popularly, the word mouth is often applied to the lips, as when a woman is said to have a pretty mouth—a comment which manifestly is not intended for the slit-like opening, and still less for the cavity behind it. (It may not be amiss to call attention to the fact that the Latin *os*, meaning a mouth, has *oris* for its genitive, and gives origin to our English oral; whereas *os*, meaning a bone, is *ossis* in the genitive, and thus stands behind our English osseous.) The upper lip extends vertically from the nose above to the free border below, and laterally to the crease which courses down and out from the hind border of the wing of the nose, and is called the *geno-labial sulcus;* the lower lip extends from its free edge above to a transverse crease, the *mento-labial sulcus*, which presents a downward concavity, and separates the lip from the chin. The middle portion of the upper lip projects farther downward than do the parts which bound it laterally, and its skin surface is marked by a somewhat triangular depression, the *philtrum*. The border of the skin of this lip describes a line which is a mark of beauty, and is called by artists the bow of Cupid. The "chin" (*mentum, genium*) is the central prominence which finishes the face below, in and near the mid-line. It is not distinctly separated from the cheeks. The main part of each lateral aspect of the face is the "cheek" (*mala, gena*), which presents a broad, quadrilateral expanse, bounded below by the inferior border of the lower jaw, behind by the vertical portion of the bone of this jaw, above by the lower margin of the orbit (the cavity lodging the eye) and by the ridge of bone running back from it, and in front above by the side of the nose, below this by the geno-labial sulcus and an imaginary line in continuation of this. The outlines of the lower part of the face are determined largely by its framework, the inferior jaw-bone (*mandibula*), which, with its various attachments and coverings, constitutes the under jaw (*maxilla inferior*). The upper jaw-bone is the staging upon which the greater part of the central zone of the face reposes. On separation of the lips the "teeth" (*dentes*) are seen projecting beyond the "gums" (*gingivæ*) in two arches with the convexities forward; and on depressing the lower jaw a view of the cavity of the mouth is obtained. In its floor we see the muscular "tongue" (*lingua*) with its rough upper surface; its roof is formed by the "hard palate" (*palatum durum*), and behind is the "soft palate" (*palatum molle*) hanging like a short curtain over the base of the tongue. Between the two upright ridges to which the soft palate extends on each side is the "tonsil" (*tonsilla, amygdala*), and beneath the pendulous veil of the palate we can see a part of the rear wall of a cavity for which the laity have no name, but which we know as the *pharynx*.

The "neck" (*cervix, collum*) connects the head and the trunk (Fig. 2). In front it extends from the level of the lower jaw to the "breast-bone" (*sternum*) in the middle line and the "collar-bone" (*clavicula*) on each side. These bones can readily be felt through the overlying structures. Behind, in the middle line, the neck extends from the base of the cranium to the seventh segment of the back-bone or spine, the tip of which can be both felt and seen projecting beyond the plane of any of its fellows above. Between this segment (*vertebra prominens*) and the collar-bones—that is, at the sides—there is no clear demarcation of the neck from the trunk when the upper limbs hang passively: there is usually an unbroken slope from the head to the peak of the shoulder. But if the shoulders are raised straight upward, a crease is produced which sharply indicates the boundaries of the neck for two-thirds or more of the distance, and suggests the line for the remainder. In this attitude of hunched shoulders the neck rises like a column from a depressed base. Although not exact in every respect, this technical delimitation of the neck is vastly more definite, as well as more restricted, than that which is in popular vogue concerning women arrayed in what is known as "full dress," whose necks, varying at different times according to the dictates of fashion, may find their lower limits anywhere between the collar-bones and the nipples in front, and between the vertebra prominens and

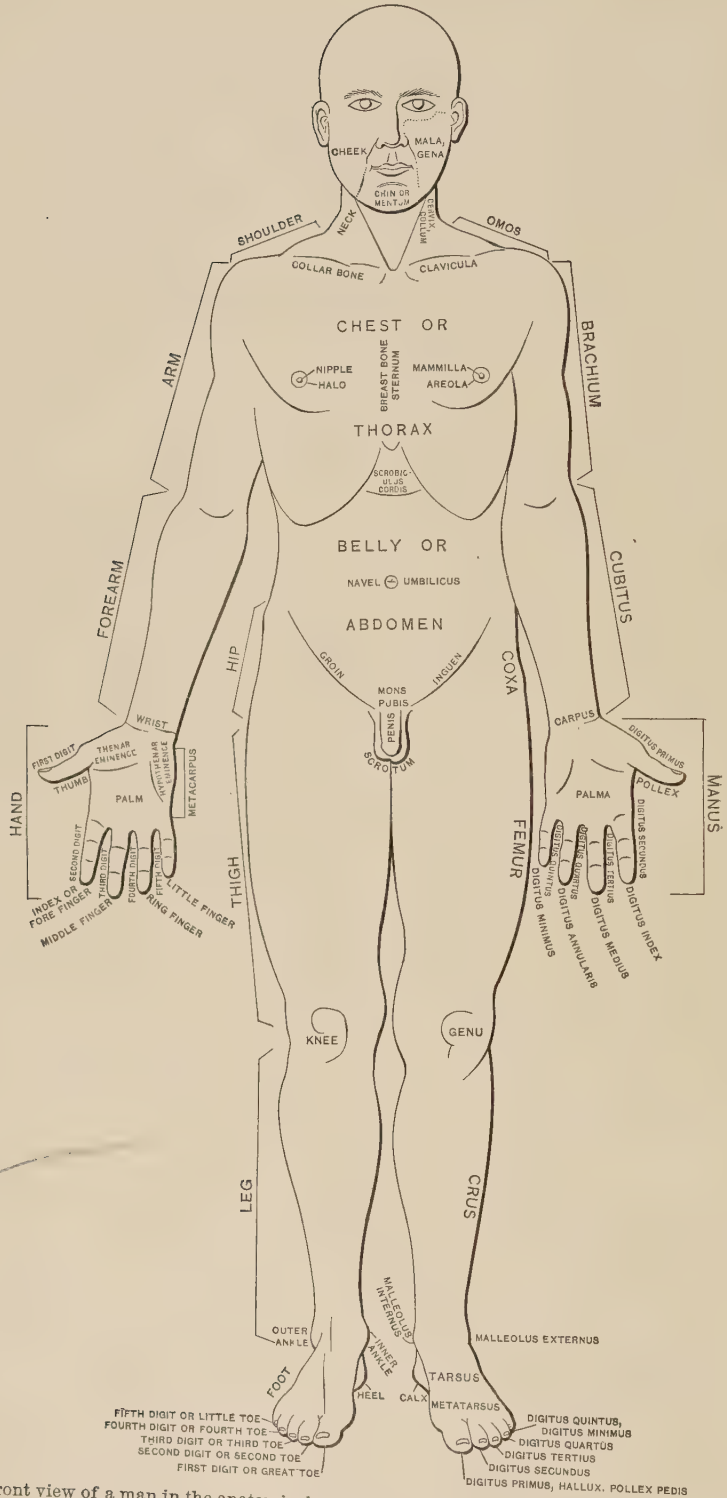

FIG. 2.—Front view of a man in the anatomical position. On one lateral half the parts are labelled in English, on the other in Latin. The right upper limb is drawn away from the trunk in order to show the arm more fully than is possible when it hangs perpendicularly. (F. H. G.)

the small of the back behind. The word "throat" has no anatomical equivalent. It is variously used to designate the front part of the neck, or the tonsils and adjacent parts of the soft palate, or the pharynx, or the organ of voice (*larynx*). High up on the neck in front is a hard protrusion, more prominent in men than in women, caused by the thyroid cartilage of the larynx, and called "Adam's apple" (*pomum Adami*) in playful celebration of the most noted and unfortunate gastronomic performance on record. The median portion of the neck behind is the "nape" (*nucha*). Just above the top of the breast-bone is often seen a little pit, esteemed a mark of beauty by artists, who have named it "Diana's pool."

The body proper, as distinguished from the entire organism, is known as the "trunk" (*truncus*), and presents two grand divisions, the upper of which is the "chest" (*thorax*), the lower the "belly" (*abdomen*). The superficial line of separation between them is pronounced, and is made by the bones and cartilages which form the lower border of the thoracic cage, as the skeleton of the upper cavity is called. Sloping downward and outward from the lower part of the breast-bone, the boundary-line is continued backward at the sides, and then obliquely upward behind. But this surface marking is by no means an indication of the relative size of the two cavities: it only shows the line along which is attached the base of a muscular dome, the *diaphragm* or midriff, whose central portion rises to the level of a point about halfway up the sternum, and shuts off the cavity of the thorax from that of the abdomen. Thus, the summit of the belly-cavity is rounded, presenting a marked convexity upward, and the base of the chest-cavity, into which the former rises, is correspondingly concaved.

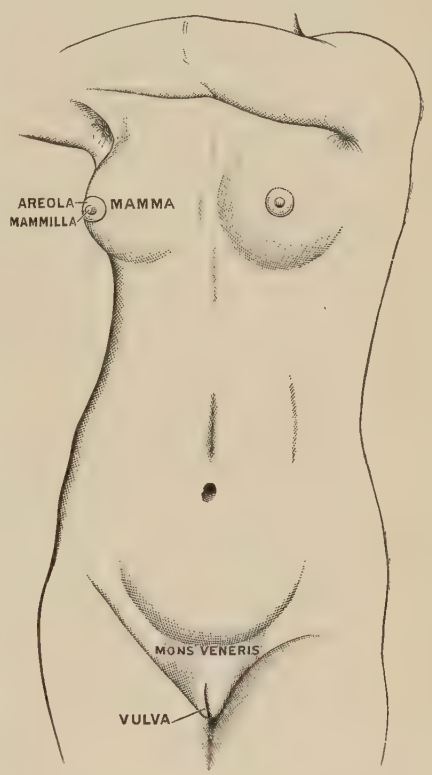

FIG. 3.—Front of torso of woman. (F. H. G.)

From the front of the chest of the adult female there projects a nearly hemispherical mass on each side (Fig. 3). This is the "breast" (*mamma*), the organ in which milk is formed. The valley between these hillocks is properly the "bosom," but this word is often used as synonymous with breast. At about the central point of each mamma stands out the nipple or teat (*mammilla*, literally "the little breast"), its base surrounded by a circular space which is distinguished by the darkness of its skin, and is called the *areola* (literally "the little area") or the "halo." The male has no milk-forming organ, but he has in the same relative situation upon the chest-wall slightly developed mammillæ, which indicate the position of rudimentary mammæ. These are good illustrations of a rule that the generative organs which are fully developed in one sex are aborted in the other, being represented in the latter by some little bulge or dimple, whose only use seems to be to suggest the narrow escape of its possessor from being of the opposite sex.

The belly at its upper central part presents a shallow depression, popularly called the "pit of the stomach," but technically *scrobiculus cordis*, which literally means "the little pit of the heart." This confusion of names arises from the physical (not the figurative) nearness of the heart and stomach, the one resting upon, the other lying underneath, the diaphragm, and both being in the region of this slight hollow. Farther down in the mid-line, and usually nearly on

a horizontal drawn between the highest points of the haunch-bones, is an irregular, puckered dimple, the "navel," called in Latin *umbilicus*, from *umbo*, the button in the centre of an ancient shield; so that we see that the childish name for the part—belly-button—has the sanction of a noble classical derivation. Following down in the middle line, we find at its lowest part an area which extends considerably sidewise, and is covered in the adult with crisp, curly hairs. This is the *pubes*. Behind the skin of the pubes the male has a little pad of fat, and the slight elevation which is thus produced is sometimes called *mons pubis*—that is, the mountain of the pubes. In the grown female there is so marked an accumulation of fat here as to make a very noticeable hillock, which is named *mons Veneris* (the mount of Venus), in honor of the Roman goddess of love.

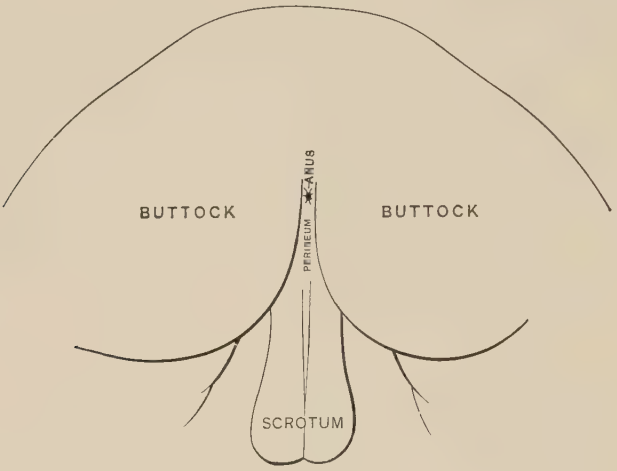

FIG. 4.—The male perineum and surrounding parts. (After His.)

Running obliquely upward and outward from the pubic region on each side is a crease which separates the trunk from the lower limb in front, and is called the "groin" (*inguen*). The name is usually applied to a narrow but indeterminate area of the abdomen immediately above this shallow furrow, and the adjacent area of the thigh just below it.

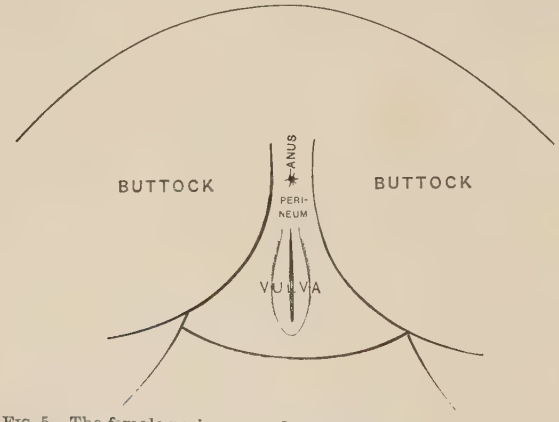

FIG. 5.—The female perineum and surrounding parts. (After His.)

Below the pubes are some of the generative organs—those which are superficially located, the external genitals (*genitalia externa*). In the male is the organ of copulation, whose technical title, *penis*, has practically displaced the entire

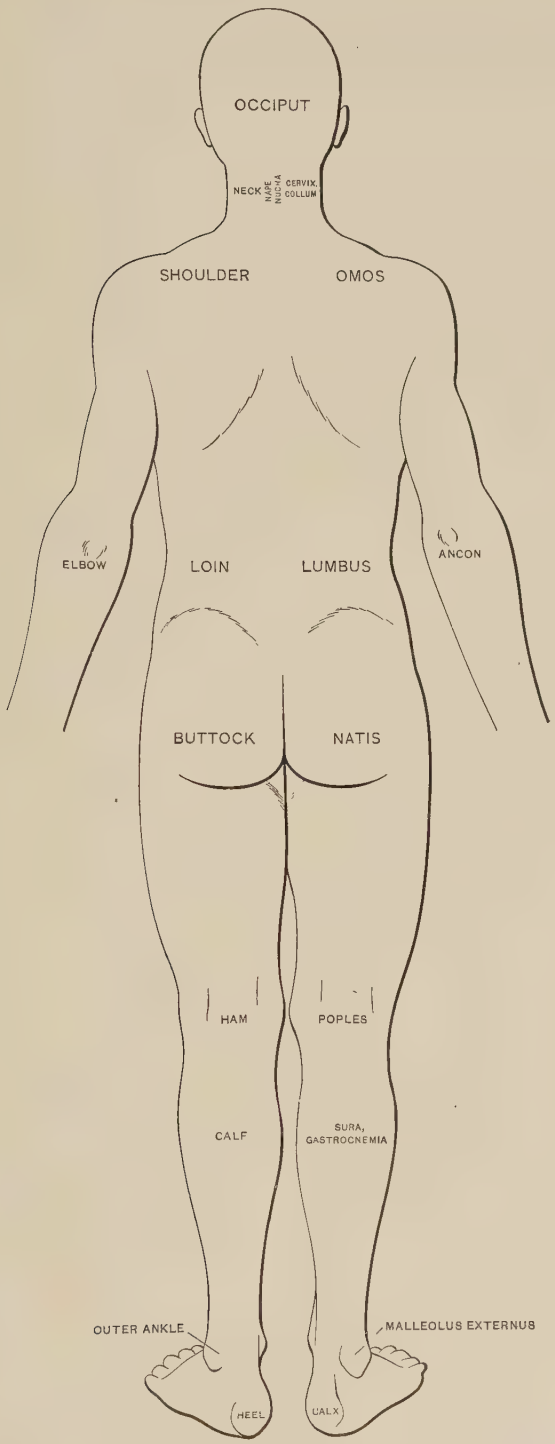

FIG. 6.—Back view of a man. On one lateral half the names of the parts are given in English, on the other in Latin. (F. H. G.)

group of Anglo-Saxon names by which it was formerly known. The free end of the penis, the "head," or *glans penis* (literally "the gland of the penis," from its resemblance to some internally located secreting glands), is covered by a long, movable fold of integument, the "foreskin," or "prepuce" (*preputium*). At the tip of the glans is a little slit, *meatus urinarius*, the termination of the common passage-way of the urine and semen. Behind the penis hangs the "bag" (*scrotum*) in which are suspended the essential male organs of generation, the two "balls" or "stones," which are more usually called by their Latin name *testes* (witnesses) or by the Anglicized diminutive of this word, "testicles." In the female the group of external genitals is designated by the name *vulva*, for which modern English dictionaries, with a fastidiousness not always imitated in popular speech, afford no single-word synonym. These structures are sometimes called *pudenda*, which means "things to be ashamed of"—as if such a criticism could justly be applied to the organs which are necessary for the perpetuation of the human race. The vulva presents a fore-and-aft cleft, which starts just below the pubes and runs backward between the thighs. This fissure is bounded laterally by thick folds of skin, *labia majora* (the greater lips), upon separation of which are seen the *clitoris* (which is the suppressed representative of the penis), two thin folds of membrane, *labia minora* (the smaller lips), the *meatus urinarius*, and the opening of the *vagina*, the tube which leads to the "womb" (*uterus*). Behind the external genitals of both sexes, between the thighs, and in front of the lower opening of the bowels is a narrow antero-posterior area called *perineum*, a word with no vernacular equivalent (Figs. 4 and 5). The rear limit of the perineum is marked by the outer opening of the *anus*, the terminal portion of the alimentary canal.

The posterior surface of the trunk (Fig. 6), generally called the "back" (*dorsum*), shows in the middle line from end to end a furrow in which appears a continuous series of bony prominences, each of which belongs to a separate segment of the pile of bones called the spinal column, or, naming the whole from a part, merely the spine or back-bone. Between the lower margin of the thoracic cage and the crest of the hip on each side, in the region known as the small of the back, is a "loin" (*lumbus*).

Projecting from the trunk are the "limbs" or "extremities" (*membra* or *extremitates*,) arranged in two pairs, an upper and a lower. Each pair has a bilateral symmetry, and therefore the statements which apply to one limb need not be repeated for its mate of the opposite side.

The "upper limb," "upper extremity," or "thoracic extremity" (*membrum superius*, *extremitas superior*, or *extremitas thoracica*) is divided naturally into four distinct segments. These, in regular order from above downward, are shoulder, arm, forearm, and hand. The "shoulder" (*omos*) connects the trunk and arm. The "arm" (*brachium*) extends between the shoulder- and elbow-joints. Beneath the shoulder-joint, and between the side of the chest and the arm, is a pyramidal space, with its base presenting downward, called the "arm-pit" (*axilla*). The "forearm" is known as *antebrachium*, which is the exact Latin equivalent of the English name, and also as *cubitus*, from which comes the name of a measure of length anciently employed. It includes all between the elbow- and wrist-joints. Its upper end is marked behind by a prominence, the "elbow" (*ancon*). The fourth and final segment of the upper limb is the "hand" (*manus*). This is subdivided into a proximal portion, the "wrist" (*carpus*), a central part, which constitutes the body of the hand, the *metacarpus* (meaning "beyond the carpus"), and a distal part, the "digits" (*digiti*). The front surface of the metacarpus is the "palm" (*palma*), and the hind surface is the "back" (*dorsum manus*). There are five digits to each hand, numerically named, beginning with that farthest from the median line of the body and counting inward. They have also other designations, which are used with equal or greater frequency. The first digit (*digitus primus*) is the "thumb" (*pollex*); the second (*digitus secundus*) is the "fore finger" (*digitus index*); the third (*digitus tertius*) is the "middle finger" (*digitus medius*); the fourth (*digitus quartus*)

is the "ring finger" (*digitus annularis*, from *annus*, "a ring"); and the fifth (*digitus quintus*) is the "little finger" (*digitus minimus*, literally "the least finger"). Each digit has three segments, except the thumb, which has but two.

The "lower limb," "lower extremity," or "pelvic extremity" (*membrum inferius*, *extremitas inferior*, or *extremitas pelvina*) is the homologue of the upper—that is, it is built on substantially the same structural plan.[1] It has four segments: hip, thigh, leg, and foot, which correspond respectively to shoulder, arm, forearm, and hand. Between hip and thigh is the hip-joint; between thigh and leg, the knee-joint; and between leg and foot, the ankle-joint. The "hip," or haunch (*coxa*), is so firmly united to the back-bone that it serves as a portion of the wall of the abdomen, the greater cavity of the trunk. Behind the hip and immediately below the loin is a large mass of muscle and fat, the "buttock" (*natis*). The "thigh" extends from the hip to the leg, and is technically called *femur*, which name is also applied to the single bone that forms its framework. The prominence in front at its lower end is the "knee" (*genu*), and the space opposite the knee on the posterior aspect is the "ham" (*poples*). The mistake of calling the buttocks the hams is often made, but has no justification. From knee-joint to ankle-joint is the "leg" (*crus*). Its rear bulge is the "calf" (*sura* or *gastrocnemia*, literally "the belly of the leg"), and the sharp vertical ridge in front is the "shin." At the lower end of the leg are two bony prominences, the "inner ankle" (*malleolus internus*) and the "outer ankle" (*malleolus externus*). *Malleolus* means "a little hammer." The "foot" (*pes*), like its homologue the hand, is divided into three parts—a hindmost, the *tarsus*, a middle, the *metatarsus*, and a foremost or distal, the "digits" (*digiti*). The "instep" of popular nomenclature has no equivalent in anatomical terminology, as it includes parts of both tarsus and metatarsus; and, on the other hand, there are no vernacular words corresponding to tarsus and metatarsus. The part of the tarsus which projects to the rear is the heel (*calx*); the top of the foot is its "back" (*dorsum pedis*); and the entire under surface is the "sole" (*planta*). The five digits are designated numerically, like their homologues in the hand, the count beginning, however, not at the outer end of the series, but at the inner—that nearer the median line of the body. Thus, the "toes" or digits of the foot (*digiti pedis*) are first, second, third, fourth, and fifth (*primus*, *secundus*, *tertius*, *quartus*, and *quintus*), respectively. But the first and last have other names also, the one being commonly called the "great toe" (*pollex pedis*, "the thumb of the foot," or *hallux*); and the other the "little toe" (*digitus minimus pedis*, literally "the smallest digit of the foot"). In giving the Latin names for the toes it is rarely necessary to employ *pedis* ("of the foot") to distinguish those of the lower extremity, as the context indicates which limb is concerned; and it is never essential to say *manus* ("of the hand"), as this is understood unless the contrary is obvious.

THE SYSTEMS OF ORGANS AND THEIR FUNCTIONS.

In studying anatomy the thoughtful learner is almost certain to conclude that he needs to know a great deal about every other part in order to comprehend fully the one which he has in hand. No organ, however simple, is independent: every one is so related to others, perhaps to many others, that they are absolutely essential to its life. In the same way it is true that some knowledge of many is necessary to the complete, or even sufficient, understanding of a single one. This fact constitutes a chief obstacle in the path of the anatomical student; but it may be diminished very considerably, and its residue rendered less discouraging, by his having presented to his mind at the beginning of his course a con-

[1] The difference between homology and analogy must be borne in mind. *Homology* relates to similarity of structure, *analogy* to likeness of function. The two do not always go together. For example, the upper limb of a man and that of a bird are homologous, because they are constructed on the same plan; but they are not analogous, because the one is used for prehension (grasping), and the other for locomotion (flying). The organization in the two cases is strikingly similar; the function is radically different. But compare the wing of a bird with that of a butterfly; both are devoted to the same use—namely, flying; but they are essentially different in structural plan, as can be seen on the most cursory inspection. Therefore they are analogous, but not homologous.

cise recital of the principal organs of the body and a statement of the chief function of each. In this way he will learn a number of most useful anatomical facts, and they will be grasped all the more readily because they are strung on a physiological thread. In the few succeeding pages an effort is made to afford the student just this assistance.

Organs Removing Waste Matters.

The human body is a machine, and, like every other machine, wears out in using. We all know that even in circumstances favorable for the preservation of a corpse, such as coolness and dryness of the atmosphere, it undergoes destructive changes so rapidly that before many days have passed what was once an object of beauty and the occasion of delighted admiration becomes altogether grewsome and revolting. And yet, swift as is this putrefaction, the wearing out of the tissues in life is more speedy. The greater the physical activity of a man, the more rapidly are his textures broken down. Every movement, however trifling, every glance of the eye, every thrill of sensation, every thought or emotion, is attended with destruction of substance. The products of this waste are poisonous, and if retained in the system in any considerable amount cause sickness and even death. But there are channels by which these effete and toxic materials are continually escaping—namely, the *lungs*, the *skin*, the *kidneys*, and the *bowels*. Water, the common vehicle in the body-changes, carries them out in solution. The solvent and vehicular services of water are very manifest in the case of the urine, which is loaded with the waste escaping through the kidneys; and they are often as plain in the case of the perspiration, which contains the effete matters discharged through the skin. The excrement which comes from the bowels is not in solution when it appears, but this is due to its loss of water subsequently to its formation and during its detention in the intestine. Other products of decomposition are borne out with every expired breath, this being saturated with water, as appears by its visible condensation whenever the surrounding air is sufficiently cooled.

The Vascular System.

At this point there naturally arises the question of the means by which the various effete materials that are constantly being formed in every part of the body get to the four outlets named. This carriage is accomplished by the vascular system, which consists, first, of a complicated series of tubes, the *blood-vessels*, connected with which is a powerful organ, the *heart*, which drives the blood in a continuous current through them; and, second, of another set of tubes, the *lymph-vessels*, whose stream of lymph flows into that of the blood. Almost everywhere in the body there are minute crevices between the elementary particles and threads of the tissues, and into these chinks the textures discharge their wasted molecules, always in solution in water. These tissue-crannies communicate with little cylindrical tubes, into which the liquefied waste is poured. The tubes are lymph-vessels, and they conduct their contents to certain blood-vessels, where it mingles with the current of blood. Some effete matters pass from the tissues directly into the blood. The blood is contained in and completely fills the heart and the blood-vessels associated with it, these being, first, the arteries, which are tubes through which the blood flows from the heart *to* the tissues; second, capillaries, microscopic tubes of wonderful thinness and delicacy, through which the blood flows *in the midst of* the tissues; and, third, veins, through which the blood flows *away from* the tissues. The heart, which is a kind of force-pump, drives the blood through this great system of tubes in a ceaseless stream, and thus brings it in practical contact with the tissue-elements that make up the various organs. When the blood, laden with impure matters from every part of the body, comes to one of the organs (kidneys, lungs, bowels,

or skin) which is capable of withdrawing decomposition-products from it, the particular poison which this organ can abstract is removed, and the blood is by just so much rendered less impure. Coming to another one of them, it gets rid of the foul material which can be unloaded at this door of exit; and so on at the others. The lungs are sewers for certain excrementitious substances, the kidneys for others, the skin for a third group, and the intestines for the remainder. In this way are eliminated all of the materials which result from the constant wearing out of the body.

Organs Supplying Nourishment.

If there were no compensation for the destructive changes which are going on incessantly, in a very short time every life would cease. But just in proportion to the extent of the waste, and practically simultaneously with it, repair takes place. As an old particle lapses from a tissue a new one supplies its place without delay, even as the ranks of an army, though constantly suffering from the ravages of disease, death, and desertion, are kept full by the enrolment of fresh recruits. The portals of the body by which the new materials are introduced are the respiratory and the alimentary organs.

First of all in importance is the *respiratory system*, which embraces the nasal passages, the pharynx, the larynx, the windpipe, the bronchi, the bronchial tubes, and the lungs, the last being the essential parts. But some critic observes immediately that the lungs have been mentioned already as channels of elimination. Very true, but they are also channels of appropriation. Not only do they expel vile and injurious waste matters with every outgoing breath, but they admit to the blood pure and sustaining nutrient material with every incoming breath. Here is one of the economies of nature—the wagon is never empty: it carries out the offal and it returns with a load of food. Second, we have the *alimentary tube*, with its attendant organs, the *salivary glands*, the *pancreas*, and the *liver*. This tube is very long, including the mouth, part of the pharynx, the gullet, the stomach, the small and the large intestines, the last mentioned having, like the lungs, the double and contrary functions of appropriation and excretion. It is furnished with apparatus by which solid food can be chopped, crushed, moistened, and reduced to a pulp, and other contrivances which dissolve and change the food in various ways until it is in such condition that it can pass through the walls of the tube and enter the capillary blood-vessels and lymph-vessels, which form fine networks in the substance of its walls. Passing into these two sets of vessels by the process of absorption, some of it reaches the blood immediately, and the remainder somewhat indirectly by way of the lymphatics. The blood, therefore, is seen to be enriched by gaseous material in the lungs and by liquids and liquefied solids in the alimentary tube. All of these additions are brought by the veins to the heart, and thence are pumped into the arteries. The latter pour their contents into the capillaries, which are embedded in the tissues. These minute vessels are so thin that the nutrient substances in the blood can pass through their delicate wall, come into direct contact with the tissues, and flood them with food. To each tissue is offered a repast substantially identical with that furnished to every other, but no two of them choose the same articles from this sumptuous table, each having a selective capacity for those things which are best adapted to the preservation of its own peculiar characteristics. So, each tissue having appropriated whatever it needs, the residue of the nutrient material is carried away by the lymphatics along with the waste products already mentioned. It will be observed that it is the vascular system which takes supplies to the tissues, and the same system which carries from them the products of waste.

In connection with the alimentary tube were mentioned, as accessory parts, the salivary glands, the pancreas, and the liver. These are true glands—that is, organs which abstract certain materials from the blood, manufacture them into

new substances, and discharge these last into cavities or upon surfaces. The salivary glands empty their products into the mouth; the pancreas and the liver pour theirs into the small intestine; and these fluids—saliva, pancreatic juice, and bile—effect certain digestive changes in the food.

Organs of Internal Secretion.

There are other organs which resemble true glands in their general gross appearance, but are unlike them in an important respect: they have no tubes through which their products can be discharged upon a surface or into a cavity, and hence they are called ductless glands. They are the spleen, the thyroid body, the thymus, the suprarenal capsules, the hypophysis, the parathyroids, and the carotid and coccygeal glands. It is supposed that they furnish substances which produce a profound impression upon nutrition, and that these matters, as soon as formed, are thrown into the blood, whence the material for their formation was originally derived.

Organs of Motion.

Certain organs are devoted to the work of movement. Through their instrumentality man is enabled to seize and retain his food, to defend himself from and to assail his enemies, to move about from place to place, and to do numberless other acts in which motion is the principal factor. The organs giving man such power are *muscles*. They form the most of the bulk of the limbs and a great part of the walls of the cavities of the trunk. The lean meat of animals, which is a part of our food, is muscular tissue.

Framework Organs.

All of the organs of the body are held in suitably close relation to each other, and are yet kept from crowding together with injurious force, by certain structures which are called skeletal. The most striking and familiar of these are the bones, which form a stable framework for the various parts, a strong protective wall for cavities containing organs of great delicacy, and powerful levers upon which the muscles act. Cartilages are usually closely associated with bones, but there are cases in which cartilages by themselves perform just such services as bones more commonly do. However conspicuous these hard structures may be in their peculiar line of work, it is doubtful if they are of more use in the animal economy, even in their peculiar province, than are certain soft, flexible tissues. The fibrous tissues do almost all of the minute detail of support, the bones and cartilages being devoted only to the coarser kinds. All through the organs is a fine network of these tissues, furnishing a veritable skeleton for the microscopic elements of which the organs essentially consist. There are also substances which serve as stuffing and cushion-material for various parts.

Organs of Relation.

Of all the organs, those constituting the nervous system are the most exquisite in structure and the highest in function. They are the *brain*, the *spinal cord*, numerous small collections of nervous tissue called *ganglia*, and a great number of cords, the *nerves*, each of which has a connection at one end with some one of the nervous masses above mentioned. The nervous system gets its proper share of attention from the other organs which have been spoken of as engaged in carrying off waste, furnishing material for repair, moving parts or the whole of the body, and doing the passive service of framework. But it acts as if it recognized the great obligation resting on nobility, and it returns the devotion of its humbler neighbors by services of the most exalted order. It regulates and harmonizes the operations of all of the other parts, keeping them up to their work, restraining them if a tendency to overdoing appears, sustaining the equilibrium of all the functions. But, in

addition to all this, it brings the individual into conscious relation with the world around him through the medium of the organs of special sense. Without this last service our lives would be purely vegetative.

Organs of Reproduction.

The functions of the organs thus far mentioned concern only the individual, providing, first, for his preservation, and, second, for his relation to the things around him. There are other organs—not, however, in a condition of functional activity during the whole of life—which are necessary to the preservation of the race. These are the organs of generation. One series of them is present in the female, and its chief members are the *ovaries*, which furnish eggs; the *Fallopian tubes*, by which the eggs are conducted to the womb (uterus); the *womb* itself, in which the eggs, if fertilized, may remain during the period of pregnancy; the *vagina*, which receives the penis of the male in copulation and gives passage to the young when the time for its birth has arrived; and the *mammæ*, from which the progeny obtain sustenance for a considerable period. The other set of organs belongs to the male, and its principal parts are the *testicles*, which furnish the essential part of the semen for the impregnation of the eggs; certain *tubes* by which the semen flows to the *urethra*, the conduit common to the urine and the generative fluid; and, finally, the *penis*, the member by which sexual connection is effected and the male product deposited in the female generative passages.

THE ORDER OF TOPICS.

The chapters in this book are arranged substantially in the conventional order. First comes a brief presentation of the elementary tissues, followed immediately by a chapter on embryology. Then succeeds the descriptive anatomy, in which the organs are treated in systems, and after this the topographical, which deals with the relations of the different organs to each other.

That the account of the histologic materials composing the various organs should precede the description of these structures, and that the mutual relations of the latter should not be presented until the organs themselves have been described, are so logically necessary as to require no explanation. But the succession of topics in the systematic anatomy should be made to vary according to circumstances.

If the learner is studying anatomy only, the arrangement set forth in the table of contents is useful. But if he is studying physiology at the same time, he would do well so to modify the order that he may obtain a knowledge of the structure of each organ just before its function is considered. As physiology is concerned largely with the contents of the cavities of the body, this plan will involve the study of the viscera, including the brain and cord, early in the course. Any hours which are fairly due to anatomy and are not consumed in this preparation for the profitable study of functions should be devoted to osteology, and after this has been mastered the topics would best be taken up in the order as stated—joints, muscles, fasciæ, vessels, and nerves.

METHODS OF STUDY.

Any work which is done according to a prearranged system is more economical of time and effort and more productive of desirable results than that which is done in an unmethodical way. It is particularly important for the student of anatomy to follow lines wisely laid down for his guidance, because of the limited time at his disposal in which to acquire a mastery of the multitude of facts needful for his subsequent progress. Some words of counsel, therefore, are here offered as to the methods of study which experience has shown to be advantageous.

Merely reading the text-book is productive of but little good. Many a man who has done this faithfully is utterly unable to answer a question which would be likely to be included in the list prepared by any competent board of examiners. The facts are so numerous, and often so seemingly unrelated to each other, the names of objects are so unlike anything previously known, and the allusions are so frequent to matters which must remain unexplained until a later part of the course, that it is wellnigh impossible to bring away from a single reading, however careful, much more than a chaotic impression of the subjects considered. Some students in their desperation resort to the plan of verbal memorizing—learning word for word the descriptions in the book. It is hard to conceive of a method more wasteful of energy and less fruitful of results. One who has done this may be able to pass a brilliant oral or written examination, but he has not begun to be an anatomist; he is helpless in the presence of the dissected subject, and incapable of using what he has studied in any practical way. A student should not allow himself to adopt this method. He must learn the facts in such a way that a permanent image of every object is produced in his mind, and thus his knowledge will be available at the bedside. Of course it is necessary to acquire a nomenclature—to learn the names of the objects dealt with—for without these labels of things it is impracticable to receive information, to retain it easily, or to impart it after it has been gained. But this is a vastly different thing from committing to memory the precise phraseology in which any author, however learned and eloquent, has framed his presentation of the facts. The clearer and more forcible a statement in the book, the better is it for the student; but, the idea having been grasped, its clothing of words should be ignored. The student should be satisfied with nothing less than such a comprehension of the fact that he can lucidly convey it in his own language to one who never heard of it before.

It is generally very advantageous for the student to have before him the object while he is reading the description of it, for thus he is able to verify or correct the account which is given, and to get more concrete and enduring ideas of the various qualities of the thing itself. When osteology is under consideration, it is not difficult to pursue this ideal course; for even if the student cannot afford to buy a complete articulated skeleton, he can obtain by a small expenditure a sufficient number of separate bones to supply almost all of his needs. The little outlay required for this purpose will be more than justified by the returns, however impecunious he may be.

Many of the organs cannot be preserved in such condition that they can be studied to advantage in any such way as can the bones; but as substitutes for them we have casts and models—the former representing exactly the external form, size, and color of the originals, the latter in many cases doing this and also showing some details of internal structure. Both casts and models may be more instructive to the beginner than the objects for which they stand, even supposing the latter to be entirely normal, inasmuch as the real specimens are generally so soft and flabby that they do not retain their shape as do their artificial representatives, which are made of rigid materials and possess the additional merit of comparative indestructibility and can be used year after year without appreciable diminution of value. When minute parts are in question models are far preferable to the real objects, as they are of colossal size. The pigmy organ tells its story in a tiny voice which we cannot understand unaided; the giant model shouts its message in tones which a whole roomful of people can hear.

But even casts and models are usually not available except in medical schools, and we are consequently driven to employ pictures, which, fortunately, are to be had in such abundance and of so admirable quality that we often hardly miss the the really ideal means of illustration. Every one learns more quickly from a good pictorial representation than from the best description, for the mind stores up the impressions of form and color which enter it by the channel of sight far more eagerly and tenaciously than it does those which reach it by way of spoken

words. Where the subject is very complex, a diagram is commonly more useful than the best pictorial representation, because it eliminates everything but the essence of the matter, and thus does not confuse the mind by too vast an array of facts. The student, however, should scrupulously avoid allowing himself to be content with a merely diagrammatic knowledge of any part of anatomy: he should use the schematic picture only as a prelude to the actual thing, as the map which informs him where and how to find and learn about the unknown land and its contents.

Although descriptions, diagrams, pictures, models, and casts have their distinct value, each in its peculiar field, it must never be forgotten that after learning all which they can teach it is of the greatest importance to have contact with the natural object. Dissection of the dead body supplements and rounds out the knowledge which has been previously gained, and its service is indispensable. It is not well to attempt dissection until one has learned by other means the principal facts about the part to be dissected, because without such antecedent knowledge material, which in most places is scarce and costly, will be wasted by unintelligent cutting. But after the student has qualified himself to appreciate the views which can be obtained only in the anatomical laboratory, he should embrace every opportunity to dissect, for thus only can he become a practical anatomist. When a human body cannot be procured for this work, the manual dexterity which is so important an accomplishment for a surgeon may be cultivated by the dissection of cats, dogs, and other animals, which are abundant and cheap; and this practice is a most desirable preparation for the study of human anatomy for other reasons than the mere skill in the use of some instruments which it bestows.

Among the aids to the acquisition of anatomical knowledge, two which are but little appreciated deserve especial mention.

The first of these is the recitation. In this exercise the student is obliged to describe the things which he has been studying. This is a severe but most wholesome test of his knowledge. By it his attention is attracted as in no other way to the defects of his attainments. Some matters which he had flattered himself were perfectly understood are found to have been only partially learned, and in others he discovers that he has acquired mistaken notions. The ability to describe a thing clearly and fully to others is a convincing evidence of attainment, and the exercise of it is a capital method of fastening the truth in the mind. If possible, the student should associate with himself another of the same class, and no day should be allowed to pass without a serious, exacting quiz, the two alternating in the office of questioner.

Valuable as are the quiz and recitation in correcting and increasing one's knowledge, they are almost equalled in these respects by drawing. Sight and touch give an excellent idea of the form of a bone, but the information gained by these means is greatly intensified by making a free-hand picture of it; and in the process one is almost sure to see features which were not previously appreciated, and to rectify some faulty opinions. The same is true of all other objects, and the student is earnestly advised to make a drawing of every one of his dissections. If the natural objects are not available, he should draw the casts and models which he has the privilege of studying, and, in default of better representations, even the pictures in his text-book.

But the objection is at once raised that only a few peculiarly gifted persons are capable of drawing. It is not uncommon to hear men declare that they cannot learn to draw. This statement, however, is absurdly incorrect, for every such objector can already write, and writing is nothing but the drawing of certain arbitrary characters. One who makes a capital A can surely outline a tent; if he can make an S, he can draw a wriggling snake; in forming an X he has pictured a St. Andrew's cross; and thus every one who signs his name demonstrates his ability to draw. The talent is undoubtedly more marked in some persons than in others, but is possessed in some degree by all; and, however

slight it may be originally, it can be cultivated to such an extent as to be wonderfully serviceable to the medical student.

Although the few succeeding paragraphs are not specifically anatomical in their bearings, they have a pertinency in this place because every medical student at the beginning of his career should be given the advice which they carry and which he is unlikely to find elsewhere.

Among the articles of equipment which a medical student needs none is more important than a good medical dictionary. It is an indispensable. If he ignores its aid, he is doomed to stumble and blunder in every direction; if he accepts the assistance which it will give for the asking, he can progress readily and vigorously in all the paths of medical study.

A medical dictionary, in order to be thoroughly serviceable, ought to possess the following characteristics: The inclusion of substantially all of the words employed by the English-writing medical authors of the time; the arrangement of these words in alphabetical order; the various accredited spellings of the words; the pronunciation of those words on whose orthoëpy one might go astray; the etymon or original form of each, and the simplest translation of it; and a concise definition of the word in each signification in which it is employed. Several lexicons constructed on these lines are available, any one of which will do good service; but one which is less ample will not satisfy the reasonable requirements of the student.

Although the so-called Roman pronunciation of Latin is generally taught in the schools and colleges of this country, the dictionaries, for sufficient reasons, use the English pronunciation of the Latin and Latinized words which form the principal part of the vocabulary of medicine; and this method is recommended to the student for his adoption.

The student is earnestly advised to establish the habit of consulting his dictionary whenever he encounters a word whose meaning he does not know. He should fix the spelling in mind, learn the definition, observe and remember the derivation, and repeat the proper pronunciation until the tongue has fully mastered it. Finally, he will do well to ascertain the kinship of the word, if any exists, to other words already known, and to group these all together in his memory as relatives. By this method he will rapidly acquire a large vocabulary, the ability to employ words with strict regard to their meaning, to spell correctly, to pronounce elegantly, and, as an accompaniment and result of this training, he will be content with nothing less than precision of thought.

ELEMENTARY TISSUES,

AND THE STRUCTURE OF MEMBRANES AND GLANDS.

By F. H. GERRISH.

A FULL presentation of microscopic anatomy would require a large volume. It is the main purpose of this chapter merely to give a brief description of the elementary tissues which enter into the formation of the body. Without a knowledge of these primary textures much that must be said of the gross anatomy of different parts will be unintelligible; indeed, it is impossible to understand any organ, either from the anatomical or physiological point of view, unless the materials of which it is composed and the various physical properties of these substances are known with perfect familiarity; for the tissues are to the organs as the letters of the alphabet are to written words.

The minute structure of the viscera will be described in connection with the macroscopic features of each organ in turn.

CELLS.

The word "tissue" means, in ordinary parlance, a web-like structure or a woven fabric. Anatomically, it is applied to any organized substance in the body. Notice that in this definition the word "organized" is used, not "organic." The latter would, indeed, exclude the substances which are inorganic—that is, all of the ultimate elements, of which there are many in the body—leaving them to the consideration of the chemist; but it would include quite a number of substances found in the body which, although organic, have no title to be called structures, and belong in the domain of the physiologist, who deals with the proximate principles. Thus, albumin and fibrin are organic substances, but not organized; and, consequently, they are not tissues, for tissues are always organized.

Every tissue originally consists of microscopic particles, named "cells," which have been aptly called the simplest expression of tissue. Etymologically, the word "cell" is an unfortunate designation, based upon a mistaken belief as to the structure of the corpuscle. At first it was thought that cells were cysts, sacs, vesicles, with fluid contents. But it was long ago learned that they are usually solid bodies, and hence a word which implies the existence of a cavity, as does "cell" (Latin, *cella*, "a small, hollow cavity"), is a misnomer in the majority of cases. However, the substitutes proposed have not met with general favor, and "cell" has become so firmly fixed in our nomenclature that we shall not attempt to displace it; indeed, there is no call to do so, since no confusion need arise from its use in this arbitrary sense.

Not only is it true that all of the tissues primarily are composed of cells, but, going back much farther than this, we recognize the origin of the entire body from a single cell, the ovum (egg). This enforces the saying, which has become almost an axiom, that every cell comes from a pre-existing cell.

Of the numerous definitions of cells, that which seems most exact is the *ultimate morphological elements of the tissues*. It is not sufficient to say that they are the "ultimate elements" of the tissues, because that term refers to their chemical constituents: it is necessary that the definition should include a word which explains that the elements referred to have a definite, distinguishable, and characteristic shape, and this requirement is fulfilled by the word "morphological," the adjective from "morphology," the science of form. Thus is conveyed the idea that in histological analysis—which is to the microscopic structures what dissection is to the macroscopic—we do not go beyond the cell; that this is the last thing reached by the process; and that in all of the textures it has such definiteness of form as to enable us to differentiate one tissue from another.



FIG. 7.—Diagram of a cell. (F. H. G.)

The typical cell (Fig. 7), capable of development and reproduction, is a round or ovoid mass of protoplasm in which is a nucleus.

Protoplasm (from Greek words meaning "the first" and "the thing formed") is a substance whose properties underlie the vital functions, and therefore it has been called the physical basis of life. It is homogeneous, soft, and jelly-like, and possesses contractility—the power of shortening a diameter, of drawing one of its parts nearer to another. It usually looks granular, but this appearance will be explained a little later.

The *nucleus* is a roundish mass, generally central in location, and named from the Latin word which means "the kernel," because its situation is so suggestive of the meat of a nut. Sometimes the nucleus contains a small body (perhaps more than one) bearing to it a relation similar to that which the nucleus itself sustains to the cell; and this is called the *nucleolus* ("the little kernel").

The typical cell has no investing membrane. The granular appearance of its protoplasm is due to a network (*spongioplasm*) which becomes visible with lenses of high power. In the meshes of this plexus is a nearly fluid, homogeneous material (*hyaloplasm*). The nucleus has a similar construction, but has additionally a limiting membrane. The nucleoli are connected with the reticulum (network) of the nucleus. One point on the nucleus is called its pole, and the exactly opposite point is its antipole.

The protoplasm may become condensed at the surface, and this hardened peripheral part is called the cell-wall. A deposit of chemical substances in the wall frequently occurs, and contributes to its solidity. Cells may produce material superficially in large amounts without essential change of their own shape; and thus are formed substances called intercellular ("between the cells"). Tissues consist of cells and intercellular substance. In shape cells differ widely: the various forms will be described in connection with the discussion of the respective textures. Some cells are less than $\frac{1}{2500}$ inch in diameter, others more than $\frac{1}{200}$, and between these extremes are all possible gradations.

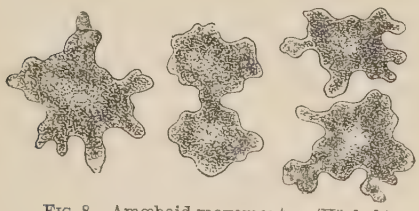

FIG. 8.—Amœboid movements. (Häckel.)

As has been said, the protoplasm of the cell possesses contractility, and this property enables it to display movements which are known as amœboid, because they are observed in a typical form in a unicellular, aquatic creature called *amœba*. In its amœboid movements (Fig. 8) the cell alters its form rapidly, assuming indescribably fantastic outlines, due to the irregular contraction, first, of one portion of the mass, and then of another part. By virtue of this quality the cell can move from place to place, one point becoming fastened, and the rest of the cell moving up to it and pushing out a process to a farther point in the same

direction. Thus is accounted for the migration of cells from blood-vessels, and their wandering from one point to another outside of the vessels.

CELL REPRODUCTION.

The formation of new cells is accomplished by division of old cells. The direct method, by which every element of a cell was equally divided by a transverse constriction, was formerly supposed to obtain generally, but is now known to be very rare. The indirect plan of division is almost, if not quite, universal. By this method the nucleus undergoes a series of complicated modifications, which, taken as a whole, are called *karyokinesis*, a name derived from the Greek words for "nut" and "change," the signification of the compound being "the changes in the kernel" or nucleus. In studying the details it is well to bear in mind that in this process, which is the principal movement toward the creation of two cells out of one, there occurs such a division of the cell-protoplasm and of the nucleus that each of the new-born cells inherits a half of every portion of the parent-cell's estate.

When division is about to take place the nucleus noticeably enlarges (Fig. 9). The nuclear membrane and the nucleoli disappear, and the secondary filaments of the reticulum are drawn into the primary threads, making them thicker and more conspicuous (Fig. 10). It is not positively determined whether these threads

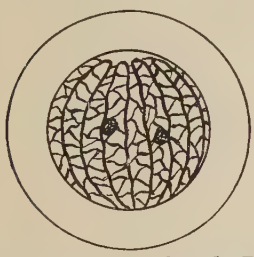

FIG. 9.—Nucleus enlarged. The body of the cell is represented merely in outline in this series of diagrams. (F. H. G.)

FIG. 10.—Nucleoli and secondary filaments have disappeared. (F. H. G.)

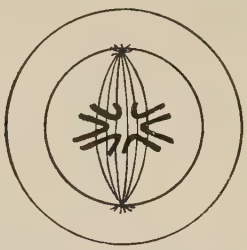

FIG. 11.—The spindle and V loops, side view. (F. H. G.)

all unite and make one, or are separate; whichever is true, they form a peculiar and complicated tangle which is called the *skein*. The diagram does not attempt to display all of the tortuosities of the skein, as they are rather confusing. There now appears a skeleton *spindle* (Fig. 11), formed of delicate filaments of the interstitial substance, placed with one extremity at the pole and the other at the antipole. At each end of the spindle fibrils of the protoplasmic network converge and produce the appearance of rays. At the next step (Fig. 12) a number of

FIG. 12.—V loops, end view. (F. H. G.)

FIG. 13.—Daughter loops, end view. (F. H. G.)

V-shaped loops are observed in place of the skein, these resulting either from the breaking of the single thread, on the one theory, or, on the other, from the plainer manifestation of the always separate threads. These V-shaped pieces are short and thick, and marshal themselves around the equator of the spindle, with apices to the centre and limbs outward, producing a star-like appearance, which is

sometimes called the *wreath*. Simultaneously with this movement the loops are split lengthwise (Fig. 13), so that each original (or mother) loop is made into a pair of secondary (or daughter) loops—a most important part of the series of changes. Next, the twin sisters in each V-shaped loop turn away from each other, one moving her head toward the pole, the other toward the antipole, their limbs being interlocked (Fig. 14). Presently they separate entirely, and migrate to pole and antipole respectively, travelling along the lines of the spindle, which seem to serve as guides to their movements. Arrived at their destination, each

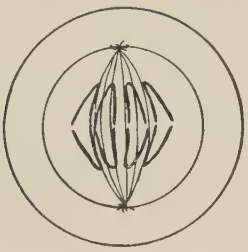

FIG. 14.—Migration of daughter loops toward pole and antipole, side view. (F. H. G.)

FIG. 15.—Arrival of daughter loops at pole and antipole. (F. H. G.)

forms a *star* (Fig. 15). Now, as far as can be seen, there has been accomplished an equal partition of the original reticulum of the nucleus, and the mass divides into two masses which are henceforth distinct nuclei. In each of these two bodies there takes place a reversal of the steps with which the karyokinesis was inaugurated: the V-shaped loops of the stars elongate, their limbs stretch out to the opposite side of the nucleus (Fig. 16), and the skein-like appearance is observed. Then branches are put forth from the main or primary filaments, and

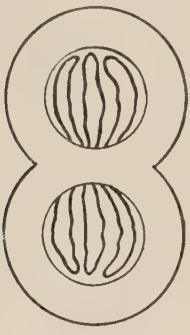

FIG. 16.—Division of nucleus into two nuclei, and elongation of V loops. (F. H. G.)

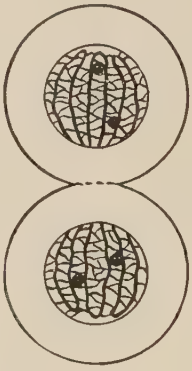

FIG. 17.—Reappearance of secondary filaments and nucleoli. Division of entire cell into two. (F. H. G.)

form the secondary filaments necessary to complete a network. Nucleoli come in sight, and a wall is formed around the nucleus (Fig. 17). Before these last stages are accomplished the protoplasm of the cell shows a constriction which rapidly deepens, and continues to increase until the cell is bitten in two, each part being furnished with a perfect nucleus in which is no sign of a spindle. It is held by some authors that the wall of the nucleus is not complete, and that thus is permitted a mingling of the interstitial substance of the nucleus with the cell-protoplasm. However this may be, nobody questions the intercommunication after the disappearance of the nuclear wall.

Various modifications of karyokinesis are frequently observed, but the foregoing description comprises the main features in a typical and complete case.

CLASSES OF TISSUES.

I. Tissues furnishing the free surfaces of the body : **Epithelial Tissues.**
II. Tissues passively supporting other parts : **Sustentacular Tissues.**
III. Tissues performing a nutritive function : **Liquid Tissues.**
IV. Tissues devoted to movement : **Muscular Tissues.**
V. Tissues essential to sensation : **Nervous Tissues.**

THE EPITHELIAL TISSUES.

Tissues furnishing the Free Surfaces of the Body.

There is a peculiar propriety in speaking of this class first, as it is composed entirely of cells, and also because the male and female cells, by whose union every human being is created, are, to all intents and purposes, epithelial cells.

On every surface which is free, as distinguished from attached, are found multitudes of cells, and with hardly an exception the surfaces are covered with them or, more properly speaking, completely composed of them. Thus, the top layer of the skin is made wholly of cells ; so also is the exposed surface of every cavity, tube, or passage which connects directly or indirectly with the skin ; as, for example, the alimentary canal from mouth to anus, all of the air-passages, the urinary organs, the generative ways ; the surface of cavities which are entirely closed, which cannot be reached without dissection, such as the pleura, the heart, the blood-vessels ; and others which need not now be enumerated.

These cells, thus spread out in close contact with each other, are *epithelial cells*, and the sheet of tissue which they form is *an epithelium*. Etymology does not suggest the character of the tissue, the extent of its distribution, its uses, or any other valuable fact about it, the word being derived from the Greek words signifying "upon the nipple." It is best, therefore, to employ it in a perfectly arbitrary way. Many groups of these cells—indeed, all of those which limit the surfaces of shut sacs, shut tubes, and other cavities which are not directly or indirectly continuous with the skin—are called *endothelial*, and the sheet of tissue which is formed by them is named an *endothelium*, the derivation giving it the meaning of "within the nipple"—a term which has not even the minute justification to be accorded to "epithelium ;" for there is epithelium upon the nipple, but there is no endothelium within it, except as there is in every part which contains blood- and lymph-vessels. As Macalister most pertinently says, "The distinction between endothelium and epithelium is not always either histologically certain or functionally possible, nor can its development be relied on as a criterion." It would be well if the attempt to keep up the distinction were abandoned ; but, as some writers still employ the term endothelium, it is well to understand that they refer to a cellular tissue which develops from what will presently be described as connective tissue. In this book all such will be included under the head of epithelium.

Originally all epithelial cells are nucleated : in most of them the nucleus can be demonstrated at any stage of their existence ; but in some it becomes obliterated, usually as the result of pressure or exposure to the drying effects of the air.

The cells almost literally constitute the entire tissue, the intercellular substance being reduced to its lowest terms, and consisting of a minute quantity of a semi-fluid, adhesive material called the *interstitial cement-substance*, which glues the cells together.

Usually an epithelium rests upon a transparent, structureless sheet of extreme thinness, rather difficult of demonstration, the *membrana propria* or *basement membrane*. Though called structureless, it is shown to be made up of flattened plates of typical connective tissue, which will be treated of a little later.

An epithelium contains no blood-vessels and a very diminutive supply of

nerves. When destroyed or in any way lost the cells are regenerated, as a rule, with rapidity.

Epithelium performs many important services, among which may be mentioned the protection which it furnishes to underlying tissues, the prevention of the escape of lymph from the parts which it covers, the absorption of nourishing materials into the blood, the maintenance of motion in the fluid which comes in contact with it, the smoothness which it imparts to surfaces, the formation of secretions, and assistance in the appreciation of certain sensory impressions.

The materials composing epithelial cells and the substance uniting them are sufficiently yielding to permit considerable alterations in their form without injury. Thus, when the structures upon which an epithelium rests enlarge or contract, it readily adapts itself to the changed conditions, without cracking in the one case or wrinkling in the other.

No classification of epithelial cells is very satisfactory, but the study of them is made somewhat easier by the knowledge that (excepting a few—the spheroidal—whose form presents but a slight departure from that of the typical cell) they may be placed in two classes, in one of which they are long and slender, and are arranged with their chief axis perpendicular to the surface, and in the other of which they are broad and thin, with the long axis parallel with the surface upon which they rest.

In the first class—the cells standing on end—are columnar (cylindrical), prismoidal, conoidal (pyramidal), pyriform (pear-shaped), club-shaped, fusiform (spindle-shaped) cells. In the second class—the cells lying on side—are flattened (scaly or squamous) cells (Fig. 18).

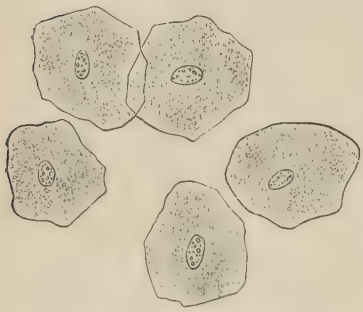

Fig. 18.—Flattened epithelial cells. (Dalton.)

It will be observed that this classification is based upon form only, and that the difference between one and another is accounted for by the direction in which pressure is applied. For example, suppose that a large number of soft, globular cells are placed upon an even plane, side by side, each just touching every immediate neighbor, and imagine that an equal number of exactly similar cells are introduced additionally upon the same area. Of course something must give way, or the proposed problem has no solution; and what actually yields is the shape of each of the plastic cells. The cell cannot go downward, for the surface upon which it rests prevents this; sidewise pressure of every adjacent cell deprives it of a considerable part of its former standing-room; and, as its bulk remains unaltered, it is obliged to move a part of its mass upward, and its free surface, reduced by the lateral squeezing, is thrust two or three times as far from its attached surface as it was originally. The cell has become elongated, changed from a sphere to a cylinder or column, by pressure applied in a number of lateral and parallel directions. If the surface upon which the cells originally rested was convex in every direction, instead of flat, the cells would be changed from spheres to cones or pyramids by pressure made laterally on each at many points, and progressively increasing in force from the part nearest the surface downward. The difference in results depends upon the variation of the supporting surface. If the cells are pressed between two parallel planes, one of which is the surface upon which they rest, the result is a flattened cell. It is easy to imagine how the other and less common shapes have been evolved.

Flattened epithelium is often called tessellated, or pavement, because, when one looks directly down upon it, it presents the appearance of a flagging of stones. The names, however, are objectionable, not only because they are superfluous, but more because they are equally applicable to the columnar variety when it is viewed in the same way; for the flat, free ends of the latter look just

as much like a pavement—indeed, are even more suggestive of one than are the others (Figs. 19, 20).

While these classes include nearly all epithelial cells, many cells have peculiarities which are distinguishing, and it is convenient to designate them by descriptive names, such as *ciliated* and *prickle*, from their appendages; *sensory* or *neuro-*, from their relation to the periphery of a special-sense organ; *pigmented*, from their coloration; *goblet* or *chalice*, from their modification of shape; *transitional*, from their being of a rapidly varying form; *glandular*, from their work in secretion. A brief mention of the chief points of each variety is desirable.

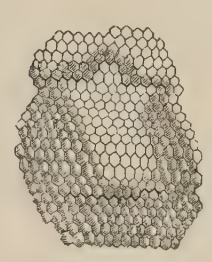

FIG. 19.—End view of a number of epithelial cells, presenting the appearance of a pavement. (Retzius.)

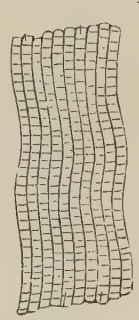

FIG. 20.—Side view of some of the cells of Fig. 19, showing that they are long and slender. (Retzius.)

Ciliated cells (Fig. 21) in man are always of the columnar form, and are characterized by the projection from their free extremity of a number of delicate processes strongly suggestive of eyelashes, and hence called *cilia*. The cilia have a constant vibrating motion, with a strong stroke in one direction and a weak one in the other. They are situated in various parts, but never where they are likely to be subjected to hard usage. Thus, they are nowhere in the alimentary tract, where the masses of food and excrement would injure them; but they exist almost everywhere in the breathing passages, which transmit nothing hurtful to them. Their more powerful stroke is always made in the same direction; thus, in the respiratory tract it is invariably such that the mucus which smears the surface is moved toward the open end of the system—that is, from the deep parts of the lung to the surface of the body. Cilia are found in the adult mainly in the organs of breathing and those of generation.

FIG. 21.—Two conoidal epithelial cells, their free ends furnished with cilia.

Prickle-cells (Fig. 22) exist in the middle layers of the stratified epithelium of the epidermis, the outer layer of the skin. They are polyhedral, and the little spaces between them are bridged over with delicate threads, which break when the cells are separated and present the appearance of short, rigid spines.

FIG. 22.—Prickle-cells.

Sensory epithelium, or neuro-epithelium cells (Figs. 23, 24), are found in close relation with the filamentous terminals of the nerves devoted to taste, smell, hearing, and sight; from which fact the names *sensory* and *neuro-* ("nerve") are derived. Such a cell is intimately associated at its attached end with the periphery of a sensitive nerve, and at its free extremity is quite generally prolonged into a stiff, hair-like process, which may project beyond the plane of the surrounding surface. These distal bristles receive a shock from a wave of the fluid into which they protrude, and this causes a thrill to pass through the cell and to agitate the nerve-filament, which carries the impression to the nerve-centre.

Pigmented cells are found in various situations. They are of different shapes, generally very irregular, and have been invaded by (perhaps filled with) black particles. In the colored races the lower layers of the epithelium of the skin are highly charged with them.

Goblet or chalice cells (Fig. 25) are a modification of the cylindrical or conoidal, and their names are explanatory of their form. The nucleus retreats to the attached end of the cell, and the rest of the cell becomes filled with a granular material. The granules swell, causing the part in which they are contained to bulge out at the sides and crowd over into the territory of the adjacent cells; and, finally, the internal pressure becomes so great that the cell bursts at its free end, its contents escaping upon the surface as a glairy substance called *mucus*. A goblet-cell, therefore, is a one-celled gland, doing real secreting work. In the true mucous glands the secreting cells are of this variety. A goblet-cell may soon return

FIG. 23.—Neuro-epithelial cells. Three cells project beyond the general surface, and are supported by intermediate cells. (Frey.)

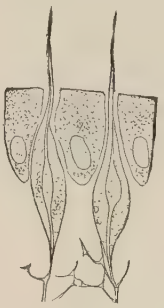

FIG. 24.—Neuro-epithelial cells. Two send long processes beyond the general surface. (Schultze.)

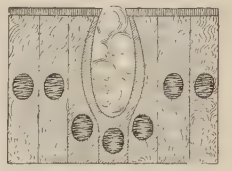

FIG. 25.—Goblet-cell, surrounded by cylindrical cells.

to the condition of an ordinary cylindrical or conoidal cell or remain a chalice for a long time.

Transitional epithelium (Fig. 26) partakes of the features of a number of other groups. Its typical illustration occurs in the bladder, where the superficial layer is composed of thick, flattened cells, with dimples on their under surface into which the large ends of pear-shaped cells of the next layer are received, the spaces between the last being filled with the inverted cones of the lowest set.

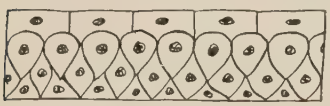

FIG. 26.—Transitional epithelium.

No two layers are alike, and a lower is in a state of transition to a higher plane.

Glandular epithelium (Fig. 27) is composed of cells of differing shapes—cuboidal, cylindrical, conoidal, polyhedral, and spheroidal, the last being rarely found except in the remotest recesses of tubular and racemose glands. The various forms of these cells are accounted for by the different shapes of the cavities to which each series is compelled to adapt itself. The function of glandular cells is secretion.

FIG. 27.—Glandular epithelium as seen in a salivary gland. At the lower right-hand corner is a duct lined with conoidal epithelial cells. (Kölliker.)

When an epithelium consists of only one stratum of cells it is called *simple* or *single-layered;* when it has two or more layers it is known as *stratified*. If a ciliated epithelium is stratified, only the cells of the upper layer are furnished with cilia.

THE SUSTENTACULAR TISSUES.

Tissues Passively Supporting Other Parts.

1. *Mostly fibrous.*
   - (*a*) White Fibrous Tissue (Connective Tissue Proper).
   - (*b*) Yellow Fibrous Tissue (Elastic Tissue).
   - (*c*) Areolar Tissue.
   - (*d*) Adipose Tissue.
   - (*e*) Gelatinous Tissue.
   - (*f*) Adenoid Reticular Tissue.
   - (*g*) Neuroglia.
2. *Cartilaginous.*
   - (*a*) True Cartilage.
   - (*b*) White Fibro-cartilage.
   - (*c*) Yellow Fibro-cartilage.
3. *Osseous.*
4. *Dentinal.*

The members of this large group present many violent contrasts in their physical qualities: we find the soft and the hard, the transparent and the opaque, the flexible and the rigid, the nearly liquid and the almost stonily solid, the fibrous and the granular, the moist and the dry, the colorless, the white, the yellow, the pearly, and the pink. And yet, in spite of these antipodal traits, the individuals making up this class have certain common characteristics which distinguish it from all others. One which strikes the attention most forcibly is the absolute passivity of every member of it: not one of them does anything actively; they stand still like stocks and stones, and are acted upon by the other tissues; they originate no action. But the service which they perform, though humble, is of essential importance, and is measurably presented to the mind by any one of the various names borne by the group. "Sustentacular" suits our purpose excellently, suggesting mechanical support, the upholding that requires strength and endurance. "Connective substance" is good, as referring to a very prominent function—the uniting of neighboring parts. "Connective tissue," of course, inherently carries an equal significance, but the term has been so much used to designate a leading member of the group, that it is not always certain to convey one's intent to include all of them. "Skeletal" is highly descriptive to one who has divested his mind of the popular notion that nothing but bony structures are entitled to be considered a skeleton. Probably the best term of all in our language is "framework," because everybody knows that a framework may be made of any materials which have suitable physical qualities, and understands that it does the work of supporting mechanically, of connecting near and distant parts of the whole, and of keeping these same parts away from each other—the last being an office quite as important as the more prominently mentioned connective work. As, however, the term is so little used in a titular way by anatomists, another has been selected to distinguish the group.

The word "framework," like "skeletal," to an anatomist suggests far more than the massive, bony staging, which is the gross basis of the human form. To him it means the delicate, and even microscopic, rafters, beams, and shelves, which serve to give definite shape to minute organs and to small parts of large structures, and to keep their active portions from pressing upon and being pressed upon by each other. So, too, in his mind, "connective" has both macroscopic and microscopic applications. It is a name given to the tissue of which are made the bands which tie the bones together, and the strong, flexible sinews which unite contractile organs to the parts which they move; and it is equally deserved by minute parts which, on a small scale, do work of a comparable kind.

These tissues are very widely distributed in the body—so extensively, indeed, that their diffusion may almost be declared to be universal. If every particle of material except the sustentacular tissues were to be withdrawn from the body of a person with whom we were well acquainted, there would be no difficulty in recognizing him, even in minute details of form.

It is interesting to observe not only that the sustentacular tissues are similar in a functional way, but that they are structurally allied. They originate in the same elements of the embryo, to a certain extent they are interchangeable, and they often shade into each other.

They consist of cells and intercellular substance, though in most of them, when mature, the cellular elements are inconspicuous, and the material between the cells is so largely developed as to constitute almost the entire bulk of the tissue.

White Fibrous Tissue.

The name of this tissue is highly descriptive, for it is distinctly white when seen in a mass, and its fibrous character is manifest. It is often called "connective tissue proper," or even merely "connective tissue," because of its great abundance, both absolute and comparative, and its very wide distribution; but, while its conspicuousness among the sustentacular tissues entitles it to the name which implies the fact, the designation is confusing, and would better be dropped in favor of the descriptive appellation which is here chosen. Teased out with needles and viewed with the microscope, it is seen to consist almost wholly of extremely fine, colorless fibrils, arranged side by side in bundles which have an undulating outline (Fig. 28). The fibrils may be very long—some inches—and do not branch. Closely applied to the bundles of fibrils are cells; but these are not a prominent feature in the adult tissue, and are liable to escape attention unless staining agents are used. The cells proper to the tissue are flattened, irregular, nucleated, granular, and have long processes (Fig. 29).

FIG. 28.—White fibrous tissue.

FIG. 29.—Cells of white fibrous tissue, often called connective-tissue cells.

White fibrous tissue is distinguished chiefly for its great strength and flexibility, and is found where these qualities by themselves are needed. For example, it is almost the only tissue in most of the bands (ligaments) which fasten the bones together, and in the cords (tendons) by which the force of muscular tissue is transmitted to and applied at distant points. In these situations great strength is required, for without it the bones would readily become dislocated and the muscular contractions would be fruitless of result; flexibility is demanded, since rigid ligaments and tendons would either prevent movement or break, and thus prove useless. If, in addition to strength and flexibility, elasticity were added, the bones would get out of place during many movements, and muscular contraction, instead of moving the object to which the distal end of the tendon was attached, would be devoted in large part to the stretching of the tendon itself.

These illustrations will show that this tissue is well fitted by its physical qualities to make up the ropes, cords, protective sheets, and outer shells of organs.

Yellow Fibrous Tissue.

This texture is composed mainly of fibres, and in large masses presents a delicate yellow hue, from which facts it is named. Under the microscope its fibres are seen to differ materially from those of white fibrous tissue: they are ribbon-like, thick, branched, and curled at the ends into hooks, which result from their fracture in the preparatory teasing (Fig. 30). The chief physical properties of this tissue are strength, flexibility, and elasticity, the last being that which distinguishes it from all others, and gives it the name by which it is often known, "elastic tissue." Elasticity, the quality which restores bodies possessing it to their normal shape after distortion, is not to be confounded with contractility, the attribute which enables a body to shorten a diameter (for example, to draw its two ends nearer to each other) under the influence of a stimulus. Elasticity is a merely passive property: it cannot display itself until some outside force has stretched or otherwise deformed the substance in which it resides; but contractility is active, and is manifested under influences which have no such effect upon elastic bodies. The elasticity of yellow fibrous tissue, while disqualifying it for the work of tendons, eminently fits it for other duties, and it is found performing valuable service in many places. Wherever it is located, it does precisely such work as india-rubber would do, if similarly arranged. It is commonly associated with white fibrous tissue, though in relatively small quantities. The amount of it in the system is not large as compared with that of white fibrous tissue. The clearest masses of it are the ligamenta subflava between the laminæ of the vertebræ. Its strength is not equal to that of the white fibrous.

FIG. 30.—Yellow fibrous tissue. (Queckett.)

Areolar Tissue.

Areola is the Latin word for "a little space," and areolar tissue gets its name from its appearance of being full of minute spaces. It is sometimes called "cellular tissue"—a term which has no justification to the histologist, to whom the word "cell" has come to have an arbitrary meaning, entirely independent of its etymology. The designation "cellular tissue" is applicable properly only to a texture made up substantially of the histological elements called cells—such a tissue, for instance, as epithelium.

In areolar tissue we discover no material different from those which we have already studied—only a new arrangement of some of them. It is composed of a mixture of white and yellow fibrous tissues, so disposed in irregularly criss-crossed bundles as to make a network, the meshes of which bound innumerable areolæ (Fig. 31). The bulk of each bundle is white fibrous tissue, and around it are loosely twined threads of yellow fibrous tissue. The little spaces between the meshes are not definitely walled, but are indescribably irregular cavities, which communicate in the freest way with each other (Fig. 32). The fasciculi are moistened by a lymph-like fluid, which contributes to their flexibility and diminishes the friction between them.

Areolar tissue is found almost everywhere subjacent to the skin and mucous and serous membranes, between muscles, blood-vessels, nerves, and other parts. It forms a layer which is attached on one side to the deeper structure, on the other side to the more superficial. When one of these structures moves, the areolar tissue permits it to slide upon the other for a little distance, the wavy bundles of white fibrous tissue being straightened out, and the narrow ribbons of yellow fibrous being put on the stretch. The motion ceasing and the disturbing

agency being removed, the strained yellow fibres assert their elasticity, pull the white fasciculi back into their undulations, and assist a little in the restoration of the parts between which it lies to their former attitude of repose. The tissue is connective in a typical sense.

Disease and accident afford striking illustrations of the freedom of intercommunication of the areolæ,



FIG. 31.—Areolar tissue, composed of bundles of white fibrous tissue and branched strands of yellow fibrous tissue loosely intertwined.

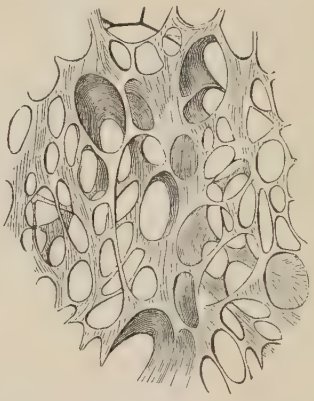

FIG. 32.—A portion of areolar tissue inflated and dried, showing areolæ.

and also of the vast extent of this structure just beneath the skin—here called the subcutaneous areolar tissue. The lymph-like fluid mentioned above is sometimes formed more rapidly than is normal, or, what amounts to the same thing in effect, its absorption is less rapid than its formation, and the excess accumulates in the areolæ. But, as each of these spaces opens into all of its neighbors, the fluid gravitates from one to another into those which are most dependent, and these it distends proportionately to its amount. In such a case, when the feet have been upon the floor all day, by evening they are swollen; but, after the patient has passed a night in bed in the horizontal position, the enlargement disappears almost entirely, because the fluid has gravitated back again and has become widely diffused. Sometimes, as in fracture of a rib, a sharp fragment of bone perforates the chest-wall and slightly punctures the lung, leaving an open tract between some of the air-vesicles of the latter organ and the areolar tissue near the surface of the body. Every time that air is drawn into the lung, some of it escapes through the accidental opening into the subcutaneous areolar tissue, the spaces of which become inflated, at first only in the region of the injury, but at each breath more and more extensively, until finally all of the areolæ under the skin are so ballooned that the victim presents such an appearance as is shown in Fig. 33.

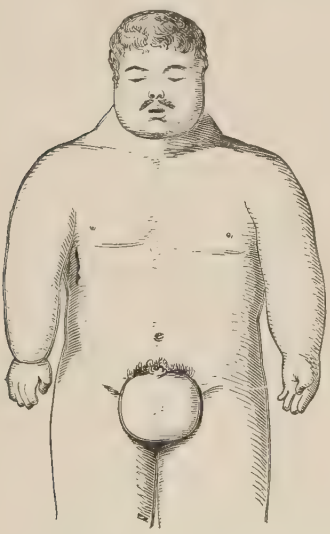

FIG. 33.—Inflation of subcutaneous areolar tissue, due to introduction of air through a wound in the chest-wall and lung. (Gross.)

The areolar tissue around certain organs, as vessels, becomes somewhat condensed and forms a distinct sheath. The nourishing vessels of a part are situated in its areolar tissue. In the narrow spaces between the lobules of a solid organ, as the liver; forming a layer outside of the mucous coat of hollow organs, as the

stomach; everywhere among bundles of fibres, as in muscle,—in all such situations is areolar tissue, furnishing a springy bed for the blood-vessels. Indeed, it may be laid down as a rule that vessels are developed in this sort of tissue, and always continue to occupy it.

Adipose Tissue.

Areolar tissue has been described as composed of white and yellow fibrous tissues, disposed in such a way as to leave irregular spaces between their bundles. Some of the cells of the white fibrous tissue of this combination in certain circumstances undergo peculiar changes. The outer layer hardens, forming a delicate cell-wall; the most of the substance of the cell is converted into liquid oil; and the nucleus, previously central, is crowded off to one side, thus becoming peripheral, and is fastened to the cell-wall. Thus is formed a *fat-cell* (Fig. 34)—a veritable sac of liquid oil, deserving the name "cell" in the etymological as well as in the histological sense. Such cells are lodged in the

FIG. 34.—Fat-cells: *a*, filled with oil; *b*, exhausted of oil, the cell-wall shrivelled. (Kölliker.)

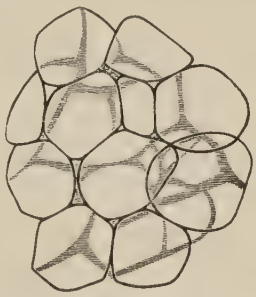

FIG. 35.—Fat-cells packed closely together, and thus becoming polyhedral.

spaces of areolar tissue very generally; but in a few localities they are never seen—the penis, the eyelids, the cavity of the cranium, and the lungs (excepting a little near the roots). When the number of fat-cells is sufficient to fill the areolæ even moderately, the *tissue* is called *adipose* or *fatty*. The cells are round or ovoid, except when they are closely packed, and then the mutual pressure produces angular facets all over them (Fig. 35). Fatty tissue is yellow, soft, and resilient when living, but hard when dead. Its amount is very variable, and there is no absolute criterion of the normal quantity. But when its shifting line of healthful development is overstepped, obesity or corpulence is reached—a pathological condition which may interfere with the proper performance of vital functions. Sometimes the fat in the abdominal wall attains a thickness of six inches.

The uses of adipose tissue are various. It is a cushion for organs—the kidneys always lie in a bed of fat, and other organs are similarly provided, though less lavishly. Being a slow transmitter of heat, it is a protection against cold—it is always found in the great serous apron which hangs down in front of the bowels, and doubtless serves to keep them warm. Adipose tissue is a reservoir of nutrient material which is drawn upon in starvation. If an animal is deprived of suitable food, his system relies largely upon its store of fat in the emergency. If a wolf and a sheep are starving, each feeds upon its own fat, the herbivorous animal becoming for the time practically a carnivorous one, since it lives on fat mutton. A man wasting with fever lives on his own tissues—cannibalistically consumes human flesh. The adipose, being a cheap tissue, is used most freely; nervous tissue, the most costly, suffers the least loss of weight. During the process of starvation the oil is abstracted from the cells, and the walls become wrinkled and collapsed. The nucleus, however, keeps alive; and, when nourishment is again appropriated by the system, the nucleus becomes active, takes from the blood the materials suitable for the manufacture of oil, combines them properly, and deposits the product in the cell-cavity, which soon becomes plump again. Finally, it is not unworthy to mention the æsthetic effect of a reasonable amount of adipose, which softens the asperities of sharp angles, and contributes to the production of the graceful contours, which are so essential to perfect beauty of form.

Gelatinous Tissue.

This tissue is jelly-like, as its name implies. It is also called *mucous tissue* and *mucoid tissue*. No typical example of it occurs in the adult body; but the gelatin of Wharton in the umbilical cord illustrates it perfectly. Here is seen a protoplasmic network, formed by the union of the processes of cells, which are identical with those of white fibrous tissue. In the meshes of this reticulum is a semifluid ground substance. This tissue is the most immature form of fibrous tissue.

The vitreous body (or humor) of the eye is composed of gelatinous tissue; but the fibrous element is so slightly developed that its existence is by some observers denied, and almost all of the cells have disappeared, the few which remain being shrunken and indistinct. The vitreous is in large part (about 99 per cent.) water, and its appearance is that of a mass of beautifully transparent, colorless, and delicate jelly.

The service performed by the vitreous is strictly sustentacular. It is the stuffing which keeps the ball of the eye in its globular shape, preventing the wrinkling of the retina, which would be utterly destructive of definiteness of sight. When lost, the vitreous is not restored, having a low vitality and practically no recuperative power.

Adenoid Reticular Tissue.

The word *reticulum* is the diminutive of the Latin *rete*, "a net," and consequently means "a little net." "Adenoid" comes from the Greek word for "gland," and signifies "gland-like." *Adenoid reticular tissue*, therefore, means the tissue forming the network in gland-like structures, particular reference being had to the framework of the so-called lymphatic glands, which are far better named "nodes," since they are not real glands.

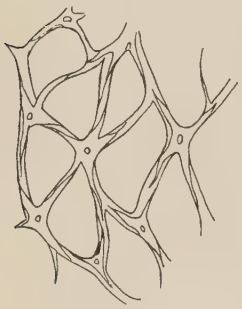

Fig. 36.—Adenoid reticular tissue.

This network has points of resemblance to areolar tissue—may, indeed, be regarded as a modification of it. The reticulum consists of strands of white fibrous tissue, with few, if any, yellow fibres intermingled, and these delicate trabeculæ ("little beams"), which support the proper substance of the node, are nearly or quite covered by fibrous-tissue cells in the shape of broad, thin plates closely applied and wrapped around them (Fig. 36).

Though the most characteristic display of this tissue is in the lymphatic nodes, it is widely distributed in the body, and is particularly abundant in mucous membranes.

Neuroglia.

Literally, the word *neuroglia* means "nerve-glue," and is misleading, for it is used as the name of a network supporting the nerve-substance of the brain

Fig. 37.—Neuroglia cells.

and spinal cord. This reticulum is not made of white fibrous tissue, as is that

of adenoid tissue, but is composed of peculiar bodies, called glia-cells, and their processes. The cells (Fig. 37) are irregular and stellate, and their branches are frayed out at the end in tufts of minute fibrils, which ramify everywhere between the nerve-cells and fibres.

Besides the neuroglia, there are two other means of mechanical support for the tissues of the great nervous centres. From the attached portion of the epithelial cells which line the cavities of the brain and spinal cord delicate fibrils run peripherally and end in the pia, the fibrous and vascular covering of these masses. Finally, the pia itself sends prolongations inward, which are of manifest sustentacular value.

Cartilaginous Tissues.

Cartilage, popularly called "gristle," is a dense tissue, but much less hard than bone, elastic, and serving important skeletal uses.

It occurs in three varieties:

True or Hyaline Cartilage.
White Fibro-cartilage.
Yellow Fibro-cartilage.

Hyaline cartilage is so named from the Greek word for "glass," because of the transparency of a thin slice of it. It is also called *true cartilage*, because it is the only variety which presents pure and unmixed the features which characterize this tissue. It encrusts the parts of bones which enter into the composition of movable joints, in such situations, being called articular cartilage; it forms the extensions of the ribs to or toward the breast-bone; it constitutes the bulk of the larynx; it stiffens the windpipe and bronchial tubes with strips and plates; it is the framework of the front of the nose, and does similar service in one or two other places. Hyaline cartilage is opaque, bluish-white, firm, elastic, and readily and smoothly cut with a knife. Covering it closely is a coat, called *perichondrium* ("around the cartilage"), which has an outer fibrous and an inner cellular layer, and is the agent by which the protection and growth of the cartilage are effected. Under the microscope cartilage is seen to consist of small clusters of roundish, nucleated cells (Fig. 38), each group crowded into a little cavity (*lacuna*, "a little lake"), between which and its neighbors is an expanse of apparently homogeneous intercellular substance (*matrix*). The cells are modified fibrous-tissue cells (the so-called connective-tissue cells), and the matrix is really composed of extremely delicate fibrillæ, the mass of which is pervaded by minute lymph-channels. Cartilage is non-vascular, and the nourishing material for the parts farthest from the surface permeates the tissue through these lymph-paths.

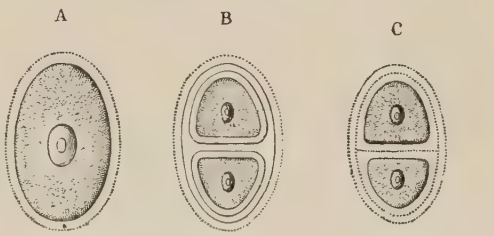

Fig. 38.—Cartilage-cells: *A*, mother cell; *B*, *C*, daughter cells. (Testut.)

White fibro-cartilage is otherwise known as *fibrous cartilage* and *fibro-cartilage*. It makes the great disks between the bodies of the vertebræ, the plates at the movable symphyses, the masses between the bones in the freely-movable joints, and the nodules which strengthen tendons in exposed situations. It has no proper perichondrium, and, indeed, is more like tendon than it is like true cartilage. Microscopically (Fig. 39), it is seen to consist of a dense

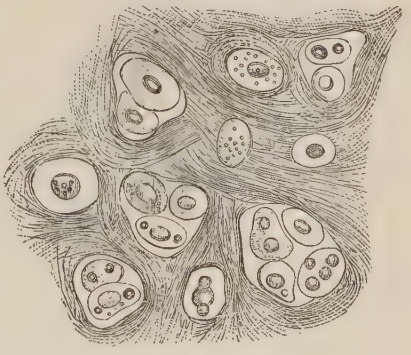

Fig. 39.—White fibro-cartilage.

felting of white fibrous tissue, imbedded in which are nests of cartilage-cells, as if the seeds of cartilage and those of connective tissue proper were sown together in the same field and developed in an intimate mixture. The physical properties of the tissue are such as would be expected from such an association of ingredients—elasticity from one element, flexibility and toughness from the other.

Yellow fibro-cartilage is called also *elastic cartilage* and *reticular* ("network") *cartilage*, for structural reasons which will presently be manifest. Its principal examples are the framework of the auricle and that of the epiglottis in the larynx. It is opaque and yellowish, and more elastic, flexible, and tough than hyaline cartilage. Viewed with the microscope, it is seen to consist of a close network of yellow fibrous tissue, containing scattered groups of true cartilage-cells (Fig. 40)—a composition which readily explains its physical qualities.

As both the second and third varieties of cartilage have a fibrous tissue mingled with the true cartilage,

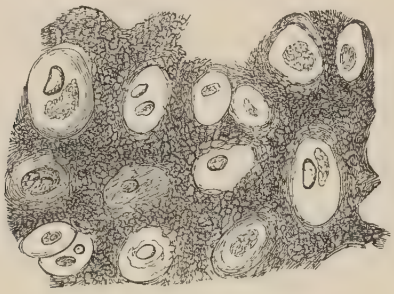

FIG. 40.—Yellow fibro-cartilage. (Kölliker.)

the names "fibro-cartilage" and "fibrous cartilage" do not differentiate one from the other. As all cartilage is elastic, the name "elastic cartilage" is not clearly helpful in the designation of that containing yellow fibrous tissue; and "reticular" is no better as a title for the third variety than is "fibrous" for the second, since in each its fibrous tissue is arranged as a network. The names which are given above are preferred because they actually convey a correct idea of the structure of each form respectively.

Osseous Tissue.

The word "osseous" is derived from the Latin *os*, meaning "a bone." Osseous tissue, therefore, is bony tissue, and it is the characteristic material in the bones. A bone is one of the numerous hard organs, which, taken together, make up the skeleton. One of the long bones of the limbs will show typically all of the features which we need for the study of osseous histology.

FIG. 41.—Vertical section of a long bone. (Testut.)

A long bone has a central cylindrical portion, the shaft, and an expanded portion at each end. The parts of the extremities of the bone which present surfaces in movable joints are crusted over with a layer of cartilage, and the rest of the bone is covered with a fibrous and vascular membrane, called the *periosteum*, meaning the structure "around the bone." The fibrous part of the periosteum makes it protective; the vascular serves for the nourishment of the bone. The deepest portion of the periosteum is composed of cells, called *osteogenetic* ("bone-begetting"), because essential to the formation of osseous tissue. If the bone is divided into halves by a vertical cut, its shaft is found to be hollow (Fig. 41). The open space is called the *marrow-cavity*, and is lined by a fine,

fibrous layer, the *endosteum*, meaning the structure "within the bone." The material in the outer parts of the bone is very dense, and is, consequently, known as *compact osseous tissue*. It is very thick in the shaft, but shades off toward the expanded extremities, and in them is merely a thin shell. The residue of the bone has the appearance of a network, with the finest meshes nearest the outer surface, the coarsest next to the marrow-cavity. It is called *spongy osseous tissue*, on account of its porous character, and *cancellous*, from its being a latticework. But compact and spongy are terms which have reference only to gross appearances, which are caused by the arrangement of the material: the structure is essentially the same everywhere. The *marrow-cavity* is occupied by the *marrow* or *medulla*, a very vascular material, containing many peculiar bodies (*marrow-cells*), which are largely changed into oil as adult life is approached, the color of the marrow being, therefore, altered from red to yellow.

Osseous tissue is one of the hardest materials in the body, being surpassed in density by two tissues only—dentine and enamel—both of which exist in the teeth. It is very tough and elastic, as well as hard, and will resist great strain without breaking. It is composed of two kinds of substance, earthy and animal, so intimately commingled that, if either is removed, the other maintains the form of bone even in its minute details. The earthy matter, which is mostly salts of lime and makes up two-thirds of the weight of the bone, can be removed by the action of a dilute acid. The bone is thus decalcified, and consists of a brownish, tough, flexible, and elastic material, so free from stiffness that the bone, if a very long one, may be tied into a knot (Fig. 42). The animal matter can be driven off by heat. When this has been done, the bone is white, rigid, and brittle to the last degree: it can be crushed into fragments between the thumb and finger. In the fresh condition the color of bone is delicate pink in the compact portion, deep red in the cancellated.

FIG. 42.—Human bone which has been deprived of its earthy matter and tied in a knot. (Dalton.)

If the shaft of a long bone is sawed in two transversely, and a very thin slice is removed from the cut surface and examined with the microscope, it will be seen that there are numerous nearly circular or oval perforations, around each of which is a series of concentric rings, which represent long, hollow cylinders fitted accurately one over another, so as to form a solid rod perforated from end to end (Fig. 43). This constitutes a *Haversian system*, named from the celebrated anatomist, Havers. The concentric rings are *lamellæ* or *laminæ* ("layers"), and the hole in their midst is a Haversian canal. In the solid substance of the rod are numerous small excavations called *lacunæ* ("little lakes"), from which radiate in every direction fine channels, called *canaliculi* ("little canals"), which, by uniting with those from neighboring lacunæ, establish a free communication between the Haversian canal and the lacunæ farthest away from it. The lacunæ and canaliculi are lymph-paths, and are important agents in the nutrition of the bone. The Haversian canal is occupied by blood-vessels, nerves, and lymphatic vessels, all imbedded in a mass of areolar tissue. The canals have a general longitudinal direction, but some run more obliquely and connect the more vertical. Immediately subjacent to the periosteum and parallel to it is a series of lamellæ which form a continuous sheath for the more central parts, and are called *circumferential lamellæ*. A similar arrangement obtains at the inner free surface, several concentric lamellæ encircling the medullary cavity, and standing in the relation to it that the Haversian lamellæ do to their central canal. Indeed, this inner circumferential series with its contained marrow has been called a mammoth Haversian system. In the spaces between the Haversian systems are series of layers arranged at irregular angles to each other. They are called *intermediate lamellæ*, and, like the inner and outer

circumferential, are of periosteal formation, the remnants of an earlier stage of growth than is shown in any Haversian system.

The lacunæ are occupied by nucleated corpuscles, called *bone-cells*, fine processes of which extend into the canaliculi. Lacunæ and canaliculi are characteristic of osseous tissue, and are found in all true bone. But Haversian canals are not present in plates of bone which are so thin that sufficient nourishment is afforded by blood-vessels upon their opposite surfaces, as in many lamellæ of the cancellous tissue, and frequently in a part of the lachrymal bone.

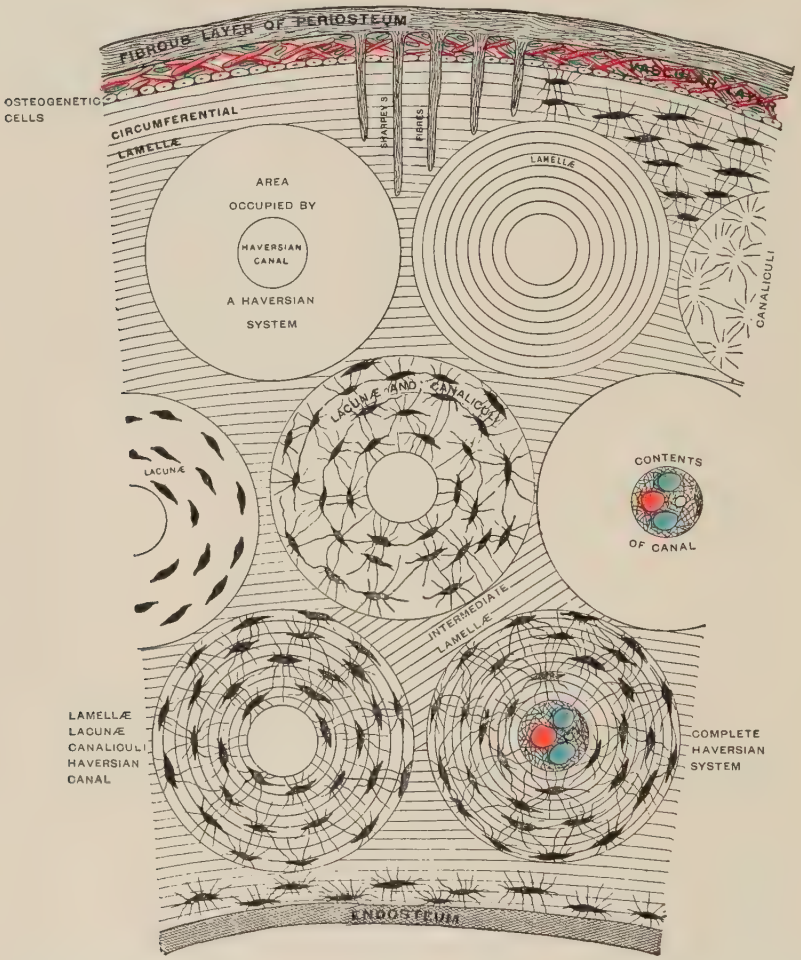

FIG. 43.—Diagram of the structure of osseous tissue. A small part of a transverse section of the shaft of a long bone is shown. At the uppermost part is the periosteum covering the outside of the bone; at the lowermost part is the endosteum lining the marrow-cavity. Between these is the compact tissue, consisting largely of a series of Haversian systems, each being circular in outline and perforated by a central canal. In the first one is shown only the area occupied by a system; in the second is seen the concentric arrangement of the lamellæ; and in the others, respectively, canaliculi; lacunæ; lacunæ and canaliculi; the contents of the canal, artery, vein, lymphatic, and areolar tissue; lamellæ, lacunæ, and canaliculi; and, finally, all of the structures composing a complete system. Between the systems are circumferential and intermediate lamellæ, only a few of which are represented as lodging lacunæ, though it is to be understood that lacunæ are in all parts. The periosteum is seen to be made up of a fibrous layer and a vascular layer, and to have upon its attached surface a stratum of cells. From the fibrous layer project inward the rivet-like fibres of Sharpey. (F. H. G.)

If a thin layer is peeled off of the surface of a decalcified bone, minute projections from its under surface may be seen. These are inward prolongations of the periosteum, and are known as the perforating *fibres of Sharpey*. They are not found in Haversian systems, but only in the circumferential and intermediate lamellæ, which, as has been already said, are developed from the periosteum. They seem to contribute to the strength of the portions of bone in which they

exist by riveting them together; and they certainly make the attachment of the periosteum firmer by giving it a more than superficial hold. Tendons, when attached to bone, are prolonged into it as perforating fibres.

A delicate, longitudinal sliver of bone is seen to have minute openings, which

FIG. 44.—*A*, transverse section of a long bone, natural size; *B*, the dark part of *A*, magnified 20 diameters. Haversian systems of different sizes are seen, with canals, lamellæ, and lacunæ. The enlargement is not sufficient to show canaliculi. At *b* is a portion of the cancellated tissue. (Peaslee.)

represent the tracks of canaliculi; and, if the flake is superficial in origin, larger holes also appear wherein have lain the perforating fibres. Between the apertures is a very fine reticulum of fibrillæ, showing the essentially fibrous character of the tissue and its consequent homology with ordinary connective tissue.

Marrow fills the cavity of the shaft of the bone and extends into the interspaces of the cancellous portion. Its elements are supported on an areolar network, and it is extremely vascular, especially in the spongy bone, where, on account of the great number and size of the vessels, its color is red. In the shaft of an adult bone the marrow has been mostly changed into adipose tissue, and is yellow. In the marrow are multitudes of cells, like those of fibrous tissue, and they are called *marrow-cells*. There are also great, irregular masses, with many nuclei—*giant-cells*. The marrow and the contents of the Haversian canals are practically identical; indeed, they are continuous one with the other, and the comparison of the marrow and its encircling lamellæ with the Haversian canal and its surrounding lamellæ is not fanciful.

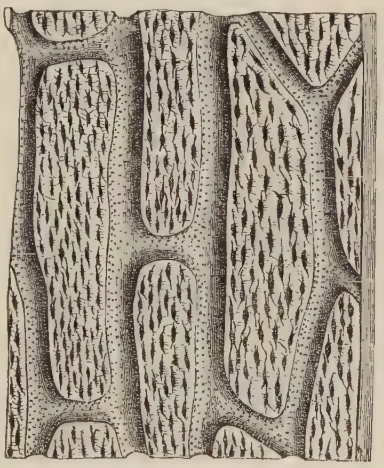

FIG. 45.—Longitudinal section of compact osseous tissue, greatly magnified. The Haversian canals are cut lengthwise. The dots in the canals are the openings of canaliculi. (Testut.)

From what has been said, it will be understood that osseous tissue consists of cells, fibres, and an interstitial substance, which is saturated with lime salts; and, consequently, that the feature in which

it principally differs from white fibrous tissue is its impregnation with this earthy matter.

It is important to remember that the integrity of the periosteum is essential to the proper nourishment of bone, and, if it becomes peeled off by accident or by disease, it should be replaced speedily in order to prevent death of the part which it supplies with blood.

Dentinal Tissue.

Dentinal tissue gets its name from the fact that it makes up the bulk and determines the form of the teeth, the Latin for "tooth" being *dens*. A tooth has a crown, the part which projects from the gum; a fang or root, the part buried in the jaw; and a neck, the narrow and sometimes constricted part embraced by the edge of the gum. If a vertical section is made through the middle of a tooth (Fig. 46) which has a single root, there is brought to view a long central cavity, containing the

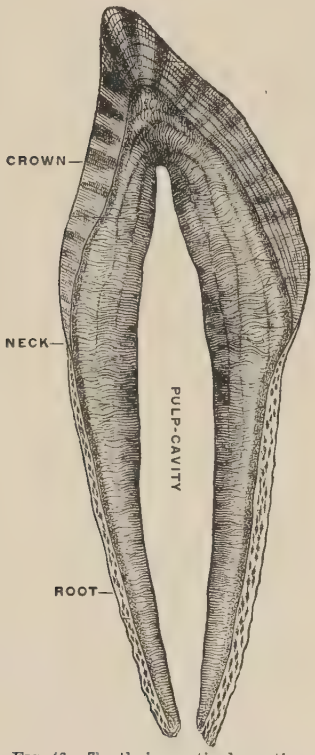

FIG. 46.—Tooth in vertical section.

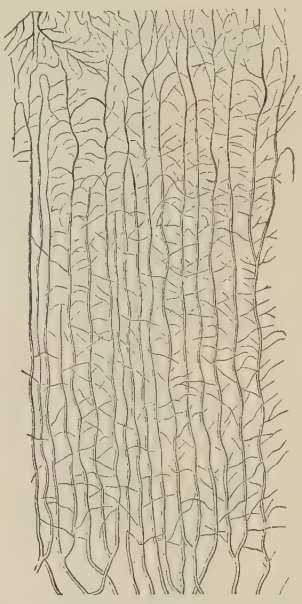

FIG. 47.—Dentinal tubules, in longitudinal section. The lower part of the cut shows the portion of dentine near the pulp-cavity. (Kölliker.)

pulp, the latter being composed of vessels and nerves, supported on a staging of areolar tissue, and also a great number of cells of the connective-tissue class arranged at the periphery of the cavity. Around this pulp-cavity is the hard portion of the tooth, in which are three different tissues: a crust of epithelial tissue all over the crown, the enamel; a crust of osseous tissue all over the fang, the cementum; and the main mass of the structure, the dentine or ivory.

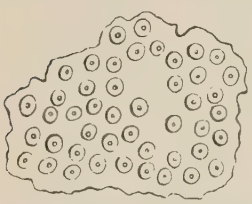

FIG. 48.—Dentinal tubules in cross-section, showing their cavities, walls, and the intertubular substance.

The *dentine* is white, very dense, closely allied to bone, than which it is a little harder. It is developed from closely-packed white fibrous tissue, which becomes infiltrated with lime-salts. This compact mass is riddled with minute channels, *dentinal tubules* (Fig. 47), which radiate in wavy lines from the pulp-cavity in every direction, except at the tip of the fang, where there is an opening through which pass

the vessels and nerves. The tubules branch as they pass toward the surface of the tooth, and the matrix is particularly dense just around them, thus forming a thick wall for each (Fig. 48). The peripheral pulp-cells, called *odontoblasts* ("tooth-germs"), send delicate processes into the tubules. The undulations of the microscopic tubules produce an appearance of striation which is visible to the naked eye.

THE LIQUID TISSUES.

Tissues Performing a Nutritive Function.

An elaborate presentation of the liquid tissues is not needed in an elementary work on anatomy, for a knowledge of them, except in a superficial way, is not required for the comprehension of the description of macroscopic structures. Consequently, they are treated here in a cursory manner, and the student is referred to his text-book on physiology for more detailed accounts of them.

The liquid tissues are—

The Lymph.

The Blood.

They originate in connective tissue, but are so different from it in appearance, physical properties, and function as to merit consideration in a group by themselves.

The Lymph.

Fine and closely stowed as are the elements of the tissues, there are between them spaces, mere chinks and crannies, extremely diminutive and indescribably irregular, into which ooze from the blood of neighboring vessels nutrient materials, and from the tissues themselves the substances which result from their waste. Thus, the tissues are constantly bathed in a mixture of their food and excrement. The spaces containing this fluid communicate freely with each other, and open into the beginnings of minute and delicate tubes, which last, uniting with others of similar size, form larger tubes; these pursue a like course, and so on until tubes of considerable capacity are reached. The little crevices and the tubes are respectively *lymph-spaces* and *lymph-vessels*, and their contents are called *lymph*. The word "lymph" etymologically means "water," but histologically and physiologically it is much more than this. It varies in composition in different parts, being poorest at the periphery and richest near the centre. Examined microscopically, it is seen to consist of a clear, fluid portion, *liquor lymphæ* ("the liquid of the lymph"), and a cellular portion, the latter floating in the former, so that this is a tissue whose intercellular substance is liquid. The cells are *lymph-corpuscles*, and are spheroidal, granular, jelly-like, colorless bodies, averaging $\frac{1}{2500}$ inch in diameter each, with a vaguely defined nucleus, and capable of amœboid movements. They are sometimes called *leucocytes* ("white cells"), because of the whitish appearance of a mass of them.

The lymph-vessels which absorb lymph from the small intestines contain, during the intestinal digestion of food, not only ordinary lymph, but also products of the digestive process. This mixture is called *chyle*, and is milky-looking from the fact that, like milk, it contains a large proportion of oily material finely subdivided—pulverized, we would say, if it were a solid.

The Blood.

Like the lymph, the blood is a tissue composed of cells and a liquid intercellular substance. The fluid portion is called *liquor sanguinis* ("the liquid of the blood") or *plasma*. In it float microscopic particles of various kinds (Fig. 49), of which the most conspicuous and easily demonstrated are the colorless and the colored corpuscles, the former, though without a tint, often being called white, and the latter, though yellowish, red, because, when seen in heaps, they present respectively the hues which these names suggest.

The *colorless corpuscles* are globular, granular, about $\frac{1}{2500}$ inch in diameter, and possess nuclei which are indistinct during the life of the cell. At rest they display amœboid movements. This description will be seen to coincide with that of the lymph-corpuscles; and this will not be surprising to one who has learned that the lymph-stream pours incessantly into the current of blood, so that what is at one moment a lymph-corpuscle, at the next, having entered the blood-vascular system, is a blood-corpuscle. The colorless corpuscles are divisible into a number of varieties, which are chiefly differentiated by means of staining tests.

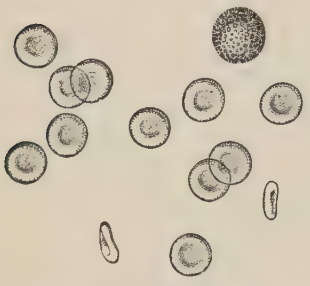

FIG. 49.—Blood-corpuscles. One colorless corpuscle is seen at the top; the others are colored. (Dalton.)

The *colored corpuscles* are very abundant, numbering perhaps five hundred to one of the colorless, and making about one-half of the volume of the blood. They are circular, non-nucleated discs, with rounded edges and centrally depressed surfaces, smooth, amber, transparent, flexible, elastic, and about $\frac{1}{3333}$ inch broad. Besides these bodies are others, inconspicuous and somewhat difficult of demonstration, which need not be mentioned here.

The blood is contained in the chambers and tubes of the blood-vascular system, from which it does not normally escape, excepting in the spleen, where it courses in wall-less channels, and in the case of women during menstruation, when it is discharged through ruptures in the vessels.

THE MUSCULAR TISSUES.

Tissues Devoted to Movement.

Contractility is in some degree an attribute of various tissues. The typical and original cell manifests its amœboid movements by virtue of its contractility, which it brings to bear now in one direction, presently in another. The cilia on the free surface of an epithelium are made to perform their rhythmical lashings because of contractility in their cells. But the muscular tissues alone depend upon this property for the sole functional quality which distinguishes them. Their contractility is displayed on a macroscopic scale, and results in the active movements by which locomotion of the body and changes in the relation of its different parts are effected.

We distinguish three kinds of muscle, which differ anatomically, and, for the most part, physiologically also. They are—

1. Plain muscular tissue.
2. Cross-striped muscular tissue.
3. Cardiac muscular tissue.

Plain Muscular Tissue.

This tissue is known by a variety of names besides that just given. It is called *smooth*, for the same reason that it is called *plain*, because of the usual appearance of its cells; *non-striated* or *unstriped*, to distinguish it from the second kind of muscle, which is characterized by a regular criss-cross of lines on its cells; *involuntary*, from the fact that it is not under the control of the will; *vegetative* and the *muscular tissue of organic life*, because it aids directly in the performance of those offices which are classed as vegetative—in the organic action which is beneath consciousness.

It is found, for the most part, in the walls of the hollow organs, as, for example, the alimentary tube, the urinary bladder and the tubes leading to and from it, and the arteries and veins.

It is made up of cells (Fig. 50) which typically are fusiform; but their ends

are sometimes forked instead of being single-pointed, and sometimes the spindle shape is lost by the rounding of the extremities. Often there is observed a faint appearance of lines running lengthwise, as if the cell were trying to develop into a striped fibre. A transverse cut shows that the cell has flattened sides, evidently the result of pressure from forcible contact with its fellows. The cell is always nucleated, and generally beyond each end of the nucleus is a little collection of granules. The cell has a delicate structureless sheath. The length of the cells varies between $\frac{1}{500}$ and $\frac{1}{10}$ inch, the greater part being very small. In some situations, as in the arterioles, the cells are separate; but usually they are associated in such a way as to make bundles (*fasciculi*) or layers (*strata*), being united by a small amount of adhesive material. The cells are aggregated with much regularity, the bulge of one being adjusted to the tapering tips of its nearest neighbors (Fig. 51). When distinct bundles are

FIG. 50. — Cells of plain muscular tissue.

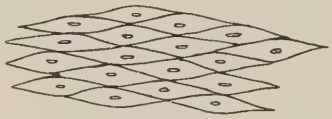

FIG. 51.—Cells of plain muscular tissue arranged in a sheet.

formed, they are usually attached at their extremities to some other structure through the agency of a fibrous prolongation.

Cross-striped Muscular Tissue.

This variety, also, like the plain, has a number of other names: *striped* or *striated*, from its microscopic appearance; *voluntary*, because the most of it is under the control of the will; the *muscular tissue of animal life*, because, while it has little direct effect upon the organs of the vegetative functions, it is largely concerned in those manifestations which are peculiar to animals. This tissue makes up a very considerable part of the bulk of the body, is principally connected with the bony skeleton, and is that material which, in other mammals, is called "flesh" or "lean meat." It is commonly found in coherent masses, of varying but definite shape, each of which, taken in connection with a fibrous prolongation at each end, is known as a muscle.

The histological unit of cross-striped muscular tissue is a *muscle-fibre*, which is the homologue of the cell of the plain muscular tissue. This fibre is like a long cylinder, with somewhat flattened sides, and rounded or conical ends. It is completely enveloped in a very delicate sheath, the *sarcolemma* ("the flesh-husk"). When examined under an objective of moderate power, it seems to be marked with delicate, longitudinal, parallel, and equidistant lines, and with broad, transverse, regularly placed bands or stripes, from which the ordinary names of striated or striped (better, cross-striped) originate (Fig. 52). Between these cross-stripes are lighter areas, which, with a stronger objective, seem to be divided by a fine line. The cause of these peculiar appearances is not manifest until the tissue is studied with a microscope of great power, but then it is found that they are deceptive. There are no continuous bands or lines running transversely, and the apparent breaks in the longitudinal continuity of the cross-lines are an illusion, caused by the extreme fineness of the contractile material at regularly alternating intervals. The accompanying diagram (Fig. 53) will illustrate this. The fibre is represented as composed of a series of threads placed side by side in longitudinal rows. Each of these threads is a fibril (*fibrilla*), and is marked by alternating bulges and constrictions, regularly placed, and arranged in the following order: a long, wide, fusiform bulge, a constriction, a small, globular bulge, a constriction, and so on

from one end of the fibril to the other. Or, to put it in a different way, a fibril looks like a fine thread, upon which are strung large, spindle-shaped beads and small, round beads, regularly alternating, and leaving a little of the thread exposed between each bead and its two neighbors. These fibrils do not touch each other, but between them, and also separating them from the sarcolemma, is a thin (probably fluid) substance, called *sarcoplasm*. The fibrils are the contractile por-



FIG. 52.—Part of a fibre of cross-striped muscular tissue, showing the alternating bands.



FIG. 53.—Diagram showing the minute structure of cross-striped muscular tissue.

tion of the fibre, and, when they contract, their spindles and beads shorten in the line of the long axis of the fibre, and swell out in the lateral direction. This causes a displacement of the sarcoplasm, which, consequently, pushes out the sarcolemma, and thus produces regularly placed protrusions along the surface of the fibre.

If the diagram is viewed at a distance (as across the room), which will obscure some of its details, the effect is very like that produced by the examination of a fibre of muscle with a microscope of mod-

FIG. 54.—Fragment of a fibre of cross-striped muscular tissue, showing fibrils separated at one end by teasing.

FIG. 55.—Fragment of a fibre of cross-striped muscular tissue, hardened, showing transverse cleavage. (Kölliker.)

FIG. 56.—Transverse section of muscle-fibre, showing nuclei. (Testut.)

erate power—faint, longitudinal lines and broad, transverse stripes, the latter separated by light intervals, which are crossed from side to side by a thin, dark streak.

The spindle portion of the fibril is called a *sarcous element;* the round beads in a single transverse plane constitute what is known as *Krause's membrane.*

In the teasing of a bit of muscular tissue with needles, it happens that many fibres are torn, and the broken ends of the fragments sometimes are frayed out

like a coarse brush, the fibrils standing for the bristles (Fig. 54). When the fibre has been hardened by certain reagents, it will occasionally show a cross-cleavage, by which it is divided into discs (Fig. 55).

Upon the inner surface of the sarcolemma are scattered a number of oval nuclei, the *muscle-corpuscles* (Fig. 56), so unobtrusive that they generally escape observation unless reagents are used in the examination. They are regarded as nucleated accumulations of the sarcoplasm.

In a fibre are many groups of fibrils, each collection being called a *muscle-column*. The fibres are aggregated in bundles (*fasciculi*), and the bundles are assembled in the contractile portion of the muscle. The fibres may be 2 inches long and $\frac{1}{250}$ inch thick, or only a tenth part of these measurements. In muscles or fasciculi whose length is greater than that of their component fibres the latter are joined to each other end to end. Fibres commonly do not branch; but in some of the lingual and facial muscles terminal divisions may be observed.

The fasciculi, as a rule, run from one end to the other of the contractile part of a muscle; but exceptions occur in double-bellied muscles and in others which have a tendinous interruption of the muscular continuity. The fasciculi, from the closeness with which they are packed, have flattened sides, and are thus more or less prismoid.

As has been said above, each fibre has, as its true and perfect investment, the *sarcolemma*. Between the fibres is a delicate areolar tissue continuous with a thicker layer of the same, which sheathes the fasciculi; and this is merely an inward prolongation of a still more pronounced lamina which coats the entire muscle. The outer tunic (Fig. 57) of the muscle is called *epimysium* ("upon muscle"); the sheaths of the bundles constitute the *perimysium* ("around muscle"); and the tissue between the fibres is the *endomysium* ("within muscle"). All of these are continuous, each with the others, and all are composed of areolar tissue.

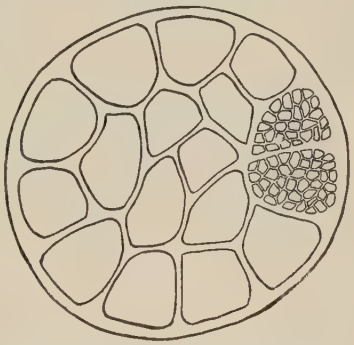

Fig. 57.—Sheaths of muscular tissue in cross-section. The muscular tissue does not appear, but is represented by the spaces between the partitions. Outside of the entire muscle is *epimysium;* between the bundles is *perimysium;* between the fibres is *endomysium*—the last shown in two areas at the right. Diagrammatic. (F. H. G.)

Fibres which end in tendon come to it either in line with its axis or obliquely to it. The sarcolemma of the end of the fibre is very closely attached to the tendon, and there is a continuity of the areolar tissue between the fasciculi of the muscle and that between the bundles of the tendon. In these ways the two parts of the muscle are so firmly united that their separation by violence is extremely rare.

The blood-vessels course between the fibres in the areolar tissue, making a network of long meshes. Lymphatics, also, are numerous in the areolar tissue, and the nerves of the muscle are abundant.

Cardiac Muscular Tissue.

The muscular tissue of the heart has peculiarities, which ally it to the plain muscular tissue on the one hand and to the cross-striped on the other. It is like the former in being composed of nucleated cells, and in being beyond the control of the will; it resembles the latter in being cross-striped, and in presenting in a mass a color similar to that of voluntary muscle. The cells (Fig. 58) are short, branched at one end, cross-striped (though with less regularity and plainness than in the case of ordinary striated muscle), and are not furnished with sarcolemma. The cells are connected with their



Fig. 58.—Cell of cardiac muscular tissue. (Testut.)

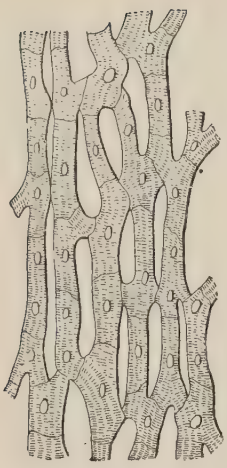

FIG. 59.—Cardiac muscular tissue, the cells united in a network. (Testut.)

neighbors by an abrupt union, and form fasciculi and networks (Fig. 59). The cardiac muscular tissue has a remarkably abundant supply of blood- and lymph-vessels.

THE NERVOUS TISSUES.

Tissues Essential to Sensation.

The nervous apparatus is conveniently considered under two heads—the central portion and the peripheral portion. The former comprises the brain and spinal cord, and is otherwise known as the cerebro-spinal axis; the latter includes the cords which radiate from this axis, and also the ganglia ("knots") upon these cords. In both the central and the peripheral regions two kinds of tissue are recognized, which are distinguished by their color as gray and white. The white is much the more abundant in both regions, but there is a great deal more of the gray in the central than there is in the peripheral. Functionally regarded, the gray matter is that which receives impressions, retains, converts, and marshals them in various ways, and originates impulses: it is the part which feels, thinks, remembers, wills; the white matter merely conveys impressions and impulses, connecting the gray matter with distant parts and associating one portion of it with another. The gray is cellular; the white is made up of fibres. Nerves consist of fibres of this kind, grouped together in bundles of small or large size.

The *gray nervous tissue* is composed essentially of cells, called *nerve-cells* or ganglion-cells. These vary greatly in shape and size in different parts, but they all have certain common features which are characteristic. They are granular, nucleated, usually pigmented, and have projections or processes which are called poles. At least one pole of a cell is prolonged as a nerve-fibre (Fig. 60), and thus it is seen that there is a structural connection between the two

FIG. 60.—Nerve-cell. All of the processes are protoplasmic except that marked *a*, which is the axis-cylinder process; *b* indicates a clump of pigment-granules. (Gerlach.)

kinds of nerve-tissue. The other processes of the cell—of which there may be many—radiate from its general mass, divide again and again, and terminate in minute twigs, which mingle with, but do not become continuous with, corresponding ramifications from neighboring cells. These processes are called protoplasmic processes or *dendrites* ("tree-like"). A nerve-cell, with its dendrites, and the nerve-fibre which is continuous with the cell, constitute a *neuron* (Fig. 61). The neuron is the unit of structure of nervous tissue.

The *white nervous tissue* (called white on account of the appearance of a mass of it) is made up of fibres which vary in diameter and length, but have their

main difference in the presence or absence of a certain coat. The simplest, because least clothed, of the fibres are small, pale, fibrillated, nucleated threads of tissue, whose component fibrillæ are the minutest independently recognizable portions of the tissue. Such a thread is called a *pale fibre*, and also bears the name "non-medullated," on account of the lack of the tunic which distinguishes the other kind. It sends off minute filaments at a right angle with its course soon after emerging from the cell, and then continues without further branching until near its end, where it divides into bundles of fibrillæ, each of which splits up into smaller bundles, and so on, until the fibre has frayed out into its ultimate filaments.

Besides the pale fibres is a more numerous class, called *white* or *medullated fibres*. A typical representative of this variety has three parts, of which the first and essential is centrally located, and from this fact is named the *axis-cylinder* (axis-band or axial fibre). The axis-cylinder is like a pale fibre, being fibrillated, giving off fine, lateral twigs near its origin, and dividing into its ultimate fibrillæ at its periphery in the same manner.

Outside of the axis-cylinder is a thick, insulating tunic, composed of a soft, oily material (myelin), and known as the *medullary sheath* or white substance of Schwann. Surrounding this first coat is a second, very delicate and thin, but sufficiently strong to keep the medullary sheath in shape. It is called the *primitive sheath*, *neurilemma* ("nerve-husk"), or nucleated sheath. The medullary sheath is evenly spread upon the axis-cylinder, excepting at regular intervals, where it is lacking for a minute space, thus leaving the primitive sheath as the sole covering of the fibre. At these places the fibre presents the appearance of being encircled with a cord so tightly as to squeeze the medullary substance away from the part. These constrictions are known as the *nodes of Ranvier*, and the lengths of fibre between them are called the *internodes* (Fig. 61).

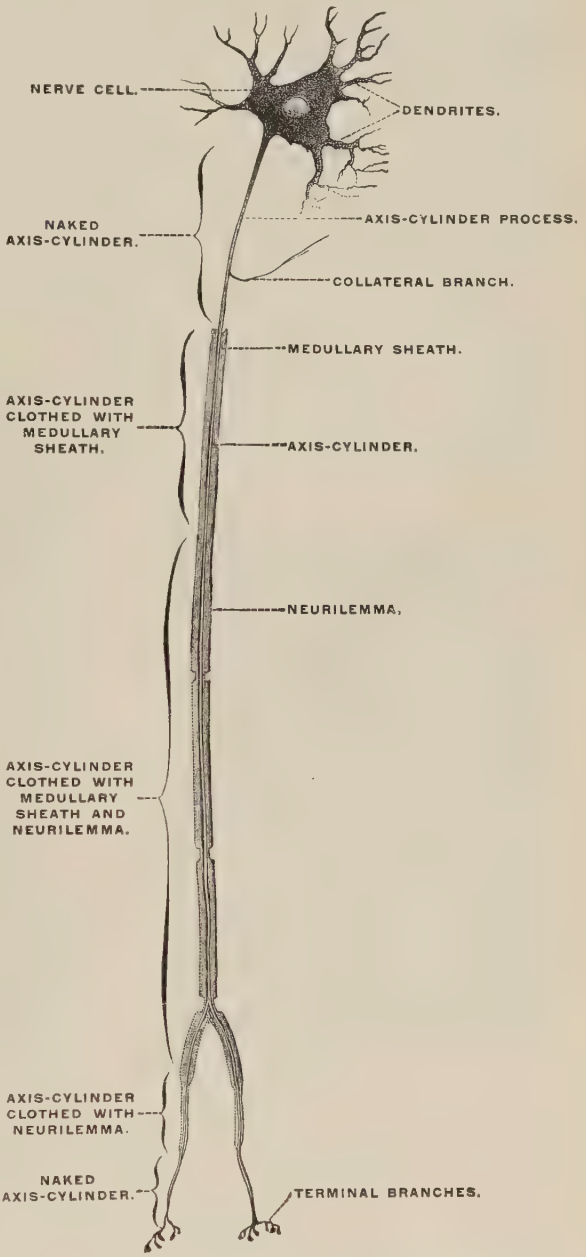

FIG. 61.—A neuron. (Stöhr.)

The primitive sheath has on its inner surface a nucleus for each internode, midway between the ends of the latter. Either or both of the sheaths may be lacking; and in the latter case the axis-cylinder alone is left, and we have a pale fibre instead of a white one. In brief, the axis is always present as the one essential thing in a nerve-fibre; if it is coated with the medullary sheath, it is a white fibre; and it may be in one part naked and in another clothed. There is no break in the continuity of the axis from one end to the other. The filaments or fibrillæ composing it are held together by a cement called *neuroplasm*.

A number of nerve-fibres gathered into a coherent bundle constitutes a *funiculus* ("little rope"). It is enclosed in a sheath of laminated fibrous tissue, called *perineurium* ("around nerve"), from the innermost layer of which shelf-like trabeculæ project between irregular groups of nerve-fibres, and compose the *endoneurium* ("within nerve"). A single funiculus with its wrappings may constitute a nerve; but usually a number of funiculi are grouped together in a nerve, and, when this obtains, they are kept in close relation to each other by a common sheath, the *epineurium* ("upon nerve"). The bundles in a nerve have a network arrangement, each funiculus splitting up more or less at short intervals, and its component fibres passing into neighboring funiculi (Fig. 62). The fibres, however, always retain their individuality: while they cross and recross in the nerve, and any one of them may be an ingredient of many funiculi in passing from centre to periphery, there is never any coalescence between them. In the branching of nerves the same rule is observed: a funiculus lets some of its fibres switch off at the side or separates them into substantially equal parts, but the fibres themselves remain undivided (Fig. 63). The larger vessels of a nerve course in its sheath, and the capillaries are arranged in long meshes between the fibres. The epineurium is also supplied with nerves, called *nervi nervorum* ("the nerves of the nerves").



Fig. 62.—Connection between the bundles in a nerve. (Dalton.)



Fig. 63.—Branching of a nerve. (Dalton.)

The origin of nerves varies with their function. Those which convey impulses from the centre to the periphery, called *efferent nerves* (meaning "carrying from"), grow outward from nerve-cells in the centre; while those which convey impressions from the periphery to the centre, called *afferent* (meaning "carrying to") or sensory nerves, grow inward from nerve-cells in organs of special sense or in

ganglia. These fibres branch within the nerve-centre, and send their ultimate twigs among the cells, but do not unite with them.

Ganglia ("knots") are bunches of various sizes occurring in the course of nerves. They are made up of nerve-cells and their coverings, massed upon and between the fibres of nerves (Fig. 64). Each cell of a ganglion has one or more axis-cylinder processes, which are prolonged into nerve-fibres. The ganglion is clothed with areolar tissue, which sends trabeculæ through it in every direction.

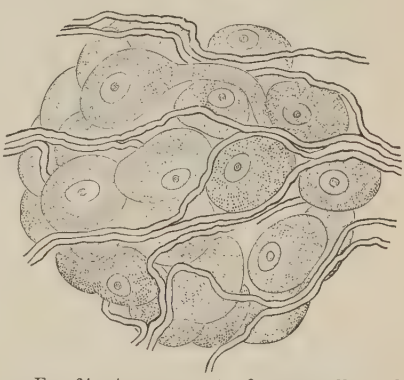

Fig. 64.—Arrangement of nerve-cells and nerve-fibres in a ganglion. (Dalton.)

Before coming to their peripheral division many medullated nerves lose their white substance; but others retain it during several stages of branching, and in these last the division takes place at nodes. After the disappearance of the medullary sheath the primitive sheath continues for a variable distance.

Afferent (sensory) *nerves* have various peripheral terminations. Some of them end in cells, others in special organs, as tactile corpuscles, end-bulbs, and Pacinian bodies. These will be described in the chapter devoted to the organs of the senses. Certain afferent nerves end peripherally by the final separation of the axis-cylinder into its component fibrils, which run between the tissue-elements, and generally either end there or else penetrate the cells. The sensory nerve-endings in tendons are often suggestive of the ending of motor nerves of voluntary muscle, to be described presently. Close to the muscle proper a medullated fibre passes into the tendon, divides repeatedly, and the filaments of the axis-cylinder penetrate widely into the tendon.

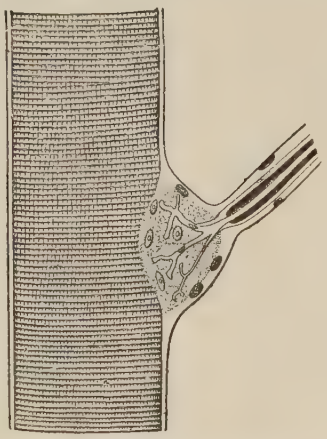

Fig. 65.—Motorial end-plate, the termination of a nerve in a fibre of cross-striped muscle. (Testut.)

Efferent nerves have different endings according to the variety of muscle to which they are distributed. In the case of the plain muscular tissue the fibrillæ of the nerve are brought close to the muscle-cells, after the nerve has formed a plexus in which ganglion-cells often occur. In cardiac muscle the nervous filaments come from a long-meshed plexus, and are applied to the contractile fibres. Finally, in striated muscle, after the formation of a close plexus, the nerve loses its white sheath, the axis-cylinder enters the muscle-fibre, and just beneath the sarcolemma splits up into its fibrillæ, which spread out in a thin mass of granular material in which nuclei are embedded. This is the *motorial end-plate* (Fig. 65).

MEMBRANES.

In its widest meaning the word "membrane" is used to designate any thin expansion of tissue, either simple or compound. Thus, we speak of the periosteum, the covering of bone, as a fibrous membrane; we call the layer of cells beneath the epithelium of free surfaces the basement membrane; and a structure composed largely of blood-vessels may be known as a vascular membrane. But in a restricted, although the commonest, sense the word is applied to a broad, sheet-like organ, with a free (unattached) surface, furnishing the covering of a

part or the lining of a cavity. With the latter signification the term is employed in this section.

The type upon which all of the members of the group are constructed consists of a foundation of white and yellow fibrous tissue, which is limited toward the free surface by a single layer of very thin, plate-like cells, and upon this last an epithelium (Fig. 66). The fibrous tissues are felted into a layer of variable thick-

FIG. 66.—A typical membrane in vertical section. (F. H. G.)

ness, strength, flexibility, and elasticity, according to the proportion and arrangement of its ingredients, and is called the *corium* ("leather"). The lamella of flattened cells surmounting this is really a part of the corium, for it consists merely of cells of the white fibrous tissue, greatly attenuated and adhering to each other at their edges. It is termed the *basement membrane.* Finally comes the *epithelium,* which presents upon the free surface, and may be either simple or stratified in numberless layers.

In most cases the attached surface of the membrane is connected with the underlying structures by areolar tissue, abundant or scanty, which permits some gliding of the membrane on the subjacent parts. This areolar tissue is called subserous, submucous, subcutaneous, and so on, according to the kind of membrane under which it lies. The line between it and the corium of the membrane is not exactly determinable, as a rule, the two structures being made of precisely the same materials, differing only in their mode of arrangement, and gradually shading from one into the other. When the membrane is peeled off from the areolar tissue its under surface is flocculent, on account of the attachment of bundles of the fibrous tissues of the latter. In the areolar tissue course the larger vessels and nerves of the region, sending their branches to, or receiving their radicles from, the corium.

There are four classes of membranes:

1. Serous Membranes.
2. Synovial Membranes.
3. Mucous Membranes.
4. Cutaneous Membrane.

SEROUS MEMBRANES.

Of all the membranes, the serous (*membranæ serosæ*) are the simplest—the nearest the type which has been described. They are always moist with a fluid very like blood-serum, and from this fact they derive their name. They are thin and transparent, permitting a view of the immediately subjacent parts, fairly strong, considering their delicacy, and somewhat elastic. With a single exception, which obtains in all females, but never in males, the serous membranes are shut sacs; that is to say, they have no opening by which they communicate with the surface of the body (Fig. 67). In the simplest of them this condition is so plain as to be easily understood; in the most complicated it is not especially difficult to demonstrate, even though the form of the membrane

FIG. 67.—Diagram showing arrangement of a serous membrane. The broken line represents the membrane lining the closed cavity. (F. H. G.)

suggests but remotely that of a sac. In those which are manifestly bag-like, and which furnish a complete or partial coating to internal organs, two parts are recognized—that which is attached to the viscus, and that which is fastened to the walls of the cavity in which the organ is contained. The former is called the *visceral layer*, the latter the *parietal* ("on the wall") or *reflected portion*. The relations of parts will be easily comprehended by reference to Fig. 68.



FIG. 68.—Diagram showing that when a viscus encroaches upon the space of a cavity, it still remains outside of the serous membrane, which gives it an external tunic while continuing to line the cavity. (F. H. G.)

The diagram represents a viscus pushing one wall of the serous sac inward, thus making this portion serve as a tunic for the organ; consequently, this is the visceral part. The other portion of the sac lines the wall of the cavity in which the viscus now is enclosed, and is, therefore, the parietal part. It is not asserted that this is the precise way in which the viscera procure their serous coat; but the condition which exists is such as would obtain if this procedure were actual. For the sake of clearness in the diagram, a cavity is represented between the epithelial surface of the visceral layer and that of the parietal layer; but, as a matter of fact, the two layers are in actual contact, and the serous cavity, of which mention is often made, is not real, but virtual.

Serous membranes present many folds, which connect viscera with each other or with the walls of a cavity, or simply project into a cavity and return on themselves, forming a tassel or an apron. A serous membrane may line a fibrous bag, and be reflected over the surface of a contained viscus, and in such case is denominated a *fibro-serous membrane*.

The *corium* is thin, but contains blood-vessels, lymph-vessels, and lymphoid and adipose tissues. The lymphatics are especially abundant. The nervous supply is small and is sympathetic in origin.

The *epithelium* (Fig. 69) is always single and flattened, the cells having irregular, notched edges and fitting accurately together, except that, at intervals, little apertures are found, some of which are the beginnings of lymph-vessels, and from this fact are named *stomata*, from the Greek word for "mouth;" and others are filled with processes from cells in the corium, and hence are called *pseudo-stomata* ("false mouths"). The true stomata are distinguished by a little boundary of cells, much smaller than those furnishing the general surface. The demonstration of their immediate connection with lymph-vessels led to the belief that serous membranes are only expansions of lymphatics, and, consequently, are to be regarded as belonging to the lymphatic system. Their physiological performance and their behavior in disease support this theory.

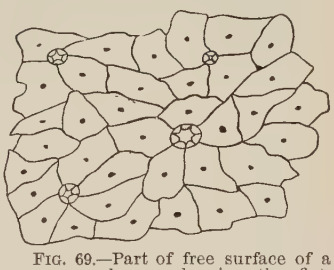

FIG. 69.—Part of free surface of a serous membrane, showing the flattened epithelial cells and the stomata.

The *epithelial surface* is particularly smooth and glistening, and thus the gliding of opposing portions is accomplished with very slight friction, which is still further reduced by the presence of the thin fluid constantly secreted by the cells. This fluid, which lubricates the membrane, is normally present in so small an amount that it merely moistens the surface. Just as fast as it is formed it is withdrawn by the lymphatics through the stomata. But, in disease, when the equilibrium between secretion and absorption is so disturbed that the lymphatics do not carry the fluid away as rapidly as the cells manufacture it, an accumulation occurs, the parietal layer is pushed away from the visceral by the intervening liquid, and in this way the virtual cavity is converted into a real one.

Serous membranes may be divided into tolerably distinct classes, as follows:

1. Serous membranes proper.
2. The lining membrane of the vascular system.
3. The lining membrane of certain cavities in sustentacular tissues.
4. The lining membrane of the cavity of the cerebro-spinal axis.

1. Serous Membranes Proper.

Under this head are included the various membranes which result from the division of the original serous membrane lining the thoracico-abdominal cavity (Fig. 70). These are derived from the single sac by constriction, the thoracic first

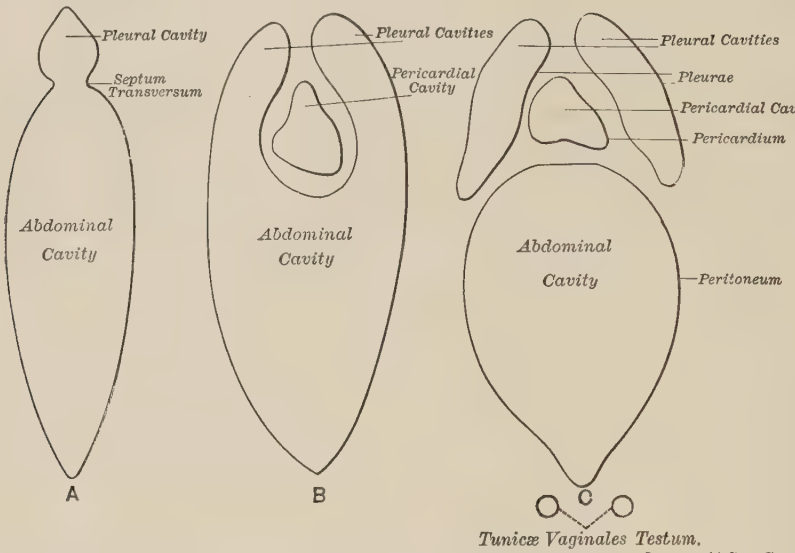

FIG. 70.—Diagram showing formation of several serous sacs from the one original sac. (After Gegenbauer.)

being separated from the abdominal, and then subdivisions of each of these making three distinct sacs of the upper grand division—the two pleuræ and the pericardium—and three of the lower grand division—the peritoneum and the two vaginal tunics. They are called serous membranes *proper*, because they present, to an extent which the others do not, the features which have been mentioned as characterizing this class of structures. The pleuræ cover the lungs and line the portions of the thoracic cavity which contain them; the pericardium stands in a similar relation to the heart; the peritoneum lines the abdominal cavity and clothes its contained viscera; and the vaginal tunics perform a like service for the two chambers of the scrotum and the organs (the testicles) which are lodged in it. These serous membranes will be treated of in detail in connection with the organs to which they are respectively related.

2. The Lining Membrane of the Vascular System.

This is the internal coat of the heart and vessels, known also as the *tunica intima*. It bears a close resemblance to the proper serous membranes in structure and appearance. Its power of forming a fluid like that of the great serous sacs is not to be doubted, but is not demonstrable, as the fluid must mingle with the current of blood or lymph as soon as it is formed. One at all acquainted with the circumstances favoring the coagulation of the blood, and the necessity of having it flow freely through the microscopic tubes which we call capillaries, would feel warranted in the declaration that no other membrane than a serous would be practicable as a lining to the blood-vessels and lymphatics. If a mucous membrane were employed for the purpose, the small vessels would

speedily become clogged with its thick and slimy secretion; and the thinnest and most delicate cutaneous membrane would obviously be too thick and coarse to permit the transudation necessary for the nutrition of the tissues. Only a serous membrane with its almost frictionless surface and its watery secretion could possibly meet the requirements of the case.

The details of structure of the tunica intima will be presented in connection with the description of the heart, blood-vessels, and lymphatics, respectively.

3. The Lining Membrane of Certain Cavities in Sustentacular Tissues.

The most conspicuous illustration of this form of serous membrane is found in the internal ear. Around the greater part of the membranous labyrinth, which is the essential portion of the organ of hearing, and between it and the bone in which it is lodged, is a considerable space, lined with serous membrane and filled with a watery fluid, which is called perilymph. Another example is found between the back of the eyeball and the bed of fat upon which it reposes. It is called the capsule of Tenon, and is a shut sac, with a visceral layer upon the globe of the eye and a parietal layer attached to the postjacent adipose tissue. It permits free movements of the eye in the orbit with the least possible friction. In character and function it closely resembles the proper serous membranes.

4. The Lining Membrane of the Cavity of the Cerebro-spinal Axis.

The brain and spinal cord are hollow organs. Their cavities are lined with a delicate membrane, serous in character, its epithelium being in embryonic life ciliated, and its secretion thin and watery. The membrane is known as the *endyma* ("garment") or *ependyma*. It will be described in the chapter on the Cerebro-spinal Axis.

SYNOVIAL MEMBRANES.

By certain authorities the synovial membranes (*membranæ synoviales*) are classed with the serous, and there are some good arguments in favor of this association. But, while these membranes have no communication with the surface, and have the same order of function as the serous membranes, there are such differences as to justify a separation of the one from the other. The group of synovial membranes with which surgeons have most to do are not shut sacs, although each forms a part of the wall of a closed cavity; they have a different lining from serous membranes; their secretion is not serous; and they are not associated with the viscera. Therefore, they are here treated by themselves.

The synovial membranes form a part or the whole of the enclosure of certain cavities, which are associated with the osseous framework or the muscular system, or both; and the service which they render is the lubrication of parts which glide upon each other.

Fig. 71.—Synovial membrane—free surface, showing imperfect covering of cells.

A synovial membrane is composed of fibrous tissue, having on its free surface an imperfect covering of cells (Fig. 71), and thus affording the great exception to the rule that free surfaces are completely clothed with cells. These cells are of no regular shape, are branched, and are gathered into little patches, which are scattered over the surface, leaving considerable areas upon which no cellular structure appears. The cells are often called *epithelioid*, which means "like epithelium." Their secretion is a glairy fluid, which smears the entire free surface of the membrane, and is called *synovia*, from its resemblance to the white of egg.

Synovial membranes are divided into the following groups:

1. Articular.
2. Vaginal.
3. Bursal.

1. Articular Synovial Membranes.

These occur in those articulations of the bony skeleton wherein two surfaces move upon each other. The bones concerned in such a joint are covered on the surfaces, which enter into the composition of the articulation, with a crust of cartilage, whose free surface is very smooth and hard. The bones are held together by strong bands of white fibrous tissue—the ligaments—which encapsulate the expanded ends of the bones, forming hollow cylinders, which bound the joint. The inner surface of a capsular ligament is covered with a synovial membrane, which is reflected from it a little way upon the margin of each of the cartilages. Thus, the synovial membrane is a short tube with its edges turned inward. The arrangement of the parts will be seen in Fig. 72.

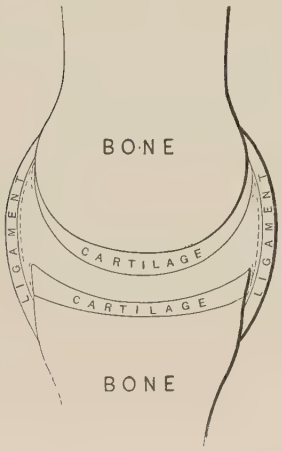

FIG. 72.—Diagram of articular synovial membrane. The cartilages are represented as drawn apart for the sake of clearness. The synovial membrane is shown by a broken line. (F. H. G.)

If, as sometimes occurs, a ligament or a tendon passes across or through the joint-cavity, the synovial membrane ensheaths it. Occasionally the membrane exhibits folds, which cross the cavity or hang into it like fringes, and perhaps contain some adipose tissue. In all cases the synovia secreted by the membrane lubricates the cartilages and other structures, which present a free surface in the joint.

2. Vaginal Synovial Membranes.

These are so named from *vagina*, "a sheath," and are also known as *synovial sheaths*. They are found in situations where the tendons of muscles run over bones, to which they are bound down by strong, fibrous bands. The bone in these cases is grooved, and the fibrous tissue bridges over the gutter, thus making a very strong, fibro-osseous canal, through which a tendon passes to its destination. The synovial membrane is arranged in the form of a tubular sheath, one portion lining the canal, the other investing the enclosed tendon, as will be seen in Figs. 73 and 74.



FIG. 73.—Diagram of a vaginal synovial membrane in cross-section. The membrane is shown by the broken lines. A space is left between the tendon and channel-wall for the sake of clearness. (F. H. G.)

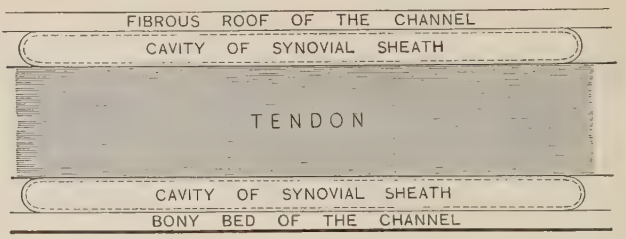

FIG. 74.—Diagram of a vaginal synovial membrane in longitudinal section. Compare with Fig. 74. (F. H. G.)

In the movements of the tendon friction is reduced to its lowest terms by the lubricating agency of the synovia.

3. Bursal Synovial Membranes.

Other names for these structures are *synovial bursæ* ("synovial purses"), *bursæ mucosæ* ("mucous purses"), and *vesicular synovial membranes*. A synovial bursa is a little bag of fibrous tissue, lined with synovial membrane, and placed between parts which move upon each other, as two muscles, two tendons, a muscle or tendon and a bone, the skin and a bone. The sac is connected with surrounding parts by areolar tissue, and the opposite sides of its internal surface are in contact, and kept moist with synovia. Some of these membranes are developed from spaces of areolar tissue by closure of connection with surrounding spaces, and condensation of the contiguous fasciculi of the tissue.

MUCOUS MEMBRANES.

The serous and synovial membranes line closed sacs; the mucous membranes (*membranæ mucosæ*) line passages and cavities which have a direct communication with the outer surface of the body. Indeed, from the physiological point of view, the parts which are covered by them are external, for they are regarded as inversions of the integument—portions of the outer investment tucked in and modified, but never lacking continuity with it.

There are two separate sets of mucous membranes—the gastro-pulmonary and the genito-urinary. Each of these consists of a continuous membrane, which lines two series of organs, and varies in many respects according to the organ of which it forms a part. The *gastro-pulmonary mucous membrane* (Fig. 75) furnishes a free surface for the alimentary and respiratory systems, and gets its name from a principal organ of each—the stomach and the lung. The *alimentary part* of it begins at the lips and passes through the mouth, the middle and lowest parts of the pharynx, the gullet, stomach, small and large intestines, and anal canal, and then comes to the skin-surface. In its course it sends offsets to the ducts of the salivary

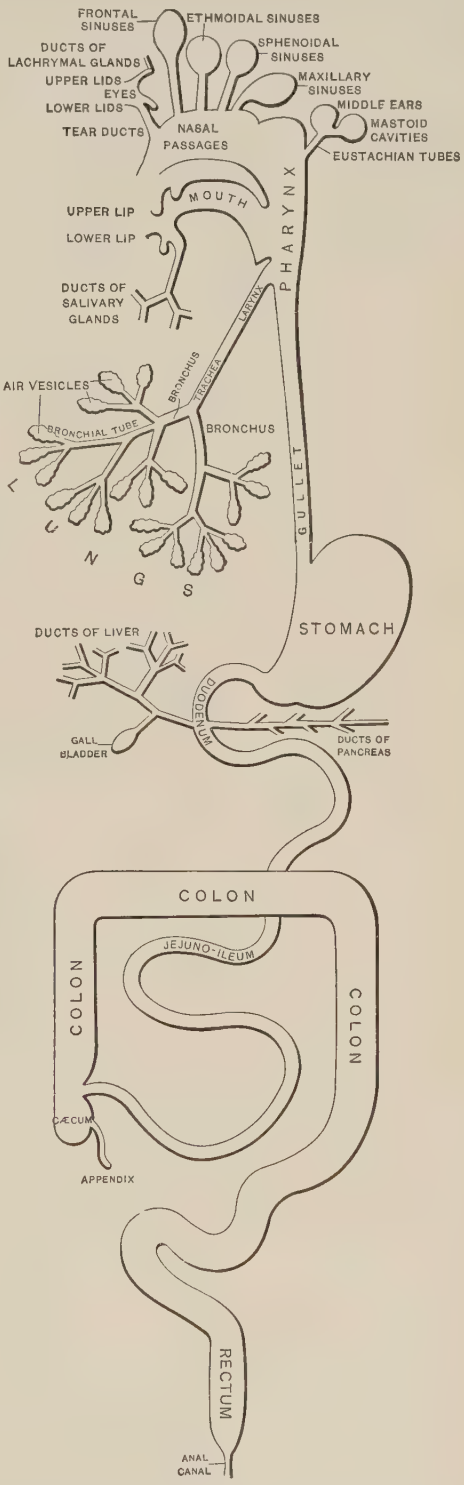

FIG. 75.—Diagram of the gastro-pulmonary mucous membrane, showing the continuity of all its parts. (F. H. G.)

glands, of the pancreas, and of the liver, to the gall-bladder, and to the vermiform appendix. The *respiratory portion* begins in the nostrils, and passes through the entire pharynx, the larynx, trachea, bronchi, and bronchial tubes, ending in the air-vesicles of the lungs. From the nasal cavities it gives prolongations to the inner surfaces of the eyelids and the front of the eyeballs, and to the chambers in the frontal, ethmoid, sphenoid, and upper-jaw bones; and from the pharynx it runs through tubes to the drums of the ears and the cavities of the mastoid portion of the temporal bones. The *genito-urinary mucous membrane* lines the genital and urinary tracts, as its name implies. The portion which forms a part of the male reproductive organs (Fig. 76) leaves its junction with the skin at the distal open-

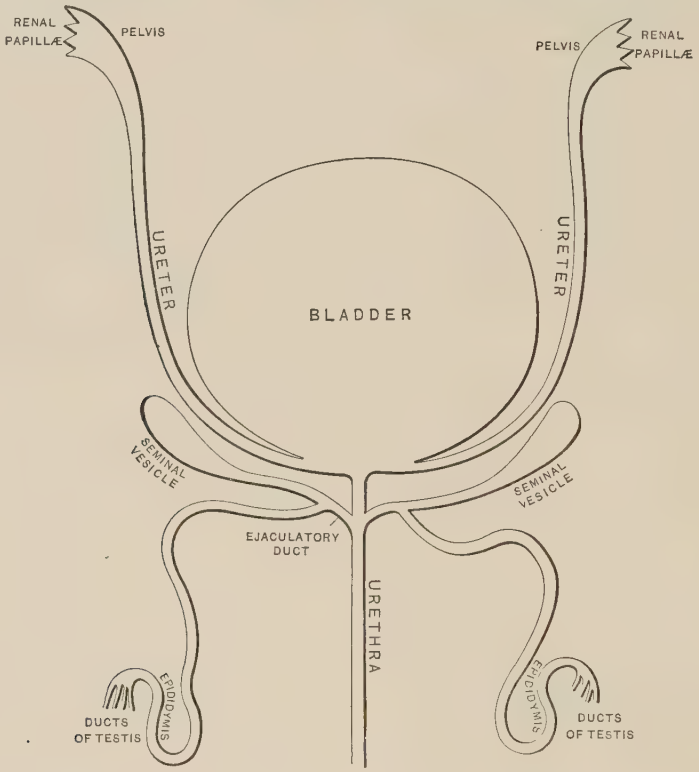

FIG. 76.—Diagram of male genito-urinary mucous membrane, showing continuity of all its parts. (F. H. G.)

ing of the penis, and is traced through the urethra to within an inch of its proximal end, where it enters the male womb and switches off on each side into the ejaculatory duct, from which it sends one prolongation to the seminal vesicle and a second to the vas deferens, and through this last runs to the epididymis and the ducts of the testicle. It sends offsets to the ducts of the suburethral glands and to those of the prostate. In the female the mucosa of the genital tract (Fig. 77) begins at the vulva, goes through the vagina, the uterus, and the two Fallopian tubes, at the free extremities of which it is continuous with the serous membrane lining the abdominal cavity. Offsets from it line the ducts of the vulvo-vaginal glands. In both sexes the *urinary mucous membrane* lines the urethra, bladder, and ureters, ending at the papillæ of the kidney.

The variations in the character of the mucous membrane in different parts are very great, and changes are extremely abrupt at several points, while in other cases the modifications are effected very gradually. The *corium* (Fig. 79) is generally much thicker than in serous and synovial membranes. It contains a comparatively small proportion of yellow fibrous tissue. When it is largely occupied by follicular glands, the ordinary fibrous tissue is to a considerable extent replaced

by adenoid-reticular, in whose meshes are entangled lymphoid cells, thus constituting a diffuse lymphatic tissue. Usually the corium is bounded toward the free surface by a basement membrane, and deeply by a thin layer of plain muscular tissue, which is named *muscularis mucosæ* ("the muscular [coat] of the mucous

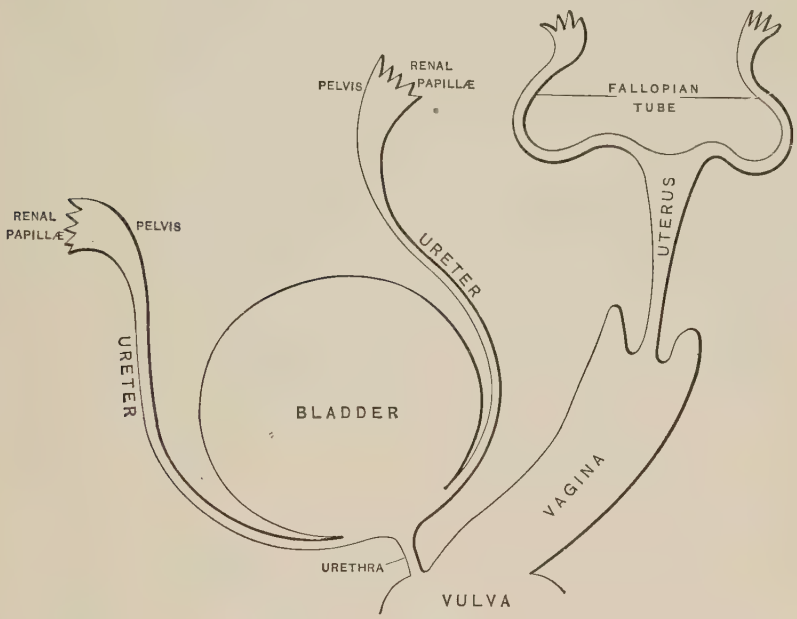

FIG. 77.—Diagram of female genito-urinary mucous membrane, showing continuity of all its parts. (F. H. G.)

[membrane]"). The *epithelium* is the one element in the membrane which is never wanting; but there are only a few cases and very limited areas in which it is the sole representative, the covering of the cornea being the most conspicuous.

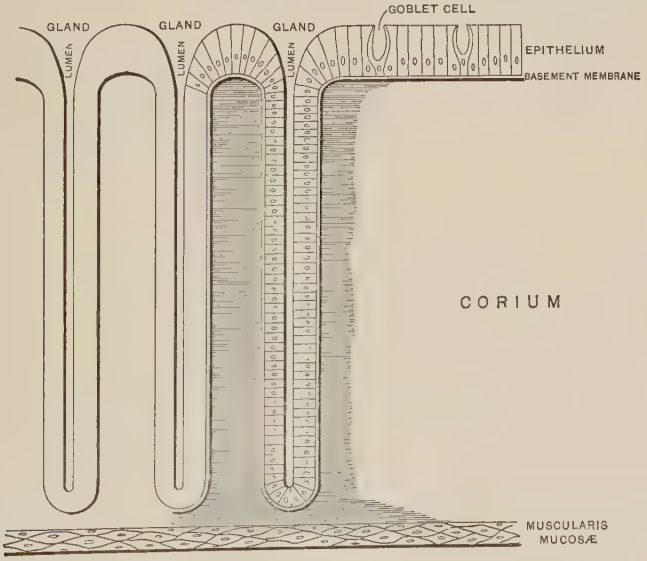

FIG. 78.—Diagram of mucous membrane in vertical section. (F. H. G.)

The epithelium may be single or stratified, of any possible shape, and with or without cilia. The membrane derives its name from the glairy fluid, *mucus*, which always covers it. This secretion is protective, and is abundant in propor-

tion to the amount of irritation to which the membrane is subjected. Where the epithelial coat is columnar and single, the mucus is furnished very largely by the goblet-cells of the epithelium; but, as these chalices are a modification of columnar cells, they are not found where the epithelium is flat; and in such cases all of the mucus comes from distinct glands, which devote themselves to this work.

Mucous membrane is generally connected with subjacent parts by areolar tissue; but exceptionally this is not present, and then the membrane is attached directly. This occurs only in cases where the passage or cavity which the membrane lines is not subject to distention, as in the nose, where the corium is fastened to the bone. In general, the areolar layer beneath mucous membrane is very abundant, and the usefulness of this arrangement appears when we consider that the corium has but little elastic tissue in its composition, and in many cases is pervaded by glandular structures, which would be injured by the stretching of the membrane. As a rule, the cavities and tubes which are lined with mucous membrane are liable to great changes of size, owing to their intermittent occupation by solids and fluids to such an extent as to distend them. Between the periods of distention are times of collapse. If the membrane were elastic, like serous membrane, and had no delicate glands embedded in its substance, it could be stretched within a large range without harm, and would return to its state of relaxation on removal of the distorting force; and in such circumstances it would need but a moderate areolar layer between it and the subjacent parts. As it is, the membrane when relaxed becomes more or less folded—thrown into shallow or deep wrinkles—and presents a series of ridges, called *rugæ*, which in tubes are arranged in line with the longitudinal axis of the organ (Fig. 79). When a

Fig. 79.—Diagram showing the folding of the mucous membrane in a collapsed tube. (F. H. G.)

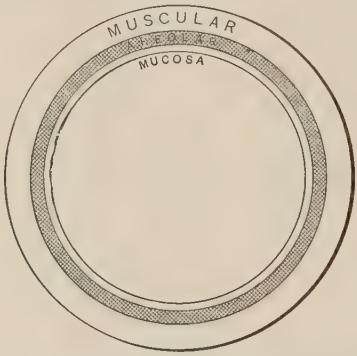

Fig. 80.—Diagram showing the effacement of the folds of mucous membrane and the compression of the areolar layer when the tube is distended. Compare with Fig. 80. (F. H. G.)

distending force is applied, as in the passage of a bolus of food through the gullet, or after a large dinner has been deposited in the stomach, these folds are effaced, the membrane becomes smoothed out, and presents an even surface (Fig. 80). This extensive change is rendered possible by the abundance of the submucous areolar coat, which is strong and elastic.

Mucous membrane is very vascular, the vessels for its supply running in the submucous areolar tissue, and sending minute branches into the corium above. Its nerve-supply varies greatly in different parts—some being extremely sensitive, others dull of feeling. As would be inferred from the amount of lymphoid tissue in the corium, its lymphatics are very abundant. The peculiarities of the mucous membrane of each part where it exists will be detailed in the description of the organs respectively concerned.

CUTANEOUS MEMBRANE.

By this term is indicated the membrane which furnishes the outer covering of the body, and is ordinarily called *skin*. It is a complex structure, and has

a variety of functions, among which is the distinguishing of impressions of touch. It will, therefore, be more appropriately considered with the organs of the senses.

GLANDS.

A gland is an organ, which abstracts from the blood certain materials and makes of them a new substance, which is then discharged into a cavity or upon a surface. In other words, a gland is a secreting organ, its process and its product both bearing the name of secretion. Simply constructed membranes, such as the serous, doubtless perform some secretory work; but it is always of a low order, and the resulting product is only slightly different from the materials of which it is composed. It would not be expected that the cells upon a plane surface, whose principal function is protective, and which are constantly subjected to hard usage on account of their exposed situation, would be able to do secretory work of any but the most primitive kind. It would be as reasonable to demand a high grade of work from an artisan stationed in the middle of a thoroughfare, where he would be jostled by every passer. Such a one needs freedom from interference, and withdraws from the bustle of the throng into a secluded retreat, where he has every facility for doing the most delicate and elaborate tasks. Nature acts in precisely this way in constructing an organ which is to make a secretion: a depression appears in a membrane—an inversion of the surface-structure takes place—and the cells, which are thus removed from the worries and dangers of the open and exposed locality, experience various changes. They become plumper and softer, their nuclei enlarge, and they develop a capacity for secretion, which their less favorably environed neighbors never emulate. The materials which they abstract from the blood are so wrought over that their original character is not suggested by the nature of the secretion of which they are the ingredients. The organ which accomplishes this thing is a true gland; and, as a rule, the more completely it is guarded from annoyances and interruptions, the more elaborate and valuable is its work.

The essential thing in a gland, as has already been intimated, is the *epithelial cell*. The forms of secreting cells are as varied as possible, but the tendency is to keep near the spherical type. Indeed, spheroidal epithelium is hardly to be looked for outside of glands.

The simplest form of a gland is the follicular, a mere dimple in the surface (Fig. 81, *A*). Enlargement of the embedded tube, without dilatation of its open-

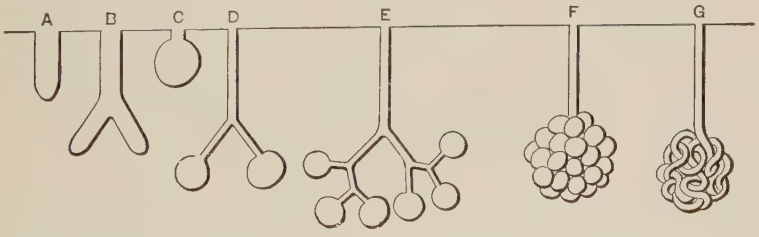

FIG. 81.—Diagram showing development of glands: *A*, a mere dimple in the surface; *B*, enlargement by division; *C*, enlargement by dilatation; *D*, a combination of *B* and *C*; *E*, a racemose gland; *F*, development of method of *E*; *G*, a single tube intricately coiled. (F. H. G.)

ing, makes a saccular or flask-shaped gland (Fig. 81, *C*). Branching of the lower parts changes a simple gland into a compound (Fig. 81, *B*), and what was previously the upper part of the secreting organ now becomes the duct of discharge, its epithelium losing its true glandular character, and becoming more like that upon the general surface. By repetition of these processes the gland becomes not only larger, but more complicated — fibrous or reticular tissue occupies the interstices, and affords mechanical support; muscular

tissue forms around the ducts; and in many ways elaboration goes on, until in some glands not a suggestion of the original type remains to casual observation. And yet, the parentage of the most intricately constructed gland can be traced back to the little inversion of the surface, which has been shown to be a simple follicular gland, and the structural principle is identical in the two.

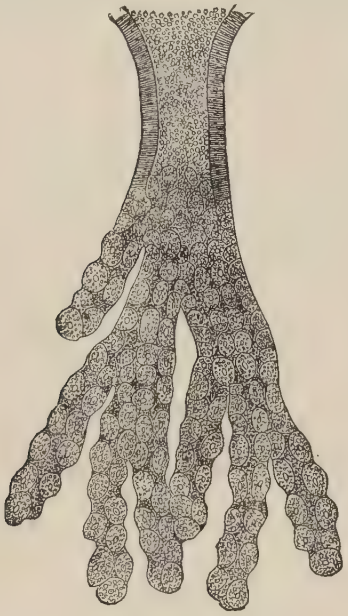

FIG. 82.—Compound tubular gland. The upper part is the duct; the lower is the secreting portion. (Kölliker.)

FIG. 83.—Compound racemose gland. The resemblance to a bunch of fruit is very marked. (Milne-Edwards.)

EMBRYOLOGY.

By J. P. McMURRICH.

AT one period of its existence every vertebrate animal is represented by a single cell, from which the adult individual develops by its repeated division and by the functional and histological differentiation of the aggregate of cells so formed. The cell, however, which has the power of undergoing this development is one which results from the complete fusion of two distinct elements, likewise cells, one of which is termed the *ovum*, and represents the female element of reproduction, the other being the *spermatozoön*, the male element.

Spermatogenesis.

The male cell is formed in the testis, and, if a section of a seminiferous tubule be examined, an arrangement will be seen which is represented diagramatically in Fig. 84. The cells lining each tubule are arranged in several layers, the outermost

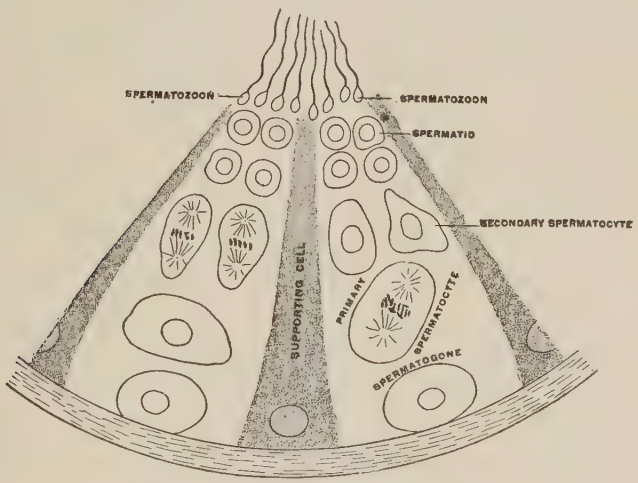

FIG. 84.—Development of spermatozoa.

layer being formed principally by a number of cells known as *spermatogones*. Each of these from time to time divides, one of the cells so produced persisting as a spermatogone, while the other becomes what is termed a *primary spermatocyte*. This cell later divides into two cells, each of which is a *secondary spermatocyte*, and these, undergoing a further division, give rise to cells termed *spermatids*. Thus, from each primary spermatocyte, by two divisions, four spermatids are developed, and each of these last becomes a *spermatozoön*. In addition to these various cells, others are to be found resting upon the basement membrane of the tubule, and extending through the various layers of the developing cells, the spermatozoa being grouped upon their inner ends. These are the *Sertoli cells*, or *supporting cells*, and they do not take any part in the formation of the spermato-

zoa, but, as their name indicates, serve for the support of the germ-cells, and probably assist in their nutrition.

The spermatozoa are the result of modification of the spermatids. Each of these latter is at first a round cell with a rather large nucleus, near which lies the *centrosome*. Gradually this cell elongates, the nucleus takes up a position near one extremity, an axial filament develops in the cell-body, the centrosome comes to lie behind the nucleus, and, as the final result, there is produced the mature spermatozoön, a body measuring in length about $\frac{1}{500}$ inch, and consisting of (*a*) a pyriform head composed of the nucleus of the original spermatid, surrounded by an exceedingly thin layer of protoplasm; (*b*) of a "middle piece," immediately behind the head, and representing probably the centrosome of the spermatid; (*c*) of the tail, derived from the cell-body of the spermatid, and composed of an axial filament surrounded by a sheath of protoplasm, somewhat variable in form, though usually simply cylindrical; and (*d*) of a terminal filament, which is the end portion of the axial filament.

Oögenesis.

The ovum, as it exists in the ovary, corresponds to the primary spermatocyte of the male, and must undergo certain changes ere it is ready for union with the spermatozoön.[1] When ready to burst from the Graafian follicle, the human *ovum* (Fig. 85) is a spherical cell about $\frac{1}{150}$ inch in diameter, enclosed within a membrane, the *zona radiata*, and containing a large *nucleus*, situated somewhat excentrically, while centrally there are a number of granules of *food-yolk*, a substance much more abundant in the ova of other mammals, such as the cat, and which forms the greater mass of the ovum of birds and reptiles. The maturation phenomena (Fig. 86) by a series of divisions convert the ovum into a structure homologous with a spermatid.

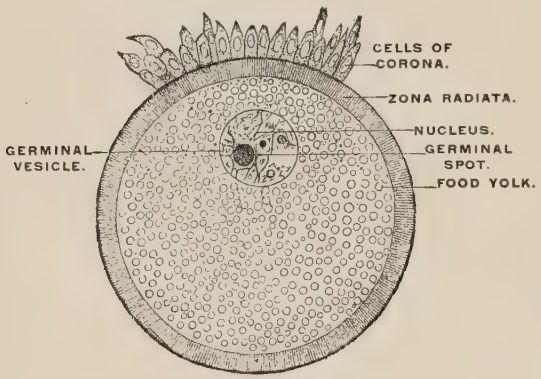

FIG. 85.—Ovum. (Waldeyer.)

At the first division (*A*, *B*, *C*) the *oöcyte*, as the ovum at this stage may be termed, divides into two cells, one of which is, however, very small and is termed a *polar globule*, while the other is practically as large as the original oöcyte. By a second division (*D*, *E*) a second polar globule is formed, and the nucleus then passes into the resting stage and moves toward the centre of the ovum (*F*). There are thus two maturation divisions, just as there are two divisions of the spermatocytes in spermatogenesis; and the polar globules are to be regarded as abortive ova, which take no further part in development, but degenerate.

After the extrusion of the polar globules the ovum is ready for union with the spermatozoön—a process which occurs probably, as a rule, in the upper part of the Fallopian tube. A spermatozoön penetrating the zona radiata is received into the substance of the ovum, and gradually passes centrally toward the ovum-nucleus. The tail of the spermatozoön is sooner or later absorbed; but the head—which, it will be remembered, represents the nucleus of the spermatid—and the middle piece pass on to come into close apposition, and finally to fuse, with the ovum-nucleus, the compound nucleus so produced soon becoming converted into a division spindle which inaugurates the segmentation of the ovum.

[1] Neither these changes nor the phenomena of fertilization have yet been observed in the human ovum. They have been observed, however, repeatedly in the ova of many of the lower animals, both vertebrate and invertebrate, and their general similarity in all cases makes the probability that they occur also in the human ovum almost a certainty.

It would seem from these phenomena that the essential feature of fertilization is the union of the nuclei of two cells, the small amount of protoplasm present in the head of the spermatozoön seeming to play little part in the process. Since both paternal and maternal characteristics may be inherited, it has been supposed

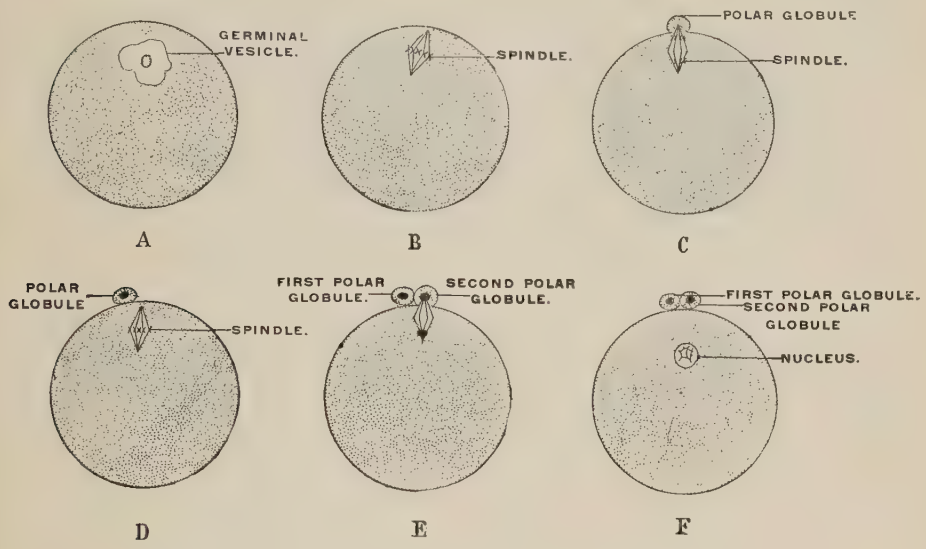

FIG. 86.—Diagram illustrating the phenomena of maturation. (Testut.)

that the nuclei must be the material bearers of heredity; and, since the characteristic substance of a nucleus is the chromatin, this has been regarded by many authors as the actual substance concerned in transmitting inherited peculiarities from the parent to the offspring.

The Early Stages of Development.

By segmentation is meant the conversion of the unicellular ovum into a mass of cells, a process which results from a series of divisions. The ovum first divides (Fig. 87) into two cells (*a*), each of these again dividing, so that four cells are

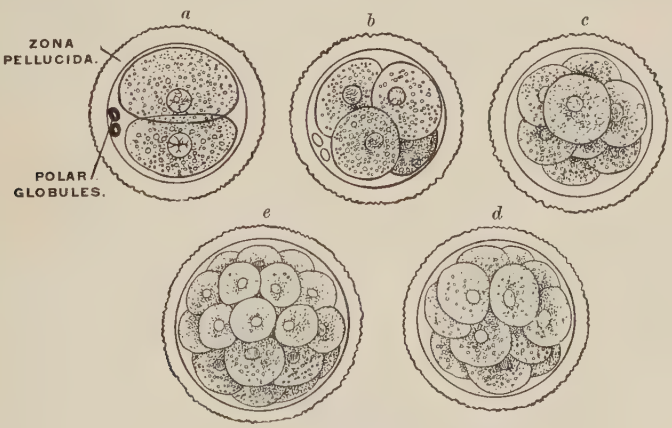

FIG. 87.—Segmentation of the ovum. (After van Beneden.)

formed (*b*), and, the divisions continuing (*c*, *d*), a solid mass of cells, termed a *morula*, is produced (*e*). A section through such a mass (Fig. 88, *A*) will show that it is composed of an outer layer of somewhat flattened cells enclosing a

number of distinctly granular cells. At first no cavity exists in the centre of the morula, but soon the outer cells become in large part forced away from the inner ones by the imbibition of a fluid supplied by the walls of the uterus, and what is

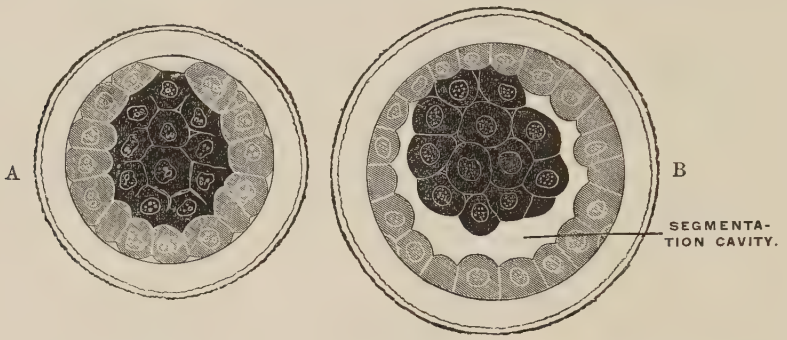

FIG. 88.—Sectional views of ovum, after segmentation. (After van Beneden.)

termed a *segmentation-cavity* is formed (Fig. 88, *B*). The morula is thus converted into a hollow vesicle, termed the *embryonic vesicle*, whose wall is composed of a single layer of cells, except at one region, where what were the inner cells of the morula form a lenticular thickening (Fig. 89).

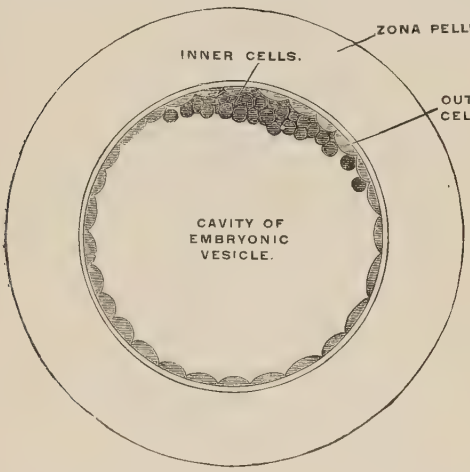

FIG. 89.—Embryonic vesicle. (After van Beneden.)

Later, the innermost cells of this thickening become somewhat flattened and arrange themselves in a distinct layer, which extends out in all directions and eventually completely encloses the segmentation-cavity, which now is known as the *yolk-sac*, or *umbilical vesicle*, the layer of cells enclosing it being termed the *endoderm* (Fig. 90, *A*). While this process is taking place a cavity, known as the *amniotic cavity*, makes its appearance in the outer part of the lenticular thickening, and the cells which form the floor of the cavity become columnar and constitute a layer termed the *ectoderm*, while the cells between this and the endoderm remain irregular in shape and form the *mesoderm* (Fig. 90, *A*). These three layers are known as the *germ-layers*, and it is by the differentiation of their cells that the various tissues and organs of the embryo are developed, each layer giving rise to certain definite structures. To the portions of the germ-layers which lie in the floor of the amniotic cavity the term *embryonic disc* is applied, since it is from this portion alone that the embryo proper will form, the remainder of the embryonic vesicle giving rise to accessory structures necessary during embryonic and fœtal life, but discarded at birth.

The outer layer of cells which forms the wall of the embryonic vesicle has, in the meantime, increased in thickness; its inner cells, which are continuous at the edges of the embryonic disc with the embryonic mesoderm, may be regarded as forming the extra-embryonic portion of that layer. This mesoderm now splits parallel with the surface of the vesicle into two layers, one of which, the *somatopleure*, adheres to the wall of the vesicle, while the other, the *splanchnopleure*, is more closely associated with the endoderm (Fig. 90, *B*). The narrow cleft between these two mesodermic layers rapidly increases in size with the growth of the vesicle, and becomes an extensive cavity known as the extra-embryonic *body-*

cavity, or *cœlom*, into which there projects the yolk-sac, enclosed within the endoderm and splanchnopleure, and united to the wall of the vesicle by a mass of meso-

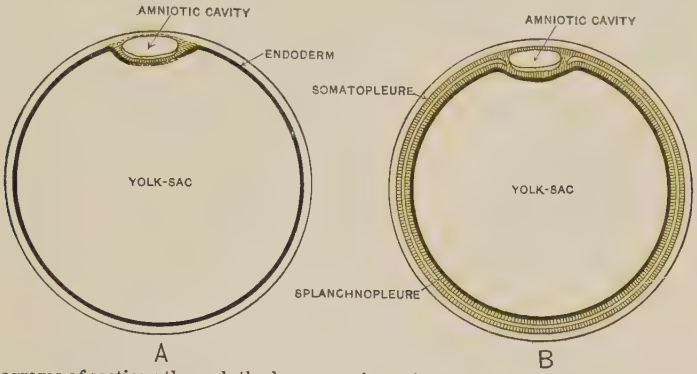

FIG. 90.—Diagrams of sections through the human embryonic vesicle in early stages. The ectoderm is white, mesoderm yellow, and endoderm black.

derm in which the amniotic cavity and embryonic disc are imbedded (Fig. 91).[1]

In succeeding stages of development the embryonic disc and with it the amniotic cavity enlarges, the growth being largely in the direction in which the

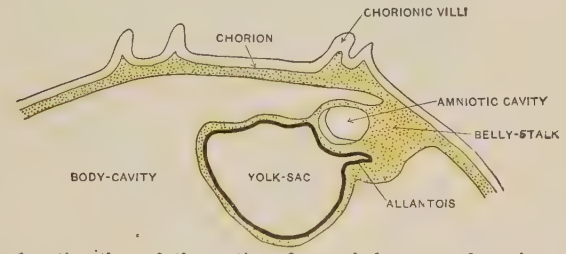

FIG. 91.—Diagram of section through the portion of an early human embryonic vesicle which contains the embryo. (After Graf Spee.)

head end of the embryo will later develop. The portion of the mesoderm which lies behind the amniotic cavity and embryonic disc remains accordingly unaltered, and increasing in thickness and length forms a pedicle, the *belly-stalk*, united to the embryo near its hind end, and attaching it to the inner surface of the embryonic vesicle (Fig. 96). Immediately in front of it on the embryonic disc a dark line extends some distance forward; it is formed by the fusion in this region of the three germ-layers, and is termed the *primitive streak* (Fig. 92). From its anterior end a narrow band of cells grows forward, displacing the original endoderm along the median line of the embryonic disc, and forming what is termed the *chorda endoderm*. Up to this stage, however, there has been no indication of a differentiation of definite organs; but now a groove appears in the median line of the embryonic disc, extending from the anterior end of the primitive streak almost to the front edge of the disc, and later the ectoderm on either side and in front of the groove rises up to form ridges or folds, which enclose the groove and are known as the medullary folds, the groove itself being termed the *medullary groove* (Fig. 92), the two together forming the first indications of the nervous system. Immediately beneath the medullary groove another groove appears in the chorda endoderm, the convexity of the groove being directed toward the floor of the

[1] This is practically the shape which the earliest human embryo at present known has reached. It is evident, therefore, that the various processes described above are hypothetical so far as their application to the human embryo is concerned, though they are known to occur in the ova of other mammals. It may also be noted that the account given above differs materially from that found at present in embryological text-books, but the structure of early human ova recently studied seems to demand some such previous processes as described.

medullary groove; its lips later unite, the cavity of the canal so formed becomes obliterated, and a solid rod, the *notochord*, lying beneath the central nervous system, is produced (Fig. 93).

The remainder of the chorda endoderm grows out on each side between the ectoderm and endoderm to form a plate of mesoderm, which displaces or unites with the mesoderm already present. The plates do not long remain simple, however, but become separated into two layers (Fig. 93), one of which becomes continuous with the extra-embryonic somatopleure and the other with the splanchnopleure. The cavity which separates these two layers is the embryonic cœlom, and is continuous with the corresponding extra-embryonic cavity. The splitting of the mesodermal plates does not, however, in the higher mammalia extend quite to the inner edge of each plate, but only to a longitudinal groove which has appeared, marking off a narrow portion of each plate immediately external to the median line of the body. This median band of mesoderm now becomes divided by a series of transverse constrictions into a number of oblong masses, which have been termed *protovertebræ*, or, better, *mesodermal somites* (Figs. 93 and 94), the tissue which lies beneath the groove separating these from the more lateral portions of the plates being termed the *intermediate cell-mass*. The formation of the somites begins in what will be the neck region of the embryo, and thence extends both forward and

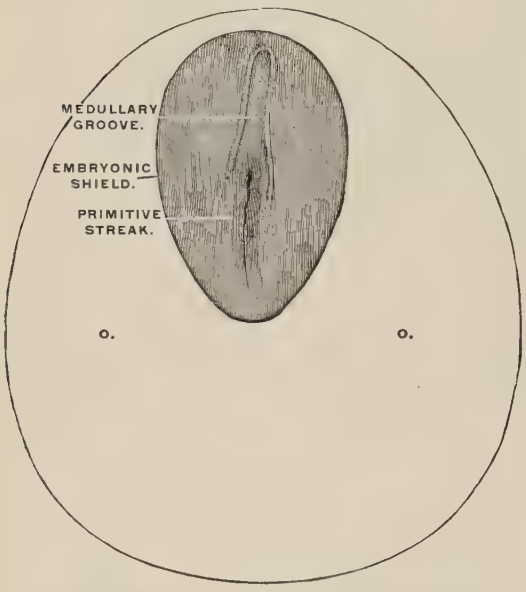

FIG. 92.—Formation of primitive streak and medullary groove. (Kölliker.)

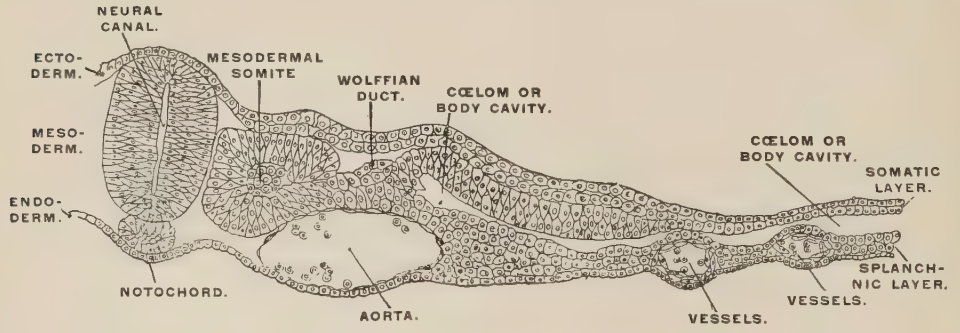

FIG. 93.—Transverse section through dorsal region of embryo.

backward until the median portions of the mesoderm of the trunk and neck regions of the body are divided into somites, indications of them also occurring in the head region.

As the result of these changes the embryonic disc has become differentiated into several areas. Along its median part is the central nervous system, the mesodermal somites, and the intermediate cell-masses, these forming the embryonic area proper; external to this is a region where the disc presents a somewhat transparent appearance, and this is termed the *area pellucida;* while the more peripheral portions are opaque and receive the name of the *area opaca*. In this last region extensive changes have been taking place in the mesoderm: some

of its cells arrange themselves so as to form a network of cords, into the substance of which fluid penetrates from the surrounding tissues, the cords being thus transformed into canals in which lie numerous cells. These canals are blood-vessels; the fluid which they contain becomes the plasma of the blood; the outermost cells of the original cords flatten and produce a thin wall for the vessels, while the more central cells group themselves into masses, which project here and there into the interior of the vessels from their walls, and are termed the *blood-islands*. An abundant network of blood-vessels traversing the area opaca is thus

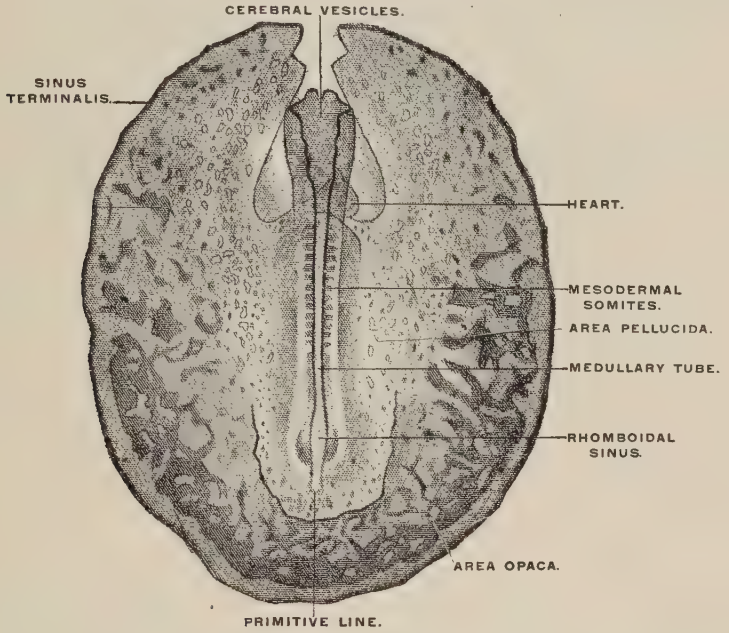

FIG. 94.—Development of somites. (Testut.)

formed, the intervals of the network being occupied by masses of unspecialized cells, which are termed *substance-islands*, and later give rise to embryonic connective tissue. Toward the periphery of the area opaca a circular blood-vessel, known as the *sinus terminalis*, is formed, marking the extreme periphery of the vascular region; and, though the area opaca may extend beyond this, the blood-vessels do not, and it is thus possible to divide the area opaca into a more central *area vasculosa* and a more peripheral area opaca proper. The formation of blood-vessels begins a little later in the area pellucida, and thence they grow in toward the body of the embryo.

The Umbilical Cord and the Placenta.

The embryo during the early stages of its development forms a flat disc, which may be regarded as resting upon the surface of the yolk-sac, and forming the floor of the amniotic cavity, its ectoderm and somatopleure being continuous with the wall enclosing that cavity at the edges of the embryonic disc. At its hind end a thick pedicle, the belly-stalk, composed of mesoderm, unites it to the wall of the embryonic vesicle, which is now known as the *chorion*, and into the substance of the belly-stalk there projects a small diverticulum of the yolk-sac, which represents a rudimentary *allantois*, a structure largely developed in lower forms, in which it serves as an organ of respiration and secretion during embryonic life.

While the changes above described have been taking place the embryo has begun to constrict itself off from the yolk-sac by a tucking in, as it were, of its more peripheral portions, so that it gradually becomes transformed from a dis-

coidal to a cylindrical structure. The tucking in proceeds more rapidly from before backward than in other directions, and constricts the yolk-sac, converting it into a pear-shaped vesicle connected with the intestine of the embryo by a narrow stalk (Fig. 96). Eventually the tucking-in process results in the complete

FIG. 95.

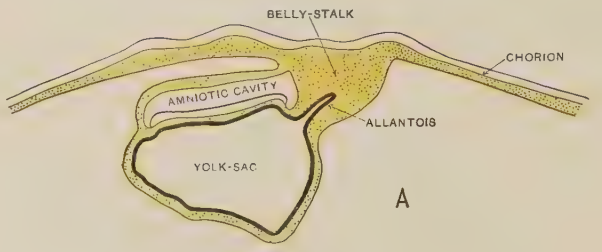

FIG. 96.

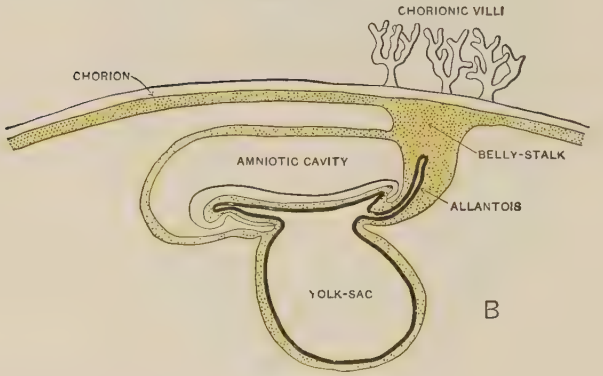

FIGS. 95 and 96.—Diagrams of sections through the human embryo in early stages of development. (Modified from Graf Spee.)

closure of the ventral surface of the embryo except over a small area, the *umbilicus*, through which the stalk of the yolk-sac and the belly-stalk pass. From the margins of this area the body-wall now becomes reflected outward, and encloses the two structures in a common investment, the cord so formed being known as the *umbilical cord* (Fig. 97). Since the edges of the embryonic disc are continuous with the wall of the amniotic cavity, this is carried around the embryo during the tucking-in process, and as the body-wall grows out over the stalk of the yolk-sac and belly-stalk the amnion is also carried out until its attachment to the embryo is at the outer end of the umbilical cord, and the embryo hangs suspended in a large amniotic cavity (Fig. 97). The mesoderm which the umbilical cord contains becomes converted into a peculiar jelly-like connective tissue, known as Wharton's jelly, in which are imbedded the rudimentary allantois and the yolk-sac, and in which the umbilical arteries pass out to the chorion, and the umbilical vein passes in to the embryo. Over the entire extent of the chorion numerous branched processes, termed *chorionic villi*, are developed; but the majority of these disappear later on, only those lying over the outer end of the umbilical cord persisting (Figs. 96 and 97). That portion of the chorion upon which the villi persist is termed the *chorion frondosum*, while that from which they disappear is the *chorion lævе*. Into each villus a loop of the umbilical vessels passes, and the chorion frondosum forms the fœtal portion of the *placenta*, the organ by which the fœtal structures are brought into relation with the maternal (Fig. 97).

In the meantime important changes have taken place in the walls of the uterus. The mucous membrane lining it becomes greatly thickened, forming what is termed the *decidua vera*, and that portion of it which is in contact with the chorion frondosum becomes especially thick, and its blood-vessels dilate to

form wide sinuses into which the chorionic villi project, so that a ready osmotic interchange can take place between the maternal and fœtal bloods through the thin walls of the villi, and the nutrition, as well as the respiration and secretion of the embryo, can thus be carried on. To this portion of the uterine mucosa which forms the maternal portion of the placenta the name *decidua serotina* is

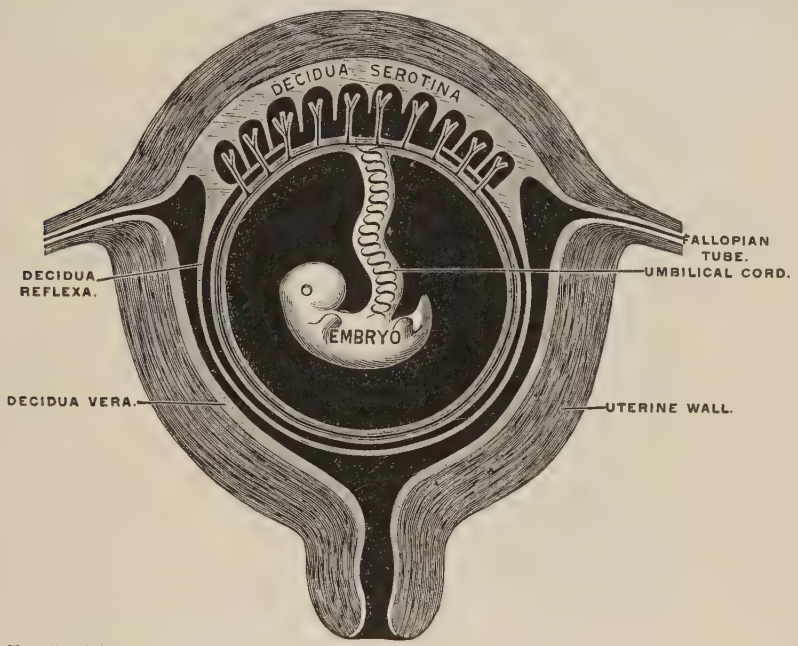

FIG. 97.—Diagram of gravid uterus, showing formation of deciduæ and placenta. (Testut.)

applied. Finally, when the ovum reaches the uterus after fertilization, it imbeds itself in the substance of the mucosa, and the portion of that membrane which thus covers the ovum becomes later the *decidua reflexa* (Fig. 97). At birth the amnion is ruptured, allowing the escape of the amniotic fluid, and after the birth of the fœtus the amnion and placenta, together with other deciduæ which separate from the walls of the uterus, are cast off, forming what is known as the *after-birth*.

To return now to the embryo proper. At its first separation from the embryonic shield it is practically straight, but a bend soon makes itself apparent in what will later be the region of the mid-brain, the fore-brain being bent ventrally until it is almost at a right angle to the rest of the body; and, at about the same time, a linear depression directed dorso-ventrally appears on each side of the neck region, and gradually deepens until it almost unites with the cavity of the digestive tract. This depression is known as a *branchial cleft*, and is succeeded by three others which develop successively from before backward (Fig. 98). When the second cleft is developed a second flexure of the embryo appears, the posterior portion of the body being bent dorsally. This flexure, however, is of short duration, and leaves no permanent trace of its existence; but, when the third branchial cleft forms, a third and more prominent flexure appears, this time a ventral flexure situated in the neck region, and, as the dorsal portion of the body also becomes curved in the same direction, the embryo seems to be coiled upon itself. Soon after the development of this neck-flexure the limbs make their appearance as simple paired, bud-like outgrowths from the sides of the body, and, as development proceeds, they increase in size, and rudiments of the fingers and toes appear. Gradually in later stages

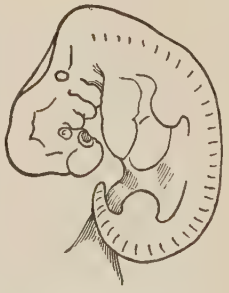

FIG. 98. — Development of the embryo—first month. (His.)

the branchial clefts disappear or are modified into special structures not seen from the exterior, the features are gradually developed, the neck-flexure straightens out, and by about the third month of development the embryo has acquired a distinctly human appearance.

It will now, after this sketch of the formation of the embryo, be convenient to consider the development of the more important organs of the body, and these may be grouped according to the germ-layers from which they are principally formed. For convenience the development of the organs derived from the endoderm will first be considered.

ORGANS DERIVED FROM THE ENDODERM.

At the stage with which the description of the formation of the germ-layers ended the endoderm formed a tube closed at either end, and having connected with it two outgrowths, the umbilical stalk and the allantois. An examination of the surface of the embryo at this stage will show an irregular depression opposite the anterior end of the endodermal tube (Fig. 99). This depression is the *oral sinus*, or *stomodæum*, and it is bounded in front by the edge of a median fold of tissue known as the *fronto-nasal process*, while on either side is a >-shaped ridge, the anterior limb of each ridge being termed the *maxillary*, and the posterior the *mandibular process*. The thin partition which forms the floor of the oral sinus soon ruptures, and the endodermal tube is thus placed in communication with the exterior, its endoderm becoming continuous with the ectoderm of the sinus. Soon after the mouth is thus formed the two maxillary ridges, growing toward each other, meet with the fronto-nasal process, and, in the connective tissue which the two contain, the maxillary bones develop. From each of these bones a horizontal lamella grows inward, and meets with its fellow of the opposite side and with corresponding lamellæ from the palatine bones behind, and the hard palate is thus formed, separating the original mouth-cavity into an upper or nasal and a lower or oral portion, these two cavities communicating behind with the upper or pharyngeal part of the intestinal tube.

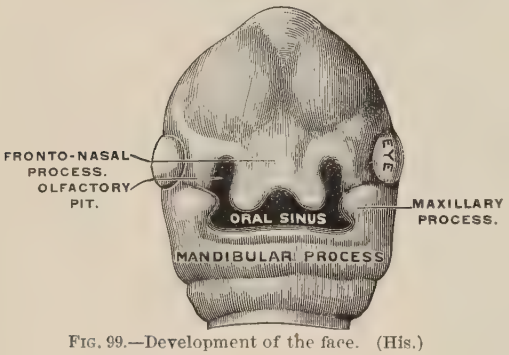

FIG. 99.—Development of the face. (His.)

The Teeth and Salivary Glands.

As early as the sixth week of development there appears, dipping into the lower and upper surfaces respectively of the maxillary and mandibular processes, a thickening of the ectoderm, whose cells subsequently arrange themselves into an anterior and posterior layer, the space which appears between these layers becoming the groove between the lip and the gum (Fig. 100). From the posterior layer a horizontal ridge grows inward into the substance of each gum, forming the *dental shelf*, and upon the under or upper surface of each shelf ten thickenings arise, each of which forms a more or less globular mass of cells, the *enamel organ*, connected with the dental shelf only by a narrow neck which ultimately disappears. In the mesoderm beneath each organ a rapid proliferation of cells forms a papilla, over which the enamel organ is folded like a cup, those cells of the papilla which are in contact with the enamel organ becoming, like the outermost cells of the latter, cylindrical, and forming the *odontoblasts*, whose office it is to deposit the dentine between themselves and the enamel organ. This they begin to do at about the end of the fourth month of development, and at about the same

time the *enamel* begins to be formed by the lower ends of the deeper layer of cells of the enamel organ becoming transformed into calcareous prisms. Finally, around the outside of that portion of the papilla which is not covered by the enamel organ

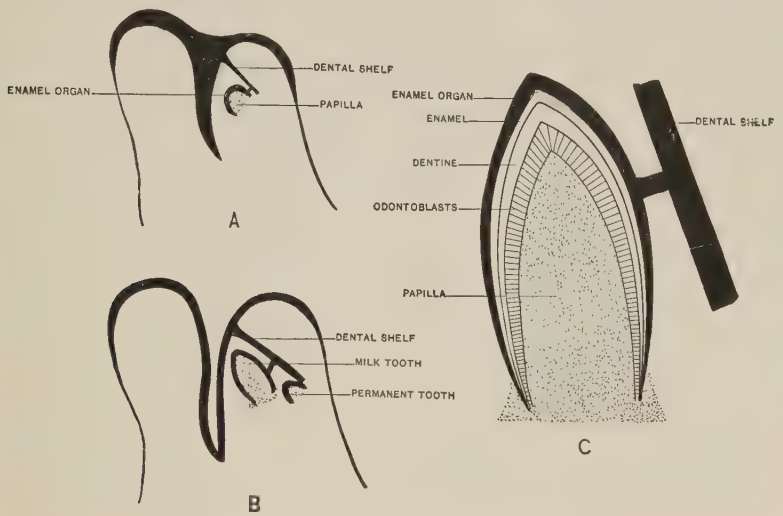

FIG. 100.—Diagram of the development of a tooth.

there appears, about the fifth month, a deposition of bony matter derived from mesodermal cells and constituting the *cement.*

After the separation of the anlagen of the milk teeth from the dental shelf the latter continues to sink deeper into the substance of the jaw, and opposite each milk tooth a *second enamel organ* arises from it, and, mesodermal papillæ also forming as before, the anlagen of the permanent incisors, canines, and premolars are formed. The permanent molars arise in a similar manner from a lateral extension of the dental shelf, and as soon as all the anlagen are formed the tissue of the shelf in the intervals between the various teeth begins to disappear, occasionally, however, persisting in irregular masses until adult life, and producing various abnormalities.

In addition to the teeth certain glandular structures develop from the epithelium of the oral cavity, the most important of which are the *salivary glands,* which arise as simple tubular evaginations, and gradually, by branching, become more and more complicated.

The Branchial Clefts and the Structures derived from Them.

At each side of the pharynx there are, as already stated, four furrows (Fig. 99), represented internally by corresponding depressions, so that along each furrow the pharyngeal epithelium is in contact with the ectoderm of the surface of the body. In the lower vertebrates actual perforation of the thin membrane so formed occurs, forming the gill-slits, but in birds and mammals the perforations do not develop. The first furrow lies immediately behind the mandibular process, and between the members of each successive pair of furrows is a thickened ridge, constituting a branchial arch, each arch being homologous with the maxillo-mandibular processes, which really represent the first arches, the mouth being the first branchial cleft. As development progresses the second arch of each side grows more rapidly than the others, which are in consequence pushed inward toward the median line, and a deep depression is formed at the side of the neck, the *sinus præcervicalis.* From the posterior edge of the second arch a fold grows backward over the mouth of this sinus, and eventually completely covers it in by uniting posteriorly with the side of the body.

From or in connection with the branchial arches or clefts a number of structures develop, some of which may be considered here. From the epithelium of the fourth pair of clefts two thickenings develop, and subsequently fuse together, the single mass so formed growing backward toward the pericardium, separating from the clefts, and enlarging by branching at its posterior end. It forms the *thymus gland*, whose epithelial anlage becomes early infiltrated with lymphatic tissue, and which, subsequent to the second year after birth, begins to undergo degenerative changes. The *thyroid gland* arises partly from the last pair of clefts as paired hollow evaginations, and partly from a median evagination of the floor of the pharynx in the vicinity of the second branchial arch. These anlagen early fuse together, and the gland usually loses all connection with the pharynx, the foramen cæcum at the base of the tongue representing, however, the place of the origin of the median anlage.

The tongue is, embryologically, partly a product of the pharyngeal region, and arises from two anlagen. Its anterior portion arises as a thickening of the floor of the oral cavity, its back portion, however, developing as a pair of thickenings situated in the vicinity of the second and third branchial arches. These thickenings extend forward and outward, forming a V-shaped mass, which encloses in front the posterior end of the anterior anlage. The junction of the two anlagen is indicated in the adult by the V-shaped groove in which the circumvallate papillæ are situated, the foramen cæcum, already referred to in connection with the thyroid gland, lying at the apex of the groove.

The Trachea and Lungs.

Below, the pharynx communicates with the tubular œsophagus, and on the inner surface of the upper part of this there early appears a longitudinal groove, from the lower end of which two pouch-like outgrowths develop. As soon as these begin to form the groove begins to be constricted from below upward from the œsophagus, and becomes the trachea and larynx, the constriction not continuing to complete separation, so that the larynx communicates above with the pharynx. In the connective tissue of the walls of the trachea cartilaginous rings develop, the uppermost of which form the cricoid and arytenoid cartilages of the larynx, the thyroid cartilage being produced by the fusion of the ventral ends of two pairs of cartilaginous bars which are primarily developed in the mesoderm of the fourth and fifth branchial arches. The pouch-like outgrowths are the anlagen of the lungs, and at an early stage become lobed, three lobes appearing in the right lung and two in the left. Secondary and tertiary sacculations later appear, and the complicated structure of the adult lung is acquired. It is to be noted that the epithelium of the lungs, trachea, and larynx is of endodermal origin.

The Intestine and Mesenteries.

From that portion of the primitive intestine which succeeds the œsophagus, the stomach and intestines, together with the liver and pancreas, develop. Of the two structures which in early embryonic life are connected with it, the allantois early separates, its intra-embryonic portion persisting as the urinary bladder and the urachus, while the stalk of the umbilical vesicle retains its connection until after birth, the intra-embryonic portion of it occasionally persisting even into adult life as a more or less pronounced diverticulum of the lower part of the small intestine, known as Meckel's diverticulum.

At first the intestine is a simple straight tube attached to the dorsal wall of the abdominal cavity by a dorsal mesentery, formed by the reflection over it of the peritoneal lining of the abdominal cœlom. Its upper portion is also attached to the anterior wall of the abdomen by a ventral mesentery, whose lower border is falciform in shape, and is attached to the abdominal wall at the umbilicus. This simple arrangement, however, soon disappears, as the intestine,

growing in length more rapidly than the cavity in which it lies, is pushed out into a loop, as is represented in Fig. 101. The elongation continuing, the loop

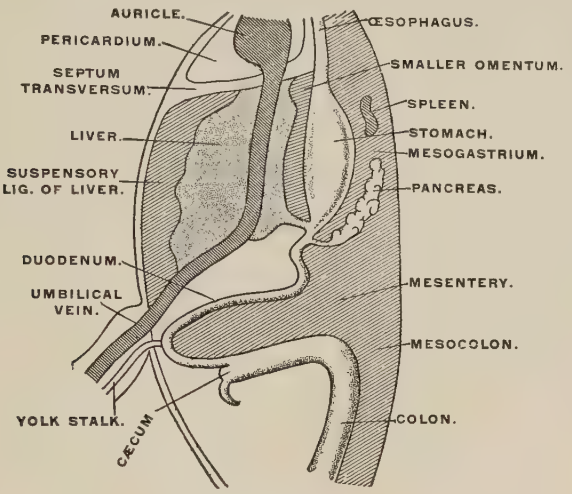

FIG. 101.—Diagram of the human mesentery in its primitive relations. (C. S. Minot.)

bends upon itself, that portion of the intestine which will become the *transverse colon* passing over the portion which is to become the *duodenum*. During the elongation of the intestine the edge of the dorsal mesentery which is attached to it undergoes a corresponding increase in length, while at the line of attachment to the body-wall it increases but slightly, the mesentery of the loop in consequence assuming a fan-like form, and, when the twisting of the loop supervenes, becoming funnel-like.

By this time a differentiation of the intestinal tube has occurred, the portion of it above the loop becoming enlarged to form the *stomach*, while the portion of the loop which passes transversely across the abdominal cavity and the portion of the intestine below this becomes the *large intestine*. The *cæcum* develops as an outgrowth from the large intestine at the point where it is joined by the small intestine, and the *vermiform appendix* is an outgrowth from the cæcum. The

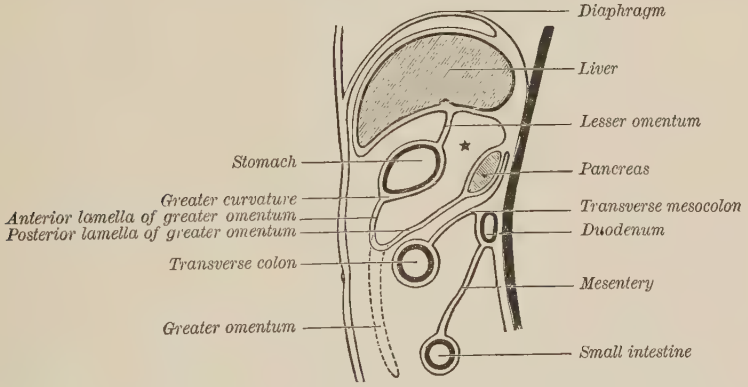

FIG. 102.—Diagram to illustrate the history of the human mesentery—earlier stage. (Hertwig.)

further changes in the intestine consist principally of a continued elongation, especially of the *small intestine*, and of the occurrence of fusion and degeneration of certain portions of the mesentery. Thus, the *mesentery* attached to the transverse colon, primarily radiating from the apex of the mesenterial funnel, later

extends its insertion laterally upon the body-wall, forming a transverse sheet, the mesocolon. This passing over the duodenum binds it fast to the posterior wall of the abdomen, and as a result the duodenal mesentery degenerates. The ascending and descending colon likewise come to lie in contact with the abdominal wall, and their mesentery degenerates to a certain extent, their lower portions being only covered, and not enclosed, by peritoneum.

The *stomach*, in the mean time, has also been undergoing certain changes in position. At first it is straight, what later becomes the small curvature being directed anteriorly; but soon its pyloric end shifts over toward the right side of the body, and, at the same time, the entire structure twists in such a manner that its original left surface becomes anterior, and the small curvature is directed to the right.[1] As the result of this the portion of the dorsal mesentery which is attached to the stomach becomes thrown into a pouch lying behind the stomach, the cavity of the pouch forming the omental cavity, and its floor later being drawn downward to form the great omentum, the posterior layer of which, as it passes back to the body-wall, fuses with the mesocolon.

During the progress of these changes a pair of outgrowths have been developing from the duodenum and passing forward between the two layers of the ventral mesentery. They unite to form the *liver*, which quickly reaches a large size—so large, in fact, that the two layers of the mesentery cannot quite meet around it,

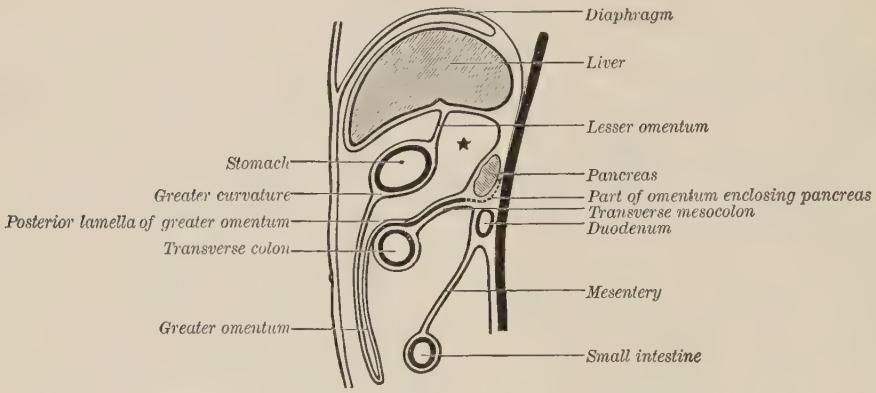

FIG. 103.—Diagram to illustrate the history of the human mesentery—later stage. (Hertwig.)

but are reflected from its sides as the coronary ligaments. The upper portion of the mesentery, above the liver, remains unchanged, however, forming the falciform ligament, while the portion below is affected by the torsion of the stomach, so that its faces come to lie dorsally and ventrally, instead of right and left, and it forms the small omentum (Figs. 102, 103).

The Liver and Pancreas.

The *liver* arises as a pair of hollow outgrowths from the ventral surface of the upper part of the duodenum. Each outgrowth, which represents one of the lobes of the adult liver, becomes greatly complicated by the development of numerous lateral solid branches, these developing others, and so on, the various branches uniting with one another to form a network in the meshes of which are found capillary blood-vessels. The solid branches, termed *hepatic cylinders*, become converted partly into *bile-ducts* and *capillaries* by hollowing out, and partly into the liver *parenchyma*, the original network becoming more or less inconspicuous. The various bile-capillaries unite to form the right and left hepatic ducts, which

[1] It may be pointed out that this twisting is the cause of the position of the pneumogastric nerves in their course over the stomach in the adult, the left nerve passing in front of and the right nerve behind the viscus.

at first open separately into the duodenum; but later the duodenum becomes pouched where they enter, and this pouch is drawn out to form the *common bile-duct*, from which the *gall-bladder* and *cystic duct* arise as a hollow evagination.

The *pancreas* arises as a hollow evagination of the dorsal wall of the duodenum opposite the point where the liver anlagen appear, and grows dorsally between the two layers of the dorsal mesentery, gradually becoming very much branched. It is affected by the torsion of the stomach, so that it assumes a transverse position in the abdominal cavity, and on the development of the mesocolon is pushed with the duodenum against the dorsal wall of the abdomen, its mesentery in consequence undergoing degeneration. Its duct, which at first is attached to the dorsal surface of the duodenum, gradually moves around toward the ventral surface, and finally, as a rule, unites with the common bile-duct.

ORGANS DERIVED FROM THE MESODERM.

The primitive layers of the mesoderm have their cells arranged at first in an epithelial manner, and this arrangement is preserved by certain portions of the layers for a considerable time, even, it may be, throughout life; to these portions the term *mesothelium* may be applied. At certain regions, however, cells are budded off from the primitive layers to form irregular masses, or become scattered throughout the body without any definite arrangement; and these cells are termed *mesenchyme*. It is possible, in accordance with this division of the mesoderm, to recognize mesothelial and mesenchymatous organs.

The Skeleton.

From the mesenchyme are derived the connective and supportive tissues of the body, whose histological differentiation need not be considered here. A few statements may be made, however, concerning the development of the skeleton. The first trace of a supportive structure in the embryo is the *notochord* (Fig. 104),

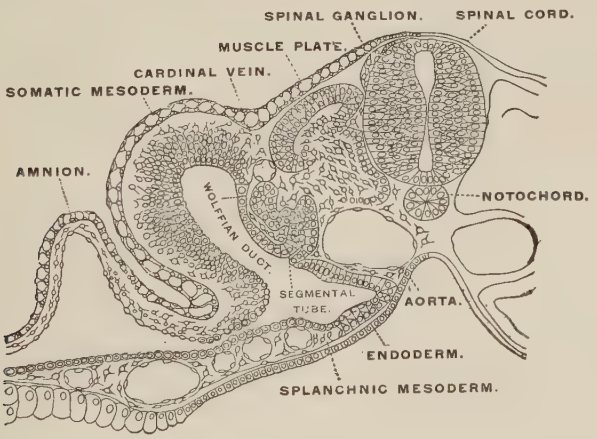

FIG. 104.—Cross-section of embryo.

whose formation has already been described, and which is practically a transitory structure, being replaced later by the spinal column and skull. From a portion of each of the mesodermal somites a mass of cells is budded off, and these masses arrange themselves on either side of the notochord, which they eventually enclose, growing dorsally at the same time around the spinal cord. Each mesenchymatous mass so produced by the members of each pair of mesodermal somites early becomes converted into a mass of hyaline cartilage, which later ossifies to form the *vertebral centrum;* and, as the ossification proceeds, portions of the notochord enclosed by the

centra are gradually encroached upon and finally disappear, the intervening portions persisting as the gelatinous substance of the intervertebral disks. The *neural arches* develop a little later than the centra, and ossify separately, uniting with the centra only after birth.

The *ribs* arise by the chondrification and subsequent ossification of the mesenchymatous tissue situated between the members of each pair of mesodermal somites, the ribs of the thoracic region being, however, the only ones which undergo complete development, extending in the wall of the body to the ventral surface, where a number of them unite to form the sternum. In the other portions of the trunk and in the neck they remain small, and become united with the vertebræ, being represented in the cervical region by the ventral portions of the transverse processes, in the lumbar region by the costal processes, and in the sacrum by the lateral masses.

The *skull* shows from the beginning no trace of being composed of distinct vertebræ, except in the occipital region. The first trace of the skull is found in two cartilaginous bars, placed one on each side of the anterior end of the notochord. These are the *parachordal cartilages* (Fig. 105), and in front of them two other cartilages known as the *trabeculæ cranii* are formed. These four cartilages eventually unite together, and the trabeculæ uniting at their anterior extremities to form a plate, known as the *ethmo-vomerine plate*, a cartilaginous basis cranii is formed, which later extends dorsally behind and at the sides, leaving, however, the greater portion of the brain covered only by membrane. About the third month of development centres of ossification begin to appear in this chondro-cranium, resulting in the formation of a number of separate bones, which later fuse with one another to a certain extent to form the occipital, sphenoid, and ethmoid bones, all of which are really composite bones.

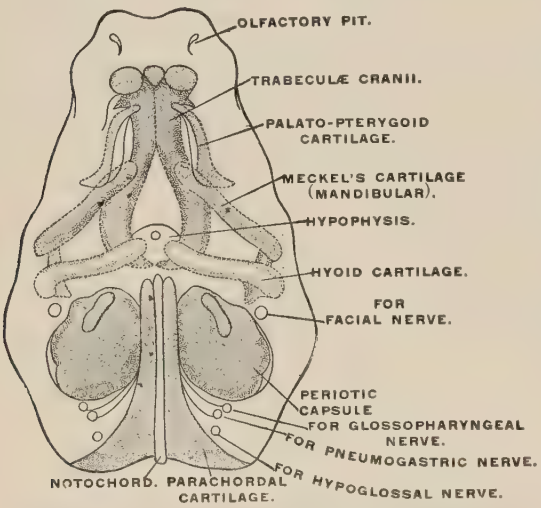

FIG. 105.—Cranial cartilages of embryo. (C. S. Minot, after W. K. Parker.)

In addition to the bones which are thus developed, other elements occur in the skull and may be arranged in three groups: (I.) A number of bones are developed without being preformed in cartilage, their osseous matter being deposited directly in fibrous connective tissue. In this way—as *membrane bones*, as they are termed—are formed the parietals and frontals and the bones of the face, such as, for example, the nasals, malars, lachrymals, palatines, and maxillæ. (II.) Around each auditory organ a cartilaginous case, the *periotic capsule*, develops, quite independently of the primary chondro-cranium, filling up a gap in its walls on each side between the occipital and sphenoid bones, and from it are formed the petrous and mastoid portions of the temporal, the squamous and tympanic portions being membrane bones, which secondarily unite with the capsule. (III.) In each branchial arch a cartilaginous bar develops, these bars forming what is termed the *visceral skeleton*, and certain of them become intimately related to the skull. The dorsal end of the maxillo-mandibular cartilage becomes entirely replaced by membrane bones, the maxillæ, palatines, and internal pterygoid plates of the sphenoid; while its lower end, known as *Meckel's cartilage*, ossifies and unites with a number of membrane bones, which enclose it, to form the lower jaw or mandible, and also takes part in the formation

of the ossicles of the middle ear. The cartilages of the second and third arches unite to form the hyoid bone, the small horn, the stylo-hyoid ligaments, and the styloid processes of the temporals representing the complete second arch, while the great horn represents the incomplete third arch. The fourth and fifth arches become greatly reduced, and fuse together, as already indicated, to form the thyroid cartilage of the larynx.

The *bones of the extremities* are all preformed in cartilage, and for the long bones at least two or three centres of ossification are usually present, one being for the shaft and one for each epiphysis, these latter, however, being merely provisions for the growth in length of the bone, and not representing originally distinct bones. In the scapula, however, two primary centres are formed, one for the greater portion of the bone, and one for the coracoid process, which in the lower vertebrates is a distinct bone; and similarly three primary centres are found in each hip-bone, one for the os pubis, one for the ischium, and one for the ilium, each of these being primarily a distinct bone. In the carpus and tarsus certain fusions also occur. Typically, each consists of nine bones arranged in a proximal row of three bones, a distal row of five bones, and a single bone between the two. The following scheme will show the fusions which have taken place, each composite bone ossifying from two centres, the rest from one:

Carpus.		*Tarsus.*	
Scaphoid,	Radiale.	Tibiale, Intermediate,	Astragalus.
Semilunar,	Intermediate.		
Cuneiform,	Ulnare.	Fibulare,	Calcaneum.
(Fused with Scaphoid)	Centrale.	Centrale,	Navicular.
Trapezium,	Carpal I.	Tarsal I.,	Internal Cuneiform.
Trapezoid,	" II.	" II.,	Middle Cuneiform.
Os Magnum,	" III.	" III.,	External Cuneiform.
Unciform,	" IV.	" IV.,	Cuboid.
	" V.	" V.,	

The pisiform does not belong to the same category as the other carpal bones, being an ossification in the tendon of the flexor carpi ulnaris, just as the patella is an ossification in the tendon of the quadriceps extensor femoris. Such bones are known as sesamoid bones.

The Heart and Blood-vessels.

It has already been seen that the formation of the blood-vascular system begins in the area opaca of the blastodermic vesicle, and thence extends toward the embryo, two vessels, the *vitelline veins*, carrying the blood from the yolk-sac to the embryo. While the embryo is still spread out flat upon the surface of the blastodermic vesicle the splanchnic layer of the mesoderm on each side of the body buds off a small collection of cells (Fig. 106, *endocardium*) into the space between it and the endoderm; these early arrange themselves in a tubular form and become enclosed within a fold of the splanchnic mesoderm. These folds (Fig. 106, *myocardium*) and tubes so formed are the anlagen of the heart, the two halves of which are at first widely separated; but as the embryo becomes constricted off from the yolk-sac they are brought nearer together, and finally unite to form a single double-walled tube, the folds becoming the muscular walls of the heart, while the mesenchymatous tubes form its endocardium.

The *heart*, thus formed, is situated in the neck region of the embryo, and has communicating with it behind the vitelline veins, while anteriorly it is continued into the aortic trunk. This simple tubular heart now undergoes a considerable increase in length, and, as a result, bends upon itself in an S-shaped manner (Fig. 107), the aortic end being ventral to the venous. The venous end now begins to enlarge, and pouches out into a sac on each side, forming the *right* and *left auricles;* and

from its dorsal wall between the two auricles a vertical partition begins to form, which, growing backward toward the horizontal portion of the heart, would separate the auricles completely were it not that a foramen forms in its upper part

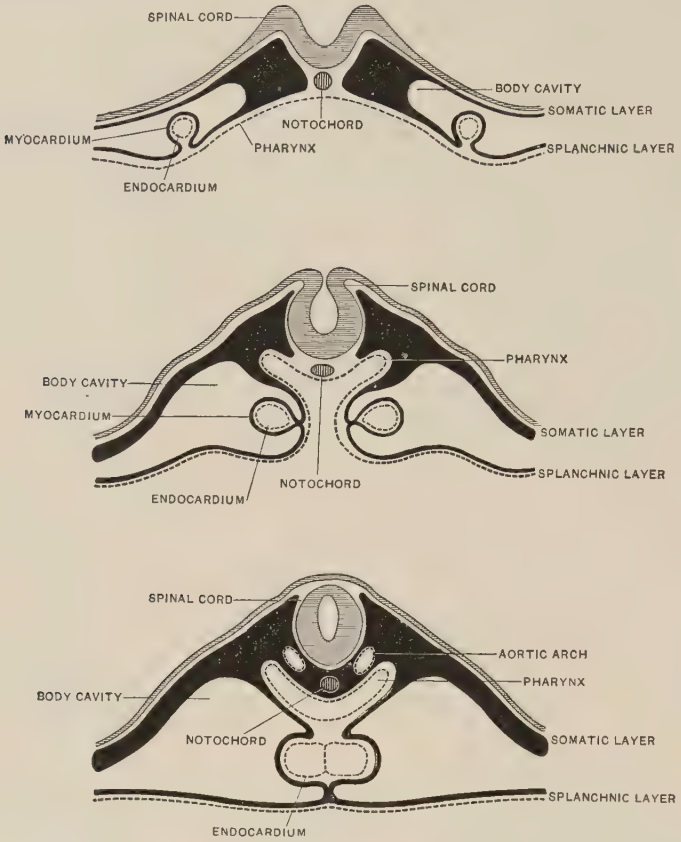

FIG. 106.—Development of the heart: cross-sections of the cervical region of an embryo; diagrammatic. (Testut.)

(the *foramen ovale*), which persists until birth, closing normally shortly thereafter. The partition passes to the left of the opening by which the blood from the vitelline

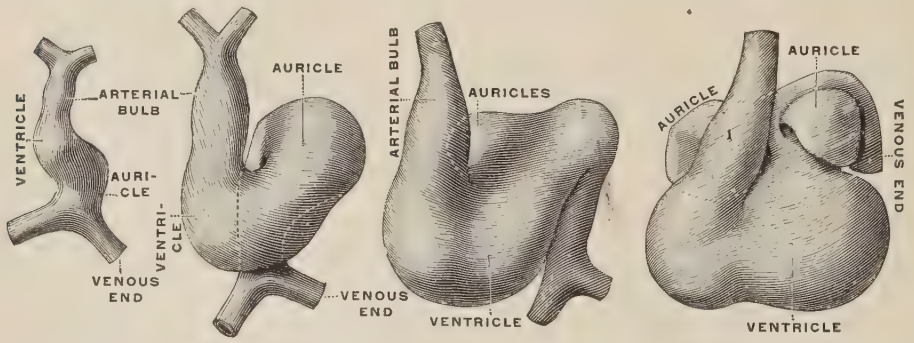

FIG. 107.—Four stages in the development of the heart: front view; diagrammatic. (Testut.)

veins flows into the heart, and, consequently, this opening now communicates with the right auricle, the left receiving four small veins which come to it from the lungs.

The point of union of the auricular and ventricular regions has in the mean time become considerably constricted, and the auricular septum extends far enough

downward to divide the opening between them into two parts. In the ventricle a crescentic partition develops from the posterior and dorsal walls, and grows upward toward the auricular septum, with the lower border of which it unites, ending, however, in a free edge beneath the opening by which the aortic trunk communicates with the ventricle. The *aortic trunk* has meanwhile flattened dorso-ventrally, and on the inner surfaces of the flat sides two ridges develop, and finally unite, dividing the lumen of the aortic trunk longitudinally into two portions (Fig. 108). The partition extends down into the ventricle, and unites

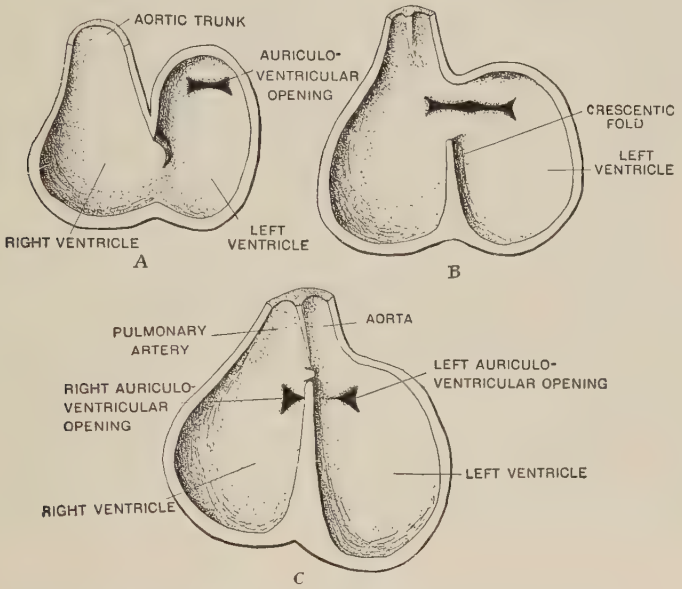

FIG. 108.—Development of the aorta and pulmonary artery. (After Born.)

with the free edge of the ventricular septum, so that the *division of the ventricle* becomes complete, and the aortic trunk then separates completely into two tubes, one of which, the *aorta*, communicates with the left ventricle, while the other, the *pulmonary artery*, opens into the right ventricle. The original tubular heart has thus become converted into a four-chambered organ which differs from the adult heart only in the existence of the foramen ovale in the auricular septum.

The aortic trunk, prior to its division, in passing forward from the heart gives off from time to time pairs of lateral branches, which pass dorsally in the branchial arches. These are the *aortic arches*, which, on each side, unite above the branchial clefts to form a longitudinal vessel, and this, passing backward, unites with its fellow of the opposite side to form the *dorsal aorta* (Figs. 109, 110). This primitive condition is, however, merely transitory, the first arches early disappearing, and then the second, the continuations of the aortic trunk from which these arches arise persisting, however, to form the *external carotid arteries*, while the branches of the dorsal aorta into which they opened likewise persist to form the *internal carotids*. The third arches persist, becoming portions of the internal carotids, and forming the connections between those arteries and the external carotids; but the portions of the branches of the dorsal aorta which intervene between the third and fourth arches disappear, thus cutting off the direct connections of the internal carotids with the dorsal aorta. The fourth arch of the left side persists in its entirety, forming the arch of the aorta of the adult, and is the only connection between the heart and the dorsal aorta, since the right branch of the dorsal aorta disappears completely behind the third arch, the right fourth arch forming part of the right *subclavian artery*. The fifth arches give rise to an artery on each side, the pulmonary arteries, and the portion of the arch distal to the branch on the right

side disappears, but persists on the left side to form the *ductus arteriosus*, uniting the pulmonary artery with the dorsal aorta—a connection functional for the passage of blood up to birth, but aborting later.

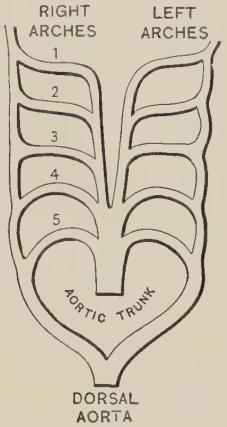

FIG. 109.—Aortic arches, early arrangement. (After Rathke.)

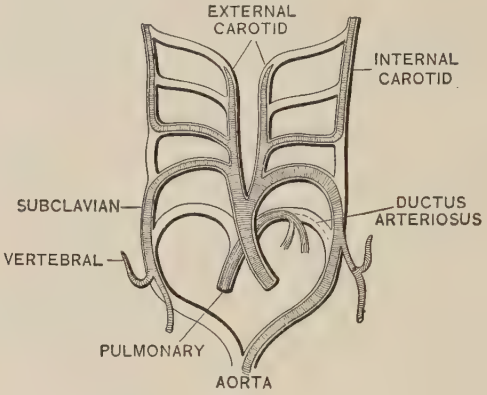

FIG. 110.—Aortic arches, final condition. (After Rathke.)

Of the *venous system* it has already been seen that there is a pair of vitelline veins coming from the yolk-sac and opening into the venous end of the embryonic heart. In addition to these, other veins are developed at an early period, which unite together and with the vitelline veins before entering the heart, forming a *sinus venosus*, which later is taken up into the right auricle. Of these veins there are, first, the umbilical veins, which bring back the blood from the placenta, entering the body of the embryo at the umbilicus (Fig. 111). The left umbilical vein

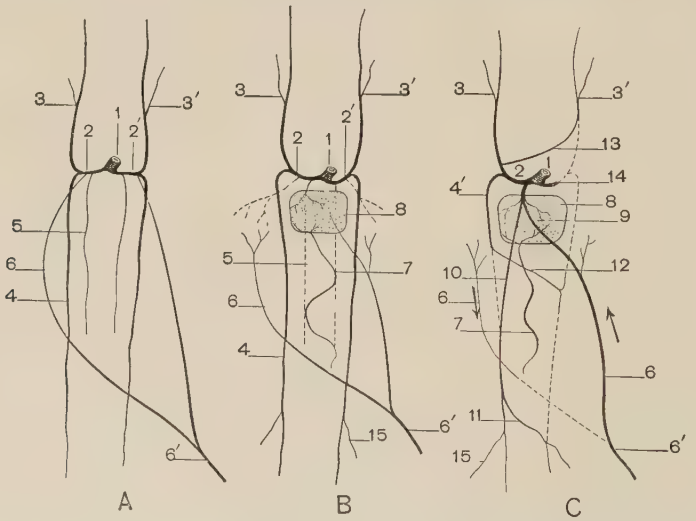

FIG. 111.—Development of the veins: *A*, primitive condition, bilateral symmetry; *B*, formation of portal system; *C*, final condition; diagrammatic. 1, sinus venosus; 2, right ductus Cuvieri; 2′, left ductus Cuvieri; 3, right jugular vein; 3′, left jugular vein; 4, cardinal vein; 4′, vena azygos major; 5, vitelline vein; 6, umbilical vein; 6′, umbilical vein in cord; 7, portal vein; 8, liver; 9, ductus venosus; 10, vena cava inferior; 11, common iliac vein; 12, vena hemiazygos; 13, left brachio-cephalic vein; 14, coronary sinus; 15, veins of lower limbs. Atrophied parts in broken lines. (Testut.)

degenerates later almost entirely, but the right passes forward in the ventral midline of the abdomen to the under surface of the liver, to which it distributes blood, continuing onward, however, to open into the sinus venosus. During embryonic life this vein increases in size, the vitelline veins, on the other hand, becoming smaller and, forming connections with one another, eventually giving rise to the portal vein. After birth, however, as soon as the placental circulation ceases, the

umbilical vein becomes converted into a solid cord of tissue, which, from the transverse fissure of the liver to the umbilicus, is known as the *round ligament*, while the portion above this becomes the *ductus venosus*, the uppermost part persisting as the upper part of the *vena cava inferior* and receiving the hepatic veins.

Secondly, there are two other pairs of veins which are entirely confined to the embryo—the *jugulars*, which bring back to the heart the blood from the head and upper extremity, and the *cardinals*, which return the blood from the trunk and lower limb, the jugulars and cardinals of each side of the body uniting together before opening into the sinus venosus to form a transverse branch, the *ductus Cuvieri*. As the embryo develops the jugulars increase in size more rapidly than the cardinals, so that the Cuvierian ducts seem to be the continuations of the jugulars; and when the sinus venosus is taken up into the right auricle the two Cuvierian ducts and the umbilical vein, which open into the sinus from the right and left sides and from below, respectively, come to have separate openings into the auricle, forming the three principal openings found in the adult.

The cardinal veins do not, however, persist until adult life in their original condition, but are to a certain extent replaced by an unpaired venous trunk, the *vena cava inferior*, which makes its appearance in the tissue between the two primitive kidneys, and early unites with the cardinals by means of transverse branches, through which it receives the blood from the kidneys and rapidly increases in size. In the mean time, a connecting trunk has formed between the left and right cardinals, and the main mass of the blood from the left lower limb flows over into the right cardinal, which thus becomes enlarged and forms apparently the continuation of the inferior vena cava. Above, the vena cava opens into the umbilical vein, and, on the degeneration of the umbilical after birth, this uppermost part of it persists as the upper end of the vena cava. This vessel is, therefore, composed of three originally distinct parts: (1) the independent trunk between the primitive kidneys; (2) the lower end of the right cardinal vein; and (3) the uppermost part of the umbilical. When completely formed it receives the blood from the greater part of the territory originally drained by the cardinals, the upper portions of these latter still continuing, however, to receive the blood from the intercostal spaces of the thorax. The lower part of the left cardinal completely disappears, and it also loses its connection with the left ductus Cuvieri, forming instead a transverse connection with the right cardinal, and becoming the *vena hemiazygos* (azygos minor) of adult anatomy, the upper part of the right cardinal becoming the *vena azygos major*.

In the mean time, a slight change has taken place in the jugulars, a branch passing across from the left to the right, and forming the *left brachio-cephalic vein* of the adult, which receives and passes over to the right jugular all the blood returning by the left jugular. As the result of this the portion of the left jugular between the origin of the left brachio-cephalic vein and the left ductus Cuvieri becomes greatly reduced, being represented in the adult only by the small oblique vein on the back of the left auricle; but the left ductus Cuvieri, thus separated from both the jugular and the cardinal vein which originally opened into it, does not degenerate, since it still receives a large proportion of the blood returning from the tissue of the heart itself through the coronary veins, but persists as the coronary sinus.

The Diaphragm.

Closely associated with the development of the venous trunks is the formation of the diaphragm. At first the body-cavity or cœlom is a continuous cavity extending the entire length of the trunk, and even into the head region; but during development the portions in the head and neck disappear, the thoracic and abdominal portions persisting, and being at first continuous. After the heart has formed, however, a thick transverse partition, the *septum transversum*, begins to grow from the ventral and lateral walls of the body toward the sinus venosus,

enclosing the venous trunks which open into the sinus. By its formation the thoracic and abdominal portions of the cœlom are almost completely separated, the only communication between them being by a pair of small canal-like openings, one on each side of the dorsal mesentery; and, as the lungs develop, they push the walls of the canals in front of them, these walls thus forming the pleuræ. At a comparatively early stage of development the pericardial portion of the thoracic cavity becomes separated from the pleural portions; and considerably later the latter become cut off from the abdominal cavity, then known as the peritoneal cavity, by the growth forward from the dorsal wall of the body of a partition which unites with the free edge of the septum transversum.

The Lymphatic Vessels, the Spleen, and the Suprarenal Capsules.

Of the development of the *lymphatic vessels* comparatively little is known with certainty, though they seem to be formed similarly to the blood-vessels by a hollowing out of strands of mesenchymatous cells. The mode of development of the *spleen* is also but imperfectly known: it arises as a collection of mesenchymatous cells situated between the layers of the dorsal mesentery of the stomach, and early receives a rich supply of blood-vessels.

The *suprarenal bodies* are formed from certain tubules of the mesonephros (see below), a rich nerve-supply from the abdominal portion of the sympathetic system later penetrating into the tissue. *Accessory suprarenals*, also known as *Marchand's adrenals*, occur in the broad ligament of the female and the spermatic cord of the male, and are also formed from some tubules of the mesonephros.

The Muscular System.

From the mesothelial portions of the mesoderm the voluntary muscles and the urino-genital system develop. The voluntary muscles are derived from the mesodermal somites, the greater portions of which become transformed into muscle-tissue, and, consequently, the voluntary musculature has primarily a segmental arrangement, consisting of a series of muscle-plates placed one behind the other on each side of the body, and extending forward even into the head-region of the embryo. Each plate is supplied by a cranial or a spinal nerve, and has the fibres of which it is composed directed longitudinally, and arising from and inserted into the connective-tissue membranes which separate each pair of plates. This primitive arrangement, however, is not long retained, the various muscle-plates fusing together to a greater or less extent, and dividing longitudinally and into various layers, and so producing the complicated muscular system of the adult.

The involuntary muscle-tissue which occurs distributed through the walls of the various viscera seems to arise by the differentiation of mesenchymatous cells, and to have nothing to do with the mesodermal somites.

The Excretory and Reproductive Organs.

The excretory and reproductive systems arise from certain of the mesodermal somites just where they join the splanchnic and somatic layers, and the first portion of the excretory system to appear arises from certain somites in the vicinity of the heart, a solid cord of cells growing out from each somite toward the ectoderm. Each cord later becomes converted into a canal, which opens at one end into the cœlom, and is connected at the other end with the ectoderm. This collection of tubules is termed the *pronephros* (Fig. 112), and as it develops there is formed from the ectoderm, along the line where the tubules are in contact with it, a longitudinal canal, which later separates from the ectoderm and comes to lie close to the mesoderm (Fig. 104). This is the *pronephric* or *Wolffian duct*, with which the tubules of the pronephros unite, and which opens posteriorly into the urogenital sinus, to be described later.

The pronephros, however, is but a transitory organ, and it soon degenerates; a second excretory organ, the *mesonephros* or *Wolffian body*, makes its appearance, its development being similar to that of the pronephros. Its tubules, which open at one end into the cœlom and at the other into the Wolffian duct, reach a consider-

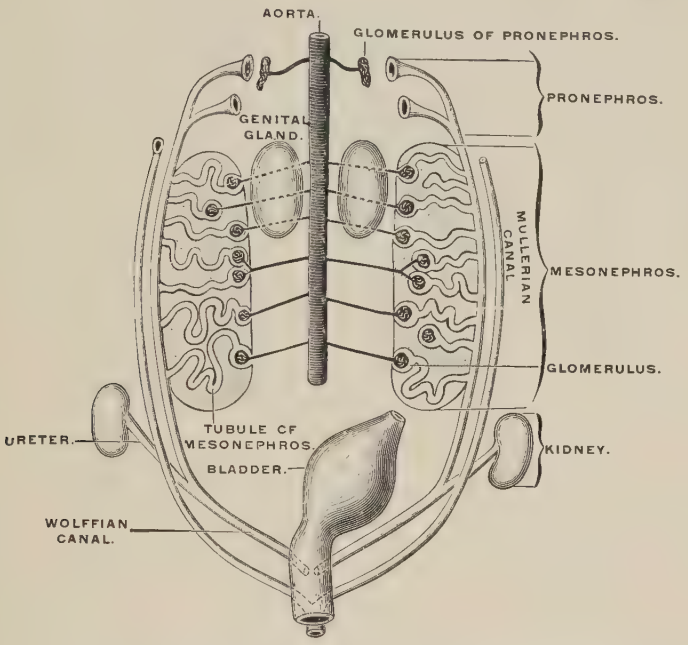

FIG. 112.—Diagram of the various excretory organs successively developed in the formation of the urinary system. (Testut.)

able length, and become much contorted, and a knot of capillary blood-vessels, developing in contact with each tubule, pushes its wall in front of it to form a *glomerulus* projecting into the tubule. The tubules early lose their connection with the cœlom, and, though at first they present a strictly segmental arrangement, this is not adhered to, as secondary and tertiary tubules arise from each mesodermal somite, develop glomeruli, and unite with the primary tubules to open into the Wolffian duct. The Wolffian body thus becomes an exceedingly complicated organ, which, on account of its size, forms a strong projection into the cœlom from the dorsal wall of the body.

But even this second kidney does not persist into adult life as a functional excretory organ, but portions of it degenerate, while other parts are adapted to new functions, its excretory functions being assumed by a new kidney, the *metanephros*. This appears as a tubular outgrowth from the dorsal surface of the lower part of each Wolffian duct, and from the anterior end of this a number of tubules grow out and push their way into a mass of mesodermal tissue which has concentrated around them. The original outgrowths become the *ureters*, and the tubules, which become very numerous, develop into the *urinary tubules*, in connection with which *glomeruli* (Malpighian corpuscles), derived from the mesodermal mass, develop. The compact organ thus formed becomes the functional kidney of the adult.

When the Wolffian bodies are fully developed a cord of cells appears on the lateral surface of each of them, and becomes converted into a canal opening behind into the cloaca and in front into the cœlom. This is the *Müllerian duct*, and by the time it is established a thickening of the peritoneal cells covering the mesial surfaces of each Wolffian body appears, forming the *germinal ridges*, from which the ovaries or testes develop. In the case of the *ovaries* the mesenchyma-

tous tissue immediately beneath the thickenings develop into the stroma, into which cords of cells (Fig. 113) grow from the thickening. Certain of the cells

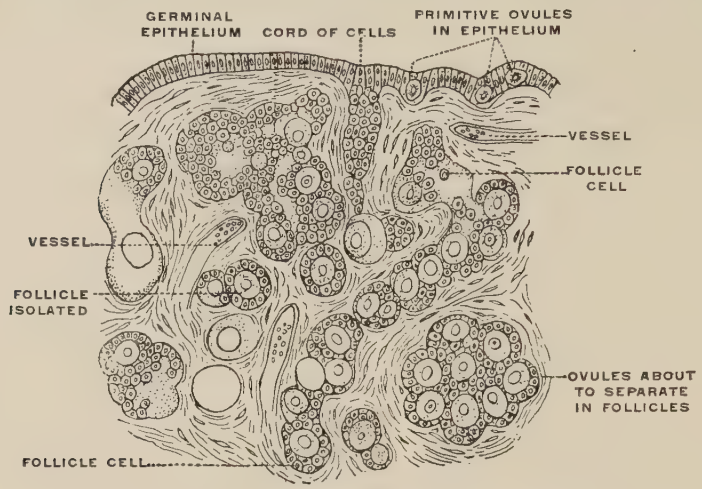

FIG. 113.—Section of the ovary of a new-born child. (After Waldeyer.)

of the cords enlarge greatly and become ova, the remaining cells multiplying rapidly by division and becoming the follicle-cells. Division of the cells which are to form ova appears to cease at about the second year after birth, by which time, therefore, all the ova are differentiated. The *testes* are at first very similar to the ovaries, and have a similar development, the spermatic cells being derived from the cells of the germinal ridge, and the stroma of the ovary being represented by the tunica albuginea and the trabeculæ of the testis.

When mature the ova are extruded from the ovary practically into the peritoneal cavity, though, as a matter of fact, they are usually received at once into funnel-like openings by which the Müllerian ducts communicate with the peritoneal cavity, these ducts becoming the *Fallopian tubes* of the adult, and their lower portions fusing to form the *uterus* and *vagina*. In the embryo, however, the Müllerian ducts extend much farther forward than the position of the ovary, the ostium of the Fallopian tubes being a new formation and not the original terminal opening, the more anterior portion of each duct being probably represented in the adult by the *hydatid of Morgagni* (Fig. 114), a small vesicular structure attached to one of the fimbriæ of the secondary opening. While the ovary and the metanephros have been developing the mesonephros has been degenerating, and all those portions of the Wolffian ducts which lie anterior to the points of outgrowth of the metanephric ducts disappear, except small portions at each end. The upper end, through mesonephric tubules which communicate with it, comes into intimate relation with the ovary, forming with its tubules the *parovarium*, which in the adult lies close to the ovary in the substance of the broad ligament. The lower ends of the Wolffian ducts persist as the *canals of Gärtner*, situated on each side of the upper end of the vagina, while the mesonephros almost completely disappears, its uppermost tubules just mentioned and a small portion of its lower end alone persisting, the latter forming a cyst-like structure lying between the layers of the broad ligament, and termed the *paroöphoron*.

It has been seen that the ovaries appear at the level of the mesonephros—that is to say, well forward in the abdominal wall. This position, however, is not retained, but they descend as development proceeds, and finally lie in the pelvic cavity. This descent is partly produced by the contraction of a band of connective tissue which descends from the lower end of the mesonephros to be attached to the skin in the region where the labia majora will later appear, and which is represented by the *round ligament* of the adult.

The testes and the parts in their neighborhood undergo changes comparable to those just described for the ovaries, the principal difference being that the Müllerian ducts degenerate except at their two extremities, the anterior ends persisting as a small vesicle attached to each epididymis, and known as the *hydatid of the epididymis*, while the lower ends unite together to form a small sac, which opens into the prostatic portion of the urethra, and is termed the *sinus pocularis*. This latter structure from its mode of formation is evidently homologous with the uterus of the female, and has consequently been termed the *uterus masculinus*. On the other hand, the Wolffian ducts persist, forming the *vasa deferentia*, and, as in the female, the tubules of the upper portions of each Wolffian body grow inward toward the testes, with which they unite, their testicular ends forming the *tubuli recti* and *rete testis*, while the ends connected with the Wolffian ducts form the *epididymis*. The remainder of the Wolffian bodies undergoes almost complete degeneration, portions, however, as in the female, persisting, and forming the structures known as the *vasa aberrantia* of the epididymis and the *paradidymis* or *organ of Giraldès*.

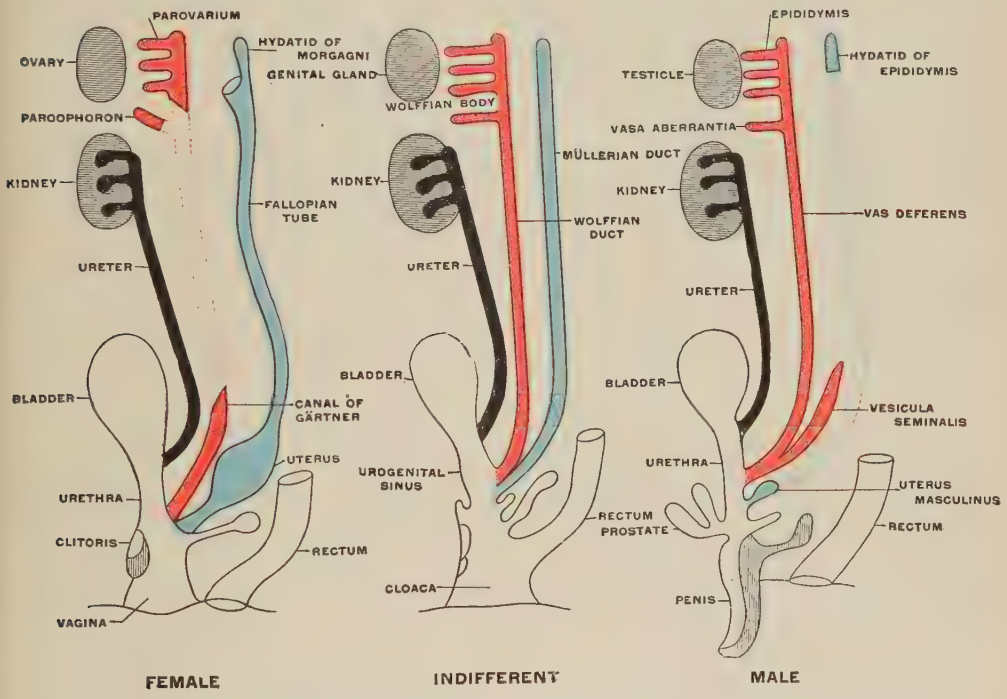

FIG. 114.—Diagram of the development of the genito-urinary apparatus. (Modified from Huxley.)

The round ligament, whose contraction occasions the descent of the ovary into the pelvic cavity, since it is primarily in connection with the mesonephros, has naturally a representative in the male, passing from the lower end of the mesonephros to that region of the skin where the scrotum will develop. By its contraction the descent of the testis is brought about, this organ being drawn first into the cavity of the false pelvis, and then into the inguinal region. Here, in the mean time, on each side, a downgrowth of a finger-like process of peritoneum into the scrotum by the side of the round ligament has occurred, the downgrowth being preceded by prolongations of various muscular layers of the abdominal wall. The testes, continuing their descent, follow these peritoneal downgrowths, and thus come to lie within the scrotum, the peritoneal processes wrapping themselves around them and forming the *tunicæ vaginales*, the neck by which the process communicates with the general peritoneal cavity subsequently closing by the fusion of its walls, while the remaining coverings of the testes are produced by the

muscle- and fascia-layers of the abdominal walls which preceded the peritoneal process. The cord, which represents the round ligament, is to be found in the adult in a small cord which passes from the epididymis to the wall of the scrotum, and is termed the *gubernaculum*.

It has already been stated that the allantois does not entirely degenerate at birth, the middle part of its intra-embryonic portion persisting as the *urinary bladder*, and the part between this and the umbilicus becoming converted into a solid cord, known as the *urachus*. The part between the bladder and the intestine forms what is termed the *urogenital sinus*, and into it the Müllerian and Wolffian ducts open. In the development of the *ureters* the portions of the Wolffian ducts between their point of origin and the sinus are, in the male, gradually taken up into the sinus, so that the ureters and the vasa deferentia have separate openings, the former uniting with the base of the bladder, while the latter open into the sinus. Since the allantois is connected with the intestine, that portion of the digestive tract receives the urinary and genital products as well as the fæces, and thus receives the name of the *cloaca* (Fig. 115). At an early period this cloaca becomes divided by a partition into a dorsal and a ventral portion; this partition becoming gradually thicker, the dorsal portion, representing the lowermost part of the rectum, becomes separated from the ventral portion, the region intervening between the two being the *perineum* (Fig. 117).

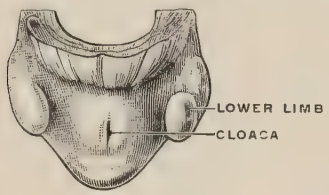

FIG. 115.—External view of the cloaca. (Hertwig.)

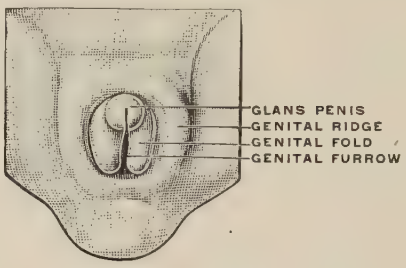

FIG. 116.—Anlage of the penis or clitoris. (Hertwig.)

In the mean time, however, on each side of the urogenital opening a ridge of skin, the anlage of the scrotum in the male and the labia majora of the female, has appeared, and between the anterior (ventral) ends of the ridges a tubercle develops, along whose posterior surface a groove is formed which opens proximally into the urogenital sinus. This tubercle is the anlage of the *penis* or *clitoris* (Fig. 116), and at this stage there is practically no difference between the male and female genitalia. In the male the lips of the penial groove now meet together and fuse, the groove being thereby converted into a canal continuous with the urogenital sinus, the canal and sinus together constituting what is termed the *urethra* of the adult. As a result of this closure of the groove the scrotal ridges of either side are brought into contact, and fuse together below the penis to form the adult *scrotum* (Fig. 118). In the female the lips

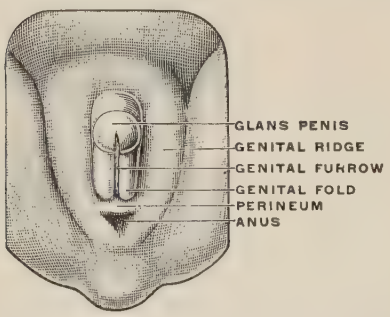

FIG. 117.—Formation of the perineum, separating the alimentary and the genito-urinary passages. (Hertwig.)

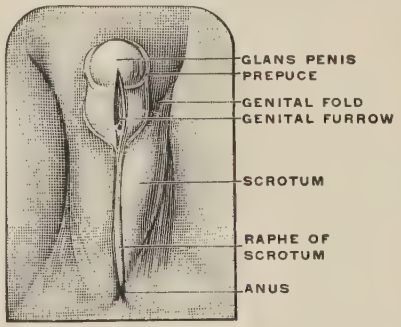

FIG. 118.—Development of urethra and scrotum. (Hertwig.)

of the groove on the clitoris do not fuse, but become greatly enlarged and form the *labia minora*, and the *labia majora* remain separated by a depression into which the urethra, developed in this case from the urogenital sinus alone, and the *vagina* open (Fig. 119). The final arrangement of the female external

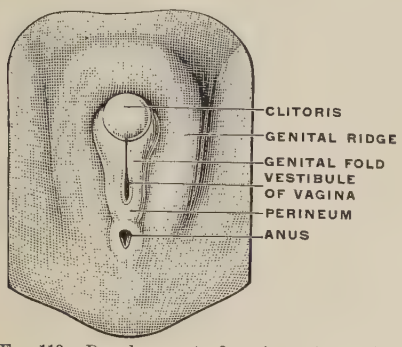

FIG. 119.—Development of vagina. (Hertwig.)

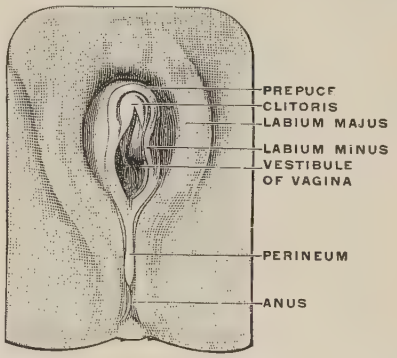

FIG. 120.—Development of the female external genitals. (Hertwig.)

genitalia may thus be readily compared with an early stage of development of the male organs, the latter undergoing a greater amount of differentiation than those of the female.

ORGANS DERIVED FROM THE ECTODERM.

Of the ectoderm the derivatives are the outer layers of the skin and its appendages—hairs, nails, sudoriparous, sebaceous, and mammary glands—and the nervous system and sense-organs. Of the former a detailed account is unnecessary here, but the nervous system requires due consideration.

The Nervous System.

As has been seen, the central nervous system makes its appearance as the medullary groove. As development proceeds the lips of the groove gradually come together, and eventually fuse, transforming the groove into the medullary canal, broader in front than behind, and running the entire length of the body. The cavity of the canal becomes the *central canal of the spinal cord* and the *ventricles of the brain*, while its walls become converted into the various parts of the central nervous system.

At first the cells composing the walls of the canal are practically similar, but later certain of them, the *neuroblasts*, lying nearer the central canal, begin to proliferate rapidly, forming *nerve-cells* (Fig. 121), while the remainder, the *spongioblasts*, scatter themselves among the nerve-cells and become the *neuroglia*, some of them eventually coming to line the central canal and forming the *ependyma* (*endyma*). The walls of the canal also become of unequal thickness, the portions in the dorsal and ventral mid-lines becoming thin and forming

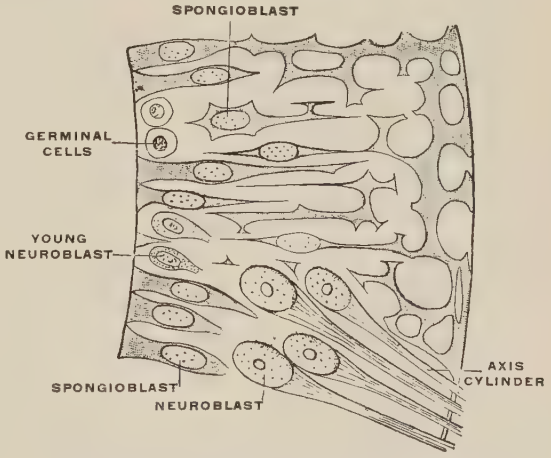

FIG. 121.—Development of nerve-cells and neuroglia-cells in wall of the medullary canal. (Testut and His.)

respectively the *roof-plate* and the *floor-plate*, while each of the lateral thicker portions becomes divided by a longitudinal groove into a *dorsal* and a *ventral zone*.

The spinal cord develops from the narrower posterior portion of the medullary canal, and is formed mainly by the growth of the cells of the ventral zones, the dorsal zones being represented only by the dorsal horns of the gray matter, while the parts contributed by the roof- and floor-plates are comparatively insignificant. At an early period a series of constrictions, separated from one another by definite intervals, appear throughout its entire length, and give it the appearance of being composed of a series of segments, which are termed *neuromeres*, and to each of which a pair of nerves corresponds. The existence of the constrictions is, however, transitory, and it is probable that their appearance is related to the occurrence of the mesodermal somites.

Up to the end of the third month the cord is practically as long as the spinal canal, but later the canal grows in length more rapidly than the cord, so that the latter becomes relatively shorter, though actually it elongates. As a result of this unequal growth, the nerves which pass out between the lower vertebræ must lengthen, and so the bunch of nerves termed the *cauda equina* is formed. The *motor nerves* arise from cells situated in the ventral horn of the cord, and grow out toward the muscles for which they are destined; the *sensory nerves*, however, arise from a series of thickenings situated just external to the lips of the medullary groove, which, on the closure of the groove, separate from the ectoderm and sink down into the mesoderm. From each cell of these thickenings, which are the *dorsal root-ganglia*, two processes are sent off, one of which penetrates the substance of the cord, while the other extends peripherally. There is thus a fundamental distinction between the motor and the sensory nerve-fibres, the former always growing out from the central system, while the latter arise externally to the cord and brain, and grow inward toward them.

In the anterior portion of the medullary canal, from which the brain develops, neuromeres are present as in the cord; but, in addition, two more distinctly marked constrictions appear and divide the brain into three primary vesicles. The roof-plate of the most posterior vesicle forms a thin roof to the cavity of the vesicle (Fig. 122), which broadens out to form the *fourth ventricle*, a transverse thickening, however, developing in the more anterior part of the roof, and later enlarging to form the *cerebellum*. In the posterior part of the vesicle the dorsal and ventral zones become well developed, forming the *medulla oblongata*, while anteriorly fibres grow downward on each side from the cerebellum toward the ventral mid-line, forming the *pons*. In consequence, it is customary to regard the third vesicle as being secondarily divided into two vesicles, the posterior of which is termed the after-brain, or *metencephalon* (myelencephalon), while the anterior, which includes the cerebellum and pons, is known as the hind-brain, or *epencephalon*.

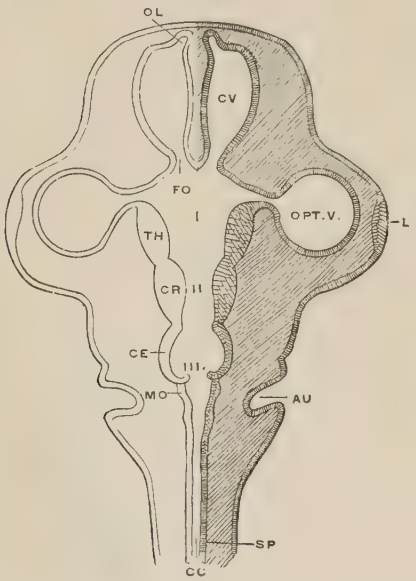

FIG. 122.—Diagram of the brain at an early stage of development: *I*, cavity of primary prosencephalon; *II*, cavity of mesencephalon; *III*, cavity of epencephalon; *AU*, auditory pit; *CC*, central canal of spinal cord; *CE*, cerebellum; *CR*, crura cerebri and quadrigemina; *CV*, cerebral vesicle; *FO*, foramen of Monro; *MO*, medulla oblongata; *OL*, olfactory lobe; *OPT. V.*, optic vesicle; *SP*, spinal cord; *TH*, thalamus opticus. (Martin.)

The cavity of the middle vesicle does not increase in size as rapidly as the others, but assumes the form of a canal, and is termed the *iter* or *aqueduct*. The roof-plate retains its primitive slight development, the dorsal zones, however, giving rise to four well-marked thickenings, the *corpora*

quadrigemina, while the ventral zones become modified to form the *crura cerebri*. To this differentiated middle vesicle is given the name of the mid-brain, or *mesencephalon* (Fig. 123).

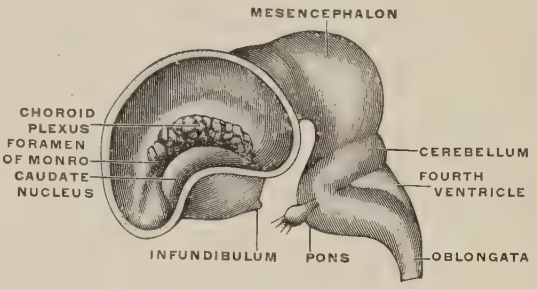

FIG. 123.—Brain of embryo, side view. (Mihalcovics.)

The anterior vesicle undergoes greater changes than either of the others. First, from the lower part of its lateral walls two pouches grow out, finally come into contact with the ectoderm of the sides of the head, and form the optic vesicle (Fig. 122), and later a constriction of the original wall of the vesicle appears, the vesicle thus becoming divided into two portions, the anterior of which, growing most rapidly on each side of the median line, eventually gives rise to the cerebral hemispheres, which are together termed the forebrain, or *prosencephalon*, while the median portion, together with the entire posterior portion of the original vesicle, forms the 'tween-brain, or *thalamencephalon*, which contains the *third ventricle*.

The anterior wall of the third ventricle is evidently, since the hemispheres are lateral outgrowths, the front wall of the primitive brain, and it constitutes the *lamina terminalis* of the adult. The greater portion of the roof of the third ventricle becomes reduced to a thin layer of cells, which, together with the pia, which lies immediately above it, forms the *velum interpositum*, while more posteriorly an evagination of the roof produces a stalk surmounted by a solid oval body, the *epiphysis*, or pineal body, which comparative anatomy shows to be the rudiment of an unpaired, median eye. In the floor of the ventricle there is to be found, in addition to the optic stalks, a hollow, funnel-like downgrowth, the *infundibulum*, which ends in a solid body, the *hypophysis*, or pituitary body, formed partly by a dilatation of the extremity of the infundibulum, and partly by a mass of tissue which arises as an upgrowth from the roof of the mouth, from which it becomes separated; and lastly, in each of the lateral walls of the ventricle there is to be found an oval thickening, the *optic thalamus* (Fig. 122), developed from the dorsal zone, the subthalamic tissues being the product of the ventral zones.

Since the cerebral hemispheres develop as lateral enlargements of the anterior of the two secondary portions of the vesicle, and since this portion contains a cavity (a part of the third ventricle), it is clear that each hemisphere will contain a lateral prolongation of this cavity, a *lateral ventricle*, and that each lateral ventricle will communicate with the sides of the anterior end of the third ventricle, this communication being the *foramen of Monro*. The hemispheres are, strictly speaking, excessive developments of the dorsal zones of the anterior vesicle, and there occurs in the wall of each of them a thickening, termed the *corpus striatum*, which is continuous behind with the optic thalamus. As the hemispheres continue to develop they project in front of the lamina terminalis and overlap behind the roof and sides of the 'tween- and mid-brains; and the lateral ventricles, increasing in size *pari passu* with the growth of the hemispheres, become prolonged into anterior, posterior, and lateral horns. Into the outer layers of the hemispheres an immigration of cells occurs, the cerebral cortex being thus formed, and during the earlier months of development division of these cells occurs with considerable rapidity, gradually becoming rarer, however, until some time before birth, when it completely ceases, there being, in all probability, no normal increase in the number of cells forming the cerebral cortex after birth.

At about the fourth week of development a finger-like dilatation forms on the anterior part of the under surface of each cerebral hemisphere, a prolongation from the lateral ventricle of the same side passing into it. Anteriorly, the dila-

tations fuse with the olfactory ganglia, to which the olfactory nerves pass from the mucous membrane of the nasal cavity, and they form the *olfactory lobes*, or *rhinencephalon*, the cavities which they contain becoming obliterated before adult life is attained.

Up to the fifth month of development the surface of the hemispheres is smooth, but at this time a depression appears at the side of each hemisphere (Fig. 124) involving that portion of the cortex which lies immediately external to the corpus striatum; this is the *Sylvian depression*. Later the lips of the depression grow toward each other, the upper one growing more rapidly and forming a distinct fold, the *operculum*, which covers in the floor of the depression. This covered portion of the cortex is the *insula* of descriptive anatomy, the fissure between the edge of the operculum and the lower lip of the depression being the *Sylvian fissure*. In the subsequent months of development additional fissures appear, some of which are of sufficient depth to form elevations projecting into the cavities of the lateral ventricles, the *hippocampus* of the middle horn and the *calcar* of the posterior horn being formed in this manner.

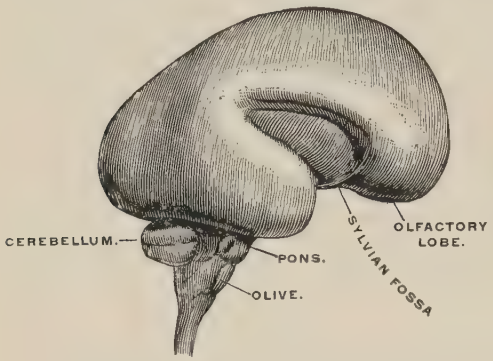

FIG. 124.—Brain of six-months' human embryo, natural size. (Kölliker.)

The lamina terminalis, as has been seen, forms the front wall of the third ventricle, and accordingly connects the two cerebral hemispheres in front. Its lower part remains relatively thin, but above it becomes much thickened from before backward, the thickening having a triangular shape. In the thickening a slit-like cavity appears, and through that portion of the thickening which forms the roof of the cavity nerve-fibres pass across from the cortex of each cerebral hemisphere to that of the other, forming the *corpus callosum*, while in the floor of the cavity longitudinal fibres develop, forming the pillars of the *fornix*. The cavity itself is the so-called *fifth ventricle*, its lateral walls being the *septum lucidum*, and it is evident from its mode of development that it cannot be considered homologous with the other ventricles of the brain.

One other set of structures require notice here, though they are not actual constituents of the central nervous system. These are the *choroid plexuses*, which consist of collections of blood-vessels developed in the pia over certain portions of the brain where the walls are exceedingly thin—as, for instance, over the roof of the third and fourth ventricles and along the floor of the lateral ventricles. The vessels push these thin membranes in front of them into the interior of the brain, and thus come to lie apparently in the interior of the ventricles, though in reality they are separated from them by the prolongation of the roof or floor which they carry in front of them.

The Sympathetic System.—The sympathetic ganglia have usually been regarded as formed by a proliferation of cells from the anlagen of the dorsal root-ganglia, and as being, therefore, of ectodermal origin. More recent observations tend to assign them to the mesenchyme, their first indication being found in a cord of cells in the mesenchyme just external to the dorsal aorta. The history of the system needs further study, however, before definite statements can be made concerning it.

The Olfactory, Gustatory, and Tactile Organs.—Of the organs of special sense the tactile and gustatory are not as yet thoroughly understood embryologically. The olfactory organ appears as two circular thickenings of the ectoderm, one on each side of the fronto-nasal process, just in front of the mouth, and these, sinking beneath the surface, come to form the floor of a pair of depressions (Fig. 99)

whose lips, gradually approaching, finally fuse, except below, to form a pair of cavities, the openings into which are the *anterior nares*. These at first communicate with the mouth, but become separated from it by the union of the two maxillary processes, a separation further perfected by the formation of the hard palate.

The Eye.—The first indications of the eye are a pair of hollow outgrowths from the anterior vesicle of the brain (Fig. 122), and these take the form of vesicles in contact with the ectoderm externally and united to the 'tween-brain by narrow optic stalks. That portion of the wall of each vesicle which is in contact with the ectoderm becomes invaginated, and the vesicle thus becomes converted into a double-walled cup, from whose walls the *retina* is formed. The invagination proceeds more rapidly on the under side of the vesicle, and is continued backward some distance on the optic stalk, which thus becomes grooved on its under surface, the optic cup being imperfect along a narrow line on its under surface, this opening being the *choroidal fissure* (Fig. 125). When the retina is established nerve-fibres grow from its cells toward the brain, choosing the optic stalk as the path of least resistance, and thus converting it into the solid *optic nerve*.

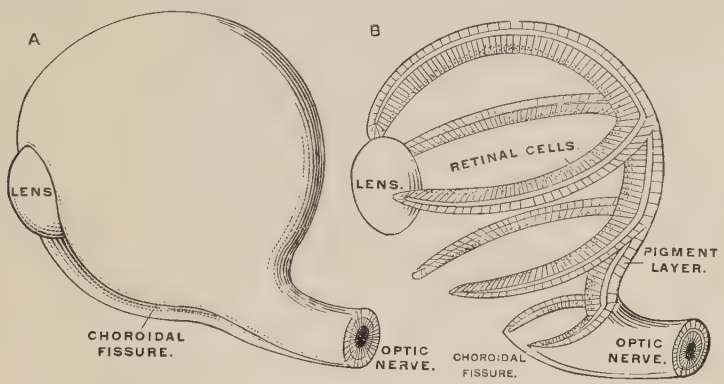

FIG. 125.—Diagrams of the formation of the optic cup and choroidal fissure.

That portion of the surface ectoderm with which the optic vesicle came in contact early begins to thicken, and later becomes invaginated, pressing upon the wall of the vesicle. This ectoderm gradually separates from the surface and forms a spherical, hollow structure, lying in the mouth of the optic cup; it is the anlage of the *lens* (Fig. 126). Later, the cells of its anterior wall flatten down to form the epithelium of the lens (Fig. 127), while those of the posterior wall become much elongated, and are converted into fibres running in various directions and completely filling the original cavity. At first the lens is in close contact with the surface ectoderm; but later mesenchymal tissue pushes in between it and the ectoderm, forming a layer which becomes converted into the *cornea* (Fig. 127), the ectoderm external to it forming the *conjunctiva*. At the same time a concentration of mesenchyme takes place all around the optic cup to form the *sclerotic* and *choroid coats* of the eyeball, and between the outer surface of the lens and the cornea fluid collects, forming the *aqueous humor*. The *vitreous body* is formed by the migration of mesenchyme into the interior of the optic cup through the choroid fissure, and is at first richly supplied with blood, the artery bringing it running along the groove on the under surface of the optic stalk, and so entering the choroid fissure. In the later

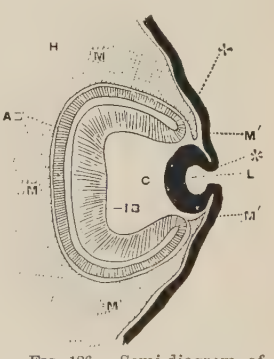

FIG. 126.—Semi-diagram of the secondary optic vesicle and the developing lens: *AB*, layer which becomes pigmentary retinal layer; *C*, posterior chamber, to be occupied by vitreous; *H*, remnant of cavity of primary optic vesicle; *IB*, layer which becomes greater part of retina; *L*, lens, as a cup open on exterior; *M*, *M*, *M*, mesoderm; *M'*, *M'*, points from which mesoderm grows in to form iris and body of cornea; +, place at which the primary optic vesicle has been doubled back on itself; *, point of invagination of ectoderm to form lens. (Wiedersheim.)

development the choroid fissure closes completely, and the lips of the groove on the stalk also meet and close, the artery thus becoming enclosed by the stalk, and forming the *arteria centralis retinæ* of the adult. Later on, the mesenchyme in

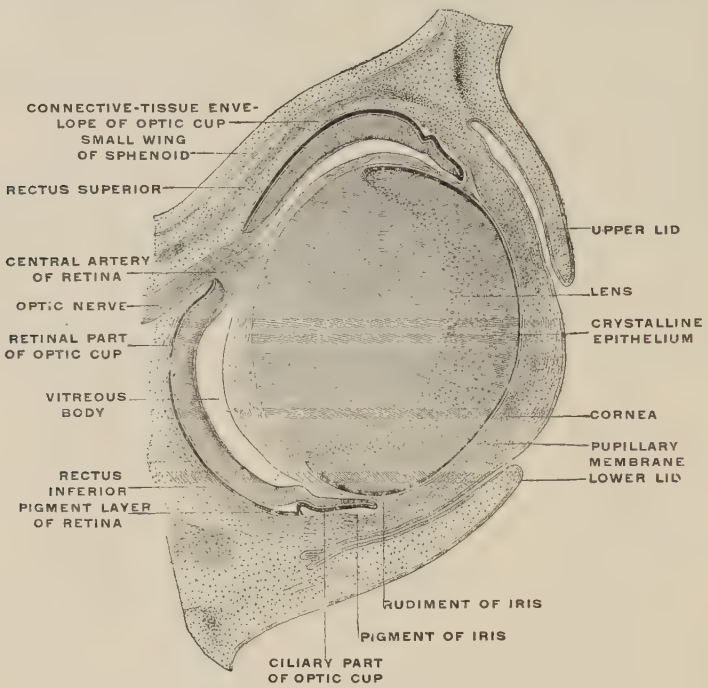

FIG. 127.—Horizontal section of the developing eye. (After Kölliker.)

the interior of the optic cup becomes converted into the peculiar gelatinous tissue of which the vitreous is composed, and its blood-supply becomes cut off, the only trace of the existence of the artery in front of the retina being the space originally occupied by the artery, persisting as a canal traversing the centre of the vitreous, and known as the *hyaloid canal*. When the blood-supply of the vitreous is at its highest development it extends as far forward as the lens, which it surrounds with a vascular capsule, which later normally disappears completely.

Of the structures accessory to the eye, the *eyelids* develop as folds of skin, which grow together over the eye, and remain fused together until shortly before birth. The *lachrymal glands* are formed as solid ingrowths (later becoming hollow) from the conjunctiva, just at the point where the upper-eyelid folds arise, while the *lachrymal duct* is developed as a thickening of the ectoderm, which forms the floor of the groove found at an early stage between the fronto-nasal and the maxillary processes. This thickening later becomes hollowed out, and the lips of the groove meet over the canal so formed, completely enclosing it, and, as the nasal cavity differentiates, the lower end of the duct comes to communicate with it.

The Auditory Organ.—The *membranous labyrinth* or inner ear is the first portion of the auditory organ to develop, appearing as a circular depression of the ectoderm over the first visceral cleft (Fig. 122). This auditory pit deepens, sinking down into the subjacent mesenchyme, its floor at the same time thickening, and it eventually becomes constricted off from the ectoderm as a completely closed sac, a small process from one side of this representing the remains of its connection with the surface, and forming the *ductus endolymphaticus*. From the ventral wall of the sac a tubular outgrowth forms, which is the anlage of the *cochlea*, and in the angle between this and the sac proper is to be found the *auditory ganglion*, which had previously formed as a thickening of the ectoderm

near the auditory pit, and had migrated into the subjacent mesenchyme. A constriction now begins to form in the inner wall of the sac (Fig. 129), dividing it into an upper and a lower portion; and from the upper portion two flat hollow disc-like outgrowths develop, one of which lies in a horizontal plane, while the other is directed vertically, but is bent so that the anterior half of it lies almost at right angles with the posterior. These are the anlagen of the *semicircular canals* (Fig. 130), which are finally formed from the edges of the discs, the central portion of the horizontal disc and of each half of the vertical one disappearing, so that three canals are formed, each opening at both extremities into the upper portion of the auditory sac. At one end of each canal a widening occurs, and, from the mode of development just outlined, it will be seen that the two vertical canals will be united together at one end to form a common canal before opening into the sac (Fig. 131). The constriction of the wall of the sac deepens gradually, until finally the upper portion, or *utriculus*, communicates with the lower portion, or *sacculus*, only by a slender canal, which represents that portion of the original sac with which the ductus endolymphaticus communicates. While these processes have been going on, a second constriction has formed between the cochlear anlage and the sacculus, whereby the connection of these two parts is also reduced to a slender canal, the *canalis reuniens*. In correspondence with this division of the original sac a division of the auditory ganglion also occurs, one portion of it, the *vestibular*

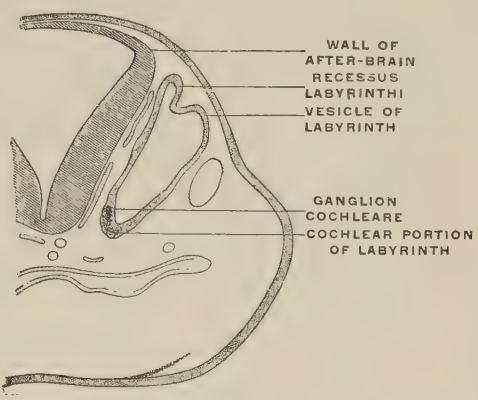

FIG. 128.—Section through the auditory vesicle of a sheep embryo. (Hertwig, after Boettcher.)

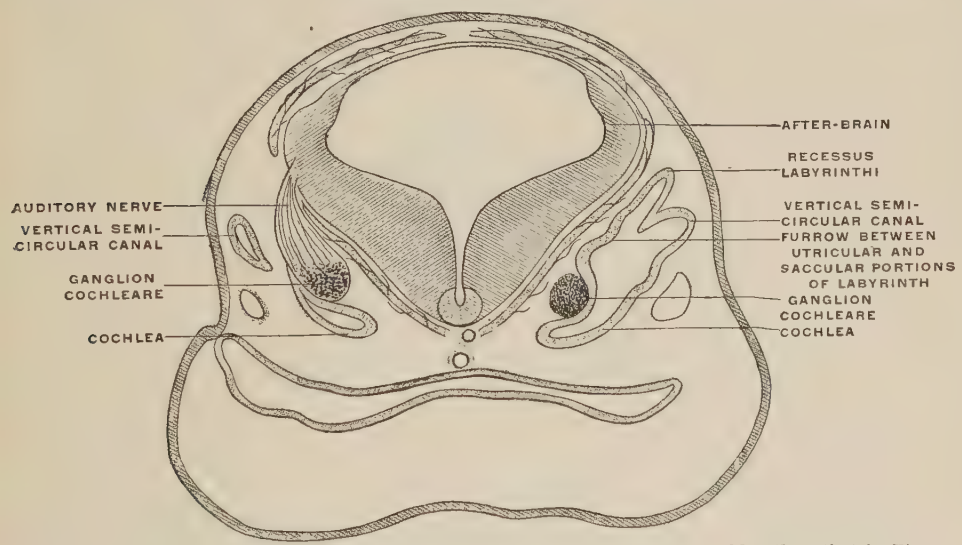

FIG. 129.—Section through the auditory vesicle of sheep embryo, somewhat older than that in Fig. 128. (Hertwig, after Boettcher.)

ganglion, being in relation to the sensory epithelium of the utriculus, sacculus, and semicircular canals, while the other is drawn out into an elongated band, the *spiral* or *cochlear ganglion*, which follows the coils into which the cochlea becomes thrown, and stands in relation to the *organ of Corti*, which develops from the cochlear epithelium.

In the mean time, a condensation of the mesenchyme surrounding each audi-

tory sac has been taking place, and the portions of the tissue immediately in contact with the walls of the sac become converted into fibrous connective tissue, and so strengthen the walls of the membranous ear, while the outermost portions become converted into cartilage, and later into bone, forming the periotic capsule, in whose walls, however, three membranous areas are left, one of these being where a canal, the *ductus perilymphaticus*, leads from the perilymphatic space to the surface of the bone. Between the inner wall of the capsule (which is composed of dense bone, and forms what is termed the *osseous labyrinth*) and the connective tissue a layer of the mesenchyme is left in the form of a loose connective tissue, which subsequently degenerates, leaving a space, which becomes filled with fluid, around the membranous ear. This is the *perilymphatic space*, which, in the cochlea, is separated into two parts by the membranous cochlea, being attached on either side to its wall, so that a section of any coil of the cochlea will show the membranous cochlea, known in anatomy as the *scala media*, with a perilymphatic space above it, the *scala vestibuli*, and another below it, the *scala tympani*, these two spaces communicating, however, at the apex of the cochlea.

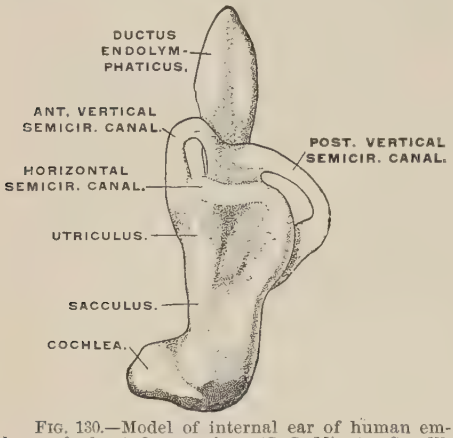

FIG. 130.—Model of internal ear of human embryo of about five weeks. (C. S. Minot, after W. His, Jr.)

The middle ear is the remains of the first visceral cleft, the groove on the wall of the pharynx which represents the cleft becoming converted into a canal

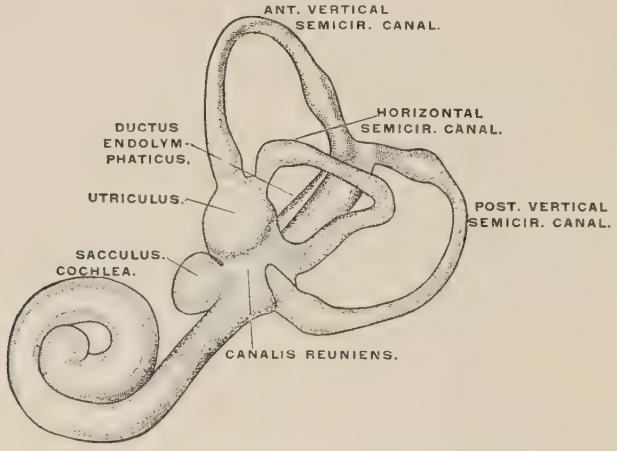

FIG. 131.—Model of internal ear of human embryo of about two months. (C. S. Minot, after W. His, Jr.)

by the fusion of its lips, the upper end of this canal being enlarged to form a cavity, the *tympanic cavity*, while the rest of it forms the *Eustachian canal*, which opens below into the pharynx. The tympanic cavity is, however, up to birth exceedingly narrow, practically merely a slit, its walls, beneath the mucous membrane lining it, being largely composed of a loose gelatinous tissue, in which lie imbedded three small bones, the *malleus*, *stapes*, and *incus*. The upper end of Meckel's cartilage, which develops, as has been seen, in the first branchial arch, separates from the lower portion, and forms two small bones, which are imbedded in the front wall of the tympanum, and are the malleus and incus; while the stapes seems to be produced by the fusion of two distinct parts. Its flat portion,

which rests in one of the three unossified spots of the osseous capsule of the internal ear, the *foramen ovale*, seems to be really the portion of the wall of the capsule which should fill this foramen, the mesenchyme immediately around it having remained membranous, while its arch is the ossified upper end of the cartilage of the second branchial arch. These bones are at first imbedded in the gelatinous tissue of the wall of the tympanic cavity. After birth, air is taken into this cavity through the Eustachian tube, and the cavity enlarges, pressing aside the gelatinous tissue and surrounding bones, which thus form a chain extending from the tympanic membrane to the foramen ovale, and apparently passing through the middle of the tympanic cavity, though in reality they are enclosed by the mucous membrane which lines the cavity.

Two of the three unossified spaces in the wall of the osseous capsule of the inner ear have been accounted for in the ductus perilymphaticus and the foramen ovale; the third opening is the *foramen rotundum*, which is closed by a membrane on which the scala tympani abuts. The outer wall of the tympanic cavity is formed by the *tympanic membrane*, and is at first thick with the gelatinous tissue which encloses the auditory ossicles, it being only after birth that it is reduced to the thin membrane found in the adult. It is formed partly by the partition between the external and internal grooves of the first branchial cleft, and partly by the upper ends of the first and second branchial arches.

Just as the inner groove of the first branchial cleft forms the Eustachian tube and tympanum, so the upper end of the outer groove of the same cleft forms the outer ear, the *pinna* developing from elevations appearing on the first and second visceral arches in the vicinity of the persistent part of the groove.

THE FASCIÆ.

By F. H. GERRISH.

THE word *fascia*, meaning literally a "band" or "bandage," is applied to fibrous, membranous expansions of greater or less density, which are wrapped around various organs, most conspicuously muscles, and serve to keep them in definite and intimate relation with one another. The term is also used to designate certain strong, fibrous sheets which are stretched between bony parts.

Fasciæ are conventionally divided into two groups or varieties—the superficial and the deep. These terms, however, convey very little useful information about the organs to which they are applied. Some members of each group are structurally indistinguishable from typical specimens of the other. The ground of distinction upon which the names are based is their situation; but one variety will frequently be found to shade off by almost imperceptible gradations into the other, even on the same plane. In their typical forms, however, the superficial fascia is a loose, extensible structure; the deep fascia is firm, strong, and inextensible.

THE SUPERFICIAL FASCIA.

Immediately beneath the skin in almost every part of the body is a continuous layer of areolar tissue, which is called the *superficial fascia*. In most cases it differs in no essential respect from the areolar tissue in other localities: it contains fat-cells, it furnishes a suitable medium for the lodgement of vessels and nerves on their way to and from various organs, and it both connects and separates structures between which it is interposed—always the skin on one surface, and usually the deep fascia on the other. It varies greatly in thickness, in some places being extremely thin and delicate, and in others very thick and large-meshed, the belly and buttock furnishing striking illustrations of the latter condition. Though it usually permits free movement of the skin on the subjacent parts, there are notable exceptions to the rule, as in the palm and sole, where it contains strong bands which lash down the skin tightly, and almost deprive it of mobility.

The superficial fascia is in some parts peculiarly modified: in the scrotum it contains no fat-cells, has mingled with its fibrous tissues a quantity of unstriped muscle, and is known as the *dartos*; in certain places it becomes condensed into a fibrous film, as in the *cribriform fascia*, which is stretched across the saphenous opening. Sometimes it is directly continuous with the other (deep) fascia, the latter thinning out and gradually losing itself in the areolar tissue. Occasionally the superficial adheres to the deep along a line of considerable length, as on the thigh near the inguinal ligament, and thus a subcutaneous accumulation of fluid is steered off in a special direction, as would not be the case but for this peculiarity. Two distinct layers are found in certain situations, as on the front of the abdomen, and they may differ considerably in structure, the more superficial generally containing more fat-cells, the deeper being more condensed. The veins which

course through this tissue are in some situations large and conspicuous, as on the dorsum of the hand and foot. Other organs are located in it, of which the most notable is the mammary gland.

The occasions for calling this structure other than subcutaneous areolar tissue are very infrequent; and, as the name "fascia," unless limited by an adjective, is usually employed in surgical parlance to designate the deep fascia, it will be thus used in the remainder of this chapter, unless specific exception is made.

THE DEEP FASCIÆ.

The typical deep fasciæ are close sheets of fibrous tissue, in which the white variety exists in an almost unadulterated form. On account of this histological composition these fasciæ are pearly white, flexible, strong, and inelastic. Their structure and physical qualities immediately bring to mind the characteristics of ligaments and tendons, which have identical structure; and the suggestion is especially apt for the reason that some fasciæ are really interosseous ligaments, and a number are properly to be regarded as tendons. Moreover, the employment of the word "fascia" is ofttimes arbitrary, as, for example, in the case of the transversalis abdominis muscle, whose tendon of origin is almost always described as a layer of the lumbar fascia, and whose tendon of insertion is conventionally dubbed an aponeurosis, although in both situations the tendons are sheet-like expansions, which serve for the ensheathing of muscles.

In this connection it is interesting and useful for the student to observe anew the continuity of the fibrous membranes—ligaments, tendons, and fasciæ blending with periosteum, tendons and fasciæ serving as ligaments, tendons losing themselves in fasciæ, tendons of some muscles acting as fasciæ for other muscles, and so on.

THE FASCIÆ OF THE HEAD.

A structure which may fairly be included in this group is the *epicranial aponeurosis*, which has already been described in connection with the muscles of the region (page 362).

The Temporal Fascia.

The *temporal fascia* has its superior attachment on the upper temporal ridge, its inferior on both borders of the zygoma, splitting into two layers just before reaching this arch. It encloses the temporal muscle, and is partially covered by the epicranial aponeurosis, the orbicularis palpebrarum, attrahens aurem, and attollens aurem.

The Masseteric Fascia.

The *masseteric fascia* is directly continuous with the cervical fascia. It covers the masseter muscle, and ends above at the lower border of the zygoma. In front it is in part attached to the coronoid process and in part blends with the buccinator fascia. Traced backward it is found to cover the parotid gland, and this portion is often called the *parotid fascia.*

The Buccinator Fascia.

The *buccinator fascia* covers the buccinator muscle. Above and below it is attached to the alveolar processes of the jaw-bones, behind is continuous with the masseteric fascia, and in front gradually thins out into areolar tissue.

THE CERVICAL FASCIA.

The deep fascia of the neck is conveniently divided for description into three portions : the outer or superficial, the middle, and the inner or deep, all of which, however, are continuous (Fig. 428).

The Outer Cervical Fascia.

The *outer portion* forms a firm investment for the organs of the neck, its shape being suggestive of a hollow cylinder. Its upper limit extends from the

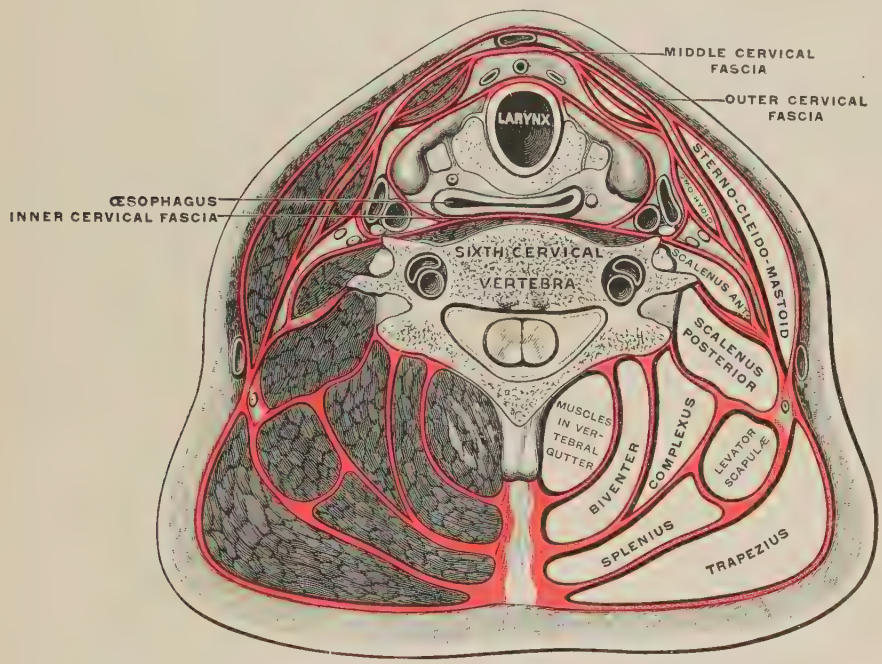

FIG. 428.—The cervical fascia, as seen in a horizontal section of the neck at the level of the sixth cervical vertebra. (Testut.)

external occipital protuberance to the lower part of the symphysis of the mandible, attaching itself to the series of skeletal prominences most nearly coinciding with a line drawn around the head and intersecting these points. Below it is fastened to the sternum, clavicle, acromion, and scapular spine, beyond the last named losing itself in the fascia of the back. Thus it includes, especially in its lower parts, somewhat more than the strict anatomical neck. It is attached behind to the ligamentum nuchæ, and in front it is continuous across the middle line. In its course around the side of the neck it splits twice, first embracing the trapezius, and then the sterno-mastoid, forming strong sheaths for these muscles. Traced from below upward in the region in front of the sterno-mastoid, it is found to be attached to the hyoid, from which it runs to its upper limit on the lower border of the mandible (Fig. 429). From the hyoid insertion it sends to the internal oblique line of the mandible a lamella, which lines the

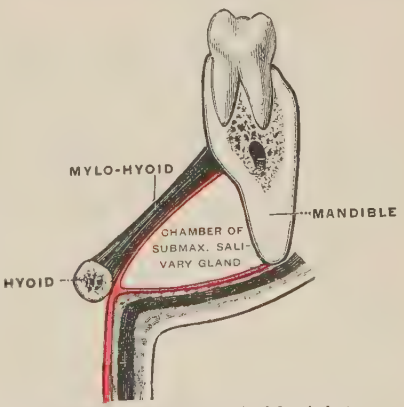

FIG. 429.—The outer cervical fascia between the hyoid and mandible. (Testut.)

under surface of the mylo-hyoid muscle. Thus it may be said that the fascia splits at the hyoid, and encloses between its two lamellæ a space, which is triangular in vertical section, and forms a chamber occupied by the submaxillary salivary gland. Below and in the middle line in front the fascia separates into two layers, one going to the anterior, the other to the posterior border of the top of the manubrium (Fig. 430). From the front of the portion of the fascia which forms a sheath for the sterno-mastoid, and where it is continuous with the masseteric fascia, a prolongation is given off forward and inward, is attached to the angle of the lower jaw, passes behind the parotid gland, and ends by insertion into the styloid process of the temporal, forming thus the *stylo-mandibular ligament* (Fig. 255).

The Middle Cervical Fascia.

The *middle portion* of the cervical fascia—that is, the portion between the superficial and deep layers—lies close behind the front part of the outer layer (Figs. 430, 431), arching between the omo-hyoids of the two sides, forming a sheath for each of them, and extends vertically from the hyoid to the sternum, and laterally from one scapula to the other, its side borders corresponding with the omo-hyoids. The part which ensheathes these muscles sends from each a band down to the sternum and the cartilage of the first rib. From the point where the fascia is attached to the middle line of the sternum a prolonga-

FIG. 430.—The cervical fascia between the hyoid and sternum. (Testut.)

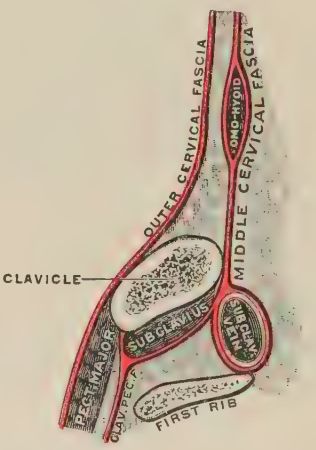

FIG. 431.—The cervical fascia in the clavicular region. (Testut.)

tion of it encircles the left brachio-cephalic vein (Fig. 430), and then passes down into the thorax and blends with the pericardium. On each side it is fastened to the clavicle, gives off expansions which encase the subclavian vein, and then are attached to the first rib and become continuous with the neighboring fasciæ (Fig. 431). A continuation of the middle layer enters into the formation of the sheath of the axillary vessels and nerves. Prolongations also are sent inward and furnish the neck muscles with sheaths; for the most part, however, these processes have not the firmness of the main layer, but are areolar in character.

The Inner Cervical Fascia.

The *inner* or *deep layer* of the cervical fascia, known also as the *prevertebral*, is continuous with the middle portion at the sheaths of the carotid arteries and internal jugular veins. It is attached above to the basilar process of the occipital bone, at the sides to the transverse processes of the cervical vertebræ, and below

gradually thins out and merges into the areolar tissue of the posterior mediastinum. In front of it are the pharynx and œsophagus, behind it the prevertebral muscles.

Peculiar interest attaches to these different portions of the cervical fascia on account of their influence upon the direction which accumulations of fluid will take when occurring in this region (Fig. 432). Fluid in front of the outer layer

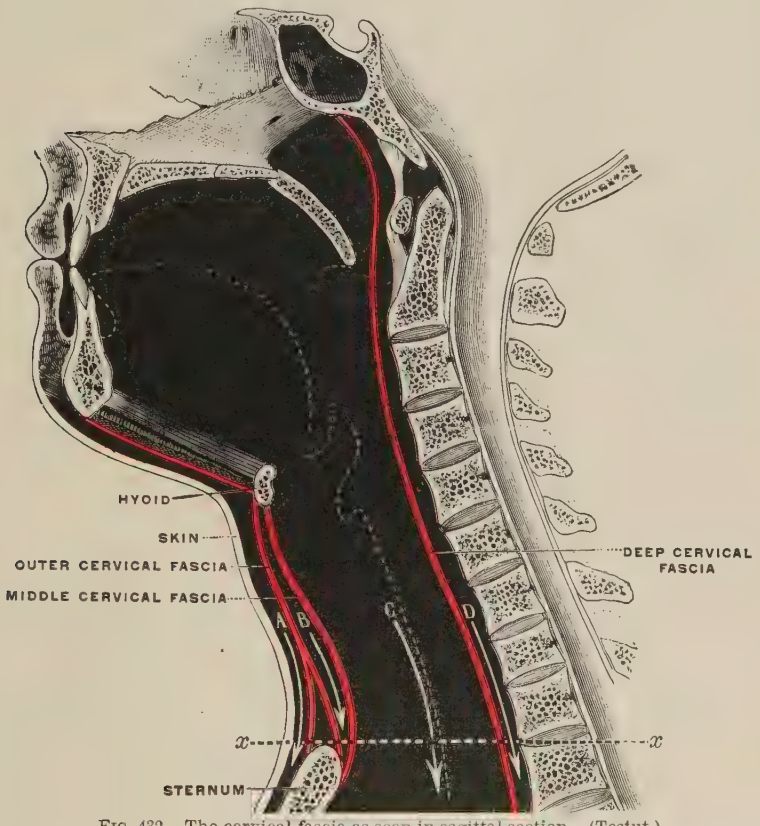

FIG. 432.—The cervical fascia as seen in sagittal section. (Testut.)

is confined to the subcutaneous region; between the outer and middle layers is kept from descending by the sternum; between the middle and inner or prevertebral is guided into the pharynx and œsophagus, or possibly into the larynx; and behind the last layer may be steered into the mediastinum.

THE THORACIC FASCIA.

This name, though often limited to the fascia of the pectoralis major, is much more fittingly applied to the entire series of fasciæ of the antero-lateral region of the chest, and is here employed in this sense.

The Pectoral Fascia.

The *pectoral fascia* (Fig. 433), thin and weak, covers the pectoralis major, and its attachments coincide with the margins of origin of this muscle. It turns around the lower border of the muscle and spreads upward over the hind surface. At the line where it makes the bend it is continuous with the true *axillary fascia*, a thick, strong membrane, which crosses the base of the armpit, describing an arch in its course, unites with the fascia which encases the latissimus, and through

this last becomes attached to the spines of the thoracic vertebræ. At its outer side the axillary fascia merges with the sheath of the vessels and is continuous with the fascia of the arm; it is also connected with the fascia of the shoulder.

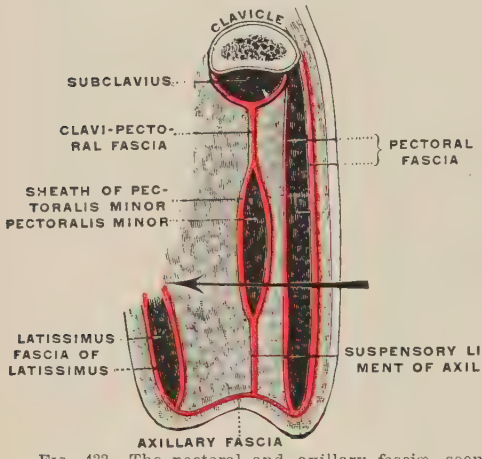

FIG. 433.—The pectoral and axillary fasciæ, seen in sagittal section. (Testut.)

The Clavi-coraco-axillary Fascia.

This is a quadrilateral sheet which runs vertically from the clavicle and coracoid process above to the fascia of the armpit below, and lies just behind the pectoralis major (Fig. 434). It has a double attachment to the clavicle, one layer being in front, the other behind, and between them is lodged the subclavius, to which they furnish a strong sheath. The hind layer is continuous with the sheath of the axillary vessels, which extends downward from the cervical fascia. In the middle of its course the clavi-coraco-axillary fascia splits and closely embraces the pectoralis minor between its layers. From the lower (outer) border of this muscle it is again single, and, extending outward, unites with the sheath of the coraco-brachialis. The portion of the fascia above the pectoralis minor, being fastened internally to the first rib, is named the *costo-coracoid membrane* and *clavi-pectoral fascia*. The uppermost part of it is the strongest, and is called the *costo-coracoid ligament*. The portion of the fascia between the pectoralis minor and the coraco-brachialis is triangular, its apex being at the coracoid process, its base at the lowest part of the axilla. It serves to preserve the hollow of the armpit, and has, consequently, been named the *suspensory ligament of the axilla*.

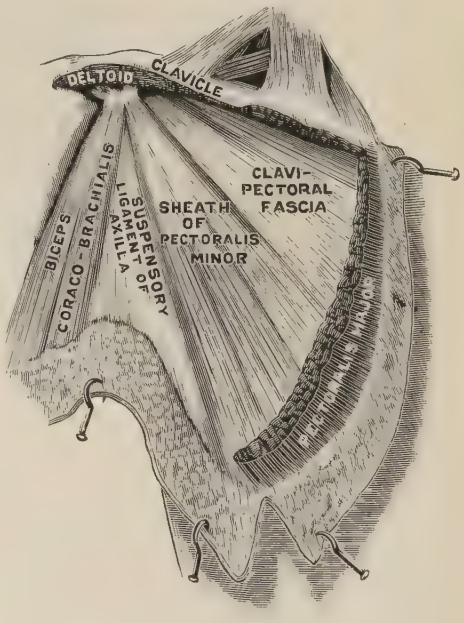

FIG. 434.—The clavi-coraco-axillary fascia of right side, front view. (Testut.)

The Intercostal Fasciæ.

The external intercostal muscles are covered on their outer surfaces and the internal intercostal on their inner surfaces by the fibrous membranes, which are called respectively the *external* and *internal intercostal fasciæ*. They are most pronounced in the portions of the spaces between the ribs which are not occupied by both varieties of these muscles. A thinner fascia separates the muscles of each space.

THE FASCIÆ OF THE SHOULDER.

In the region of the shoulder are the subscapular, supraspinous, infraspinous, and deltoid fasciæ (Fig. 435).

The Subscapular Fascia.

The *subscapular fascia* is attached to the margins of the fossa of the same

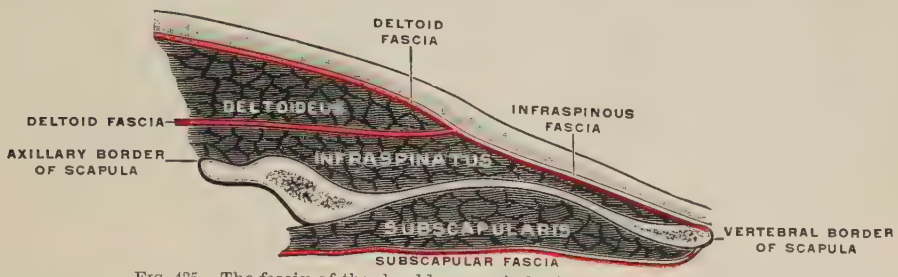

FIG. 435.—The fasciæ of the shoulder, seen in horizontal section. (Testut.)

name, and forms a covering for the subscapularis muscle.

The Supraspinous Fascia.

The *supraspinous fascia*, dense and strong, is attached to the borders of the fossa above the spine of the scapula, thus completing the osseo-fibrous chamber, which is filled by the supraspinatus muscle.

The Infraspinous Fascia.

The *infraspinous fascia* is like the last named in structure and similar in arrangement, being attached at the edges of the lower fossa on the dorsum of the scapula, thus forming with the bone a cavity, which is completely occupied by the infraspinatus. Where this muscle is overlapped by the hind border of the deltoid the fascia splits, one layer passing upon the latter muscle and forming part of the deltoid fascia, the other going in front of the deltoid and ending by fusion with the fibrous structure of the shoulder-joint.

The Deltoid Fascia.

The *deltoid fascia* covers in the deltoid muscle. It is continuous behind with the infraspinous fascia, in front with the pectoral. It is fastened above to the bones from which the muscle takes origin, and is continuous below with the fascia of the arm.

THE FASCIA OF THE ARM.

The *brachial fascia* is continuous above with the pectoral and axillary fasciæ, as well as with that of the shoulder, and below with that of the forearm. It is attached to the condyles of the humerus and the olecranon process. It not only enwraps the muscles of the brachial region, but from its inner surface sends septa between them. The greater part of these partitions are merely areolar, but two are strong and rigid, and need especial mention. One of them is attached to the outer lip of the bicipital groove, the outer supracondylar ridge, and the intervening portion of the shaft; the other is similarly situated on the inner side—thus being formed the *external* and the *internal intermuscular septa*, which divide the muscles into an anterior and a posterior set.

THE FASCIA OF THE FOREARM.

The *forearm fascia* is a direct continuation of the brachial fascia above, and ends below in the fascia of the hand. It has attachments to the olecranon and the posterior border of the ulna. From its inner surface many septa are given

off and extend between the muscles. For the most part these are areolar; but near the elbow, where groups of muscles arise from the condyles, the fibrous partitions are well marked. Between the first and second layers of the flexor muscles is stretched a thin layer of fascia, and a similar one is found between the superficial and deep groups of extensors. The fascia is much thicker behind than in front. At the lower end of the forearm the fascia terminates in the so-called annular ligaments, anterior and posterior. The name implies a ring-like structure; but each extends only half-way round the limb, and, while the posterior is almost entirely within the limits of the forearm, the anterior is wholly within the boundaries of the hand.

The Posterior Annular Ligament.

The *posterior annular ligament* (Fig. 437) is chiefly composed of transverse bundles of fibres constituting a broad and strong band, which has bony attachments on the inner side to the styloid process of the ulna, the cuneiform and the pisiform, on the outer side to the lower end of the ventral border of the radius, and between these extremities to the vertical ridges on the back of the radius. In this way are formed six osseo-fibrous passages, lined with synovial membrane, and occupied by the tendons of the extensor muscles of the forearm which are inserted in the hand.

THE FASCIÆ OF THE HAND.

In the hand are the anterior annular ligament, the palmar fascia, the interosseous fasciæ, the superficial transverse ligament, the dorsal fascia, and the sheaths of the tendons of the digital muscles.

The Anterior Annular Ligament.

The *anterior annular ligament* runs transversely across the front of the carpus from the scaphoid and trapezium on the outer side to the pisiform and uneiform on the inner, thus converting the groove of the carpus into a tubular passage, through which run the flexors of the digits. It is continuous above with the forearm fascia, and below with the palmar fascia.

The Palmar Fascia.

The *palmar fascia* is divided into three parts, a middle and two lateral. Of these the middle is the most important, and often no other part is intended when the term "palmar fascia" is employed.

The *middle palmar fascia* is thick and strong, and seems to be in great part an expansion of the palmaris longus, though there appears to be no lack of the fascia in cases where the muscle is absent. Other portions originate from the anterior annular ligament. The fascia spreads out in fan-shape as it descends, is firmly adherent to the skin, and is inserted into the bases of the four fingers by a division for each. From these divisions slips are sent to the skin, the anterior metacarpo-phalangeal ligament, the sides of the neighboring metacarpal bones, and the digital sheaths, which will presently be described. From the lateral borders of the fascia a partition passes backward to the interosseous fascia, and in this way is formed a canal in which are lodged the tendons which traverse the palm.

The *lateral portions of the palmar fascia* are thin, cover the thenar and hypothenar groups of muscles, and, extending around the borders of the hand, become continuous with the dorsal fascia.

The *anterior interosseous fascia* is a thin layer which lies in front of the interosseous muscles, and is attached to the anterior ridges of the metacarpal bones.

In the interdigital commissures is a thin band, which extends from the index to the little finger, and forms the basis of the webs. It is called the *superficial transverse ligament.*

The Dorsal Fascia of the Hand.

This is a thin layer, continuous on each side with the lateral parts of the palmar fascia, above with the fascia of the forearm, and below with the sheaths of the extensor tendons. Between the metacarpal bones are stretched delicate fasciæ, which cover the dorsal interosseous muscles.

Fascial Sheaths of Tendons in the Hand.

On the palmar aspect of the digits each flexor tendon runs in a tubular canal, made by the concaved phalangeal surfaces and strong fibrous bands, which arch over these from the lateral margins of the bones. The bands are called *vaginal ligaments*, because they help to form the sheath (*vagina*) of the tendon. They are very dense opposite the shaft of the phalanx, much thinner opposite the joints. Each of the canals is provided with a vaginal synovial membrane (Fig. 436). Those of the index, middle, and ring fingers are independent, cylindrical sheaths, covering the length of two phalanges; that of the thumb, also, is separate, and extends from about two inches above the radiocarpal joints to the interphalangeal articulation; and that of the little finger, starting a trifle higher in the forearm, reaches to the distal end of the second phalanx, and includes also the flexor tendons of the other fingers as far as half-way down the palm.

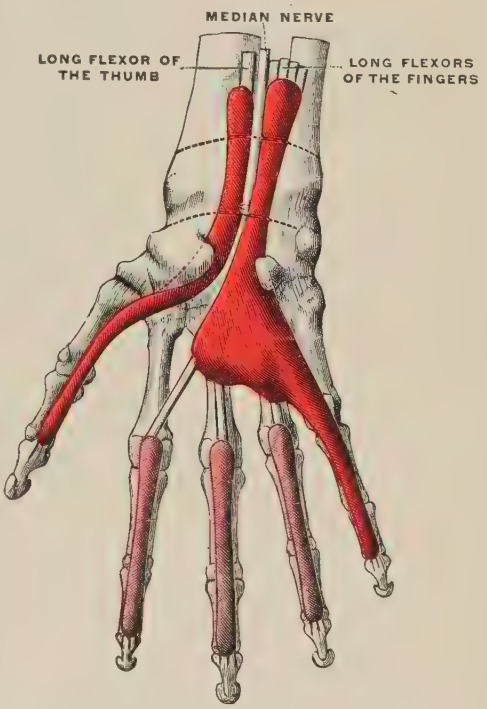

FIG. 436.—Synovial membranes of tendons in the palm, artificially distended. (Testut.)

On the dorsal aspect of the hand a different arrangement obtains (Fig. 437). The tendons of the digital extensors spread out upon the back of the first and second phalanges and blend at the sides with the lateral ligaments of the joints from the metacarpo-phalangeal down, themselves acting as posterior ligaments. As has already been said, the posterior annular ligament forms with the hind surface of the adjacent bones of the forearm a series of tubular canals, through which extensor tendons pass. These channels are provided with vaginal synovial membranes, which extend above and below the limits of the ligament. They contain tendons as follows: the first—that on the radial border—the extensor ossis metacarpi pollicis and the extensor brevis pollicis; the second, the extensores carpi radiales longus and brevis; the third, the extensor longus pollicis; the fourth, the extensor communis digitorum and the extensor indicis; the fifth, the extensor minimi digiti; and the sixth—that on the ulnar border—the extensor carpi ulnaris.

THE FASCIÆ OF THE BACK.

The Vertebral Fascia.

The *vertebral fascia* is an extension downward of the back part of the outer layer of the cervical fascia. It stretches from the spinous processes of the thoracic vertebræ to the angles of the ribs, covering in the deep vertical muscles of the

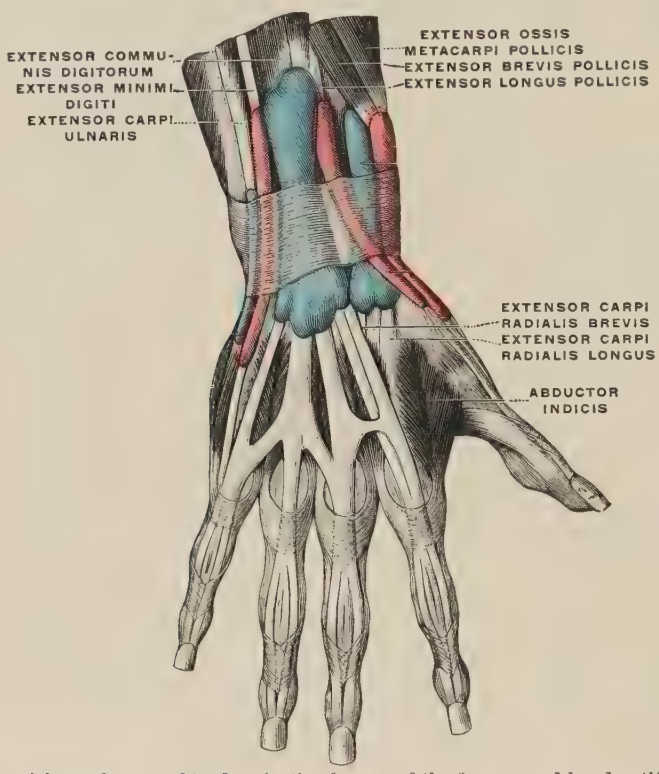

FIG. 437.—Synovial membranes of tendons in the dorsum of the forearm and hand, artificially distended. (Testut.)

back, passing in front of the serratus posterior superior, and becoming continuous below with the lumbar fascia.

The Lumbar Fascia.

The *lumbar fascia* (Fig. 438) is, in reality, rather a combination of tendons than a true fascia of investment, although it serves also in the latter capacity. The latissimus, serratus posterior inferior, obliquus internus abdominis, and transversalis abdominis all participate in its formation. Regarded as a fascia, it springs from the vertebral column in three layers, the outer or posterior, the middle, and the inner or anterior. The *outer layer* begins at the tips of the spinous processes of the lumbar and sacral vertebræ, forming a direct downward continuation of the vertebral fascia. It is attached above to the last rib, and below to the hind third of the outer lip of the iliac crest and the ilio-lumbar ligament. The *middle layer* starts from the free ends of the transverse processes of the lumbar vertebræ; and the *inner layer* arises from the front of the bases of the same processes. The outer and middle unite at the outer edge of the erector spinæ, which occupies the space between them; and this double layer is joined by the inner a little farther away from the middle line, the enclosure thus bounded being filled by the quadratus lumborum. The fascia resulting from the combination of the three layers gives

origin to the transversalis abdominis; the obliquus internus abdominis is inserted into a secondary lamella, which splits off from the outer layer; and the latissimus and serratus posterior inferior arise from still another lamina, which separates from the main fascia nearer the median line.

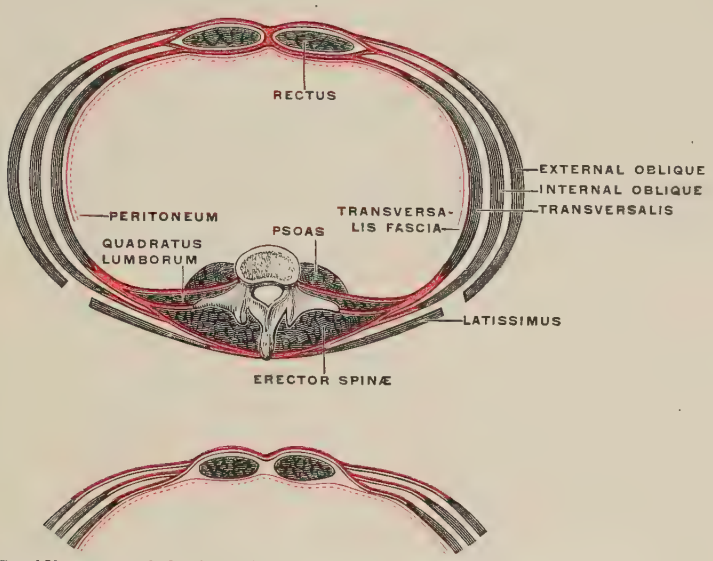

FIG. 438.—Semidiagrammatic horizontal section of trunk to show the lumbar fascia and the tendons of the lateral abdominal muscles. The upper figure shows the complete sheathing of the rectus in its superior portions; the lower shows the arrangement in its inferior fourth. (Testut.)

The front portions of the abdominal wall are largely made up of the tendons of insertion of the external oblique, internal oblique, and transversalis muscles, and these tendons are fasciæ in the same sense that the different tendons are, which constitute the lumbar fascia; but they are rarely mentioned other than as aponeuroses of insertion—a term which implies their tendinous character.

THE FASCIÆ OF THE ABDOMINAL CAVITY.

The abdominal cavity is everywhere lined with a serous membrane, the peritoneum. Between this, which furnishes the free surface of the cavity, and the muscular portion of the abdominal walls is interposed a delicate membrane, which, in the greater part of the abdomen proper, is known as the *transversalis fascia*, on account of its intimate connection with the great muscle against whose inner surface it lies, and, in the back part of the abdomen proper and in the pelvis, is called the *iliac fascia*, because the iliacus is one of the great muscles with which it is in close relation, the other being the psoas. Each of these fasciæ is somewhat prolonged beyond the abdominal cavity, as will presently be detailed.

The Transversalis Fascia.

The *transversalis fascia* is thickest at the groin, gradually becomes thinner as it is traced upward, and is nothing but areolar tissue where it lines the under side of the diaphragm. It is attached to the inner border of the iliac crest, the outer half of the inguinal ligament, the spine of the pubic bone, and the ilio-pectineal line. Beneath the inguinal ligament, a little to the inner side of its middle, the great vessels of the thigh, the femoral artery and vein, are found, the vein nearer the median line of the body. In front of these vessels this fascia is prolonged, forming the anterior part of their common sheath (the *femoral* or *crural sheath*), the posterior part being contributed by the iliac fascia. As the transversalis fascia escapes from the abdomen at this point, it is strengthened by a band, which

curves over the vessels, and is called the *deep crural arch*. The inner portion of this arch is the part of the fascia which is attached to the os pubis and ilio-pectineal line. Between the femoral vein and Gimbernat's ligament is a little gap, the *femoral ring*, through which hernia is most liable to occur in females, this being the weakest spot in the inguinal region of the members of this sex. It is the abdominal opening of the femoral or crural canal, and is occupied by a lymph-node and some fat. About half-an-inch above the middle of the inguinal (Poupart's) ligament is an oval opening in the transversalis fascia, called the *internal abdominal ring*. It is the beginning of the inguinal canal, the other end of which is in the tendon of the external oblique muscle, just above the crest of the pubic bone. Through this canal passes the spermatic cord in the male and the round ligament of the uterus in the female. In each case the transversalis fascia is extended upon the structure contained in the canal, forming a covering which from its funnel-shape is called the *infundibuliform fascia*.

The Iliac Fascia.

The *iliac fascia* lies upon the iliacus and psoas muscles, which, as has been said, are intimately connected. The portion which covers the psoas is attached to the vertebral column coextensively with the front origin of the muscle, and also to the upper part of the sacrum. From this mesial origin it runs outward, its upper part joining the inner (anterior) layer of the lumbar fascia, its lower part blending with the fascia over the iliacus. Its upper end is attached to the ligamentum arcuatum internum. The portion of the fascia which invests the iliacus stretches from the inner margin of the iliac crest to the iliac part of the ilio-pectineal line, and is also attached to the outer half of the inguinal (Poupart's) ligament. It accompanies the united muscles out of the pelvis into the thigh, and, running behind the femoral artery and vein, furnishes the posterior part of the sheath of these vessels, the front part of which is derived from the transversalis fascia. It finally becomes continuous with the pubic portion of the fascia of the thigh, at the line of fusion of the two a partition being given off between the psoas and pectineus to the ilio-pectineal eminence and the capsular ligament of the hip.

THE PELVIC FASCIA.

In direct downward continuation of the transversalis and iliac fasciæ, which belong to the abdomen proper, is the *pelvic fascia*, which, as the name implies, lines that portion of the belly-cavity which is known as the true pelvis (Fig. 439).

Besides the osseous and ligamentous structures presenting surfaces in the pelvic cavity, there are the internal obturator muscles at the sides, the pyriformis muscles behind, and the levatores ani and coccygei below. The levators arise along a line from the body of the pubic bone to the ischial spine, pass downward toward the median line, and there blend, thus forming the greatest part of the sagging floor of the pelvic cavity. This floor is perforated by the rectum, and in the female by the vagina also, and it separates the pelvic cavity from the subjacent perineal or ischio-rectal space. All of these parietal structures are lined by the pelvic fascia, which also gives support to the viscera.

Two principal portions of the pelvic fascia are recognized—the obturator fascia and the recto-vesical fascia.

The Obturator Fascia.

The *obturator fascia*, so named from its lying upon the surface of the obturator internus muscle, is attached to the bone around the margin of the muscle, being continuous with the obturator membrane beneath the obturator vessels, and, extending back to the front of the sacrum, covers the pyriformis and the sacral nerves, in this region being much attenuated. This hind portion is sometimes

called the *pyriformis fascia*. As the obturator internus leaves the pelvis it takes with it a reflection of its fascia, which thus becomes continuous with the fascia which invests the muscles in the hip and thigh.

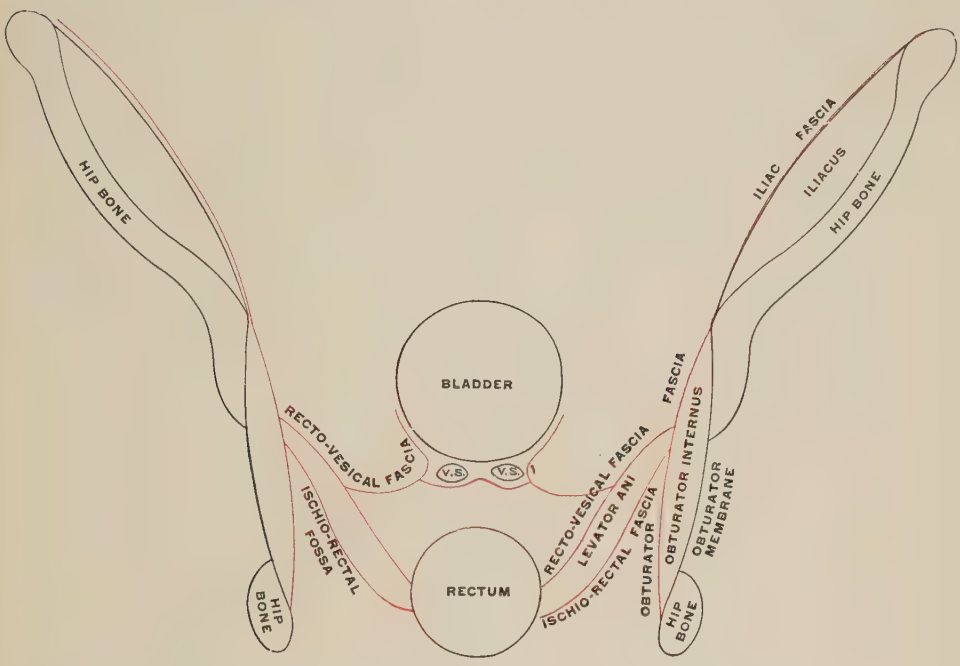

FIG. 439.—Diagram of a coronal section of the pelvis, designed to show the relations of the pelvic fascia and the ischio-rectal fossa. V. S.=Vesicula seminalis.

The Recto-vesical Fascia.

Along the curved line which marks the upper border of the origin of the levator ani (*i. e.*, from the symphysis pubis to the ischial spine) the fascia is somewhat thickened, and is called the *white line* (arcus tendineus, linea albuginea). From this line the *recto-vesical fascia* arises, and extends toward the median line in close contact with the upper surface of the levator ani. When it reaches the bladder, it splits into two layers, one of which spreads upward and disappears in the wall of this viscus, and the other passes downward upon the prostate gland, and thus forms its sheath. The portion around the prostate is continuous with the upper layer of the triangular ligament, which will presently be described.

When the recto-vesical fascia reaches the rectum, its fibres intermingle with those of this intestine. In the female the fascia forms a partial covering to the vagina.

Certain portions of the recto-vesical fascia are described as the *true ligaments of the bladder*; but the lateral and the posterior are generally so indistinct as to be demonstrable with difficulty, if at all, and only the anterior are constantly worthy of mention.

A little to each side of the median line a fold of the fascia runs forward from the bladder, and attaches itself to the body of the pubic bone. This fold encloses a small bundle of muscular tissue, which is called, from the parts which it connects, the *vesico-pubic muscle*. Thus are formed the *anterior ligaments of the bladder*. Between these two ridges is a median depression, in which the fascia is thin.

THE FASCIÆ OF THE PERINEUM.

The *deep fascia of the perineum* forms a triangle with its apex forward, and is often called the *triangular ligament of the perineum.* It extends nearly horizontally sidewise between the lateral walls of the pelvis, and ventro-dorsally from the pubic symphysis to the central point of the perineum, which is about an inch in front of the anus. At the base of the triangle the fascia is single, but immediately splits into two layers, the superficial and the deep, between which are situated the constrictor muscle of the urethra, the suburethral (Cowper's) glands, vessels and nerves, as well as a part of the urethra. From this last fact and its

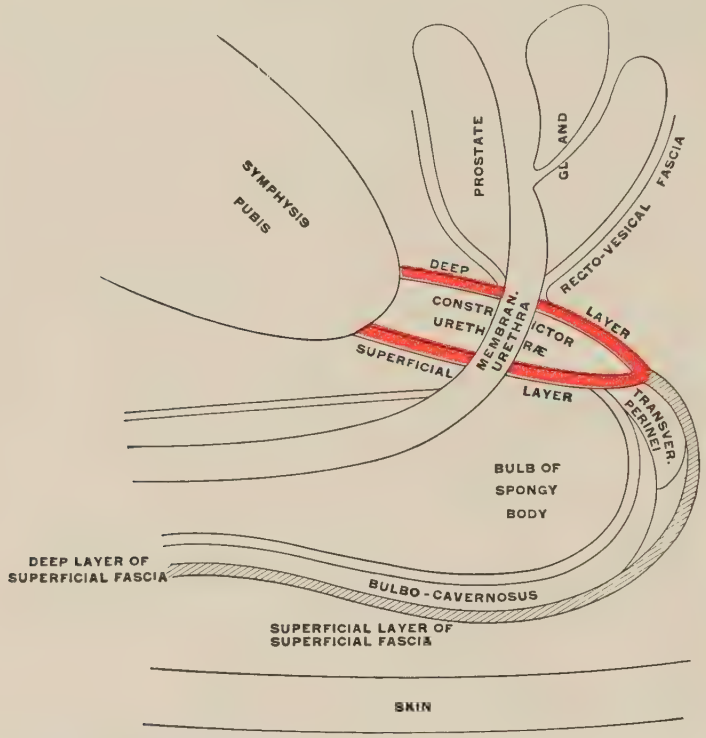

FIG. 440.—Diagram of a median sagittal section of the anterior portion of the perineum, designed to show the relations of the triangular ligament (red).

shape the fascia is most commonly known as the *triangular ligament of the urethra* (Fig. 440).

The *superficial* (inferior) *layer* stretches between the ischio-pubic rami, strengthened near the front by a fibrous band, called the *transverse ligament of the pelvis.*

The *deep* (superior) *layer* is connected laterally with the obturator fascia, just above the latter's attachment to the pubic and ischial rami.

In the female the vagina perforates this fascia.

The *superficial fascia* requires a more detailed description in the perineum than in most other localities. Its *deep layer* (fascia of Colles) is rather firm and close, and is attached at the sides to the entire lower border of the ischio-pubic rami and the ischial tuberosities. Its hind margin is united to that of the triangular ligament, between which structure and it are the transversus perinei muscles. Between this deep layer and the skin is the *superficial layer*, loose and areolar, its spaces occupied with fat-cells.

The name *ischio-rectal fossa* is applied to the considerable space on each side between the sagging floor of the pelvis and the osseo-muscular pelvic wall. The outer wall of this fossa is lined by the lower part of the obturator fascia, the

inner wall by a thin, fibrous lamina, which covers the lower (external) surface of the levator ani, and is called the *ischio-rectal* or *anal fascia*. The fossa is prolonged forward over the superior layer of the triangular ligament. These fossæ are commonly filled with adipose tissue, which is continuous with that subjacent to the skin of the buttocks.

THE FASCIÆ OF THE HIP AND THIGH.

These structures are not separated by a clearly defined boundary, and will be considered as one, which, on account of its great extent, is commonly called *fascia lata* ("the broad band"). It is cylindrical in shape, and extends from the highest margin of the hip to the lowest limit of the thigh. At its upper end it is attached along an irregular line, which lies successively upon the coccyx, sacrum, iliac crest, the inguinal (Poupart's) ligament, the body and descending ramus of the os pubis, the ascending ramus and tuberosity of the ischium, and the great sacro-sciatic ligament, thus completing the circuit. It also has an attachment to the ilio-pectineal line, which will be mentioned again presently. It is continuous below with the fascia of the leg, is attached by its deep surface to the bony prominences around the knee, and contributes to the formation of the capsular ligament of this joint. In most parts it is a single layer, but, in the region of the gluteus maximus, it has two lamellæ, which ensheathe the muscle, and a similar arrangement obtains in the case of the tensor vaginæ femoris, otherwise called the tensor fasciæ latæ. The portion of the fascia on the outer aspect of the thigh is the strongest, and is called the *ilio-tibial band*, from its attachments at the iliac crest and the outer tuberosity of the tibia. The fascia sends inward to the femur two *intermuscular septa*, which partition the thigh into an anterior compartment and a posterior, the former containing the quadriceps and sartorius, the latter the other muscles. These septa, external and internal, have their osseous attachments respectively upon the outer and inner lips of the linea aspera and their upward and downward prolongations. Other and less important septa also occur. Just below the median end of the inguinal (Poupart's) ligament is an oval hole, measuring about an inch in its long (vertical) diameter, and called the *saphenous opening*, from its transmission of the long saphenous vein. The saphenous opening is closed in by a thin layer of areolar tissue (superficial fascia), which, from its being perforated by many vessels, suggests a sieve, and hence is called the *cribriform fascia*. The part of the fascia at the outer side of this aperture is the *iliac portion*; the part at the inner side is the *pubic portion*. The saphenous opening may be regarded as a notch in the upper border of the fascia, the angles of the notch overlapping each other without contact, so that the opening has not a continuous margin. The part of the margin which comes in front is continuous with the inner end of the inguinal (Poupart's) ligament; that which goes to the rear curves backward, and is attached to the ilio-pectineal line. The upper, outer, and under portions of the rim taken together are sickle-shaped, and bear the name of *falciform process*. It is attached to the front of the sheath of the femoral vessels. Behind the plane of the saphenous opening are the upper parts of the femoral artery and vein. Elsewhere these vessels, like others generally, are enclosed in a snugly fitting sheath; but here for about three-quarters of an inch they are clothed with a somewhat loosely fitting investment, the *femoral* or *crural sheath*, the anterior portion of which is a prolongation

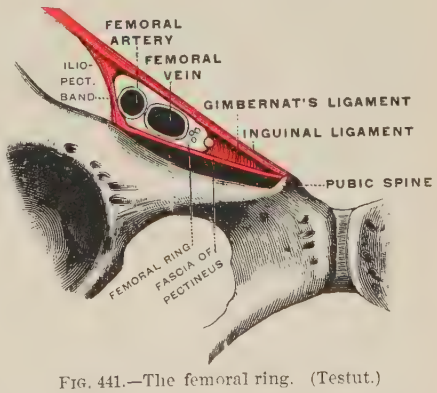

FIG. 441.—The femoral ring. (Testut.)

of the transversalis fascia, the posterior part an extension of the iliac fascia. The femoral sheath has the shape of a funnel with its large end up, and its small end down, continuous with the sheath of the distal portion of the vessels. Two vertical septa divide the space included by the femoral sheath into three compartments, in the outer of which lies the femoral artery, in the middle the femoral vein, and in the inner a little adipose tissue, and perhaps a small lymph-node, which fill the space but imperfectly. The inner compartment is the *femoral* or *crural canal*. Its upper end about half an inch across, between the femoral vein and Gimbernat's ligament, is the *femoral* or *crural ring*, and is closed by a rather firm layer of areolar tissue, the *septum crurale*. The anterior part of the femoral sheath at its highest level is enforced by a transverse band, which curves over the vessels and is known as the *deep crural arch*. At its outer end the arch is connected with the iliopectineal line and the fascia covering the pectineus by a fibrous cord, the *iliopectineal band*. The obturator artery usually courses close to the outer side of the femoral ring; but it may run on the mesial side of the ring—a fact to be remembered in operating on a femoral hernia, which protrudes through the weak spot in the abdominal wall afforded by the femoral ring and canal.

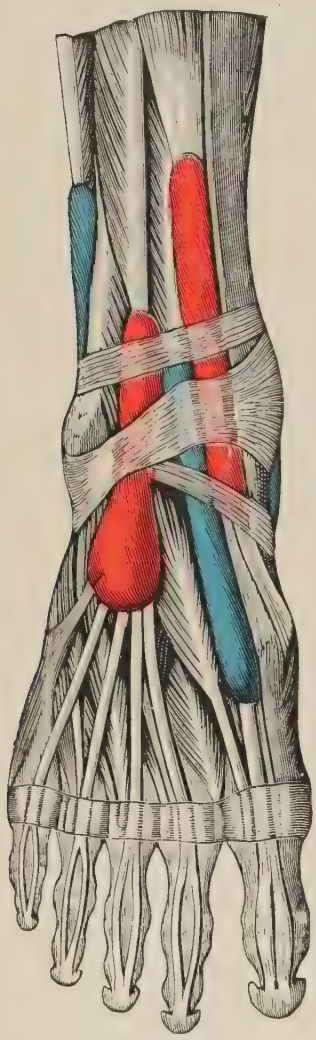

FIG. 442.—The anterior annular ligament of the ankle and the synovial membranes of the tendons beneath it artificially distended. (Testut.)

THE FASCIÆ OF THE LEG.

The principal fascia of the leg is directly continuous with that of the thigh above and that of the foot below. It is not, however, a complete enclosure for the leg, being deficient at the places where the bony framework is subcutaneous. For example, at the inner surface of the tibia the fascia merges with the periosteum at the borders of this area; and it is disposed in like manner at the heads of the tibia and fibula, and at the malleoli. It sends *intermuscular partitions* inward at several points, the most perfect of them being two on the outer side of the leg which have bony attachments along the neighboring borders of the fibula, and separate the peronei longus and brevis from the front and back groups of muscles respectively. Between the muscles which are inserted into the calcaneum and the other posterior muscles is stretched the *deep transverse fascia*, attached to the tibia and fibula, and binding down the muscles in front of it.

In the region of the ankle the fascia is strengthened and to some extent prolonged into the foot by a series of transverse bands, which nearly encircles the limb, each of its primary divisions being called an annular ligament. They are three in number—anterior, internal, and external. The *anterior annular ligament* (Fig. 442) consists of two parts, an upper and a lower. The *upper band* runs across the front of the leg between the anterior borders of the tibia and fibula, just above the malleoli, keeping the vertical tendons in place. The *lower band* begins on the outer side of the calcaneum, and splits into two layers at the outer border of the peroneus tertius, one going in front and the other behind; at the inner border of the extensor longus digitorum the layers unite, thus forming a channel through which these two

muscles pass. The band then divides into two branches—a superior, which goes upward to the front of the inner malleolus, and is there attached; and a lower, which crosses to its insertion on the scaphoid and internal cuneiform bones and in the plantar fascia. These bands confine the tendons of the tibialis anterior and extensor proprius hallucis closely to the subjacent structures. Each of the last-named has a synovial sheath, but the extensor longus digitorum and peroneus tertius have one in common. The *internal annular ligament* (Fig. 443) is stretched between the internal malleolus and the postero-inferior part of the inner surface of the os calcis. From its deep surface processes are given off to the neighboring ridges of bone, thus forming compartments through which pass the tendons of muscles from the back of the leg to the sole of the foot, as follows: next behind the malleolus the tibialis posterior, then the flexor longus digitorum, and, finally, after an interval in which lie the vessels and nerves, the flexor longus hallucis. Each of the tendons has its separate synovial membrane. The *external annular ligament* (Fig. 444) runs from the tip of the external malleolus to the outer side of the calcaneum, binding down the peroneus longus and peroneus brevis, which are enclosed together in a single synovial membrane.

THE FASCIÆ OF THE FOOT.

The homology of the fasciæ of the foot and hand is so marked that it is unnecessary to dwell minutely upon the former, the latter having been already described. That in the sole is called the *plantar fascia*, and is divided into three parts. The central portion starts from the inner tuberosity of the calcaneum, runs forward below the flexor brevis digitorum, and terminates in front in a process for each toe and in slips for the skin. At the sides it is continuous with

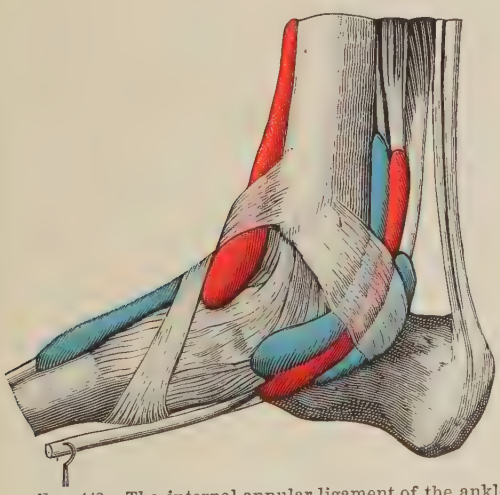

FIG. 443.—The internal annular ligament of the ankle and the artificially distended synovial membranes of the tendons which it confines. (Testut.)

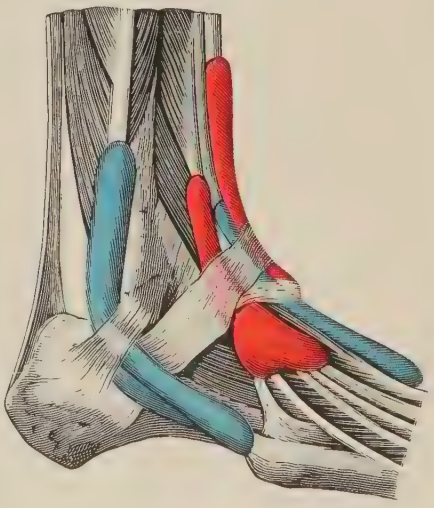

FIG. 444.—The external annular ligament of the ankle and the artificially distended synovial membrane of the tendons which it confines. (Testut.)

the lateral portions, which extend around the margins of the foot. Where the central portion joins each lateral a process passes upward, and thus are formed partitions between corresponding groups of muscles. The external lateral portion is attached behind to the calcaneum, the internal to the internal annular ligament. The interosseous fasciæ, the dorsal fascia, and the superficial transverse ligament of the toes, all are similar to their homologues in the upper limb, but the last named connects five digits, instead of only four. The tendons of the toes are kept in place by fibrous bands, and are provided with synovial membranes, as are the corresponding organs in the hand.

SYNOVIAL BURSÆ.

The structure of bursal synovial membranes (*bursæ synoviales*) has already been presented (page 71). It is not desirable to give in this place a detailed description or even to make mention of all of these organs that have been found; for of the great number, many are insignificant, and others are so rare as to be merely curiosities. It will suffice to indicate the situation, relations, and connections of those which are constant or even common, and those which have especial physiologic or clinical importance. Of the bursæ infrequently seen, some are found only in those persons in whom some peculiar, localized stress has provoked their development from open spaces in areolar tissue. Illustrations of this are encountered over the spine of the scapula in individuals who carry burdens on the shoulder; over the xiphoid process, and between the rectus femoris and the vasti in shoemakers; and over the angle between the first and second pieces of the sternum in carpenters and cabinet-makers.

It should be understood that the bursæ mentioned in the following enumeration are not all constant, but that any particular one of the inconstant may be found in any case. The initial letter of "bursa" will be used instead of the full word in giving the Latin name.

B. trapezii is situated between the trapezius and the triangular surface at the base of the spine of the scapula.

B. acromialis subcutanea lies between the skin and the acromion process.

B. subacromialis is located between the capsular ligament of the shoulder and the arch made by the coracoid and acromion processes, and extends beneath the deltoid muscle, from which fact it is often called *B. subdeltoidea.*

B. coraco-clavicularis media is found between the conoid and trapezoid ligaments.

B. pectoralis majoris separates the tendon of the greater pectoral muscle from the *B. intertubercularis* and the latissimus. The latter bursa is the prolongation of the articular synovial membrane of the shoulder, which invests the tendon of the long head of the biceps.

B. coracobrachialis is situated between the coracobrachialis and the biceps on one side, and the subscapularis on the other.

B. latissimi lies between the latissimus and teres major. Sometimes a bursa is found between the latissimus and the lower angle of the scapula.

B. teretis majoris is lodged between the tendon of insertion of the teres major and the small tuberosity of the humerus.

B. subscapularis, between the subscapularis and the neck of the scapula, is really a diverticulum of the synovial membrane of the shoulder-joint.

B. epicondyli externi subcutanea and *B. epicondyli interni subcutanea* lie upon the external and internal condyles of the humerus respectively.

B. bicipito-radialis, often double, is situated between the tuberosity of the radius and the tendon of the biceps, which is inserted into it. At the inner side of this bursa and its associated tendon is sometimes found the *B. ulno-radialis* (*B. cubitalis interossea*), close to the ulna and the muscles of the neighborhood.

B. olecrani subcutanea covers the dorsal surface of the olecranon process.

B. olecrani subtendinea is located above the olecranon, in front of the triceps, and behind the posterior ligament of the elbow-joint.

B. anconei is between the anconeus and the elbow-joint.

B. extensoris carpi radialis brevis is placed beneath the tendon of insertion of the muscle named. A bursa is less often found in the same relation to the long radial extensor of the wrist.

B. extensoris carpi ulnaris is situated beneath the origin of the ulnar extensor of the wrist, and may communicate with the elbow-joint.

B. capitula ulnæ subcutanea lies beneath the skin over the styloid process of the ulna.

B. sacralis is found upon the spinous process of the fourth sacral vertebra, or over the joint between the sacrum and the coccyx.

B. subiliaca is located behind the united tendons of the iliacus and psoas muscles and in front of the capsular ligament of the hip-joint, with the cavity of which it is often connected.

B. trochanterica subcutanea is situated under the integument which covers the great trochanter.

B. trochanterica profunda is placed between the outer surface of the great trochanter and the upper part of the tendon of insertion of the gluteus maximus.

B. glutei maximi ischiadica is found between the tuberosity of the ischium and the lower border of the muscle named.

B. glutei medii anterior lies between the anterior part of the tendon of the middle gluteal muscle and the great trochanter.

B. glutei medii posterior intervenes between the hind part of the tendon of this muscle and the pyriformis.

B. glutei minimi is between the tendon of insertion of this muscle and the anterior surface of the great trochanter.

B. pyriformis is placed either between the tendon of this muscle and the gemellus superior, or beneath its tendon of insertion.

B. obturatoris interni is situated between the tendons of the internal obturator and the gemelli, and may communicate with the B. ischiadica. There is also a bursa in the small sciatic notch, over which the obturator internus glides.

B. pectinei has on one side the insertion of the pectineus, and on the other the lowest part of the iliacus and the adjacent surface of the femur.

B. semitendinoso-bicipitalis lies between the united tendons of origin of the semitendinosus and biceps flexor cruris and the tuberosity of the ischium.

B. sartorii separates the sartorius from the inner tuberosity of the tibia, and from the tendons of the gracilis and semitendinosus.

B. semimembranosi, often double, is situated between the tendons of the semimembranosus and quadratus femoris. Another bursa lies between the expansion of the tendon of insertion of the semimembranosus and the inner tuberosity of the tibia.

B. tibialis interna (B. anserina) is placed between the lower part of the inner hamstring tendons and the internal lateral ligament of the knee. This bursa may connect with the knee-joint through the B. gastrocnemii interna.

B. bicipitis cruris (B. fibularis) is lodged between the tendon of insertion of the biceps of the leg and the external lateral ligament of the knee, and may communicate with the joint.

B. poplitei has the tendon of origin of the popliteus on one surface and on the other the external tuberosity of the tibia and the capsule of the knee. It always connects with the joint-cavity, of which it may be considered a diverticulum, and sometimes communicates with the superior tibio-fibular articulation.

B. supra-acetabularis lies between the reflected tendon of origin of the rectus femoris and the upper margin of the acetabulum.

B. suprapatellaris is situated between the quadriceps extensor cruris and the lower part of the anterior surface of the femur. Its cavity communicates with that of the knee-joint.

B. prepatellaris subcutanea is located on the anterior surface of the patella, just beneath the skin.

B. infrapatellaris is placed between the ligamentum patellæ and the anterior surface of the head of the tibia.

B. condyli externi and *B. condyli interni*. One is found between the external condyle of the femur and the skin, the other in similar relation to the internal condyle.

B. pretibialis lies between the tubercle of the tibia and the superjacent fascia.

B. gastrocnemii interna is situated behind the inner condyle of the femur and

the capsule of the knee-joint, between the inner head of the gastrocnemius and the semimembranosus. It communicates with the joint.

B. postcalcanea superficialis is found between the tendo calcaneus (Achillis) and the deep fascia.

B. postcalcanea profunda (B. tendinis calcanei) is placed between the tendo calcaneus and the posterior surface of the os calcis.

B. subcalcanea lies between the inferior surface of the calcaneum and the plantar fascia.

B. malleoli externi subcutanea is located under the skin which covers the external malleolus. The internal malleolus is provided with a similar bursa—*B. malleoli interni subcutanea.*

B. tibialis anterioris is lodged between the distal tendon of the muscle named and the internal cuneiform bone.

B. sinus tarsi is lodged between the fascia binding down the extensor longus digitorum and the head of the astragalus.

B. prementalis is situated beneath the skin at lower margin of the symphysis menti.

B. musculi trochlearis is in the pulley of the superior oblique muscle of the eyeball.

B. coccygea lies between the free end of the coccyx and the sphincter ani.

B. prominentiæ laryngeæ subcutanea occurs principally in the aged between the skin and the upper part of the thyroid cartilage.

THE BLOOD-VASCULAR SYSTEM.

THE *blood* is the vehicle by which nourishing materials are carried to the tissues, and many effete substances conveyed away from them. It is contained in a continuous series of chambers and tubes, which constitute the blood-vascular system. The chambers are the compartments of the heart, and the tubes are the arteries, the capillaries, and the veins—including under the last term not only the veins proper, but also certain channels which are called venous sinuses. The *arteries* are the vessels which carry blood *from the heart* to the tissues; the *capillaries* are those through whose delicate walls the interchange of nutrient and waste matters takes place *in the midst of the tissues*; and the *veins* are the vessels which convey the blood from the tissues *to the heart*. The whole blood-vascular system is closed in the normal condition, and no blood escapes from it, with two exceptions, which are as follows: in the female, during the child-bearing portion of her life, there is a periodical discharge of blood through ruptured vessels; and in the spleen of all persons the blood leaves the minute vessels, and flows through wall-less tubes in the parenchyma of the organ.

In the entire blood-vascular system *one structural feature is constant*—the serous membrane which lines it. Muscular and fibrous coats in most parts are found surrounding the serous, but they are not, like it, invariable. The importance of this smoothest of all membranes as a lining for the heart and vessels is appreciated, when we consider that any roughness of a surface over which blood flows causes clotting of the fluid, and this results in the plugging of vessels, and the consequent starvation of the parts which they should supply with blood.

THE HEART.

BY F. H. GERRISH.

THE *heart* (Latin *cor*, or *cardia*) is the central organ of the vascular system. It is the force-pump which propels the blood through the vessels. In some animals it has but one cavity, in others it has two, in still others three. In man there are really two hearts, each having two chambers. The two hearts in the adult may be compared to a block of two houses, which are independent of each other except for the fact that the partition wall between them is common to both. During intrauterine life there is a door of communication between the upper chamber of one and the corresponding cavity of the other; but this is closed at birth, and thenceforward the blood cannot get from one side to the other without leaving the heart and going by a roundabout path.

These two hearts are called, on the basis of their independence, the *right heart* and the *left heart* respectively; on the ground of their union, they are named the right side of the heart and the left side of the heart respectively. Both sets of designations are misleading as regards the relative situation of the two organs (or sides of the same organ), for they are not placed right and left, but one—the right—is in front of the other. One chamber of each is called *auricle*, because of the resemblance of an appendage of it to an animal's external ear; the other chamber is named *ventricle*, from its bulging like a prominent abdomen. The

auricles are spoken of as if they were entirely on a higher level than the ventricles, whereas they are nearly on the same plane.

Each auricle receives blood from veins, and delivers it to the corresponding ventricle, which then discharges it through an artery.

The Circulation of the Blood.

The course of the blood is as follows (Fig. 445): Beginning in the auricle of the right side, the blood, which has just come from the tissues of the entire body, passes through the large aperture by which the auricle communicates with its ventricle, and which is called the right auriculo-ventricular opening; from the right ventricle it is driven through the pulmonary artery to the lungs, through the walls of whose capillaries it loses certain impurities and gains oxygen from the air, thus being changed from venous blood to arterial; from the lungs it flows through the pulmonary veins to the left auricle, thence through the left auriculo-ventricular opening to the left ventricle, whence it is forced into the aorta, the great trunk of the general arterial system, and by this and its branches it is distributed throughout the body. From the twigs of the arterial system the blood is poured into the capillaries, and here parts with nourishing materials, synchronously receiving a load of effete substances, in this way being altered from arterial to venous. From the capillaries it courses into the veins, which conduct it to the right auricle, the place from which the reckoning began. This description of the track of the blood confirms the statement previously made that the communication between the right and left sides of the heart is not direct, through the partition wall, but is entirely indirect—it being necessary for the blood to go out of the heart and through the capillaries of some organ in order to get from either side to the other.

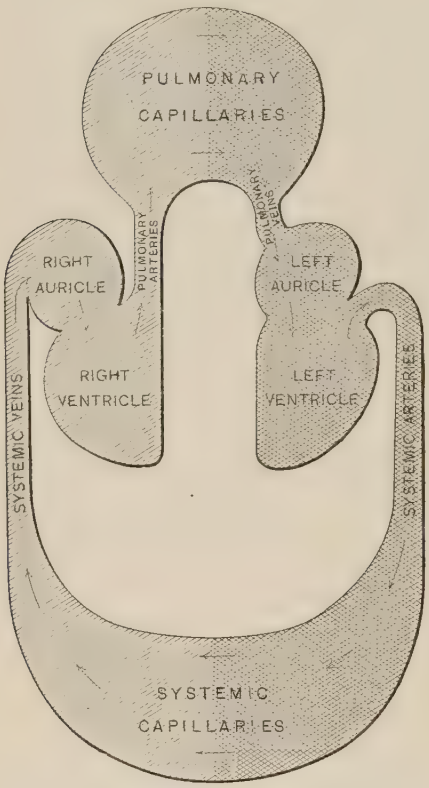

FIG. 445.—Diagram to show the course of the blood in passing from a given point through the two sets of capillaries to the starting point. (F. H. G.)

The journey of the blood from the right heart to the left through the capillaries of the lungs is the less or *pulmonary circulation*; and the passage of the blood from the left heart to the right through the capillaries of the organs of the body is the great or *systemic circulation*. It is to be noted that, in going through the lung-capillaries, the blood is changed from venous to arterial; and that, in its course through the capillaries of the general system, the reverse occurs—it is altered from arterial to venous. The kind of blood contained in a vessel does not, however, make the latter either vein or artery, as the pulmonary artery bears foul or venous blood, and the pulmonary veins are full of purified or arterial blood. *Arteries* carry blood, red or blue, *from the heart*; *veins* carry blood, blue or red, *to the heart*.

The Tissues of the Heart.—The lining of the heart, like that of all other parts of the vascular system, is serous membrane, and is called *endocardium* ("within the heart"). The outer covering, too, is serous, and is called *pericardium* ("around the heart"). It will be described in detail on a subsequent page.

Between the endocardium and the pericardium is a middle coat, which is muscular and fibrous, and, on account of the enormous preponderance of the contractile tissue, is named *myocardium* ("muscle of the heart"). The muscular tissue is of the cardiac variety. The arrangement of the bundles of fibres is extremely intricate, and not yet fully understood in all of its details.

The Thickness of the Cardiac Walls.—The muscular walls of the right auricle are thin and so flabby that they fall together when the cavity is empty; they have to drive the blood but a short distance—only into the ventricle—and through a very large opening. The right ventricle has thick, firm walls, so powerful that by them the blood is sent through the pulmonary artery and its branches, into and through the numberless capillaries of the lungs, through the pulmonary veins, and into the left heart. The left auricle has walls but little thicker than those of the right, yet quite equal to the trifling labor placed upon them—that of forcing the blood through the large auriculo-ventricular orifice into the left ventricle. The left ventricle by its contraction must drive the blood through the vessels of the systemic circulation; and, as these are much more numerous than those of the pulmonary set, and present, on account of their situation, far greater frictional resistance to the passage of the blood in proportion to their number, there is necessity for vastly greater power in the ventricular walls, which, in fact, are three times as thick as those of the right ventricle (Fig. 446). The bulging of the interventricular septum into the right ventricle is due to this greater thickness of the parietes of the left; indeed, this whole partition has the appearance of being formed by the latter.

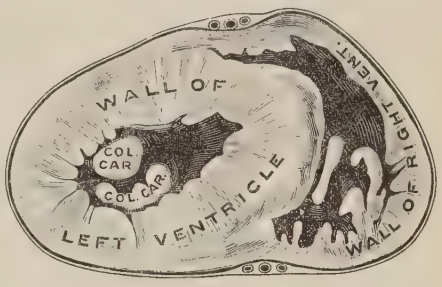

FIG. 446.—Cross-section through both ventricles, showing the shape of their cavities and the relative thickness of their walls. (Testut.)

The auriculo-ventricular openings and those of the pulmonary artery and the aorta are guarded by valves, which do not interfere with the passage of the blood in the course already described, but do serve to prevent a return of blood to a cavity from which it has been discharged.

The heart is situated in the lower part of the chest, toward the front, extending much farther to the left side than to the right. It lies obliquely, the auricles being at the right of and a little higher than the ventricles. The details of its situation will be given a little later.

The Right Auricle (Fig. 447), when viewed from the inside, presents a main chamber, the *atrium* ("hall"), and a little ante-chamber, the cavity of the *auricular appendix*, the latter being at the front and upper part of the auricle. A number of openings are seen. At the back the two *venæ cavæ* enter, the superior above, the inferior below. The floor of the atrium is largely formed by a trap-door, the tricuspid valve, which closes the oval *auriculo-ventricular opening*. Several *cardiac veins* of considerable size, returning blood from the substance of the heart itself, open directly into the cavity. The largest of these is called the *coronary sinus*, and enters between the inferior vena cava and the auriculo-ventricular orifice, its orifice being protected by a serous fold, the valve of Thebesius. There are also some very small veins, *venæ minimæ cordis* ("the least veins of the heart"), whose apertures, together with others of similar appearance, which are said to be blind depressions, have been named *foramina Thebesii* ("holes of Thebesius"). On the hind wall, which is the partition between the two auricles, is a shallow depression, the *fossa ovalis* ("oval pit"), bordered, except below, by a ridge, the *annulus ovalis* ("oval ring"). The fossa marks the site of a hole (*foramen ovale*), which exists in the *septum auricularum* ("partition of the auricles") in intrauterine life, and at birth becomes permanently closed by a flap of membrane. Various projections from the surface are observed, some

being muscular, others merely folds of endocardium. A network of muscular ridges covers the wall of the appendix, and on the right wall of the atrium is a series of vertical bands of nearly equal size, not inaptly named *musculi pectinati* ("comb-like muscles"). Connecting the margin of the inferior vena cava and the anterior edge of the annulus ovalis is a membranous fold, the *Eustachian valve*, which is prominent in proportion to the youth of the individual. In the fœtus it serves to guide the blood from the inferior vena cava through the foramen ovale of the septum into the left auricle. Between the openings of the venæ cavæ is an indistinct projection, the tubercle of Lower.

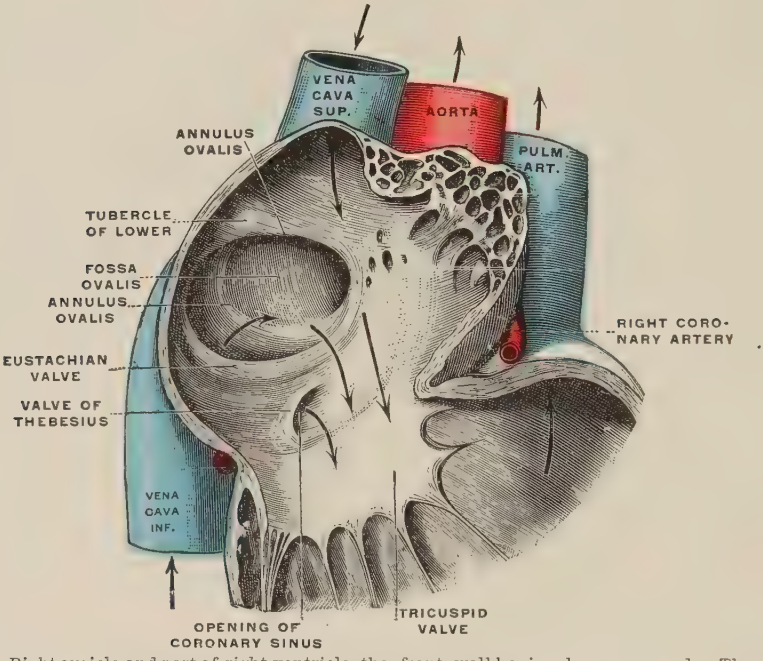

FIG. 447.—Right auricle and part of right ventricle, the front wall having been removed. The auricular appendix projects above at the right. The arrows indicate the direction of the blood-current. (Testut.)

The Right Ventricle has an irregular cavity, its wall being concave in front and convex behind, where the *septum ventriculorum* ("partition of the ventricles") presents. There are two large openings—the *auriculo-ventricular orifice*, and that of the *pulmonary artery*, the latter being at the apex of the *infundibulum*, a somewhat funnel-shaped portion of the chamber toward the left side. The auriculo-ventricular opening is closed by the *tricuspid valve*, so called from its three conspicuous segments. These are of unequal size and irregular shape, having ragged and frayed free edges, and between their attached borders frequently small secondary segments. One flap is at the left, one at the right, and one behind. They are composed of white fibrous tissue, and their attached borders are united to a fibrous ring, which encircles the orifice. At the junction of the pulmonary artery with the heart is the *pulmonary valve*, made up of three fibrous festoons of semilunar shape (Fig. 451). The free edge of each is marked at its middle by a nodule, the *corpus Arantii* ("body of Arantius"). The attached margin is strengthened by a ring of fibrous tissue. Behind each flap is an enlargement of the arterial bore, making a little recess, the *sinus of Valsalva*. Many large muscular prominences, *columnæ carneæ* ("fleshy columns"), are observed everywhere, except in the infundibulum (Fig. 448). Of these there are three kinds: those that are sculptured in high relief from the wall—attached at both ends and all of one side; those that are fastened at both ends and nowhere else; and those that have only one extremity secured to the wall. The last are known as *papillary muscles*, because they stand out like nipples, and they are arranged in two princi-

pal sets, anterior and posterior. From their summits project delicate tendons, *chordæ tendineæ*, which are inserted into the free edges and under sides of the flaps of the tricuspid valve. Running across the chamber obliquely is usually a prominent muscular beam, the *moderator band*.

Action.—When the muscular wall of the ventricle contracts, the cavity is practically obliterated, and its contents are discharged. As soon as contraction begins, the tricuspid valve is closed, and, were it not for the special restraining apparatus, its flaps would be swept into the auricle, and the greater part of the blood in the ventricle would go with them. But the papillary muscles come into action simultaneously with all other parts of the wall, and pull the valve downward exactly to the extent that the blood tends to push it upward beyond the plane at which the free margins of its segments come in close contact. Thus regurgitation is prevented, and the blood is forced through the only other avenue of escape, the pulmonary artery. The contraction of the ventricle ceasing, the distended artery has a tendency to return some of its contents to the ventricle; but, as soon as the column of fluid starts backward, the semilunar festoons, which have been flattened by the outrush of blood from the heart, are closed with a snap, the accumulation in the sinuses behind them giving the first impulse, and the pressure of the fluid in the artery completing the act. In this way not a drop is allowed to regurgitate. The columnæ carneæ of the first and second varieties are useful in regulating contraction and evenly distributing pressure, the moderator band being of especial service in preventing too great distention and in causing approximation of the opposite walls.



FIG. 448.—The three varieties of columnæ carneæ. (F. H. G.)

The Left Auricle presents fewer irregularities of internal surface than does the right (Fig. 449). The *musculi pectinati* are less numerous and less pronounced. Toward the rear on each side are the orifices of two *pulmonary veins*. The position of the fœtal foramen ovale is indicated by a slight indentation on the septal wall. The *auriculo-ventricular opening* is much like that in the right heart, but a little smaller. It is guarded by the bicuspid valve.

The Left Ventricle has a capacity equal to that of the right, but its cavity has a different shape, being ovoidal. In general features it strongly resembles the other ventricle. The three varieties of *columnæ carneæ* are present; but, while these muscular bundles are more numerous, they are of less size. The *papillary muscles* are disposed in two series. A band, similar to the moderator of the right ventricle, but much smaller, crosses the chamber. At the uppermost part of the septum anteriorly the wall is fibrous and very thin, constituting a weak area, sometimes called the *undefended space*. The auriculo-ventricular orifice and that of the aorta are very close together, the former being toward the rear, the latter near the front. The *auriculo-ventricular valve* is called *bicuspid*, on account of its having two chief segments, and *mitral*, because these flaps, when open, are somewhat suggestive of a bishop's mitre (Fig. 450). One segment lies close to the hind wall, the other and larger is between the two orifices. Frequently small secondary segments are found between the two great flaps. The valve is connected with papillary muscles by *chordæ tendineæ*, and in general features of structure is like the tricuspid, already described. The valve at the base of the aorta (Fig. 451) is a repetition of that of the pulmonary artery, except that in almost every respect its characteristics are more pronounced. The semilunar segments are situated

respectively in front, at the left behind, and at the right behind. From the sinus of the first of these is given off the *right* (anterior) *coronary artery*, and from that of the second the *left* (posterior) *coronary artery* springs. These vessels are

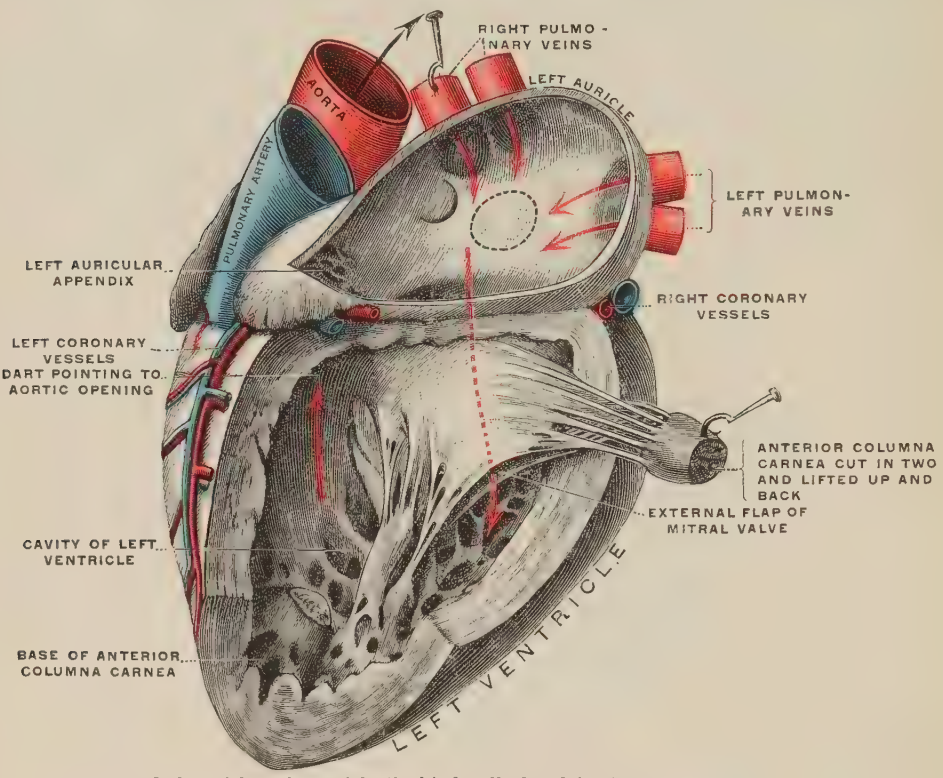

FIG. 449.—Left auricle and ventricle, the hind wall of each having been removed. (Testut.)

called coronary because they encircle the heart like the band of a crown. They are the first branches of the aorta, and feed the heart. Between the auriculo-

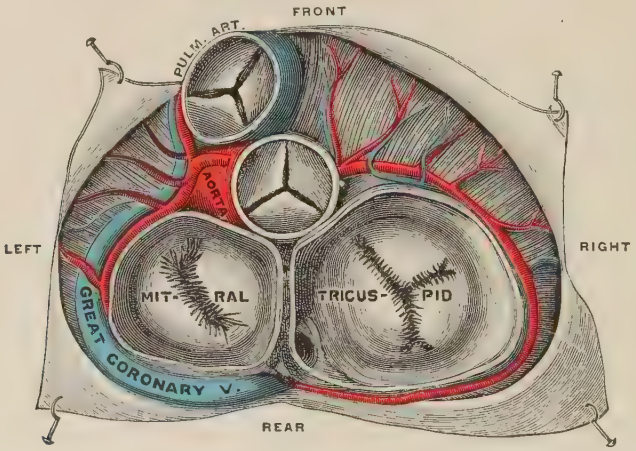

FIG. 450.—Valves of the heart and great arteries, viewed from above, the auricles having been removed. (Testut.)

ventricular and aortic orifices is a mass of mingled white fibrous tissue and white fibro-cartilage, from which are given off fibrous prolongations forming rings around the openings, and so stiffening their margins that stretching is prevented.

The *bulk* of the heart has been said to be approximately that of the fist of its owner; but to this rough-and-ready rule there are so many exceptions as to render it of little value. During life the diameters of the heart are constantly changing, and measurements made after death may be misleading. Its average length is about five inches, its width three and a half, and its thickness two and a half. It increases in weight and volume with rather unsteady progression to the end of life. Its average *weight* in the male is about eleven ounces; in the female it is somewhat less. Its *blood-vessels* are the coronary arteries and veins. It has numerous lymphatics. The *nerve-supply* is derived from the pneumogastric and from fibres of the cervical and thoracic ganglia of the sympathetic.

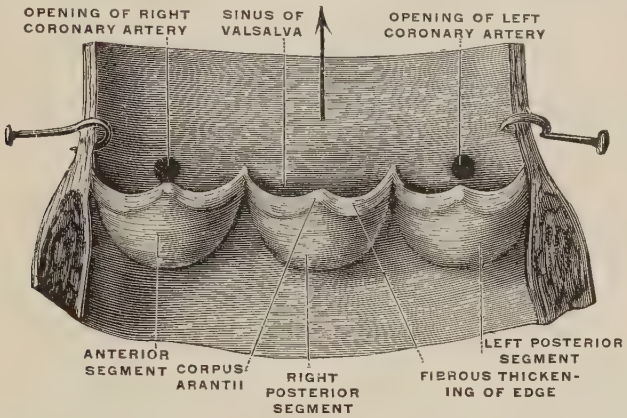

FIG. 451.—Aortic valve. The artery has been cut open between the anterior and left posterior segments, and spread out. (Testut.)

The External Configuration of the Heart.

The Grooves of the Heart.—The surface of the heart is marked by a series of grooves, which indicate the superficial limits of the various cavities.

Between the auricles and ventricles is the *auriculo-ventricular groove*, which is incomplete in front, where the anterior surface of the pulmonary artery is continuous with that of the right ventricle. This vessel occupies the broad ventral depression between the auricles—the *anterior interauricular groove*. The *posterior interauricular groove* lies between the right pulmonary veins and the portion of the right auricle which connects the superior and inferior venæ cavæ.

Between the ventricles are the interventricular grooves, which are continuous at the right of the apex of the heart. The *anterior interventricular groove* begins between the pulmonary artery and the left auricular appendix, and runs downward upon the ventral surface of the heart. The *posterior interventricular groove* starts at the left of the inferior vena cava, almost in continuation of the posterior interauricular groove, and courses forward upon the inferior surface of the organ. The grooves are occupied by vessels, embedded in adipose tissue.

The Surfaces of the Heart.—When the heart has been hardened while maintaining its natural relations with contiguous organs, it presents six surfaces, separated from one another by borders, which are defined with varying degrees of distinctness.

The Ventral Surface (Fig. 452) is slightly convex, irregularly quadrilateral, and looks forward and a little upward. It presents the front of the right ventricle, a part of the right auricle, of both appendixes, and of the left ventricle. The right (anterior) coronary artery is seen in the right auriculo-ventricular groove, giving off branches, of which the principal are the preventricular above, and the right (anterior) marginal below, the latter running to the left near the lower border. The anterior interventricular groove lodges a branch of the left (posterior) coronary artery and the great coronary vein. The ventral surface is

bounded by the ill-defined *right border*, which falls upon the convex surface of the right auricle; below by the *antero-inferior border*, which separates it from the inferior surface, and is so sharp that it is called *margo acutus*; on the left by the *left border*, on the marked convexity of the left ventricle; and above by the line of junction of the pulmonary artery with the heart, and by the upper margin of the appendixes.

The Dorsal Surface (Fig. 453) is irregularly convex, looks backward, and presents the greater part of the left auricle. Above are the horizontally directed primary divisions of the pulmonary artery, the right and left pulmonary arteries; at the right the posterior interauricular groove; below, the auriculo-ventricular

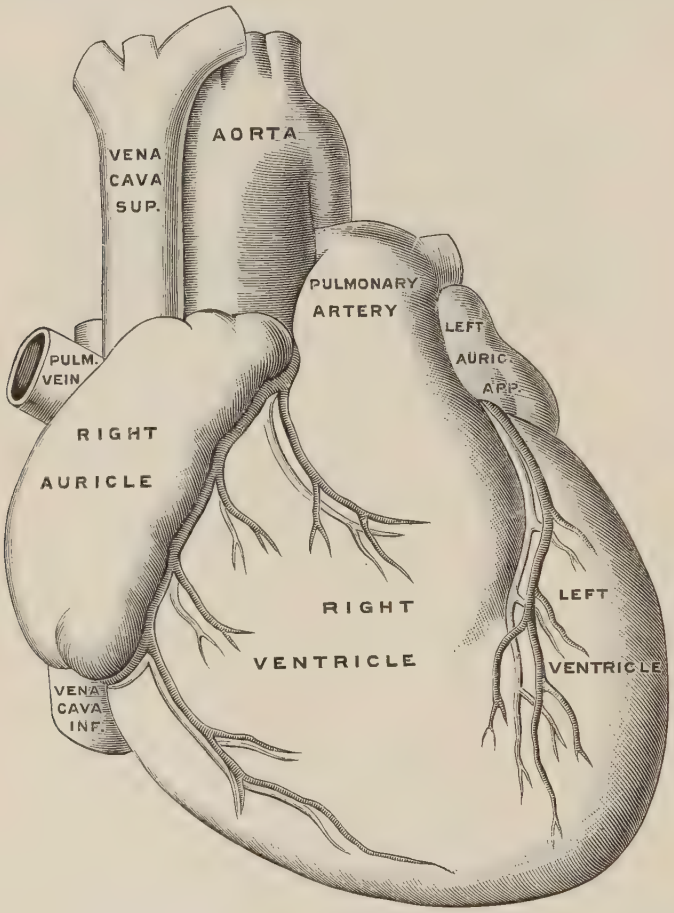

FIG. 452.—Front view of the heart. The auriculo-ventricular and anterior interventricular grooves and the vessels in them are not labelled, but cannot be mistaken. (From the His cast. F. H. G.)

groove; at the left a line leading downward from the left pulmonary veins, commonly marked by the oblique vein (of Marshall), which ends below in the coronary sinus.

The Right Surface is convex, quadrilateral, and exhibits nearly all of the right auricle which is not included in the ventral surface. At the postero-inferior angle the vena cava inferior enters, and the vena cava superior is seen above. Behind is the posterior interauricular groove; below, the auriculo-ventricular groove; and in front is the right border, already mentioned.

The Left Surface is unevenly convex and somewhat triangular. It presents above and behind a part of the left auricle, and in front of this a portion of its appendix; below, the left ventricle, tapering to the apex, and showing in the

midst of this space the marginal branch of the left coronary artery and the left marginal vein; and, between the auricle and ventricle, the great coronary vein.

The Inferior Surface is nearly flat, and looks downward and backward, conforming to the sloping upper surface of the anterior portion of the diaphragm. Here are seen parts of both ventricles, separated by the posterior interventricular groove, which lodges the interventricular branch of the right coronary artery and the middle cardiac vein; and at the back and right a small part of the right auricle and the aperture of entrance of the vena cava inferior.

The Upper Surface is small and irregular, and is occupied by the great vessels which form the bulk of the stem of the heart—the pulmonary artery, the aorta, and the vena cava superior.

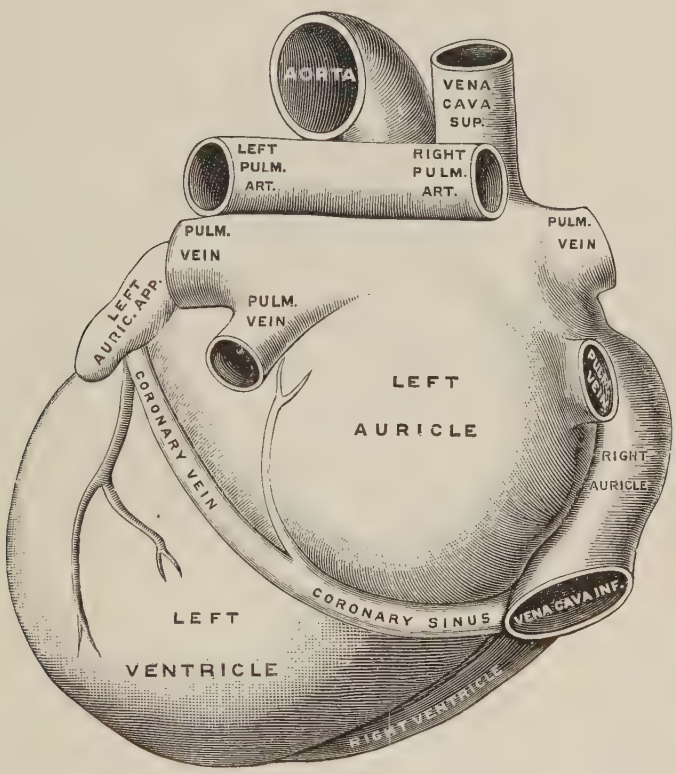

FIG. 453.—Rear view of the heart, showing the dorsal and inferior surfaces. (Modified from the His cast. F. H. G.)

The ventral, inferior, and left surfaces converge at the left anterior portion of the heart to a blunted point, called *the apex*. This is constituted entirely by the left ventricle, owing to the fact that the wall of this chamber is very much thicker than that of the right ventricle. The apex lies behind the space between the fifth and sixth costal cartilages, about three and a half inches from the middle line.

THE PERICARDIUM.

The *pericardium* ("around the heart") is the sac in which the heart is contained (Fig. 454). It consists of two parts: (1) an external, fibrous portion, and (2) an internal, serous portion.

The *fibrous bag*, composed mostly of white fibrous tissue, somewhat loosely encloses the heart, and is attached to various structures in the immediate neighborhood. Inferiorly it is firmly adherent to the diaphragm, with whose central

tendon its fibres are intermingled. It extends upward onto the great vessels for two inches or more, blending with their sheaths; and in this region it is also continuous with a downward prolongation of the cervical fascia. In front it is connected with the breast-bone by two fibrous bands, the *superior* and *inferior sterno-pericardial ligaments*; and the parietal pleuræ are adherent to its lateral surfaces.

The *serous membrane* furnishes a lining to the fibrous bag, and is thence reflected onto the contained organs, giving them a closely attached covering. The lining of the fibrous pouch is the parietal portion of the serous membrane, and

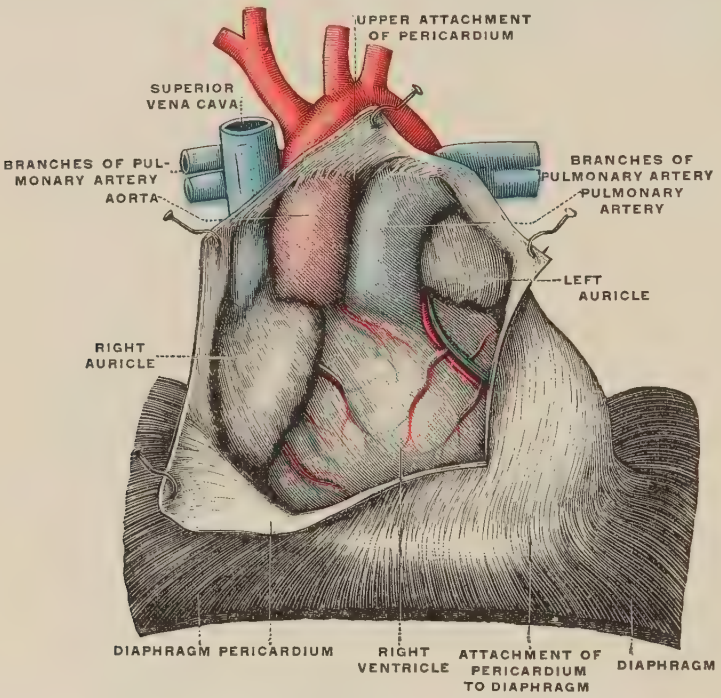

FIG. 454.—The heart *in situ*. The pericardium has been cut open in front, and reflected. (Testut.)

the clothing of the heart and vessels is the visceral portion, the latter sometimes being called the *epicardium* ("upon the heart"). Thus, the heart, which changes its position seventy times a minute all through life, is enabled to move with the least possible friction.

The pericardium does not completely encase all of the vessels attached to the heart. The aorta and pulmonary artery are enclosed in one sheath, the others are only partially covered. Many pouches of pericardium are found between the vessels at the lines of reflection of the membrane.

The *arteries* which supply the pericardium are the internal mammary, phrenic, pericardiac, œsophageal, and bronchial. Its *nerve-supply* comes from the pneumogastric, phrenic, and sympathetic.

THE SITUATION AND RELATIONS OF THE HEART.

The cavity of the thorax is divided into three unequal parts—two lateral, which are occupied respectively by the right and left lungs, each enveloped in its serous coat, the pleura; and a part between these, in which are lodged the remaining thoracic organs. This third portion is called the *Mediastinum* ("standing in the middle"). Ventro-dorsally the mediastinum extends between the

sternum and the vertebral column, laterally from the mesial surface of one pleura to that of the other, and vertically from the diaphragm to the upper opening of the thoracic cage, which aperture is outlined by the top of the sternum, the first ribs, and the first thoracic vertebra. The part of this space above the pericardium is the *superior mediastinum*, that in front of the pericardium is the *anterior mediastinum*, that behind the pericardium is the *posterior mediastinum*, and that occupied by the pericardium and its contents is the *middle mediastinum*. The pericardium is so close to the front wall of the chest that the anterior mediastinum has but little ventro-dorsal depth, and it contains no organs of much practical importance; but the superior and posterior mediastina hold the principal parts of many organs of the greatest moment, of which the chief are the trachea, the œsophagus, the great vessels connected with the heart, the vagus and other nerves, and the thoracic duct.

Enclosed in the pericardium the heart lies upon the diaphragm, fully two-thirds of its volume being to the left of the median plane of the body. Its base is directed to the right, upward and backward, its apex to the left downward and forward.

Its position with reference to the front wall of the thorax may be mapped out as follows: the apex being behind the fifth intercostal space, $3\frac{1}{4}$ or $3\frac{1}{2}$ inches from the middle plane, a line somewhat convex downward, drawn from this spot to the articulation of the seventh right costal cartilage with the sternum indicates its lower limit; a line drawn at the level of the upper border of the third costal cartilages from a point half an inch from the sternum at the right to a point an inch from the sternum on the left marks the upper limit; the dextral boundary is shown by a line convex to the right, connecting the right ends of these lines; and the remaining side of the figure is made by uniting the left extremities of the upper and lower lines by one that is somewhat convex to the left.

The *pulmonary valve* is behind the junction of the third left costal cartilage and the sternum; the *aortic valve* is behind the mesial end of the third left intercostal space; the *mitral valve* is behind the fourth left costal cartilage and the adjacent part of the sternum; the *tricuspid valve* is behind the middle line of the sternum, opposite the fourth intercostal space. The pulmonary value is the most superficial, the mitral the farthest from the surface.

The heart, enclosed in the pericardium, has *below* it the diaphragm; *in front*, between it and the sternum, the remains of the thymus gland, the anterior margin of the lungs with their pleuræ, the triangularis sterni muscle, the sterno-pericardial ligaments, the internal mammary vessels, and some areolar tissue; *above*, the great vessels; *laterally*, the lungs in their pleuræ, and the phrenic vessels and nerves; *behind*, the descending aorta, the bronchi, the gullet, the thoracic duct, the vagus nerves, and the vena azygos major. An irregular area on the front of the heart at the lower third of the gladiolus and extending about two inches to the left of it is not covered by the lungs during expiration; during inspiration this space is much diminished.

THE PHYSIOLOGICAL ANATOMY OF THE BLOOD-VESSELS.

Before one studies the systematic anatomy of the blood-vessels, it is important that he should know their physiological anatomy. The few succeeding pages, therefore, will be devoted to a presentation of the principal features of the structure of the different kinds of vessels, with especial reference to the relations between their histological composition and their functions.

The Arteries.

The arteries (*arteriæ*) are the tubes by which blood is carried away from the heart. The name etymologically conveys the idea that these vessels are air-bearers, the ancients regarding them as performing the function of distributing air to the tissues, because they contain no blood or other liquid after death. But although this belief was long ago exploded, the name is not altogether inappropriate, and may be considered a prophetic blunder; for physiology demonstrates that the blood in the arteries is laden with oxygen, which is the essential nourishing ingredient in the air, and the most important element in the income of the body.

The Coats of Arteries.—An artery has three coats—an inner, a middle, and an outer. The points of especial practical value about these tunics are as follows: the *inner coat* (tunica intima) is serous, like the lining of every other portion of the vascular system; the *outer coat* (tunica adventitia) is composed of white fibrous tissue, with its bundles arranged longitudinally; and between these two is the *middle coat* (tunica media), made up of plain muscular and yellow fibrous tissues (Fig. 455).

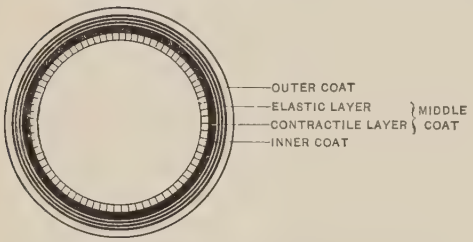

FIG. 455.—Diagram of a cross-section of an artery, showing the composition of its tunics. (F. H. G.)

While this statement of the structure of the arteries embraces the essential features of their physiological anatomy, a somewhat detailed description will not be out of place. The inner coat has three layers: an epithelial, consisting of flat, polygonal cells; a subepithelial, of white fibrous tissue, with sometimes yellow fibrous; and an elastic, of yellow fibrous tissue, closely reticulated. The middle coat is composed of plain muscular fibres, arranged crosswise in layers (Fig. 456), between which there is more or less yellow fibrous tissue. The outer coat, mostly of white fibrous, contains yellow fibres. Thus it appears that each tunic has some elastic tissue, the bulk of which, however, is an ingredient of the middle one.

FIG. 456.—Diagram of the arrangement of muscle-cells in an arteriole. (F. H. G.)

The Functions of the Arterial Coats.—The inner tunic by its smoothness reduces the friction of the blood-current to its lowest terms; the outer by its strength and toughness is protective; the middle by virtue of its elasticity enables the vessel to return passively to its average diameter after it has been distended, and on account of its contractility serves actively to reduce the bore of the tube to less than its average. The larger the artery the greater is the relative amount of yellow fibrous tissue; and the smaller the artery the greater the relative amount of muscular tissue. The relativity of the quantity of these ingredients should be carefully noted; for, while the comparative contribution of muscle to a minute artery is great, its absolute amount is very small. From these facts it may be inferred that the large arteries are very elastic and but slightly contractile; the small are highly contractile, and only feebly elastic; and those of medium size possess both of these attributes to a considerable extent, the one or the other predominating according to the degree of nearness to the distal or the proximal limits of the arterial system.

Vessels and Nerves of Arteries.—Outside of the artery is an enclosing *sheath* of areolar tissue, in which are situated the nerves and blood-vessels of the artery itself. These are called respectively *nervi arteriarum* and *vasa arteriarum*; but, as the veins are similarly provided, generic, instead of the above specific, names are more frequently used—*nervi vasorum* and *vasa vasorum*, respectively "the nerves of the vessels" and "the vessels of the vessels." In surgical operations

it is important to avoid unnecessary separation of the sheath from the artery, because the destruction of the feeding vessels of the latter deprives the part of its nourishment, and results in its death. The vasa vasorum are either branches of the artery which they supply, being given off a little distance above their areas of distribution, or else they are contributed by a neighboring artery.

The Branching of Arteries.—The arterial system is aptly compared to a tree, from whose trunk many large branches spring, each of these giving origin to smaller branches, and so on until the most diminutive twigs are reached. Various methods of branching are observed in arteries (Fig. 457). Often an artery

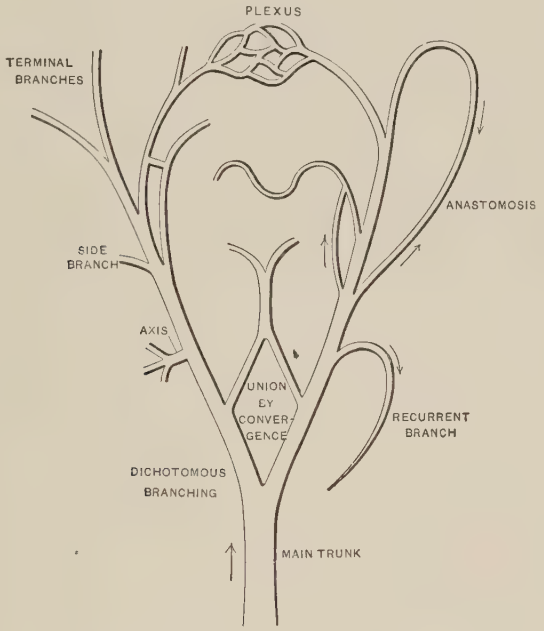

FIG. 457.—Diagram showing the branchings, anastomoses, and confluence of arteries. (F. H. G.)

divides into two terminal branches of nearly equal size, this method being called dichotomous, because the end of the vessel is split in two. Rarely an artery terminates in three approximately equal branches that diverge from the parent stem, which hence is called an *axis*. Most branches spring from the sides of an artery, and are, consequently, said to be given off in its course. These lateral branches usually form acute angles with their trunk, but sometimes right angles, and occasionally obtuse.

The *sectional area of an artery* is always less beyond the point at which a branch springs from it; but the combined sectional area of the immediate branches of an artery is always greater than that of the trunk from which they originate. Consequently, the capacity of the arterial system at any given distance from the heart exceeds that at any plane proximal to this, and thus there is vastly more blood in the smallest arteries (arterioles) than in the aorta and pulmonary artery, which receive the fluid directly from the heart.

Arteries generally pursue a course which is substantially straight or describes a generous curve; but some are serpentine, presenting a tortuous appearance, and this condition obtains in localities where the parts are liable to great changes of form, in some of which the vessel, if straight during quiescence, would be subjected to destructive stretching.

The *course of the blood* in the arteries is, as a rule, from centre to periphery; but exceptions occur, as in the case of the so-called recurrent arteries, which run backward, carrying the blood toward the heart. These vessels are frequent about

movable joints, and insure a plentiful supply of blood, when extreme flexion interferes with the direct and usual provision.

When the distal end of one artery is united to the end of another, so that the blood can flow in either direction, the arrangement constitutes an *anastomosis*, because the tubes are "mouth to mouth," and is also called an *inosculation*, which means "a kissing by mouths." Frequently a number of arteries form many and free inosculations within a limited area, thus making a network or *plexus*. Two arteries of equal size may unite, not by anastomosis, but to form a trunk, just as two venous radicles combine to constitute a larger vein. The vertebrals thus constitute the basilar artery.

The Capillaries.

At the periphery of the arterial system the vessels are microscopic, and consist of hardly more than the epithelium of the intima and a few scattered muscle-cells. When this imperfect contractile covering disappears, the vessel ceases to be an artery and becomes a capillary. The name *capillary* means hair-like; but these vessels are much finer than hairs, some of them having so narrow a lumen that a colored corpuscle of the blood cannot pass through it without being squeezed out of its normal shape. The length of a capillary is only a minute fraction of an inch. The wall of the tube is epithelial (Fig. 458), and is so thin that the materials of the blood pass through it into the spaces around the tissues, and the waste substances of the tissues traverse it in the opposite direction, and enter the blood. The capillaries are arranged in networks. The fineness of the vessels and the size and shape of the areas between them vary greatly. Thus, in the muscles the capillaries run between the fibres, and for the most part have a direction parallel with the fibres, the longitudinal being connected by obliquely crossing vessels, and enclosing long, narrow spaces, bounded by nearly straight lines; but in the air-vesicles of the lungs the capillaries are tortuous, very large, irregular, and so closely placed that the distance between them in some places is less than their own diameter. Some capillary vessels come from veins instead of arteries. For example, the interlobular branches of the portal vein give off the capillary plexus within the lobule, and from this the blood is collected by the intralobular vein.

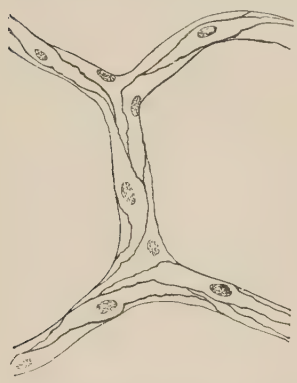

FIG. 458.—Capillaries, showing the shape and arrangement of the cells which make their wall. (Carpenter.)

The Veins.

The *veins* are vessels which conduct the blood from the periphery toward the centre of the vascular system. They begin where the capillaries end. As the loss of the last semblance of a middle coat changes an arteriole into a capillary, so the addition of a tunic, however scanty, to a capillary converts it into a *venule* ("little vein"). The venous system is comparable to the portion of a tree which is in the ground. It begins in rootlets at the distal end of the capillaries (Fig. 459). These minute veins are properly called *radicles* or *tributaries*, and the same terms are used to designate veins of any size, which by their confluence form a larger vessel. They are often called branches instead of radicles; but the term "branches" should be restricted to vessels resulting from division rather than from union. The desirability of the distinction is perceived in cases where a vein divides into two or more veins. The last are clearly branches of a parent stem, but, at the same time, are radicles of one or more veins nearer the heart.

The veins are more numerous than the arteries, and the capacity of the venous system is considerably greater than that of the arterial.

The veins have a structure, which in the main, is like that of the arteries; but there are such variations of detail that, in some respects, the two sets of vessels behave very differently. The *inner coat* is essentially like the arterial intima, with the addition of numerous transverse folds, which, strengthened by plates of white fibrous tissue, form *valves* (Fig. 460). The *middle tunic* is thinner than that of the arteries of comparable size, contains less muscle, more white fibrous, and only a little yellow fibrous tissue. The *external coat* is very like that of the arteries. This combination results in vessels which are very strong, capable of sustaining more strain than arteries without giving way, but so flabby that they collapse when emptied of

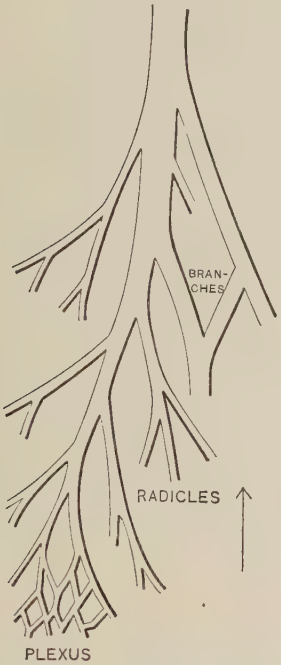

FIG. 459.—Diagram, showing the formation of large veins by convergence of small, and the branching of veins. (F. H. G.)

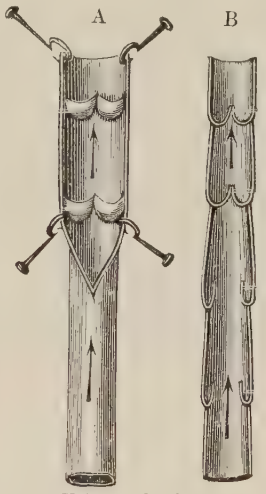

FIG. 460.—Valves of veins. A shows a vein cut open between the segments of two valves. B shows appearance of valves closed and open. (Testut.)

blood; whereas arteries, stiffened as they are with elastic and a large amount of muscular tissue, stand open in similar circumstances.

The *valves* are not found in all veins. They generally have two flaps each, which are directed toward the heart, when open. At the base of each valve the vein bulges, forming a *sinus*, into which the blood enters as soon as any obstruction to its flow occurs, and causes instant closure of the valve.

A few *exceptions* are found to the rule that capillaries intervene between arterioles and venules. In the interior of erectile organs small arteries may open directly into venous cavities; and in the spleen the arteries discharge into the interstices of the organ.

THE ARTERIES.

By A. D. BEVAN.

THE arteries are divided into two sets. One of these carries the vitiated blood from the right ventricle of the heart to the lungs, in which it gets rid of certain impurities and gains oxygen. This is the *pulmonary* ("lung") set. The other conveys nourishing blood from the left ventricle of the heart to the tissues throughout the body, and is called the *systemic* set.

The branches of the systemic arteries, as a rule, supply the structures among which they course; and, since this fact may be safely assumed, it is not always stated in the text. It may also be inferred that, where two or more arteries are distributed to the same region, an anastomosis occurs between their small branches.

While studying the arteries of a region, one will derive valuable assistance from a consultation of the figures of other structures in the same locality, particularly those in the chapters on the veins and the nerves. By pursuing this plan the relations of the parts will be much more readily comprehended.

THE PULMONARY ARTERY.

The **Pulmonary Artery** (Fig. 461) carries the venous blood from the right ventricle to the lungs. It arises from the upper and front part of the right ventricle, and passes upward, backward, and to the left for the distance of two inches, the vessel being contained in the pericardial cavity. Its termination is at a point beneath the transverse portion of the aorta opposite the fifth thoracic vertebra. Here it divides into the right and left pulmonary arteries.

Relations.—*In front* is the pericardium, superficial to which are the remains of the thymus, and the left pleura and lung, which respectively are behind the gladiolus and the sternal end of the second intercostal space. *Behind* its lower part is the ascending part of the arch of the aorta; higher up is the left auricle. *At the right* are the ascending part of the aortic arch, the right auricular appendix, and the right coronary artery. *At the left* are the pericardium, the left pleura, the left auricular appendix, and the left coronary artery.

The *right pulmonary artery* passes beneath the aortic arch to the right lung, and breaks up into three branches supplying the upper, the middle, and the lower lobes.

The *left pulmonary artery* passes in front of the descending aorta to the root of the left lung, and divides into two branches supplying the upper and lower lobes.

The pulmonary arteries carry venous blood to the lobules of the lungs, in which it experiences the changes produced by the function of respiration, the structure of the lungs being supplied with arterial blood by the bronchial arteries, branches of the thoracic aorta. The branches of the pulmonary arteries do not anastomose with each other—they are terminal arteries.

Passing from the pulmonary artery to the arch of the aorta is a fibrous cord, the remains of the *ductus arteriosus*, a vessel, which in the fœtal circulation

carries the blood sent through the pulmonary artery into the aorta. After birth this soon disappears; but, as an abnormality, it may persist.

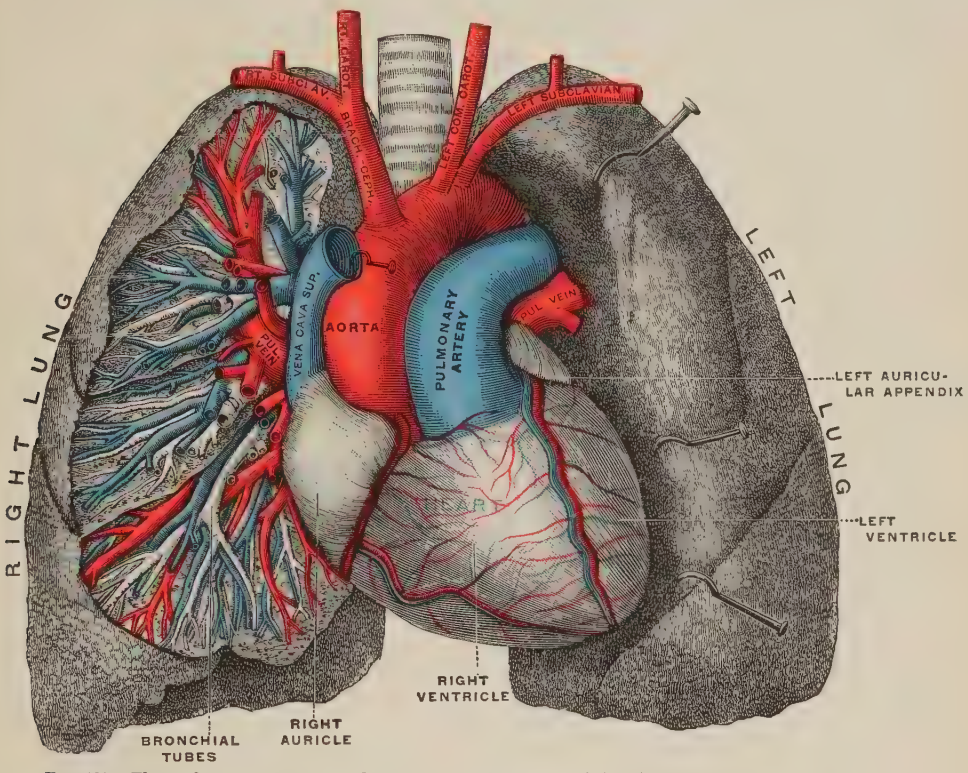

FIG. 461.—The pulmonary artery and aorta. The front part of the right lung has been removed, and the pulmonary vessels and the bronchial tubes are thus exposed. (Testut.)

THE SYSTEMIC ARTERIES.

The arteries of the systemic circulation all come directly or indirectly from the aorta. This great trunk will first be described, and afterward in regular sequence its branches will be traced to their ultimate destination. In this plan an orderly method will be pursued, and the origin, course, branches, distribution, and relations of each artery will be presented. Where important anastomoses occur, and variations from what is believed to be the normal are frequently observed, these facts will be noted.

THE AORTA.

General Description.—On leaving the left ventricle of the heart the aorta forms an arch, which extends backward to the vertebral column. Then the vessel runs downward on the bodies of the vertebræ to its termination at the fourth lumbar vertebra. In the artery itself there are no lines of demarcation separating it into distinct parts; but conventional divisions have been made for ease of description. The arch reaches to the lower border of the fifth thoracic vertebra; from this point to the aortic opening in the diaphragm the vessel is called the thoracic aorta; and all below that is known as the abdominal aorta. From each of these portions branches are given off. At its very beginning the aorta sends the coronary arteries to the heart. From the top of the arch spring three great vessels, which supply the head, the neck, the upper limbs, and a part of the thorax. From the thoracic aorta originate arteries which are distributed to the greater part of the parietes of the chest, and to all of its viscera, except-

ing the heart. The abdominal aorta supplies the diaphragm and the larger part of the walls of the belly, the viscera of the abdomen proper, and a part of those in the pelvis, and finally divides into two great vessels, which carry blood to the pelvic walls and viscera, to a part of the abdominal parietes, to the external genitals, and to the lower limbs.

The aorta is divided by some anatomists into an ascending aorta, an arch, and a descending aorta, the ascending aorta corresponding to the ascending portion of the arch in the description which is given here, the arch corresponding to the transverse portion of the arch, and the descending aorta beginning at the lower border of the fourth thoracic vertebra, and, therefore, including the descending portion of the arch in the division here adopted.

THE ARCH OF THE AORTA.

The arch (Fig. 461) is divided into three portions: the ascending, the transverse, and the descending.

The Ascending Portion of the Arch.

The *ascending portion*, two inches long, begins at the postero-superior part of the left ventricle, opposite the lower border of the left third costal cartilage, and behind the sternum. It passes upward and to the right to the level of the upper border of the second costal cartilage. At its origin it is enlarged and presents three bulges, the *sinuses of Valsalva*, each guarded by a semilunar flap of the aortic valve.

FIG. 462.—Horizontal section through the sixth thoracic vertebra—upper surface of the lower segment—showing the ascending portion of the aortic arch, and the thoracic aorta. (Braune.)

Relations (Fig. 462).—*In front* are the right auricular appendix and the pulmonary artery, below; the pericardium, the right pleura and lung, and the remains of the thymus gland, above. *Behind* are the left auricle, below; the right pulmonary artery, and the right bronchus, above. *At the right* are the right auricle, below, and the superior vena cava, above. *At the left* is the pulmonary artery.

The Transverse Portion of the Arch.

The *transverse portion* (Fig. 463), nearly two inches long, begins on a level with the upper border of the left second costal cartilage, curves with an upward convexity backward and to the left, and ends at the lower border of the fourth thoracic vertebra at its left side.

Relations.—*In front* are the left phrenic nerve, cardiac nerves from the vagus and sympathetic, the left vagus, the left superior intercostal vein, and vestiges of the thymus, all overlapped by the front borders of the pluræ and lungs. *Behind* are the trachea, the left recurrent laryngeal nerve, and the deep cardiac plexus,—the gullet and the thoracic duct being on a plane behind. *Above* are the left brachio-cephalic vein, and the beginning of the three great vessels which spring from the arch. *Below* are the bifurcation of the pulmonary artery, the left bronchus, the ductus arteriosus, bronchial lymph-nodes, the left recurrent laryngeal nerve, and the superficial cardiac plexus.

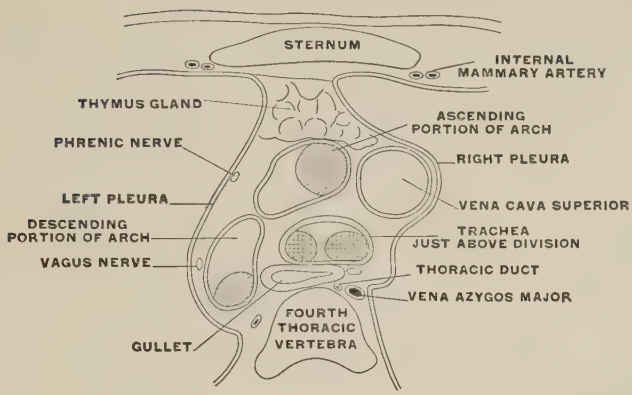

FIG. 463.—Horizontal section through the fourth thoracic vertebra—upper surface of the lower segment. The cut is made at the lower part of the transverse portion of the aortic arch. (Braune.)

THE DESCENDING PORTION OF THE ARCH.

The *descending portion* runs downward on the ventro-sinistral aspect of the body of the fifth thoracic vertebra and the cartilaginous disc above it. It has a markedly smaller diameter than the first portion on account of the great size of the vessels given off by the transverse portion.

Relations.—*In front* are the left pleura and the root of the left lung. *Behind* and at the right are the body of the fifth thoracic vertebra and the intervertebral disc above it. *At the right* are the gullet and the thoracic duct. *At the left* are the left pleura and lung.

THE THORACIC AORTA.

The *thoracic aorta* (Fig. 504) is situated in the posterior mediastinum. It begins at the lower border of the fifth thoracic vertebra on its left side and toward the front, and passes downward and mesially to the lower border of the twelfth thoracic vertebra in the middle line, conforming in its course to the curve of the part of the spinal column to which it is so closely applied.

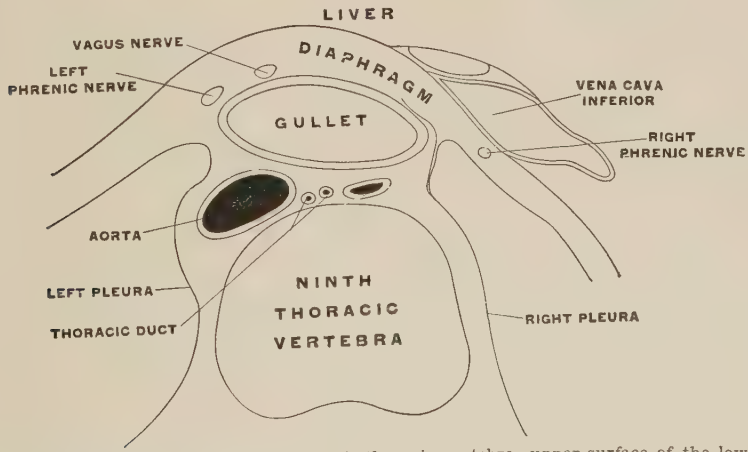

FIG. 464.—Horizontal section through the ninth thoracic vertebra—upper surface of the lower segment. (Braune.)

Relations (Figs. 462, 464, 465).—*In front* are the root of the left lung, the gullet, which crosses the artery from right to left, the pericardium, and, below, the diaphragm. *Behind* are the thoracic vertebræ and their intervertebral discs from the sixth to the twelfth, and the vena azygos minor. *At the right* are the

gullet, above, the thoracic duct, the vena azygos major, and the right pleura and lung. *At the left* are the left pleura and lung, and, below, the gullet.

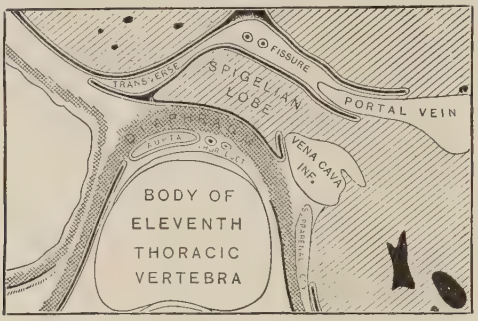

FIG. 465.—Horizontal section through the eleventh thoracic vertebra—upper surface of the lower segment. (Braune.)

THE ABDOMINAL AORTA.

The **abdominal aorta** (Fig. 505) begins at the lower border of the twelfth thoracic vertebra in the middle line, passes downward and slightly to the left, and ends on the ventro-lateral surface of the body of the fourth lumbar vertebra, bifurcating into the common iliac arteries.

Relations (Figs. 466, 467).—*In front* are the solar plexus, the splenic vein, the pancreas, the left renal vein, the third portion of the duodenum, the aortic plexus, in order from above downward; small intestines, and the median lumbar lymph-nodes. *Behind* are the upper four lumbar vertebræ and their fibro-cartilages, the left crus of the diaphragm, and the left lumbar veins. *At the right* are the right crus, the vena cava inferior, the receptaculum and the thoracic duct, the right semilunar ganglion, and the vena azygos major. *At the left* are the left crus, the left semilunar ganglion, the pancreas, and small intestines.

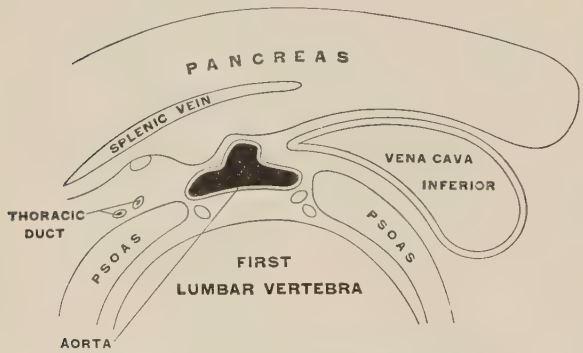

FIG. 466.—Horizontal section through the first lumbar vertebra—upper surface of the lower segment. (Braune.)

Variations.—The arch of the aorta varies as regards the height to which it rises, the direction in which it runs, and its conformation. There are also many cases of deviation from the normal in the number, position, and arrangement of the branches from the transverse position. It is unnecessary, however, from the practical point of view to specify these variations in detail. The ductus arteriosus may persist as a vessel. The thoracic and abdominal portions of the aorta are much less subject to variations than is the arch. The thoracic is sometimes obliterated just below the arch, in which case the blood reaches the parts below by means of a collateral circulation through branches of the great vessels of the arch, which anastomose with recurrent branches from the abdominal aorta. The last named may bifurcate a little lower than usual, or a great deal higher, possibly at the level of the second lumbar vertebra.

Branches.—The vessels which arise from the aorta will be considered in the order of their origin.

The **branches of the arch** are the right coronary and the left coronary arteries, which are given off from the ascending portion, and the brachio-cephalic, the left

common carotid, and the left subclavian arteries, which arise from the transverse portion.

The **Right Coronary Artery** (Fig. 452) arises from the anterior sinus of Valsalva, winds to the right in the auriculo-ventricular groove to the posterior interventricular groove, where it divides into two branches, one of which continues in the auriculo-ventricular groove, while the other descends in the interventricular.

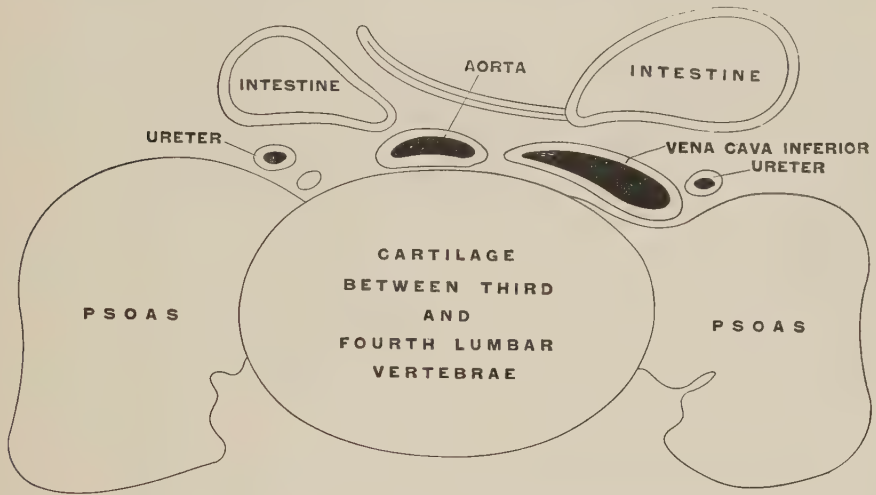

FIG. 467.—Horizontal section between the third and fourth lumbar vertebræ—upper surface of the lower segment. (Braune.)

The **Left Coronary Artery** (Fig. 452) springs from the left posterior sinus of Valsalva, runs forward behind the pulmonary artery and bifurcates,—one branch descending in the anterior interventricular groove to the apex, the other running backward in the auriculo-ventricular groove, and anastomosing with the right coronary.

The coronary arteries supply the heart and the contiguous portions of the aorta and pulmonary artery. They are called "coronary," because they encircle the heart like a crown ("corona").

The brachio-cephalic, the left common carotid, and the left subclavian arteries arise from the top of the arch in the order given; and as the arch extends backward and to the left, the brachio-cephalic is nearest the front, the left subclavian farthest from the front, and the left common carotid between the two, and somewhat nearer the brachio-cephalic.

THE BRACHIO-CEPHALIC ARTERY.

The *brachio-cephalic* ("arm-head") *artery* (Fig. 461), often called *innominate*, as if it had no name, is from an inch and a half to two inches long. It springs from the arch of the aorta opposite the upper border of the second costal cartilage on the right side, passes upward and to the right in front of the trachea, and ends behind the top of the sterno-clavicular joint, there dividing into the right common carotid and right subclavian arteries.

Relations (Fig. 468).—*In front* of its lower part are the left brachio-cephalic and right inferior thyroid veins, and higher up the sterno-hyoid and sterno-thyroid muscles, and cardiac nerves from the right vagus. *Behind* its lower part is the trachea, behind its upper part the right pleura and lung. *At the right* are the right brachio-cephalic vein, the right vagus nerve, and the right pleura and lung. *At the left* are the left common carotid artery, the left inferior thyroid vein, and the trachea.

Variations.—The brachio-cephalic may be absent, the right common carotid and subclavian springing directly from the aorta. It may be longer or shorter than usual—less than an inch, or more than two inches in length.

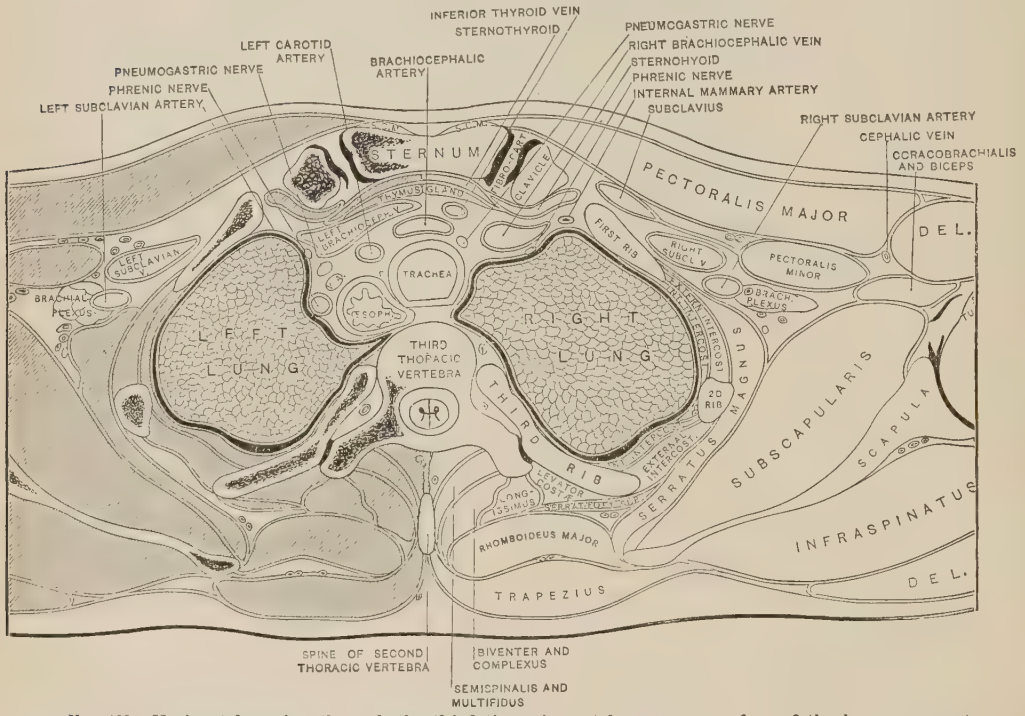

FIG. 468.—Horizontal section through the third thoracic vertebra—upper surface of the lower segment—showing the relations of the brachio-cephalic artery. (Braune.)

Branches.—In addition to the terminal branches, the right common carotid and right subclavian, the brachio-cephalic occasionally gives off a branch, the *thyroidea ima*, which passes upward on the surface of the trachea to the isthmus of the thyroid.

THE COMMON CAROTID ARTERY.

The name "carotid" is derived from a Greek word, signifying "to produce sleep," and was applied to certain arteries because they were supposed to be concerned in the causation of sleep.

The *common carotid arteries* (Fig. 470) differ upon the two sides. The right takes its origin from the brachio-cephalic, the left from the arch of the aorta; the left is, therefore, the longer of the two. In the neck the common carotids are so nearly alike that one description will answer for both. It will be necessary, however, to describe that portion of the left carotid which extends from the arch to the level of the sterno-clavicular articulation.

The Left Carotid Artery in the Thorax.

This portion resembles somewhat the brachio-cephalic artery in length and in its relation to surrounding structures. Arising from the arch of the aorta close to the brachio-cephalic, it passes upward and sinistrally behind the manubrium and the anterior margin of the left lung to the level of the left sterno-clavicular joint.

Relations.—*In front* are the remains of the thymus gland, and the left brachio-cephalic vein—the latter low down. *Behind* are the trachea, gullet, thoracic duct,

and left recurrent laryngeal nerve. *At the right* are the brachio-cephalic artery below, and the trachea and left inferior thyroid vein above. *At the left* are the left lung with its pleura, and the left subclavian artery and left vagus nerve—the last two being somewhat at the rear.

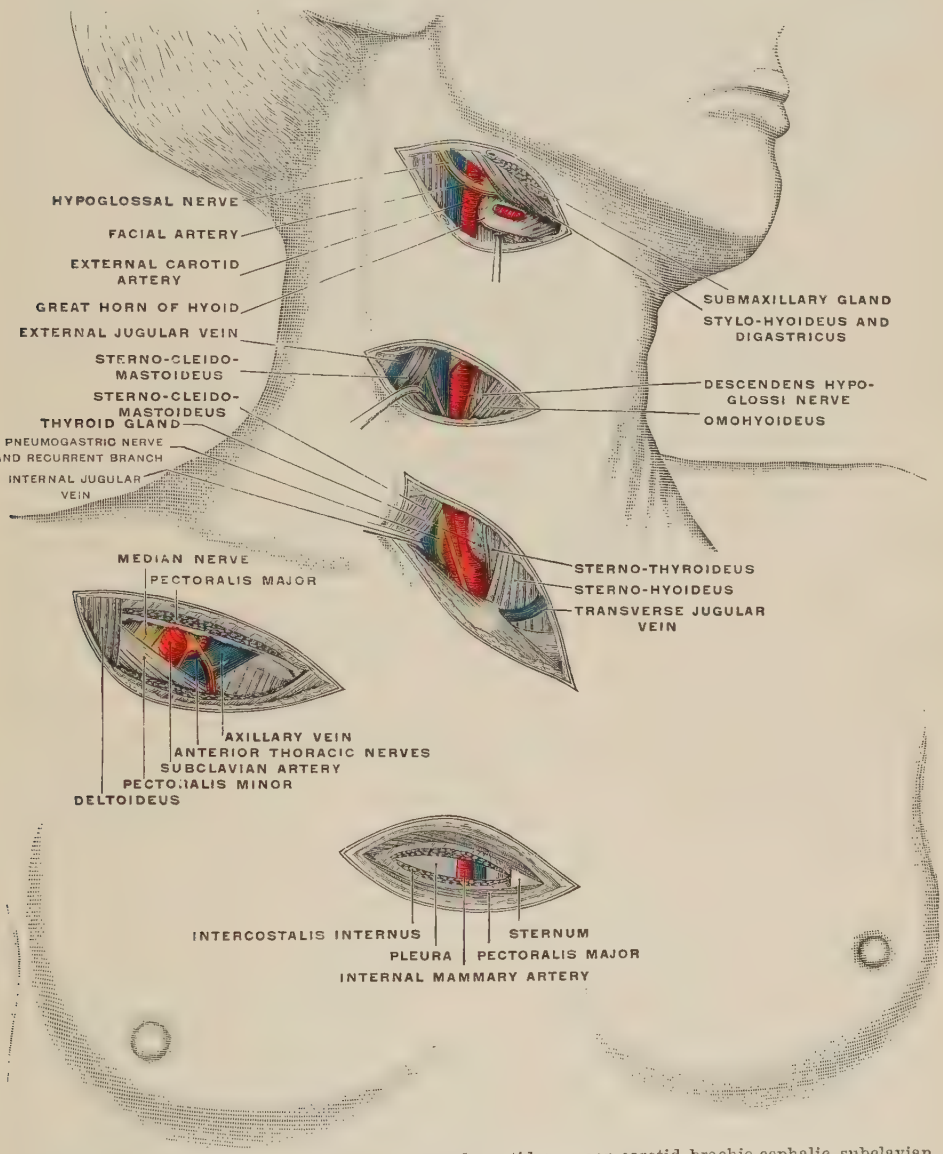

FIG. 469.—Surgical relations of the lingual, external carotid, common carotid, brachio-cephalic, subclavian, and internal mammary arteries. (Kocher.)

The Common Carotid Artery in the Neck.

The common carotid in the neck begins behind the sterno-clavicular articulation, passes upward and outward in a direction indicated by a line drawn from its origin to a point midway between the angle of the jaw and the mastoid process, and ends at the level of the upper border of the thyroid cartilage by bifurcating into the external and internal carotids. It is overlapped by the sterno-cleido-mastoid muscle, the inner border of which is the guide to its course. It is

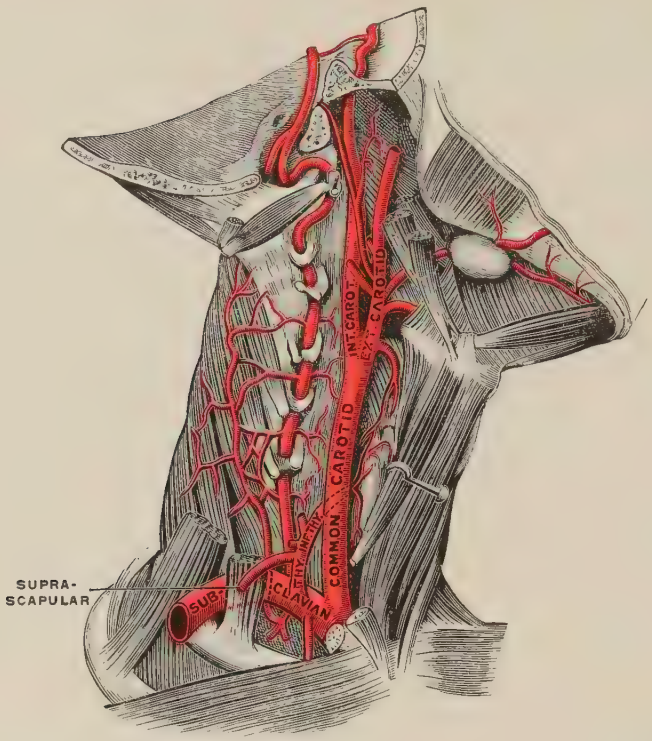

FIG. 470.—Right subclavian and carotid arteries. The vertebral artery is seen threading the costo-transverse processes of the vertebræ. (Testut.)

enclosed in a sheath which is common to it, the internal jugular vein, and the vagus nerve. It is deeply situated at first, but is much nearer the surface in its upper part.

Relations (Fig. 471).—*In front* is the sterno-cleido-mastoid throughout; below are the sterno-hyoid and sterno-thyroid, the thyroid gland, and the anterior

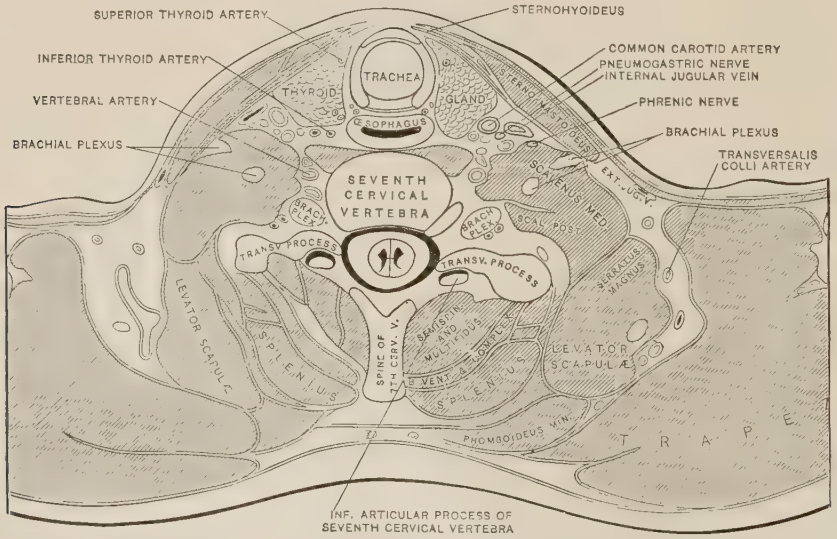

FIG. 471.—Horizontal section through the seventh cervical vertebra—upper surface of the lower segment—showing the relations of the common carotid. (Braune.)

jugular vein; opposite the cricoid cartilage is the omo-hyoid; above are the superior and middle thyroid veins, the sterno-mastoid artery, and the descendens

hypoglossi nerve—the last either upon or inside of the sheath. *Behind* are the sympathetic nerve; the longus colli, the inferior thyroid artery, and the recurrent laryngeal nerve below; the rectus capitis anterior major above; the vagus nerve is dorso-external to the artery. *On the outer side* is the internal jugular vein, and the vagus nerve behind and between the artery and vein. *On the inner side* are the trachea, thyroid gland, recurrent laryngeal nerve, and inferior thyroid artery below; the larynx and pharynx above.

Variations.—The right common carotid sometimes springs directly from the arch of the aorta; sometimes the left common carotid springs from a left brachio-cephalic artery; the common carotid is sometimes absent, the internal and external carotids springing directly from the arch of the aorta or from a brachio-cephalic artery. In some cases it divides above or below the usual point, low down in the neck, or as high as or higher than the hyoid bone.

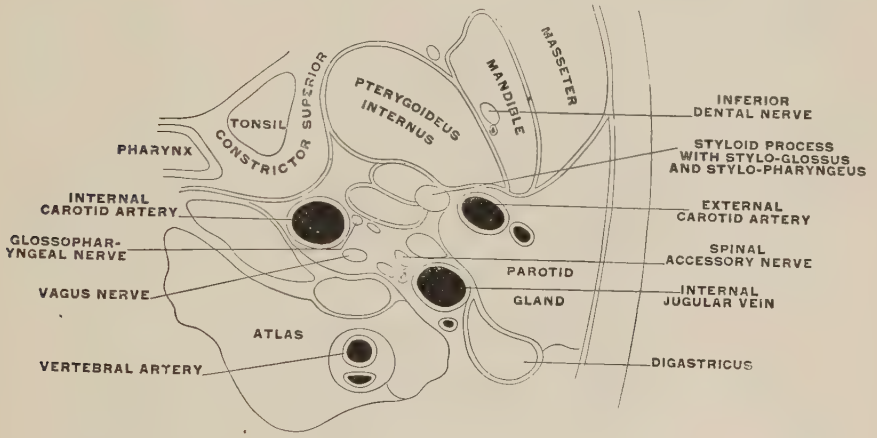

FIG. 472.—Section of the head from the mouth backward and a little upward—upper surface of the lower segment. The internal and external carotids of the right side are shown. (Braune.)

Branches.—The common carotid, as a rule, does not give off any branches in its course; in rare cases it gives off a superior or an inferior thyroid or the vertebral artery. The terminal branches are the internal carotid and the external carotid.

The External Carotid Artery.

The **External Carotid** (Figs. 470, 473), a terminal of the common carotid, begins opposite the upper border of the thyroid cartilage, runs upward and a little backward to a point between the neck of the condyle of the mandible and the external auditory meatus, where, in the substance of the parotid gland, it bifurcates into the internal maxillary and temporal arteries. It is overlapped by the inner border of the sterno-cleido-mastoid muscle in a large part of its course.

It supplies the ventral part of the neck, the superficial and deep parts of the face, the scalp, the dura, and the bones between these, the pharynx, and the external and middle ears.

Relations (Fig. 472).—*In front* are the hypoglossal nerve, the lingual and facial veins below, the digastric and stylo-hyoid muscles at a higher level, the parotid gland, facial nerve, and internal pterygoid muscle above. *Behind* are the internal carotid artery at its origin, the superior laryngeal nerve in the lower part, the stylo-glossus, stylo-pharyngeus, and glosso-pharyngeal nerve at a higher level, and the parotid gland above. *At the inner side*, from below upward, are the hyoid, pharynx, and parotid gland, with the styloid process mesially.

Variations.—The external carotid may arise above or below its usual point. Sometimes the artery arises from the aortic arch. Occasionally the external carotid is altogether absent, the common carotid not dividing into the internal and external carotids, but supplying from a common trunk the branches usually arising from these vessels.

Branches.—The external carotid, in addition to its two terminal branches, the internal maxillary and the temporal, gives off three anterior branches, the superior thyroid, the lingual, and the facial; two posterior branches, the occipital and the posterior auricular; and one internal branch, the ascending pharyngeal.

The *Superior Thyroid Artery* (Fig. 470).—This artery is named from its being the upper of the two vessels that supply the thyroid gland. It comes off from the external carotid close to its origin, runs upward and inward, and then downward and forward to the upper part of the thyroid gland.

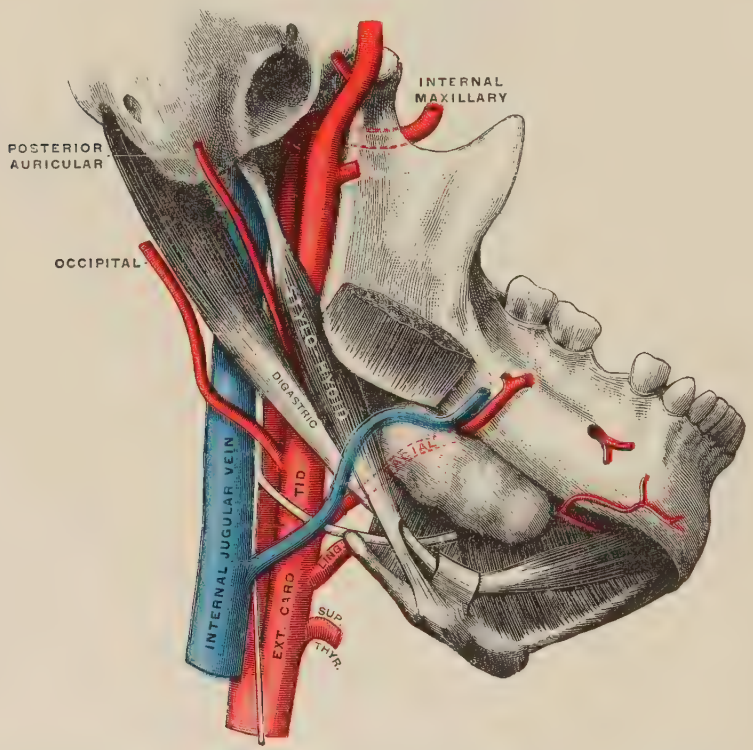

FIG. 473.—The external and internal carotid arteries. The hypoglossal nerve, the digastric and stylo-hyoid muscles, and the internal jugular vein are to be noted. (Testut.)

Relations.—The superior thyroid at its origin is superficially situated and covered by the skin, superficial fascia, platysma, and deep fascia; before it reaches the thyroid gland it becomes more deeply situated by passing beneath the omo-hyoid, sterno-hyoid, and sterno-thyroid muscles.

Variations.—The superior thyroid is sometimes given off as a branch of the common carotid, and sometimes as a branch of a trunk from the external carotid, common to it and the lingual or facial.

Branches.—*Muscular* branches are given off to the omo-hyoid, sterno-hyoid, sterno-thyroid, and the inferior constrictor of the pharynx. *Glandular* are supplied to the thyroid gland. The *hyoid* runs along the lower border of the hyoid bone, and gives twigs to the parts just below. The *sterno-mastoid* branch passes outward and downward, and is distributed to the muscle whose name it bears, and

to the platysma and skin. The *superior laryngeal* accompanies the superior laryngeal nerve in its distributton to the interior of the larynx, passing with the nerve through the thyro-hyoid membrane, and supplying the mucous membrane and muscles of the larynx. The *crico-thyroid* artery runs inward on the surface of the crico-thyroid membrane, to the crico-thyroid muscle and the interior of the larynx.

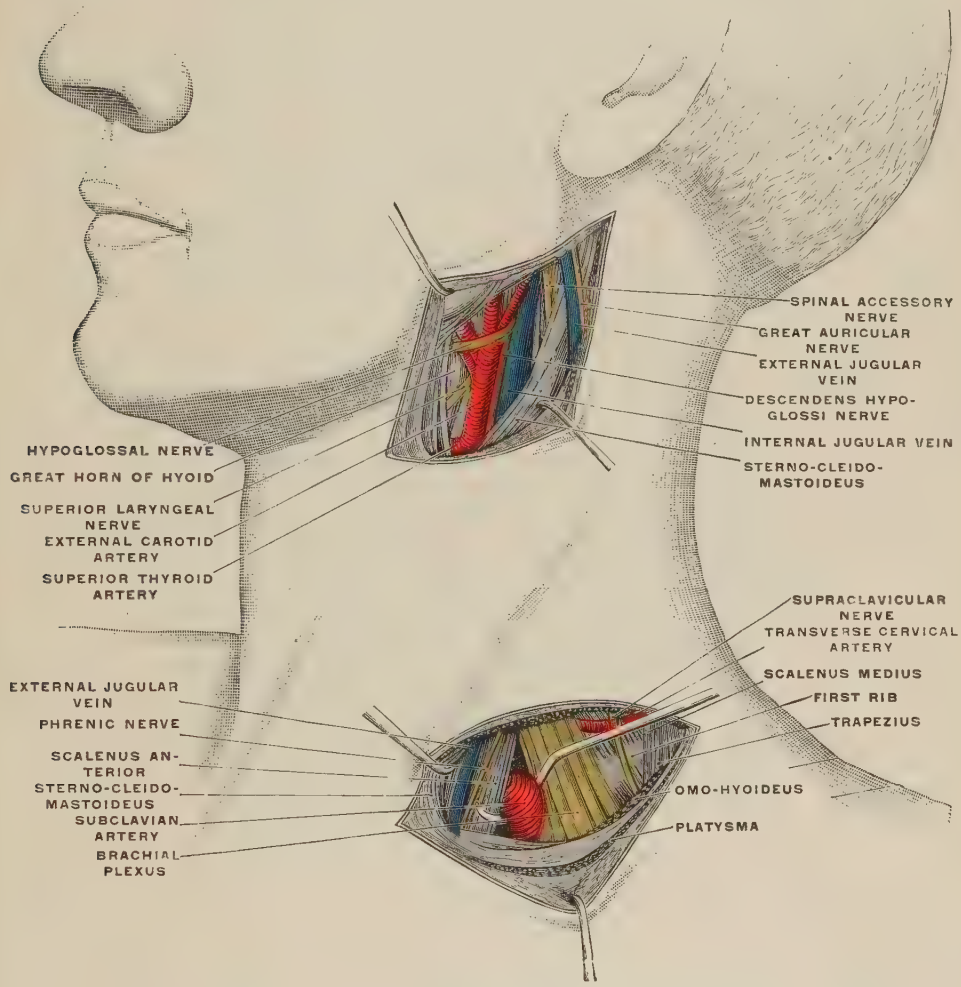

FIG. 474.—Surgical relations of the external carotid, lingual, facial, occipital, subclavian, and transverse cervical arteries. (Kocher.)

The Lingual Artery (Fig. 475).—It springs from the external carotid above the superior thyroid and a little below the hyoid bone, runs along the upper border of the great cornu of the hyoid, then leaves the bone, passes to the base of the tongue, and courses along its under surface, terminating as the ranine artery.

Relations.—The artery is at first superficial, then passes beneath the digastric and hyoglossus muscles, and has in front of it the hypoglossal nerve; later it is situated in the base of the tongue between the hyoglossus and genio-hyoglossus muscles; it then, as the ranine becomes again superficial, being covered only by the mucous membrane of the inferior surface of the tongue.

Variations.—The lingual artery is sometimes a branch from a trunk of the external carotid common to it and the facial, or to it and the superior thyroid; or the three vessels may arise from a common trunk.

Branches of the lingual are the hyoid, dorsal lingual, sublingual, and ranine.

The *hyoid* runs along the upper border of the hyoid bone, and is distributed to adjacent muscles. The *dorsal lingual* runs upward to the mucous membrane of the dorsum of the tongue, which it supplies, together with the tonsil and soft palate. The *sublingual* supplies the sublingual gland, the neighboring muscles, and mucous membrane. The *ranine* gives off branches to the muscles of the tongue, and runs in a tortuous course to its tip, being in the last part of its course superficial, covered only by the mucous membrane.

The Facial Artery (Fig. 476) arises from the anterior surface of the external carotid above the hyoid bone, and passes upward and forward to the inferior border of the lower jaw. In its course it is covered and partly surrounded by the submaxillary gland, so that the vessel occupies a groove on its deep surface. The artery winds over the body of the lower jaw in front of the masseter muscle, marking the bone in this position by a shallow groove. It then passes upward and forward on the face to the side of the nose, and then upward to the inner canthus of the eye, where it terminates as the *angular* artery.

Relations.—At its point of origin the vessel is superficial, being covered by the skin, superficial fascia, platysma, and deep fascia; it then passes beneath the

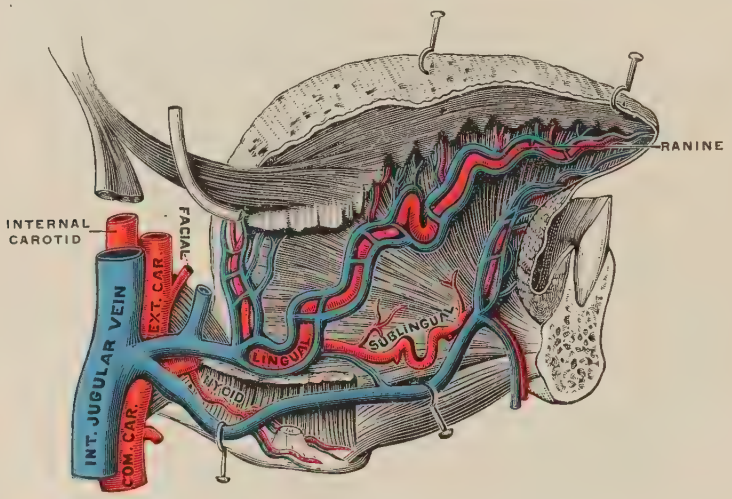

FIG. 475.—Arteries and veins of the tongue, viewed from the right side. (Testut.)

stylo-hyoid and digastric muscles and the submaxillary gland, and is deeply situated. At the border of the jaw the vessel again becomes superficial, and its pulsations can be readily felt in front of the masseter. In the face it passes among the fasciculi of the facial muscles adjacent to it.

Variation.—The variation most commonly met with is the occurrence of a trunk from the external carotid, common to the facial and lingual arteries.

Branches.—The branches of the facial are divided into two sets, a *cervical set* and a *facial set.*

In the cervical region the facial gives off the ascending palatine, the tonsillar, the glandular, the submental, and the muscular. The *ascending palatine* passes to the outer side of the pharynx, which it supplies; it also sends a branch to the soft palate, and anastomoses with the descending palatine artery, a branch of the internal maxillary. The *tonsillar* is a branch to the tonsil and tongue. The *glandular* are branches given off to the submaxillary gland. The *submental* is a large branch which runs along the lower border of the jaw to the chin; here the vessel gives off terminal branches, which wind over the jaw, and supply the tissues of the lower lip. *Muscular* branches are given off to the muscles with which the vessel is in contact. The *facial branches* are the inferior labial, the coronary, the

lateral nasal, the angular, and muscular. The *inferior labial* runs parallel with the body of the jaw forward to the chin; it supplies the tissues of the chin and lower lip. The *coronary* arteries are given off at the angle of the mouth, and run, one in the tissues of the lower lip, the other in the tissues of the upper lip, in close contact with the mucous membrane, sending branches to the ala and septum of the nose. The *lateral nasal* supplies the ala and dorsum of the nose. The *angular* is the terminal branch of the facial. It ascends to the inner canthus of the eye, and supplies the structures in this position, anastomosing with the infra-orbital, and with the nasal branch of the ophthalmic artery.

The Occipital Artery (Fig. 476) arises from the external and posterior surface of the external carotid, opposite the facial, at a point a little above the level of the hyoid bone. It winds upward and backward to the mastoid portion of the

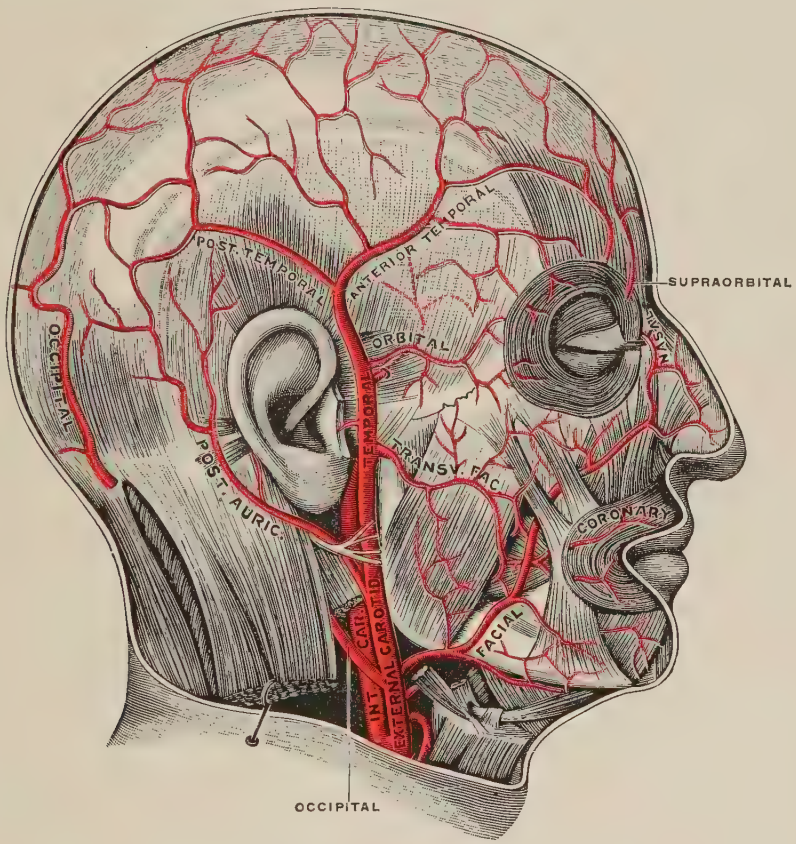

FIG. 476.—Superficial arteries of the head. (Testut.)

temporal bone, occupying a groove on its inferior surface. The vessel is here covered by the digastric and stylo-hyoid muscles, and crosses the internal carotid, the internal jugular vein, and the vagus nerve; it then continues upward and backward beneath the muscles attached to the superior curved line of the occiptal bone and the space between this and the inferior curved line, becomes superficial by piercing the trapezius or the fascia between the occipital attachments of the trapezius and sterno-cleido-mastoid, and then runs forward in the scalp tissue to the vertex of the skull, anastomosing with the branches of the temporal and posterior auricular.

Variations.—The occipital is in rare cases a branch of the internal carotid; sometimes it is given off from the inferior thyroid.

Branches.—The muscular, the sterno-mastoid, the posterior auricular, the

meningeal, the arteria princeps cervicis, and the terminal. *Muscular* branches are given off to the muscles with which it is in contact; one large muscular branch, the *sterno-mastoid*, is distributed to the sterno-cleido-mastoid, and is here accompanied by the spinal accessory nerve. The *auricular* branch supplies the posterior portion of the external ear. The *meningeal* branch is one of the posterior meningeal arteries, and enters the skull through the jugular foramen. The *arteria princeps cervicis* passes downward, and, deeply situated, divides into two sets of branches, one anastomosing with the deep cervical branch of the superior intercostal artery, the other with the superficial cervical branch of the transverse cervical. The *terminal* branches are distributed to the soft parts of the occipital region.

The Posterior Auricular Artery (Fig. 476) springs from the posterior surface of the external carotid, passes upward and backward beneath the parotid gland to a groove between the external meatus and the mastoid process, where it divides into two branches: the *mastoid*, supplying the scalp-tissue over the mastoid process, and anastomosing with the occipital; and an *auricular*, supplying the back of the ear, and anastomosing with branches of the temporal.

Variations.—The posterior auricular artery is sometimes a branch of the occipital. On the other hand, it is sometimes a vessel much larger than the occipital, being distributed to the region usually supplied by the occipital and temporal arteries.

Branches.—In addition to the two terminal branches, the auricular and mastoid, already sufficiently described, the artery gives off a *stylo-mastoid* branch, which enters the stylo-mastoid foramen, and supplies branches to the mastoid cells, tympanum, and internal ear.

The Ascending Pharyngeal Artery arises from the dorso-mesial surface of the external carotid, within half an inch of its origin from the common carotid, runs upward on the side of the pharynx and, covered by the internal carotid artery, to the base of the skull.

Variations.—The ascending pharyngeal may be a branch of the internal carotid or common carotid.

Branches.—The branches of the ascending pharyngeal are the prevertebral, the pharyngeal, the palatine, the tympanic, and the meningeal. The *prevertebral* branches supply the anterior recti and the longus colli muscles, and the nerves and lymph-nodes of this region. The *pharyngeal* branches supply the pharynx, tonsil, and soft palate. The *palatine* is distributed to the velum pendulum. The *tympanic* runs to the inner wall of the drum of the ear. The *meningeal* are several small vessels entering the skull through the jugular foramen, the anterior condylar foramen, and the foramen lacerum medium, and distributed to the dura.

The Temporal Artery (Fig. 476) (*superficial temporal*) is one of the terminal branches of the external carotid, and begins at a point a little below the condyle of the jaw. It passes upward through the substance of the parotid gland external to the zygoma, to a point from an inch and a half to two inches above the zygoma, and here divides into the anterior and posterior temporal arteries.

Variations.—The temporal artery is not frequently subject to variations from the usual type. It may be very small, and its place be taken by a large posterior auricular. The transverse facial may be of large size and take the place of a small facial artery.

Branches.—The branches of the temporal are its terminals, the anterior temporal and the posterior temporal, and the transverse facial, the middle temporal, the orbital, and the anterior auricular. The *transverse facial* (Fig. 448) is given off close to the point of origin of the temporal, passes forward across the face beneath the zygoma, on the surface of the masseter, and supplies the parotid gland, the masseter, and the skin of the face. The *middle temporal* is given off anteriorly, perforates the temporal fascia, and supplies the temporal muscle, anastomosing with the deep temporal branches of the internal maxillary. The *orbital* runs forward on the upper border of the zygoma to the orbit, supplying the orbicularis palpebrarum. The *anterior auricular* branch is distributed to the

anterior surface of the external ear. The *anterior temporal* winds forward and upward over the frontal bone, and supplies the scalp structures. In this position the artery is very superficially situated; its pulsations can be readily felt and often seen. The position of the artery is such that, in giving an anæsthetic the anæsthetizer can from this vessel feel the condition of the pulse. The *posterior temporal* passes backward and upward superficially in the scalp to the vertex of the skull, supplying the scalp in this region, and anastomosing with the occipital, the posterior auricular, and the vessel of the opposite side. Besides these principal branches smaller ones are given off to the temporo-mandibular articulation, to the parotid gland, and to the masseter.

The Internal Maxillary Artery (Figs. 477, 478), the vessel which nourishes the deep parts of the face, is one of the terminal branches of the external carotid.

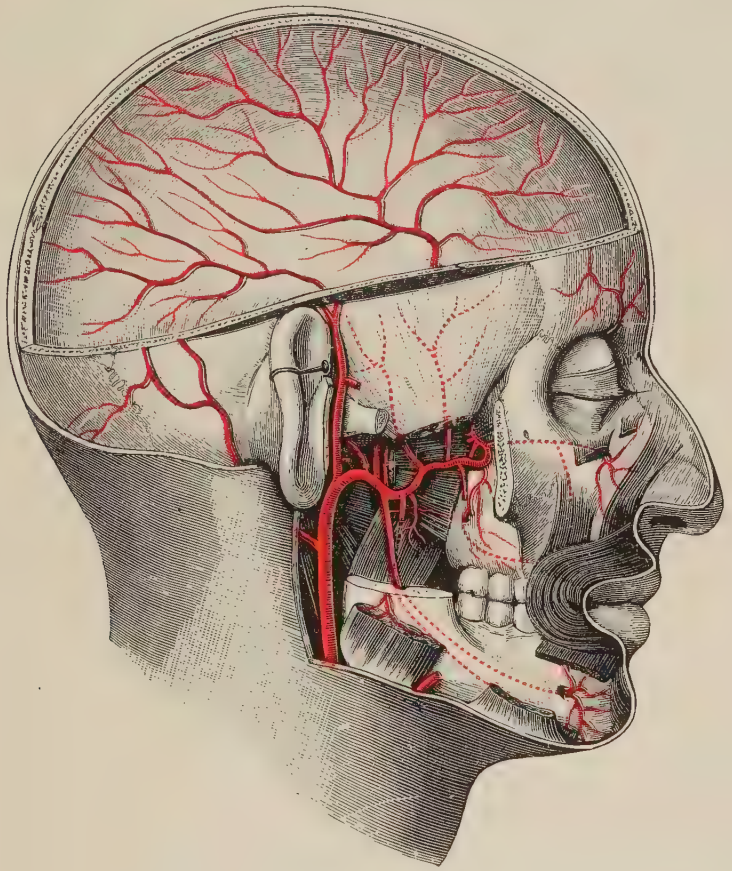

FIG. 477.—Internal maxillary artery. See Fig. 478. (Testut.)

It begins a little below the condyle of the jaw, in the substance of the parotid gland, whence it passes inward and forward to the spheno-maxillary fossa. It is divided into three portions, a maxillary, a pterygoid, and a spheno-maxillary. The *maxillary portion* lies below the external pterygoid muscle; the *pterygoid portion* lies on the outer surface of that muscle; the *spheno-maxillary portion* is in the spheno-maxillary fossa.

Variations.—The internal maxillary in rare cases is given off as a branch from the facial; the number of branches varies considerably, as two or more often arise by a common trunk.

Branches.—From the first or *maxillary portion* of the vessel are given off the

tympanic, the middle meningeal, the small meningeal, and the inferior dental arteries. The *tympanic* passes through the Glaserian fissure to the tympanum, which it aids in supplying. It gives a *deep auricular* branch to the skin of the external meatus. The *middle meningeal* enters the skull through the foramen spinosum, occupies a groove in the great wing of the sphenoid, passes upward and outward, and divides into an anterior and posterior branch. These branches groove the inner surface of the bone, running between the bone and the dura, and furnish the principal arterial supply of the latter. The *small meningeal* artery passes through the foramen ovale into the cranial cavity, and supplies the Gasserian ganglion and contiguous dura. The *inferior dental* (*mandibular*) is a large branch which passes downward to the inferior dental foramen, which it enters with the inferior dental nerve, running forward in the inferior dental canal to supply the mandible and teeth. Before entering the foramen the artery gives off the mylohyoid branch, which is distributed to the mylohyoid muscle, and occupies the mylohyoid groove on the internal surface of the mandible. The artery gives off branches to each tooth, and opposite the mental foramen a *mental* branch, which passes forward to supply the structures of the chin.

The branches of the *pterygoid portion* of the internal maxillary artery supply the muscles of mastication. They are the *deep temporal* (*posterior* and *anterior*),

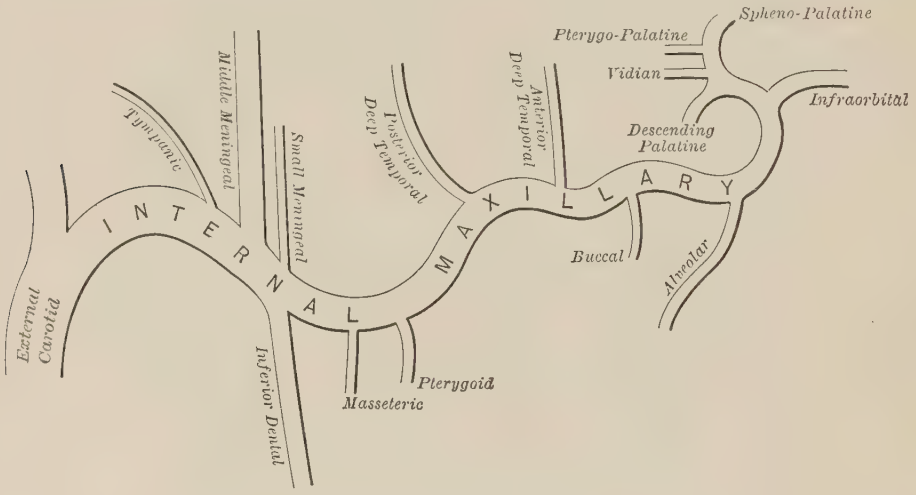

FIG. 478.—Diagram of the internal maxillary artery and its branches.

the *masseteric*, the *pterygoid*, and the *buccal*, and carry blood to the temporal, the masseter, the internal and external pterygoids, and the buccinator.

The branches from the third or *spheno-maxillary portion* are the alveolar, the infraorbital, the descending palatine, the Vidian, the pterygo-palatine, and the spheno-palatine. The *alveolar* (*posterior dental*) supplies the posterior portion of the alveolar process of the maxilla, the antrum, the gums, and the molar and bicuspid teeth. The *infraorbital* passes with the infraorbital nerve along the infraorbital groove and canal, makes its appearance on the face at the infraorbital foramen, and supplies here the soft tissues over the superior maxillary bone, anastomosing with branches from the facial. In the orbit the artery gives off muscular branches, which supply the inferior oblique and inferior rectus muscles, and in the canal branches to the canine and incisor teeth. The *descending palatine* passes with the descending branches of Meckel's ganglion down the posterior palatine canal to the mouth, then runs in a groove on the under surface of the hard palate forward to the anterior palatine canal, where it anastomoses with the naso-palatine artery, and supplies the gums, mucous membrane, and glands of the hard palate. The *Vidian* passes backward through the Vidian canal to be distributed to the pharynx and Eustachian tube. The *pterygo-palatine* passes back-

ward through the pterygo-palatine canal, and also is distributed to the upper part of the pharynx. The *spheno-palatine* passes through the spheno-palatine foramen into the nasal cavity. It divides into two branches, the *naso-palatine*, which runs in a groove of the vomer downward and forward to the anterior palatine foramen, where it anastomoses with the descending palatine artery; and an *external* branch, which supplies the mucous membrane of the outer wall of the nasal cavity, and the maxillary, ethmoidal, and sphenoidal sinuses.

The Internal Carotid Artery.

The *internal carotid* (Fig. 470) artery springs from the common carotid opposite the superior border of the thyroid cartilage, runs upward in front of the transverse processes of the upper three or four cervical vertebræ to the carotid canal in the petrous portion of the temporal bone, through the canal to its internal opening, enters the cranial cavity, and then passes into the cavernous sinus, in which it is covered by the lining membrane of that channel. It leaves the sinus at the inner side of the anterior clinoid process, and passes to the Sylvian fissure, where it breaks up into its terminal branches. The artery is distributed mainly to the brain and eye. It is divided into four portions: a cervical, a petrous, a cavernous, and a cerebral.

The cervical portion is that extending from its origin to the lower opening of the carotid canal.

Relations (Fig. 472).—*In front*, below, is the external carotid artery, overlapped by the sterno-cleido-mastoid; higher up in order are the digastric and the stylo-hyoid muscles, the hypoglossal nerve, the occipital and the posterior auricular arteries, the glosso-pharyngeal nerve, the stylo-pharyngeus and the stylo-glossus muscles. *Behind* are the rectus capitis anterior major, the superior cervical ganglion, and the superior laryngeal nerve; and, near the skull, the ninth, tenth, eleventh, and twelfth cranial nerves between the artery and the internal jugular vein. *At the outer side* are the internal jugular vein and the vagus nerve—the latter posterior. *At the inner side* are the pharynx with the tonsil, the superior laryngeal nerve, and the ascending pharyngeal artery.

Variations.—The internal carotid sometimes arises directly from the arch of the aorta. It is in rare cases absent. It very exceptionally gives off branches in the neck, which are usually the occipital and ascending pharyngeal.

Branches.—As a rule, the internal carotid gives off no branches of importance in the neck. (See Variations.)

The petrous portion of the vessel is that part contained in the carotid canal. Here the artery makes two sharp turns, which are supposed to diminish the arterial pressure. Its course is successively upward, forward, and inward and upward. From this portion of the artery a small branch is given off to the tympanum.

The cavernous portion is that part of the vessel which is in the cavernous sinus. Here the vessel gives off the following branches: the arteriæ receptaculi, the anterior meningeal, and the ophthalmic. The *arteriæ receptaculi* are small vessels which supply the pituitary body and the Gasserian ganglion. The *anterior meningeal* artery is distributed to the dura of the anterior fossa at the base of the skull.

The Ophthalmic Artery (Fig. 479) passes with the optic nerve through the optic foramen into the orbit. It goes first forward and outward, then crosses the optic nerve and passes forward and inward, runs along the inner wall of the orbit, beneath the inner portion of the orbital margin, leaves the orbit, and terminates by dividing into the frontal and nasal arteries. In its course the ophthalmic artery gives off branches to the walls and contents of the orbit. These branches are the central artery of the retina, the ciliary arteries, the lachrymal, the muscular, the supraorbital, the ethmoidal, and the palpebral. The *central artery of the retina* is given off from the ophthalmic near the optic foramen. It accompanies

the optic nerve, and is distributed to the retina. The branches of this vessel can be well seen in ophthalmoscopic examinations of the retina, The *ciliary* arteries are divided into three sets—the long, short, and anterior ciliary arteries. The *short ciliary* arteries are eight or ten in number, pierce the sclerotic coat near the optic nerve, and run forward to supply the choroid. The *long ciliary* arteries, two in number, one on each side, pierce the sclera some distance from the optic nerve, and run forward to supply the ciliary body and iris. The *anterior ciliary* arteries are branches of the muscular branches of the ophthalmic. They perforate the sclera near the cornea and supply the iris. The anterior and long ciliary arteries form an anastomosis around the outer margin of the iris, and another around its free margin. The *lachrymal* artery arises from the ophthalmic external to the optic nerve, passes forward and outward to the lachrymal gland, which it supplies, and, leaving the gland, sends small branches to the eyelids, known as *external palpebral* branches. *Muscular* branches are given off from various portions of the ophthalmic in its course to the muscles of the globe. The *supraorbital*

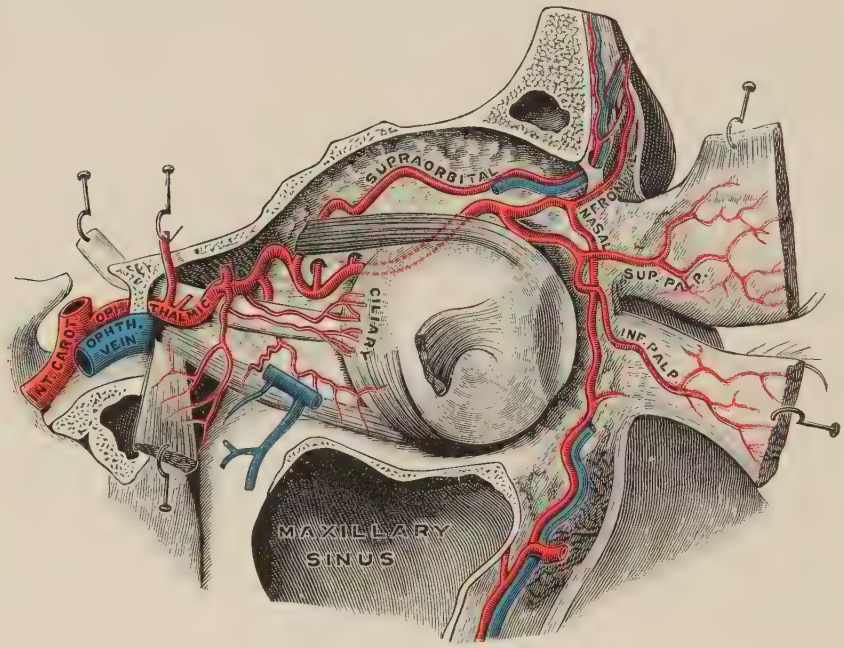

FIG. 479.—Arteries of the orbit. (Testut.)

artery is a vessel of some size, which runs along the roof of the orbit to the supraorbital notch. Leaving the orbit at this point, it courses upward in the muscles and integument of the forehead. The *ethmoidal* arteries, two in number, are given off from the ophthalmic opposite the anterior and posterior ethmoidal foramina. Entering the cranial cavity through these foramina they give off *anterior meningeal* vessels, supplying the dura in the anterior fossa at the base of the skull. The *anterior ethmoidal* is the larger, and, after giving off a meningeal branch, leaves the cranial cavity with the nasal nerve, passes through an opening in the cribriform plate to the nasal cavity, runs along the inner surface of the nasal bone, and supplies the tip of the nose. The *palpebral* arteries, two in number, the superior and inferior, supply the upper and lower lids. The *nasal* artery leaves the orbit above the inner canthus, and supplies the bridge of the nose, anastomosing with the angular branch of the facial. The *frontal* leaves the orbit at the upper and inner angle, winds up over the forehead near the median line, supplying the soft tissues in this region.

Variations.—The ophthalmic is sometimes situated beneath the optic nerve,

and on the inner side of the orbit throughout its entire course. It may be a branch of the middle meningeal, or even give origin to that vessel. Variations in the number and position of the branches as described frequently occur.

The cerebral portion of the internal carotid has for its branches the posterior communicating, the anterior choroid, the anterior cerebral, and the middle cerebral arteries. The *posterior communicating* passes backward to the posterior cerebral artery, a branch from the basilar, and forms the lateral portion of the circle of Willis. The *anterior choroid* passes outward and backward to the descending horn of the lateral ventricle, where it supplies the choroid plexus, the velum interpositum, the hippocampus, and the fimbria. The *anterior cerebral* runs forward and inward to the great longitudinal fissure between the hemispheres. In this fissure the artery lies close to its opposite mate, and connecting them is a short trunk, the *anterior communicating*. The artery winds over the anterior extremity of the corpus callosum to reach its superior surface. It gives off branches to the anterior perforated space, to the under surface of the frontal lobe, and the mesial surface of the hemisphere, and anastomoses with the posterior cerebral artery. The *middle cerebral* (Sylvian) artery passes forward and outward to the fissure of Sylvius, and then runs along the fissure to the insula and the external surface of the hemisphere. In its course it gives branches, which enter the anterior perforated space, and supply the ganglia and other structures in the floor of the lateral ventricle. One of these vessels is of special interest, the *lenticulo-striate* artery, called also Charcot's *artery of cerebral hemorrhage*, because it is a very common site of arterial rupture in cases of apoplexy. This vessel is situated between the external capsule and the corpus striatum. The cortical brain substance of the motor area is also supplied by the middle cerebral artery, and here arterial lesions are common and often produce localizing symptoms. After discussing the vertebral artery, which with the internal carotid supplies the encephalon, the arterial supply of the brain will be given more in detail.

ARTERIES OF THE UPPER EXTREMITY.

From the brachio-cephalic on the right side and from the arch of the aorta on the left begins a great trunk which extends to below the bend of the elbow, presenting in its course no intrinsic markings by which it can be divided. For the sake of convenience, however, certain extrinsic structures have been selected, by which this long trunk is divided into three portions. The first extends from the origin of the vessel to the horizontal level of the outer border of the first rib, and is called the subclavian artery; the second reaches from the first rib to the lower border of the teres major muscle, and is known as the axillary artery; and the third runs from the teres major to a point half an inch below the bend of the elbow, and is named the brachial artery.

THE SUBCLAVIAN ARTERY.

The *subclavian* ("under the clavicle") *artery* (Fig. 480) takes its origin on the left side from the arch of the aorta, on the right side from the brachio-cephalic artery. Each vessel passes upward and outward into the neck, and then arches downward and outward to terminate in the axillary, at the horizontal level of the outer border of the first rib. The subclavian artery is divided into three portions, according to its situation with reference to the scalenus anterior muscle. The first portion extends from the origin of the vessel to the inner border of the scalenus anterior muscle; the second portion lies behind this muscle; and the third portion runs from the outer border of the muscle to the outer border of the first rib. The first portions of the subclavian arteries differ, and must be described separately. A single description will answer for the second and third portions of both arteries.

The first portion of the left subclavian is deeply situated in the thorax. Springing from the transverse portion of the aortic arch farther back than the other great arteries, it passes upward and a little forward to the mesial edge of the left scalenus anterior, where this muscle is inserted into the first rib.

Relations.—*In front* at its lowest part are the left brachio-cephalic vein and the left vagus nerve; high up the left phrenic nerve crosses the artery; toward the right is the left carotid artery; and elsewhere are the internal jugular, vertebral, and subclavian veins, and cardiac sympathetic branches; the left lung with its pleura overlaps these structures. *Behind* are the gullet, thoracic duct, inferior cervical sympathetic ganglion, and longus colli muscle. *At the left* is the left lung with its pleura. *At the right* above are the gullet and thoracic duct; below are the trachea and recurrent laryngeal nerve.

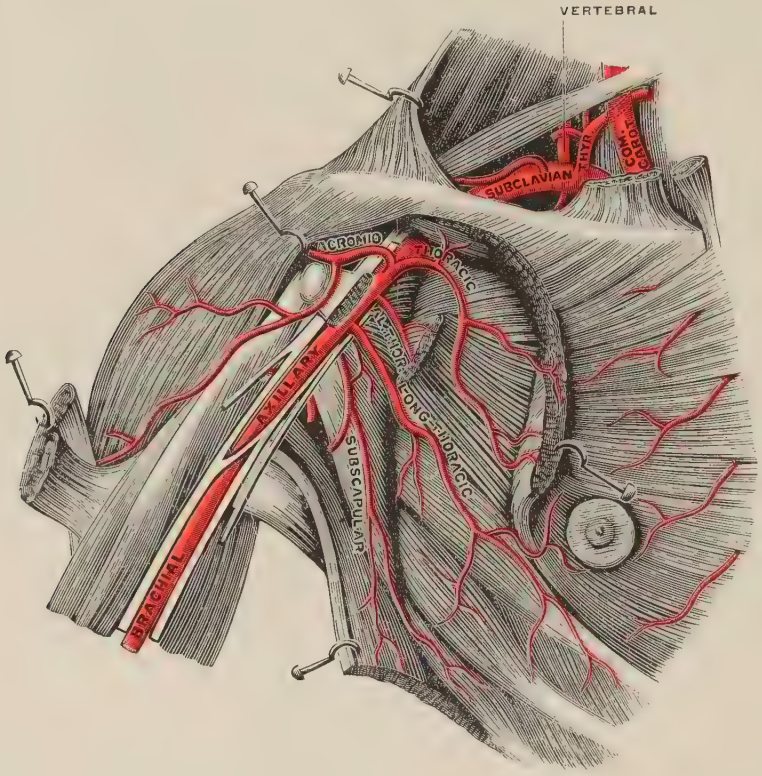

FIG. 480.—Subclavian and axillary arteries. (Testut.)

The first portion of the right subclavian takes its origin from the brachio-cephalic artery, and extends upward and outward to the inner border of the scalenus anterior. It is about an inch and a quarter long.

Relations (Fig. 481).—*In front* are the right internal jugular and vertebral veins, the right vagus and phrenic nerves, the sympathetic nerve and its superior cardiac branches. *Behind* are the right lung with its pleura, the recurrent laryngeal and sympathetic nerves. *Below* are the lung and pleura, and the recurrent laryngeal nerve.

The second portion of the subclavian is behind the scalenus anterior. It is three-quarters of an inch long.

Relations.—*In front* is the scalenus anterior, which separates the artery from the subclavian vein (the latter being on a lower level), and from the phrenic nerve. *Behind* are the apex of the lung covered by pleura, and the scalenus medius. *Above* is the brachial plexus. *Below* is the lung with its pleura.

The third portion of the subclavian extends from the outer border of the scale-

nus anterior to the outer border of the first rib. It is the most superficial portion of the artery, and is in the subclavian triangle.

Relations.—*In front* it is in contact with the posterior layer of the cervical fascia, the suprascapular artery, the external jugular vein, and cervical veins

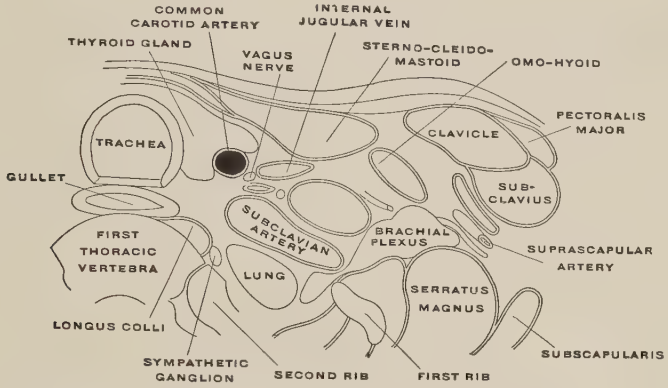

FIG. 481.—Horizontal section through the first thoracic vertebra—upper surface of lower segment. The ventral and dextral part of the section is shown. (Braune.)

which are tributary to it. *Behind* are the scalenus medius and part of the brachial plexus. *Above* are the brachial plexus and the posterior belly of the omo-hyoid muscle. *Below* is the first rib.

Variations.—The subclavian is sometimes on both sides a direct trunk from the aortic arch, or on both sides a branch from a right and left brachio-cephalic

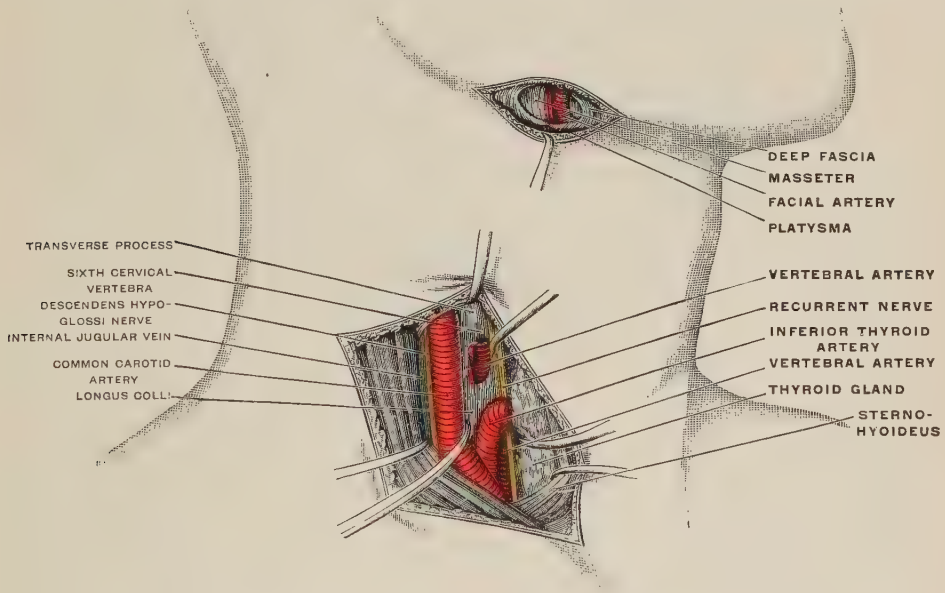

FIG. 482.—Surgical relations of the facial, vertebral, and inferior thyroid arteries. (Kocher.)

artery. The vessel is usually at its high point in the neck a half inch above the clavicle, but sometimes it rises considerably higher; and it may be beneath the clavicle entirely.

Branches.—These are usually four in number, namely, the vertebral, the internal mammary, the thyroid axis, and the superior intercostal. All but the last spring

from the first portion; and this one does so in many cases, but more frequently comes from the second. The posterior scapular very often is given off from the third portion.

The Vertebral Artery.

The *vertebral* (Fig. 470), so called from its situation in the cervical vertebræ, is the largest branch of the subclavian, from the posterior surface of which it is given off. Its blood is principally distributed to the spinal cord, the cerebellum, and the posterior part of the cerebral hemispheres. It passes up between the scalenus anterior and the longus colli, and behind the internal jugular and vertebral veins, to the costo-transverse foramen of the sixth cervical vertebra, and goes upward through this and the corresponding foramina of the vertebræ above; it then runs backward behind the articular process of the atlas, and over the

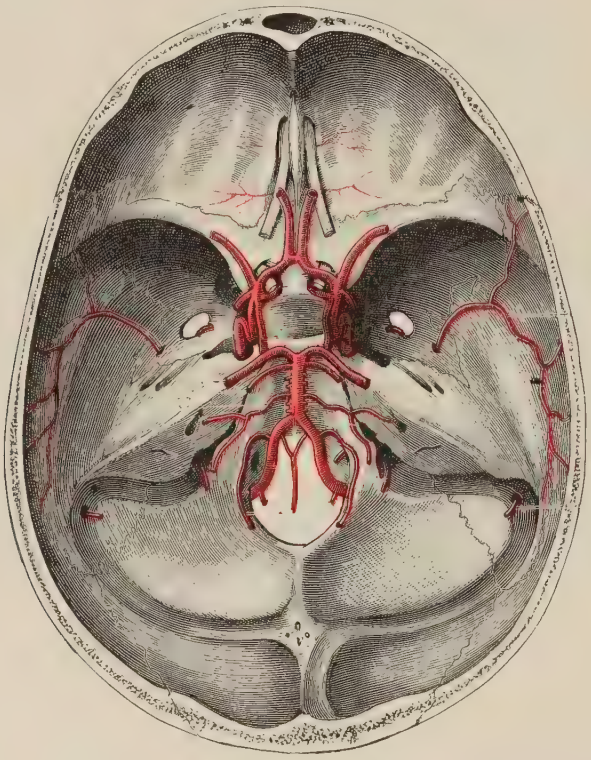

FIG. 483.—Arteries at the base of the brain, seen in their relations to the skull. See Fig. 484, Key. (Testut.)

upper surface, and enters the cranial cavity through the foramen magnum. On the basilar process of the occipital the vertebral arteries of the two sides unite at the lower border of the pons, and thus form the basilar artery.

Variations.—The vertebral may arise from the common carotid or from the arch of the aorta. It may pass through all of the costo-transverse foramina of its side, or none below the third.

Branches.—The branches are considered in two sets—the cervical and the cranial. Those in the neck are the lateral spinal and the muscular. The *lateral spinal* enter the spinal canal through the intervertebral foramina, and supply the cord, its membranes, and the vertebræ. The *muscular* are distributed to the deep muscles of the neck.

The cranial branches (Figs. 483, 484) are the posterior spinal, the anterior spinal, the posterior inferior cerebellar, the bulbar, and the posterior meningeal.

The *posterior spinal* runs down beside the oblongata, reaches the back of the cord, and descends behind the dorsal roots of the spinal nerves to the cauda equina, anastomosing freely all the way with arteries entering the canal at the side. The *anterior spinal* joins its opposite fellow near the foramen magnum, and the resulting vessel runs down ventrally the length of the cord, inosculating with vessels which enter the canal through the intervertebral foramina. The *posterior inferior cerebellar*, the largest branch, is distributed to the hind and under portions of the cerebellum, and in the fourth ventricle. The *bulbar* are small branches to the oblongata, as the name implies. The *posterior meningeal*, of small size, are distributed to the parietes of the posterior cranial fossa.

The **Basilar Artery** (Figs. 483, 484), so called from its situation at the base of the cranium, is formed by the union of the vertebral arteries, and supplies considerable portions of the encephalon in its lower levels. It runs forward and upward in the groove on the ventral surface of the pons, and divides into the posterior cerebral arteries. In its course it gives off as branches the transverse, the anterior inferior cerebellar and superior cerebellar arteries. The *transverse* or pontal arteries supply the pons, and one branch enters the internal auditory meatus with the facial and auditory nerve, and runs to the labyrinth of the ear. The *anterior inferior cerebellar* arteries supply the anterior portion of the inferior surface of the cerebellum. The *superior cerebellar* arteries wind backward and upward to the upper surface of the cerebellum, which they supply. All of these arteries to the brain anastomose freely with one another, and with branches of the vertebral.

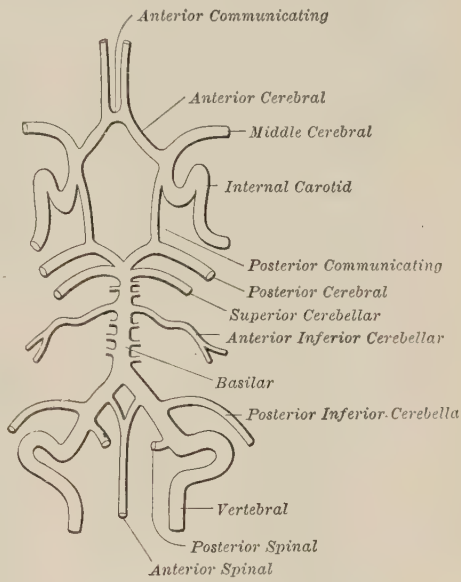

FIG. 484.—Key to Fig. 483.

The terminal branches of the basilar, the *posterior cerebral* arteries, are vessels of large size, which anastomose with the posterior communicating to complete the circle of Willis behind. They pass to the under surface of the occipital lobes of the cerebral hemispheres, their terminal branches supplying these and the neighboring temporal lobes. Numerous small branches (*ganglionic*) are given off in the course of these arteries to the thalami, great ganglia at the base of the brain, passing through the posterior perforated space; and others (*choroid*) go through the transverse fissure to the velum interpositum.

The **Circle of Willis** is an anastomosis formed in front by the anterior cerebral arteries and the anterior communicating which unites them; behind by the posterior cerebral; and laterally by the internal carotid and posterior communicating. From the cerebral arteries close to the circle of Willis deep ganglionic branches are given off which penetrate the brain substance, and are distributed to the great basal ganglia and the contiguous structures. Beyond this the vessels supply the cortex. A point of practical importance in this connection is the fact that the arteries which supply the brain are terminal arteries, and that there is no anastomosis between the vessels going to the ganglia and central structures of the brain and those supplying the cortex. As a result, whenever occlusion of an artery of the brain occurs, the portion of cerebral tissue supplied by the vessel beyond the point of obstruction has its arterial supply permanently cut off, and disorganization ensues.

The Internal Mammary Artery.

The *internal mammary* (Fig. 485) is named from its deep situation and its distribution in part to the milk-gland. Besides this destination it supplies to some extent muscles in the chest and abdomen, the sternum, the anterior mediastinum, and the pericardium. It is given off from the under surface of the subclavian, passes from the neck into the thorax behind the first costal cartilage, and then runs down in front of the pleura half an inch away from the side of the sternum to the sixth intercostal space, where it divides into the superior epigastric and musculo-phrenic arteries.

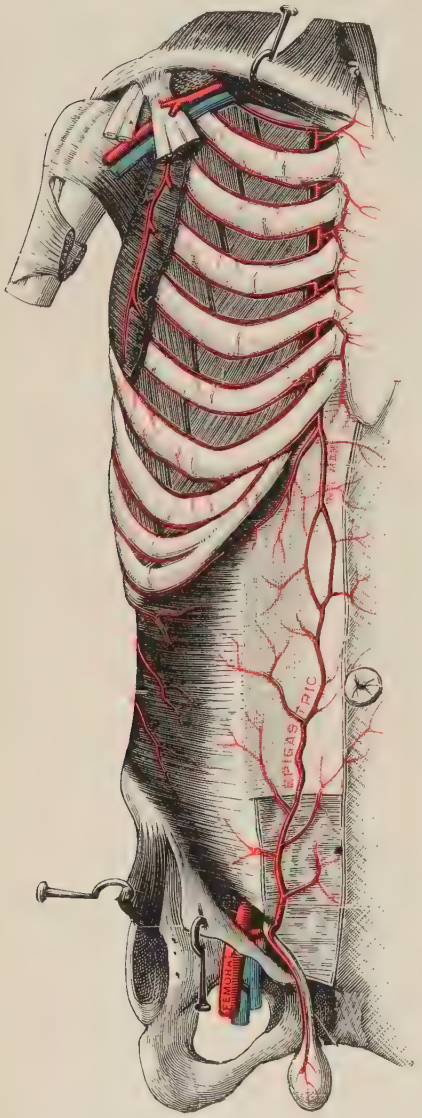

FIG. 485.—Internal mammary and deep epigastric arteries. (Testut.)

Branches.—The branches given off in its course are the superior phrenic, the mediastinal, the pericardial, the sternal, the anterior intercostal, and the perforating. The *superior phrenic* (comes nervi phrenici) accompanies the phrenic nerve, and is distributed to the diaphragm. The *mediastinal* branches supply the structures in the anterior mediastinum. The *pericardial* go to the upper portion of the pericardium, and the *sternal* to the breast-bone and triangularis sterni. The *anterior intercostal*, one to each of the upper five or six spaces, supply the neighboring portions of these spaces, each artery dividing into an upper and a lower branch, which inosculate with the intercostals which come from the aorta. The *perforating* pierce the intercostal muscles in the upper five or six spaces, and pass forward and outward to the pectoralis major, the mammary gland, and the skin. The terminal branches are the musculo-phrenic and superior epigastric. The *musculo-phrenic* winds outward and downward along the inner surface of the costal arch, and opposite each one of the lower intercostal spaces it gives off an intercostal branch, and sends also a number of muscular branches to the diaphragm and abdominal muscles. The *superior epigastric* descends into the abdominal wall, at first occupying a position between the rectus muscle and its posterior sheath, then passes into the substance of the rectus, and anastomoses with the deep epigastric artery. It sends branches also to the oblique muscles of the abdomen and to the diaphragm.

The Thyroid Axis.

The *thyroid axis* (Fig. 470, THY.) is so called from the distribution of its largest branch to the thyroid gland. It supplies many structures in the neck and shoulder. It is a short, wide vessel, arising from the antero-superior surface of the first portion of the subclavian, and it divides into three diverging branches, the inferior thyroid, the suprascapular, and the transverse cervical.

The Inferior Thyroid Artery passes upward and then inward in front of the vertebral and behind the common carotid to the lateral lobe of the thyroid gland. Its chief distribution is to structures in the ventral part of the neck. The recurrent laryngeal nerve passes sometimes in front and sometimes behind the artery, in intimate relation to it.

Variations.—The inferior thyroid may spring from the vertebral, the common carotid, or the subclavian.

Branches of the inferior thyroid are the glandular, muscular, ascending cervical, inferior laryngeal, tracheal, and œsophageal. The *glandular* are terminal, and ramify in the thyroid gland, anastomosing with branches of the other thyroid arteries. The *muscular* supply the muscles in the immediate neighborhood. The *ascending cervical* goes upward between the scalenus anterior and the rectus capitis anterior major, and anastomoses with the occipital, vertebral, and ascending pharyngeal. It supplies muscles in its course, and sends spinal branches to the vertebræ and cord. The *inferior laryngeal* accompanies the recurrent laryngeal nerve, and supplies the muscles and mucous membrane of the larynx. The *tracheal* and *œsophageal* are distributed to the organs suggested by their names.

The Suprascapular Artery supplies various structures of the shoulder. It passes outward from the thyroid axis to the upper border of the scapula, running almost parallel with the clavicle, crosses the transverse ligament into the supraspinous fossa, where it supplies the supraspinatus muscle, passes behind the neck into the infraspinous fossa, and ramifies in the infraspinatus. It anastomoses with the posterior scapular and dorsal scapular arteries.

Variations.—It sometimes arises directly from the subclavian, occasionally from the axillary.

Branches, in addition to the terminal branches already given, are, *muscular* to contiguous muscles, *suprasternal* to the integument over the sterno-clavicular articulation, *nutrient* to the clavicle, *supra-acromial* to the tissues over the acromion, and *subscapular* to the subscapularis muscle.

The Transverse Cervical Artery (transversalis colli) passes outward and backward in front of the scaleni and the brachial plexus, under the anterior border of the trapezius to the levator scapulæ, where it divides into the superficial cervical and the posterior scapular. It is distributed to muscles of the shoulder and neck. The *superficial cervical* passes upward under the trapezius, supplying this muscle, the levator scapulæ, the splenius, and neighboring lymph-nodes. The *posterior scapular* passes downward along the vertebral border of the scapula to its inferior angle. In its course it is covered by the rhomboid muscles, and anastomoses with other scapular arteries—suprascapular, dorsal scapular, and subscapular.

Variation.—The posterior scapular is very often a separate branch from the third portion of the subclavian.

The Superior Intercostal Artery.

The *superior intercostal* is distributed chiefly to the first intercostal space. It springs from the postero-superior surface of the first or second portion of the subclavian. It runs back over the apex of the lung to the neck of the first rib, in front of which it then passes down to the first intercostal space, which it supplies after the manner of the aortic intercostals. Very often the artery is continued down to the second intercostal space, and supplies it like the first. Before it enters the thorax the artery gives off a *deep cervical* branch, which goes backward, and then runs up the neck between the complexus and semispinalis cervicis, supplying the muscles in its region, and inosculating with the cervical branch (princeps cervicalis) of the occipital.

Variations.—The superior intercostal is sometimes a branch of the thyroid axis. The deep cervical may be a branch from the subclavian or from the posterior scapular.

THE TRIANGLES OF THE NECK.

The quadrilateral surface of the neck, which is bounded below by the clavicle, above by the inferior border of the mandible and a line drawn from the angle of the jaw to the mastoid process, behind by the anterior border of the trapezius muscle, and in front by the median line of the neck, is divided by the sterno-cleido-mastoid muscle into two triangles, called the *anterior* and *posterior triangles* of the neck. These two triangles are subdivided, the posterior into two, the *occipital*, and the *subclavian*, by the posterior belly of the omo-hyoid; the anterior into three by the anterior belly of the omo-hyoid, and the two bellies of the digastric. These are called the *inferior carotid*, the *superior carotid*, and the *submaxillary* triangles (Fig. 422).

The boundaries of these triangles and their principal arterial contents are as follows:

The *occipital triangle* is bounded in front by the sterno-cleido-mastoid, behind by the trapezius, below by the posterior belly of the omo-hyoid, and contains the transverse cervical artery. The *subclavian triangle* is bounded in front by the sterno-cleido-mastoid, postero-superiorly by the hind belly of the omo-hyoid, below by the clavicle, and contains the subclavian artery. The *inferior carotid triangle* is bounded in front by the median line, dorso-inferiorly by the sterno-cleido-mastoid, dorso-superiorly by the anterior belly of the omo-hyoid, and contains the common carotid and inferior thyroid arteries. The *superior carotid triangle* has the sterno-cleido-mastoid behind, the anterior belly of the omo-hyoid in front, and the posterior belly of the digastric above. It contains the common, the internal, and the external carotids, and the beginnings of all of the branches of the last, except the terminals and the posterior auricular. The *submaxillary triangle* is formed above by the mandible and a line from its angle to the mastoid process, below in front by the anterior belly of the digastric, below behind by the posterior belly of the same. It contains the external carotid, the facial, the posterior auricular, and the internal carotid arteries.

THE AXILLARY SPACE.

The axilla or arm-pit is the wedge-shaped space between the inner surface of the arm and the side of the chest. It presents for examination as boundaries anterior, posterior, internal, and external walls, a base and an apex. The *anterior wall* is formed by the pectoral muscles; the *posterior wall* by the subscapularis, the latissimus, and the teres major muscles; the *inner wall* by the upper four ribs and intercostal spaces, covered by the serratus magnus muscle; and the *outer wall* by the humerus, covered by the coraco-brachialis and the biceps muscles. The *apex* corresponds to the small area above the first rib, from which the brachial plexus and the axillary artery and vein emerge. The *base* is formed by the integument and fascia which stretch across the arm-pit from the pectoralis major to the latissimus and teres major. Its contents are the axillary artery and its branches, the accompanying veins, the brachial plexus of nerves, lymph-nodes and vessels, and considerable fat and areolar tissue.

THE AXILLARY ARTERY.

The *axillary artery* (Fig. 487), named from its situation in the arm-pit, begins where the subclavian ends, at the outer border of the first rib, passes downward and outward through the axillary space to the lower margin of the teres major muscle, and there terminates by becoming the brachial. Its branches are distributed to the walls of the chest, the mammary gland, the arm-pit, the shoulder, and the upper part of the arm. At its beginning the artery is deeply situated; but its lower portion is near the surface, and can be felt a third of the distance from the

front to the back of the axilla, at the inner border of the coraco-brachialis. The artery is crossed by the pectoralis minor muscle, which divides it into three portions. The first portion is between the outer border of the first rib and the inner margin of the pectoralis minor, and is about an inch long; the second portion is behind the pectoralis minor, and measures a little more than an inch; and the third portion is between the outer border of the pectoralis minor and the lower border of the axillary space, and is three inches in length. The relations of these three portions differ.

Relations.—First Portion.—*In front* are the pectoralis major, the costo-coracoid membrane, the external anterior thoracic nerve, the cephalic and acromio-thoracic veins. *Mesially* and somewhat to the front is the axillary vein. *Behind* are the first intercostal space, the second rib, the serratus magnus, the internal anterior thoracic and posterior thoracic nerves. *Externally* is the brachial plexus.

Second Portion (Fig. 486).—*In front* are the pectoralis major and minor. *Mesially* are the inner cord of the brachial plexus, the axillary vein, and the internal anterior thoracic nerve between the artery and vein. *Behind* are the pos-

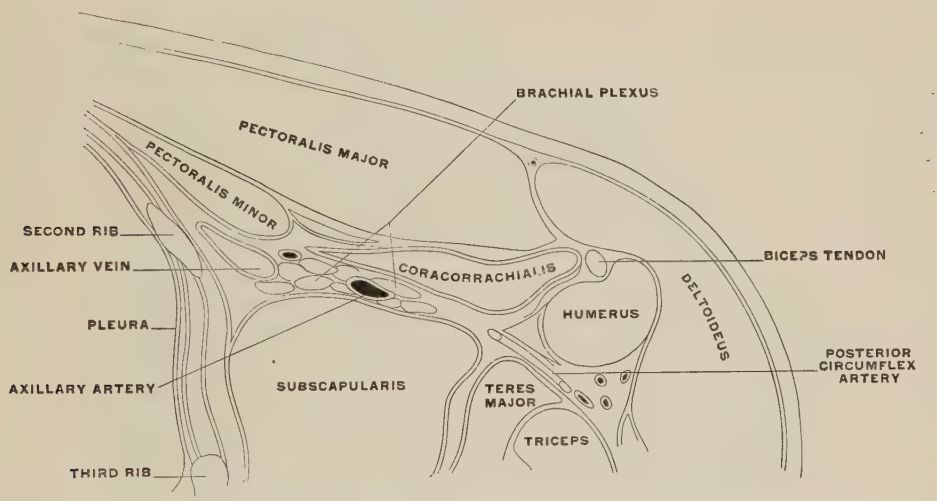

Fig. 486.—Horizontal section below the head of the humerus, showing the relations of the axillary structures at this plane. (Braune.)

terior cord of the brachial plexus and the subscapularis. *Externally* is the outer cord of the brachial plexus.

Third Portion.—*In front* are the pectoralis major in the upper half of this portion, the skin and fasciæ in the lower, the inner head of the median nerve, the internal cutaneous nerve, and the outer brachial vena comes. *Mesially* are the ulnar nerve, the axillary vein, and the small internal cutaneous nerve in the order named, and at the lower part the brachial venæ comites. *Behind* are the musculo-spiral and circumflex nerves, the subscapularis, latissimus, and teres major. *Externally* are the median and musculo-cutaneous nerves, and the coraco-brachialis.

The **Branches** of the axillary artery are usually seven in number, two, the superior thoracic and acromio-thoracic, from the first portion; two, the long thoracic and alar thoracic, from the second; and three, the subscapular and the posterior and anterior circumflex, from the third portion. There is a very free anastomosis between these branches, and between them and other arteries in the region. The *superior thoracic* arises from the first portion of the axillary, and passes downward and forward to supply the pectoralis major and minor muscles. The *acromio-thoracic* artery arises from the first portion of the axillary; it breaks up into three sets of branches: one passes outward to the acromion and deltoid,

the second passes down the arm with the cephalic vein, and is distributed to the pectoralis major and deltoid, and the third supplies the pectoral and the serratus magnus muscles. The *long thoracic* artery arises from the second portion of the axillary, passes downward along the outer border of the pectoralis minor, and sends branches to the serratus magnus, the pectorales major and minor, and the mammary gland. The *alar thoracic*, arising from the second portion, consists either of a single branch or a number of small branches, distributed to the lymphatic nodes, the fat and the areolar tissue of the axilla. The *subscapular* artery is the largest branch of the axillary. It starts from the third portion, passes downward on the subscapularis muscle, and, at about the centre of the axillary border of the scapula, it gives off a large branch, the *dorsal scapular* artery, which winds into the infraspinatus muscle, and anastomoses with the suprascapular and posterior scapular arteries. The rest of the artery passes

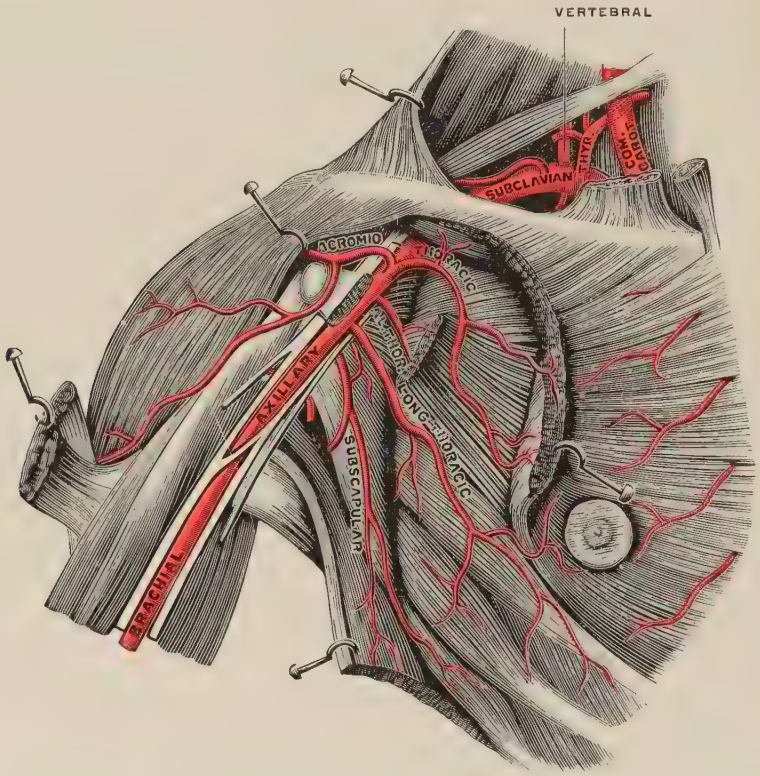

FIG. 487.—Axillary and subclavian arteries. (Testut.)

downward on the chest wall, and is distributed to the muscles in this region—the subscapularis, the serratus magnus, the latissimus, and the teres major. The *posterior circumflex* is much larger than the anterior. It arises from the third portion of the axillary, and winds backward between the teres muscles, the humerus and the long head of the triceps, and around the neck of the humerus. It accompanies the circumflex nerve, and supplies the deltoid and other structures about the shoulder, and the joint itself. The *anterior circumflex* arises from the outer side of the third portion of the axillary artery. It passes forward in front of the humerus, is covered by the coraco-brachialis and the tendons of the biceps, sends branches to the shoulder-joint and deltoid, and anastomoses with the posterior circumflex.

Variations.—The axillary sometimes gives off one of the arteries of the fore-arm. This is usually the radial, but is sometimes the ulnar, and, occasionally,

the interosseous. Very often the usual number of branches from the axillary is diminished by the origin of two or more from a common trunk. The third portion of the axillary is sometimes crossed by a muscular slip extending from the latissimus to some muscle or fascia in or near the front of the axilla.

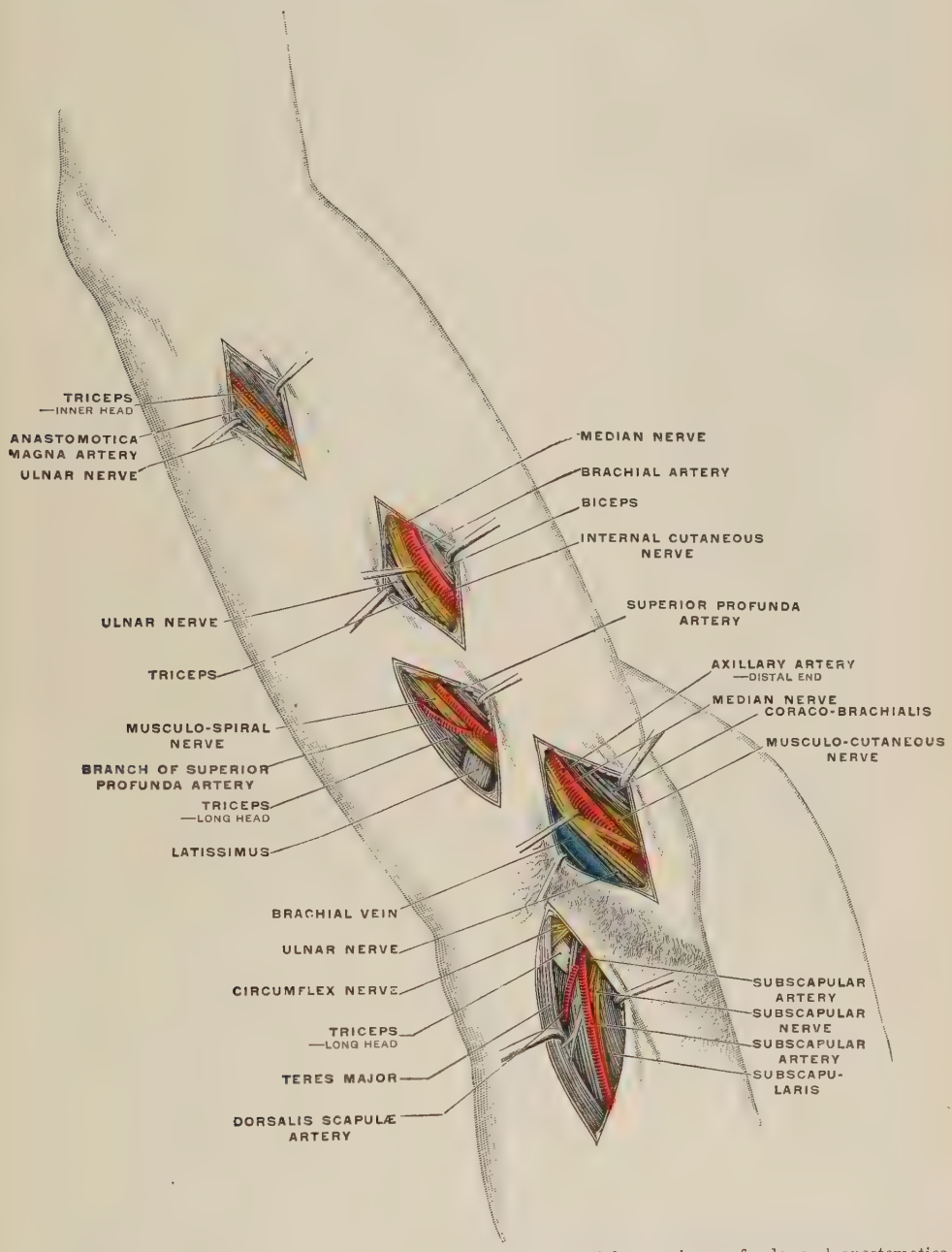

FIG. 488.—Surgical relations of the axillary, subscapular, brachial, superior profunda, and anastomotica magna arteries. The right arm is represented as raised almost to the perpendicular. (Kocher.)

THE BRACHIAL ARTERY.

The *brachial artery* (Fig. 489), sometimes called the *humeral*, is the great trunk of the arm. It extends from the lower border of the teres major to half an inch

below the bend of the elbow, following the direction of the inner border of the coraco-brachialis and biceps, thus being at first in the mesial part of the arm, gradually curving forward, and ending in the middle of the front of the limb just below the plane of the head of the radius.

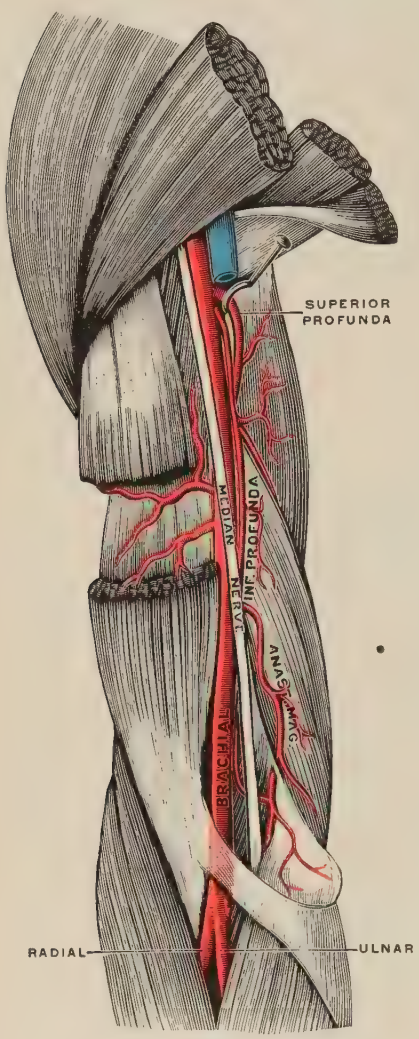

FIG. 489.—Brachial artery. (Testut.)

Relations (Figs. 490–492).—*In front*, in the greater part of its course, the coraco-brachialis and biceps in turn overlap the artery, the median nerve crosses the middle third; in the lowest part are the secondary tendon of insertion of the biceps, separating the artery from the median basilic vein, with the brachio-radialis and pronator teres overlapping. *Behind*, successively from above downward are the long and internal heads of the triceps, the coraco-brachialis, and the brachialis. The musculo-spiral nerve and superior profunda artery lie between the brachial and the long head of the triceps. *At the inner side* are the internal vena comes, and the basilic vein, the latter separated from the artery in its lower part by the fascia; in the upper third the internal cutaneous and ulnar nerves; in the lower part the median nerve and inferior profunda artery. *At the outer side*, the external companion vein, the coraco-brachialis and biceps, and in the upper third the median nerve, which is thus seen to be successively at the outer side, in front, and at the inner side.

Variations.—High division of the brachial is frequently seen, and has been noted at all parts of its course. The vessel given off high up is usually the radial, sometimes the ulnar, rarely the interosseous.

Branches.—The brachial artery ends in two terminals, the ulnar and radial, and gives off in its course the superior profunda, inferior profunda, nutrient, anastomotica magna, and muscular. The *superior profunda*, the largest branch, arises very near the beginning of the brachial from its dorso-mesial aspect, passes backward and around the humerus in the musculo-spiral groove with the musculo-spiral nerve, which it accompanies to the front of the external condyle, and anastomoses with the radial recurrent. Its principal offset is the articular branch, which supplies the elbow-joint, and inosculates behind the external condyle with posterior recurrent branches from the interosseous and ulnar, with the inferior profunda and the anastomotica magna. It gives branches to the muscles among which it runs, and the largest and highest of these anastomoses with the posterior circumflex. It may give a nutrient branch to the humerus. The *inferior profunda*, a smaller vessel, springs from the mesial side of the brachial below the superior, and runs to the back of the inner condyle in company with the ulnar nerve. It inosculates with the posterior ulnar recurrent and the anastomotica magna. The *nutrient* (medullary) enters the humerus through the nutrient foramen. The *anastomotica magna*, called "the great anastomotic," from the extent to which it takes part in the formation of the arterial network around the elbow-joint, arises about two inches above the bifurcation of the brachial from its mesial

aspect, goes inward above the internal condyle and around the back of the humerus, and forms an arch above the olecranon fossa, inosculating with the articular branch of the superior profunda and the interosseous recurrent, and also with the anterior and posterior ulnar recurrent. The *muscular* branches are variable in number, and supply adjacent muscles.

The Ulnar Artery.

The *ulnar artery* (Figs. 494–496), one of the terminal branches of the brachial, passes from its origin inward and downward in the ventral portion of the forearm. It is deeply situated in the upper part of its course, but becomes superficial in the lower half of the forearm, where it runs upon the flexor profundus digitorum and between the flexor carpi ulnaris and flexor sublimis. It passes over the anterior annular ligament into the palm, which it crosses in a gentle

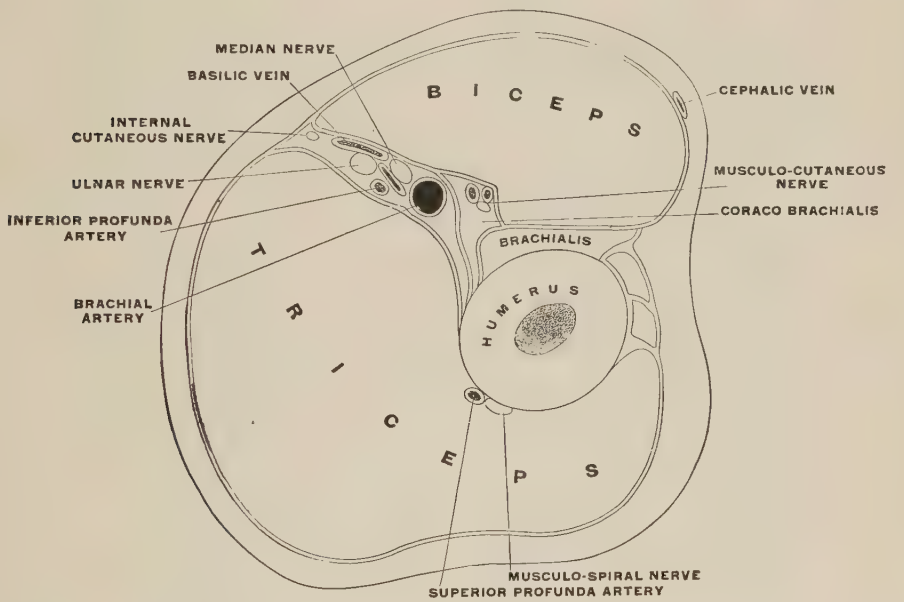

FIG. 490.—Horizontal section through the middle of the right arm—upper surface of the lower segment. (Braune.)

curve, and becomes the chief factor in the formation of the superficial palmar arch.

Relations.—IN THE FOREARM (Figs. 498–500).—*In front* in the upper half are the superficial flexors; in the lower half, the fasciæ. *Behind* are the brachialis above, and the flexor profundus below. *At the inner side* are a vena comes all the way; for the lower two-thirds the ulnar nerve and the flexor carpi ulnaris. *At the outer side* are a vena comes throughout, the flexor sublimis for the most of its course, and the pronator teres above.

IN THE WRIST.—*In front* is the tendon of insertion of the flexor carpi ulnaris. *Behind* is the annular ligament. *At the inner side* are the pisiform bone and the ulnar nerve. *At the outer side* is the unciform. Venæ comites accompany the artery.

IN THE HAND BELOW THE WRIST.—The artery runs across nearly on a line with the lower border of the forcibly extended thumb. *In front* are the palmar fascia and palmaris brevis. *Behind* are the flexor tendons, the short muscles of the little finger, and branches of the median and ulnar nerves. Venæ comites accompany the vessel.

Variations.—The ulnar may arise from the brachial in the arm, or may come from the axillary. It is sometimes superficially situated in its entire course.

Branches.—These are considered in three groups: those in the forearm, those in the wrist, and those in the hand below the wrist. In the first group are the

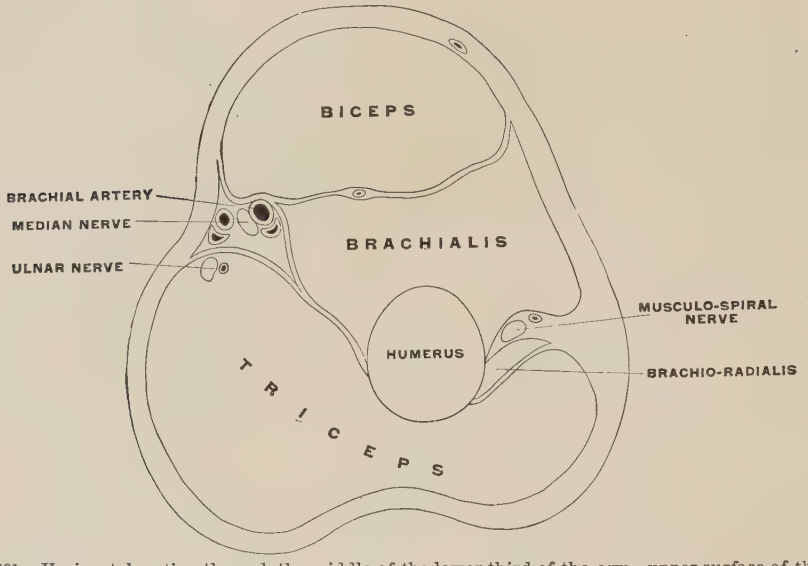

FIG. 491.—Horizontal section through the middle of the lower third of the arm—upper surface of the lower segment. (Braune.)

anterior and posterior ulnar recurrent, the interosseous, and the muscular; in the second, the anterior and posterior ulnar carpal; in the third, the deep palmar, and the digital. The artery beyond the point of origin of the deep palmar

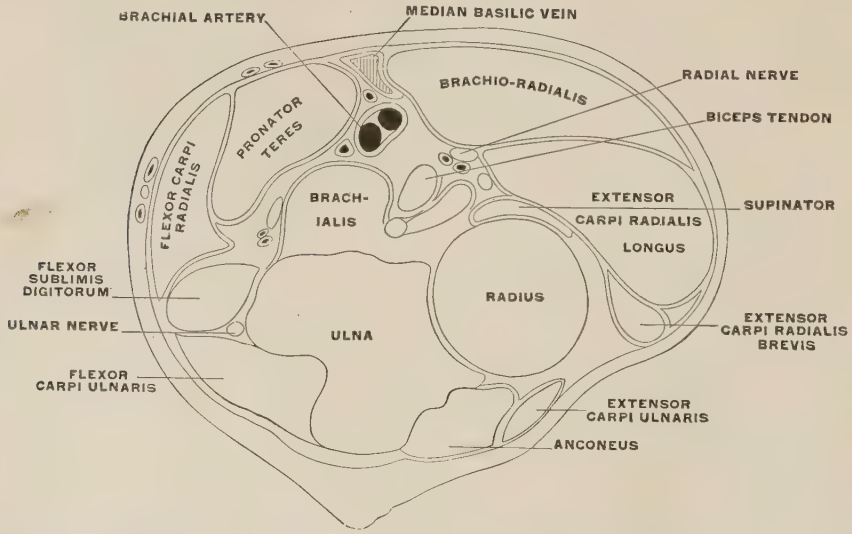

FIG. 492.—Horizontal section just below the bend of the elbow, showing the brachial artery at its bifurcation. (Braune.)

is sometimes considered as one of two terminal branches, and is then called the superficial palmar.

BRANCHES IN THE FOREARM.—The *anterior ulnar recurrent*, the highest branch, runs upward and inward to the front of the internal condyle. It some-

times arises from a trunk common to it and the posterior recurrent. The *posterior ulnar recurrent*, larger than the preceding, winds backward and inward beneath the flexor sublimis, behind the internal condyle, lying near the ulnar nerve. It supplies the joint and the adjacent muscles, and inosculates with the inferior profunda, anastomotica magna, and interosseous recurrent arteries. The *interosseous*, a very short vessel, arises from the dorso-external aspect of the ulnar below the radial tuberosity, passes backward and downward to the upper border of the interosseous membrane, and there divides into the anterior and posterior interosseous. The *anterior interosseous* passes down on the ventral surface of the interosseous membrane, giving branches to the deep muscles, *nutrient arteries* to the ulna and radius, an offset, the *median* artery, to the median nerve, and one which anasto-

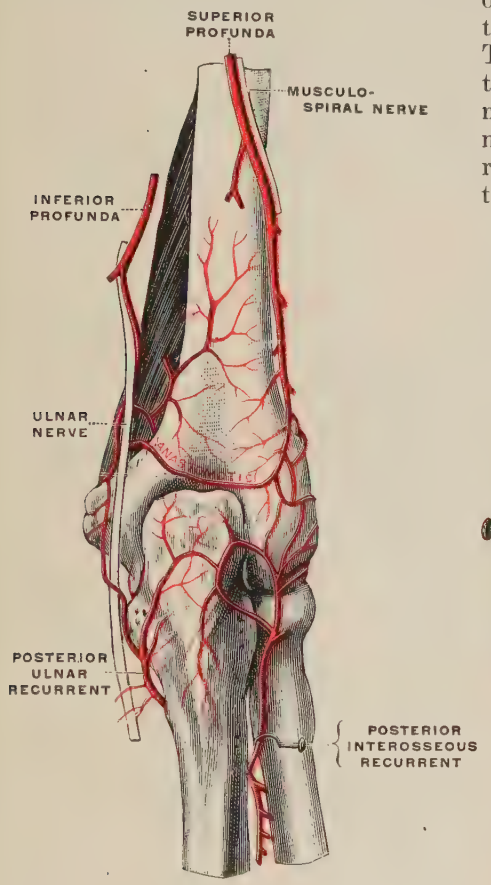

FIG. 493.—Anastomoses at the back of the elbow. (Testut.)

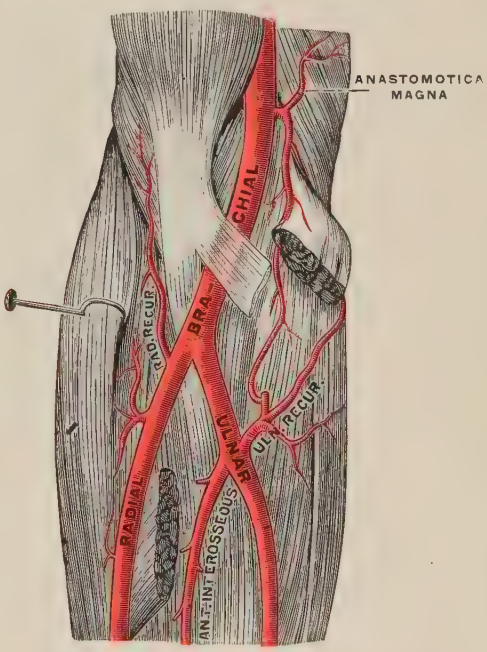

FIG. 494.—Arteries in the region of the bend of the elbow. (Testut.)

moses with the anterior carpal arch. It runs behind the pronator quadratus, through the interosseous membrane to the back of the forearm, anastomoses with the posterior interosseous, and finally inosculates with the posterior carpal arch. The *posterior interosseous*, a larger vessel, courses back above the upper margin of the interosseous membrane, and then down the forearm between the superficial and deep muscles. It anastomoses with the anterior interosseous and the posterior carpal arch. High up it gives off the *posterior interosseous recurrent*, which runs to the elbow between the external condyle and the olecranon, and anastomoses with various arteries of the arm and forearm. The *muscular* branches supply the muscles contiguous to the artery.

BRANCHES IN THE WRIST.—The *anterior ulnar carpal* runs across in the ventral part of the carpus, and inosculates with the anterior radial carpal, the two thus forming the anterior carpal arch. The *posterior ulnar carpal* passes outward beneath the extensor tendons and anastomoses with the posterior radial carpal, the union of the two forming the posterior carpal arch. The branches of this arch will be treated of in connection with the radial artery.

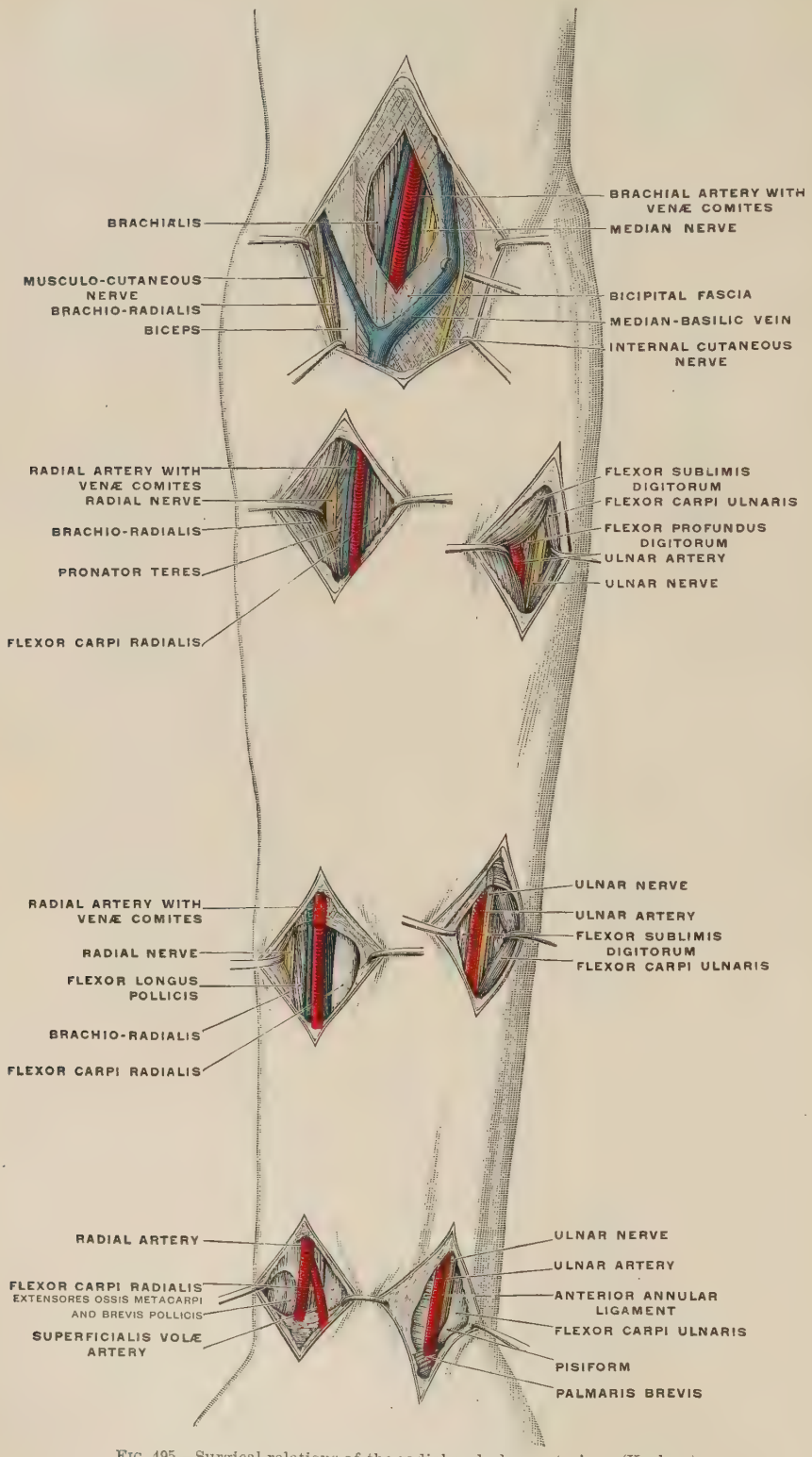

FIG. 495.—Surgical relations of the radial and ulnar arteries. (Kocher.)

Branches in the Hand below the Wrist.—The *deep palmar* (communicating), a large branch, enters the palm between the abductor and short flexor of the little finger, and by inosculation with the end of the radial contributes to the formation of the deep palmar arch. The four *digital* (Fig. 496) are named numerically, beginning at the ulnar side, are given off from the convexity of the superficial arch (superficial palmar), run down to the web of the fingers, where each except the first receives a palmar interosseous from the deep arch. The first goes to the ulnar side of the little finger; each of the others divides into two

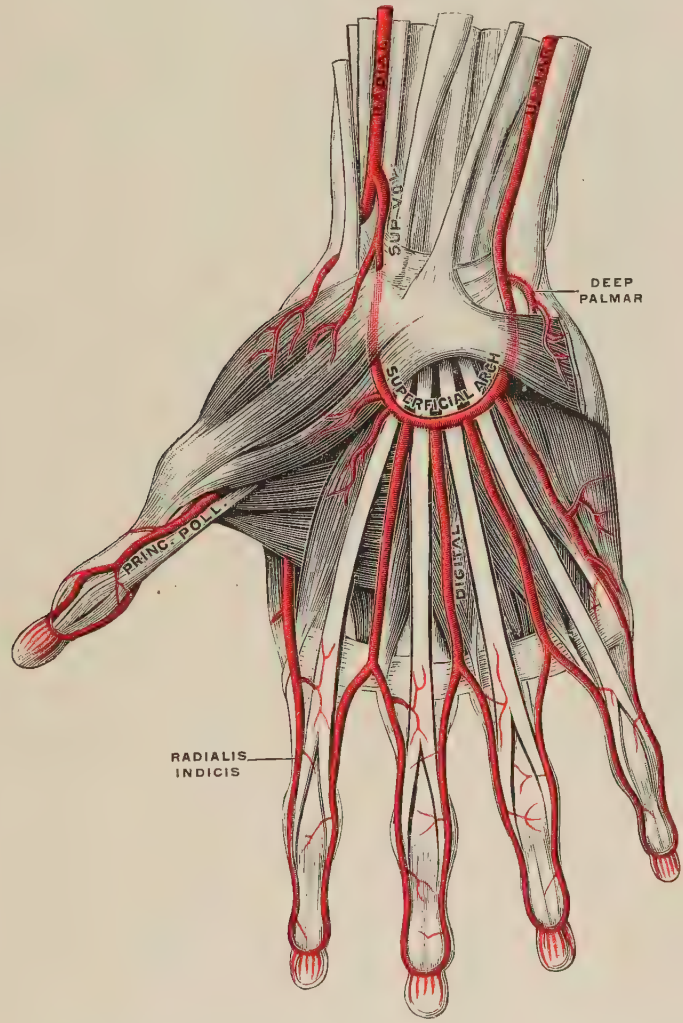

Fig. 496.—Superficial palmar arch and its branches. Of the digitals, only the third is labelled. (Testut.)

collateral digital branches, which pass to the contiguous sides of the little, ring, middle, and index fingers—the outer side of the index being fed by a branch of the radial.

The Radial Artery.

The *radial artery* (Figs. 494, 495, 497), one of the terminals of the brachial, is more in line with that vessel than is the ulnar, though somewhat smaller. It passes downward on the radial side of the forearm to the carpus, around the outer side of which it curves under cover of the extensors of the thumb to the

space between the heads of the abductor indicis, through this into the palm, crosses the proximal ends of the metacarpal bones, and ends by anastomosing with the deep branch of the ulnar, thus forming with the latter the deep palmar arch.

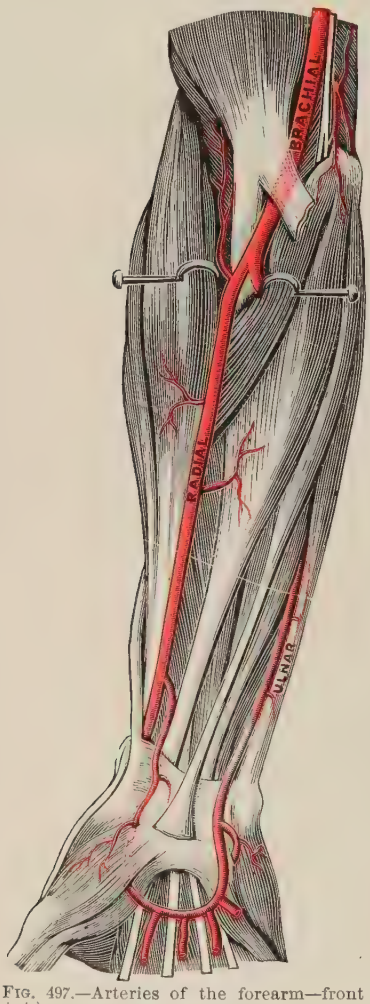

Fig. 497.—Arteries of the forearm—front view. (Testut.)

Relations.—In the Forearm. (Figs. 498–500.)—*In front* in the upper part is the brachio-radialis; elsewhere are the fasciæ, some veins, and branches of the musculo-cutaneous nerve. *Behind* in succession are the biceps, supinator, pronator teres, flexor sublimis, flexor longus pollicis, pronator quadratus, and the radius. *At the outer side* are the brachio-radialis and a companion vein all the way, and the radial nerve in the middle third. *At the inner side* are a vena comes the entire course, the pronator teres in the upper third, and the flexor carpi radialis in the lower.

In the Wrist.—It is accompanied by venæ comites; is covered in different parts by the extensors of the thumb, branches of the radial nerve, and the skin and fascia; and runs in turn upon the external lateral ligament, the scaphoid, the trapezium, and the first metacarpal.

In the Hand below the Wrist.—Venæ comites and the deep branch of the ulnar nerve lie with the artery on (in front of) the proximal ends of the metacarpal bones and the interossei; and it is covered by the adductor pollicis, the long flexor tendons, the lumbricales, and the short flexors of the little finger and of its metacarpal bone. The deep arch is about an inch nearer the carpus than is the superficial.

Variations.—The radial frequently springs from the brachial in the arm, and may even arise from the axillary. Sometimes it is very small, its place being taken by branches from the ulnar and interosseous; and in this case it may be that no pulse can be found in the place where it is usually sought—just above the carpus, between the tendons of the brachio-radialis and the flexor carpi radialis.

Branches.—These are considered in three groups: those arising in the forearm, those given off in the wrist, and those in the hand below the wrist. In the first group are the radial recurrent, the muscular, the anterior radial carpal, and the superficial volar; in the second, the posterior radial carpal, the first dorsal interosseous, the dorsal artery of the thumb, and the dorsal artery of the index finger; in the third, the main artery of the thumb, the radial artery of the index finger, the palmar interosseous, the recurrent carpal, and the posterior communicating.

Branches in the Forearm.—The *radial recurrent*, the highest branch, starts from the outer side of the artery, and passes upward between the brachialis and brachio-radialis to the elbow-joint, and anastomoses with the superior profunda. *Muscular* branches supply muscles neighboring to the radial. The *anterior radial carpal* comes off near the lower border of the pronator quadratus,

runs across the radius, and anastomoses with the anterior ulnar carpal, forming with it the anterior carpal arch. The *superficial volar* (palmar) arises just above the wrist, passes between or over the muscles of the thenar eminence, and anastomoses with the ulnar in the palm, thus completing the superficial palmar arch.

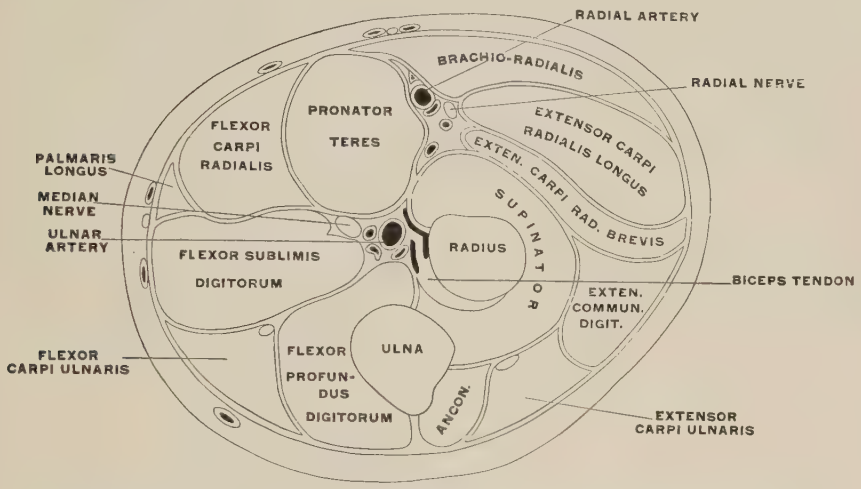

FIG. 498.—Horizontal section through the upper third of the right forearm—upper surface of the lower segment. In this and the two following figures the forearm is semipronated. (Braune.)

BRANCHES IN THE WRIST.—The *posterior radial carpal* crosses the dorsum of the carpus and anastomoses with the posterior ulnar carpal, thus being formed the posterior carpal arch (Fig. 502). From this are given off the *second* and *third dorsal interosseous*, which run down to the web of the fingers, where each divides

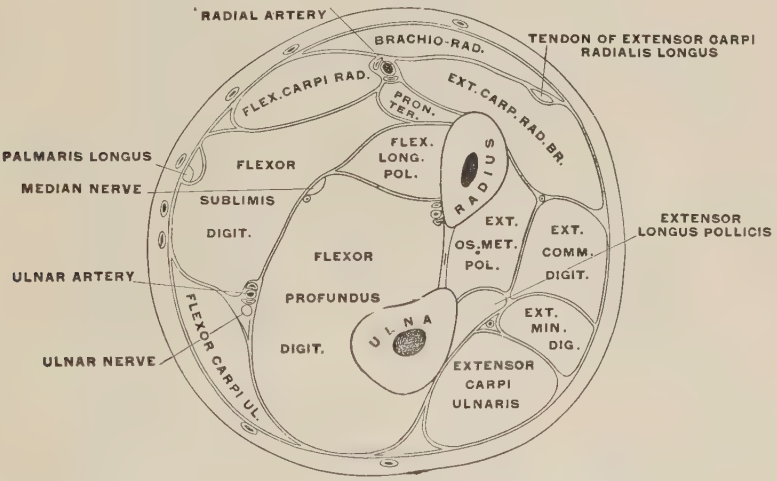

FIG. 499.—Horizontal section through the middle of the right forearm—upper surface of the lower segment. (Braune.)

into two branches (*dorsal digital*) supplying the contiguous sides of the medius and annularis, and annularis and minimus on the dorsal aspect. The arch has anastomoses with the posterior communicating branches of the deep palmar arch, and the anterior communicating of the digital branches of the ulnar. The *first dorsal interosseous*, sometimes called *metacarpal*, passes down in the second interosseous space, and is distributed through dorsal digital branches to the adjacent sides of the index and medius. It sometimes arises with the posterior radial

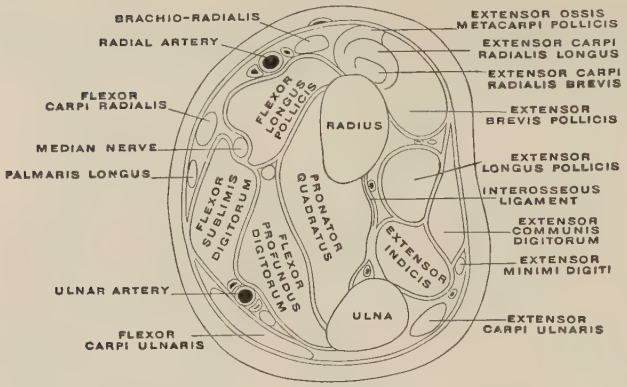

FIG. 500.—Horizontal section through the lower third of the right forearm. (Braune.)

carpal by a common trunk. It resembles the other dorsal interosseous arteries

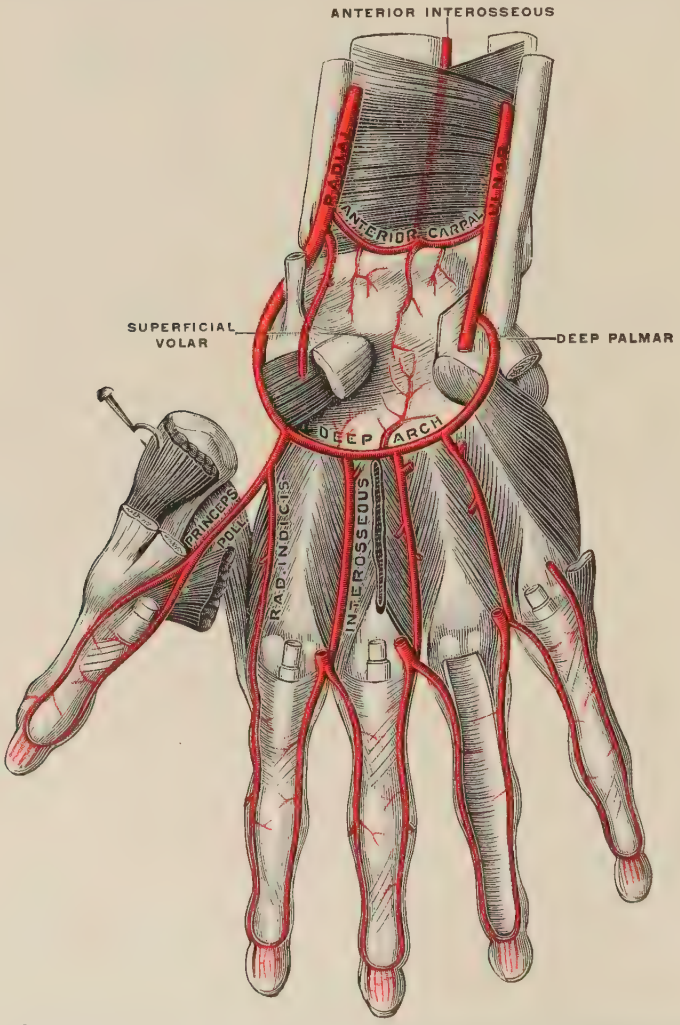

FIG. 501.—The deep palmar arch and its branches. The first metacarpal bone has been disarticulated to show the course of the radial around the wrist. Of the palmar interosseous, only the first is labelled. (Testut.)

in distribution and anastomoses. The *dorsal artery of the thumb* (dorsalis pollicis) arises either separately or from a trunk common to it and the dorsal artery of the

index, just before the radial pierces the abductor pollicis. It sends a branch down each side of the back of the thumb. The *dorsal artery of the index finger* (dorsalis indicis) is given off near the last described, or by a common trunk with it, and passes down on the back of the radial side of the forefinger.

Branches in the Hand below the Wrist (Fig. 501).—The *principal artery of the thumb* (princeps pollicis) runs along the ulnar side of the first metacarpal bone, and sends a branch down each side of the thumb on its palmar

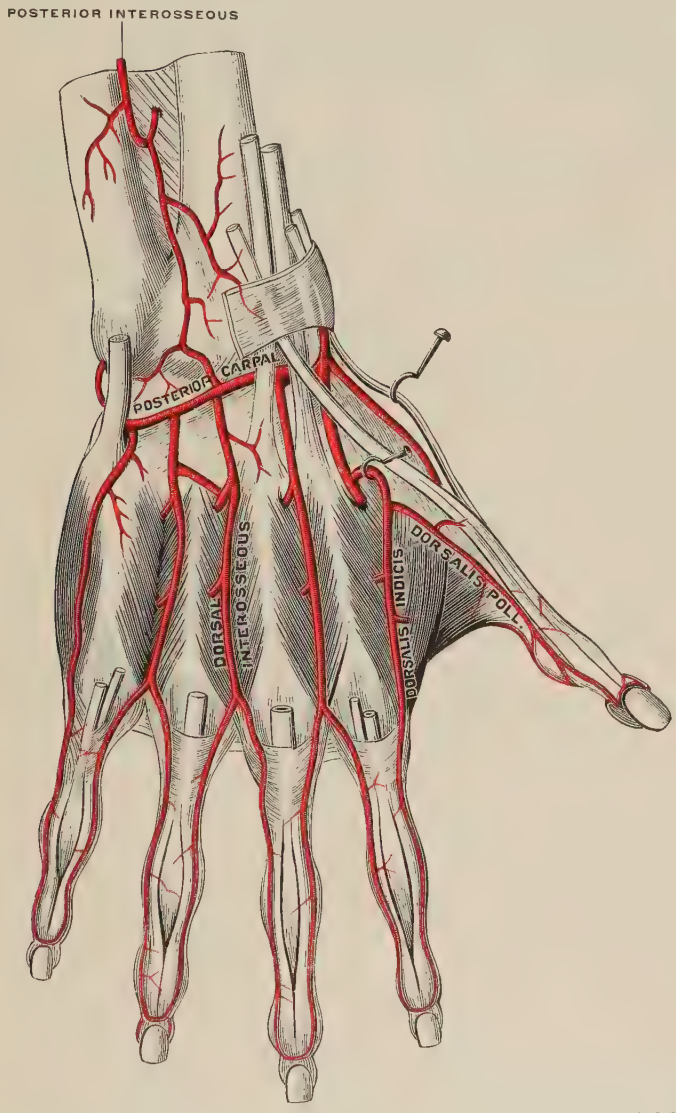

Fig. 502.—Arteries of the dorsum of the hand. Only the second of the dorsal interosseous is labelled. (Testut.)

aspect. The *radial artery of the index* (radialis indicis) arises close to the last described, or from a common trunk with it, and descends on the radial side of the forefinger. The *palmar interosseous*, three in number, arise from the deep arch, pass down in the second, third, and fourth metacarpal spaces, and inosculate with the digital branches from the ulnar at the web of the fingers. The *recurrent carpal*, of small size, and few in number, run upward, and inosculate with the anterior carpal arch. The three *posterior communicating* (perforating) run back-

ward through the upper part of the second, third, and fourth interosseous spaces, and anastomose with the dorsal interosseous arteries.

The derivation of the blood-supply of the digits of the hand is shown in the accompanying diagram (Fig. 503).

Summary (Fig. 503).—Four arches are formed by anastomoses between the radial and ulnar arteries—the posterior carpal, the anterior carpal, the deep palmar, and the superficial palmar.

The *posterior carpal arch* (Fig. 502), formed by the inosculation of the posterior carpal branches of the radial and the ulnar, crosses the dorsum of the wrist, and receives from above branches from the posterior and anterior interosseous arteries of the forearm. It gives off dorsal interosseous branches, which run

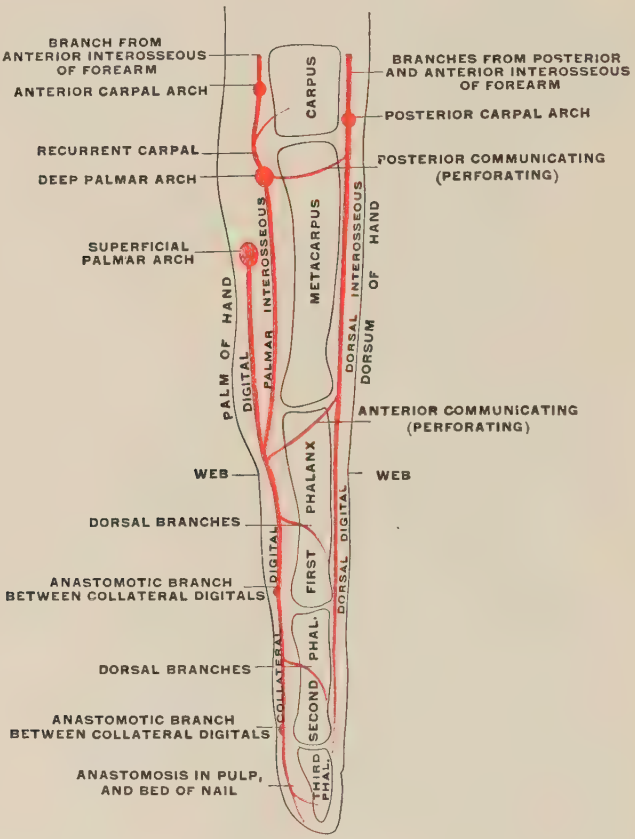

FIG. 503.—Diagram to show the arterial supply of the digits. The middle finger is shown in longitudinal section. (F. H. G.)

between metacarpal bones. Each of these divides at the web of the fingers into two dorsal digital arteries, which course at the sides of the posterior aspect of the adjacent fingers. The dorsal interosseous also send forward anterior communicating (perforating) branches, which join the digital and palmar interosseous where these unite. The posterior carpal arch is also connected with the deep palmar through the dorsal interosseous by means of the posterior communicating (perforating) arteries.

The *anterior carpal arch* (Fig. 501), formed by the anastomosis of the anterior carpal branches of the ulnar and radial, lies in the ventral part of the wrist, and receives from above branches from the anterior interosseous artery of the forearm, and from below recurrent carpal branches from the deep palmar arch.

The *deep palmar arch* (Fig. 501), made chiefly by the radial artery, but finished by the deep branch of the ulnar, rests on the proximal ends of the metacarpal bones. It gives offsets in three directions: recurrent carpal upward to the anterior carpal arch and the carpal articulations; posterior communicating (perforating) backward to the dorsal interosseous; and palmar interosseous downward to the junction of the digital and anterior communicating (perforating) in the web of the fingers.

The *superficial palmar arch* (Fig. 496), formed mainly by the ulnar artery and completed by the superficial volar, is situated between the palmar fascia and the flexor tendons, and is further from the carpus than the deep arch. It sends digital branches downward to the web of the fingers, where they are joined by the palmar interosseous from the deep arch, and the anterior communicating (perforating) from the dorsal interosseous. The artery thus formed immediately divides into two branches, which run to the adjacent sides of contiguous fingers on their palmar aspect as collateral digital arteries. Each of these last sends a dorsal branch backward to the hind surface near the middle of the first phalanx, and another near the middle of second phalanx. Proximal to each interphalangeal joint an anastomotic branch connects the two collaterals of each finger across the palmar aspect. The collaterals terminate in the pulp of the finger and the bed of the nail.

The foregoing description of the arterial supply of the digits does not precisely apply to the thumb and index finger; but their arteries are homologous to these, and their differences have been sufficiently set forth already.

THE BRANCHES OF THE THORACIC AORTA.

The branches of the thoracic aorta (Fig. 504) are the pericardial, the bronchial, the œsophageal, the posterior mediastinal, the intercostal, and the subcostal.

The *pericardial* are vessels of small size which supply the pericardium. The *bronchial* arteries supply the parenchyma of the lung with arterial blood. One is given off on the right side, and the left has two. The right one often is a branch of the first aortic intercostal. In addition to supplying the lungs the bronchial arteries send branches to the bronchial lymph-nodes and the œsophagus. The *œsophageal* arteries are small vessels, from three to five in number, supplying the œsophagus. The *posterior mediastinal* are small vessels, which pass backward to the thoracic vertebræ, and supply the lymph-nodes in the posterior mediastinum. The *intercostal* arteries arise from the posterior and lateral surfaces of the thoracic aorta and run outward to the intercostal spaces; they vary from nine to eleven in number. The upper two intercostal spaces are supplied, as already described, by the superior intercostal branch of the subclavian. Often, however, an aortic intercostal is sent to the second intercostal space. These vessels run in, or just below, the well-marked intercostal grooves on the inner surface and lower border of the ribs; and passing forward in the intercostal spaces to the anterior chest wall, they anastomose with the intercostal branches from the internal mammary and musculo-phrenic. In their course the intercostals give off posterior branches which pass backward through the intercostal spaces to reach the deep muscles of the back, which they supply. *Spinal* branches to the cord and its membranes and to the vertebral column are derived from these. The *collateral intercostal* branch runs from the main artery at a point opposite the angle of the rib to the upper border of the rib below and runs forward in the intercostal space; this branch is much smaller than the intercostal itself. In their course the intercostal arteries and their branches send vessels to the thoracic walls, the parietal layer of the pleura, and the muscles covering the thorax; several branches of good size are sent to the mammary gland, usually from the third and fourth intercostal arteries. Several of the lower intercostals run forward between the abdominal muscles, and supply them. The *subcostal* runs under the last rib, sustaining a relation to it

comparable to that of an intercostal to its rib, and is distributed to the abdominal wall.

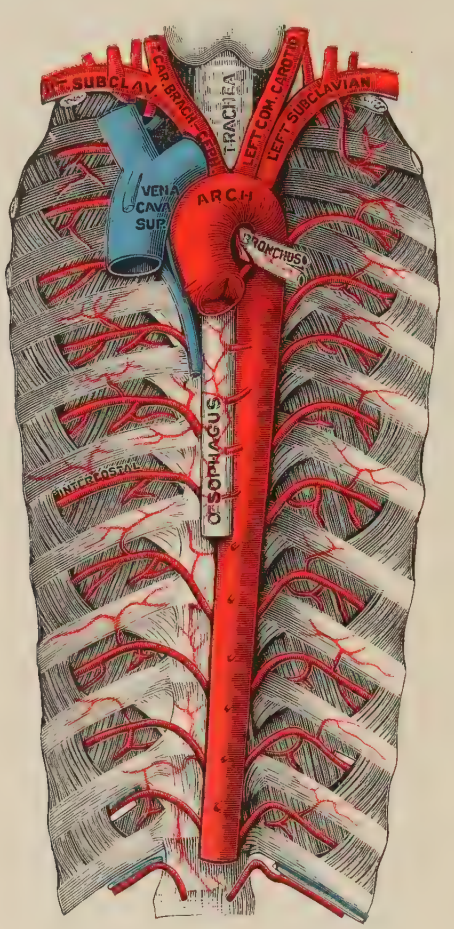

FIG. 504.—Thoracic aorta. (Testut.)

THE BRANCHES OF THE ABDOMINAL AORTA.

The branches of the abdominal aorta (Fig. 505) are conveniently divided for description into three groups—the visceral, the parietal, and the terminal. The *visceral group* includes the cœliac axis, the suprarenal, the superior mesenteric, the renal, the spermatic (or ovarian), and the inferior mesenteric; the *parietal group* consists of the phrenic, the lumbar, and the middle sacral; and the *terminal branches* are the right and left common iliac arteries.

The Cœliac Axis is given off from the abdominal aorta just below the aortic opening in the diaphragm; it is a stout, short trunk, about a half inch in length, and divides into the gastric, the hepatic, and the splenic arteries.

The **gastric artery** (Fig. 506) runs from the cœliac axis upward and to the left to the œsophageal orifice of the stomach; thence it passes from left to right along the small curvature of the stomach to the pyloric opening. In the first part of its course it gives off branches to the œsophagus; but most of its branches supply the stomach. The vessel is the smallest branch of the cœliac axis.

The **hepatic artery** (Fig. 506) passes transversely to the right to the right free edge of the small omentum; thence it passes upward in front of the foramen of Winslow to the transverse fissure of the liver, and divides into two branches to supply the right and left lobes of the liver. The relations of the hepatic artery,

the common bile-duct, and the portal vein are as follows: the vein behind, the duct in front at the right, the artery in front at the left.

The *branches* of the hepatic are the pyloric, the gastro-duodenal, the cystic, and the terminal. The *pyloric* branch passes to the pyloric end of the stomach, anastomosing with the gastric artery. The *gastro-duodenal* is a short, large vessel which passes downward and to the right behind the duodenum, and divides into the right gastro-epiploic and the superior pancreatico-duodenal. The right *gastro-*

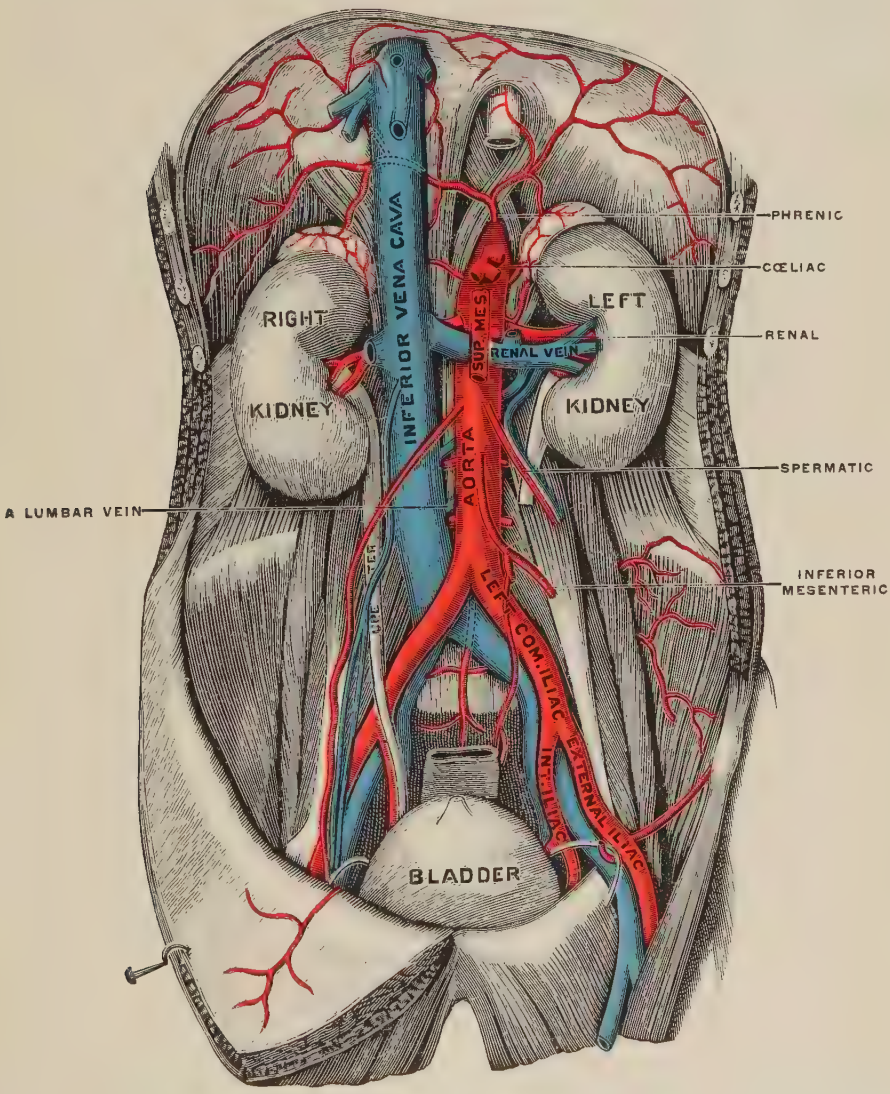

FIG. 505.—Abdominal aorta. (Testut.)

epiploic, a vessel of large size, courses from right to left along the great curvature of the stomach between the folds of the great omentum, supplies the stomach, and anastomoses with the left gastro-epiploic of the splenic. The *superior pancreatico-duodenal*, a small vessel, passes downward between the head of the pancreas and the duodenum, supplying these structures and anastomosing with the inferior pancreatico-duodenal of the superior mesenteric. The *cystic* artery supplies the gall-bladder. The *terminal* branches, right and left, supply the right and left lobes of the liver respectively.

The **splenic artery** is the largest branch of the cœliac axis; it runs from right to left, in a tortuous course, along the upper surface of the pancreas to the spleen.

The *branches* of the splenic artery are the pancreatic, the short gastric, the left gastro-epiploic, and the terminal. The *pancreatic* are numerous branches supplying the pancreas; one large trunk accompanies the main duct of the pancreas from left to right, and is called the great pancreatic. The *short gastric*, half a dozen vessels of small size, supply the left extremity of the stomach. The left *gastro-epiploic* winds along the great curvature of the stomach, and anas-

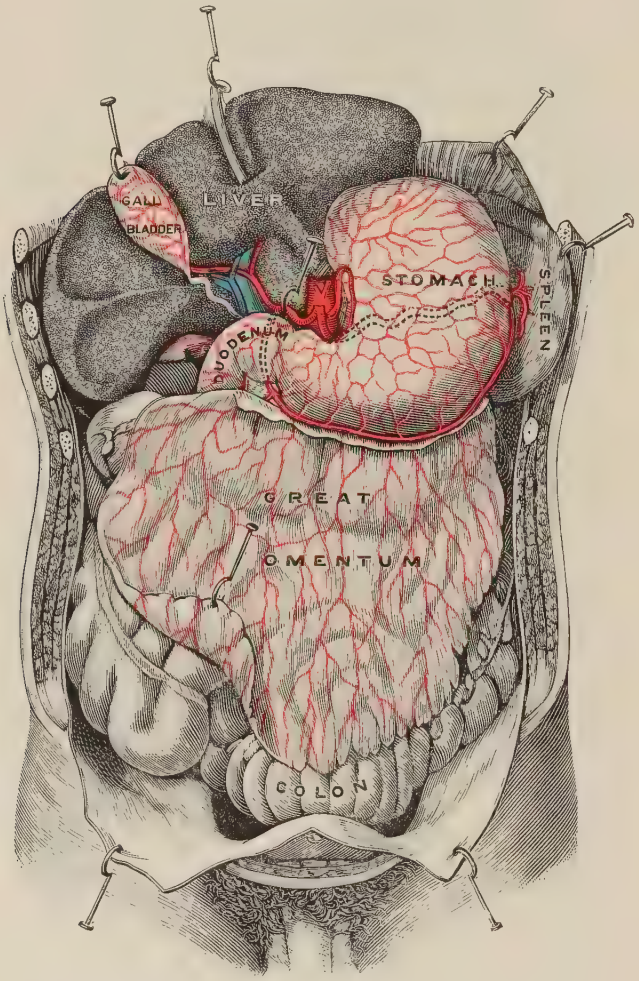

FIG. 506.—Arteries of the stomach, liver, and great omentum. (Testut.)

tomoses with the right gastro-epiploic. The *terminal* branches, five or more in number, radiate from the end of the artery, and enter the hilum of the spleen.

The Superior Mesenteric Artery (Fig. 507), a vessel of great size, arises from the anterior surface of the abdominal aorta below the cœliac axis and behind the pancreas. It passes downward and to the right between the folds of the mesentery, and breaks up into branches which supply the small intestines (except the upper part of the duodenum), the cæcum, and the ascending and transverse colon. It sometimes gives off a hepatic branch, and occasionally supplies the descending colon. Although the branches anastomose freely in the mesentery, when they reach the intestine and are distributed to it they pass between its walls at right angles to its long axis, and do not anastomose freely with one another; and, as a result of

this fact, a separation of the mesentery for any considerable extent from the intestine cuts off the blood-supply of the gut, and gangene results.

The *branches* of the superior mesenteric are the inferior pancreatico-duodenal, the middle colic, the right colic, the ileo-colic, and the arteries of the small intestine. The *inferior pancreatico-duodenal* runs between the duodenum and the head of the pancreas, supplying them, and anastomosing with the superior pancreatico-duodenal. The *middle colic* (colica media) is given off to the right, passes upward, and divides into two branches, the left inosculating with the left colic, the right with the right colic. It supplies the transverse colon. The *right colic* (colica dextra) runs to the ascending colon, and anastomoses above with the middle colic, below with the ileo-colic. The *ileo-colic* passes downward and to the right, and divides

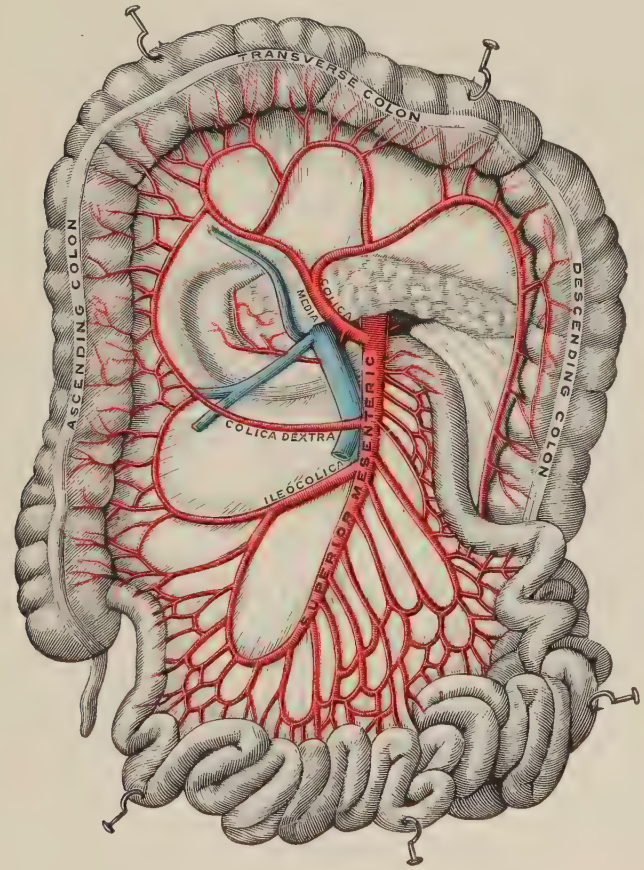

FIG. 507.—Superior mesenteric artery. (Testut.)

into two branches, one of which inosculates with the right colic, the other with the end of the superior mesenteric. The ileo-colic supplies the lower part of the ascending colon, the cæcum, and the appendix. The *arteries of the small intestine* (arteria intestini tenuis) pass in the mesentery to all portions of the small intestine except the upper part of the duodenum.

The Inferior Mesenteric Artery (Fig. 508).—The inferior mesenteric arises about an inch and a half above the termination of the aorta. It passes downward and to the left between the layers of the meso-colon, and supplies the left portion of the transverse colon, the descending colon, and the sigmoid colon. It is occasionally absent, its place being supplied by branches from the superior mesenteric.

Branches of the inferior mesenteric are the left colic, the sigmoid, and the

superior hemorrhoidal. The *left colic* (colica sinistra) supplies the descending colon, and anastomoses with the middle colic of the superior mesenteric and with the sigmoid branch. The *sigmoid* supplies the sigmoid colon, and anastomoses with the left colic and the superior hemorrhoidal. The *superior hemorrhoidal* is the direct continuation of the main artery, and passes in the sigmoid mesocolon to the beginning of the rectum. It anastomoses with the middle hemorrhoidal.

(For a description of the plan of division of the large intestine adopted in this work, the reader is referred to the chapter on the digestive organs.)

The Suprarenal Artery.—The *suprarenal* is a vessel of small size, which arises from the lateral surface of the aorta a little above the origin of the superior

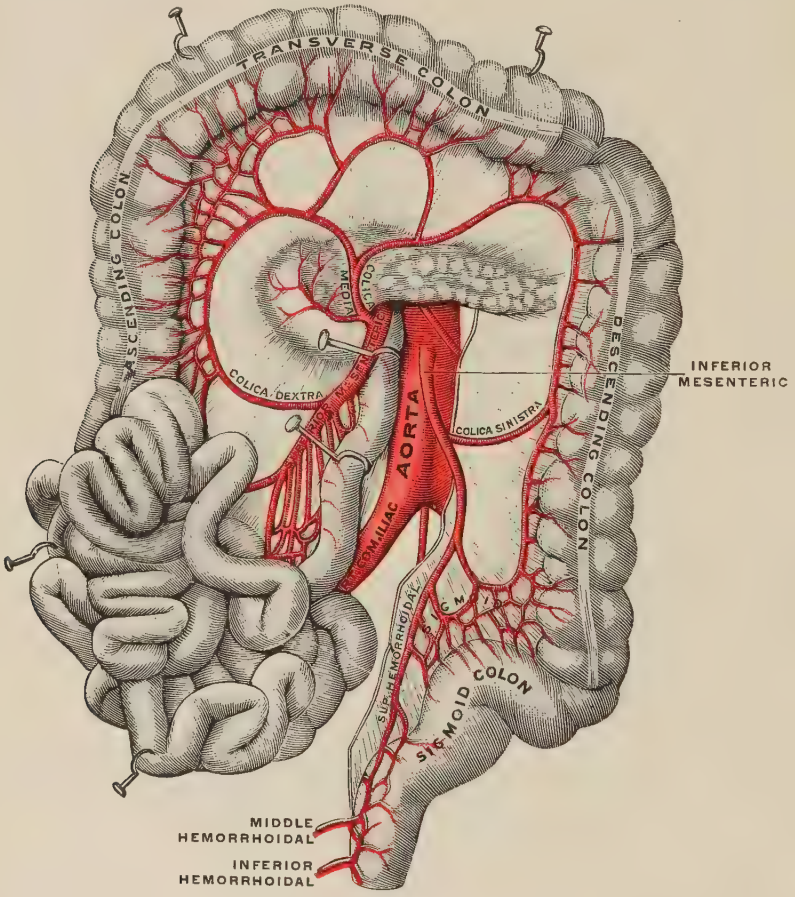

FIG. 508.—Inferior mesenteric artery. (Testut.)

mesenteric, and passes transversely outward to the suprarenal body, which it supplies.

The Renal Artery.—The *renal artery* is a vessel of very large size, which arises from the lateral surface of the aorta about half an inch below the origin of the superior mesenteric. It passes transversely outward to the hilum of the kidney, where it rapidly breaks up into branches supplying this organ. In its course it is in contact with the renal vein in front and the ureter behind. In one case in five an additional renal artery exists, and there may be several.

The Spermatic Artery.—The *spermatic artery* arises from the anterior surface of the aorta below the renal artery, passes downward behind the peritoneum and in front of the psoas magnus muscle, crosses the ureter, enters the internal abdominal ring, and forms one of the structures of the cord. It is dis-

tributed to the testicle. The spermatic may spring from the renal, and both spermatics may come from a common trunk. Occasionally the artery is double on each side.

The Ovarian Artery of the female is the homologue of the spermatic. It takes the same course behind the peritoneum, but as it reaches the broad ligament it passes between its folds to the ovary, and sends a branch of some size to the uterus. The ovarian is subject to the same variations as those occurring in the spermatic.

The Phrenic Artery arises from the aorta above the cœliac axis, sometimes those of the two sides coming from a single trunk. It passes upward to the diaphragm, which it supplies, and anastomoses with the musculo-phrenic and superior phrenic branches of the internal mammary.

The Lumbar Arteries are the homologues of the intercostals. They are four or five in number on each side, and arise from the postero-lateral surface of the aorta. Passing outward behind the psoas magnus muscle, between the transverse processes of the lumbar vertebræ, each divides into a dorsal and an abdominal branch. The dorsal branch passes backward, supplies the deep muscles of the back, and gives off a spinal branch, which furnishes branches to the spinal cord and membranes and to the lumbar vertebræ. The abdominal branch passes either in front of or behind the quadratus lumborum muscle to the muscles of the abdominal walls, winds forward, and anastomoses with the intercostal arteries and branches from the external iliac, which supply the walls of the abdomen.

The Middle Sacral (sacra media) **Artery** arises from the lower end of the abdominal aorta, passes down the middle line of the last lumbar vertebra and sacrum, and to the tip of the coccyx, where it terminates in the structure known as Luschka's gland. It anastomoses freely in front of the sacrum with the lateral sacral arteries, and gives some branches to the rectum. It is sometimes a branch from a lumbar artery, sometimes from the common iliac.

THE COMMON ILIAC ARTERIES.

The *common iliac arteries* (Figs. 505, 509) take their origin from the aorta where it bifurcates opposite the fourth lumbar vertebra. They pass downward and outward behind the peritoneum to the articulation between the last lumbar vertebra and the sacrum, and divide into the external and internal iliac arteries.

The **Relations** of the common iliac arteries differ on the two sides, owing to the fact that the common iliac veins both pass to the ascending vena cava, which is at the right of the aorta.

The *right common iliac* lies at first in front of the lower end of the vena cava inferior and the upper end of the left common iliac vein, and in the rest of its course ventral to the right common iliac vein. It is crossed in front by branches of the sympathetic nerve and, low down, by the ureter, and is covered by peritoneum, in front of which is a portion of the small intestine.

The *left common iliac* in its upper part is in front of the fourth and fifth lumbar vertebræ and the cartilaginous disc between them; in its lower part it is ventral to the left common iliac vein. Branches of the sympathetic nerve, the ureter, and the superior hemorrhoidal artery cross it anteriorly, and it is covered by peritoneum, in front of which is the sigmoid colon.

Branches.—As a rule no large branches are given off from the common iliac in its course; but it sends twigs to the psoas, the ureter, and the peritoneum. Its terminal branches are the internal iliac and the external iliac arteries.

The common iliac bifurcates into two great arteries. One, the internal iliac, is destined to supply a large part of the viscera contained in the pelvis, the pelvic walls, the external genitals, the buttock, structures about the hip-joint, and the inner part of the thigh. The other and larger, devoted to the nourishment of a portion of the abdominal wall and the greater part of the lower limb, runs as a continuous trunk from its origin to below the knee-joint, presenting in its course

no intrinsic lines of division. To facilitate description, however, this great vessel is divided into three portions by extrinsic landmarks. The first part extends from the bifurcation of the common iliac to the inguinal ligament, and is called the external iliac artery; the second runs from the inguinal ligament to the opening in the adductor magnus, and is known as the femoral artery; and the third, beginning at the adductor opening, ends at the lower border of the popliteus muscle, and is named the popliteal artery

Variations.—The length of the common iliac varies with the point of bifurcation of the abdominal aorta. When the abdominal aorta bifurcates high up, as it does sometimes, on the third lumbar vertebra, the common iliacs are long. When the bifurcation is opposite the fifth lumbar we find very short common iliacs. In rare cases the common iliac is absent, the external and internal iliacs

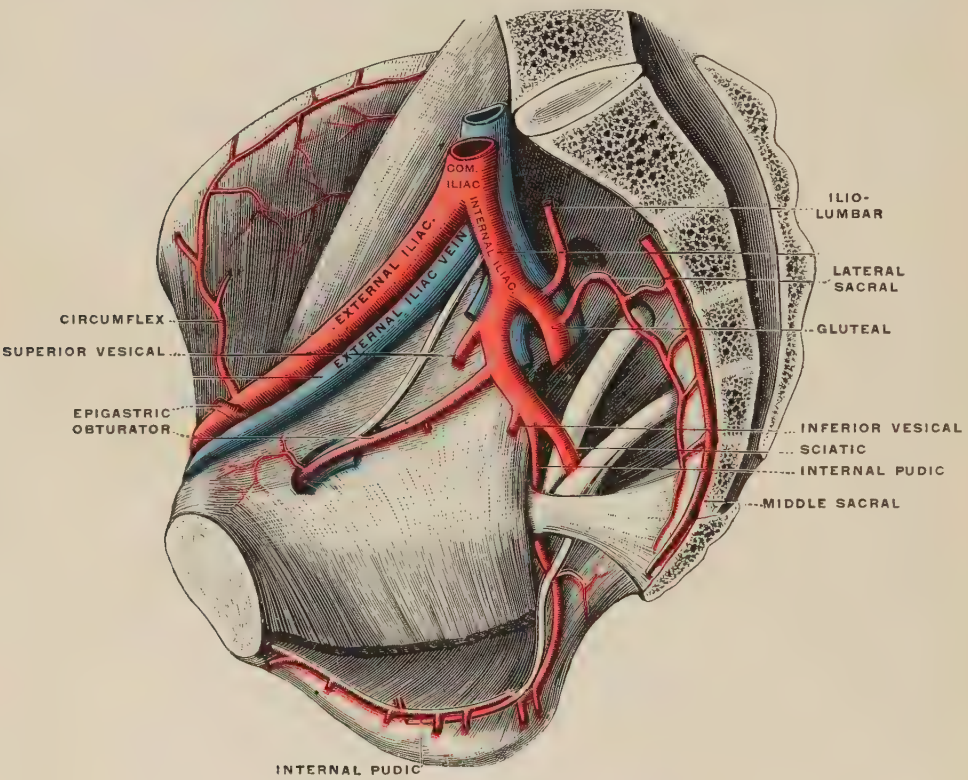

FIG. 509.—External and internal iliac arteries. (Testut.)

springing directly from the aorta. The common iliac sometimes gives off the middle sacral, a lateral sacral, a lumbar, or even the renal.

The Internal Iliac Artery.

The *internal iliac artery* (Fig. 509) takes its origin at the point of bifurcation of the common iliac opposite the articulation between the last lumbar vertebra and the sacrum, and runs downward to the upper border of the great sacro-sciatic foramen, where it bifurcates into an anterior and posterior trunk. Its branches are distributed to the viscera and walls of the pelvis, the genital organs, the perineum, the buttock, and the back and inner parts of the thigh.

Relations.—It is crossed in front by the ureter, and is covered by the peritoneum; and it has behind it the external and internal iliac veins, the lumbo-sacral cord, and the pyriformis.

Variations.—Its length varies from one to three inches. Sometimes the

branches are given off from the vessel without a previous division into an anterior and a posterior trunk.

Branches of the internal iliac artery. From the *anterior trunk* are given off the vesical, the middle hemorrhoidal, the uterine and vaginal in the female, the obturator, the internal pudic, and the sciatic arteries. From the *posterior trunk* are given off the ilio-lumbar, the lateral sacral, and the gluteal.

The Vesical Arteries are three in number, the superior, middle, and inferior vesical, which supply the bladder, ureter, prostate, and seminal vesicles. From the superior vesical a fibrous cord passes upward to the umbilicus. This is the remains of the hypogastric artery, which becomes obliterated after birth.

The Middle Hemorrhoidal Artery supplies the upper and middle portions of the rectum, anastomosing with the superior hemorrhoidal, a branch from the inferior mesenteric, and with the inferior hemorrhoidal, a branch from the internal pudic.

The Uterine Arteries are vessels of good size which run to the neck of the uterus, ascend along its lateral wall in the folds of the broad ligament to the fundus, and anastomose with the ovarian and vaginal arteries.

The Vaginal Arteries are, as a rule, two or three branches which supply the vaginal walls.

The Obturator Artery runs downward and forward to the upper part of the obturator foramen, and passes out of the pelvis through an opening in the upper part of the obturator fascia, to be distributed to the upper and inner aspect of the thigh.

From the portion of the artery within the pelvis several small branches are given off, an *iliac* (nutrient) branch to the iliac fossa, a *vesical* branch to the bladder, and a *pubic* branch, which runs upward along the inner margin of the femoral ring. In the thigh the obturator divides into an internal and an external branch. The *internal* passes downward on the inner surface of the thigh to be distributed to the adductor muscles. The *external* winds outward behind the femur to be distributed to the external rotators of the thigh.

The variations of the obturator are frequent, and should be carefully noted in connection with the study of femoral hernia. In almost one-third of dissections the vessel, instead of arising from the internal iliac, is a branch from the deep epigastric. In some cases it is given off from the external iliac. When the obturator is given off from the deep epigastric, it winds downward to the obturator foramen. In the majority of cases it is in close contact with the iliac vein, and, therefore, would be external to femoral hernia. In a small proportion of cases it winds along the inner border of the femoral ring and would be internal to a femoral hernia. In operations for the relief of strangulated femoral hernia this possibility must be borne in mind.

The Internal Pudic Artery (Figs. 509, 511) is one of the terminal branches into which the anterior trunk of the internal iliac divides, the other being the sciatic. It supplies the perineum and the external genitals. It is larger in the male than in the female. The internal pudic leaves the pelvis through the great sacro-sciatic foramen below the pyriformis muscle, winds over the spine of the ischium, enters the pelvis again through the small sacro-sciatic foramen, runs along the ascending ramus of the ischium and the descending ramus of the os pubis, enters the perineum, and bifurcates into the dorsal artery of the penis and the artery of the corpus cavernosum.

Branches.—The internal pudic gives off many small branches to the muscles contiguous to it. Besides these there arise the following: the inferior hemorrhoidal, the superficial perineal, the transverse perineal, the artery of the bulb, the artery of the corpus cavernosum, and the dorsal artery of the penis.

The **inferior hemorrhoidal** crosses the ischio-rectal fossa to reach the anal canal, to which it is distributed, as well as to the contiguous integument. It anastomoses with the other hemorrhoidal arteries.

The **superficial perineal** passes upward and forward beneath the superficial

perineal fascia, and supplies the superficial muscles and integument of the perineum, and the scrotum.

The **transverse perineal** (often a branch of the superficial perineal) runs along the transversus perinei, and supplies the back part of the perineum.

The **artery of the bulb** is given off from the internal pudic between the layers of the triangular ligament. It passes upward and inward to the bulb, which it supplies. This vessel and its branches often give rise to troublesome or even serious hemorrhage in the operation of external urethrotomy or median lithotomy,

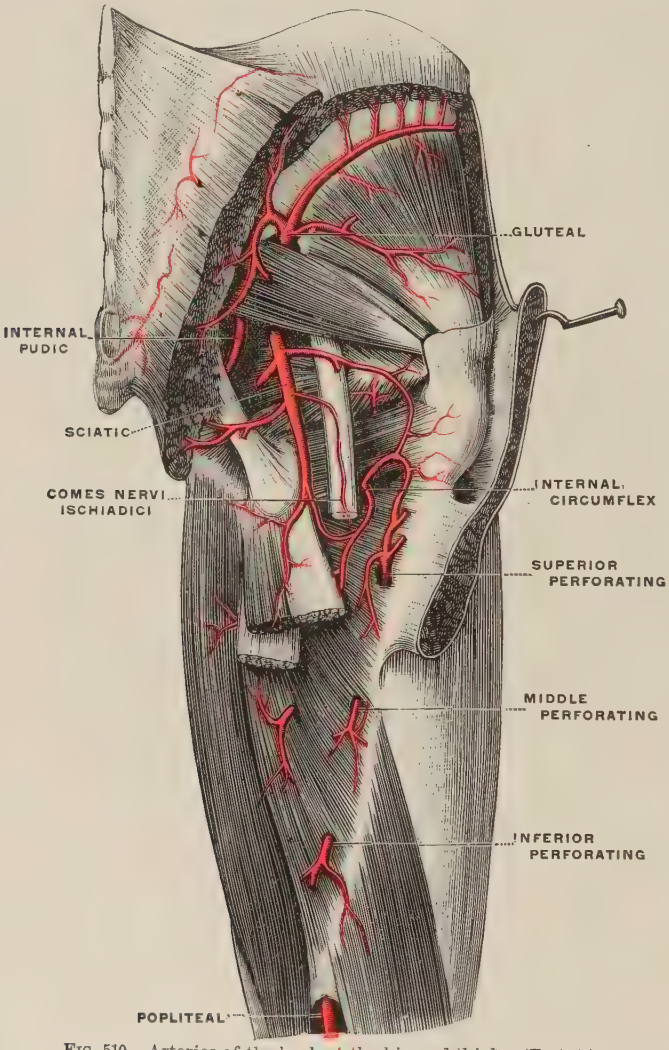

FIG. 510.—Arteries of the back of the hip and thigh. (Testut.)

in which the bulb is divided; and the artery may be wounded in operations for lateral lithotomy.

The **artery of the corpus cavernosum** runs upward and inward between the layers of the triangular ligament to the corpus cavernosum, which it supplies, breaking up into the cavernous spaces of that structure.

The **dorsal artery of the penis** passes upward to the suspensory ligament of the penis, which it pierces, and runs along the fibrous sheath of the upper surface of the penis to the glans, which it supplies. This vessel communicates with the artery of the corpus cavernosum.

The distribution of the internal pudic in the female is practically the same as in the male, but the vessel is smaller. The artery of the bulb supplies the bulbus vestibuli, and the terminal branches supply the clitoris.

The Sciatic Artery (Fig. 510) is one of the two terminal branches of the anterior trunk of the internal iliac. It leaves the pelvis through the great sacro-sciatic foramen below the pyriformis muscle, and passes down the back of the thigh in close company with the sciatic nerves to supply the buttock and upper portion of the posterior aspect of the thigh. It sometimes arises by a common trunk with the gluteal. Rarely it is a vessel of great size, and is the main source of blood for the lower extremity, practically taking the place of the femoral.

Within the pelvis the artery supplies small branches to the muscles with which it is in contact. After leaving the pelvis it gives off coccygeal, inferior gluteal, muscular and articular branches, and a branch which accompanies the sciatic

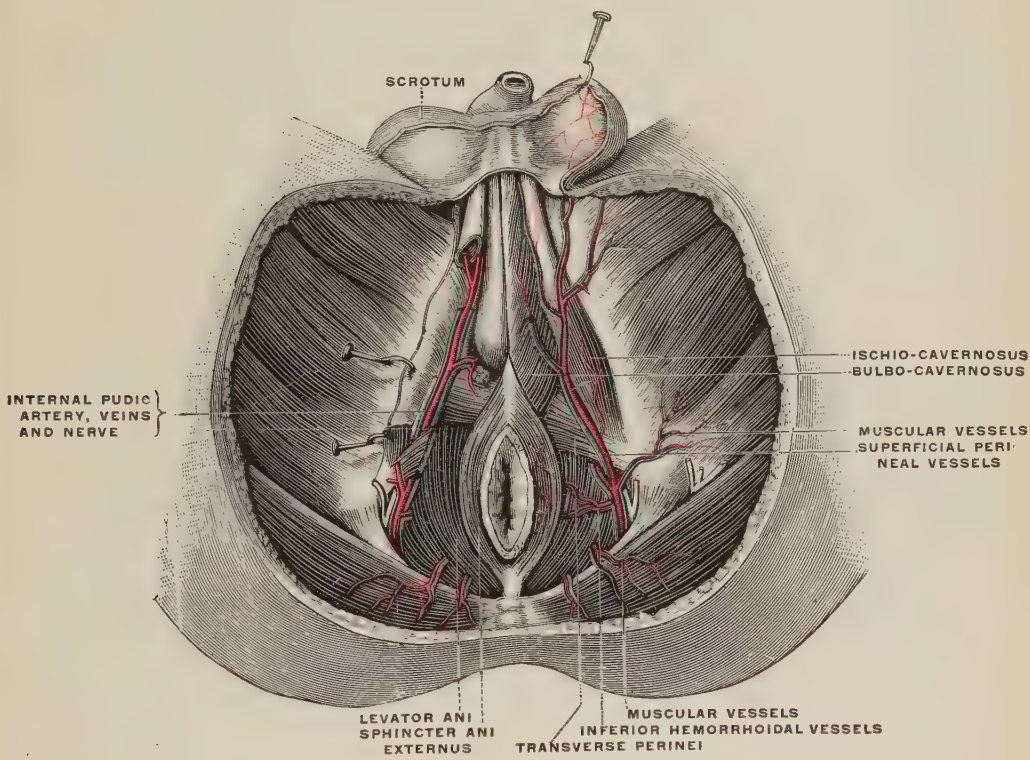

FIG. 511.—Arteries of the perineum. (Testut.)

nerve. The *coccygeal* branch supplies the tissues about the coccyx. The *inferior gluteal* branches supply the lower portion of the gluteus maximus muscle. The *comes nervi ischiadici* ("companion of the sciatic nerve") supplies the great sciatic nerve, running for some distance along its sheath. The *muscular* branches are distributed to the external rotator muscles of the thigh. The *anastomotic* takes part in the crucial anastomosis, which will be described later. The *articular* branch runs to the capsular ligament of the hip.

The *branches from the posterior trunk* of the internal iliac are the gluteal, the ilio-lumbar, and the lateral sacral.

The Gluteal Artery (Fig. 510) is a vessel of large size which leaves the pelvis through the great sacro-sciatic foramen above the pyriformis muscle. It then divides into a superficial and a deep branch. The superficial runs into the gluteus maximus muscle, and is distributed to its substance. The deep branch runs between the gluteus medius and gluteus minimus, and breaks up into two sets

of vessels, a superior and inferior, which supply these muscles. *Variations* of the gluteal are rare. The gluteal may arise by a common trunk with the sciatic, or may be absent, and its place be taken by a large branch from the femoral.

The **Ilio-lumbar Artery** passes outward behind the iliac vessels and psoas magnus muscle. Behind the muscle it divides into two branches; the lumbar, which is distributed to the psoas magnus and the quadratus lumborum muscles, and the iliac, which supplies the iliacus.

The **Lateral Sacral Arteries** are two in number, sometimes arising from a common trunk. They pass to the anterior surface of the sacrum, where they are distributed to the pyriformis and coccygeus muscles, and to the sacral nerves. Branches are sent into the anterior sacral foramina, where they supply the contents of the sacral canal and the bone.

The External Iliac Artery.

The *external iliac artery* (Figs. 505, 509), larger than the internal and about four inches long, arises from the division of the common iliac opposite the articulation between the last lumbar vertebra and the sacrum, and passes downward and outward behind the peritoneum and along the inner border of the psoas magnus muscle to the inguinal (Poupart's) ligament, where it becomes the femoral.

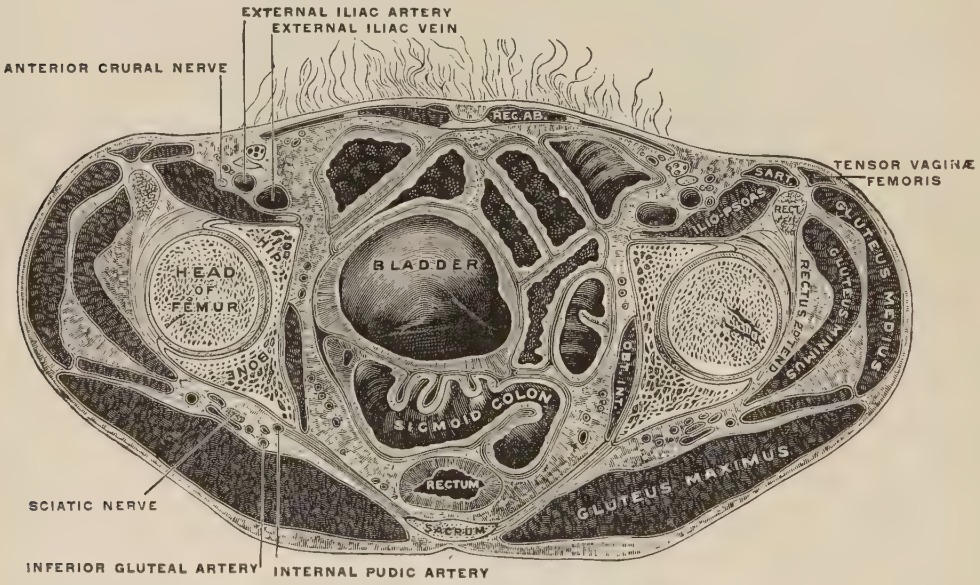

FIG. 512.—Horizontal section three inches below the sacral promontory. The upper surface of the lower segment. (Testut.)

Relations (Fig. 512).—*In front* the peritoneum separates it from intestines; and in its lower part are the spermatic vessels, a branch of the genito-crural nerve, the deep circumflex iliac vein, and some lymph-nodes. *Behind* are the external iliac vein above, and the psoas magnus muscle below. *At the outer side* is the psoas. *At the inner side* are the external iliac vein, some lymph-nodes, and, in the male, the vas deferens.

Variations.—The external iliac is sometimes of small size; its resulting femoral is small, and the lower extremity usually then receives a large part of its blood supply from a large sciatic artery. The obturator is occasionally a branch of the external iliac.

The **Branches** of the external iliac are the deep epigastric, the deep circumflex iliac, and muscular.

The **Deep Epigastric** (Fig. 485) arises from the external iliac just above the inguinal ligament. It passes inward and a little downward at first, then upward and inward between the transversalis fascia and the peritoneum to the posterior surface of the rectus muscle, continues upward along the lower and inner margin of the internal abdominal ring, breaks into branches, which are distributed to the substance of the rectus, and anastomoses with the superior epigastric branch of the internal mammary.

Variations.—The deep epigastric may take origin higher up from the external iliac, from any part of its course. As already noted, the deep epigastric very often gives off the obturator artery. It has an important relation to inguinal hernia. The vessel in the first part of its course is situated between the two rings, and will therefore be internal to an oblique hernia, and external to a direct hernia.

The *Branches* given off in the course of the deep epigastric are the cremasteric, pubic, and muscular. The *cremasteric* artery supplies the coverings of the spermatic cord. The *pubic* winds around the inner margin of the femoral ring, and anastomoses with a similar branch from the obturator. *Muscular* branches are distributed to the muscles of the abdominal wall.

The **Deep Circumflex Iliac Artery** arises from the outer surface of the external iliac just above the inguinal ligament. It runs upward and outward, covered by the transversalis fascia, to the anterior superior spine of the ilium. It then runs along the crest of the ilium between the transversalis and internal oblique to about its centre, pierces the abdominal muscles, and breaks up into branches supplying them. In its course it gives branches to the various adjacent muscles, and to the skin.

The Femoral Artery.

The *femoral artery* (Figs. 513, 515), the continuation of the external iliac, begins at the lower margin of the inguinal ligament, midway between the anterior superior iliac spine and the symphysis pubis. It runs down along the anterior and inner part of the thigh to the femoral opening in the adductor magnus, and there ends in the popliteal. Its course lies under the upper two-thirds of a line drawn from its origin to the adductor tubercle, the thigh being somewhat flexed and abducted. The proximal part of the artery is near the surface, and runs from the base to the apex of a region called Scarpa's triangle; the distal portion is deeply situated in a fibro-muscular passage named Hunter's canal. About two inches from its beginning the artery gives off a very large branch, the profunda (deep femoral); and for the purpose of discrimination the portion of the vessel above this point is called the *common femoral*, that below it the *superficial femoral*.

Scarpa's Triangle has its base upward at the inguinal ligament, its outer side is formed by the inner margin of the sartorius, and its inner by the mesial border of the adductor longus. In its floor from without inward are seen the iliacus, psoas, pectineus, adductor brevis, and adductor longus. It contains the upper part of the femoral artery and the branches given off from it, the corresponding portion of the femoral vein, the anterior crural nerve, and the superficial inguinal lymph-nodes.

Hunter's Canal is a three-sided, fibro-muscular canal, occupied by the distal portion of the femoral vessels and the internal saphenous nerve. A strong fibrous layer, extending in front of the vessels, and between the vastus internus on the outer side and adductores magnus and longus on the inner, forms its anterior boundary, and the muscles named make its other sides. Superficial to the canal is the sartorius muscle.

Variations.—The femoral may be very small, and terminate in the upper part of the thigh; and the lower limb in such cases receives its blood-supply in large part from a very large sciatic artery. The femoral has been seen to divide into two vessels and then unite to form a single popliteal. Variations in branches are frequently noted. The circumflex arteries, one or both, are sometimes derived

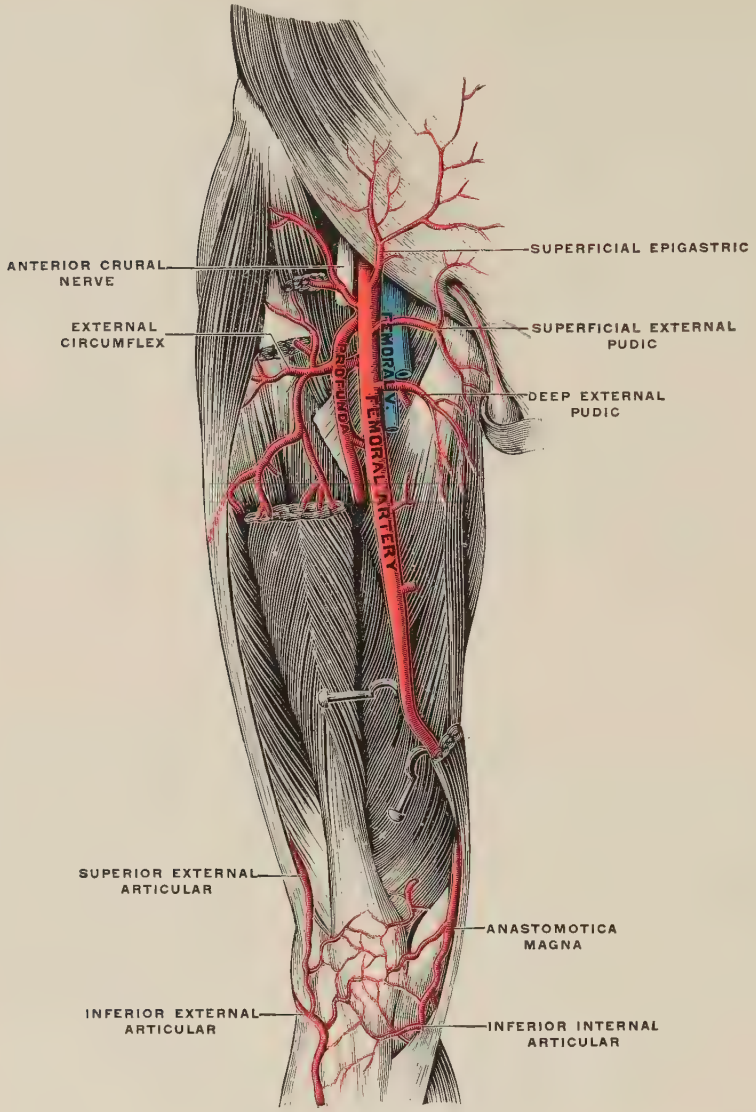

FIG. 513.—Femoral artery. (Testut.)

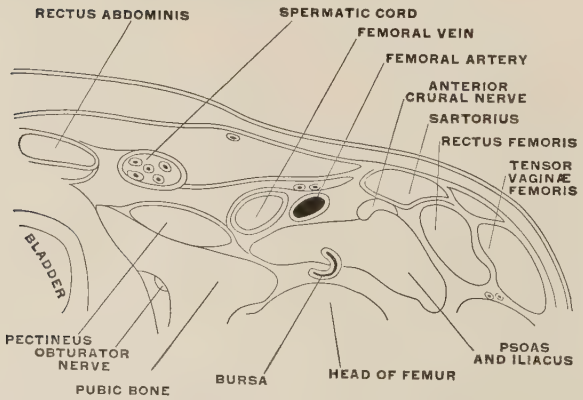

FIG. 514.—Horizontal section just above the symphysis pubis—the upper surface of the lower segment. The right side and ventral part of the section are in view. (Braune.)

from the common femoral instead of from the profunda. The profunda is sometimes given off from the inner side of the vessel instead of the outer side.

The Common Femoral Artery.

Relations (Fig. 514).—*In front*, in addition to the skin and subcutaneous areolar tissue, are the superficial inguinal lymph-nodes, the iliac portion of the fascia lata, branches of the genito-crural nerve, and the superficial circumflex iliac vein. *Behind*, in the upper part, the psoas intervenes between the vessel and the capsular

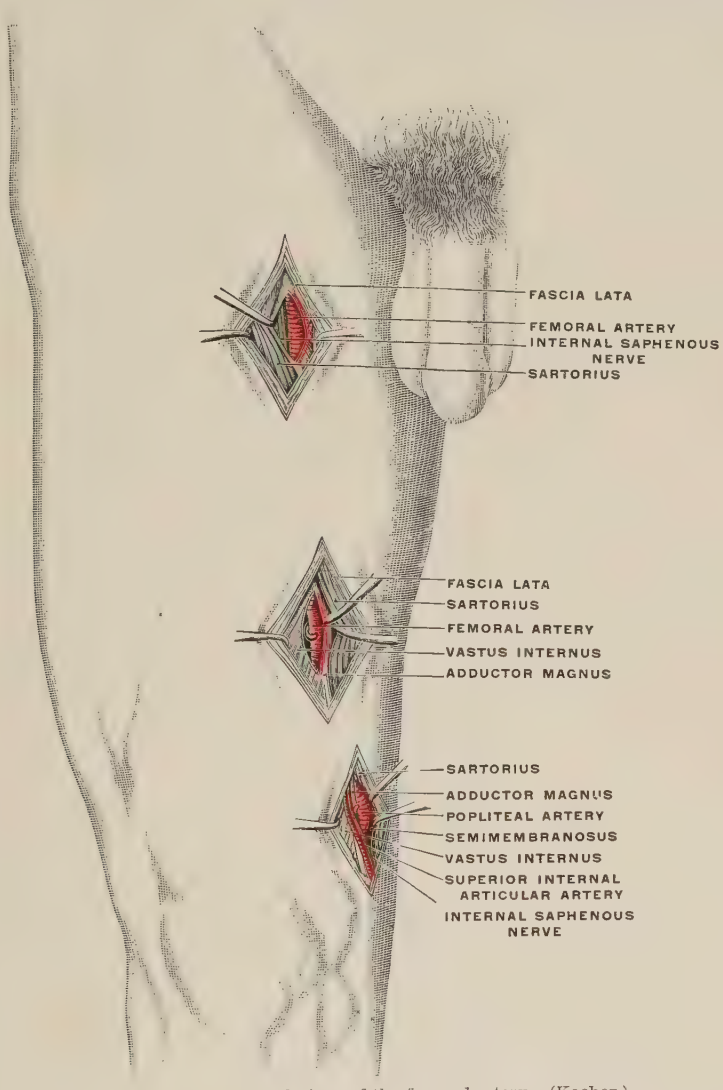

FIG. 515.—Surgical relations of the femoral artery. (Kocher.)

ligament of the hip-joint, and in the lower the pubic portion of the fascia lata separates it from the pectineus. *On the outer side* is the anterior crural nerve at a little distance. *On the inner side*, contained in the same sheath, is the femoral vein.

The Superficial Femoral Artery.

Relations (Figs. 516, 517).—**In Scarpa's triangle.**—*In front*, beneath the skin, areolar tissue, and fascia lata, is the internal cutaneous branch of the anterior

crural nerve. *Behind* are the pectineus and the profunda vessels above, the femoral vein below—the latter passing from within outward behind the artery. In the lower part is the adductor longus. *At the outer side* is the long saphenous nerve. *At the inner side* is the femoral vein.

In Hunter's Canal. *In front* are the internal saphenous nerve, and the fibrous wall of the passage, superficial to which is the sartorius. *Behind* are the femoral vein and the converging muscular walls of the canal. *At the outer side* are the vastus internus, and, below, the femoral vein. *At the inner side* are the adductor longus above, and the adductor magnus below.

The **Branches** of the femoral are the superficial epigastric, superficial circumflex iliac, superficial external pudic, deep external pudic, profunda (deep femoral), anastomotica magna, and muscular.

The Superficial Epigastric arises just below the inguinal ligament, passes through the saphenous opening, and turns upward onto the abdomen in front of

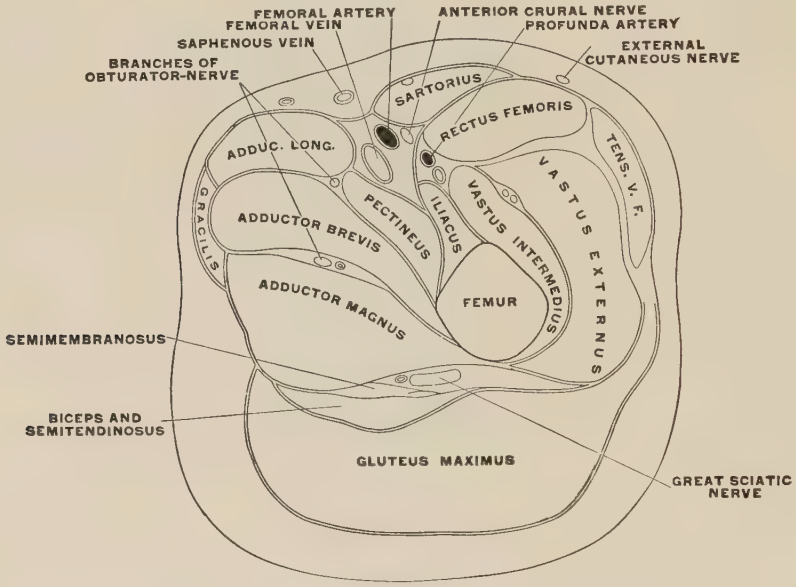

FIG. 516.—Horizontal section of the right thigh near the perineum—upper surface of lower segment. (Braune.)

the external oblique muscle, supplying the superficial inguinal lymph-nodes, and the integuments nearly up to the navel.

The Superficial Circumflex Iliac is given off near the preceding, and runs parallel to the inguinal ligament to the anterior superior iliac spine, and supplies the integments and superficial inguinal lymph-nodes.

The Superficial External Pudic arises from the inner side a little below the last described, passes through the saphenous opening, then goes upward and inward, crossing the spermatic cord (or round ligament), and supplies the integuments in the hypogastric region and the skin of the external genitals.

The Deep External Pudic arises below or in common with the superficial, runs inward beneath the fascia lata, and supplies the skin of the scrotum (or labium majus) and the perineum.

The Profunda (Fig. 513) (*deep femoral*) supplies the most of the structures of the thigh. It is the largest branch of the femoral, and arises from the outer side, two inches or less from the upper end of the artery. It passes outward, downward, and backward, goes behind the femoral artery, and then down on the posterior surface of the adductor longus, perforates the adductor magnus, and ends

in the posterior, lower, and inner part of the thigh, the terminal vessel being sometimes considered the fourth perforating branch.

Relations.—Behind from above downward are the iliacus, pectineus, adductor brevis, and adductor magnus. *In front*, besides the skin and fasciæ, are the anterior crural nerve; then the femoral and profunda veins above, and the adductor longus below. *At the outer side* is the vastus internus. *At the inner side* above is the pectineus.

The *Branches* of the profunda are the external circumflex, the internal circumflex, and the three perforating.

The *External Circumflex* is given off from the outer side of the profunda, passes outward behind the sartorious and rectus among the branches of the anterior crural nerve, and divides into three sets of branches—the ascending, transverse, and descending. The *ascending* runs upward, and supplies the abductors of the thigh and the hip-joint. The *transverse* goes outward and winds around the femur below the great trochanter, supplying adjacent muscles. The *descending* passes down to the knee behind the rectus, and supplies that muscle and the

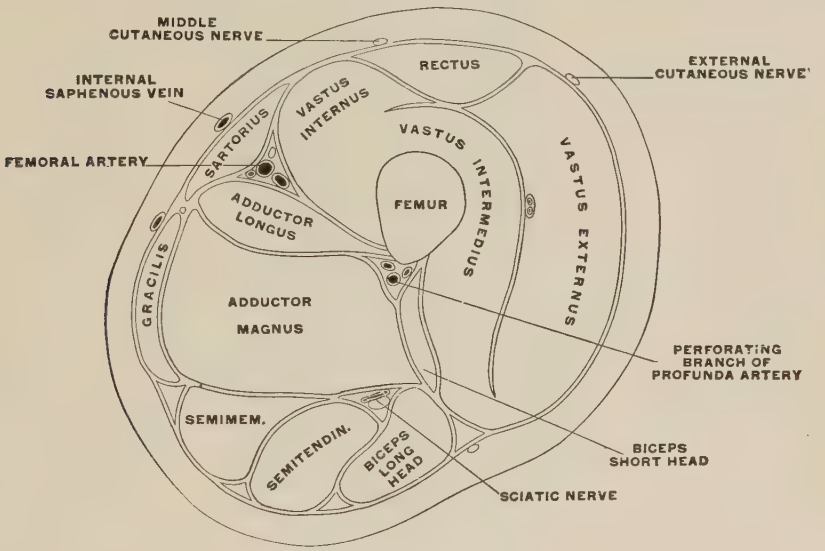

FIG. 517.—Horizontal section through the middle of the right thigh—upper surface of the lower segment. (Braune.)

vasti externus and intermedius. The *Internal Circumflex* arises from the inner side of the profunda nearly opposite the external, winds around the femur between the psoas and pectineus to the small trochanter, and gives off ascending and transverse branches. The *ascending* follows the obturator externus to the digital fossa. The *transverse* runs between the quadratus and adductor magnus, and inosculates with the external circumflex, sciatic, and superior perforating, forming the *crucial anastomosis*. The internal circumflex is distributed to the adductor group, the obturatur externus, the quadratus, and the hip-joint. The *Perforating*, usually three in number, named from their piercing the adductor magnus, are given off one above the adductor brevis, one in front of it, and one below it. Passing through the adductor magnus near the femur, they anastomose with one another, and are distributed principally to the flexors of the leg (hamstring muscles), the first additionally going to the adductor group and the gluteus maximus, and either the second or third giving the *nutrient* artery to the femur.

The preceding branches of the femoral all come from the common trunk.

In Scarpa's triangle the superficial femoral gives off no large branches, but only twigs to neighboring muscles.

In Hunter's canal several muscular branches arise, and also the anastomotica magna.

The Anastomotica Magna springs from the inner side of the femoral just above the lower end, and quickly divides into two branches. The *superficial* branch is distributed to the skin of the upper mesial surface of the leg; the *deep* branch runs down in front of the adductor magnus, enters into anastomosis in front of the knee, and sends branches to the joint and to the vasti internus and intermedius.

THE POPLITEAL SPACE.

The *Popliteal Space* ("ham-space") is a lozenge-shaped area at the back of the knee-joint. It is bounded above by the semitendinosus and semimembranosus

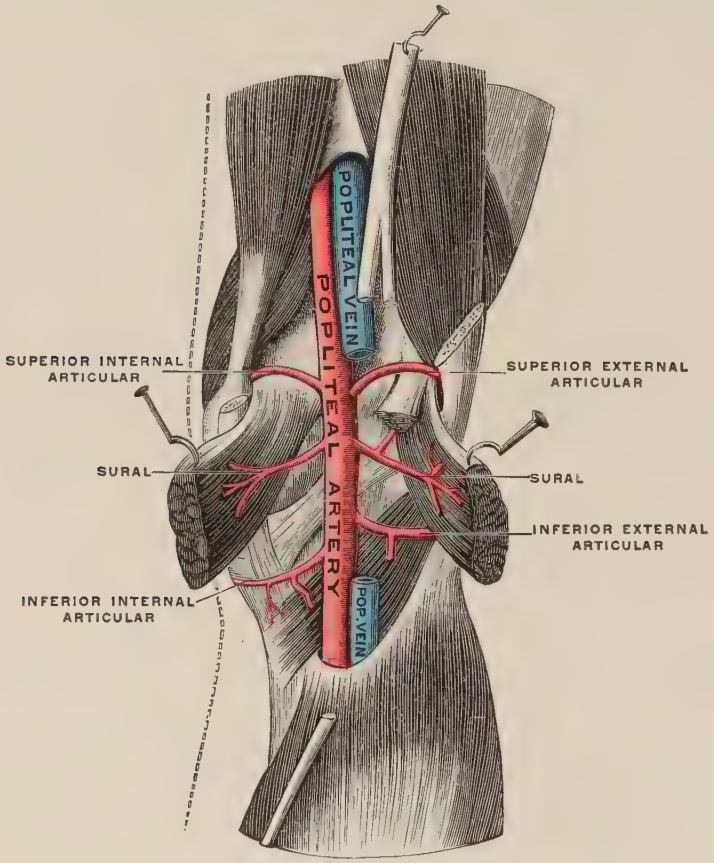

FIG. 518.—Popliteal artery. (Testut.)

mesially, and the biceps externally; below by the inner head of the gastrocnemius mesially, its outer head and the plantaris externally. Its floor from above downward presents the posterior surface of the femur, the posterior ligament of the knee, and the popliteus covered by its fascia. Its principal contents are the popliteal artery, the popliteal vein, and the internal popliteal nerve, these three standing in the order given, the artery deepest. The external popliteal nerve runs along the outer and upper wall of the space, sheltered by the biceps. A large bursa and some lymph-nodes are also found, together with adipose tissue. Before dissection the sides of the space are hardly an inch apart at the farthest. In flexion of the knee a depression is visible, but in extension there is a little bulging.

The Popliteal Artery.

The *Popliteal Artery* (Figs. 518, 520) is the third and last portion of the great arterial trunk, which begins at the bifurcation of the common iliac. It starts at the adductor opening, passes downward and a little outward through the popliteal space from its upper to its lower angle, and divides at the lower border of the popliteus muscle into the posterior and anterior tibial. It supplies the limb below its origin.

Relations.—*In front* are the structures that form the floor of the popliteal space. *Behind* are the popliteal vein, which is external to it above, and, crossing obliquely, gets to its mesial side below; the internal popliteal nerve, which is superficial to the vein, and crosses it from without inward; the semi-membranosus above, the gastrocnemius and plantaris below. At the inner and outer sides are the muscles which bound the popliteal space.

Variations.—The popliteal sometimes divides into three branches, the anterior tibial, the posterior tibial, and the peroneal; at times into the anterior tibial and

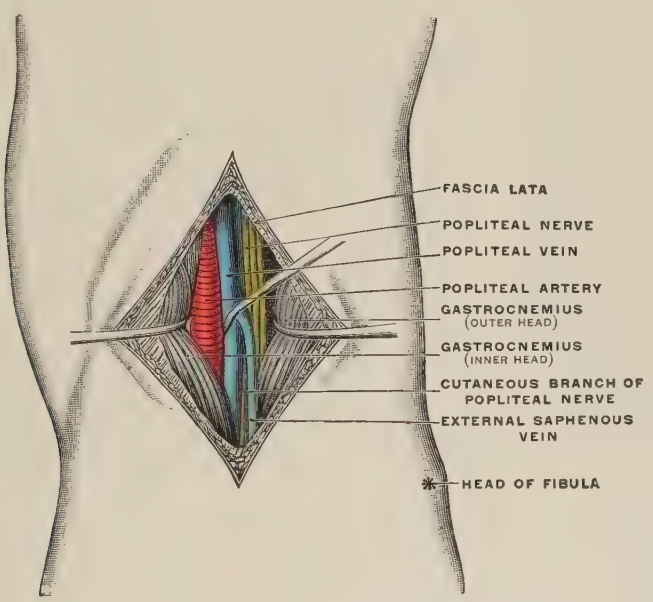

FIG. 519.—Surgical relations of the popliteal artery. (Kocher.)

peroneal, the peroneal supplying the place of the posterior tibial. Sometimes a high division of the popliteal occurs opposite the knee-joint.

Branches.—The popliteal has muscular, cutaneous, articular, and terminal branches. The *muscular* occur in two sets: the *superior*, which supply the hamstring muscles and the adductor magnus; and the *inferior* or *sural* ("calf"), which are distributed to the gastrocnemius, plantaris, soleus, and popliteus. The *cutaneous*, given off low down, supply the integument of the calf. The *articular* branches are five in number—the superior internal, the superior external, the azygos, the inferior internal, and the inferior external—and supply the joint and contiguous structures. The *azygos* arises from the anterior surface of the popliteal, and passes forward into the joint. The *superior* wind around the limb above the joint, the *inferior* just below it, and participate in intricate anastomoses about the patella with one another and with branches from neighboring arteries. The *terminal* branches of the popliteal are the posterior tibial and the anterior tibial.

The Posterior Tibial Artery.

The *Posterior Tibial Artery* (Figs. 520, 521), larger than the anterior, runs downward, and then downward and a little inward from the bifurcation of the popliteal to a point between the internal malleolus and the calcaneum, where it divides into the external and internal plantar. As its name implies, it is in the back part of the leg on the tibial side. It courses between the superficial and deep layers of muscles, and in front of the deep transverse fascia. It supplies through the branches given off in its course substantially the whole of the leg, excepting the structures in front of the interosseous membrane.

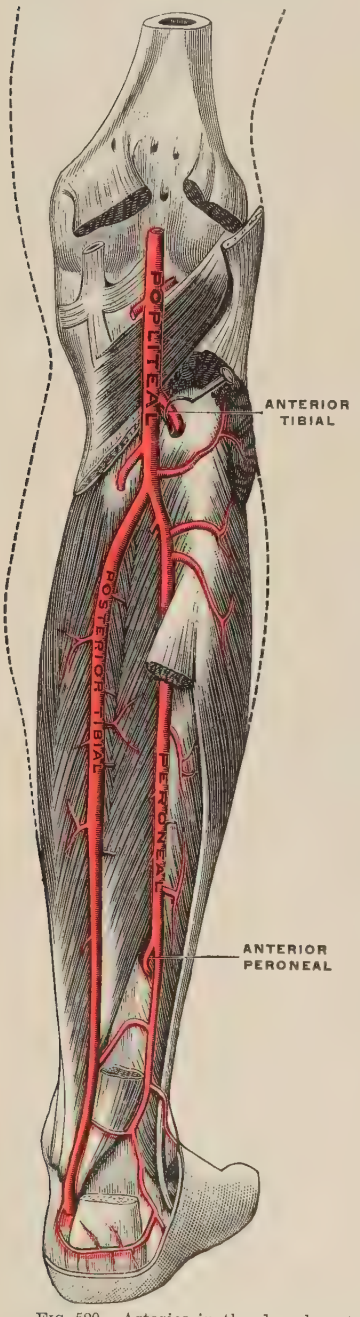

FIG. 520.—Arteries in the dorsal part of the leg. (Testut.)

Relations (Figs. 526–528).—*In front*, in order from above downward, are the tibialis posterior, the flexor longus digitorum, the tibia, and the internal lateral ligament of the ankle. *Behind* are the posterior tibial nerve in the greater part of its course, the deep transverse fascia, and, at its lowest part, the internal annular ligament, and the abductor hallucis. *At each side* is a companion vein.

Between the tip of the inner malleolus and the calcaneum the parts are arranged from before backward thus: the tibialis posterior, the flexor longus digitorum, the posterior tibial artery, the posterior tibial nerve, and the flexor longus hallucis—the artery in the middle of the group.

Variations.—The posterior tibial may be small, its place being taken by a large peroneal artery. The vessel may arise from a high division of the popliteal.

Branches.—The posterior tibial gives off the peroneal, the muscular, the nutrient, the communicating, the internal calcaneal, the external plantar, and the internal plantar.

The Peroneal (Figs. 520, 522), so called from its location near the fibula, is a large vessel and is given off about an inch below the origin of the posterior tibial. It runs outward and downward to the fibula, and then downward along its postero-internal border, either on or in the substance of the flexor longus hallucis, then across the lower tibio-fibular articulation, and ends in branches on the back of the external malleolus and outer side of the calcanenm. It is distributed to the fibula, and other structures in the back and outer side of the leg, and the outer half of the tarsus.

Branches.—The peroneal has the anterior peroneal, muscular, nutrient, communicating, which are given off in its course, and the external calcaneal and posterior peroneal, which are terminal. The *anterior peroneal* arises two inches above the outer ankle, runs forward through the interosseous membrane, and is distributed to the structures in the front and outer parts of the tarsus. The *muscular* supplies the neighboring muscles. The *nutrient* is the medullary artery of the

fibula. The *communicating*, a low branch, anastomoses with the *communicating* of the posterior tibial about an inch above the ankle-joint behind. The *external calcaneal* goes to the outer side of the os calcis. The *posterior peroneal* runs behind the external malleolus to the rear and outer surfaces of the calcaneum.

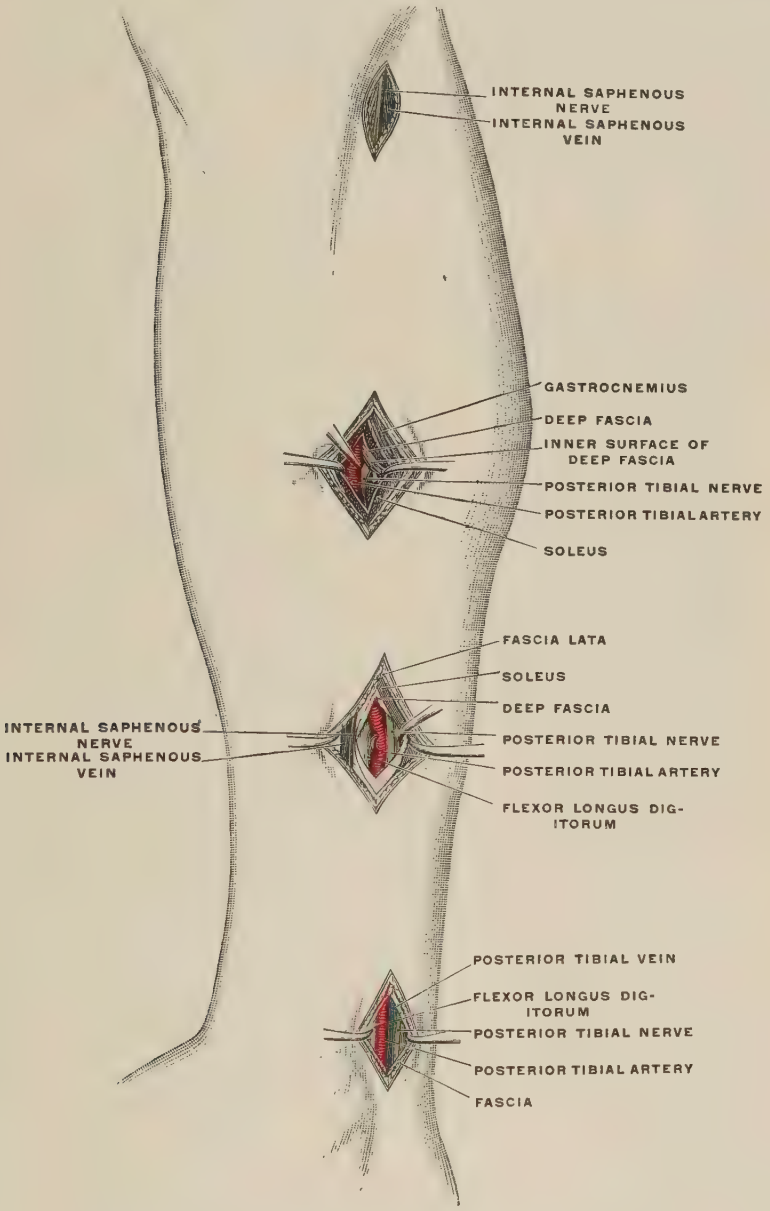

FIG. 521.—Surgical relations of the posterior tibial artery. (Kocher.)

The Muscular branches of the posterior tibial supply the muscles contiguous to that vessel.

The Nutrient, a high branch of the posterior tibial of large size, enters the tibia on its posterior surface.

The Communicating, given off low down, runs outward across the tibia above the ankle-joint, and inosculates with a corresponding branch of the peroneal.

The Internal Calcaneal—frequently several—are given off just above the

bifurcation, and supply the heel and the muscles of the mesial portion of the sole.

The External Plantar (Fig. 523), the larger of the terminal branches, passes outward and forward to the base of the fifth metatarsal bone, then curves forward and inward on the bases of the fourth, third, and second metatarsals to the first interosseous space, where it anastomoses with the deep (communicating) branch of the dorsalis pedis. Thus is formed the *plantar arch*.

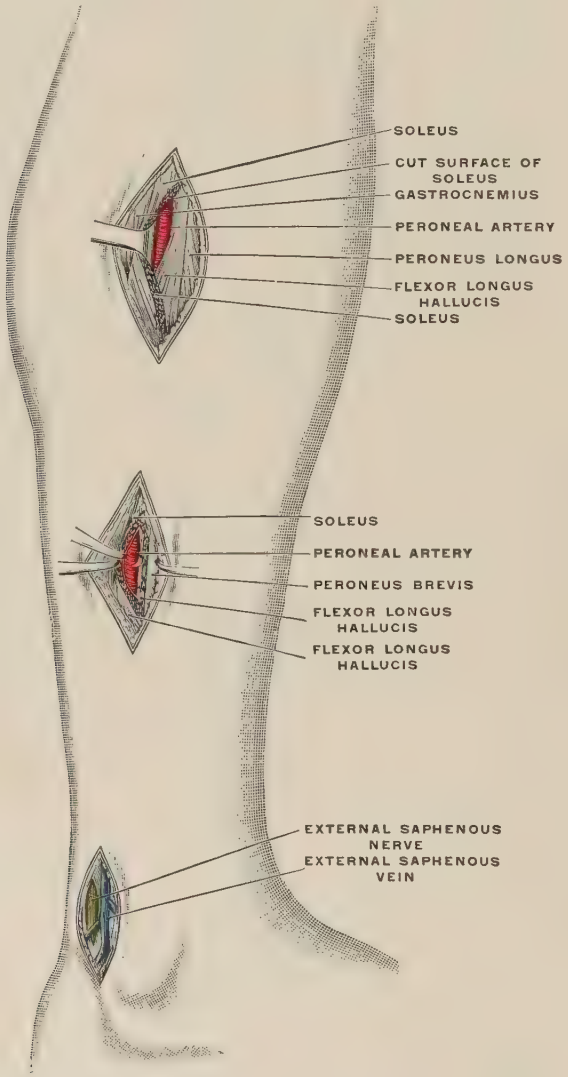

FIG. 522.—Surgical relations of the peroneal artery. (Kocher.)

The external plantar gives many small branches to muscles, skin, fascia, articulations, and so forth in its region; but the principal are the digital and the perforating.

The four *digital branches* come off from the convexity of the plantar arch, the first running forward to the outer side of the little toe, each of the others occupying an interosseous space, dividing at the web of the toes into two *collateral digital* branches, which supply the contiguous surfaces of the fifth and fourth, fourth and third, and third and second toes respectively near their plantar aspect. Just

before the bifurcation of each digital it gives off an *anterior perforating* branch, which runs upward and enters a corresponding dorsal interosseous artery.

The *posterior perforating* branches spring from the plantar arch upward through the second, third, and fourth interosseous spaces, and enter the dorsal interosseous branches of the metatarsal.

The Internal Plantar (Fig. 523) runs along the inner side of the sole of the foot, covered by the abductor hallucis at first, and then placed between this muscle and the flexor brevis digitorum. It gives off branches to the various neighboring structures, and ends by supplying the inner border of the great toe.

The internal plantar may be larger than usual, and supply two or even more

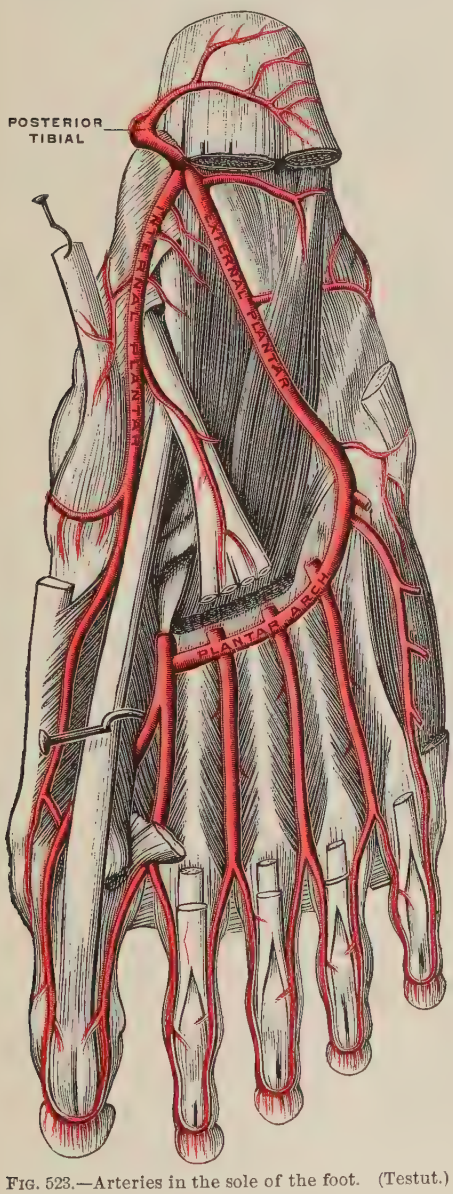

FIG. 523.—Arteries in the sole of the foot. (Testut.)

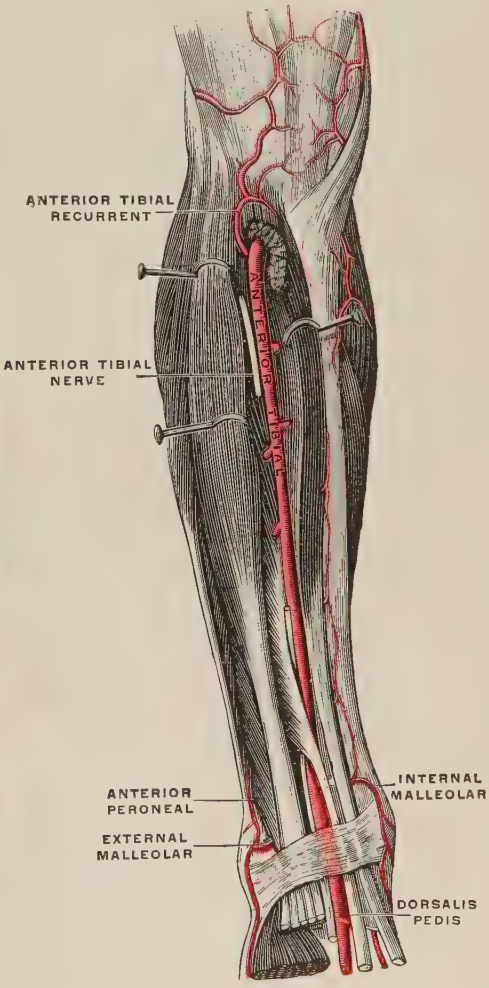

FIG. 524.—Anterior tibial artery. (Testut.)

digits; in such cases the external plantar is correspondingly diminished in size.

The Anterior Tibial Artery.

The *anterior tibial artery* (Figs. 524, 525), smaller than the posterior tibial, begins at the lower border of the popliteus, passes forward between the heads of

origin of the tibialis posterior and above the upper edge of the interosseus membrane, upon the anterior surface of which it runs down, drifting toward the tibia, upon which and the anterior ligament of the ankle it courses. Its continuation in the foot is called the dorsalis pedis. Its branches mainly supply the structures in the anterior part of the leg.

Relations (Figs. 526–528).—*In front*, in its upper two-thirds, are the tibialis anterior and the long extensors of the toes; in its middle third, the anterior tibial

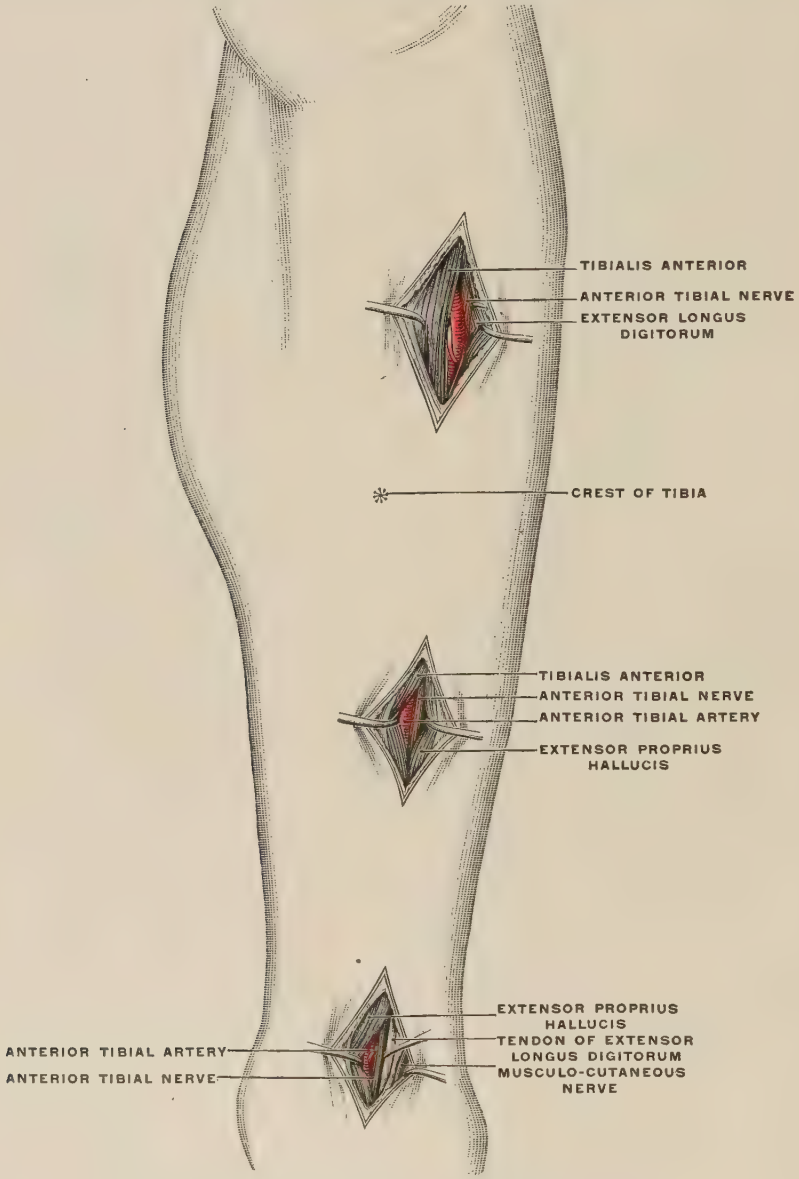

FIG. 525.—Surgical relations of the anterior tibial artery. (Kocher.)

nerve; in its lowest third, the extensor proprius hallucis and the anterior annular ligament. *Behind* are the interosseous membrane for the upper two-thirds, the tibia and ankle-joint in its lowest third. *At the mesial side* are a vena comes throughout, the tibialis anterior above, and the extensor proprius hallucis below. *At the outer side* are a vena comes for the whole length, the extensor longus digito-

rum above, the extensor proprius hallucis in the middle third, and the anterior tibial nerve in the upper and lower thirds.

Variations.—The anterior tibial may be very small, or absent, its place being taken by branches from the posterior tibial or peroneal. It has been seen to

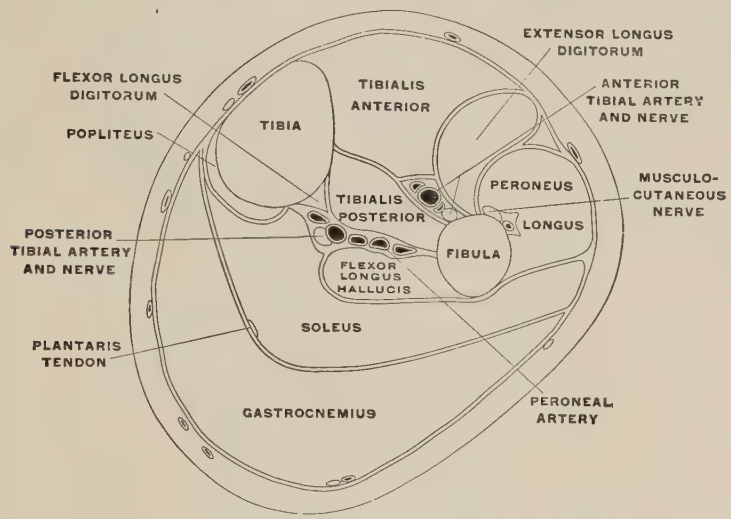

FIG. 526.—Horizontal section through upper third of right leg—upper surface of lower segment—showing anterior tibial, posterior tibial, and peroneal arteries, and their relations. (Braune.)

accompany the musculo-cutaneous nerve, winding around the fibula to reach the front of the leg.

Branches.—In its course the anterior tibial gives off the posterior tibial recurrent, the superior fibular, the anterior tibial recurrent, the muscular, the internal malleolar, and the external malleolar. The *posterior tibial recurrent* arises before

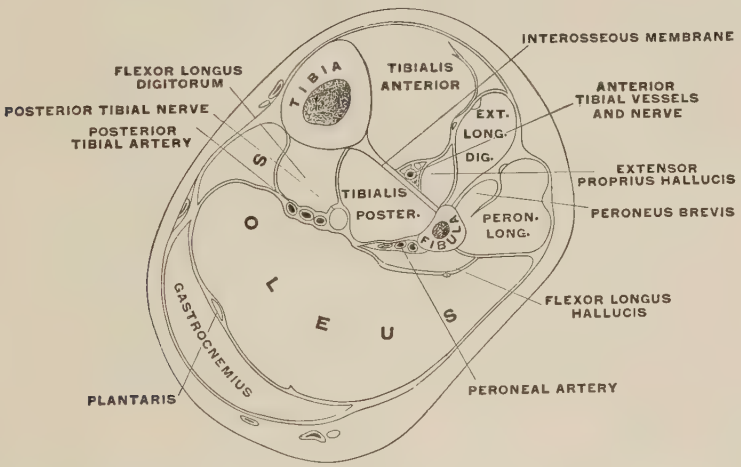

FIG. 527.—Horizontal section at middle of right leg—upper surface of lower segment. (Braune.)

the anterior tibial passes through the interosseous membrane, and runs up in front of the popliteus, supplying this muscle, the posterior ligament of the knee, and the superior tibio-fibular articulation. The *superior fibular*, given off while the anterior tibial is still behind the plane of the interosseous membrane, runs out and around the neck of the fibula to the soleus and peroneus longus. The *anterior tibial recurrent* is the first branch given off in front of the interosseous mem-

brane. It perforates the tibialis anterior, winds over the external tuberosity of the tibia, sends branches to the capsule of the knee-joint, and assists in the formation of the anastomosis around the patella. *Muscular* branches in great number are given off to the neighboring muscles and to the skin. The *internal malleolar* comes off about two inches above the end of the anterior tibial, runs behind the tibialis anterior to the inner malleolus, where it inosculates with neighboring arteries, forming a plexus. The *exterior malleolar* is given off a trifle lower than the internal, passes outward behind the extensor longus digitorum and peroneus

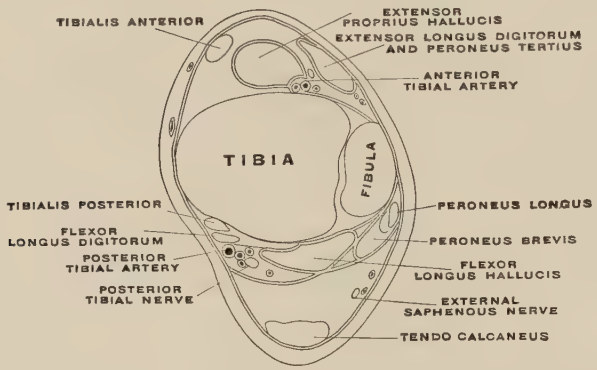

FIG. 528.—Horizontal section of right leg just above the astragalus—upper surface of lower segment. (Braune.)

tertius to the outer malleolus, and there forms, with branches of neighboring arteries, a plexus.

The Dorsalis Pedis Artery (Fig. 529) is the continuation of the anterior tibial. It begins at the bend of the ankle, and runs downward and forward to the proximal end of the first interosseous space, where it divides into the dorsalis hallucis and the deep (communicating).

Relations.—Below in succession are the astragalus, scaphoid, middle cuneiform, and their ligaments. *Above* are the anterior annular ligament in the first portion, the inner tendon of the extensor brevis digitorum at the lower end, and the fasciæ and skin elsewhere. *At the inner side* are a vena comes and the extensor proprius hallucis. *At the outer side* are a vena comes, the inner tendon of the extensor longus digitorum, and the anterior tibial nerve.

Variations.—The dorsalis pedis varies in size greatly; when large, it assists materially the plantar arteries in supplying the sole off the foot; when small, the plantar arteries may furnish a large part of the supply for the dorsum.

Branches.—The dorsalis pedis gives of the tarsal, the metatarsal, the dorsalis hallucis, and the deep (communicating). The *tarsal* passes outward over the scaphoid and cuboid, under the extensor brevis digitorum, supplying that muscle and the tarsal bones, and anastomosing freely with branches of neighboring arteries. The *metatarsal*, also called *interosseous*, given off just before the artery bifurcates, runs outward over the proximal ends of the metatarsal bones, beneath the extensor tendons, and anastomoses with the tarsal and external plantar. From it arise three *dorsal interosseous* branches, which pass forward in the second, third, and fourth interosseous spaces, receiving the posterior perforating branches of the external plantar at their proximal ends, and the anterior perforating of the same artery at the web of the toes, where each bifurcates, sending a *dorsal digital* branch to each of the digits between which it terminates, the last giving a branch also to the outer side of the little toe. The arrangement of these small digitals and their relation to the collateral digitals of the external plantar are similar to those found in homologous vessels in the hand. The *dorsalis hallucis*, otherwise known as the *first dorsalis interosseous*, one of the two terminal

branches, runs forward in the first interosseous space, and at the digital commissure gives off a branch to the mesial side of the great toe, and then bifurcates, and supplies the contiguous sides of the great and second toes. It receives the anterior perforating branch of the princeps hallucis at the web. The *deep*, often called the *communicating*, and also the *plantar digital*, one of the terminals, at the proximal extremity of the first interosseous space runs down to the end of

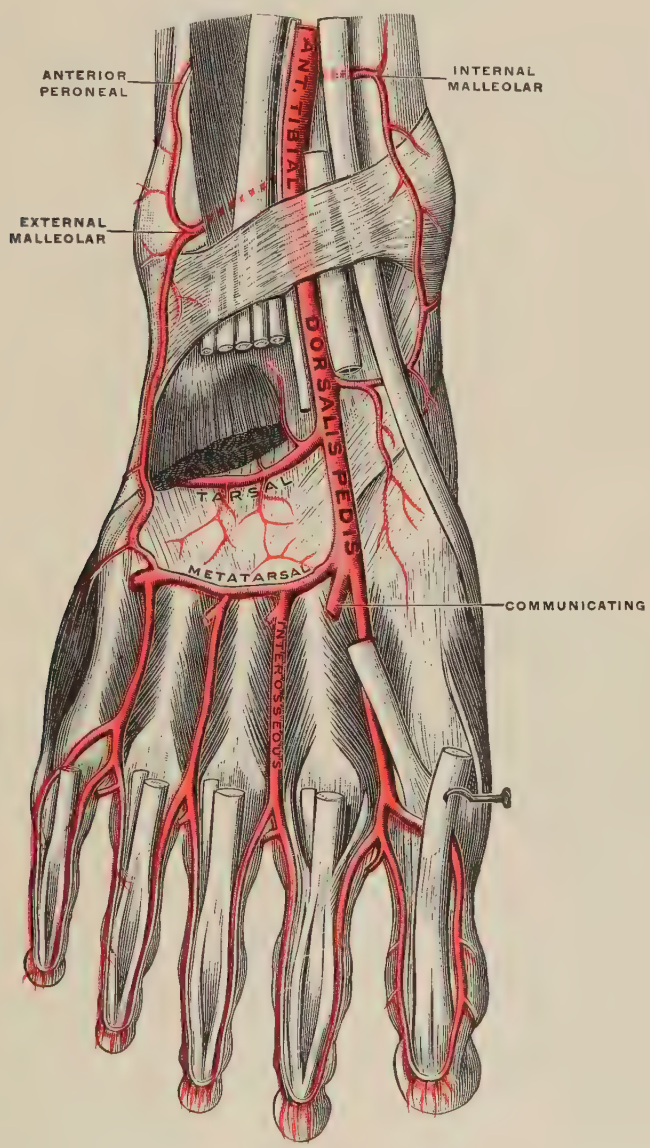

FIG. 529.—Arteries of the dorsum of the foot. Of the dorsal interosseous only the second is labelled. (Testut.)

the external plantar, and thus assists in the formation of the plantar arch. It immediately gives off the *princeps hallucis* (arteria magna hallucis), which sends a branch to the inner side of the great toe, and then runs forward in the first interosseous space to the commissure, where it behaves like the digital branches of the external plantar, giving a branch to each of the contiguous sides of the great and second toes.

THE VEINS.

By G. WOOLSEY.

THE *veins* are the vessels through which the blood is returned from the capillaries to the heart. Like the arteries, they may be divided into the *pulmonary* and the *systemic*.

THE PULMONARY VEINS.

These consist of two large, short trunks on either side, in the root of the corresponding lung (Fig. 530). They extend nearly horizontally inward and forward from the hilum of the lung to the upper part of the back of the left auricle. They lie in front of and below the corresponding pulmonary arteries, and on piercing the pericardium they are invested on their ventral aspect only by the

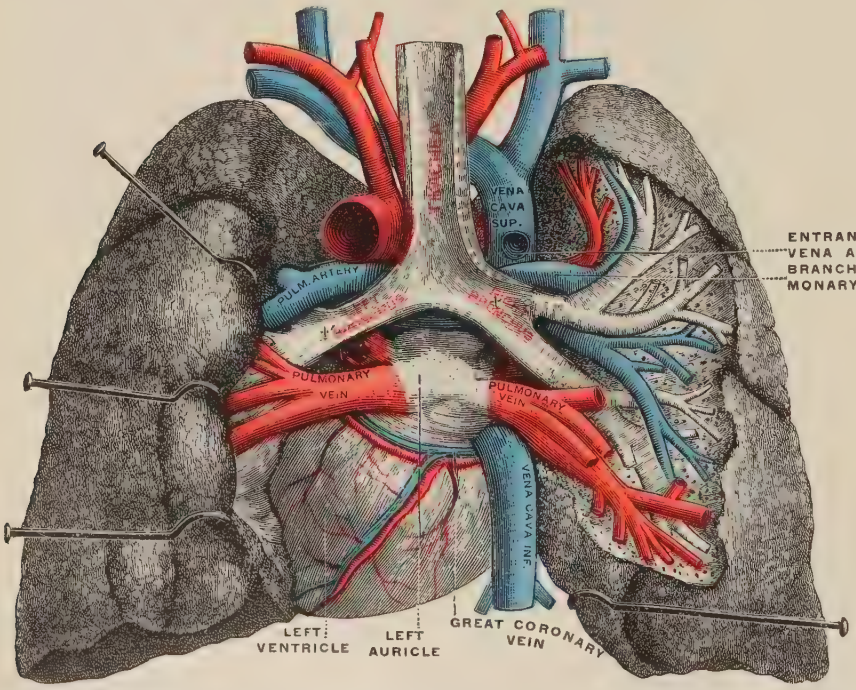

FIG. 530.—Pulmonary veins, seen in a dorsal view of the heart and lungs. The left lung is pulled to the left, and the right lung has been partly cut away to show the ramifications of the air-tubes and blood-vessels. (Testut.)

serous layer of that membrane. The two *right pulmonary veins* pass behind the superior vena cava, the ascending portion of the aorta, and the right auricle. The two *left pulmonary veins* pass in front of the descending portion of the aorta. They convey arterial blood, and have no valves.

The pulmonary veins are but little larger than the arteries they accompany. The right superior pulmonary vein commonly receives the vein from the middle lobe of the right lung, but sometimes the latter continues to the auricle separately as a third vein. The two pulmonary veins, on a side, more often on the left, sometimes unite, and terminate in a single trunk.

THE SYSTEMIC VEINS.

These convey the blood from the capillary plexuses of the rest of the body to the right auricle of the heart, which most of the veins of the heart enter by the coronary sinus, and the veins of the remainder of the body by the superior and inferior venæ cavæ. They differ from the arteries in their larger capacity, their greater number, their thinner walls, their larger and frequent anastomoses, and the presence here and there of more or less perfect valves, which prevent backward circulation. The veins from the stomach, intestines, spleen, and pancreas differ from the others in that, after joining to form a single trunk, the *portal vein*, the latter breaks up in the substance of the liver into a capillary network, from which the blood is collected by the hepatic veins, and emptied into the inferior vena cava.

The veins may be divided into *two sets*, the superficial and the deep, between which there are frequent communications. The *superficial* or *subcutaneous veins* lie between the layers of the superficial fascia, and do not usually accompany an artery. The *deep veins* usually accompany the arteries, sometimes as a single trunk, as with the larger arteries (axillary, femoral, etc.), sometimes as a frequently anastomosing pair, the *venæ comites*, one on either side of the smaller arteries (radial, tibial, etc.).

The *venous sinuses* of the cranium differ from the veins in structure. They are formed between the two layers of the dura, and lined by a continuation of the intima of the veins.

In the following pages a detailed description is necessary only for those veins which do not accompany an artery. The systemic veins are naturally divided into three groups, according as they empty into the heart through the superior or the inferior vena cava, or the coronary sinus.

THE VEINS OF THE HEART.

The *cardiac* or *coronary veins* (Fig. 531), which return the blood from the substance of the heart, accompany the arteries, but have not an exactly similar course, as the arteries start in front, while the veins empty into the coronary sinus behind.

The **Coronary Sinus** is situated in the dorsal part of the groove between the left auricle and ventricle. About an inch in length, it is covered by the muscular fibres of the auricles, and its termination in the right auricle, between the opening of the inferior vena cava and the auriculo-ventricular aperture, is guarded by the coronary or Thebesian valve. Where the cardiac veins (excepting the oblique vein) join the coronary sinus they are guarded by valves, which are wanting in the rest of their course.

The **oblique vein** of Marshall, which runs over the back part of the left auricle in the vestigial fold of the pericardium, enters the left extremity of the sinus without a valve to guard the opening. The oblique vein with the coronary sinus represents the left superior vena cava, or the left duct of Cuvier and part of the sinus venosus of the fœtus. This vein is often represented in great part by a fibrous cord.

The **Great Cardiac Vein** (anterior coronary vein) ascends from near the apex of the heart in the ventral interventricular groove to the auriculo-ventricular groove, in which it turns to the left and passes backward to terminate in the left end of the coronary sinus, which appears as the dilated continuation of this vein.

It accompanies first the anterior and then the posterior branch of the left coronary artery, and receives branches from either side of its course, one of which, ascending along the left margin of the heart (*left marginal vein*) is of some size.

The **Middle Cardiac Vein** (*posterior interventricular vein*) ascends from the apex of the heart in the dorsal interventricular groove to empty into the right extrem-

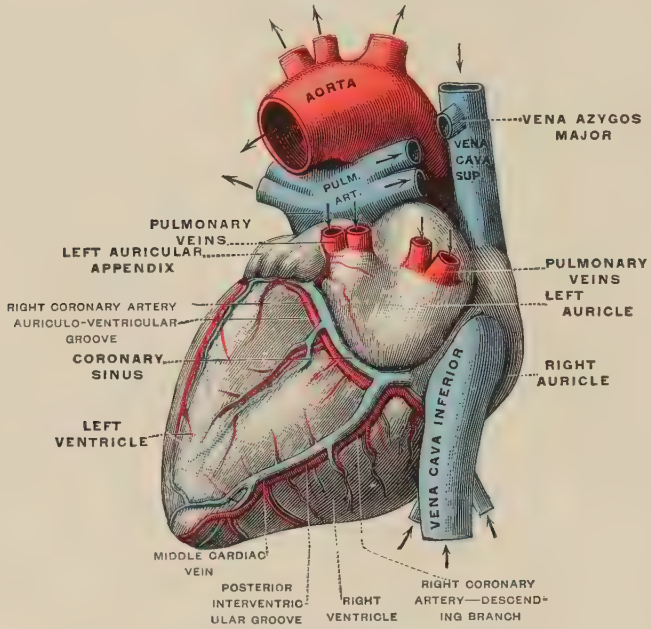

FIG. 531.—Cardiac veins, dorsal view. (Testut.)

ity of the great coronary sinus. It receives branches from the dorsal surface of both ventricles.

The **Posterior Cardiac Veins** are three or four small vessels, which ascend on the dorsal surface of the left ventricle to open along the lower border of the coronary sinus.

The **Right or Small Coronary Vein** passes along the right auriculo-ventricular groove to convey the blood from the hinder parts of the right auricle and ventricle into the right end of the coronary sinus.

The following small vessels empty directly into the heart without the intervention of the coronary sinus. The **Anterior Cardiac Veins** are two or three small vessels, which collect the blood from the ventral surface of the right ventricle, and ascend to enter the lower part of the right auricle. One larger than the others (*right marginal vein* or *vein of Galen*) runs along near the antero-inferior border of the heart. The **smallest cardiac veins** (*venæ cordis minimæ, Venæ Thebesii*) are numerous small veins within the substance of the heart, which open into some of the small foramina Thebesii in the right auricle. Similar veins are said to open into the other heart-cavities.

THE SUPERIOR VENA CAVA AND ITS TRIBUTARIES (Figs. 531, 533).

The *superior (descending) vena cava* is formed by the confluence of the right and left brachio-cephalic (innominate) veins behind the lower part of the junction of the first right costal cartilage with the sternum. From this point it passes nearly vertically downward, with a slight convexity to the right, for about three inches, to empty into the right auricle on a level with the third costal cartilage. Its lower inch and a half are contained within the pericardium, whose serous layer invests it, except along its hind border. It receives the blood returned

from the head, neck, upper extremities and thoracic walls. It contains no valves. *Relations.*—On its *right side* are the right lung and pleura, with the phrenic nerve between. On its *left side* lies the brachio-cephalic artery above, and the ascending portion of the aortic arch below. *In front* it is overlapped by the right pleura and lung. The root of the right lung lies *behind* it.

Its *lateral tributaries* are the great azygos vein, which enters it just before it penetrates the pericardium, and small veins from the pericardium and mediastinum.

The Brachio-cephalic Veins.

The *brachio-cephalic* or *innominate veins* return the blood from the head, neck, upper extremities, and the upper part of the thoracic walls. They are formed by the union of the subclavian and internal jugular veins, behind the sternal end of each clavicle, and unite below, opposite the lower border of the first right costal cartilage, at its junction with the sternum, to form the superior vena cava. At the angle of junction of the subclavian and jugular veins there open into the venous circulation the thoracic duct on the left side and the right lymphatic duct on the right side. There are no valves in the brachio-cephalic veins.

The **Right Brachio-cephalic Vein**, only about an inch in length, descends nearly vertically on the outer side of, and superficial to, the brachio-cephalic and the commencement of the subclavian arteries. The right lung and pleura lie on its right side and in front, with the phrenic nerve between.

The **Left Brachio-cephalic Vein**, two and a half to three inches long, passes from left to right with a slight downward inclination to join the right vein. In front of it lies the upper part of the manubrium sterni, with the lower ends of the sternal muscles, below it the arch of the aorta, and behind it the three branches of the arch, and the left phrenic and pneumogastric nerves.

Lateral Tributaries.—Each brachio-cephalic vein receives the vertebral, inferior thyroid, and internal mammary veins of its own side, and, in addition, the left vein receives the left superior intercostal vein, and small thymic, mediastinal, and pericardial branches.

Variations in the Superior Vena Cava and Brachio-cephalic Veins.—These are mostly due to a persistence of the left duct of Cuvier of the fœtus, which may form a left superior vena cava. This descends from the commencement of the left brachio-cephalic vein, in front of the aortic arch and the root of the left lung, to the heart, where it is continued in the usual position of the coronary sinus to open into the right auricle. In such cases the usual left brachio-cephalic vein may persist as a small communicating branch between the right and left superior venæ cavæ, or it may be altogether wanting. In a few cases, besides those of transposition of the viscera, the superior vena cava is found on the left side, the right brachio-cephalic vein taking a transverse course similar to that usually taken by the left.

VEINS OF THE HEAD AND NECK.

I. Veins of the Surface of the Cranium and Face (Fig. 532).

A. ANTERIOR REGION.

The *superficial veins* of the face and the fore part of the cranium and the deep veins of the face unite to form two trunks, the facial and the temporo-maxillary veins, while the occipital and posterior auricular veins collect the blood from the hind part of the scalp. Valves are generally absent in the veins of the head and neck, except at the lower end of the internal and external jugular veins.

The **Facial Vein** (*anterior facial*) collects the blood from the fore part of the face and scalp. It commences at the side of the nose, on a line with the lower margin of the orbit, as the direct continuation of the angular vein. It is less

tortuous than the facial artery, posterior to which it passes downward and outward to and around the lower border of the jaw, in front of the masseter muscle. Below the lower border of the jaw it inclines backward beneath the platysma muscle, and is joined by the anterior division of the temporo-maxillary vein below the digastric muscle. The trunk thus formed is called the *common facial vein*, and empties into the internal jugular vein near the level of the hyoid bone. A communicating branch passes downward along the ventral margin of the sterno-mastoid muscle to join the anterior jugular vein.

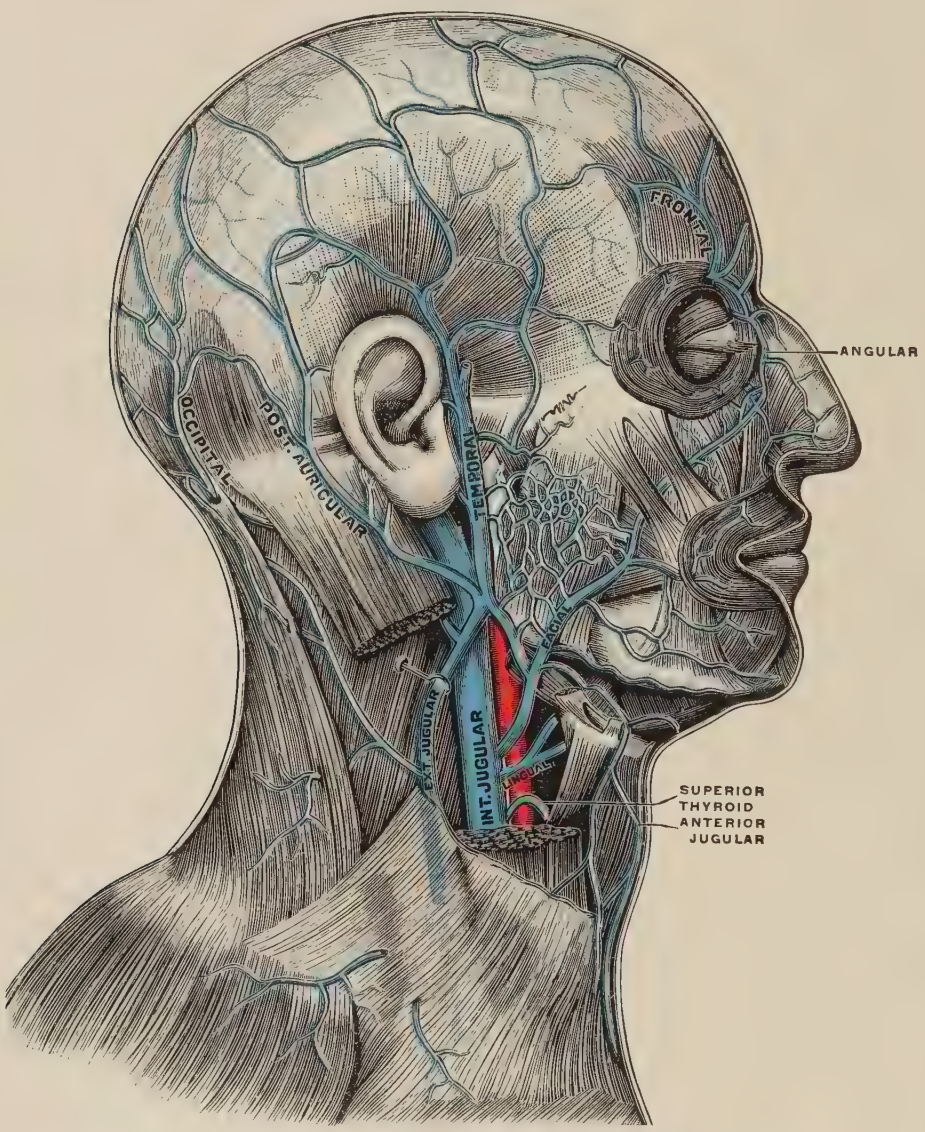

FIG. 532.—Superficial veins of the cranium and face, right lateral view. (Testut.)

The **Angular Vein**, on each side, lies along the side of the root of the nose from a point a little below the level of the eyebrow, where it is formed by the junction of the frontal and supra-orbital veins, to the lower margin of the orbit, where it becomes the *facial vein*. It appears as the continuation of the frontal vein, lies internal to the lachrymal sac, receives branches from the nose and upper eyelid, and communicates with the superior ophthalmic vein.

The **Transverse Nasal Vein** arches across the bridge of the nose, and unites the two angular veins, or the lower ends of the frontal veins.

The **Frontal Vein** is formed by branches from the forehead and the forepart of the scalp, which communicate with the anterior division of the temporal vein. These tributaries pass downward and inward to form a trunk which, connected with its fellow by cross-branches, descends nearly vertically on the side of the median line to a point a little below the inner end of the eyebrow, where it is joined by the supra-orbital vein and becomes the angular vein. The right and left frontal veins sometimes unite into a single median trunk, which bifurcates at the root of the nose into the two angular veins.

The **Supra-orbital Vein** is a smaller vessel, which collects the blood from the lower and lateral part of the forehead, upper eyelids, etc., and passes obliquely downward and inward to join with the frontal vein in forming the angular. It communicates laterally with the temporal, and dorsally with the ophthalmic vein and the frontal vein of the diploë.

The *facial vein* receives *lateral tributaries*, corresponding to the branches of the artery (*i. e.*, inferior palatine, submaxillary, submental, inferior labial, inferior and superior coronary, and lateral nasal) and in addition the following:

The **inferior palpebral veins**, two or three in number, descend from the lower eyelid, where a communication with the infra-orbital vein is established.

The **anterior internal maxillary vein** or *deep facial vein* passes downward and forward from the pterygoid plexus. It crosses the zygomatic surface of the maxilla, and opens into the facial vein beneath the zygomaticus major muscle.

Small **buccal, masseteric,** and **parotid veins** are received from the buccinator and masseter muscles and the glandula socia parotidis, respectively.

Sometimes the lingual vein joins the facial. (See lingual vein.)

The free communications between the facial vein and its tributaries and the ophthalmic vein, none of which contain valves, account for the danger of septic thrombi extending backward through the ophthalmic vein to the cavernous sinus, in case of carbuncle or other forms of inflammation near the facial vein.

B. LATERAL REGION.

The **Temporo-maxillary Vein** (*posterior facial*) is formed by the union of the temporal and maxillary veins in the substance of the parotid gland behind the neck of the mandible. It descends in the substance of the parotid gland superficial to the external carotid artery to about the angle of the jaw, where it divides into two parts. The *anterior division* passes downward and forward to join the facial vein, forming the common facial vein, while the *posterior division* is joined by the posterior auricular vein to form the external jugular vein.

The posterior auricular vein may join the temporo-maxillary vein before the bifurcation of the latter, in which case the anterior division is properly a branch of the external jugular vein.

The **Superficial Temporal Vein** collects the blood from the parietal region of the scalp, where communicating branches connect it with the supra-orbital and frontal veins in front, the veins of the opposite side above, and the posterior auricular and occipital veins behind. Its radicles unite into two trunks which, corresponding to the divisions of the artery, converge and unite in front of the ear into a single trunk.

The **Middle Temporal Vein** receives the blood from the temporal muscle, and is joined by the orbital branch, which, corresponding to the orbital branch of the temporal artery, communicates with the ophthalmic vein. Piercing the fascia near the zygoma it joins the superficial temporal to form the *common temporal vein*. The *middle temporal vein* communicates with the pterygoid plexus through the deep temporal veins, branches of that plexus corresponding to the arteries of the same name.

The **Common Temporal Vein** crosses the base of the zygoma just in front of the ear, and thence descends in the parotid gland external to the temporal artery. It

joins the internal maxillary vein opposite the neck of the jaw to form the temporo-maxillary vein.

The temporal vein also receives *anterior auricular veins* from the external ear, *transverse facial veins* from the masseter muscle, *parotid veins* from the gland, and tributaries from the plexus around the temporo-maxillary articulation, which receives a radicle from the tympanum, through the fissure of Glaser.

The **Internal Maxillary Vein** is a short vessel, which passes backward from the pterygoid plexus, accompanying the internal maxillary artery as a single or a double trunk to join with the common temporal vein in forming the temporo-maxillary vein.

The **Pterygoid Plexus** surrounds the pterygoid muscles and corresponds to the second and third portions of the internal maxillary artery, by the companion veins of whose branches it is made up. Its principal outlet is the internal maxillary vein. It also communicates in front with the facial vein, through the deep facial vein, above with the inferior ophthalmic vein and the cavernous sinus, behind with the plexus from which the middle temporal vein arises, and below with the pharyngeal plexus.

The **Posterior Auricular Vein** descends from a plexus on the lateral aspect of the scalp, which communicates with the temporal and occipital veins and with the vein of the opposite side. It is large in comparison with its companion artery, which it leaves below the ear, and inclines forward toward the angle of the jaw to join the posterior division of the temporo-maxillary vein, forming thereby the external jugular vein.

C. POSTERIOR REGION.

The **Occipital Veins** collect the blood from the hind part of the venous plexus of the scalp, and descend, as one or two trunks, with the occipital artery deeply into the neck, where they are continuous with the *deep cervical vein*. An emissary vein, passing through the mastoid foramen, connects the lateral sinus with this vein, or, in some cases, with the posterior auricular vein.

II. Veins of the Neck (Fig. 533).

The **External Jugular Vein**, formed by the union of the posterior auricular vein and the posterior division of the temporo-maxillary vein, descends nearly vertically from its commencement near the angle of the jaw to terminate in the subclavian vein opposite the middle of the clavicle. It lies beneath the platysma, and crossing the sterno-mastoid muscle obliquely it follows the posterior border of the latter in its lower half. Near the clavicle it pierces and is closely connected with the deep cervical fascia, which holds it open. It has a pair of imperfect valves at its entrance into the subclavian vein, and another an inch or two above the clavicle. The part between the valves is called the *sinus*, being often dilated. Its *lateral tributaries* are the following:

The **posterior external jugular vein.** This descends behind the sterno-mastoid muscle, from the skin and superficial muscles of the upper and back part of the neck and the lower occipital region, to terminate in the external jugular vein below its middle. It may communicate with the occipital vein.

The **transverse cervical** and **suprascapular veins** accompany their corresponding arteries, and open into the external jugular vein a little above its termination. They sometimes present a plexiform arrangement in the subclavian triangle. These veins have valves near their termination and may sometimes open directly into the subclavian vein.

The **anterior jugular vein** takes origin below the chin from small tributaries which communicate with the lower radicles of the facial vein. It descends at a variable distance from the median line to near the inner end of the clavicle, where it perforates the deep fascia and turns outward beneath the sterno-mastoid muscle to open into the lower end of the external jugular vein, or sometimes directly into

the subclavian vein. It receives a branch from the facial vein which descends along the ventral border of the sterno-mastoid muscle. A transverse branch connects the lower ends of the veins of the two sides, and others may exist higher up.

Its position behind the origin of the sterno-mastoid should be remembered in tenotomy of that muscle. It varies in size inversely with that of the external jugular vein.

The **Internal Jugular Vein** receives the blood from the cranial cavity. It begins at the enlarged *sinus* or bulb of the sigmoid sinus, which is lodged in the large dorsal compartment of the jugular foramen. After a nearly straight

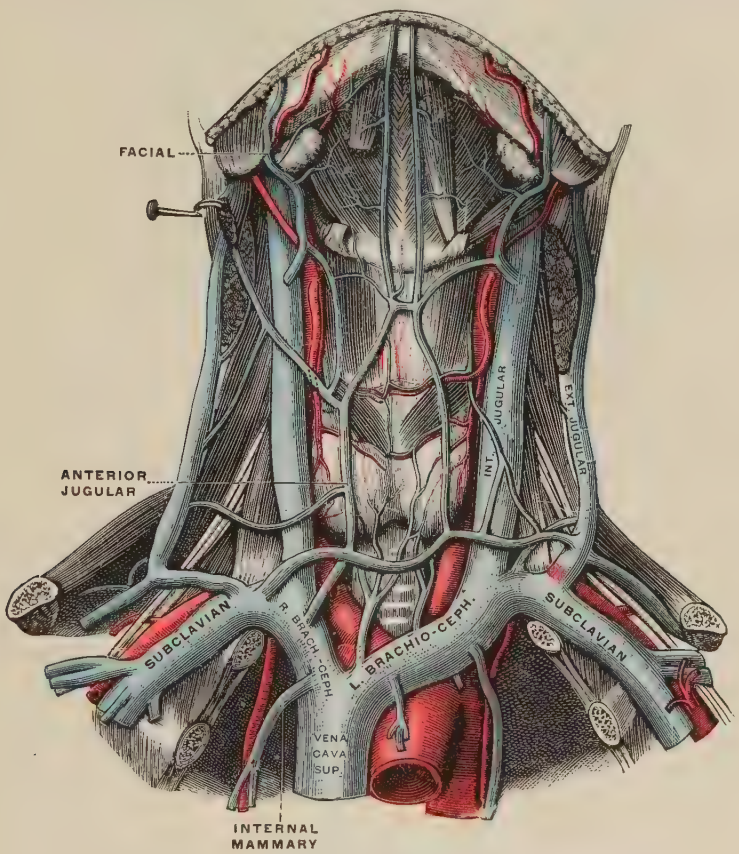

FIG. 533.—Veins of the neck and upper part of thorax, front view. (Testut.)

course it ends behind the sternal end of the clavicle, where it joins the subclavian vein to form the brachio-cephalic vein. At the base of the skull it is behind and then becomes external to the internal carotid artery. Lower down it lies external to and in the same sheath with the common carotid artery, overlapping it below, especially on the left side. A pair of imperfect valves is found about an inch above its termination. It has the following *lateral tributaries*:

The **inferior petrosal sinus** opens into the bulb or into the commencement of the internal jugular vein.

The **pharyngeal plexus**, on the outer surface of the pharynx, receives the blood from the neighboring parts, and opens into the jugular vein directly or through the common facial vein. It communicates above with the pterygoid plexus and receives branches from the soft palate and Eustachian tube.

The **lingual vein** (Fig. 534). Two small venæ comites usually accompany the lingual artery, but most of the blood is returned from the tongue by the *ranine*

rein, which starts near the tip of the tongue, and passes backward beneath the mucous membrane of its under surface. As it continues backward it is separated from the lingual artery by the hyoglossus muscle, on the outer surface of which it lies below the hypoglossal nerve. It is joined by the lingual venæ comites and by branches corresponding to the branches of the artery, and empties into the

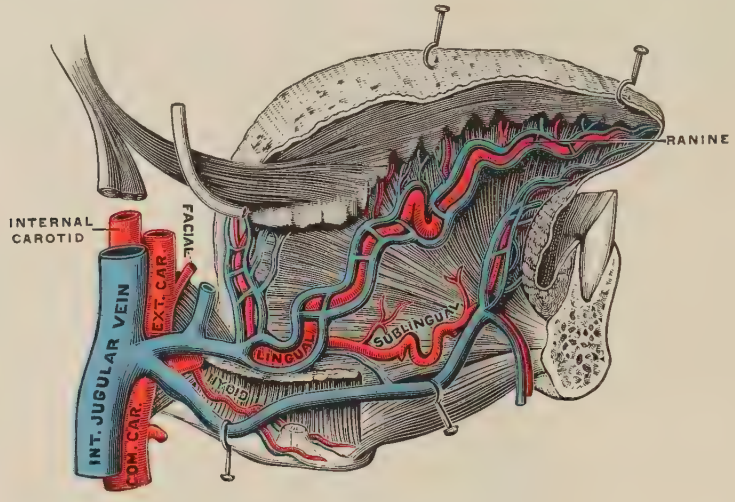

FIG. 534.—Arteries and veins of the tongue, viewed from the right side. The ranine vein is pulled downward by hooks. (Testut.)

internal jugular or the facial vein. Some of its tributaries not infrequently open separately into the internal jugular or into the facial vein.

The **common facial vein** has been described above.

The **superior thyroid vein** corresponds to the artery of the same name, and, after crossing the upper end of the common carotid artery, it empties into the internal jugular or the common facial vein. The three thyroid veins on each side communicate freely with each other and with those of the opposite side.

The **middle thyroid vein** emerges from the lower part of the lateral lobe of the thyroid body, and, after crossing the common carotid artery, empties into the internal jugular vein, a little below the level of the cricoid cartilage.

The **inferior thyroid veins** descend from the lower part of the thyroid body, one on either side of the trachea. Frequent anastomoses form a kind of plexus, from which the left vein descends to empty into the left brachio-cephalic vein, the right vein into the angle of union of the two brachio-cephalic veins, or into the lower end of the right brachio-cephalic vein, or it may join the left vein. They lie under cover of the sterno-hyoid muscles, and receive inferior laryngeal, tracheal, and œsophageal veins. They are guarded by valves at their termination. They may seriously embarrass the surgeon in performing low tracheotomy.

The **Vertebral Vein** corresponds to the cervical portion only of the vertebral artery. Commencing in the suboccipital triangle in a plexus of small veins, it accompanies the vertebral artery in a plexiform manner through the foramina of the transverse processes of the upper six cervical vertebræ. Thence as a single vessel it descends across the subclavian artery to open into the upper end of the brachio-cephalic vein, dorsally.

Tributaries.—At its upper end it communicates with the occipital, deep cervical, and intraspinal veins. It receives branches from the dorsal spinal veins of the neck, the lateral spinal veins, and the plexus on the ventral surface of the bodies of the cervical vertebræ. Near its lower end it is joined by the deep cervical and anterior vertebral veins, and usually by the first intercostal vein, which accompanies the superior intercostal artery.

The **anterior vertebral vein** descends from in front of the cervical vertebræ,

accompanying the ascending cervical artery, and receiving branches from the neighboring muscles.

The **deep cervical vein** (*posterior vertebral*) descends at the back of the neck, in company with the deep cervical artery, from the suboccipital plexus, through which it receives the occipital vein. Below the transverse process of the seventh cervical vertebra it turns forward to empty into the lower end of the vertebral vein.

III. The Veins of the Diploe (Fig. 535).

These are contained in a plexus of bony channels in the cancellous tissue of the bones of the roof and sides of the skull. They are arranged in four groups,

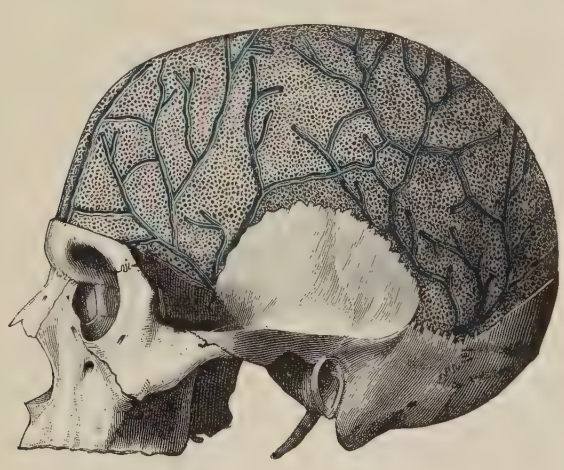

FIG. 535.—Veins of the diploë. The outer table of cranial bones is removed. (Testut.)

whose trunks descend to communicate with the meningeal veins, the sinuses of the dura and the veins of the scalp. They are named from their position.

The **frontal veins** of the diploë open into the supra-orbital vein at the bottom of the supra-orbital notch or foramen.

The **anterior temporal veins** of the diploë open into the deep temporal veins through an opening in the great wing of the sphenoid.

The **posterior temporal veins** of the diploë join the lateral sinus through the mastoid foramen or an opening at the dorso-inferior angle of the parietal bone.

The **occipital veins** of the diploë open into the occipital vein externally, or into the lateral sinus internally.

In fœtal life the veins of each bone are distinct, but they anastomose freely after the bones come together.

IV. The Venous Sinuses of the Cranium (Figs. 536, 537).

These are venous channels situated between the two layers of the dura, and lined by a continuation of the lining membrane of the veins. They collect the blood from the brain, orbit, and eyeball, and some of that from the meninges and diploë, and empty into the internal jugular vein. They communicate with the superficial veins by means of the *emissary veins*, passing through certain foramina in the cranium. They may be divided into two groups, the one situated above and behind, the other at the base of the skull; the former including the superior and inferior longitudinal, the straight, the lateral, and the occipital sinuses, while the latter embraces the cavernous, the circular, the basilar, and the inferior and superior petrosal sinuses.

The **Superior Longitudinal Sinus** extends in the median line along the attached

margin of the falx cerebri, increasing constantly in size, from the foramen cæcum in front to the internal occipital protuberance behind, where, turning sharply to one side, usually the right, it is continuous with the lateral sinus. Its triangular lumen is crossed by a number of fibrous bands (the cords of Willis), and projecting into it at intervals are the Pacchionian bodies. It receives the superior cerebral veins, which enter it mostly from behind forward (*i. e.*, against the blood-stream). It often communicates through the parietal foramen with the temporal veins of the scalp, and regularly in early life through the foramen cæcum with the veins of the nose. On approaching the internal occipital protuberance it inclines slightly to one side, usually the right, and presents a dilatation, the *torcular Herophili* ("the wine-press of Herophilus"), which is lodged in a depression on the side of the internal occipital protuberance. The torcular usually receives the occipital sinus, and gives a cross-branch to the straight sinus, where the latter bends into the opposite lateral sinus.

The **Inferior Longitudinal Sinus** is a small vessel of cylindrical form, which occupies the dorsal half or more of the lower border of the falx cerebri. It receives some tributaries from the falx and the median surface of the brain, and terminates in the straight sinus.

The **Straight Sinus**, triangular on section, extends downward and backward along the line of junction of the falx cerebri and the tentorium cerebelli, to the internal occipital protuberance, where it bends sharply to the side, usually to the

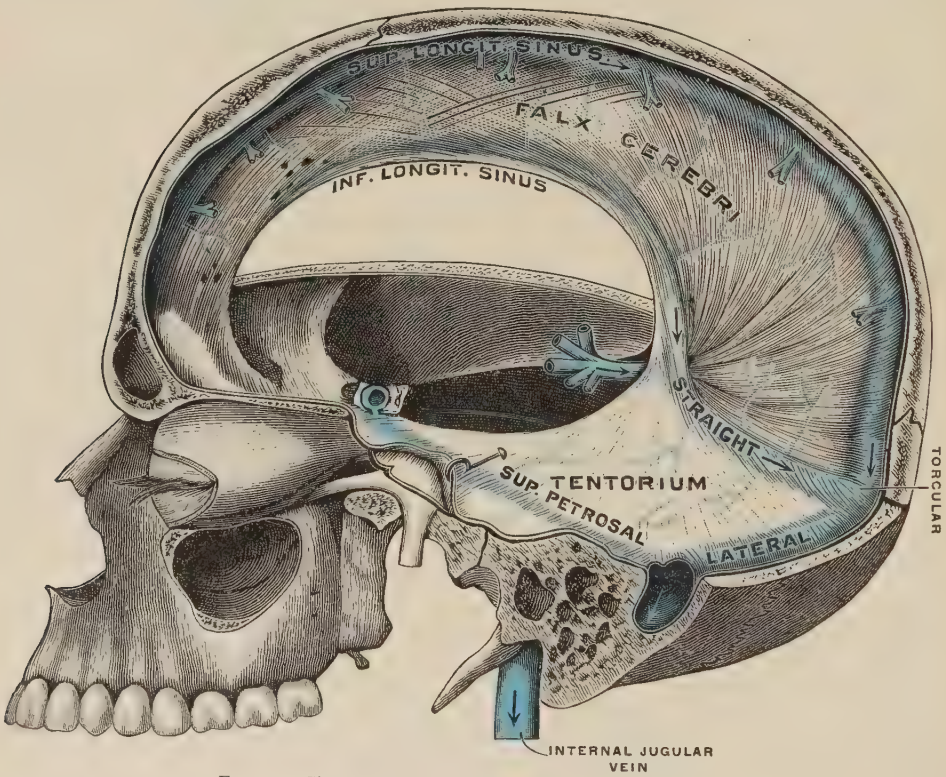

FIG. 536.—Sinuses of the dura, left lateral view. (Testut.)

left, and is continued into the lateral sinus, being connected by a cross-branch with the torcular. It is formed in front, at the margin of the tentorium, by the union of the inferior longitudinal sinus with the great vein of Galen from the interior of the brain.

The **Lateral Sinuses** commence at the internal occipital protuberance, and end at the jugular foramina in the bulbs or sinuses which are continuous with the internal

jugular veins. Each sinus passes at first nearly horizontally outward, with a slight convexity upward, in the groove on the occipital bone and the dorso-inferior angle of the parietal bone, along the attachment of the tentorium cerebelli. Thence it curves downward and inward in the groove on the inner surface of the mastoid, leaving the tentorium after receiving the superior petrosal sinus (and, when present, the petro-squamous sinus). Finally it curves forward onto the jugular process of the occipital bone to the jugular foramen. That part of the sinus on the mastoid bone and the jugular process of the occipital is called the *sigmoid sinus*, from its S-shaped course. This part is semicylindrical in shape, communicates with the occipital sinus through the marginal sinus, and with the occipital and vertebral veins by means of emissary veins passing through the mastoid and posterior condylar foramina respectively. The lateral sinus receives veins from the temporal lobe of the brain, from the upper and lower surfaces of the cerebellum, and from the medulla, pons, and diploë. The right lateral sinus is considerably larger than the left, except in cases where the superior longitudinal sinus is continued into the left sinus.

The *position* of the lateral sinus may be represented on the exterior of the skull by a line curved slightly upward from the external occipital protuberance to

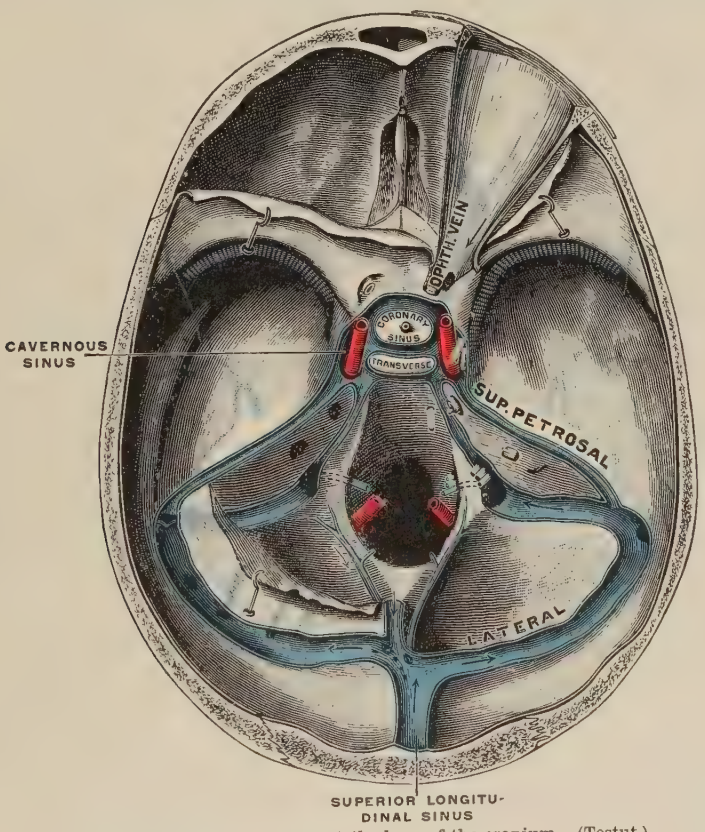

FIG. 537.—Sinuses of the dura at the base of the cranium. (Testut.)

the base of the mastoid process, and thence its sigmoid portion bends downward and inward toward the tip of the process, making a forward bend or knee which extends to within half an inch or less of the upper part of the bony external auditory meatus.

The **Occipital Sinus** ascends mesially, along the line of attachment of the falx cerebelli to the occipital bone, from the foramen magnum in front to the torcular behind. Its tributaries pass around one or both sides of the foramen magnum, as *marginal sinuses*, one or both of which communicate with the lower end of the lateral

sinuses. It communicates with the posterior spinal veins, and receives inferior cerebellar veins. The marginal sinuses occasionally end in two parallel occipital sinuses.

The **Cavernous Sinuses** (Fig. 538) lie between the layers of the dura, one on each side of the body of the sphenoid bone. They extend from the sphenoidal fissure in front, where they receive and are practically continuous with the ophthalmic veins, to the apex of the petrous bone behind, where they end in the petrosal sinuses. The two are connected across the middle line in front, behind, and often below the pituitary body, by vessels which are called *anterior*, *posterior*, and *inferior intercavernous sinuses*, and which together form the *circular* or *coronary sinus*. Each cavernous sinus is bridged across by fibrous bands, so that its cavity resembles cavernous tissue, from which it derives its name. In the outer wall are the third, fourth, and ophthalmic divisions of the fifth nerve, which lie in the order named from above downward and from within outward. The internal carotid artery and the sixth nerve also pass along in the sinus separated from its lumen

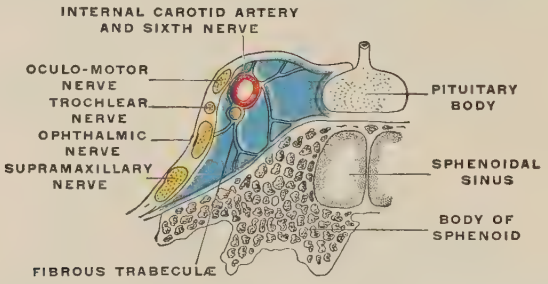

FIG. 538.—Cavernous sinus, as shown by transverse section through the middle of the sella turcica. (W. Keiller.)

by its epithelial lining only. This sinus receives some inferior cerebral veins, and communicates with the pterygoid plexus through the ophthalmic vein, and through a slender vein passing through the foramen of Vesalius and another through the foramen ovale. It also communicates with the pharnygeal plexus and the internal jugular vein, by branches passing through the foramen lacerum medium and the carotid canal respectively. This sinus also receives in front the small *spheno-parietal sinus*, which, communicating with the middle meningeal veins, near the apex of the small wing of the sphenoid, runs inward on the under surface of this bony process.

The **Superior Petrosal Sinus** extends backward as a narrow channel in the attached margin of the tentorium cerebelli, along the groove in the upper border of the petrous bone, from the cavernous sinus in front to the lateral sinus behind. It receives veins from the temporal lobe of the brain, the cerebellum, and the tympanum.

The **Inferior Petrosal Sinus**, larger but shorter than the superior, runs backward and downward in a groove along the petro-occipital suture, from the hind end of the cavernous sinus in front to the upper end of the internal jugular vein, which it reaches after passing through the forward compartment of the jugular foramen. It receives inferior cerebellar veins, and veins from the oblongata, pons, and internal ear.

The **Transverse** or **Basilar Sinus** (*basilar plexus*). Connecting the two inferior petrosal sinuses across the median line is a plexus of veins, lying in the dura on the basilar process of the occipital bone. It communicates below with the anterior spinal veins.

The **petro-squamous sinus** is sometimes found in the adult in a groove along the petro-squamous suture, opening behind into the lateral sinus, where the latter bends downward onto the mastoid bone. It represents the remains of an early fœtal condition, in which the lateral sinuses are continued forward in this course, and then through a foramen in the squamous bone, to open into the primitive (afterward the external) jugular vein, before the development of the internal jugular vein.

The Ophthalmic Veins.

Commencing near the inner canthus of the eyelid, where it communicates freely with the angular, frontal, and supra-orbital veins, the principal or *Superior Ophthalmic Vein* extends backward and inward to the inner end of the sphenoidal fissure, where it joins the inferior ophthalmic vein to form the short, thick common ophthalmic trunk. The latter passes through the fissure, to end in the fore part of the cavernous sinus. In the orbit the superior ophthalmic vein crosses above the optic nerve, a little anterior to the artery, and receives tributaries similar to the branches of the artery.

The Inferior Ophthalmic Vein.—Formed by the union of some inferior muscular branches with the lower posterior ciliary branches, this smaller ophthalmic vein runs backward in the floor of the orbit, beneath the optic nerve. It terminates by joining the superior ophthalmic vein to form the short *common ophthalmic trunk*, or by opening separately into the cavernous sinus. A branch, and occasionally the entire vein, descends through the spheno-maxillary fissure to join the pterygoid process.

As the ophthalmic veins have no valves, the blood, under certain conditions, may flow from behind forward into the angular vein or its branches, and thus obviate pressure in the veins of the retina, when the cavernous sinus is obstructed.

The Emissary Veins.

These pass through foramina in the skull to connect the cranial sinuses with the surface veins of the scalp. The blood-current may be in one or the other direction under varying conditions of intracranial pressure. They may serve as the channels along which infection is carried from the surface to the interior of the cranium. The following communications occur through emissary veins. (*A*) The *longitudinal sinus* communicates with the temporal veins through one or both parietal foramina, when present, and, in the child, with the veins of the nose through the foramen cæcum. (*B*) The *lateral sinus* is connected with the occipital (or posterior auricular) vein through the mastoid foramen, and sometimes with the vertebral vein through the posterior condylar foramen. (*C*) The *cavernous sinus* communicates with the pterygoid plexus through the foramen of Vesalius and the foramen ovale, as well as through the inferior ophthalmic vein; with the pharyngeal plexus through the foramen lacerum medium; and with the internal jugular vein by the carotid plexus through the carotid canal. (*D*) The *occipital sinus*, through the marginal sinuses, may communicate with the vertebral and extraspinal veins by way of the anterior condylar foramen. (*E*) A small vein occasionally passes to the *torcular* through a foramen in the occipital bone, near the external occipital protuberance.

The Veins of the Brain.

These open into the cranial sinuses and have several peculiarities.

THE VEINS OF THE CEREBRUM.

These have very thin walls owing to the absence of muscular tissue, and contain no valves. They are more numerous than the arteries, and, for the most part, do not accompany them. Those veins opening into the superior longitudinal sinus enter it against its current, after ascending with the arteries, instead of descending with the ascending arteries.

The cerebral veins may be divided, like the arteries, into a *superficial set* on the surface, which anastomose freely together, and a *deep set*, which emerge from the ventricles by the transverse fissure.

The **Superficial Veins** run in the fissures, and occasionally across the gyri, and are subdivided into superior and inferior groups.

The **superior cerebral veins**, eight to twelve in number on each side, pass inward and slightly forward from the upper surface of the cerebrum. After

joining others from the mesial surface, they open into the longitudinal sinus, running for some distance in its walls.

The **inferior cerebral veins** collect the blood from the outer and under surfaces of the cerebrum, and open into the cavernous, superior petrosal, or lateral sinuses, according to their position. The *Middle Cerebral Vein* is one of large size, which overlies the fissure of Sylvius, receiving branches from adjoining lobes, and ends in the cavernous sinus. The *Great Anastomotic Vein* of Trolard, by anastomosing on the parietal lobe with a branch of the middle cerebral vein and with one of the superior veins, establishes a communication between the cavernous and the superior longitudinal sinuses. Similarly the *Posterior Anastomotic Vein* of Lubbe connects the cavernous and lateral sinuses, by anastomosing with the middle cerebral vein on the temporal lobe.

The **Deep Cerebral Veins** join to form two trunks, the *Veins of Galen*, which, beginning near the porta (foramen of Monro), by the union of the choroid vein and the vein of the corpus striatum on each side, pass back, parallel with and near each other, between the layers of the velum interpositum. Beneath the splenium of the corpus callosum they pass out of the brain at the great transverse fissure, after joining to form a single trunk (vena magna Galeni), which ascends to enter the straight sinus.

The choroid vein runs forward and upward along the outer border of the choroid plexus (the blood of which it returns) to its fore part where, near the porta (foramen of Monro), it joins the vein of the corpus striatum. The latter runs forward in the groove between the corpus striatum and the optic thalamus, receiving branches from them and the neighboring parts. It joins the choroid vein as above described.

Each vein of Galen, just before it joins its fellow, receives the basilar vein of that side which, formed by the union of the anterior cerebral vein, the deep Sylvian vein, and the inferior striate vein, passes backward and around the crus cerebri to its termination. The *anterior cerebral vein* runs from the genu of the corpus callosum, the *deep Sylvian veins* from the insula and adjacent parts (communicating with the middle cerebral vein), and the *inferior striate vein* descends through the anterior perforated space from the corpus striatum.

THE VEINS OF THE CEREBELLUM.

These are divided into two sets, superior and inferior, according to their position. Of the *superior cerebellar veins* some run inward and upward to the straight sinus and the great vein of Galen, others run outward to the superior petrosal and lateral sinuses. The *inferior cerebellar veins* are larger than the superior, and some of them together with the veins of the oblongata and pons, run outward and forward to the inferior petrosal and lateral sinuses, while others pass backward to the occipital sinus.

THE VEINS OF THE UPPER EXTREMITY.

Two sets of veins are distinguished in the extremities, *superficial* and *deep*, the latter of which accompany the arteries, while the superficial set are larger, return more of the blood, and lie in the subcutaneous areolar tissue. The two sets communicate at frequent intervals. Valves are numerous in both sets, but more so in the deep veins, and are regularly found where a radicle joins a trunk, or the deep veins join the superficial.

The Superficial Veins of the Upper Extremity (Figs. 539, 540).

These commence in two plexuses, viz., a large *plexus on the dorsum of the hand*, which receives the digital veins from the fingers, and is sometimes subdivided into two parts, a radial and an ulnar; and a smaller *plexus on the front*

of the wrist, which receives a few branches from the palm and the thumb. The superficial veins of the forearm communicate freely with one another.

The **Radial Vein**, commencing in the radial side of the dorsal plexus runs up the radial side of the forearm to a little above the bend of the elbow, where, on the outer side of the biceps-tendon, it joins the median cephalic vein to form the cephalic vein. On the hand it communicates with the deep veins of the palmar arch, and along its course it receives many superficial tributaries.

The **Posterior Ulnar Vein** begins in the ulnar side of the dorsal plexus, and, after communicating with the deep palmar veins, it extends upward along the dorsal aspect of the ulnar side of the forearm, and near the bend of the elbow usually receives the anterior ulnar vein.

The **Anterior Ulnar Vein** is smaller than the foregoing, which it joins near the bend of the elbow, except rarely, when it enters the median basilic vein separately. It ascends from the wrist along the ulnar side of the front of the forearm.

The **Common Ulnar Vein** is formed by the union of the anterior and posterior ulnar veins just below the internal condyle of the humerus. After a short course it joins the median basilic, and thus forms the basilic vein.

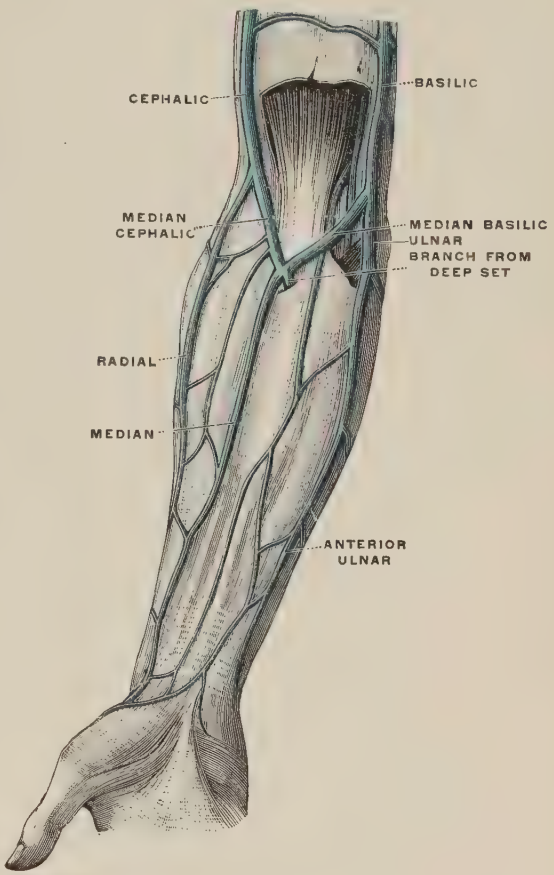

FIG. 539.—Superficial veins of front of forearm and lower part of arm. (Testut.)

The **Median Vein** ascends along the front of the forearm from the plexus on the front of the wrist to the bend of the elbow, where, after receiving the *deep median vein* from the deep set of veins, it immediately bifurcates into the median basilic and the median cephalic veins.

The **Median Basilic Vein**, the larger of the two divisions, is directed upward and inward to the groove internal to the biceps, where it forms the basilic vein by joining the common ulnar trunk or one of the ulnar veins. It crosses the brachial artery, from which it is separated by the fascial tendon of insertion of the biceps; hence in venesection, in which this vein was the one commonly chosen, on account of its size, constancy, and accessibility, the artery was sometimes punctured, leading to arterio-venous aneurism, etc. Branches of the internal cutaneous nerve cross in front of and behind it.

The **Median Cephalic Vein** runs upward and outward in the groove between the biceps and brachio-radialis muscles to form the cephalic vein, by uniting with the radial vein just above the bend of the elbow. The musculo-cutaneous nerve passes beneath it.

The **Basilic Vein** ascends in the groove, on the inner side of the biceps, a little internal to the course of the brachial artery. Perforating the deep fascia below the middle of the arm, it ends by joining the inner vena comes of the brachial artery to form the axillary vein.

The **Cephalic Vein**, the smaller of the veins of the arm, ascends in the groove external to the biceps and then in the interval between the deltoid and pectoralis major muscles to a little below the clavicle, where it perforates the costo-coracoid

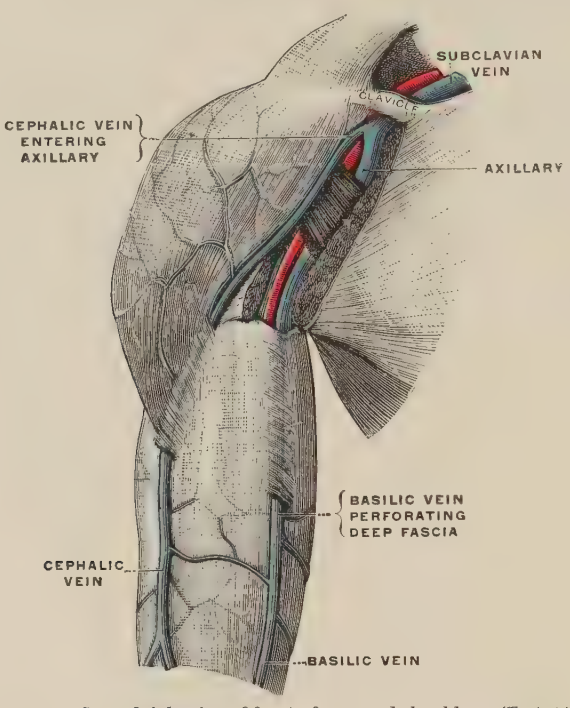

FIG. 540.—Superficial veins of front of arm and shoulder. (Testut.)

membrane, and ends in the axillary vein, after crossing the first portion of the axillary artery. Sometimes a branch, and rarely the entire vein, crosses over the clavicle to end in the external jugular vein.

The Deep Veins of the Upper Extremity.

The **Axillary Vein.**—The arteries below the axillary are accompanied by two *venæ comites* ("companion veins") with frequent cross-branches. They communicate with the superficial veins, especially in the hand and at the elbow. Near the lower border of the teres major or the subscapularis muscle, the inner brachial vena comes, and joins the basilic vein to form the single *Axillary Vein*. This accompanies the axillary artery, lying to its inner side, and ends at the outer border of the first rib in the subclavian vein. It has the same relations as the artery. It collects all the blood of the upper extremity, receiving the cephalic vein and the radicles which correspond to the branches of the axillary artery.

The **Subclavian Vein** continues the axillary vein from the outer border of the first rib to the sterno-clavicular articulation, where it ends in the brachio-cephalic vein. It lies in front of and at a somewhat lower level than the subclavian artery, from which it is separated by the scalenus anterior muscle and the phrenic nerve. It lies in the groove on the first rib in front of that for the artery. Close to the outer border of the sterno-mastoid muscle the external jugular vein empties into it, and just external to this point the vein is provided with a pair of valves.

THE VEINS OF THE THORACIC WALL.

The **Internal Mammary Veins** accompany each internal mammary artery and its branches in anastomosing pairs, which unite into a single trunk a short distance below their termination in the lower part of the brachio-cephalic vein.

The Superior Intercostal Veins.—The veins from the two to four intercostal spaces below the first join together to form a short trunk, which on the *right side* descends to empty into the upper part of the great azygos vein, and on the *left side* ascends across the arch of the aorta to empty into the left brachio-cephalic vein. The left superior intercostal vein communicates inferiorly with the left upper azygos vein, and sometimes receives the left bronchial vein. It is often connected with the oblique vein of Marshall by a fibrous cord, traceable through the vestigial fold of the pericardium and representing the left duct of Cuvier. The veins of the upper intercostal space, or sometimes the upper two intercostal spaces, ascend to join the vertebral or brachio-cephalic vein of the corresponding side.

THE AZYGOS VEINS (Fig. 541).

The **Azygos Veins**, developed from the primitive cardinal veins, form an anastomosis between the inferior and superior venæ cavæ, which is of importance in obstruction of the inferior vena cava. They receive the venous blood from the greater part of the dorsal and lateral thoracic walls. The azygos veins are three in number, and lie on the sides of the front of the vertebral bodies.

The **Right or Great Azygos Vein** (*vena azygos major*) commences in the abdomen as an upward continuation of the ascending lumbar vein, which communicates with the common iliac vein, and is often connected with the inferior vena cava and the renal vein. It ascends through the aortic opening of the diaphragm on the right of the aorta and the thoracic duct, in which position it continues upward in the posterior mediastinum in front of the right intercostal arteries, grooving the dorsal border of the right pleura. Opposite the lower end of the fourth thoracic vertebra it bends forward over the root of the right lung, to empty into the superior vena cava at a point just above where the latter pierces the pericardium.

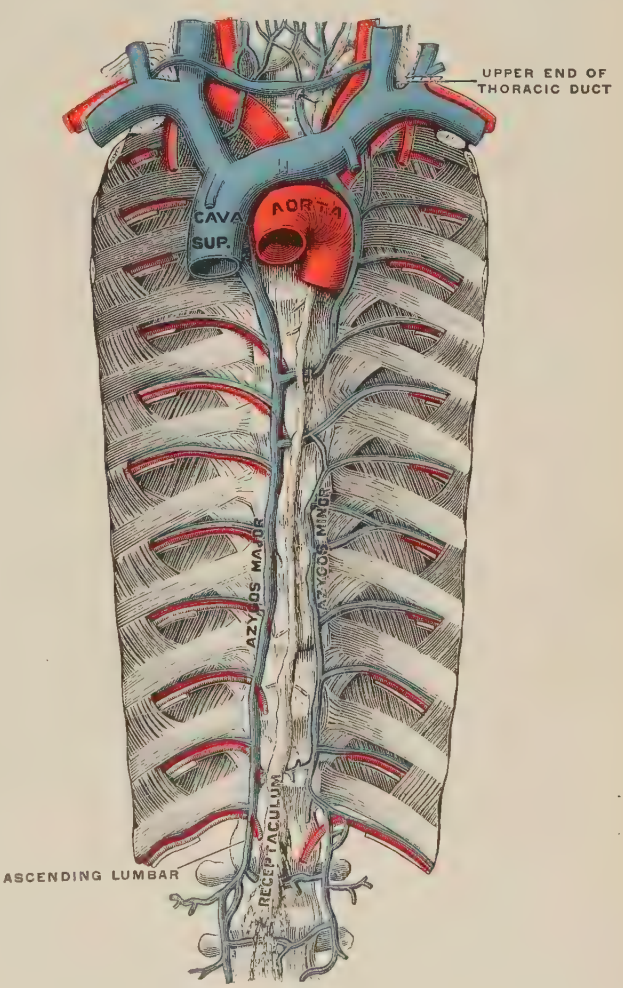

Fig. 541.—Azygos and intercostal veins. (Testut.)

Tributaries.—It recieves (1) the right subcostal vein; (2) the seven or eight lower right intercostal veins; (3) the right superior intercostal vein; (4) the right bronchial veins; (5, 6) the left lower and the left upper azygos veins, and some small (7) œsophageal; (8) pericardial; and (9) mediastinal veins.

The **Left Lower** or **Small Azygos Vein** (*vena hemiazygos, vena azygos minor*) commences in the abdomen on the left side, in a manner similar to the great azygos on the right side, the branch from the renal vein being more constant, and sometimes the principal source. It ascends through the left crus of the diaphragm, and in the posterior mediastinum it lies in front of the left intercostal arteries as far as the eighth thoracic vertebra, where it crosses behind the thoracic aorta and thoracic duct to join the great azygos vein.

Tributaries.—It receives (1) the left subcostal vein below the diaphragm; and above it (2) the lower four left intercostal veins; (3) the left upper azygos (sometimes); and some small (4) œsophageal; and (5) mediastinal veins.

The **Left Upper Azygos Vein** (*vena hemiazygos accessoria*) varies in size with that of the left superior intercostal and the left lower azygos veins, between which it is placed. It receives two or three intercostal veins. It connects above with the superior intercostal vein, and opens below into the left lower azygos vein, or, crossing the sixth or seventh thoracic vertebra, ends separately in the great azygos vein. It often receives the left bronchial vein. It is quite variable and often absent, and then its radicles, the fifth, sixth, and seventh intercostal veins, open directly into the great azygos vein.

The **Intercostal Veins** accompany the arteries as a single trunk, lying above them. They receive large dorsal branches from the muscles of the back, the dorsal spinal plexus, and the spinal canal. They are eleven in number, one for each intercostal space, the lowest thoracic vein being called the *subcostal vein*, from its position. They terminate variously in different subjects and on the two sides. (See azygos, superior intercostal, and vertebral veins.)

The **Bronchial Veins** accompany the bronchial arteries, only part of whose blood they return, that distributed to the smaller bronchi entering the pulmonary veins. They pass out at the back of the root of the lung, and enter the upper end of the vena azygos major on the right side, and the left upper azygos or the left superior intercostal vein on the left side.

VEINS OF THE SPINE (Figs. 542, 543).

These form complicated plexuses, situated without and within the spinal canal and on the spinal cord, which communicate with one another and with the veins of the neck and trunk. They contain no valves and may be described in groups as follows:

I. **Extra-spinal Veins.**—The *Dorsal Spinal Veins* form a plexus over the laminæ and adjacent processes of the vertebræ, where they receive tributaries from the skin and muscles of the back, the larger of which run forward along the interspinous ligaments. They communicate with the posterior longitudinal spinal veins by branches perforating the ligamenta subflava, and open laterally into the vertebral or the dorsal branches of the intercostal and lumbar veins, according to the region, by branches passing forward between the transverse processes.

II. The **Veins of the Vertebral Bodies** (*venæ basis vertebrarum*) occupy horizontal bony channels in the vertebral bodies and communicate with the veins in front of and at the sides of them. They open behind, through the large single or double foramen on the dorsal surface of the bodies of the vertebræ, into the transverse connecting branches of the anterior longitudinal spinal veins.

III. **Intra-spinal Veins.**—(A) The *Meningo-rachidian Veins* are those within the spinal canal between the dura and the walls of the canal.

The *Anterior Longitudinal Spinal Veins*, large and plexiform, extend the entire length of the spinal canal behind the bodies of the vertebræ, one on either side of the posterior common ligament. Opposite the bodies of the vertebræ they are dilated and communicate with each other by transverse trunks, placed between the posterior common ligament and the body of each vertebra, which receive the veins of the vertebral bodies. Opposite the intervertebral discs they

are constricted, and send lateral branches through the intervertebral foramina to join the vertebral, intercostal, lumbar, or sacral veins, according to the region. They communicate with the basilar plexus above, and with the posterior longitudinal spinal veins throughout the spinal canal. Together with the posterior spinal veins and the marginal part of the occipital sinus they form a venous ring around the foramen magnum.

The *Posterior Longitudinal Spinal Veins*, smaller than the foregoing, are situated one on each side at the back of the spinal canal, and extend throughout

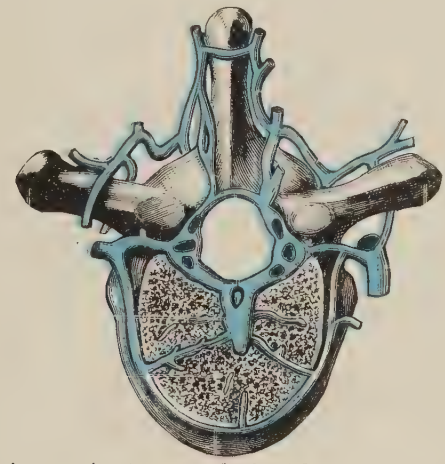

FIG. 542.—Veins of the spine, seen in a transverse horizontal section of a thoracic vertebra. (Testut.)

its entire length. They communicate with one another, by frequent transverse branches in front of the neural arches, with the dorsal spinal veins through the ligamenta subflava, with the anterior longitudinal spinal veins by lateral branches, and superiorly with the occipital sinus. Lateral branches also pass out through the intervertebral foramina to join those from the anterior longitudinal spinal veins.

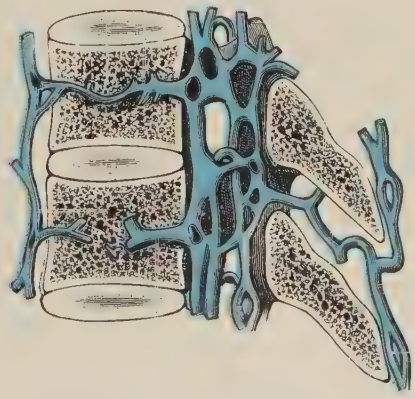

FIG. 543.—Veins of the spine, seen in a sagittal section of two thoracic vertebræ. (Testut.)

(B) The *Veins of the Spinal Cord*, of small size, run tortuously in the pia of the cord, and are disposed in longitudinal trunks over the median fissures and laterally, with plexiform communications between these trunks. Branches accompany the nerve-roots to the intervertebral foramina, where they join the lateral branches from the veins of the spinal canal. Superiorly they join the veins of the pons and cerebellum.

The principal blood-current through the veins of the spine is probably in a horizontal direction in the venous rings, formed by the communications between

the anterior and posterior veins, which send lateral branches through the intervertebral foramina.

THE INFERIOR VENA CAVA AND ITS TRIBUTARIES.

THE VEINS OF THE ABDOMEN (Fig. 544).

The **Inferior** or **Ascending Vena Cava** returns to the heart the blood from the lower extremities, the pelvis, and the abdomen, except that returned by the azygos and superior epigastric veins. It is a large vessel, which is formed by the union of the two common iliac veins in front of the right upper segment of

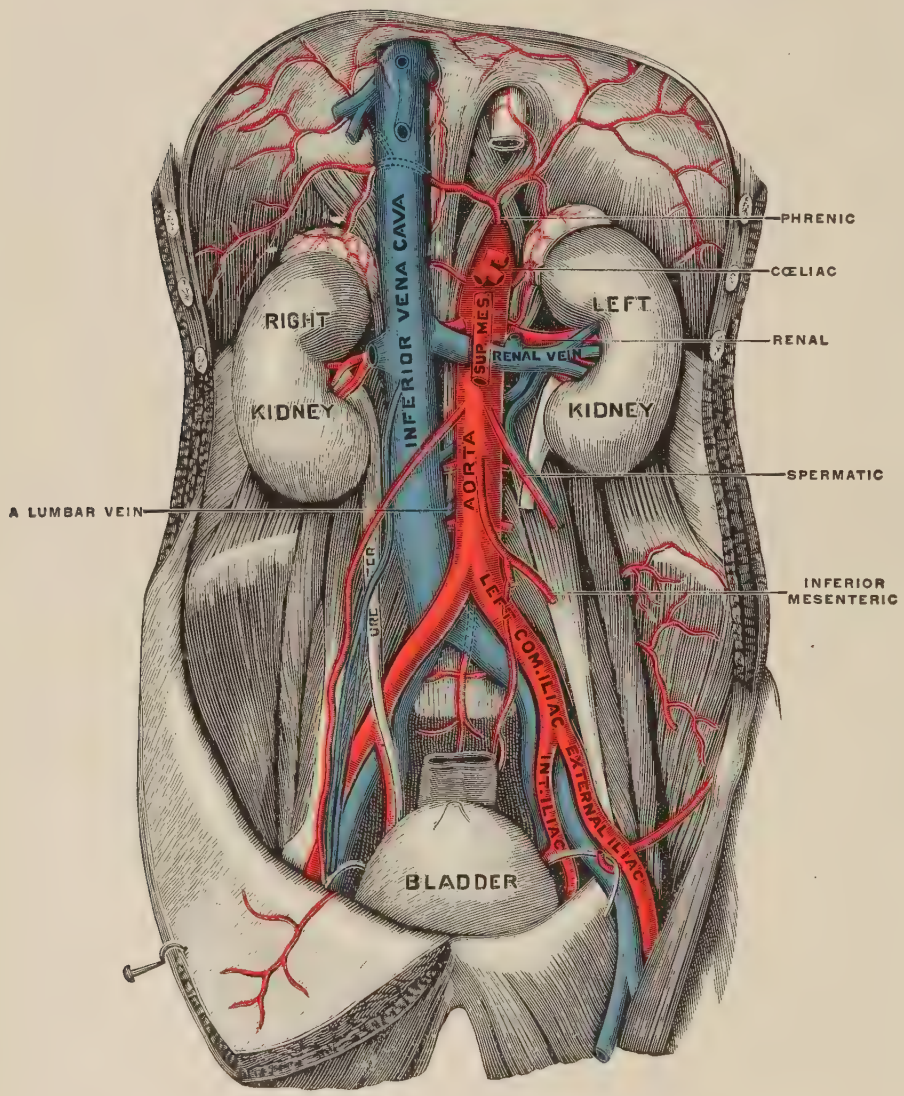

FIG. 544.—Inferior vena cava and its tributaries.

the fifth lumbar vertebra. Thence it runs upward to the right of the aorta, from which it is separated above by the right crus of the diaphragm and the Spigelian lobe of the liver as it inclines forward and lies in the groove or canal on the dorsal surface of the liver. On passing through the caval opening in the central tendon of the diaphragm, to the margins of which it is attached, it immediately

enters the pericardium. It then passes through the latter for about half an inch, only partly invested by its serous layer, to open into the lower and back part of the right auricle, opposite the upper border of the ninth thoracic vertebra. In the abdomen the liver, portal vein, pancreas, duodenum, mesentery, and right spermatic (or ovarian) artery, lie in front of it; the vertebræ, right renal and lumbar arteries, and the right crus of the diaphragm, behind it.

Tributaries.—The *hepatic veins* converge from the substance of the liver to the groove or canal occupied by the inferior vena cava, into which they empty in two or three trunks. The veins from the right and left lobes open so obliquely that the semilunar folds, presented at the lower border of their orifices, take the place of valves, which are otherwise wanting. These veins are of large size, and return the blood of the hepatic artery and the portal vein.

The *phrenic* (or *inferior phrenic*) *veins* accompany the phrenic arteries. The right one opens directly into the vena cava just below the diaphragm, while the left often joins the left suprarenal, or sometimes the left renal vein.

The *Suprarenal Veins.*—One vein on each side returns all the blood supplied by the three suprarenal arteries. The right vein terminates in the vena cava, the left in the left renal or phrenic vein.

The *renal veins* are large, short trunks, which run in front of the corresponding arteries from the hilum of the kidney to the vena cava, into which they empty nearly at right angles, the left a little above the right. The left renal vein is larger than the right. It has to cross the aorta, which it does just below the origin of the superior mesenteric artery, after receiving the spermatic (or ovarian) vein, often the suprarenal vein, and sometimes the phrenic vein of the same side. Rudimentary valves are found, especially on the left side. The shortness of the right renal vein should be remembered when dealing with the pedicle in nephrectomy.

The *spermatic veins* (Fig. 545) return the blood from the testicle and epididymis, from which they emerge dorsally, and, ascending to and through the inguinal canal, form a thick plexus (*pampiniform* ("tendril-shaped") *plexus*) in front of the vas deferens and the spermatic artery. On entering the abdomen through the internal abdominal ring the plexus merges into two or three veins, which accompany the spermatic artery beneath the peritoneum, on the psoas muscle and across the ureter. In their course they join to form a single trunk, which opens into the vena cava on the right side, and on the left side into the renal vein, which it meets at a right angle. Imperfect valves are found in the pampiniform plexuses, but the valve described at the termination of the vein may be absent in the vein of the left side, which moreover is usually slightly longer than the right vein and passes beneath the sigmoid colon, where it may be subjected to pressure.

The above differences are held to account for the greater frequency of varicocele on the left side. A few small veins ascend from the testicle behind the spermatic artery and the vas deferens and join the epigastric veins above. They are not ligated in the operation for varicocele.

The *ovarian veins* are homologous to the spermatic veins and terminate in the same manner. The *ovarian* or *pampiniform plexus*, in which they begin, lies near the ovary between the layers of the broad ligament, and communicates freely with the uterine plexus, as well as with the *ovarian bulb*, a plexus of fine veins at the hilum of the ovary. They follow the course of the ovarian arteries.

The *lumbar veins*, usually four in number on each side, accompany the lumbar arteries. They are formed by the union of ventral branches from the abdominal walls, where they communicate with the epigastric and internal mammary veins, and dorsal branches, which receive tributaries from the muscles of the back and the veins of the spine. The lumbar veins pass forward upon the bodies of the vertebræ beneath the psoas muscle, and on the left side beneath the aorta, to empty into the back of the vena cava. In front of the transverse processes and

behind the psoas muscle the lumbar veins of each side are connected by continuous vertical branches, called the *ascending lumbar vein*, which communicates below with the ilio-lumbar, common iliac, and lateral sacral veins, and is usually continued above as the azygos vein of the corresponding side.

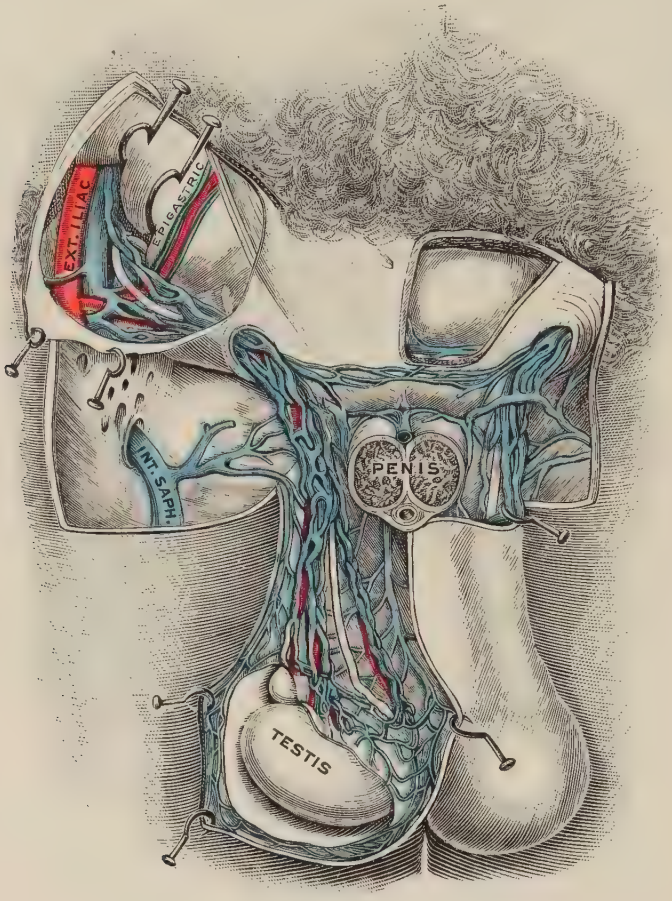

FIG. 545.—Spermatic veins. (Testut.)

The Common Iliac Veins.

The *Common Iliac Veins*, formed opposite the sacro-iliac articulations by the confluence of the internal and the external iliac veins, converge as they ascend, and unite opposite the right upper segment of the fifth lumbar vertebra to form the inferior vena cava. The *right vein*, shorter and more vertical than the left, lies behind and internal to its artery below, but above crosses obliquely behind it to its outer or right side, where it is joined by the *left vein*. The latter lies internal to the left common iliac artery and then crosses behind the upper end of the right artery to join the right vein. They contain no valves, except an occasional one in the left vein.

Tributaries.—The *ilio-lumbar veins* follow the ilio-lumbar arteries, and enter the common or internal iliac veins. They resemble the lumbar veins in their course, formation, and connections. The *middle sacral veins*, one on each side of the artery of the same name, ascend on the front of the sacrum to open into the left common iliac vein, after uniting into a single trunk. Occasionally this trunk enters the angle of junction of the two common iliac veins. These veins anastomose with the lateral sacral and the hemorrhoidal veins.

The External Iliac Vein (Fig. 546).

This is the continuation of the femoral vein, and extends from the level of the inguinal (Poupart's) ligament to the sacro-iliac articulation, where it joins the internal iliac vein. While it is internal to the artery on both sides below, on the

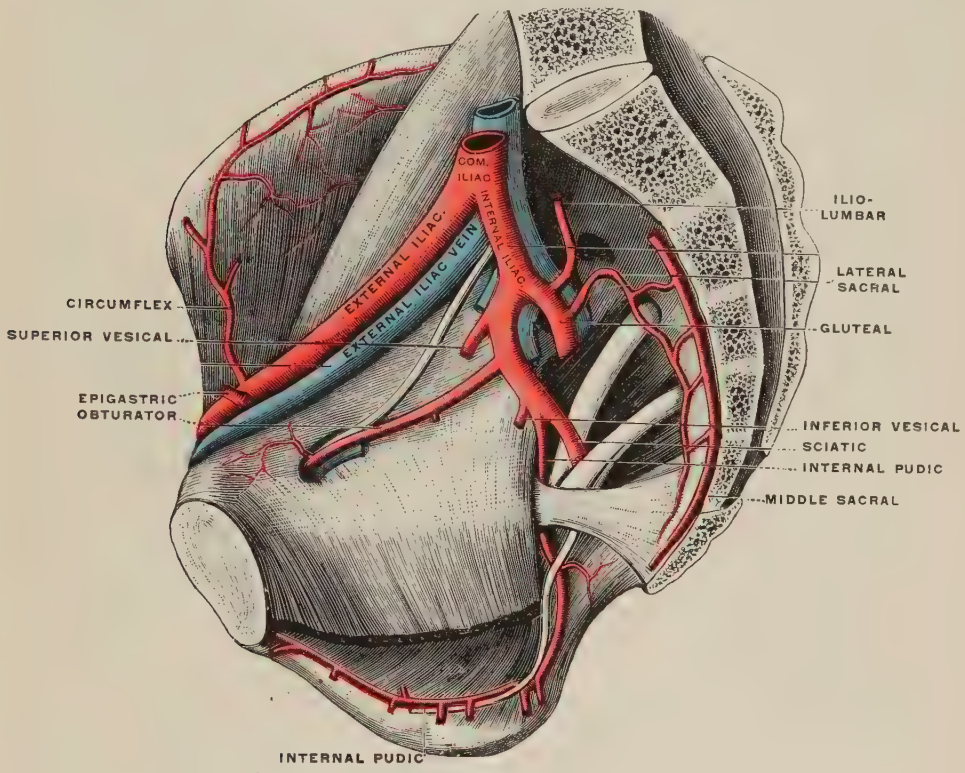

FIG. 546.—External iliac vein of right side. (Testut.)

right side above it inclines behind it. It contains one or two valves, and just above the inguinal ligament it receives the deep epigastric and the deep circumflex iliac veins, which accompany the corresponding arteries. A pubic vein, corresponding to the pubic branch of the obturator artery, ascends from the obturator vein to join the external iliac vein, and sometimes forms the main outlet of the obturator vein.

The Portal System of Veins (Fig. 547).

These are distinguished from other veins by beginning and ending in capillaries. The portal vein collects the blood from the chylopoiëtic viscera (the stomach, intestines, and pancreas), as well as from the spleen and the gall-bladder, and conveys it to the liver, to the capillaries of which it is distributed to be collected, together with the blood from the hepatic artery, by the hepatic veins, and so carried to the vena cava. The veins of this system have no valves.

The **Portal Vein** (*vena portæ*) (Fig. 548) is formed by the union of the splenic and the superior mesenteric veins, behind the upper end of the head of the pancreas, in front of the vena cava, and opposite the right side of the body of the first lumbar vertebra. From this point it runs upward and somewhat to the right for about three inches, to near the right end of the transverse fissure of the liver. Here it is somewhat enlarged (*sinus of the portal vein*), and divides into right and left branches, which enter their respective lobes and divide into

branches, in company with the hepatic artery and the hepatic duct. In its upward course it passes behind the first part of the duodenum, and then between the two layers of the right border of the small omentum, where it lies behind and between the hepatic artery on the left, and the common bile-duct on the right, and in front of the foramen of Winslow. These three structures, with the accompanying nerves and lymphatics, are enclosed by a connective-tissue sheath

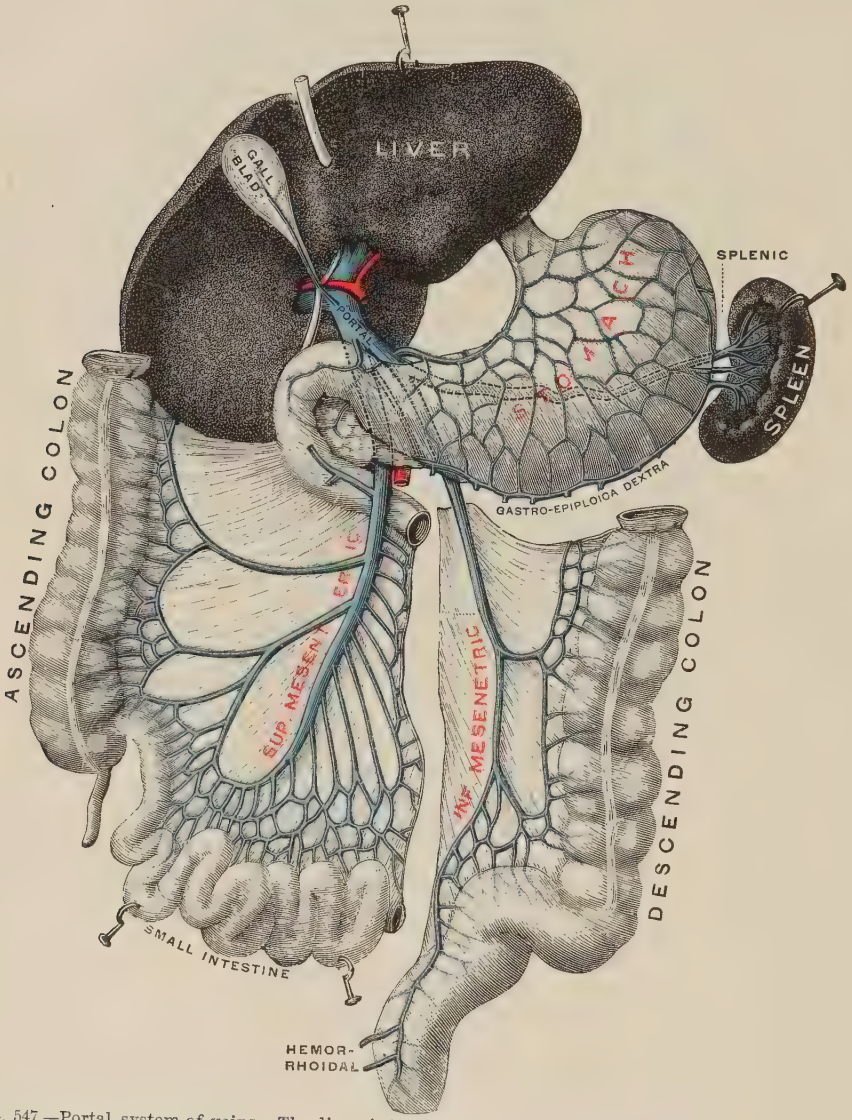

FIG. 547.—Portal system of veins. The liver is turned upward and backward, and the transverse colon and most of the small intestines are removed. (Testut.)

called the capsule of Glisson. The *left branch* is longer and smaller than the right, and where it crosses the umbilical fissure it is joined in front by the round ligament, the remains of the fœtal umbilical vein, and behind by another fibrous cord, the remains of the ductus venosus.

Tributaries.—Besides the superior mesenteric and the splenic veins, which by their union form the portal vein, the latter receives the pyloric and coronary veins from the stomach, and sometimes the cystic vein, which usually runs into the right branch.

The *Superior Mesenteric Vein* accompanies the corresponding artery, lying to the right and in front of it, and returns the blood from the parts supplied by it (the small intestine, cæcum, ascending and transverse colon) by radicles corresponding to the branches of the artery. It passes upward between the layers of the mesentery, and then in front of the third part of the duodenum and behind the pancreas, where, after receiving the *right gastro-epiploïc vein*, it joins the splenic vein to form the portal vein.

The *Inferior Mesenteric Vein* returns the blood from the rest of the large intestine (rectum, sigmoid flexure, and descending colon). Commencing in the hemorrhoidal plexus of the lower end of the rectum, where it freely anastomoses

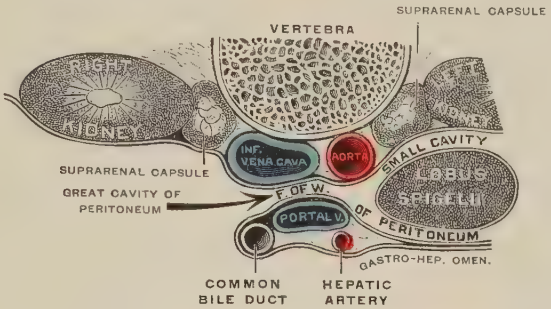

FIG. 548.—Transverse horizontal section through the foramen of Winslow, showing the relations of the portal vein. (Testut.)

with branches of the internal iliac vein, it passes up and out of the pelvis to the left of the inferior mesenteric artery. Above the origin of the latter it ascends, behind the peritoneum on the left side of the aorta, to the deep surface of the pancreas, where, inclining to the right, it joins the splenic vein near its termination.

The *Splenic Vein* is a vessel of large size, which passes from left to right below its companion artery, behind the pancreas. It commences by the union of several large branches from the hilum of the spleen, and ends, after crossing in front of the aorta, by joining the superior mesenteric vein, nearly at a right angle, to form the portal vein. It receives tributaries corresponding to the branches of the artery, and, in addition, the inferior mesenteric vein.

The *Pyloric Vein* is a small vessel which runs along the small curvature of the stomach from left to right in company with the (superior) pyloric artery. It opens into the lower part of the vena portæ.

The *Coronary* or *Gastric Vein* is a larger vessel, which accompanies the artery of the same name along the small curvature of the stomach from right to left. Near the cardiac orifice of the stomach it receives œsophageal veins and turns to the right across the spine, to end in the portal vein a little above the foregoing.

The Veins of the Pelvis.

The **Internal Iliac Veins** are short trunks without valves, which lie behind and to the inner side of the internal iliac arteries. They extend from the upper part of the great sacro-sciatic foramina to the sacro-iliac articulations, where they join the external iliac to form the common iliac veins. Each is formed by the union of veins corresponding to the branches of the internal iliac artery, excepting the *ilio-lumbar vein*, which opens into the common iliac vein, and the fœtal *umbilical veins*, which connect with the left branch of the portal vein.

The *Tributaries* correspond to the similar branches of the artery, except that the pudic vein does not begin in the dorsal vein of the penis, but in the veins of the corpus cavernosum.

The visceral veins are characterized by their large size, the number of their valves, and their frequent anastomoses, by which several connected plexuses are formed—*i. e.*, *prostatic*, *vesical*, *vaginal*, *uterine*, and *hemorrhoidal*.

The *Lateral Sacral Veins.*—These parietal tributaries also form a plexus, the *sacral plexus*, over the front of the sacrum, by anastomoses with one another and with the middle sacral veins. This plexus communicates with the veins of the spine through the anterior sacral foramina.

The *Dorsal Vein of the Penis* (Fig. 549), beginning in a plexiform circle of veins around the corona glandis, passes backward in the median dorsal groove of the penis, between the two dorsal arteries. At the root of the penis it continues backward through the suspensory ligament, and then through the triangular ligament, whereupon it divides into two lateral branches, which enter the prostatic plexus. It receives tributaries from the substance and surface of the penis. In front of the triangular ligament it communicates with the internal pudic veins. The dorsal vein may commence as two lateral vessels in front, which unite at a variable distance from the root of the penis.

FIG. 549.—Veins of the penis. (Testut.)

The *Gluteal, Sciatic, Obturator,* and *Internal Pudic Veins,* save for the exception above noted in the case of the internal pudic vein, correspond with the arteries and arterial branches which they accompany.

The *Prostatic Plexus* surrounds the prostate, especially at its base, sides, and in front, and lies beneath the sheath derived from the recto-vesical fascia. Besides the veins of the prostate it receives the dorsal vein of the penis in front, and communicates with the vesical and hemorrhoidal plexuses. It is frequently much enlarged and varicose in old men, and often contains phleboliths or vein-stones.

The *Vesical Plexus* surrounds the bladder beneath its peritoneal coat. It is particularly developed at the base and neck of the organ, where it communicates with the hemorrhoidal plexus, and with the prostatic plexus in the male, the vaginal plexus in the female. The prostatic and vesical plexuses open into the internal iliac veins by vessels passing from their lateral aspect. An abundant plexus of veins is often met with on the anterior surface of the bladder on opening that organ by the suprapubic incision.

The *Vaginal Plexus* surrounds the lower part of the vagina, and communicates with the vesical and hemorrhoidal plexuses and with the veins of the uterus.

The *Uterine Plexus* empties in part through the ovarian veins, and in part through the veins which accompany the uterine arteries. It is much enlarged during pregnancy.

The *Hemorrhoidal Plexus* lies beneath the mucous membrane of the lower part of the rectum. It communicates with the plexuses in front of it, and empties through the superior, middle and inferior hemorrhoidal veins, which accompany the arteries of the same name.

As the superior hemorrhoidal vein is a tributary of the portal system through the inferior mesenteric vein, and the other hemorrhoidal veins enter the internal iliac vein, a free anastomosis is thus established between the two

through this plexus. The veins of this plexus have no valves; hence the frequency of hemorrhoids from obstruction of the portal circulation in the liver.

VEINS OF THE LOWER EXTREMITY.

These, like the veins of the upper extremity, are divided into two sets, superficial and deep.

Superficial Veins of the Lower Extremity (Figs. 550–552).

These consist of two main trunks, internal and external, which commence in an arched plexus over the instep and on the dorsum of the foot, called the *dorsal plexus*.

The **Dorsal Plexus** receives the *dorsal digital veins* and branches from the small but numerous plexiform veins of the sole, which pass up behind the clefts of the toes and around the outer and inner borders of the foot. The veins are provided with numerous valves.

The **Internal** or **Long Saphenous Vein** commences at the inner part of the dorsal plexus, where it receives a vein of large size from the inner side of the great toe, and ends in the femoral vein an inch and a half below the inguinal ligament, after perforating the cribriform fascia of the saphenous opening. In its course it ascends in front of the internal malleolus, along the inner side of the leg, with the internal saphenous nerve, then behind the internal condyle of the femur, and finally upward, forward, and somewhat outward on the inner and forepart of the thigh. It is joined by various superficial tributaries along its course, by communicating branches from the deep veins of the sole, leg, and thigh, and, just below its termination, by the *superficial circumflex iliac*, *superficial epigastric*, and *external pudic veins*, which accompany the arteries of the same name, and also in many cases by a large anterior branch, which ascends over the front of the thigh. This vein contains from seven to twenty valves, more numerous in the thigh than in the leg.

The **External** or **Short Saphenous Vein**, commencing at the outer part of the dorsal plexus, ascends behind the external malleolus and then on the outer and back part of the leg, with the external saphenous nerve, to the lower part of the popliteal space, where it perforates the deep fascia, and ends in the popliteal vein.

Along its course it is joined by superficial radicles from the foot, the heel, and the back of the leg, and communicates with the deep veins at the ankle and in the leg. Near its termination a communicating branch usually runs upward and inward to the internal saphenous vein, and sometimes forms the main outlet of the external saphenous vein. This vein contains from nine to fourteen valves.

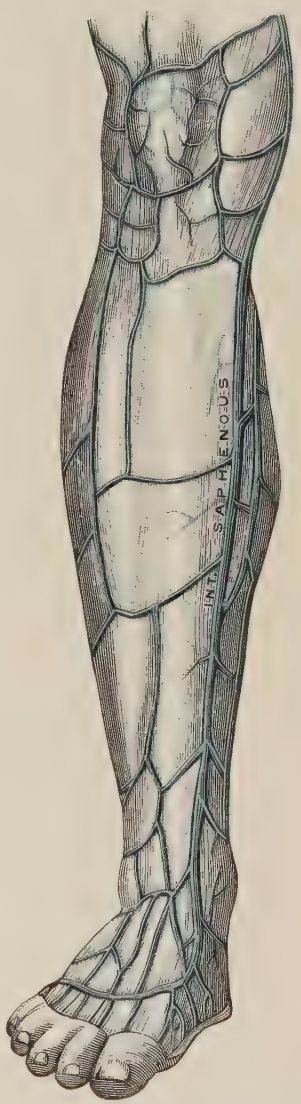

FIG. 550.—Superficial veins of the front of the leg and foot. (Testut.)

Deep Veins of the Lower Extremity.

Below the knee the deep veins accompany the respective arteries in pairs, as venæ comites.

The single **Popliteal Vein** is formed by the junction of the venæ comites of the anterior and posterior tibial arteries, near the lower border of the popliteus

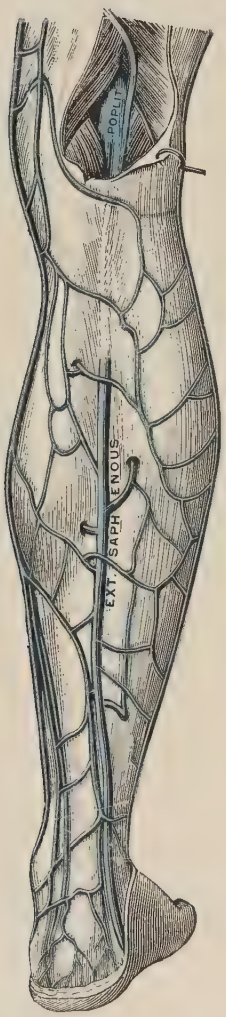

FIG. 551.—Superficial veins of the dorsum of the leg. (Testut.)

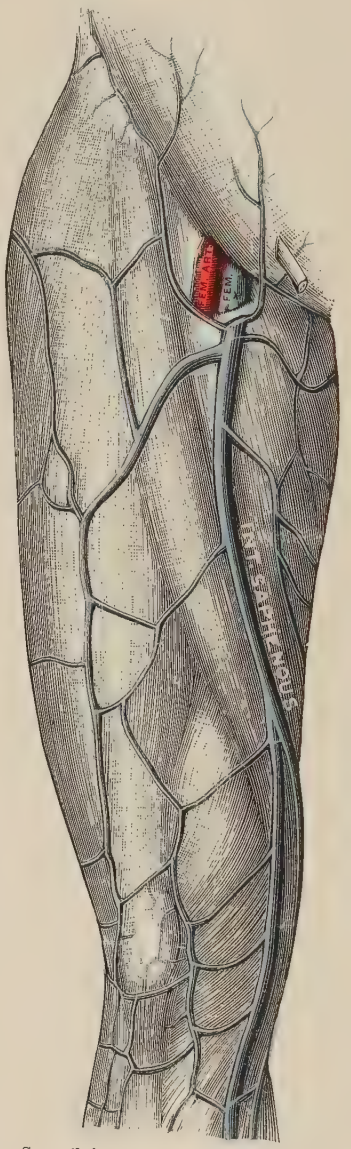

FIG. 552.—Superficial veins of the front of the right thigh. (Testut.)

muscle. This vein lies superficial to its artery throughout, internal to it below, and external to it above, after crossing it obliquely. It receives radicles corresponding to the branches of the artery, and in addition the external saphenous vein. Two or three valves are usually present. After passing with its artery through the opening in the adductor magnus, it is continued as the **Femoral Vein** up to the level of the inguinal ligament. Below, in Hunter's canal, the femoral vein lies behind and somewhat to the outer side of its artery, but, as it ascends, it

crosses obliquely behind the artery, so as to be internal to it in the upper part of Scarpa's triangle. It is joined by tributaries corresponding to the branches of the artery, except for the tributaries named as joining the upper end of the internal saphenous vein. Its tributaries include the *Deep Femoral Vein* (which ascends in front of its artery), and also, near its upper end, the internal saphenous vein. It contains three or four valves, one of which is just above the opening of the deep femoral vein, and another just below the inguinal ligament. At its upper end it is separated internally from the crural canal by a thin septum of fascia, passing between the front and rear walls of the femoral sheath.

THE FŒTAL CIRCULATION.

As the fœtus in the womb cannot use its alimentary tube or its respiratory apparatus for purposes of sustenance as the child does after birth, its support is accomplished by means of modifications in the blood-vascular system, certain devices being introduced which serve a temporary purpose, and, when no longer of use, are suppressed. These parts are the placenta and umbilical cord, which are outside of the body of the fœtus; and the continuation of the umbilical vein, the ductus venosus, the Eustachian valve, the foramen ovale, the ductus arteriosus, and the hypogastric arteries, which are contained in the body of the fœtus. After birth the extrafœtal parts decompose; the foramen ovale is closed; the Eustachian valve dwindles until, in the mature body, it is difficult to detect it; and the umbilical vein, the ductus venosus, the ductus arteriosus, and the hypogastric arteries shrink away into impervious, fibrous cords.

The *placenta* is an organ developed in the early part of pregnancy in close union with the inner surface of the uterus. It is composed of blood-vessels, and through it an interchange takes place between the blood of the mother and that of the developing child—the parent furnishing nutritious materials, the fœtus giving up those that are excrementitious.

The blood is carried from the placenta through the umbilical cord to the fœtus by the *umbilical vein*, which enters at the navel, and goes upward in the free margin of the falciform ligament to the anterior border of the liver. It runs in the umbilical fissure on the under surface of the liver, giving branches on its way to the left portions of the gland, and at the transverse fissure a large branch, which unites with the portal vein. From this point the umbilical vein is called the *ductus venosus*, and runs in the fissure at the left of the Spigelian lobe, leaving this to empty into the inferior vena cava, which receives also from the liver through the hepatic veins the blood brought into that organ by the umbilical and portal veins combined, and that which was distributed to its left portion. The inferior vena cava conveys from the lower limbs and the lower part of the trunk impure blood, which is now mingled with that from the liver, and the mixed stream flows to the right auricle of the heart. Entering at the lower part of this cavity, it is guided by the *Eustachian valve*, which is very large in the fœtus, across the cavity, through the *foramen ovale* into the left auricle, where a little impure blood from the pulmonary veins is mingled with it. It then passes into the left ventricle, and thence into the aorta, which carries almost all of it through the great branches of the arch to the head, neck, and upper limbs, though a little goes into the descending aorta and to the parts supplied by it. From the head, neck, and upper limbs the blood is returned through the superior vena cava to the right auricle, through which it passes with little or no mingling with the crossing stream from the inferior vena cava, enters the right ventricle, and is driven thence into the pulmonary artery. Only a little of this blood is sent to the lungs, however, these organs being functionless at this period; but almost all of it passes through the *ductus arteriosus*, a vessel connecting the pulmonary artery at its bifurcation with the descending portion of the aortic arch. From the aorta a small part of the blood is carried to the lower limbs and the lower

part of the trunk, the greatest part passing by way of the anterior trunk of the internal iliac arteries through the *hypogastric arteries* which run to the sides and apex of the bladder, thence upward to the navel, at which they leave the fœtus, becoming the *umbilical arteries*, and, twining spirally around the umbilical vein, go to the placenta.

It will thus be seen that the tissues of the fœtus are nowhere furnished with perfectly pure blood. That which reaches the head, neck, and upper limbs is the best, and this fact accounts for their much better development at birth than is shown by the lower part of the body and the lower limbs.

THE LYMPHATIC SYSTEM.

By F. H. GERRISH.

THE lymphatic system begins in the microscopic crevices between the cells and fibres of almost all tissues. These diminutive spaces are called "juice channels" or "juice canals," because they are the receptacles of the fluids which exude from the adjacent blood-vessels and tissues. They communicate very freely among themselves, and also with the beginnings of the capillary tubes, which are the radicles of the lymph-vessels (lymphatics), and into the latter they discharge their contents.

THE LYMPH-VESSELS.

The plan upon which the lymphatics are constructed is almost identical with that of the venous system. The small vessels unite and form larger, these in turn act as the radicles of others of still greater size, and after this manner the



FIG. 553.—Epithelium lining lymph-vessel. (Testut.)

FIG. 554.—Lymph-vessel laid open lengthwise; showing arrangement of valves.

process continues until the largest tubes are reached. There is constant increase in size and diminution in number from the periphery to the centre of the system. But the lymphatics are much smaller than the corresponding veins. Upon the surface of the body frequent plexuses of minute vessels are found, which present an intricate and very delicate reticular appearance.

All lymph-vessels contain lymph, and those of the small intestine at certain

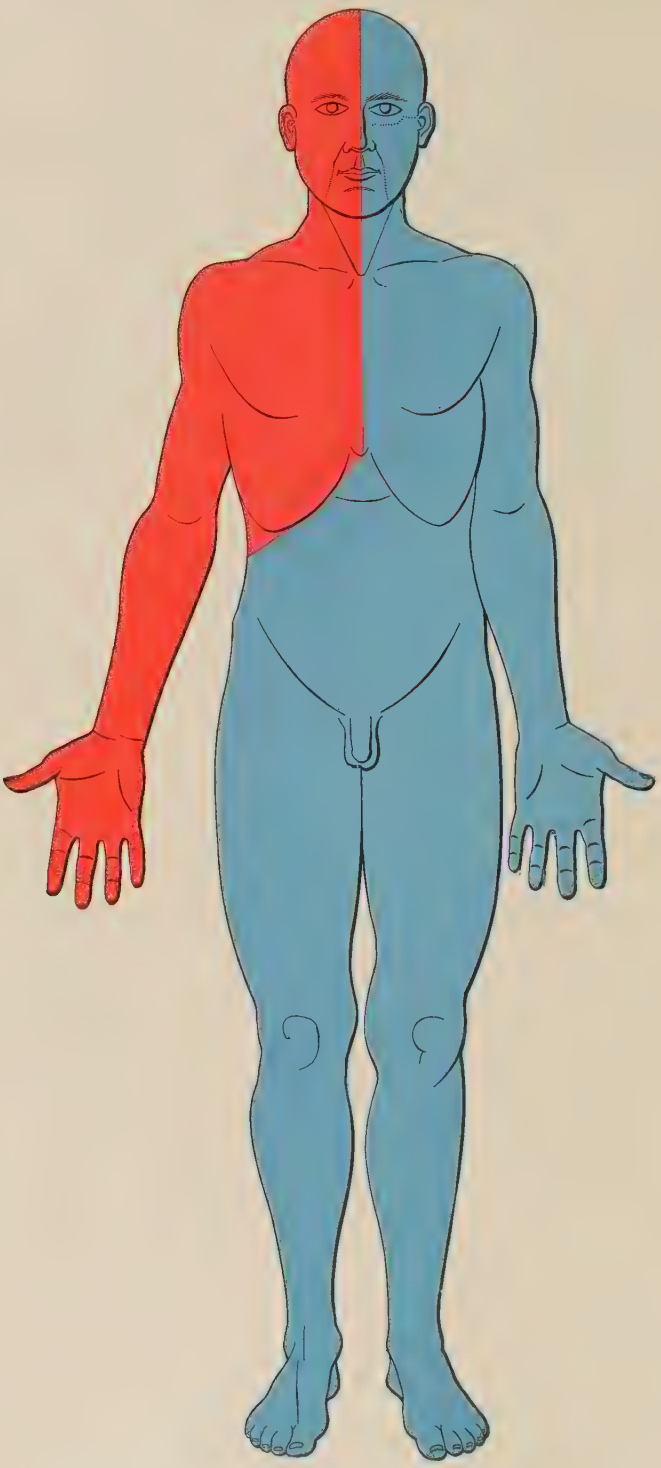

FIG. 555.—The regions whose lymph flows into the right lymphatic duct are suggested by the red area; those which are tributary to the thoracic duct by the blue. (F. H. G.)

times carry chyle also (see page 57). The chyle-bearing lymphatics do not differ structurally from other vessels of the system; but they are often called *lacteals* (literally "pertaining to milk") because, during the period of intestinal digestion, when they are filled with chyle, which is white, they look as if distended with milk, whose Latin name is *lac*.

The course of the fluid in the lymphatics is always from the periphery toward the centre, the materials being sucked up, as it were, in the distal parts of the body, and carried proximally. Consequently the lymphatic system is often spoken of as "the absorbent system." But this is an undesirable name, inasmuch as the veins, also, do considerable absorption work.

A close relationship has long been recognized between the lymphatics and the true serous membranes. These closed sacs are to be regarded as prodigiously expanded lymph-spaces, and are sometimes and appropriately called *lymph-chambers*. The true stomata of these serous membranes are the mouths of lymphatic vessels. The recognition of this continuity of lymphatic and serous surfaces is of great physiologic and pathologic importance.

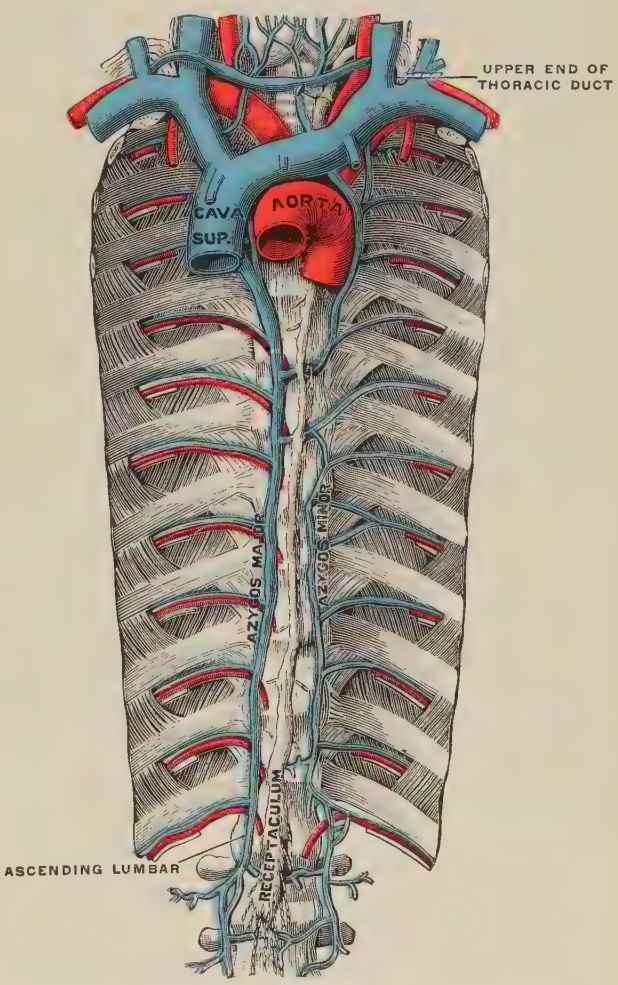

FIG. 556.—The thoracic duct and right lymphatic duct. (Testut.)

The Structure of Lymph-vessels.—The lymphatics resemble the veins in their structure, as well as in their arrangement. The smallest have but a single coat, composed of epithelial cells with notched edges, which fit accurately with those of the adjacent cells (Fig. 553). The larger vessels have three tunics: an inner one of epithelium (like that described above) and a little yellow fibrous tissue; a middle, made up of muscular and yellow fibrous tissues; and an outer, consisting of white fibrous tissue, with which is mixed a small amount of yellow. All of the coats are so thin as to be transparent. At very short intervals are valves, formed by folds of the lining membrane (Fig. 554). The position of a valve is marked by a circular constriction, distal to which is a pronounced bulge; and in this way a peculiar beaded or moniliform ("necklace-like") appearance is produced. The valves prevent backward flow of the lymph.

The lymphatics are divided into two sets, the superficial and the deep, according to their situation. *The superficial lymph-vessels* course in the subcutaneous areolar tissue. In the limbs they are more abundant upon the inner and flexor

aspects than upon the outer and extensor. They are especially numerous at the junction of the skin with mucous membrane. *The deep lymph-vessels* accompany the blood-vessels. There is free communication between the vessels of the same set; but there is no connection between the superficial and deep, except as they empty into the same nodes.

Ultimately the lymphatics end in veins; and thus the lymphatic system is seen to be an adjunct to the blood-vascular system. The lymph mingles with the venous blood, and the leucocytes, which were lymph-corpuscles a moment ago, are colorless blood-corpuscles now.

There are two points at which the lymph is poured into the blood, one on each side, where the internal jugular and subclavian veins unite to form the brachiocephalic (Fig. 556). On the right side the vessel, called the *right lymphatic duct*, is an inch or less in length, and receives the lymph from the right side of the head, neck, and chest, the right lung, the right heart, the right upper limb, and the upper surface of the liver. A double valve guards its proximal opening. On the left side the vessel, called the *left lymphatic duct*, or, more commonly, the *thoracic duct*, is a large trunk, which has its tributaries in all portions of the body not just enumerated. The parts drained by each are suggested with practical accuracy by a glance at Fig. 555. The thoracic duct begins in a pear-shaped dilatation, called the *receptaculum chyli*, situated in front of the second lumbar vertebra. It runs upward at the right of the aorta to the level of the fourth thoracic vertebra, where it passes behind that great vessel and the left subclavian artery, and then arches outward and downward to its termination. It is as large as a goose-quill, and from fifteen to eighteen inches long. It has numerous valves, a double one standing at its junction with the venous system.

LYMPH-NODES

AND OTHER LYMPHADENOID STRUCTURES.

Besides the lymph-vessels, which have just been described, the lymphatic system comprises a large amount of a compound tissue, known as *lymphadenoid tissue*. The framework of this material is adenoid reticular tissue (see page 50), and in its meshes are irregular masses of leucocytes. This lymphadenoid tissue exists in several forms, which differ from each other mainly in the degree of their compactness, some being firm, well-defined, and encapsuled, others extremely diffuse, and still others presenting various stages intermediate to these.

Sometimes, as in the mucous membrane of the intestines, the peculiar material is infiltrated, has no clearly defined boundaries, and hence is called *diffuse lymphadenoid tissue*. It is a mere network of adenoid reticular tissue enclosing colorless corpuscles. A step beyond this condition occur small masses in the submucous or subserous membrane, distinctly defined, and encircled by a series of lymph-vessels. A typical example of this class is seen in the so-called *solitary glands* of the intestine. When a number of such bodies are grouped into a coherent mass, the resulting structure is known as an *agminated gland*. Somewhat more distinct aggregations of lymphadenoid tissue, encased in a well-marked capsule, are frequently found located in small depressions in mucous membrane, illustrations of which are seen in the tongue, the tonsils, and the pharynx.

The most sharply defined collections of lymphadenoid tissue are the *lymph-nodes*—commonly, but less appropriately, called lymphatic glands. They are not, as are the varieties mentioned above, connected directly with a mucous surface; they always are furnished with a distinct capsule, which maintains their characteristic form; and they always occur in the course of lymph-vessels.

LYMPH-NODES.

A lymph-node (Fig. 557) is a small, roundish or ovoid body, situated in the course of a lymph-vessel. Upon its proximal aspect is usually a little depression

or notch, called the *hilum*, at which its arteries enter, and its veins and efferent vessels emerge. The capsule of the node is composed mainly of white fibrous tissue, but has a slight admixture of smooth muscular tissue. From its inner surface *trabeculæ* ("little beams") project toward the centre of the node, these being broad and shelf-like at the periphery, which is called the *cortex* ("bark"), but narrow and like slender rafters in the central portion, the *medulla* ("pith"). In no part are the spaces which these enclose completely circumscribed, and thus, as in areolar tissue, there is free intercommunication between them.

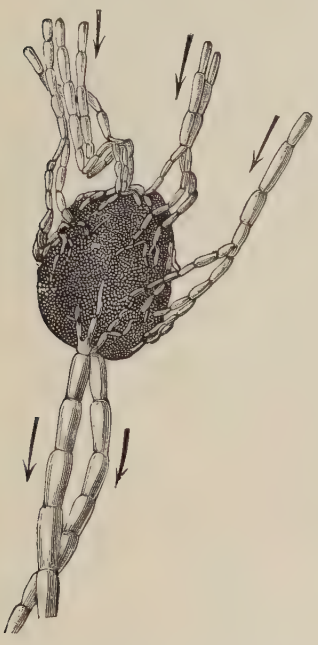

FIG. 557.—A lymph-node with its afferent and efferent vessels. (Testut.)

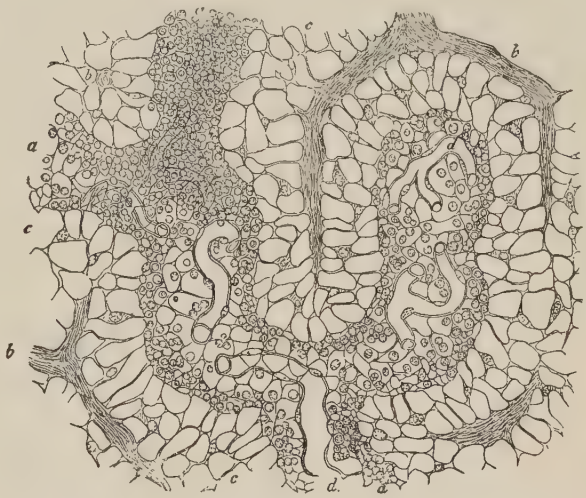

FIG. 558.—Portion of the medulla of a lymph-node. *a a a*, anastomosing columns of lymphadenoid tissue; *b*, anastomosing extension of the cortical trabeculæ; *c*, lymph-sinus; *d*, capillary blood-vessels. The lymph-cells in the sinus are not shown. (Recklinghausen.)

The irregular spaces are occupied by a rather solid mass of *pulp*, which, however, does not quite fill them, as it never touches the capsule and trabeculæ, but leaves a narrow interval between itself and them. This open interval, which appears in a section of the node like a channel, is the *lymph sinus*, and is crossed by a network of delicate adenoid reticular tissue, which is continuous on the one hand with the trabeculæ or capsule, and on the other with a still finer plexus of the same character, which pervades the pulp and forms the framework upon which the essential constituents of the pulp are supported (Fig. 558).

The *pulp* or proper substance of the node is a mass of leucocytes, held together by the fine reticulum just mentioned. The cells at the periphery of the collection are in a condition of multiplication by karyokinesis, and it is believed that the newly formed cells are continually liberated into the lymph sinus. The lymph-adenoid tissue is well supplied with blood-vessels.

The *lymph sinus* is a complicated series of freely communicating passages into which a number of lymph-vessels pour their contents, and from which a smaller number of lymph-vessels receive lymph. The inner coat of the entering (*afferent*) and emerging (*efferent*) vessels is continuous with the epithelial lining of the lymph sinus and the epithelial covering of the trabeculæ which traverse it. Thus there is no breach in the continuity of the surface over which the lymph flows, whether it is in the vessels or in the channels of the nodes.

The nodes, with the exception of the superficial inguinal, are situated beneath the deep fascia, though not always under its immediate covering. All told, there may be nearly 700 nodes, of which the greatest part are in the chest- and belly-cavities. The face and neck have a considerable number, the limbs a few, and the brain-case none. In size they vary from that of a large bean to such

diminutiveness that they escape gross observation, unless they have become enlarged by disease. In the groin they can easily be felt, but not in the axilla. Those of very small size are called *nodules*.

As age creeps on, the lymphatic tissues undergo senile atrophy. The thymus gland, whose nature is essentially lymphatic, diminishes and generally entirely disappears before adult life. The ordinary lymph-nodes gradually shrink in old age, though they do not altogether vanish, and all of the other lymphatic structures pursue a similar degenerative course.

The effect of lymphadenoid tissue upon the lymph which passes through it is very marked. For example, the lymph which enters a node has fewer corpuscles and less albuminoid material than that which flows out of it. We thus see that the influence of the node is toward the enrichment of the lymph. Extraneous matters absorbed by the lymph-vessels from the juice-channels are caught in the reticular tissue, which crosses the sinus, and are detained temporarily or even permanently. When these particles are bacteria they are liable to set up pathologic processes. The nodes act as sieves, which prevent to a considerable extent the infection of parts proximal to themselves.

The great majority of the nodes are arranged in colonies, a few stand singly by themselves. Each node or group of nodes receives lymph from fairly well-defined areas and parts. But at the periphery of these areas or parts abundant inosculation with vessels of contiguous regions occurs, and along the boundary lines the lymph may flow into one or the other, or even into both sets of vessels. A single organ may be supplied with lymph-vessels which are tributary to two or even more groups of nodes, as, for example, the uterus, the mamma, the penis, the pericardium.

It is of great importance that the sources of supply of lymph for each colony of nodes should be well understood, on account of their frequent infection by the absorption of disease materials. When a single node or colony is invaded by pathologic germs, attention is immediately directed to the region in which must be sought the lesion by which toxic material has been introduced. Consequently, it is evident that the most useful, because the most practical, method of studying the lymphatic system is to ascertain what groups of nodes there are, and what vessels are tributary to each of them. The accompanying diagrams have been devised with the idea of supplementing the verbal descriptions by graphic representations, and of enabling one to see at a glance what region or regions to examine for lesions when any particular colony of nodes is diseased. As has been already remarked, the frequent anastomoses of vessels at the boundaries of contiguous regions should be borne in mind; and additionally it must be remembered that the nodes of each group communicate freely with each other, and that every cluster of nodes is more or less intimately connected with its neighbors.

The nodes will now be studied systematically according to the regions in which they are situated, and will be taken up in the following order: nodes of the head and neck; nodes of the upper limb; nodes of the lower limb; nodes of the thorax; nodes of the abdomen.

In every surgical operation involving the cutting of soft parts, lymphatic vessels are necessarily severed; but, unless the thoracic duct or the right lymphatic duct is wounded (and these accidents are very rare) the results are trivial. The lymph-vessels generally are so small and so delicate that it is impossible to see them in ordinary, normal conditions, and, consequently, it is impracticable to avoid them. Therefore, it seems undesirable to burden the following descriptions with the exact course pursued by the majority of the small lymphatics. The situation of the several colonies of nodes will be described, the areas and organs which drain into each enumerated, and the destination of its efferents mentioned; and these are the essential practical points of the subject.

THE NODES OF THE HEAD AND NECK

and their Tributary Vessels.

The nodes of the head and neck (Figs. 559, 560) are so intimately associated that it is most convenient to consider them together.

The Deep Cervical Nodes.—The most numerous series is the *deep cervical chain*, which lies along the course of the internal jugular vein. Into this group, either directly or indirectly, is poured the lymph from the entire head and neck. It is divided into two sets—the upper deep cervical and the lower deep cervical—the first extending from the base of the skull to the level of the upper border of the thyroid cartilage, the second reaching from that line to the clavicle. The *upper deep cervical nodes* receive immediately the efferents of the parotid, the internal maxillary, the submaxillary, the suprahyoid, and the lingual nodes, and the vessels from the deep muscles of the head and neck, the tonsil, the thyroid body, the lower part of the pharynx, and the upper portion of the larynx. The *lower deep cervical nodes* take the lymph from the upper deep cervical and the superficial cervical, the lower part of the larynx and thyroid, the upper parts of the

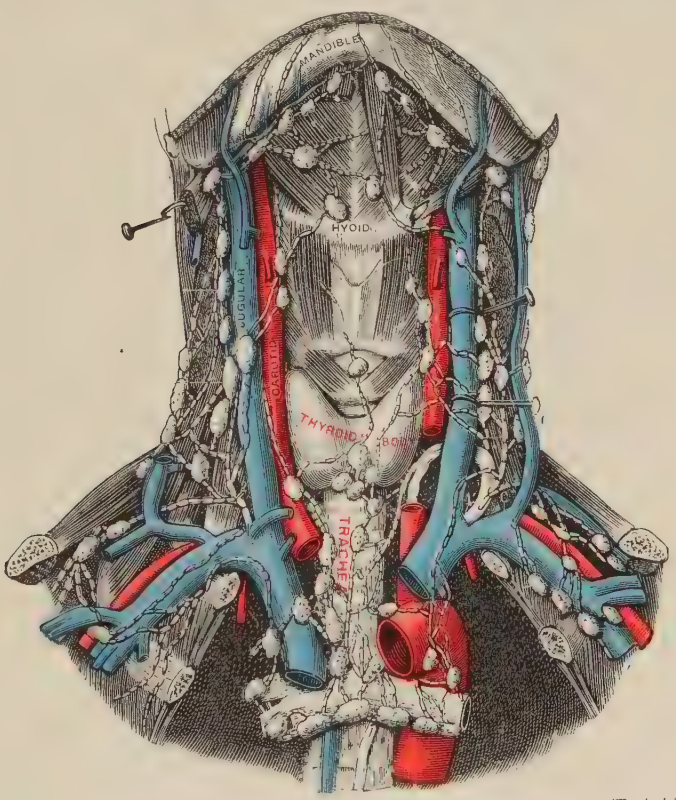

FIG. 559.—The lymph-nodes of the neck and upper part of the thorax. (Testut.)

trachea and œsophagus, and the inferior portions of the neck. The efferents of the deep cervical nodes connect with the superior mediastinal and axillary nodes.

The Superficial Cervical Nodes.—The superficial cervical nodes follow the line of the external jugular vein, occupying the posterior triangle of the neck. Their afferents come from the suboccipital, mastoid, and submaxillary nodes, the integument of the neck and that of the external ear. Their efferents run to the lower deep cervical.

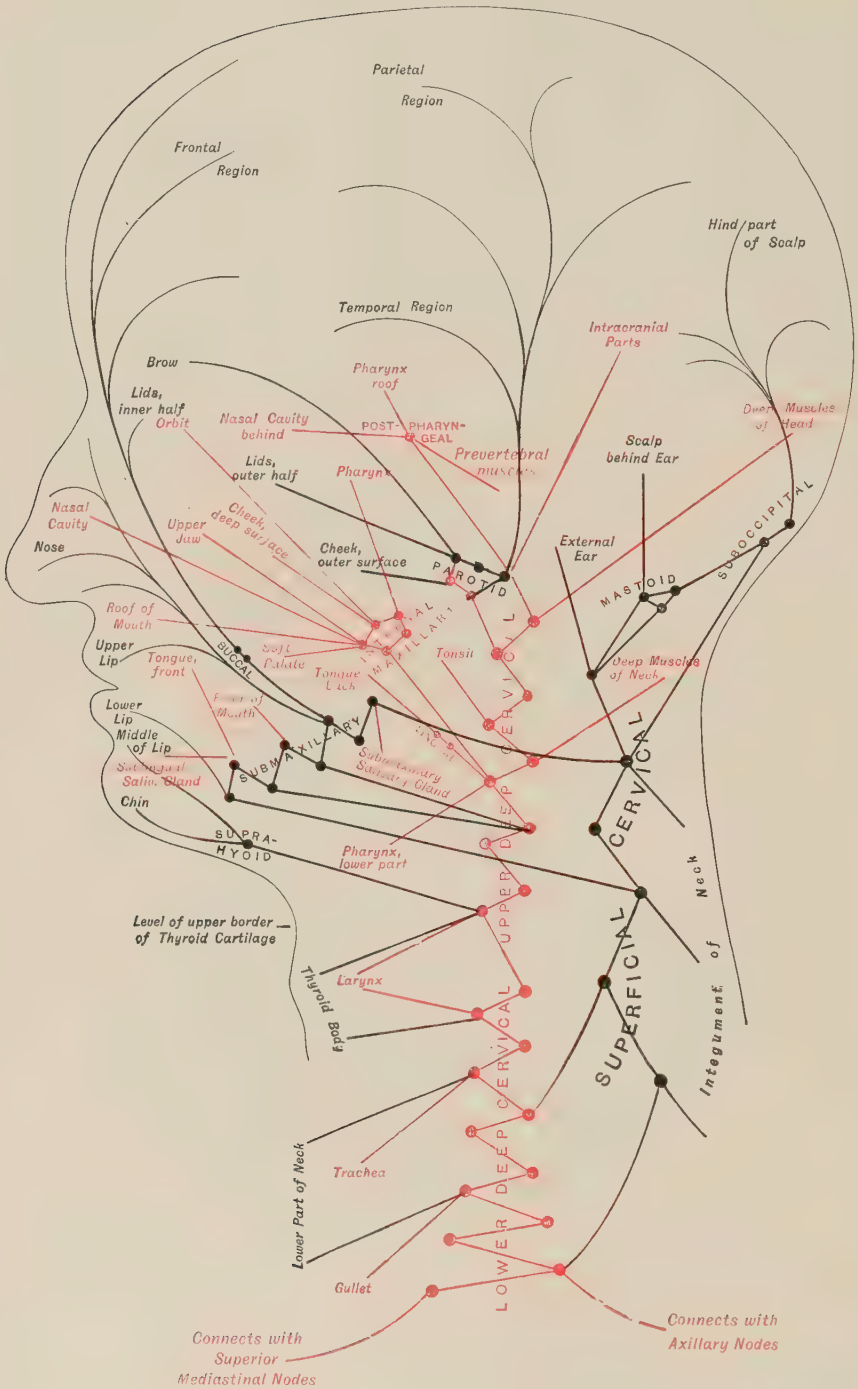

FIG. 560.—Diagram of the nodes and vessels of the head and neck, showing the regions which are drained into each group of nodes. Deep structures in red, superficial in black. (F. H. G.)

The **Suboccipital Nodes** lie just below the superior curved line of the occipital bone, taking lymph from the back part of the scalp, and passing it along to the mastoid and superficial cervical nodes.

The **Mastoid Nodes** are located behind the ear, drain the scalp in that region, and receive efferents from the suboccipital nodes. Their lymph goes to the superficial cervical.

The **Submaxillary Nodes** form a chain below and about parallel with the under margin of the mandible. They gather the lymph from the submaxillary and sublingual salivary glands, the lips, the front part of the tongue, the floor of the mouth, the nose, the frontal region, and the nasal half of both eyelids. The *buccal nodes*, which are situated upon the outer surface of the buccinator muscle, interrupt the flow in some of the vessels that bring lymph from the fore part of the face. The efferents of the submaxillary nodes empty into the upper deep cervical and the superficial cervical.

The **Suprahyoid Nodes**, which lie between the anterior bellies of the digastric muscles, are sometimes counted as belonging to the submaxillary group. They collect lymph from the middle of the lower lip and from the chin, and pour it into the upper deep cervical.

The **Parotid Nodes** are situated in the region of the ear, some being *superficial* to the great salivary gland, and others being *deep* in its substance. They derive their lymph from the outer surface of the cheek, the outer half of the lids, the brow, the parietal and temporal regions, all of the parts within the brain-case, and the post-pharyngeal nodes. They send the lymph to the upper deep cervical nodes. (Walsham says that their efferents terminate in the submaxillary and superficial cervical.)

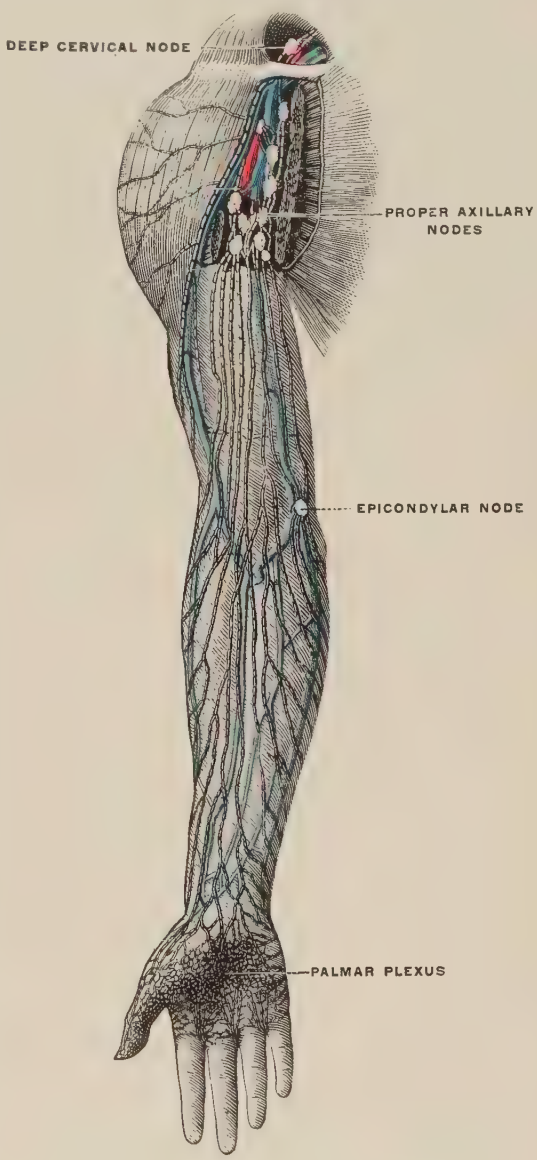

FIG. 561.—The nodes and vessels of the upper limb. (Testut.)

The **Post-pharyngeal Nodes** are placed behind the uppermost part of the pharynx. Their lymph comes from the hind part of the nasal cavity, the roof of the pharynx, and the prevertebral muscles, and goes to the parotid nodes.

The **Internal Maxillary Nodes** are situated at the side of the anterior part of the pharynx. Their afferents bring lymph from the orbit, the greater part of the nasal cavity, the upper jaw, the roof of the mouth, the soft palate, the deep surface of the cheek, and the largest portion of the pharynx; and their efferents carry the lymph to the upper deep cervical.

The **Lingual Nodes**, located on the side of the tongue, get their lymph from the back part of that organ, and empty it into the upper deep cervical nodes.

THE NODES OF THE UPPER LIMB

and their Tributary Vessels.

The **Axillary Nodes** (Figs. 561, 562) comprise four tolerably distinct groups: the axillary proper, arranged around the great vessels of the armpit; the pectoral, in the course of the long thoracic artery; the subscapular, along the subscapular artery; and the subclavian, on the costo-coracoid membrane, between the deltoid and greater pectoral muscles. There exists a free communication not only between the nodes of each set, but between the different groups; so that infection of any one may extend to all of the others. The efferents of all of these groups discharge into the thoracic duct or the right lymphatic duct.

The *proper axillary nodes* collect the lymph from the epicondylar node, the entire arm, except the surface of the outer side, and all of the forearm and hand, except a portion of the surface which drains into the epicondylar node.

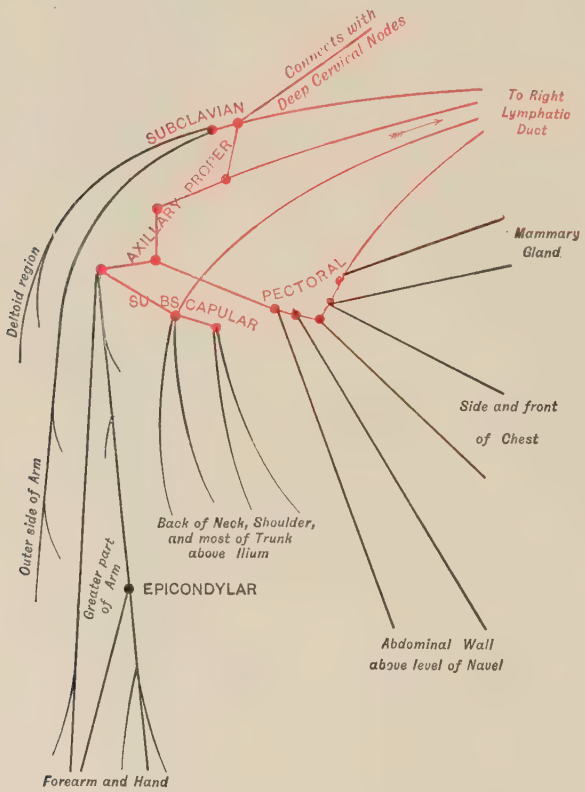

FIG. 562.—Diagram of the nodes of the right upper limb and their superficial tributaries, showing the areas drained by each group. Deep structures in red, superficial in black. (F. H. G.)

The *pectoral nodes* drain the greater part of the mammary gland, the integuments of the side and front of the chest, and those of the abdomen above the level of the navel.

The *subscapular nodes* receive lymph from the superficies of the back of the neck, the shoulder, and most of the trunk above the crest of the ilium.

The *subclavian nodes* derive their lymph from the skin of the deltoid region and the outer aspect of the arm. They connect with the deep cervical.

The **Epicondylar Node**, situated above the internal condyle of the humerus, gets its lymph from the inner portion of the surface of the hand and forearm, and its efferents carry it to the proper axillary nodes.

FIG. 563.—The nodes and vessels of the lower limb. (Testut.)

THE NODES OF THE LOWER LIMB
and their Tributary Vessels.

The nodes of the lower limb (Figs. 563, 564) are the superficial and deep inguinal, the popliteal, and the gluteal.

The **Superficial Inguinal Nodes** are arranged in two series—a superior or oblique, and an inferior or vertical.

The *superior set* is situated close to the inguinal ligament, and is subdivided into three groups—the external, the middle, and the internal—each comprising about three nodes. Their lymph comes from the integuments of the buttock and the skin around the anus, the lower and outer part of the back above the

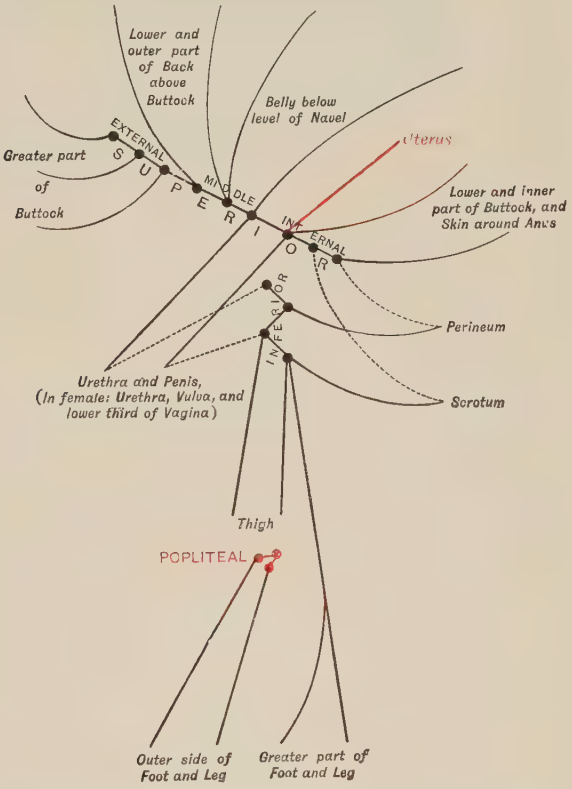

FIG. 564.—Diagram of the superficial inguinal and the popliteal nodes of the right side and their superficial tributaries, showing areas drained by each subgroup. Deep structures in red, superficial in black. Frequent variations in dotted lines. (F. H. G.)

buttock, the belly below the level of the navel, and the penis (Fig. 565); also from the distal portion of the urethra in both sexes, and from the vulva and the lower third of the vagina in the female. The scrotum and the superficial portion

of the perineum frequently drain into this set; and occasionally vessels from the uterus end in it.

The *inferior set* is situated at the saphenous opening. It takes the lymph from the superficial parts of the thigh, and of the entire leg and foot, except their outer side; also from the scrotum and the integuments of the perineum, and sometimes the penis, vulva, urethra, and lower part of the vagina.

The superficial inguinal nodes discharge partly into the deep inguinal and partly into the external iliac.

The **Popliteal Nodes**, located deeply in the ham-space, get their lymph from the surface of the outer side of the leg and foot, and the deep structures of the same segments of the limb. Their efferents join the deep lymphatic vessels of the leg.

The **Deep Inguinal Nodes** are grouped around the upper end of the femoral artery and vein. Their afferent vessels come from the superficial inguinal nodes and from the deep structures of the greater part of the limb; and their efferents run to the external iliac nodes.

The **Gluteal Nodes**, lying near the pyriformis muscle, derive their lymph from the deep parts of the buttocks, and transmit it to the internal iliac nodes.

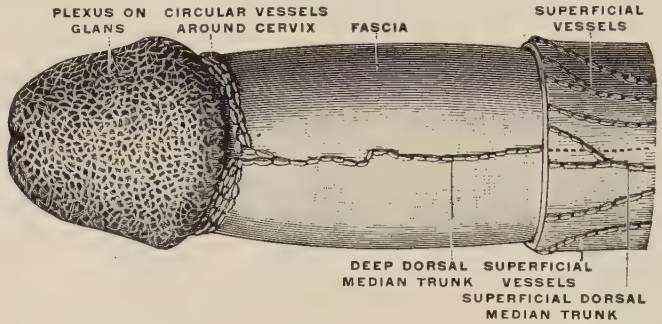

FIG. 565.—The lymph-vessels of the penis. (Testut.)

THE NODES OF THE THORAX
and their Tributary Vessels.

The nodes of the thoracic cavity (Fig. 566) are all deep, and derive their lymph from deep structures; that is, not at all from integumentary organs. They are disposed in the following groups: the sternal, the intercostal, the anterior mediastinal, the posterior mediastinal, the superior mediastinal, the bronchial, and the vena-caval. They discharge into the thoracic and right lymphatic ducts.

The **Sternal Nodes** lie in the spaces between the costal cartilages close to the borders of the breast-bone. Lymph flows to them from the deep portions of the mammary glands, from the anterior and lateral walls of the chest, from the upper part of the front and sides of the abdominal walls, from the diaphragm, and from the anterior mediastinal nodes.

The **Intercostal Nodes** are lodged in the hindmost part of the intercostal spaces. They drain the thoracic part of the spinal canal, the costal pleuræ, and the posterior and lateral portions of the chest-walls.

The **Anterior Mediastinal Nodes** are situated in front of the heart. Their lymph comes from the pericardium, the diaphragm, the liver, and the sternal nodes, and goes partly directly to the great terminal vessels of the system, and partly to superior mediastinal and sternal nodes.

The **Posterior Mediastinal Nodes**, located around the aorta, have afferents from the heart, the pericardium, the lower part of the œsophagus, and the diaphragm, and communicate freely with the bronchial nodes.

The **Superior Mediastinal Nodes** lie in front of the arch of the aorta. Their tributaries come from the thymus gland, the heart, the pericardium, the anterior mediastinal and the bronchial nodes. There is a direct connection between this group and the deep cervical nodes.

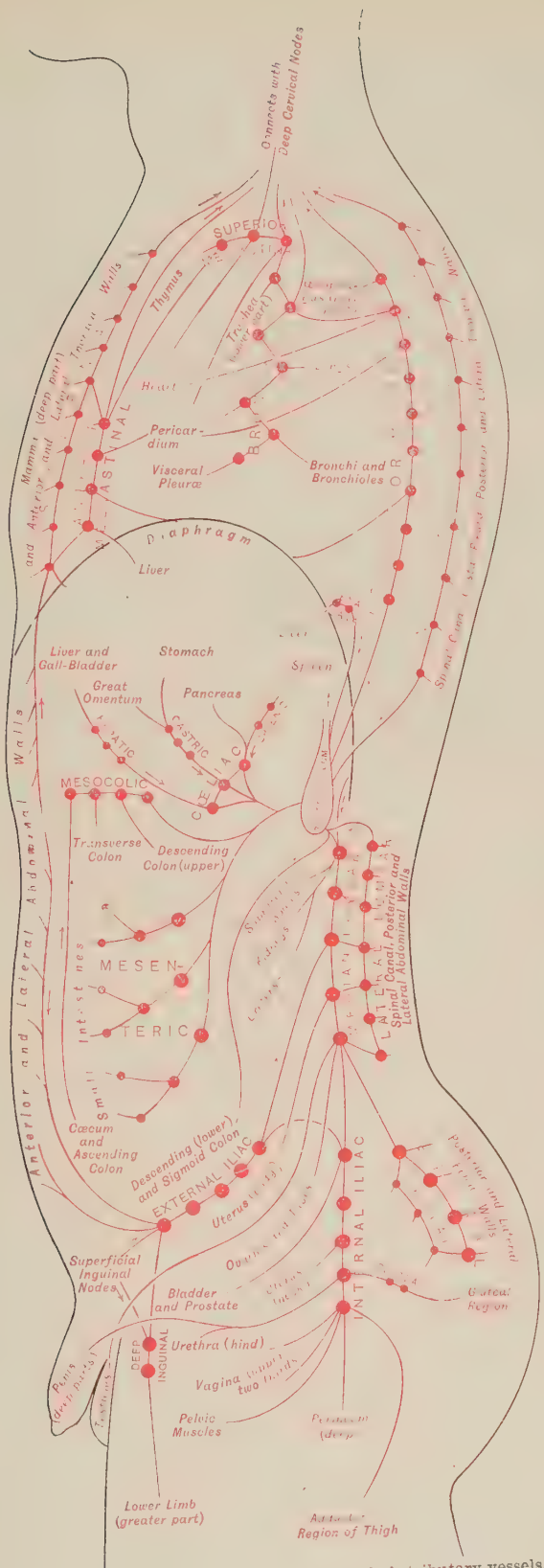

FIG. 566.—Diagram of the nodes of the trunk and their tributary vessels. (F. H. G.)

The **Bronchial Nodes** (Fig. 559), gathered at the roots of the lungs, take lymph from the lungs, the pulmonary pleuræ, the lower part of the trachea, the bronchi, the bronchioles, and the pericardium, and communicate with the superior and the posterior mediastinal nodes.

The **Vena-caval Nodes**, few and small, are placed close to the upper end of the inferior vena cava. Vessels from the upper and hind part of the liver perforate the diaphragm, and discharge into them.

THE NODES OF THE ABDOMEN and their Tributary Vessels.

Like the thoracic, the abdominal nodes (Fig. 565) are all deep, and, with a single exception, their immediate source of lymph is other than superficial. They are arranged in the following groups: the mesenteric, the mesocolic, the cœliac, the hepatic, the gastric, the splenic, the median lumbar, the lateral lumbar, the external iliac, the internal iliac, the sacral, and the rectal.

FIG. 567.—Mesenteric nodes. (Testut.)

The **Mesenteric Nodes** (Fig. 567), lodged between the layers of the mesentery, take the lymph from the small intestines through the lacteal vessels. They discharge by a large trunk into the receptaculum chyli.

The **Cœliac Nodes**, grouped in the region of the cœliac axis, receive lymph from the liver and the gall-bladder, the stomach, the pancreas, the spleen, and the great omentum, and empty it into the efferent trunk of the mesenteric. In the course of the vessels which carry lymph from the liver, stomach, and spleen to this group are small nodes, called respectively hepatic nodes, gastric nodes, and splenic nodes.

The **Mesocolic Nodes** lie between the layers of the mesocolon. Their afferents come from the cæcum, the ascending and transverse colon, and the upper portion of the descending colon; and their efferents run to the mesenteric efferent trunk.

The **Median Lumbar Nodes** are situated close to the abdominal aorta. Their supply of lymph comes from the body of the uterus, the ovaries and the Fallopian tubes, the testicles, the kidneys, the ureters, the diaphragm, the suprarenal bodies, the external iliac, internal iliac, sacral and lateral lumbar nodes; and the trunk by which they discharge into the receptaculum is joined by the efferents of the lower part of the descending and the whole of the sigmoid colon.

The **Lateral Lumbar Nodes** lie in the spaces between the transverse processes of the lumbar vertebræ. Their afferents come from the lower part of the spinal canal, and the dorsal and lateral portions of the abdominal walls; and their efferents run to the median lumbar nodes and the receptaculum.

The **External Iliac Nodes**, situated along the line of the external iliac vessels, take lymph from the ventral and lateral parts of the walls of the abdomen, and from the superficial and deep inguinal nodes. They have a communication with the internal iliac nodes, and discharge into the median lumbar.

The **Internal Iliac Nodes**, lying around the internal iliac vessels, have tributaries from the deep parts of the penis, the proximal portion of the urethra, the bladder, the prostate, the neck of the uterus, the upper two-thirds of the vagina, the deep layers of the perineum, the pelvic muscles, the adductor region of the thigh, and the gluteal nodes. They send their lymph to the median lumbar nodes, and have connection with the external iliac.

The **Sacral Nodes**, situated in the curve of the sacrum, have afferents from the dorsal and lateral pelvic parietes and from the *rectal nodes*, which take their lymph from the rectum.

THE CEREBRO-SPINAL AXIS.

By F. H. GERRISH.

THE great nervous mass which occupies the main cavity of the cranium is known as the *encephalon* ("in the head") or *brain*; and the prolongation of this, which is lodged in the canal made by the vertebræ and the cartilaginous plates between them, is called the *myelon* ("marrow") or *spinal cord*. Radiating from these structures are many cords, called nerves; and this fact suggested the name *axis* for these combined central organs, the distinguishing adjective *cerebro-spinal*, which is usually associated with the noun, deriving its first part from "cerebrum," which is the most conspicuous portion of the encephalon, and its last part from the column of bones in which the myelon is located (Fig. 568).

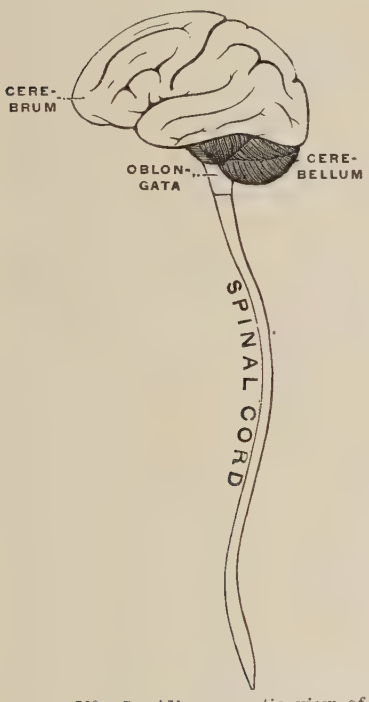

FIG. 568.—Semidiagrammatic view of the cerebro-spinal axis, left side. (Testut.)

FIG. 569.—Diagram of the conversion of the dorsal groove into a canal.

The cerebro-spinal axis is first observed in the embryo as a longitudinal groove on its dorsal aspect. Its edges grow up at the sides, curve toward the midline, meet there, and fuse together (Fig. 569). The result is that the gutter is changed into a tube. One end of the tube enlarges into a sac, and this develops into the encephalon (Fig. 570). The remainder of the tube becomes the spinal cord. The cavity of the encephalon is always continuous with that of the spinal cord.

FIG. 570.—Diagram of first stage of axial cavity.

Great changes take place in both parts, especially in the encephalon; but throughout these modifications, certain things are almost invariable. In nearly all of the amazing complications of encephalic growth, three things remain as in the simplest form of encephalon in the embryo: (1) a cavity-wall of nervous tissue; (2) a

lining of epithelium; and (3) a membranous covering, which is essentially a network of blood-vessels (Fig. 571).

(1) The nervous substance is gray, or white, or both of these. In different parts this nervous wall receives distinguishing names—gyrus, lamina, nucleus, commissure, etc.

(2) The lining is serous in character, and secretes a watery fluid, which moderately fills the entire cavity. The membrane is called *ependyma*, or merely



FIG. 571.—Diagram of transverse section of typical wall of cavity of cerebro-spinal axis.

FIG. 572.—Diagram of transverse section of axis, where a portion of the nervous wall has disappeared, allowing pia and endyma to come together.

endyma ("garment"). The fluid is called *cerebro-spinal fluid*, *cephalo-rachidian* ("head-spine") *fluid*, or *neurolymph* ("nerve-water").

(3) The covering sends nutrient vessels into the substance of the wall, and is called the *pia*, or *pia mater* ("the tender mother").

The solid wall may grow to a thickness of several inches, it may dwindle to the thinness of paper, or it may even disappear altogether (Fig. 572); but endyma and pia are persistent. The endyma is a perfect shut sac, save for three diminutive apertures by which a communication is established with another serous cavity lying outside of the axis. Real comprehension of the subject cannot be acquired without appreciation of these primary conditions, here repeated: that *the encephalon is a hollow organ, filled with fluid*; that *it has everywhere a serous lining*; that *it has a vascular plexus for its outer investment*; and that *it has nearly everywhere between its lining and its covering a solid wall of nervous tissue*, which varies immensely in thickness in different parts.

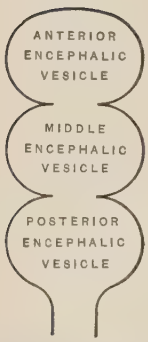

FIG. 573.—Diagram of the three secondary vesicles of the brain.

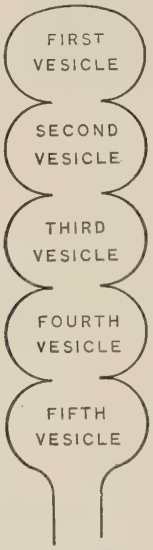

FIG. 574.—Diagram of the five ultimate vesicles of the brain.

The encephalon, at first a single vesicle, soon becomes elongated, and then constricted circularly and deeply at two equidistant points. In this way three secondary vesicles are formed (Fig. 573). They do not, however, long remain in this condition; for, while the middle one continues single, the front one and the rear one are soon constricted transversely and divided, each forming two. Thus, there is a series of five vesicles of sub-

stantially equal size, whose cavities communicate through central apertures (Fig. 574). These five vesicles are the primary forms of the five grand divisions of the adult encephalon, and are named in order, from before backward, *prosencephalon*, *diencephalon*, *mesencephalon*, *epencephalon*, and *metencephalon*. The first and second show a tendency in the developed state to revert to their original condition of unity, and the same is true of the fourth and fifth; but the third remains single and distinct from its earliest appearance to its most complete development.

Vernacular names also are given them—forebrain, betweenbrain, midbrain, hindbrain, afterbrain—but only the first of them is so clearly descriptive as to convey infallibly the idea intended, and it would be better to discard them for the technical appellations, which, while etymologically not greatly superior, are widely used by the scientific with definite meanings, and are understood by all anatomists.

When these vesicles are first observed, they are, as has been said, about equal in size and very similar in form; but the likeness which they bear to each other does not long continue: they grow at very different rates of speed, and, when fully developed, are so dissimilar in appearance that it is difficult to understand that they could have been of almost identical shape and bulk at any former period. Some parts, which are brought into close contact with others, seem to blend; while others, in nearly similar conditions, undergo shrinkage, and finally disappear.

THE CAVITY OF THE CEREBRO-SPINAL AXIS.

Let us first consider the *cavity* of the cerebro-spinal axis, ignoring for the while the enclosing walls; and, when we have gained a comprehension of this, we can proceed more understandingly to the study of the surrounding solid material.

Suppose the cavities of the five encephalic vesicles to be of equal size, and that of the spinal cord to be a cylindrical continuation from the fifth or hindmost vesicle. We have then, to start with, a series of chambers, each communicating freely with the one next behind it. This continuity of the cavities is always maintained, even though the original chambers undergo alterations of form so prodigious that only a very slight resemblance to the primitive shape remains.

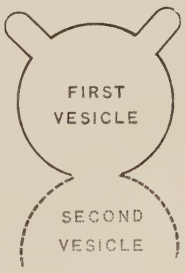

FIG. 575.—Diagram of the formation of the portæ.

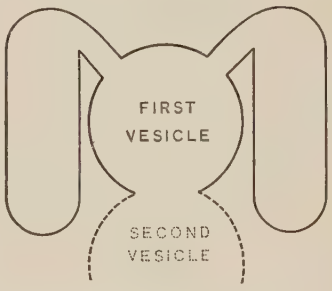

FIG. 576.—Diagram of the formation of the bodies of the lateral ventricles.

For the sake of simplification we will first examine the subject diagrammatically, taking the vesicles one by one in regular order; and, in considering each, we will ignore as far as possible the changes which in nature take place in its immediate neighbors synchronously with those in itself.

To begin with we have the *first vesicle*, the most anterior—the prosencephalon—which ultimately becomes the cerebral hemispheres. From the upper and front part of its globular cavity on each side a little sprout is put forth (Fig. 575). The distal end of this protrusion enlarges, and becomes of much greater size than the parent cavity (Fig. 576). Then each of the new appendages sends out a prolongation forward, a second backward, and a third which curls sidewise and downward. These, from their shape, are called *horns* or *cornua* (Fig. 577). In this process of enlargement the original vesicle is so far outgrown by its offshoots that it is in great danger of being lost sight of. The chief cavity on each side is called a *ventricle*, and, from its being at the side, *lateral*. Of the *lateral*

ventricle the main part is known as the *body*, and the prolongations from it are named respectively *anterior horn*, *middle* or *descending horn*, and *posterior horn*. The original sprout now serves for a passage of communication between the primary vesicle and the ventricle, and is known commonly as the *foramen of Monro*; but it is better designated as *porta* ("the doorway"). The original cavity of the vesicle, now subordinate in extent to the large chambers to which it has given rise, is called *aula* ("the hall"). Thus we have from the cavity of the first vesicle the following parts: the aula in the centre, and on each side a porta, and a lateral ventricle with its three horns (Figs. 577, 578). Notice that the aula is distinctly below the plane of the body of the ventricle, and that the middle horn descends to a level much below that of the aula.

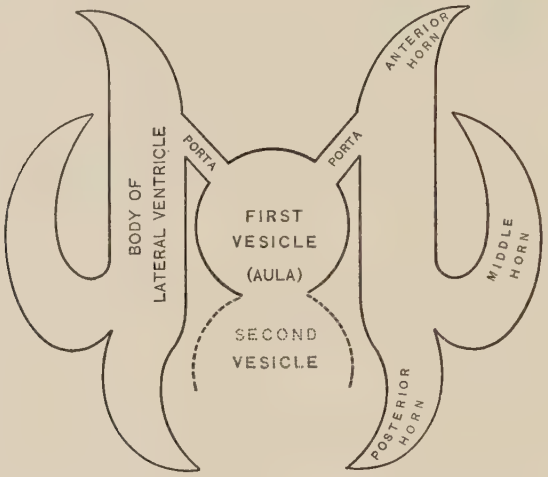

FIG. 577.—Diagram of the full development of the lateral ventricles and their cornua—view from above.

Passing to the cavity of the *second encephalic vesicle*—the diencephalon—we find that it considerably outgrows the aula, which is just in front of it. Its enlargement is very slight sidewise and is almost entirely up-and-down and backward, as if the vesicle had been squeezed between two vertical planes at the sides (Figs. 579, 580). The result of this development is to make the second vesicle a long, deep, narrow chink in the middle line—a fore-and-aft median crevice, with the aula in front and the third vesicle behind. The original constriction between this cavity and that of the first vesicle becomes practically

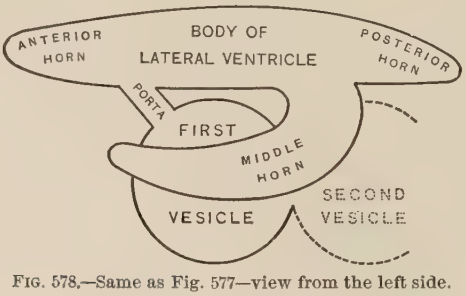

FIG. 578.—Same as Fig. 577—view from the left side.

obliterated, and, consequently, the cavities of the aula and the second vesicle merge into one, the greater portion of which is contributed by the second vesicle, that furnished by the first vesicle being located at the upper and fore part. This composite cavity, made of the whole of the second and a part of the first vesicle,

is usually called the *third ventricle*, the first and second ventricles being the lateral, which are never designated in a numerical way, but always as right lateral ventricle and left lateral ventricle. It will now be seen that the third ventricle communicates with each lateral ventricle by a separate porta.

Next we study the cavity of the *third encephalic vesicle*—the mesencephalon. This assumes a shape as if it were stretched between its neighbor in front and the one behind: it is drawn out into a small tube, and thus constitutes a long and narrow channel from the vesicle before to that behind (Fig. 581). It is named the *aqueduct* (*aqueductus Sylvii*—from Sylvius, a celebrated anatomist), and also by another name, which will be better understood a little later.

Fig. 579.—Diagram of changes in second vesicle—view from above.

The cavity of the *fourth encephalic vesicle*—the epencephalon—instead of retaining its globular shape, is flattened from above downward, as if it had been compressed between plane surfaces applied obliquely to its dorsal and ventral aspects;

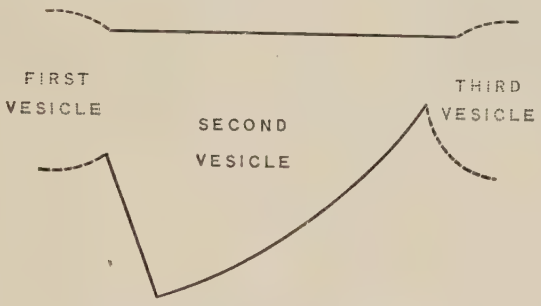

Fig. 580.—Same as Fig. 579—view from left side.



Fig. 581.—Diagram of changes in third vesicle.

and it is widened out behind, assuming a triangular form, the apex being forward (Figs. 582, 583). A little of the constriction between it and the fifth vesicle is still observable, even in the developed condition.

The cavity of the *fifth encephalic vesicle*—the metencephalon—undergoes changes in its fore part almost identical with those experienced by that of the fourth; but the triangle which it forms has its base forward, applied to the base of the triangle of the fourth vesicle, and its apex backward, and the obliquity of the surfaces is opposite to that of those of the fourth (Figs. 584, 585). Thus, the two vesicles form a single shallow cavity

Fig. 582.—Diagram of changes in fourth vesicle—view from above.

Fig. 583.—Diagram of changes in fourth vesicle—view from left side.

of rhomboidal form, when viewed from above. The hind part of this fifth vesicle is drawn out into a tube, and is continuous with the cavity of the myelon. The combined cavities of the fourth and fifth vesicles form what is commonly known as the *fourth ventricle*. We note that this fourth ventricle is connected with the third ventricle by the aqueduct, the other name of which, promised

above, can now be appreciated. It is *iter a tertio ad quartum ventriculum* ("the passage from the third to the fourth ventricle"), a name with the merit of descriptiveness, but with the fault of tiresome length.

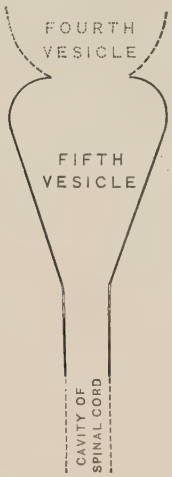

FIG. 584.—Diagram of changes in fifth vesicle—view from above.

The *cavity of the myelon* or spinal cord retains its original, cylindrical shape, and is called the *central canal of the spinal cord.* It is continuous at its cephalic end with the fourth ventricle.

The preceding diagrams have been drawn as if all of the vesicles were upon the same plane, for the sake of simplicity; but, during their synchronous development, a marked

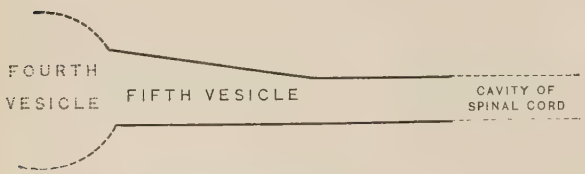

FIG. 585.—Diagram of changes in fifth vesicle—view from left side.

curve with a ventral concavity takes place at about the junction of the third ventricle and the aqueduct, and thus the long axis of the spinal cord is brought nearly to a right angle with the plane of the lateral ventricles.

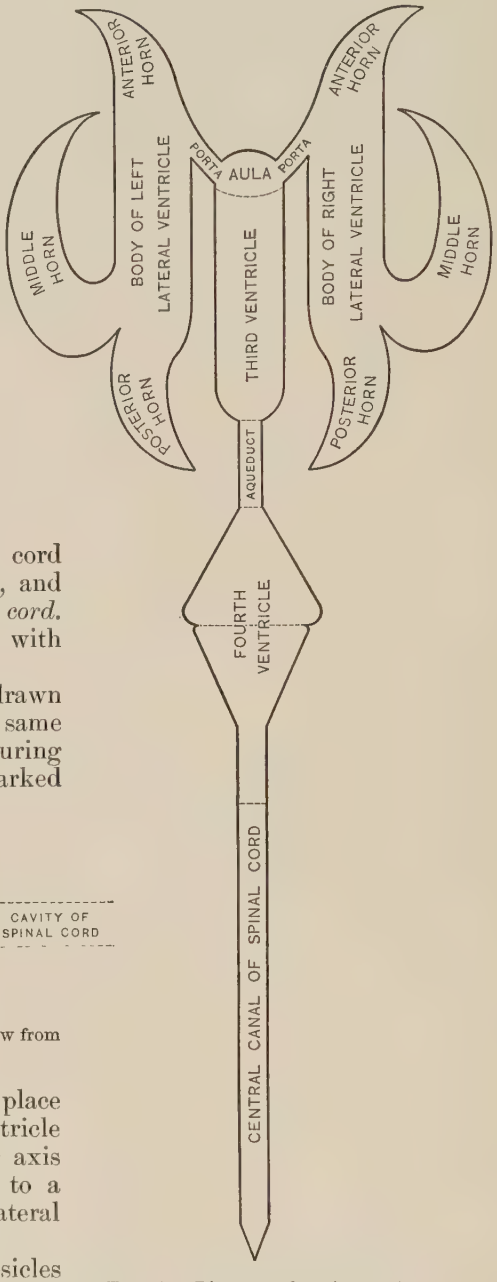

FIG. 586.—Diagram of entire cavity of cerebro-spinal axis—view from above.

The description of the encephalic vesicles here given is not designed for a portrayal of the process which is discovered by embryological research, but is intended merely to present in a diagrammatic manner the main features of the results which are reached by the developmental process.

The shape and relative size of these different cavities, when fully formed, can be seen in Fig. 587, which represents a cast, made by filling them with a

liquid material, which solidified on standing. The surrounding solid tissue being removed, we obtain a perfect cast of the *general ventricular cavity*, as the combined chambers and tubes of the encephalon are called.

The general ventricular cavity is moderately filled with a serous fluid, the cerebro-spinal, which mingles with the fluid occupying the serous space outside of the encephalic mass through a small hole, the *foramen of Magendie* (metapore), in the roof of the fourth ventricle.

To illustrate the complexity and also the continuity of this cavity of the encephalon, imagine the shortest course which a small, aquatic insect must pursue in going from the apex of the middle horn of the lateral ventricle to the canal of the spinal cord, without leaving the cavity. First it would swim outward, and then successively backward, upward, inward, and forward, following the peculiar curves of the middle horn, before it could reach the body, the main hall, of the lateral ventricle. It would then pass forward and upward, for the floor of the ventricle slopes down from its front end. At the median side of the fore part of the ventricle, just at the beginning of the anterior horn, the little creature would work its way through the porta, a brief passage-way, which would let the traveller down into the third ventricle. Coursing backward through this deep crevice to its hind end, a narrow channel, the aqueduct, would be entered and traversed in a direction backward and downward. Emerging from this contracted passage, it would find itself in the shallow fourth ventricle, the long axis of which is somewhat backward, but more downward. Going from one end of this chamber to the other, it would arrive finally in the central canal of the spinal cord.

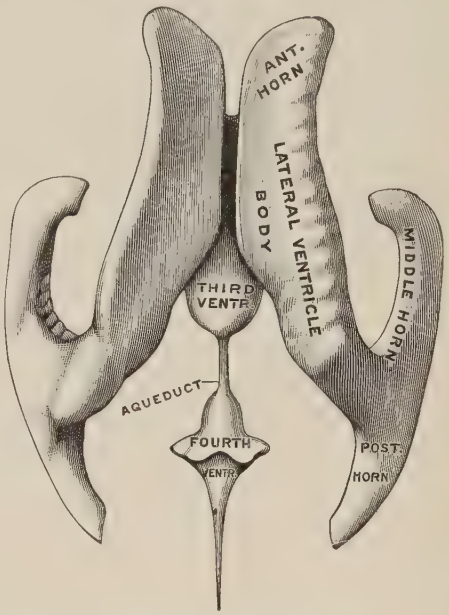

FIG. 587.—Cast of general ventricular cavity—view from above. (Testut.)

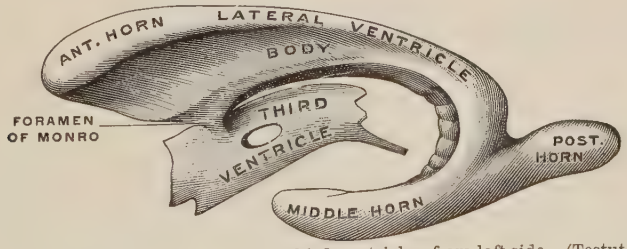

FIG. 588.—Cast of left lateral and third ventricles, from left side. (Testut.)

THE WALLS OF THE CEREBRO-SPINAL AXIS.

Having now obtained an adequate idea of the cavity of the cerebro-spinal axis we proceed to study the *walls* which enclose this space. As has been said, they are composed of nervous tissue, which is lined with endyma and clothed with pia. The mass thus constituted may be conveniently considered in sections. Thus, we will take successively the walls of the lateral ventricles, of the third ventricle, of the aqueduct, of the fourth ventricle, and of the central canal of the

spinal cord (Fig. 589). The several sections of the encephalon in their developed condition are commonly known by names other than those given to the primary vesicles, with a single exception. The walls of each lateral ventricle constitute a *cerebral hemisphere*, the two hemispheres making the *cerebrum*; the region of the third ventricle is known as the *thalamencephalon*, on account of its walls consisting to a very large extent of two great bodies called thalami; the aqueduct is enclosed in a nervous mass, which is often known by its original name, mesencephalon, sometimes as the *isthmus*, from its forming a connecting bond between the parts before and those behind it, and, perhaps most frequently, as the *crura cerebri* ("the legs of the cerebrum"), from the stalk-like appearance of its ventral portion; and the fourth ventricle is surrounded by nervous masses so differentiated from each other that they are not designated by a single collective term, but are referred to as separate organs. Of these the principal are the *cerebellum* ("the little cerebrum" or "little brain"), the *pons* ("the bridge" or "the bridge of Varolius"), and the *medulla oblongata* ("the oblong marrow"), also called by either of its names singly—preferably by the latter, as this gives

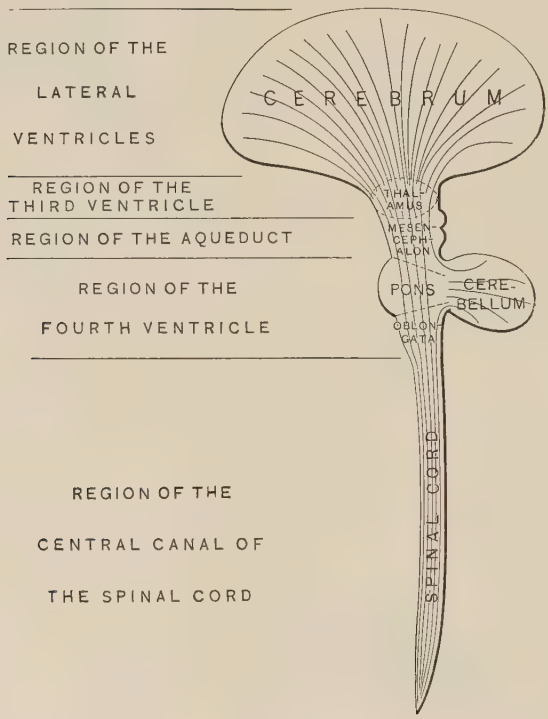

FIG. 589.—Diagram to show the relations of the cavity to the principal divisions of the axis.

no suggestion of the medulla spinalis ("the spinal marrow"), a name formerly much used instead of *spinal cord*, which is the final segment of the cerebro-spinal axis, and surrounds the central canal of the spinal cord.

The relative proportion and disposition of the gray and white nervous matter are very different in the various parts. For example, in the cord the gray occupies a central position, while in the cerebrum the greater part of this kind of material is at the surface. In the encephalon we find also many collections of gray nervous tissue, which seem to casual observation isolated, and independent of the gray at the surface and of the rather regular, continuous, and orderly arranged gray substance of the cord. The white nervous tissue is somewhat more easily understood, as we can trace a continuity in its mass for very considerable distances, indeed, practically from one extremity of the axis to the

other. Beginning our inspection in the cord, we follow the fibres successively into and through the regions of the fourth ventricle, of the aqueduct, of the third ventricle, and last into the region of the lateral ventricles, where we find them ending in the gray matter of the very surface of the cerebrum.

A Diagrammatic Description of the Brain.

The relations of the primary segments of the encephalon in their fully developed state are so complex that a diagrammatic presentation of the subject is a helpful introduction to its fuller study.

The First Vesicle.—As would be expected from the great size and wide expansion of its cavity, the first vesicle attains a volume far in excess of that reached by any other; indeed, so large does it become that its bulk surpasses that of all the others together, and it overlaps them to such an extent as to conceal them completely in the view from above. Imagine it growing as the cavity has been represented to spread out—its central part (the aula) increasing little, the lateral portions much—and suppose that in the median line the wall is relatively very thin, and almost everywhere else very thick. The result is that there is an immense mass on each side, the two separated by a deep fore-and-aft cleft, and held together by bands near the bottom of this dividing fissure. As in all other parts of the encephalon, there is substantially a bilateral symmetry in these structures; that is, the portion on one side is a reversed repetition of that on the opposite side. Seen from above each suggests by its form a half-globe; and, although the resemblance is not observed from other points of view, the name *hemispheres* is given to these cerebral masses. If the encephalon is cut in two exactly in the

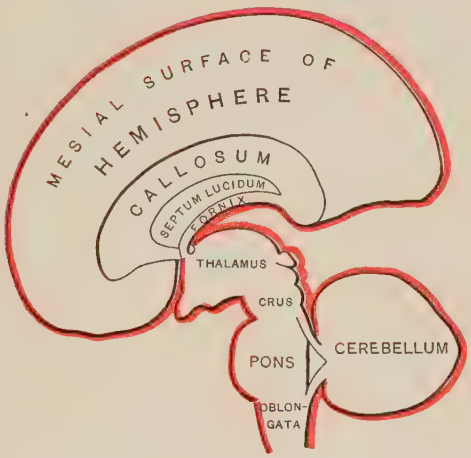

FIG. 590.—Diagram to show the relations of the parts developed from the first vesicle to the parts developed from the second vesicle. The hemisphere is tilted forward. (F. H. G.)

middle line, and an inspection is made of the left surface of the right half, we have such a view of the first and second vesicles as is shown in Fig. 590, only that the diagram, instead of displaying them in contact, as they lie in nature, represents the upper of the two segments as if nearly separated from the lower by a tilting up of its hind end and a corresponding depressing of its front, the pivotal point being the region of the porta (foramen of Monro), represented by a circle at the left of the label "thalamus" and a little above it. The red line indicates pia. Between the porta and the label is the aula (the median portion of the first vesicle), from the front and upper part of which the porta opens into the lateral ventricle. The aula and all above and in front of it is cerebrum, the development of the first vesicle. Observe that the pia is applied to the hemisphere and

is reflected from it to the thalamus, which constitutes the main portion of the wall of the second vesicle. The part marked *callosum* is the cut surface of the great bond of union between the hemispheres. This body reaches far into the substance of the hemisphere, and forms the roof of the lateral ventricle. In the picture all above, before, and behind the callosum is free surface of the hemisphere, not cut by the median incision. A little below the callosum is an arched structure, labelled *fornix*, cut through by the incision. Between callosum above and fornix below is stretched a thin plate, the *septum lucidum*. Going down to the region of the second encephalic vesicle, we find that its cavity has been completely exposed by the median cut, and its lateral wall, marked *thalamus*, displays a free surface; but when we look for the cavity of the first vesicle, we find only the aula and the porta; that is to say, the front and upper part of the third ven-

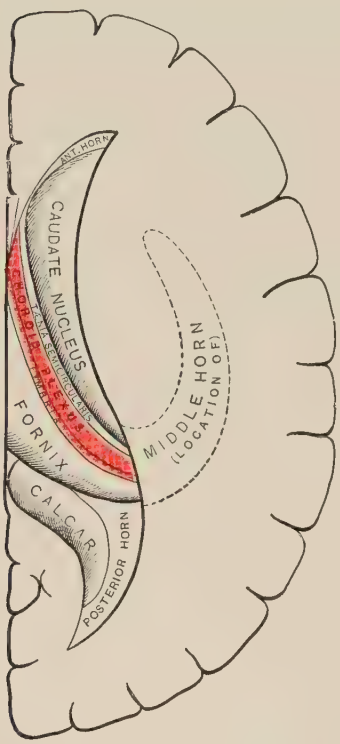

FIG. 591.—Sketch of the right lateral ventricle from above, its roof having been cut away. (F. H. G.)

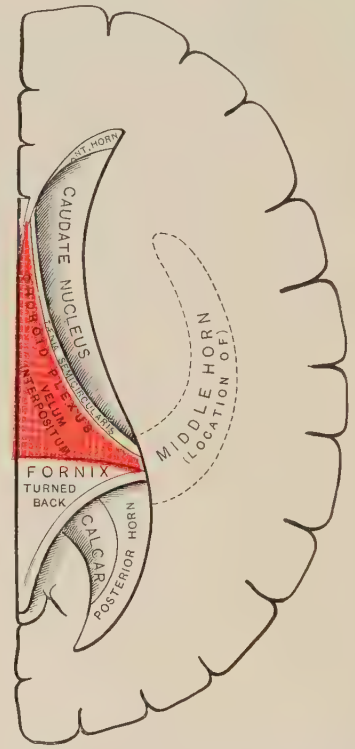

FIG. 592.—Same as Fig. 550, except that the fornix has been folded back, exposing the velum interpositum. (F. H. G.)

tricle, and the hole of communication between the third ventricle and the lateral ventricle, the last named chamber being shut from our sight by the septum lucidum. To get a view of the lateral ventricle our best plan is to slice off the mass of the hemisphere which lies over the callosum, and then to cut through the latter near the median line, removing as much of the structure as is necessary to expose the cavity beneath it. We shall then observe what is shown in Fig. 591. The right lateral ventricle has been unroofed by this removal and its floor is laid bare. This has a very uneven surface from the irregularity of the contour of the structures which form it. The intrusions of substance are due in one place to the thickening of the wall of the cavity, and in another to the infolding of the wall where it is rather thin. At the front part is an illustration of the former, the *caudate nucleus* bulging into the chamber in a region where there is a bulky wall; and at the back part is an example of the latter kind, the *calcar* being a

rounded ridge, which marks the location of a deep impression on the sloping area of the under surface of the hemisphere.

In the floor of the ventricle are seen, in regular order from front to back, the gray *caudate nucleus*, around the fore part of which bends the shallow anterior cornu, while the mesial border of the mass is marked by a white ribbon-like band, the *tænia semicircularis*; next and parallel to the last, a long, purplish body, the *choroid plexus*, composed of clumps of blood-vessels; then a white structure, the *fornix*, whose outer margin is named *fimbria*; and, finally, the *calcar*, which forms the floor and mesial side of the posterior cornu. At the hind end of the fornix begins the middle cornu, which extends far down and forward, below the level of the parts seen by the removal of the callosum. Into it are prolonged the caudate nucleus with its tænia, the choroid plexus, and the fornix with its fimbria. In Fig. 590 the fornix is shown as the undermost of the nervous structures concerned in forming the lateral ventricle in the median region, and its outer surface (which is underneath), like all external surfaces of the encephalon, is covered with pia, the vascular membrane. If we cut away the fornix (as seen in Fig. 591), peeling it off carefully from the pia beneath it, we shall expose the attached surface of this membrane, and find that the object, which we have called choroid plexus, is the fringed and crumpled edge of this part of the pia, which has intruded itself into the lateral ventricle between the free border of the fornix and the free border of the caudate nucleus—that is, between the corpus fimbriatum and the tænia semicircularis (Fig. 592). This intrusion is made possible by the disappearance of the nervous tissue along this line, and thus the pia covering the part and the endyma lining its cavity are brought into contact. The choroid plexus, like all the other parts of the wall of the ventricle, has its investment of endyma.

The Second Vesicle.—The walls of the second encephalic vesicle, enclosing the most of the third ventricle, are strikingly unequal in their development. At the sides they become very thick, forming the masses called the thalami; in front and below the walls are very thin; and at the top the nervous tissue disappears entirely, leaving the serous lining in contact with the vascular covering—the endyma and the pia thus constituting the roof of the cavity.

In Fig. 590 the cerebral hemisphere is pictured as hinged at the region of the porta and canted forward, in order that it may be more easily regarded independently of the second encephalic segment. Now, let us replace the hemisphere in the position which it normally occupies, namely, resting upon the second segment, the thalamencephalon (Fig. 593). The pia underlying the fornix and the pia overlying the thalamus are thus brought together, and in this way a double layer of vascular membrane is made to intervene between the bottom of the first encephalic segment and the top of the second. These layers fuse together and constitute the *velum interpositum* ("the interposed veil").

The first two encephalic segments have more in common than their connection in the region of the porta and the blending of the layers of pia which come between them. There is a continuation into the hemisphere of great columns of nerve-tissue from the thalamencephalon, which receives them from the parts behind and below itself; and these will be described later.

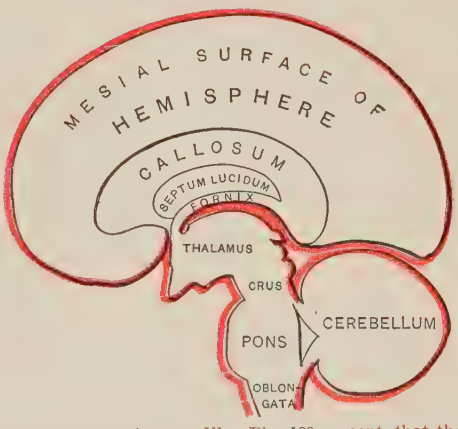

FIG. 593.—Diagram like Fig. 590, except that the hemispheres have been put back in their normal position. (F. H. G.)

The Third Vesicle.—Passing from the thalamencephalon we come to the mesencephalon, the region of the third encephalic vesicle, which contains the aqueduct. Here the walls are everywhere

thickened, and, when viewed on their ventral aspect, look like two strong pillars, the *crura cerebri*; but their dorsal aspect presents four knobs, called *corpora quadrigemina* ("the four-twin bodies").

The Fourth Vesicle.—The ventral wall of the fourth encephalic vesicle is thick, constituting the *pons*; the side walls, the *pedunculi*, are rather thin; and the true dorsal wall, the *valvula*, is very thin. But a large, solid mass, the *cerebellum*, overhangs the rest of the segment, and to casual inspection conveys the idea of an enormous thickening of the dorsal wall.

The Fifth Vesicle.—The fifth encephalic vesicle, the *oblongata*, is the part least altered from the form of the spinal cord, with which it is continuous. It looks as if it were split in the middle behind, and its upper part widely spread open. Stretching across the cavity from one of these spread edges to the other is a layer of endyma, covered by a thin layer of pia, without the intervention of any nerve-tissue, constituting the roof of this segment.

The preceding diagrammatic presentation of the salient points in the structure of the encephalon will serve as a framework on which to build up more detailed information on the subject.

THE PROSENCEPHALON—THE REGION OF THE LATERAL VENTRICLES.

THE CEREBRUM.

The Surface of the Cerebrum.

The surface of each hemisphere of the cerebrum is composed of a layer of gray nervous tissue of variable thickness in different parts. The convex, external surface, the flat mesial surface, the irregular under surface—all present an outer stratum of cellular nerve-material, called the *cortical layer*, because it is a covering, like the bark (*cortex*) of a tree. This cortical gray consists of cells of various sizes and shapes, arranged in rather indistinctly defined layers, which vary in number from four to nine. Between the layers and between the cells of each layer are nerve-fibres, some medullated and some non-medullated, running in different directions, and all supported by neuroglia. In the young fœtus the cortex is smooth and uncreased (Fig. 594); but, as months go by, it becomes

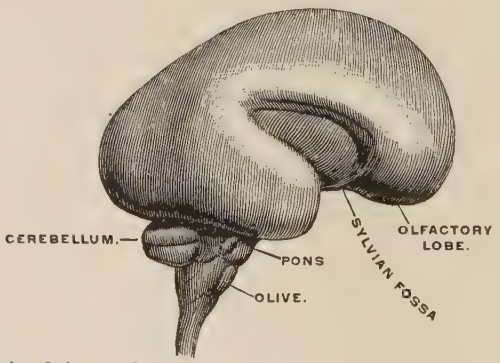

FIG. 594.—Brain of six-months' human embryo, natural size, right side. (Kölliker.)

wrinkled, narrow depressions occurring all over it, and getting deeper and more numerous with its development (Fig. 595). These creases are infoldings of the cortex; and, consequently, the more numerous and the deeper they are the greater is the amount of the peripheral gray substance. They are called *fissures*,

or *sulci*. The fissures are divided into two groups—total and partial. *Total fissures* represent a bending of the entire thickness of the brain-wall. Such a

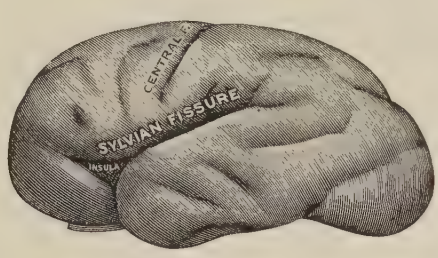

FIG. 595.—Cerebrum of eight-months' human embryo, left side. The insula is nearly covered in. (Testut.)

fissure is collocated with a corresponding elevation in the ventricular cavity. *Partial fissures* are grooves in the surface of the brain, demarcating gyri. To the uncritical eye they seem to be nearly or quite without system in their arrangement, and they give the cerebrum an appearance not inaptly compared to that of the mass of small intestines, which is seen when the abdomen is laid open and the omentum is lifted off. This coiled look has given the parts between the fissures the name of convolutions, or, better, *gyri* (Anglicized into "gyres"). Though at first glance apparently disposed without order, the fissures and gyri have been discovered to be for the most part so constant and regular that they have received names intended to be descriptive of their location or shape. They are similar on the two sides, but not identical, and are subject to considerable variations in different individuals. But before giving further consideration to the gyri and the fissures separating them, it is important to notice a few clefts which make larger divisions.

The Longitudinal Fissure.—The two hemispheres are separated by the great *longitudinal fissure*. This goes through from top to bottom of the cerebrum in front and behind; but for the middle two-fourths or more of its antero-posterior length it is stopped when half-way down by the chief of the bands or commissures which connect the hemispheres, namely, the callosum (corpus callosum). All of the other fissures are found alike in each hemisphere, except the transverse, which is half in one hemisphere and half in the other.

The Sylvian Fissure.—Inspecting the hemisphere from the side or from below, the most pronounced peculiarity of its form is seen to be due to the presence of a cleft, which starts near the centre of the base (at the anterior perforated space), and, going upward and backward, cuts so deeply as to mark off very conspicuously a large mass from the middle portion of the hemisphere at its lowest part. This fissure is the *Sylvian* (*fissura Sylviana*) (Figs. 595, 596, 600). The greatest part of the undivided fissure is plainly seen only on the base of the hemisphere, but its divisions are visible only from the side. A little of the fissure proper shows laterally, but it divides immediately into *anterior* and *posterior limbs*, the former subdividing into two short *branches*, *ascending* and *horizontal*. The posterior limb courses backward and a little upward, ending with a decidedly upward inclination at about two-thirds of the distance from the front to the back of the hemisphere, and half-way between summit and base.

The Central Fissure.—In the middle region of the lateral surface above the Sylvian fissure is the *central fissure* (Rolandic) (Fig. 596), extending in an undulating course from the longitudinal fissure forward and downward almost (or quite) to the Sylvian. It begins behind the half-way point between front and back, and ends anteriorly to this plane, thus obliquely dividing the surface into approximately equal parts.

The Parieto-occipital Fissure.—Far back on the upper margin of the hemi-

sphere, as it slopes toward the base, is seen a notch, which marks the beginning of a fissure of the mesial surface, the *parieto-occipital fissure*, which will be described later.

The Lobes on the External Surface (Fig. 596).—In these three fissures we have the basis for a division of the lateral surface into lobes; and, although the division is rather artificial, and "lobe" is not an ideal name for the segments, it is necessary to have some means of designating the various parts, and this plan is convenient. The lobes visible on this convex surface are the frontal, the parietal, the occipital, and the temporal; but, though bearing the names of certain cranial bones, the limits of the lobes do not coincide with those of the osseous structures nearest which each respectively lies and from which it gets its name. If a line is drawn from the parieto-occipital fissure downward and forward to a point on the lower border beneath the rear end of the Sylvian fissure, usually marked by a notch, the pre-occipital, and another line in prolongation of the nearly horizontal part of the Sylvian fissure is made to touch the first one a little above its middle, the delimitation of the lobes is effected. Behind the parieto-

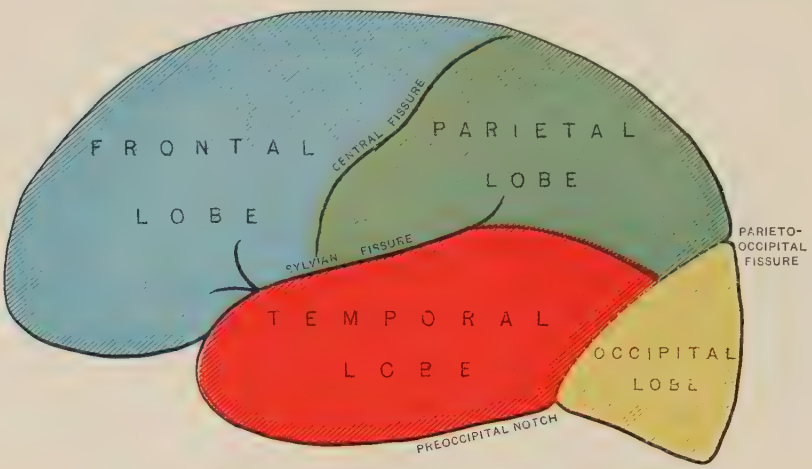

FIG. 596.—The lobes of the convex surface of the hemisphere, left side.

occipital line is the *occipital lobe*; in front of this and beneath the Sylvian fissure and its extension is the *temporal lobe* (temporo-sphenoidal); in front of the central fissure is the *frontal lobe*; and the residue, the area bounded in front by the central fissure, below by the Sylvian, behind by the parieto-occipital and its imaginary prolongation, and above by the longitudinal fissure, is the *parietal lobe*.

The Insula.—If the lower and front part of the parietal lobe and the lower and back part of the frontal lobe are lifted away from the Sylvian fissure, and the adjacent part of the temporal lobe is pressed down, there is brought into view a fifth lobe, which, from its situation, is called the *central lobe*, but is more commonly known as the *insula* ("the island") or the island of Reil (Fig. 597). Until fœtal life is half completed this lobe is distinctly superficial; but then its immediate neighbors increase so rapidly in size as to outstrip the insula in the race of growth—the parietal folds down, the frontal bulges back, the temporal crowds up from below—and among them it gets completely covered in; and in this process the Sylvian fissure is formed, the portion between the frontal and temporal lobes being the main fissure, that between parietal and temporal being the posterior limb, and that within the frontal the anterior limb. Morphologically the insula is the oldest lobe, and it stands, as will soon be shown, in closer relation than any other to the great ganglia at the base of the hemisphere.

The insula is sometimes called *gyri operti* ("the covered gyres"); and the parts of the frontal and parietal lobes which overlap the insula are known as the *operculum* ("the cover").

The Lobes of the Mesial and Tentorial Surfaces.—The *mesial surface* of the hemisphere cannot be seen plainly without dividing the encephalon in the middle line, and removing the hemispheres from each other; and the surface which con-

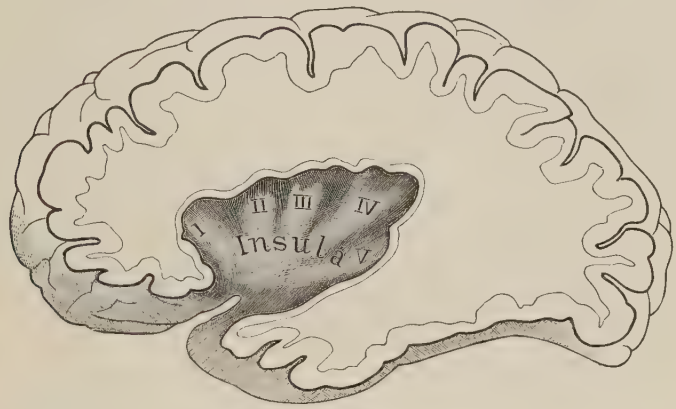

FIG. 597.—The left insula, the overlapping parts of the hemisphere having been removed. The numerals specify the gyri. (Dalton).

tinues the mesial downward (called the *tentorial surface*, on account of its resting in part upon the tentorium) is brought into view from the middle line by the removal of the crus and all below it. This dissection exposes a number of objects huddled together in the centre of the field, of which the largest, highest, and most conspicuous is the callosum, already mentioned as the great bond of union between the hemispheres. This displays a broad, cut surface, which forms a flattened arch from the front to the back of this mid region, and under the arch are gathered many structures, which, being internal, will be passed by until the study of the periphery is completed. When we look directly upon the flat, mesial surface of the hemisphere, the tentorial surface, into which the mesial runs at its lower border, slopes away from us to the lower margin of the convex, external surface, as is shown by Fig. 598. Thus, when viewed from the median line the tentorial surface is a good deal foreshortened.

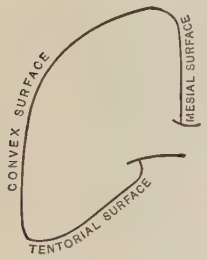

FIG. 598.—Outline of coronal section of hemisphere, showing slope of tentorial surface.

On the mesial surface (Fig. 599) are parts of two fissures already mentioned as appearing on the convex surface: the *central*, the upper end of which notches the sharp border more than half-way back; and the *parieto-occipital*, which, from its small beginning on the convexity of the hemisphere, is continued over the border, and then downward and forward, joining the calcarine at an acute angle. The *calcarine fissure* (from calcar, "a spur") runs from near the rather pointed hind end of the hemisphere upward and forward, and just beyond its middle, at the point where it receives the parieto-occipital, bends downward, and terminates beneath the rear end of the callosum. Encircling the callosum is a fissure, called the *callosal*. Beginning below the front end of the callosum is a fissure, which runs in a curve nearly concentric with that of the callosal and also with that of the margin of the hemisphere, until a point above the hind end of the callosum is reached, at which the fissure turns, and runs upward and backward to the upper border. Its situation gives it the name *calloso-marginal fissure*. Coursing in the general direction of the body of this fissure, between it and the parieto-

occipital, is frequently an irregular, somewhat broken fissure, the *precuneal* or subparietal; and running nearly horizontally in the midst of the sloping tentorial

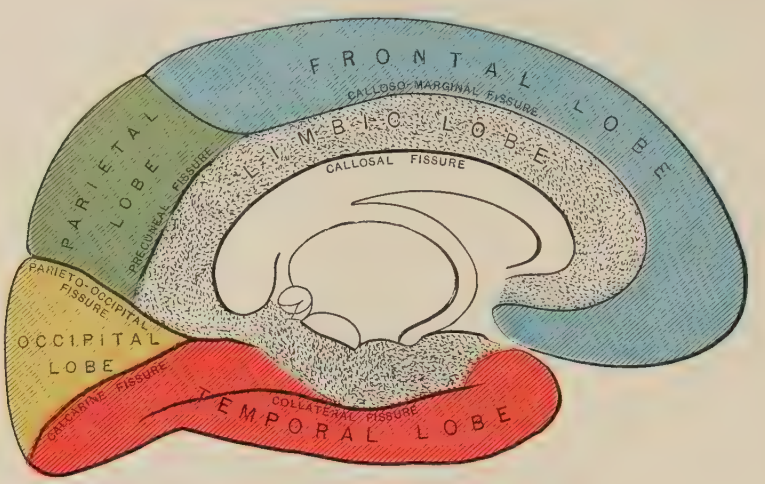

FIG. 599.—The lobes of the mesial and tentorial surfaces of the left hemisphere.

surface is the *collateral fissure*. The area between the calloso-marginal fissure and the upper edge of the hemisphere belongs to the frontal lobe; that bounded by the upturned end of the calloso-marginal fissure, the free border, the parieto-occipital, and the precuneal fissures is a part of the parietal; that between the parieto-occipital and the calcarine fissures is a portion of the occipital; and all below the level of the anterior limb of the calcarine is often assigned to the temporal. But the part of the temporal mass which is anterior to the tip of the calcarine fissure and above the collateral fissure is better associated with the area which is bounded peripherally by the calloso-marginal, precuneal, and calcarine fissures, to which (with several other structures, which need not be mentioned at present) are given the names of *limbic lobe* and *falciform lobe*, the former from its forming a border for the callosum, the latter because the sweep of its curve is suggestive of a sickle.

If we look at the hemisphere from below, we see parts of the temporal, limbic, frontal, and occipital lobes (Fig. 600).

We have now before us the primary superficial divisions of the hemisphere, namely, the insula, the frontal lobe, the parietal lobe, the occipital lobe, the temporal lobe, and the limbic lobe, and are prepared to consider the subdivisions of each of them. These secondary parts are *gyri*, and are separated from each other by fissures.

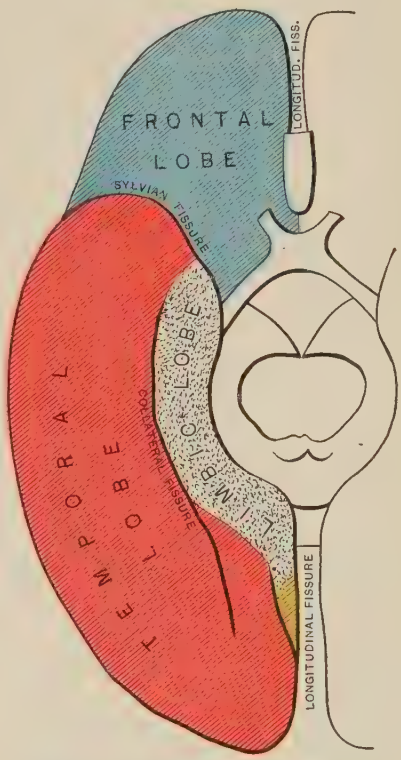

FIG. 600. — The lobes of the right hemisphere, seen from below.

Gyri of the Insula.—The *insula* or central lobe has five gyri, which radiate from the narrow lower part, like the folds of a fan from its handle (Fig. 597). They are separated from each other by simple fissures,

and the lobe is margined at the sides and top by the *circular fissure* (fissura limitans insulæ).

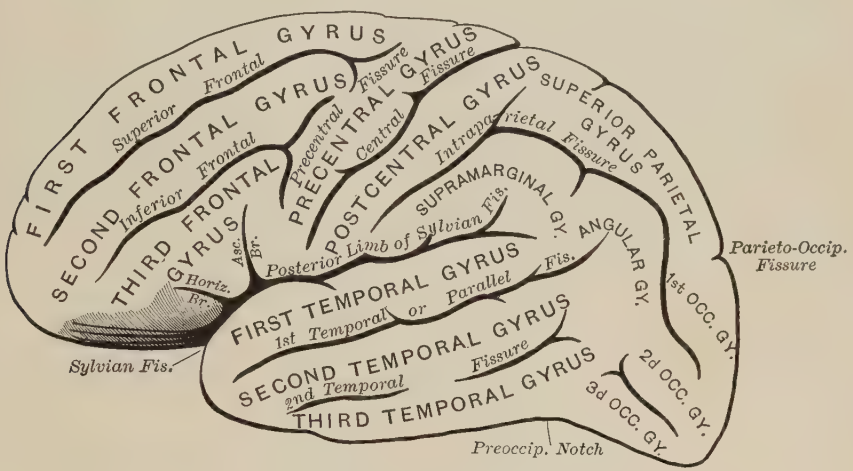

FIG. 601.—The gyri and fissures of the external lobes of the left hemisphere.

Frontal Gyri (Figs. 601–604).—On the convex surface of the frontal lobe are three *fissures*, two of which, the *superior* and *inferior frontal*, have a general fore-

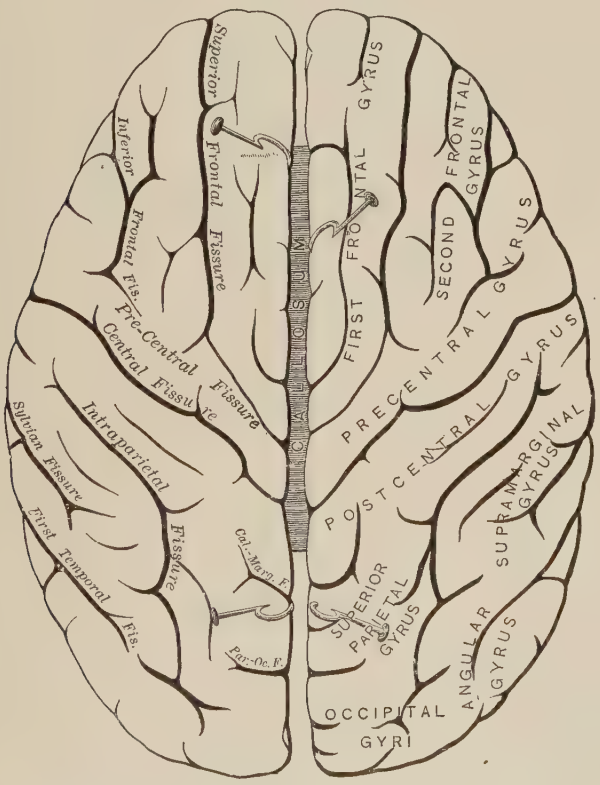

FIG. 602.—The hemispheres viewed from above. The fissures are labelled on the left side, the gyri on the right.

and-aft direction, and the third, the *precentral* (commonly broken), is substantially parallel with the central fissure. By these fissures the lobe is divided into four

gyri: the *first* (superior) *frontal*, between the longitudinal fissure and the superior frontal; the *second* (middle) *frontal*, between the superior and inferior frontal fissures; the *third* (inferior) *frontal*, beneath the inferior frontal fissure, capping the anterior limb of the Sylvian fissure; and the *precentral* (anterior central, ascending frontal) between the precentral and central fissures.

On the under surface the frontal lobe has two principal fissures. The first runs parallel with the great longitudinal and close to it, and is called the *olfactory fissure* from its giving lodgement to the olfactory nerve and its bulb. The other, the *supra-orbital fissure*, is very irregular, generally starting near the Sylvian fissure, coursing forward and then outward, and sending offshoots in various directions. The narrow gyrus between the longitudinal and the olfactory fissures is a continuation of the *first frontal gyrus* of the convex surface, the gyrus between

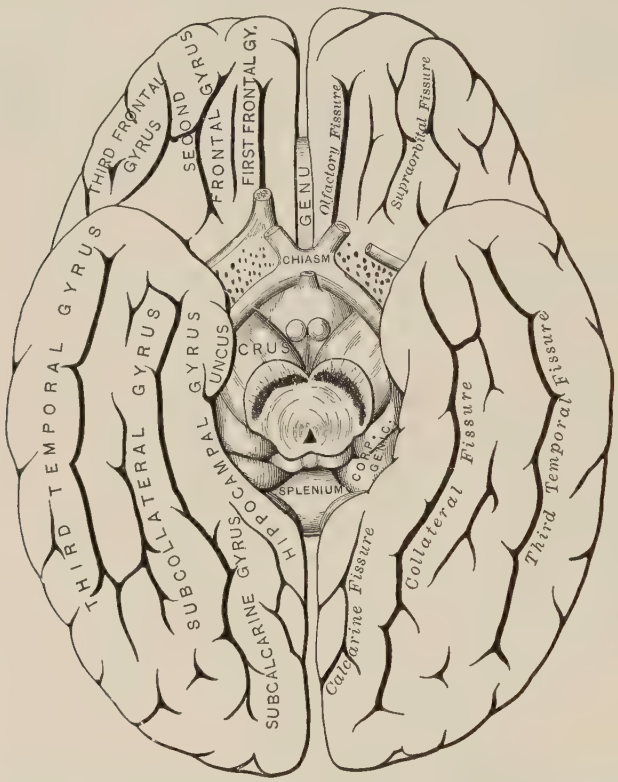

FIG. 603.—The hemispheres viewed from below. The gyri of the right hemisphere are labelled, the fissures of the left.

this and the supra-orbital fissure is continuous with the *second frontal* of the convexity, and the residue of the surface is continuous with the *third frontal*.

On the mesial surface the gyrus which begins under the front end of the callosum, and is bounded at first above, then behind, and then below by the calloso-marginal fissure, is continuous with the first frontal over the edge of the great longitudinal fissure. It is called the *marginal gyrus* from its situation. It really overlaps by a little the parietal region of the convex surface, and the central fissure appears as a notch in its hindmost part. A vertical fissure marks off a squarish area in this region, called the *paracentral gyrus*, because it is continuous with the gyri before and behind the central fissure of the convexity.

Parietal Gyri (Figs. 601–604).—The parietal lobe does not appear on the under surface. On the outer surface is the *intraparietal fissure*, which starts near the Sylvian, passes up a short distance, and then swings back and runs almost

parallel with the longitudinal. As has already been seen, the upturned end of the Sylvian fissure is within the parietal lobe. The *gyri* are the *post-central* (posterior central, ascending parietal) just behind the central fissure; the *superior parietal*, above the intraparietal fissure; the *supra-marginal*, above the hind part of the Sylvian fissure and arching over its end; and the *angular*, which occupies the remainder of the area, and is at the lower, rear corner of the lobe.

Continuous with the lateral surface over the edge of the longitudinal fissure is the mesial surface of the parietal lobe; but it has less width than the external surface, inasmuch as the calloso-marginal fissure does not end coincidently with the central, but a little to its rear, and the difference makes an addition to the frontal lobe by subtraction from the expected domain of the parietal. The mesial parietal gyri make a four-sided area, called the *precuneus*, from its relation to the wedge-shaped occipital gyrus adjoining, and "quadrate lobule" from its squarish shape.

Occipital Gyri (Figs. 601–604).—The convex area of the occipital lobe is conventionally divided into *three gyri* by two fissures; but these are very inconstant and irregular, and the typical arrangement is apparently not yet discovered—

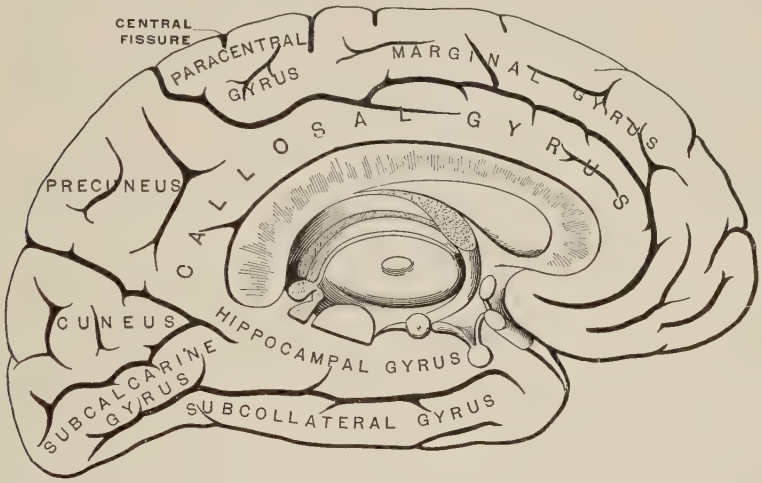

FIG. 604.—The mesial and tentorial surfaces of the left hemisphere, showing the gyri. The fissures have been named in Fig. 599.

certainly it is not agreed upon by the anatomists of the largest observation. The triangular form of the mesial occipital surface has led to its being named *cuneus* ("wedge"). It is continuous with the convex surface over the edge of the longitudinal fissure.

Temporal Gyri (Figs. 601, 603, 604).—The temporal (temporo-sphenoidal) lobe is marked by three fissures, which have a general fore-and-aft direction, two of them appearing on the lateral surface, and being called respectively the first or superior temporal or *parallel fissure* (the latter name from its relation to the posterior limb of the Sylvian fissure) and the *second* or inferior *temporal* fissure. The *third temporal fissure* is largely on the line between the lateral and under surfaces. The front half of the collateral fissure separates the temporal from the limbic lobe, and its rear half lies in the hind part of the temporal. The temporal *gyri* are the *first* (superior), the *second* (middle), and the *third* (inferior) on the outer surface, and, on the base or tentorial surface, the *subcollateral*, which is beneath the collateral fissure, and the *subcalcarine*, which lies between the calcarine fissure and the rear of the collateral.

Limbic Gyri (Figs. 603, 604).—The limbic lobe consists primarily of the *callosal gyrus* (gyrus fornicatus, "arched," gyrus cinguli, "of the girdle"), which arches over the callosum, and the continuation of this which courses forward on

top of the temporal lobe, and is known as the *hippocampal*, or uncinate, *gyrus*. The first name of the latter gyrus comes from its relation to a structure which is seen in the middle horn of the lateral ventricle; the second refers to its hook-like distal end. But, in addition, there are included in this lobe other parts, dissimilar in appearance and errant from the structural character, which we associate with the idea of a lobe of the brain. They are the lateral half of the septum lucidum, the dentate gyrus, the fornix, the striæ longitudinales of the callosum, and the peduncles of the callosum, and have been grouped with the great gyri just named on grounds of morphology and embryology, rather than from considerations based upon adult structure.

In the limbic lobe are the *callosal fissure*, previously described, and the *hippocampal fissure*, which marks the upper boundary of the hippocampal gyrus,

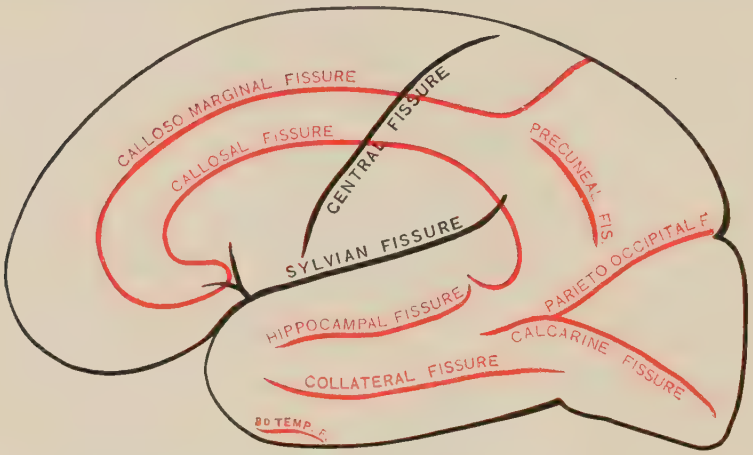

FIG. 605.—Diagram to show position which fissures of mesial and tentorial surfaces would occupy if projected in a horizontal plane sidewise to the outer surface. (F. H. G.)

extending from the back of the splenium of the callosum into the embrace of the hook of the gyrus. Seemingly lodged in the hippocampal fissure is a long, slender roll of gray substance, notched upon its exposed surface, and called the *dentate gyrus* (fascia dentata) (Figs. 609, 623). It begins behind the splenium, receiving here the striæ longitudinales of the callosum, runs to the end of the hippocampal fissure, and terminates by bending up over the uncus. Above it lies the fimbria, and between the two is a shallow cleft, called the *fimbrio-dentate fissure*.

Relation of the Principal Lobes to the Parts of the Lateral Ventricle.

The cavity of the *frontal* lobe is the anterior horn; that of the *parietal* lobe is the body; that of the *occipital* lobe is the posterior horn; and that of the *temporal* lobe is the middle horn (Fig. 606).

Situation of the Lobes in the Cranium.

The frontal rests upon the orbital plates of the frontal bone; the temporal occupies the middle fossa of the base of the skull; the occipital is supported upon the tentorium, being thus separated from the cerebellum, which fills the posterior fossa; and the parietal is held up by the subjacent cerebral structures, and is covered by the sides and vertex of the skull.

The Callosum.

Almost every part of the cortex of one hemisphere is connected with the corresponding part of the other hemisphere by nerve-fibres. In and near the median

line of the cerebrum all of these fibres are compressed vertically and, to a less degree, antero-posteriorly into a solid mass. Consequently the fibres seem to radiate from each side of this condensed body—going out, up, down, forward,



FIG. 606.—Diagram to show planes of lateral ventricle projected upon the outer surface of the hemisphere, as if the ventricle were filled with opaque pigment, and were seen through transparent wall of hemisphere. (F. H. G.)

backward—to terminate in the gray matter at the periphery of the hemisphere (Figs. 607, 608). The mass (with a slight addition, presently to be described) is the *corpus callosum* ("the hard body"), called, also, merely *callosum*. The middle of it can be seen by drawing the upper portions of the hemispheres apart, so as to widen the great longitudinal fissure, and looking directly downward into this enlarged cleft

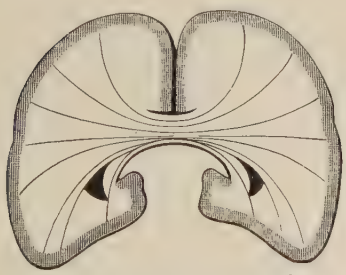

FIG. 607.—Diagram of coronal section of cerebrum to show course of fibres of callosum. (Testut.)

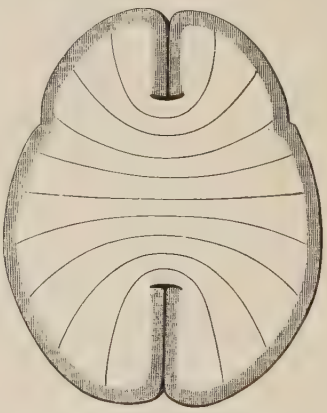

FIG. 608.—Diagram of horizontal section of cerebrum to show course of fibres of callosum. (Testut.)

(Fig. 602). It presents a free surface on top, in front, and behind; but its shape and size are not appreciated until sections of the cerebrum are made in various directions. A vertical median division of the cerebrum shows a cut surface of the callosum, which reveals its form and extent from before backward (Fig. 609). It is seen to be a long, thick, irregularly flattened arch. Its front end is curled back underneath, and is called the *genu* ("knee"). This thins out rapidly to an edge, the *rostrum* ("beak"), which is connected with the front part of the wall of the third ventricle by a delicate plate, the *basal white commissure*, or *copula*. The hind end, also, is rounded, its lower part being folded sharply forward, and is named the *splenium* ("bandage"). The portion between the genu and splenium is the *body*. If the cerebral tissues which overlie the callosum at the sides are cut away, it is found to be depressed along the middle line, and to

rise at the sides into the substance of the cerebrum (Fig. 610). The part of the

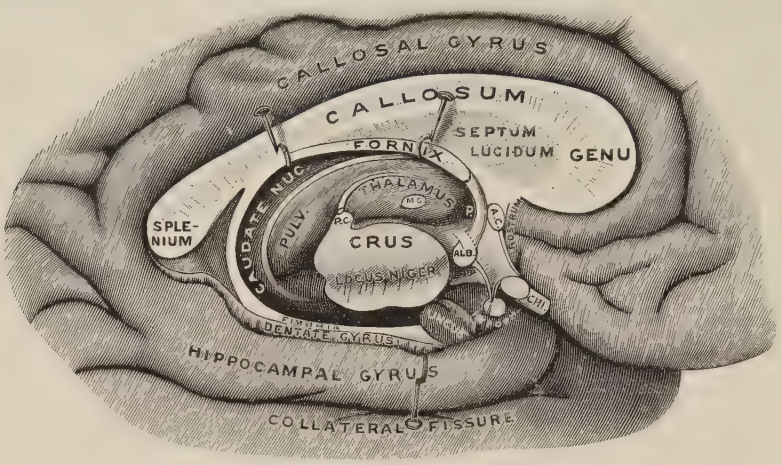

FIG. 609.—Parts of mesial and tentorial surfaces of left hemisphere, showing callosum in sagittal section with many of its relations. A.C., anterior commissure; ALB., corpus albicans; CHI., chiasma; HYPOPH., hypophysis; M.C., middle commissure; P., porta; P.C., posterior commissure; PULV., pulvinar. (Modified from Testut.)

callosum which curves forward on each side from the genu into the frontal lobe is called the *forceps anterior* or *minor*; and that which projects backward in a

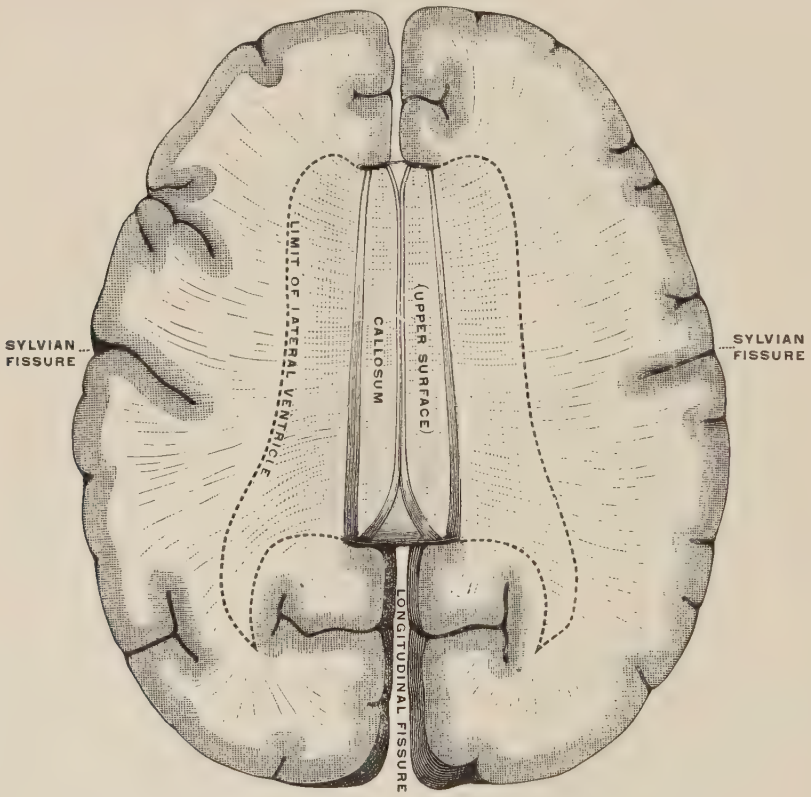

FIG. 610.—Upper surface of callosum, the overlying parts cut away. (Testut.)

corresponding manner from each side of the splenium into the occipital lobe is known as the *forceps posterior* or *major*. Between the two forceps of each side is a plate, which extends laterally into the temporal lobe, and is named the *tapetum* ("mat").

On the upper free surface of the callosum some small bundles of fibres run lengthwise, and from this fact are called *striæ longitudinales* ("longitudinal stripes"). They are in two sets on each side: a median, which lies close to the central depression; and a lateral, which is lodged in the callosal fissure, and is named *tenia tecta* ("the concealed band"), from its being covered up by the callosal gyrus. These bundles diverge in front along the inner boundary of the anterior perforated spaces, constituting the *peduncles of the callosum*, and are lost in the beginning of the Sylvian fissures. Behind they are traced into the back part of the hippocampal gyri.

There is also upon the dorsal surface of the callosum a thin lamina of gray nervous tissue, often very indistinct, called the *indusium* ("something put on"). It is a vestigial layer of cerebral cortex.

The fore-and-aft median *measurement* of the callosum is about five inches; its depth behind is nearly an inch, in front a little less.

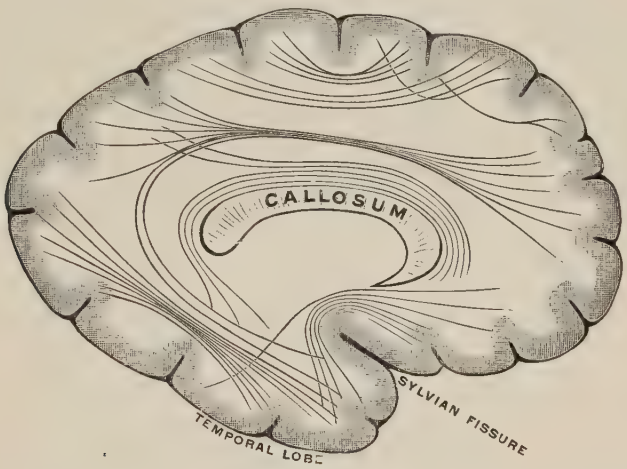

FIG. 611.—Diagram showing association-fibres of the hemisphere. (Testut.)

The callosum forms the roof of the lateral ventricles, the tapetum covering in the posterior and middle horns.

As the fibres of the callosum radiate to the cortex of the hemisphere, they interlace with those of the great columns ascending from the lower levels of the encephalon, and the two sets together constitute the chief bulk of the white substance of the cerebrum. But there are also unnumbered bundles of fibres which connect near or remote gyri, as shown in Fig. 611. They are called *association* or *intrahemispheric fibres.*

The Fornix (Figs. 612, 609, 613).

In the median section of the encephalon there is seen below the callosum and attached to the back part of its lower surface a white body, which curves forward and downward, then downward, and then downward and backward to the under surface of the brain, where it seems to double upon itself in a tight loop, and then to course upward, backward, and a little outward to the thalamus, in which it is lost. This is a part of the *fornix* ("arch"), the remainder requiring another dissection for its exhibition. The callosum and all the structures above it having been removed, we can look down upon the floor of the lateral ventricles, and thus obtain a view of the upper surface of the fornix. It is now perceived to be bilaterally symmetrical. A little of the anterior, descending part is seen in this view, and just behind this the two halves are joined together for a short distance. Traced backward, however, the bands diverge, swing off to the sides, and disappear at the upper ends of the middle horns of the ventricles. Cutting away the roof of these cornua, we find the bands following the curve of these cavities, and

partly spreading out over the hippocampus, partly continued on the inner wall of the horn. Between those parts of the diverging bands which lie in the bodies of the ventricles is stretched a thin layer of fibres. The part of the fornix which

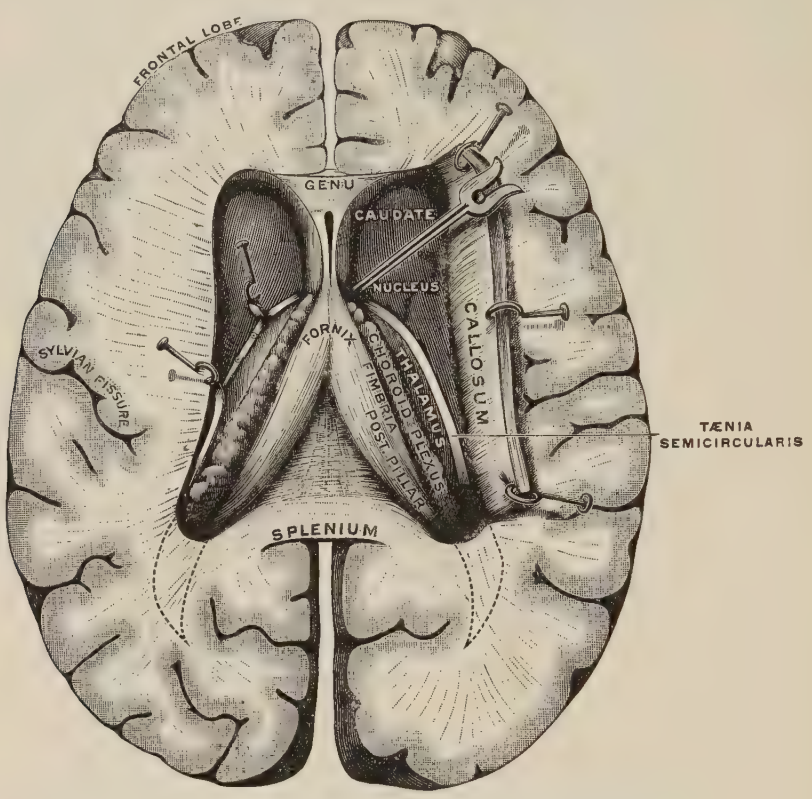

FIG. 612.—Floor of the lateral ventricles. On the left side the vein of the corpus striatum is lifted up. The director is in the right porta. Dotted outlines indicate the position of the posterior cornua. (Testut.)

results from the direct union of the two lateral bundles is its *body*; the portion in front of the body is the *anterior pillars*; the diverging bands behind the body are the *posterior pillars*; the little triangular sheet connecting the posterior pillars is

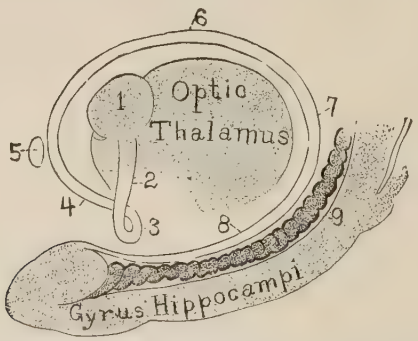

FIG. 613.—Diagram of thalamus, fornix, and hippocampal gyrus of right side, seen from middle line. *1*, anterior tubercle of thalamus; *2*, bundle of Vicq d'Azyr; *3*, corpus albicans; *4*, anterior pillar of fornix; *5*, anterior commissure; *6*, body of fornix; *7*, posterior pillar of fornix; 8, fimbria; *9*, dentate gyrus. (Dalton.)

the *lyra*; the outer free edge of the body and posterior pillar is the *fimbria*, or corpus fimbriatum ("fringed body"); the little knobs produced by the abrupt reversal of direction of the anterior pillars at the base of the brain are the *corpora albicantia* ("whitish bodies"), otherwise called corpora mammillaria ("teat-

like bodies"). The upward-passing cord from the corpus albicans of each side to the corresponding thalamus is known as the *bundle of Vicq-d'Azyr*.

Thus it appears that the fornix is a fore-and-aft commissure, pursuing a circuitous course from the base of the brain in the region of the thalami to the descending horns of the lateral ventricles. Each lateral half of the fornix is principally devoted to the association of the parts on its own side; but each also has, through the lyra, a connection with the corresponding organs on the opposite side.

The Anterior Commissure (Fig. 614).

Directly in front of the anterior pillars of the fornix a rope-like bundle of nerve-fibres runs across from the front part of one temporal lobe to the corresponding part upon the opposite side. It describes in its course a large curve with its

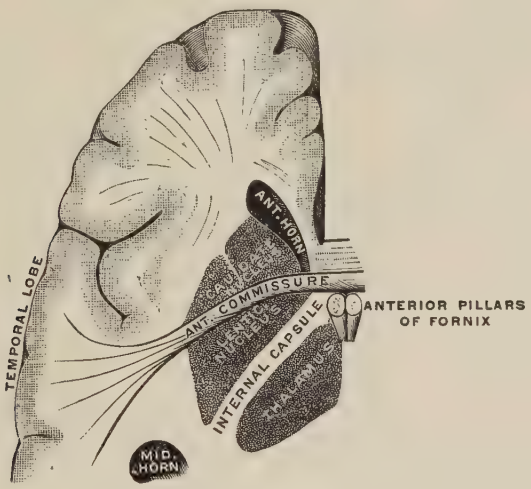

FIG. 614.—Anterior commissure, left half, viewed from above. (Testut.)

convexity forward and a little upward. It passes through the lenticular nuclei, and finally spreads out in the temporal lobes. This is the anterior commissure. It contains some fibres which connect the olfactory tracts of the opposite sides.

The Septum Lucidum.

Occupying the space between the under surface of the callosum and the upper surface of the fornix is a structure, called the *septum lucidum* ("the clear partition") (Fig. 609). It forms the dividing wall between the lateral ventricles. It consists of two layers of nervous tissue, enclosing a small, perfectly closed cavity, a mere crevice, which has no communication with any of the chambers of the encephalon. This hollow space is formed by a process of vacuolation, which means substantially that the middle part of the single thick plate, of which the septum originally consisted, was withdrawn by gradual absorption, leaving in its stead a chink, which is called *pseudocele* ("false cavity"), as it has no claim to be considered a part of the general ventricular cavity (Fig. 618). For the same reason the name, "fifth ventricle," often applied to it, should be discarded, as misleading. This space is occupied by a little serous fluid. The wall next to the cavity is gray, but is white on the outside—that is, next to the lateral ventricle.

The Ganglia of the Hemisphere.

Embedded in the substance of the hemisphere are several masses of gray matter, which seem upon casual inspection to be detached collections, quite independent of the cortex. On careful examination, however, they are found to be con-

tinuous with the superficial gray substance, and even with each other. They are the caudate nucleus, lenticular nucleus, claustrum, and amygdaloid nucleus, or amygdala (Fig. 615).

The caudate nucleus and the lenticular nucleus have commonly been described

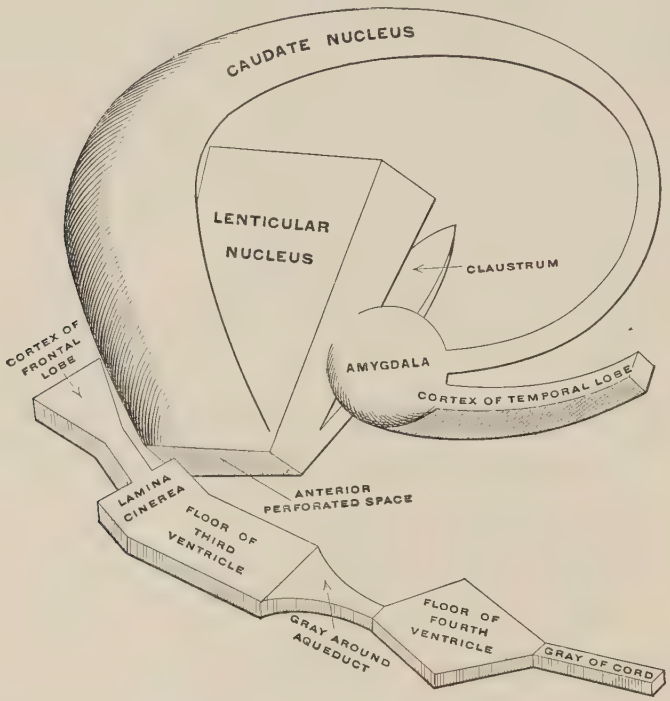

FIG. 615.—Diagram to show the continuity of the gray of the basal ganglia of the cerebral hemispheres, the cortex, and the lower segments of the cerebro-spinal axis. (F. H. G.)

as parts of a single body, called *corpus striatum* ("striped body"), on account of the peculiar, striped appearance of the surfaces resulting from its section; but description is facilitated by treating them as independent structures. The *caudate*

FIG. 616.—Right lateral ventricle opened from its mesial side. *A*, amygdala. *C*, caudate nucleus. *S*, surcingle. *V*, cavity of ventricle. 1, parieto-occipital fissure. 2, calcarine fissure. (Dalton.)

nucleus presents a free surface in the floor of the lateral ventricle, and hence is sometimes spoken of as the intraventricular portion of the corpus striatum; the *lenticular nucleus* does not appear at all in the ventricle, and, consequently, is

occasionally referred to as the extraventricular portion of the corpus striatum. The *claustrum* is a plate of gray substance, embedded between the lenticular nucleus and the insula. The *amygdaloid nucleus* is a collection of gray matter near the apex of the temporal lobe.

The Caudate Nucleus.

The caudate ("tailed") nucleus protrudes into the cavity of the lateral ventricle at the fore part of the floor, the anterior horn curving forward and outward around its most prominent portion (Fig. 617). The front end is rounded, and faces upward, forward, and inward. From this large beginning the nucleus diminishes in size as it is traced backward, and hence the most conspicuous part of it is pear-shaped. But the stem of the pear—the tail or cauda, which gives its name to

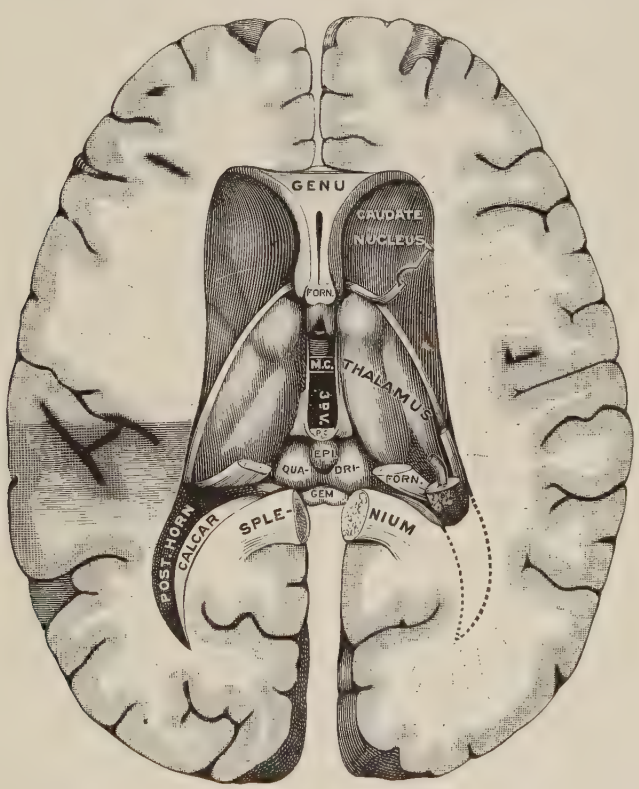

FIG. 617.—Lateral and third ventricles from above. The fornix and velum interpositum have been removed. EPI., epiphysis. M. C., middle commissure. P. C., posterior commissure. (Testut.)

the nucleus—stretches backward and outward as a slender prolongation through the body of the ventricle to the rear end, and thence in a sweeping curve into the middle horn and even to its extremity, clinging to the roof of the cornu (Fig. 616). It thus describes almost a circle, the tip of it reaching a point nearly underneath the blunt beginning. As it embraces in its loop a considerable mass of brain-tissue, it has been named the *surcingle*. It is not of regular outline, but is alternately and unevenly constricted and enlarged (Fig. 619). The caudate nucleus ends in the amygdala at the front end of the temporal lobe.

Along the inner border of the caudate nucleus is a band of fibres, which may fairly be regarded as its proper edge. It is called the *tænia semicircularis* ("the half-circle ribbon") (Figs. 617, 591). It accompanies the tail of the nucleus in the roof of the middle horn even to the amygdala. In the body of the ventricle it is covered by the vein of the corpus striatum.

The Lenticular Nucleus.

In order to obtain an adequate view of the lenticular ("lens-like") nucleus, it is necessary to make horizontal and vertical sections through that part of the substance of the hemisphere in which it is located. By such means we learn that this gray mass lies at the outer side of the caudate nucleus, but is for the most part separated from it by a thick plate of white nervous tissue, the *internal capsule*. Its shape is that of an irregular, three-sided pyramid (Figs. 618, 619). It is divided into three unequal portions by two layers of white matter, the *internal* and *external medullary laminæ*. The outer portion is the largest, is of a deep, red hue, is streaked at its inner part with nearly horizontal, white lines, and is called the *putamen* ("husk"). The other portions are yellowish-gray, and together constitute the *globus pallidus* ("the pale sphere").

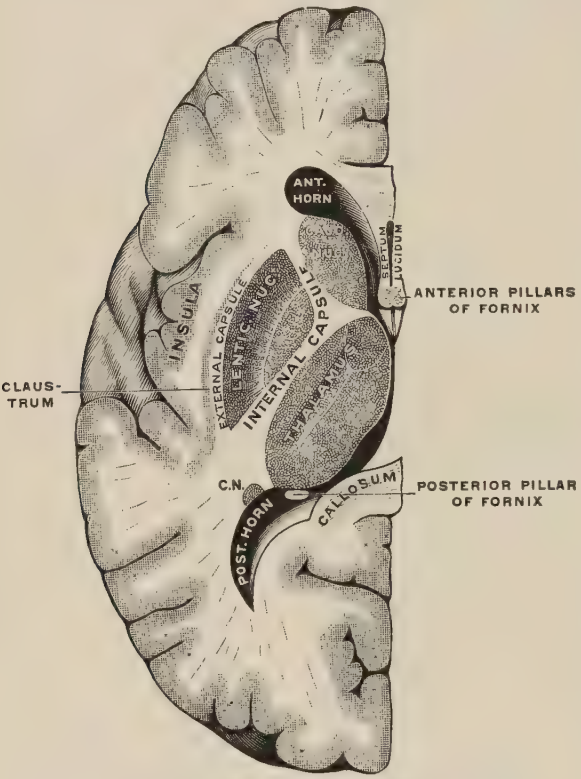

FIG. 618.—Horizontal section of left hemisphere through the basal ganglia, viewed from above. C. N., caudate nucleus. (Testut.)

The lenticular nucleus is not entirely embedded in the brain substance: a portion of it is at the surface of the base of the cerebrum, at the outer side of the chiasma and behind the roots of the olfactory lobe, in the *anterior perforated space*. The internal capsule does not wholly separate the lenticular and caudate nuclei, the two masses being united below and in front of it, and being further connected by thin cords of gray matter, which cross the capsule. The claustrum is fused with the lenticular nucleus at the anterior perforated space; the amygdala is united with its hind and lower part; and through the amygdala the nucleus is continuous with the cortex of the hemisphere. From these facts concerning the association of the gray masses of the hemisphere, we see that there is good reason for regarding them as thickenings of the peripheral gray substance.

The **Anterior Perforated Space** is situated at the base of the brain at the point from which the Sylvian fissure starts. The optic tract lies obliquely behind it, mesially it is continuous with the lamina cinerea, in front is the orbital surface of the frontal lobe. It is marked by numerous holes, through which pass blood-vessels to the lenticular nucleus. Fig. 603 shows it on each side of the chiasm.

The Claustrum (Fig. 618).

Just outside of the lenticular nucleus is a thick stratum of white tissue, called the external capsule, which will be described later. Between this external capsule and the white substance which furnishes the backing of the gray of the insula is a thin lamina of gray tissue, called the *claustrum* ("barrier"). Its surfaces are directed respectively toward the insula and the lenticular nucleus. In horizontal or vertical section its outline is undulating. The adherent tissues being

dissected away, it is seen to be of triangular shape, with its apex above; and its base, which is its thickest part, is found to reach to the surface of the brain at the anterior perforated space, where it is united to the lenticular nucleus.

FIG. 619.—Longitudinal section through the entire right caudate nucleus, viewed from mid line. The plane of the section is not perpendicular, but has followed the surcingle outward. C, caudate nucleus. CC, front part of callosum. F, frontal lobe. O, occipital lobe. T, temporal lobe. S, surcingle. 1, 2, inner and middle zones of lenticular nucleus. 3, internal capsule. Observe the continuity of the gray substance. (Dalton.)

The *olfactory lobes*, the *optic tracts*, and the *chiasma* will be considered in connection with the cranial nerves.

The Amygdaloid Nucleus (Figs. 622, 627, 616).

This ganglion, otherwise called *amygdala*, is a mass at the tip of the temporal lobe, due to a thickening of the cortex of this region. It is of sufficient size to cause a protrusion into the roof of the middle horn of the lateral ventricle, at whose distal end it receives the extremity of the surcingle. It is continuous in front and above with the lenticular nucleus.

The Velum Interpositum.

Although it is a part of the parietes of the third ventricle, the *velum interpositum* ("interposed veil"), also called *diatela*, and *tela choroidea superior* ("upper leathery web"),[1] requires description here because its fringed edges, the *choroid plexuses*, appear in the floor of the lateral ventricles, and cannot be understood except in connection with the velum. It will be recalled (Figs. 590, 593) that the pia of the under side of the developing first brain-vesicle is brought by the backward and downward growth of that segment directly in contact with the pia of the upper surface of the second brain-vesicle. The combination of the two layers of pia constitutes the velum interpositum—the veil placed between the prosencephalon and the thalamencephalon. It lies just beneath the part of the fornix which appears in the bodies of the lateral ventricles, and just above the cavity of the third ventricle, resting at the sides upon the upper surfaces of the thalami. In the floor of each lateral ventricle, between the fimbria, which makes the edge of the fornix, and the tænia semicircularis, which margins the caudate nucleus, is a narrow strip of the parietes of the first encephalic vesicle in which there is an entire absence of nervous tissue, and, consequently, the wall of the vesicle in this area consists merely of endyma and pia. The fimbria and tænia are prolonged from the body of the lateral ventricle into its middle horn; and the wall between them here is like that between them in the body of the ventricle—merely pia and endyma in close contact, the nervous tissue which once existed in this narrow area having

[1] The name *tela* ("web") is applied to a membrane resulting from the apposition of the endyma and the pia, which occurs when the normally intervening layer of nervous tissue disappears.

disappeared. The highly vascular pia, wherever it covers nervous tissue, sends branches of its vessels into the surface layers of this tissue; but along this line, which extends from the porta (foramen of Monro) to the tip of the middle horn, the pia lies against no such resistant material, being applied closely to the delicate endyma. Its branches, becoming dilated and prolonged, push the filmy serous membrane inward, so that an irregular, clumpy mass of vessels, covered everywhere with endyma, encroaches upon the space originally devoted to the ventricular cavity. This vascular structure is called the *choroid plexus* ("leather-like network") (Fig. 612). It is convenient to speak of the "intrusion" of the choroid plexus into the ventricular cavity; but as the cavity is limited by the endyma, and no breach is made in this membrane, the expression is not strictly correct, the fact being that the wall of the cavity is bent inward, and the contained space is by so much diminished. All of the choroid plexuses are explained in the same way. It is supposed that the choroid plexuses are of service in the production of the cerebro-spinal fluid. It is to be noted that, while the choroid plexus of the body of the lateral ventricle is derived from the velum, the choroid plexus of the middle horn is derived from the pia which clothes the limbic lobe.

FIG. 620.—Diagram of transverse section of axis where a portion of the nervous wall has disappeared, allowing pia and endyma to come together.

The diagram (Fig. 621) will aid one in understanding this. In it the velum is shown as a triangle marked with transverse red lines; the choroid plexuses are in solid red; the tæniæ semicirculares are in blue; and the outline of the fornix and fimbriæ is indicated by broken lines. We are looking down upon these objects. On the right of the diagram the tænia and fimbria, with the intervening choroid plexus, are represented as straightened out, as if the temporal lobe and



FIG. 621.—Diagram to show relations of tænia, fimbria, and choroid plexus in body of lateral ventricle and in middle horn. On the right side the parts are straightened out, on the left they are curved in their natural shape. (F. H. G.)

the adjacent part of the limbic lobe had been stretched backward. On the left the parts are shown with the curve naturally described by the middle horn. In making the curve the parallelism between the two nervous bands is substantially

maintained, but the tænia gets above the fimbria. The middle horn is much nearer to the mesial than to the outer surface of the temporal lobe, so near, in fact, that the fimbria is covered with pia. In the region of the velum the choroid plexus is formed by the pia which makes the velum; beyond the hind edge of the velum the plexus is made from the pia immediately on the surface of the brain.

The crevice through which the invagination of the pia is effected is called the *transverse fissure*, or the *choroid fissure*; and it extends from the porta (foramen of Monro) nearly to the distal end of the middle horn on each side.

In **the posterior horn** of the lateral ventricle (Fig. 622) the inner wall, which slopes outward toward the floor, presents a prominent protrusion, caused by the pushing in of the entire wall of the cavity at this point in correspondence with the depression upon the tentorial surface of the hemisphere, which we know as

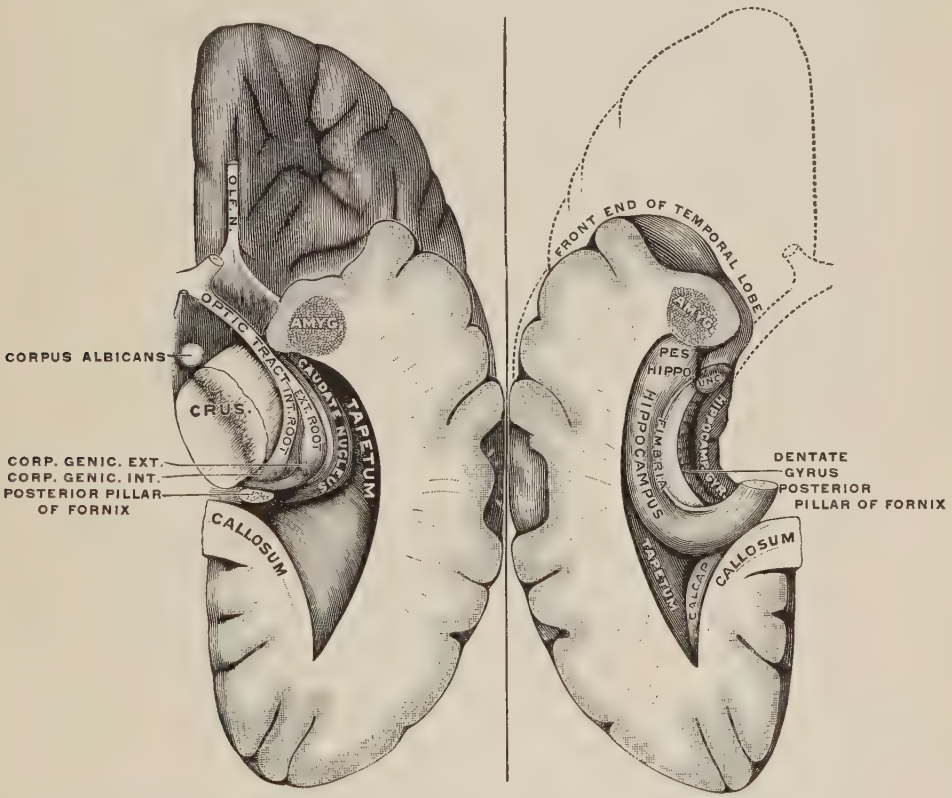

FIG. 622.—Horizontal section of left hemisphere, opening the middle horn of the lateral ventricle. The upper segment, containing the roof of the horn, has been turned off to the left. (Testut.)

the calcarine fissure. The elevation is well called the *calcar* ("spur"), although a less suggestive and helpful name, hippocampus minor ("the smaller sea-horse") is more commonly used. Just above the calcar is another prominence, the *bulb*, produced by the posterior forceps of the callosum. The roof of this cornu, as stated previously, is furnished by the tapetum of the callosum. Finally, the floor is triangular, has a convex surface, owing to the intrusion of the wall caused by the formation of the collateral fissure, and is called the *eminentia collateralis*. The posterior horn gets its peculiar curve from the intrusion of the parieto-occipital fissure on the mesial surface of the hemisphere (Fig. 599).

In **the middle horn** of the lateral ventricle the parietes are the *internal* (mesial) *wall*, the *floor*, and the *roof* (Figs. 616, 619, 622, 623). The inner wall swells outward, so that it is seen in large part in a view from above; the floor is rounded

up in the middle like a turnpiked road ; and the roof, which presents the broadest surface of this prismatic cavity, is slightly arched. The bulging of the mesial wall corresponds to the depression in the cortex, which is named hippocampal fissure, and itself is called the *hippocampus* ("sea-horse")—sometimes *major* ("the greater") being added. This peculiar elevation widens as it extends toward the apex of the horn, and terminates in a blunt indented end, called the *pes hippocampi* ("the foot of the hippocampus") from its resemblance to the paw

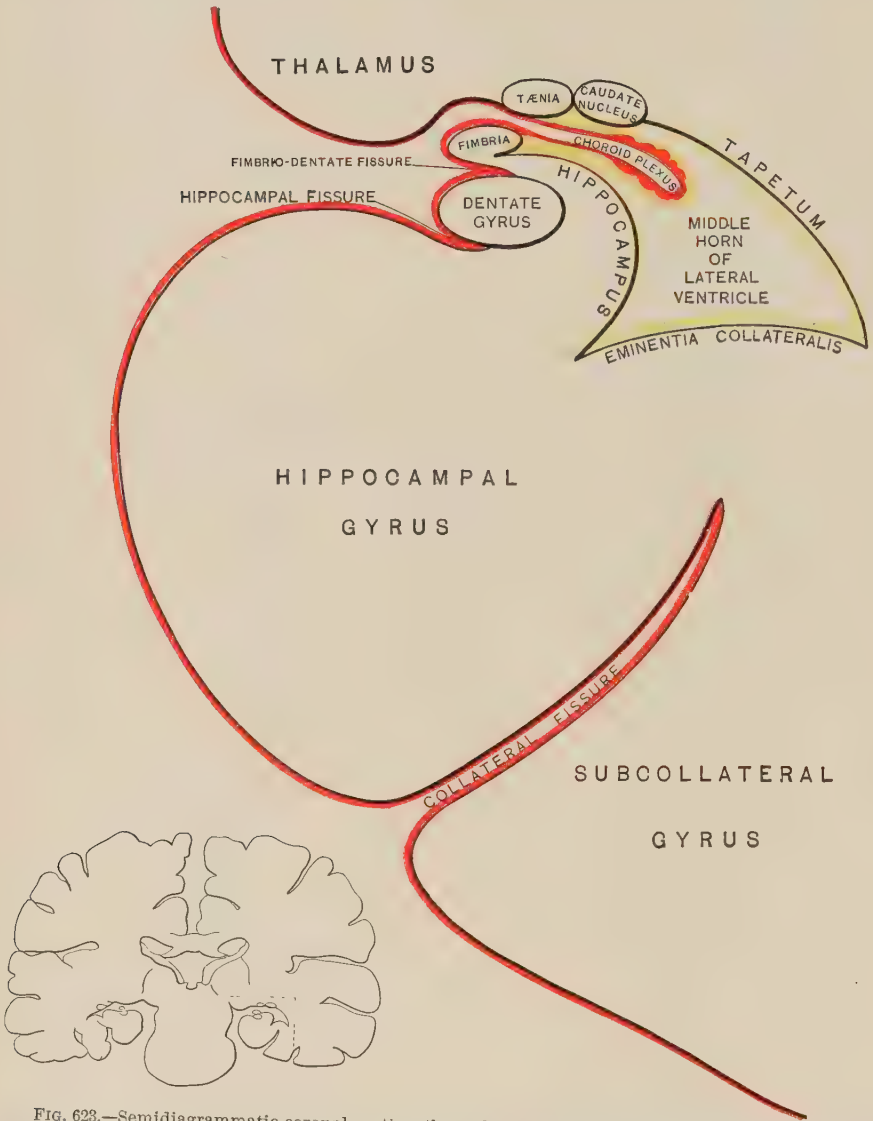

FIG. 623.—Semidiagrammatic coronal section through the middle horn of the right lateral ventricle. We look upon the hind surface of the front segment, and forward into the cavity. The pia is in red, the endyma in yellow. The transverse fissure, between the tænia and the fimbria, admits the choroid plexus to the ventricle. The small figure is the outline of the section of the brain from which the large drawing was made. The cut went through callosum and pons. The dotted lines indicate the part of the small picture which is shown greatly magnified in the large one. (F. H. G.)

of some animal. The convexity of the floor results from the bending inward of this part of the parietes of the cavity caused by the collateral fissure, anterior to the part which causes the prominence in the floor of the posterior horn. Attached to the roof, which is made by the tapetum, are the *tail of the caudate nucleus* and the *tænia semicircularis*, side by side, as they were in the body of the ventricle

from which they are traced, and ending in front in the *amygdala*. Along the top of the hippocampus courses the *fimbria*, continued from the posterior pillar of the fornix, of which organ it has become the sole representative. Between the

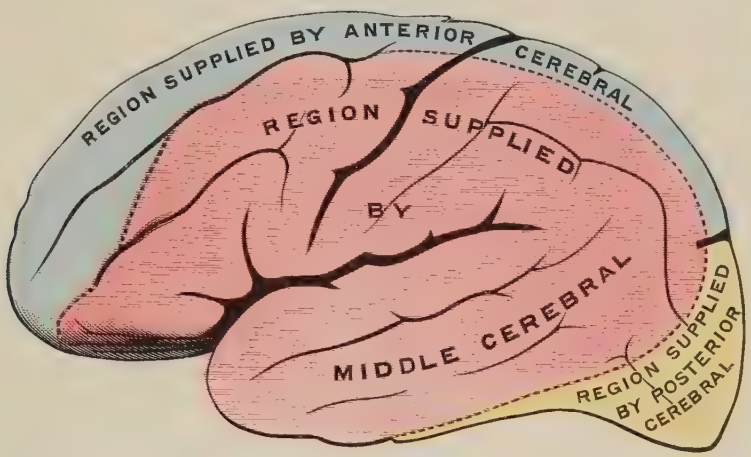

FIG. 624.—Arterial supply of the lateral surface of the cerebral hemisphere. (Testut.)

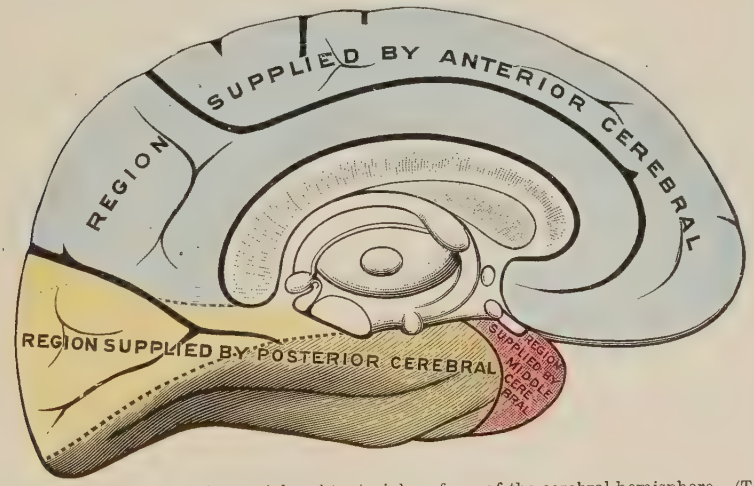

FIG. 625.—Arterial supply of the mesial and tentorial surfaces of the cerebral hemisphere. (Testut.)

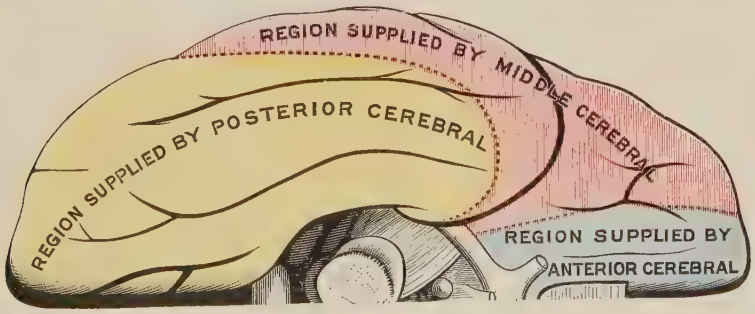

FIG. 626.—Arterial supply of the base of the cerebral hemisphere. (Testut.)

fimbria and the tænia the *choroid plexus* juts into the horn, dangling, as it were, from the junction of the mesial wall and the roof.

Arteries of the Hemisphere.—The cerebral hemispheres are supplied with

blood by the anterior, middle, and posterior cerebral arteries, which have been described in a previous chapter. It is only necessary here to refer to that account for details of course and distribution, and to call attention to Figs. 624, 626, which show most impressively the regions to which each of these vessels furnishes nourishment.

THE THALAMENCEPHALON—THE REGION OF THE THIRD VENTRICLE.

The third ventricle comprises the parts developed from the second encephalic vesicle and, in addition, the aula of the first vesicle—the latter constituting the front and upper portion, as has been related in the early part of this chapter.

The *third ventricle* (Figs. 627–629) is a narrow, deep, median crevice, on a plane distinctly below that of the body of the lateral ventricle. It opens at its

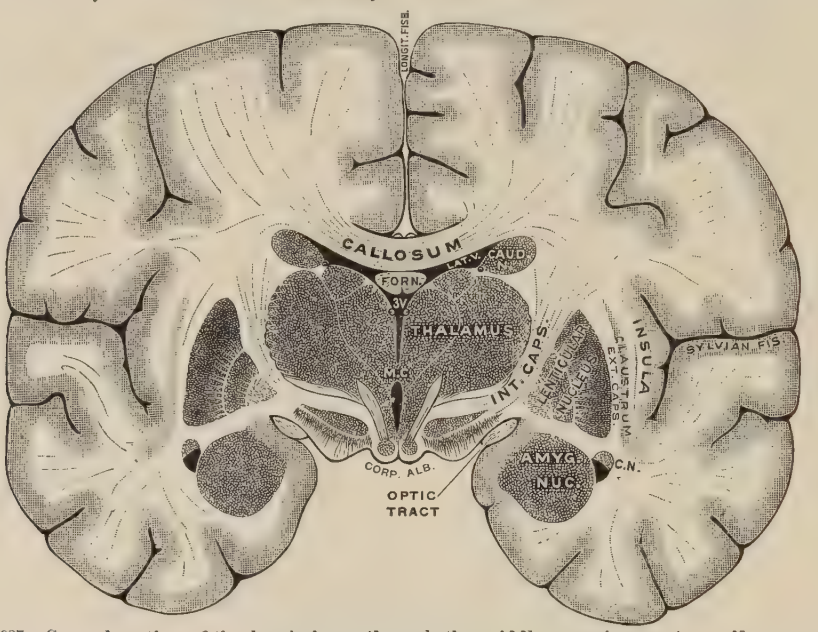

FIG. 627.—Coronal section of the hemispheres through the middle commissure; AMYG. NUC., amygdaloid nucleus; C. N., caudate nucleus in the roof of the middle horn of the right lateral ventricle; CORP. ALB., corpora albicantia; EXT. CAPS., external capsule; FORN., fornix; INT. CAPS., internal capsule; LAT. V., body of lateral ventricle; 3 V., third ventricle. (Testut.)

upper, outer and front angles into the portæ (foramina of Monro), by which communication is established with the lateral ventricles; and high up on its hind wall it is continuous with the aqueduct. Its lateral boundaries are made by the thalami; its roof is furnished by the median part of the velum interpositum; it is bounded in front by the anterior pillars of the fornix and the lamina cinerea; behind are the epiphysis (pineal gland), the posterior commissure, and the aperture of the aqueduct; its floor, reckoning from behind forward, is made by the tegmenta of the crura cerebri, the posterior perforated space, the corpora albicantia, and the tuber cinereum with the infundibulum and hypophysis (pituitary body); crossing it from side to side is the middle commissure; and hanging down into it from the roof are the choroid plexuses of the third ventricle.

As the thalamencephalon is intimately connected with the mesencephalon, it is necessary to present a brief description of the latter at this stage of our study.

The mesencephalon is the *isthmus* between the higher and lower parts of the brain. It is perforated from end to end by the *aqueduct.* In front of this passage are the *crura cerebri* ("legs of the cerebrum"), two great columns which are diverging, upward continuations of the white substance from the pons and cerebellum. The ventral part of each crus is called *crusta*, the dorsal part *tegmentum.* Behind the aqueduct the material is arranged in four distinct knobs, the *corpora quadrigemina.*

The Thalami (Figs. 628, 629).

The thalami, often called *thalami optici* ("optic couches"), are large masses of gray substance of irregular shape, presenting mesial, upper, and back surfaces,

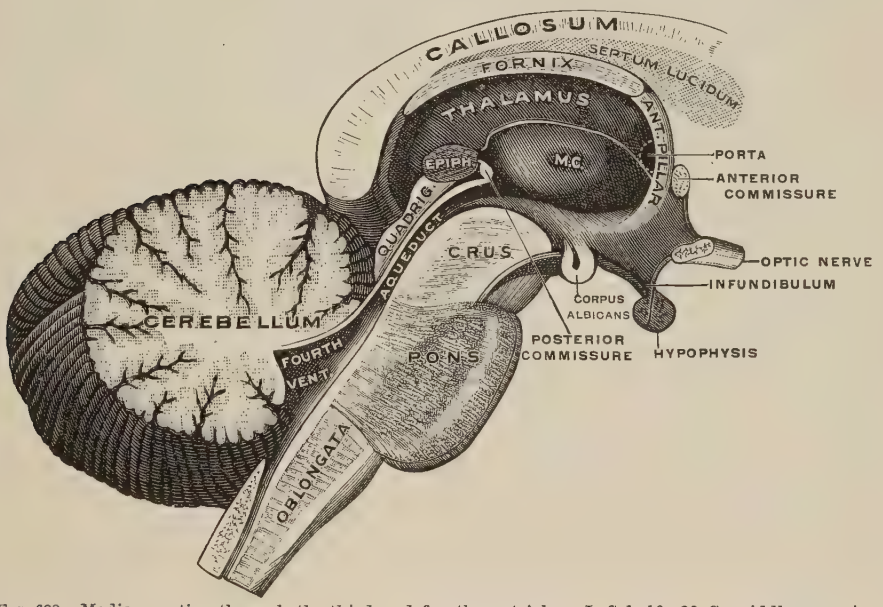

FIG. 628.—Median section through the third and fourth ventricles. Left half. M. C., middle commissure. (Testut.)

which are free, and under and outer surfaces, which are attached, being blended with contiguous parts of the brain. The free surfaces are covered with a thin layer of white nervous tissue. The *mesial surface* of each is flattened, and forms

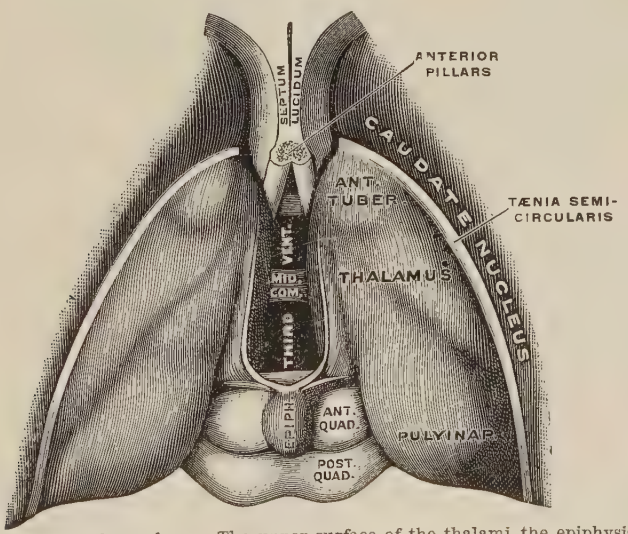

FIG. 629.—Third ventricle from above. The upper surface of the thalami, the epiphysis, and the corpora quadrigemina are seen. (Testut.)

a side wall of the third ventricle from floor to roof. The boundary between the mesial and upper surfaces is marked by a white band, the stalk of the epiphysis, extending from the anterior pillar of the fornix in front to the epiphysis behind.

Along the mesial surface from the porta to the aqueduct is a groove, the *sulcus of Monro* (*aulix*, "a furrow"), usually but faintly marked, indicating the line of junction of the dorsal and ventral zones, into which morphologists divide the encephalon.

The *upper surface* is divided into a postero-internal portion and an antero-external portion by an oblique groove. Upon the former of these areas lies the velum interpositum, whose free edge, the choroid plexus of the lateral ventricle, rests upon the latter area. A portion of this surface beyond the plexus is often, perhaps usually, seen in the floor of the latter ventricle, separated from the caudate nucleus by the tænia semicircularis. In the diagrams (Figs. 590 and 593), which represented the first and second vesicles developing separately, the thalamus manifestly could have no place in the lateral ventricle; and in the embryo it is absolutely excluded from this cavity. The upper surface of the thalamus is pial; and, while a strip of this appears in the ventricular floor, it is there covered by the endyma, which completely lines the cavity, and the thalamus is seen through this delicate membrane. At the extreme front of this surface is a rounded end, the *anterior tubercle*. Behind at the inner side of the thalamus is another tubercle, the *pulvinar* ("couch"), which extends downward, and occupies the posterior surface. At the lower and outer portion of the posterior surface are the two *corpora geniculata* ("the bended-knee bodies"), internal and external (Figs. 638, 622), connected behind with the corpora quadrigemina by the *posterior* and *anterior brachia*, and in front continued into the optic tract.

The *outer surface* and anterior end are closely related to the internal capsule, into which they send many fibres.

The *under surface* rests upon a forward extension of the tegmentum.

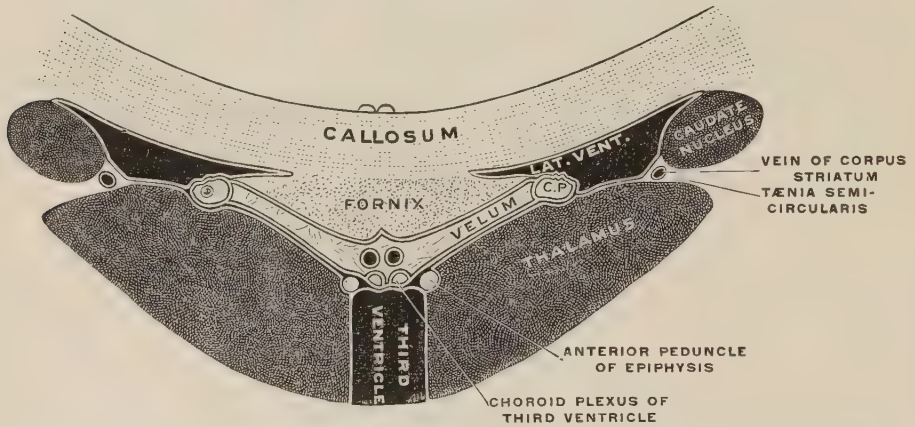

FIG. 630.—Coronal section through the lateral and third ventricles, showing the velum interpositum pushing the choroid plexuses (C. P.) into the lateral ventricles above the thalami. (Semidiagrammatic.) (Testut.)

The great bulk of the thalamus is gray substance, which is divided into *outer* and *inner nuclei* by a thin, curved, white layer. The two thalami are connected by a gray band, the *middle* (soft) *commissure*, which crosses the third ventricle nearly at its centre (Figs. 627–629). They are also united by the floor of the ventricle.

The *roof* of the third ventricle is formed by the *velum interpositum* (Fig. 630), which has already been described. The endyma lining the ventricular cavity is reflected from the thalami onto the under surface of the velum along the lines marked by the peduncles of the epiphysis (pineal body). From the under surface of the velum hang the *choroid plexuses of the third ventricle*, covered, of course, by the endyma.

Authors differ widely concerning the extent of the floor of the third ventricle. Some include every part of the walls excepting the sides and roof, thus making the floor embrace all of the parts on or near the middle line below the plane of the stalks

of the epiphysis (pineal peduncles), which indicate the uppermost lateral boundaries. Others apply the name "floor" only to the structures extending from the location of the optic chiasma back to the opening of the aqueduct, considering all from the chiasma to the junction of the pineal peduncle with the fornix as anterior wall. The latter method is pursued here, although one sees specimens which justify the subdivision of this floor-space so that a posterior wall of considerable extent may be described.

From the aperture of the aqueduct the *floor of the third ventricle* slopes quite sharply downward and forward, and is made by (1) the tegmenta of the mesencephalon, (2) the posterior perforated space, (3) the corpora albicantia, and (4) the tuber cinereum, whose central part is the infundibulum, to which the hypophysis is attached.

The tegmenta abut abruptly upon the ventricular cavity. The surface which they present is slightly convex, and is covered with a continuation of the gray matter which surrounds the aqueduct. This sheet of gray is extended forward beyond the limits of the tegmenta, and forms the greatest part of the floor. Furthermore, it rises for a little distance upon the mesial surface of the thalami, and thus covers the lower part of the anterior pillars of the fornix, where they lie against these bodies. The part of the floor in front of the tegmenta presents a free under surface, which is visible on the base of the brain. This area is rhombic, and margined in its rear portion by the diverging crura cerebri, in its front by the converging optic tracts. The surface area included by these structures is called the *interpeduncular space*, from its being, in part, between the cerebral crura or peduncles. It is composed almost wholly of gray substance, and is a bond of union between the two thalami. In its hind portion is the *posterior perforated space*; in its fore part is the *tuber cinereum* ("ashen knob"). Between these two the *corpora albicantia* ("whitish bodies") are inserted.

The **Posterior Perforated Space**, so called from its situation and appearance, is a forward continuation of the gray matter in the wall of the aqueduct, and stretches laterally between the diverging crura. Its numerous apertures give passage to small vessels.

The **Tuber Cinereum** is continuous behind with the posterior perforated space, and in front with the lamina cinerea, which forms a part of the anterior wall of the third ventricle. The central part of the tuber cinereum is prolonged downward in the shape of a cone, the *infundibulum*, whose funnel-like cavity is a part of the third ventricle (Fig. 631). To the apex of the infundibulum is attached the *hypophysis* ("the growth underneath") also called the *pituitary gland*, from the erroneous notion, formerly entertained, that it secreted the mucus (pituita), which is discharged from the nose. This body is lodged in the sella Turcica of the sphenoid bone, in which it is firmly held by the dura, the fibrous membrane lining the brain-case. The hypophysis is composed of two parts, essentially different in origin and histological character. The posterior portion is the smaller, and is a process from the ventricular wall, at first being hollow and communicating with the ventricle, but ultimately losing its cavity, and consisting of nervous matter intermingled with much fibrous tissue. The anterior portion is much the larger, and partly embraces the posterior. It is derived from the primitive oral cavity, and its structure bears a resemblance to that of the thyroid body. The hypo-

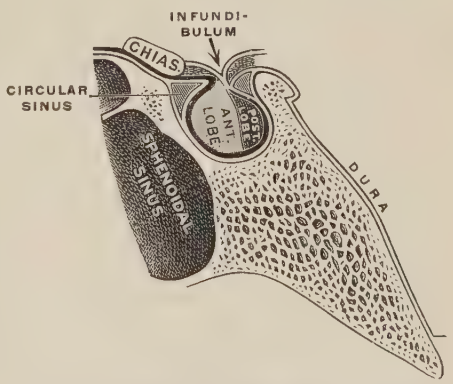

FIG. 631.—Sagittal section through the hypophysis, mesial surface of right segment. (Testut.)

physis has been found greatly enlarged in many cases of acromegaly, and hence has been supposed to sustain a relation to the stature of the individual.

The **Corpora Albicantia** (Figs. 613, 627, 628), situated about midway of the floor of the third ventricle, are parts of the anterior pillars of the fornix. The pillars are traced down from their beginning in the lateral ventricles, form a part of the front wall of the third ventricle, curve backward in their descent, and perforate the floor of the third ventricle near its centre, thus interrupting what, without them, would be the complete continuity of the expanse of gray matter in this region. Each pillar then turns abruptly on itself, forming the bunch which is named corpus albicans, and extends upward and outward to the thalamus of its own side, into the substance of which it plunges and runs to the anterior tubercle. In composition these bodies are white nervous tissue enclosing gray. They are connected with the crura cerebri by white fibres embedded in the gray material of the floor. The cord which extends from the corpus albicans to the thalamus, and which is called the *bundle of Vicq d'Azyr*, though seemingly a prolongation of the fornix, is now thought to have no histological continuity with it.

The *anterior wall* of the third ventricle consists in its lower part of the *lamina cinerea*, otherwise called *lamina terminalis*. The first of these names implies that it is composed of gray matter, and the second that it is the uttermost boundary of the third ventricle. It is continuous below with the tuber cinereum, which it joins behind the *chiasma*, or optic commissure, and it blends at its sides with the anterior perforated spaces. Together with the tuber cinereum and posterior perforated space it makes up the *basal gray commissure*. Its upper border is connected in the middle with the rostrum of the callosum by the basal white commissure, and laterally is continuous with the gray substance of the gyri of the under surface of the frontal lobes. It passes in front of the anterior commissure, which consequently lies between it and the anterior pillars of the fornix.

The upper part of the anterior wall is supplied by the *anterior pillars of the fornix*. The lower portion of each pillar is close to the thalamus of the same side, and is covered, as is the neighboring surface of the thalamus, by a thin layer of gray matter, which is a lateral extension of the basal gray commissure.

On each side between the anterior pillar of the fornix and the thalamus is the *porta* (foramen of Monro), an opening with a well-defined, oval margin. This is the developed condition of the lumen of the little sprout, which budded from the upper, front part of the wall of the first encephalic vesicle, and expanded at its distal end into the body of the lateral ventricle. It connects the third ventricle with the lateral. There is no passage directly from one lateral ventricle to the other, because the third ventricle intervenes between the two portæ. It is, however, interesting to observe that the most nearly direct course between the cavities of the lateral ventricles is across the fore and upper part of the third ventricle—the portion which is developed from the aula, the first encephalic vesicle, from which the lateral ventricles themselves are derived. The two portæ and the intervening aula together are sometimes called the *foramen commune anterius*. Each porta permits the passage of a prolongation of the choroid plexus of its lateral ventricle.

The remaining portion of the wall of the third ventricle is found in the small space between the long stalk of the epiphysis (pineal peduncle) and the opening of the aqueduct. It may be called the *rear wall*. The upper lip of the aperture of the aqueduct is formed by the anterior border of the quadrigeminal mass, at this point thickened and folded back, thus making a ridge, which stretches from side to side, and constitutes the *posterior commissure*. The fibres of this body apparently connect the thalami, and probably also extend into the white substance of the hemispheres.

Above the posterior commissure is the *epiphysis* ("the growth upon"), otherwise called *conarium* and *pineal gland*, these last names being given on account of the fancied resemblance of the body to a pine cone. Epiphysis is the best of the names, because this object is an upgrowth from the second encephalic vesicle.

At first it is hollow; but its follicles soon become filled with epithelial cells and particles of earthy material, called *brain-sand—acervulus cerebri* ("the little heap of the cerebrum"). The ancients had a grotesque theory that the epiphysis is the favorite and peculiar abiding place of the human soul. Modern morphologists have shown it to be the homologue of the third eye which some reptiles possess. It projects outside of the ventricle, and rests upon the two upper quadrigemina. It has a *double stalk* of white nervous material on each side. One of these is very short, and is connected with the posterior commissure; it stretches from one side to the other, forming the upper lip of the opening into the epiphysis, and is called the *supracommissure*. The other, already mentioned, extends from the epiphysis to the anterior pillar of the fornix, and indicates the upper, lateral boundary of the third ventricle (Fig. 628). It is called the peduncle of the epiphysis, and also the *habenula* ("little thong").

The walls of the third ventricle are so intimately blended at various points with those of the lateral ventricles that it is impracticable to determine the exact line of union; but a portion of it doubtless lies in the internal capsule.

There is *an unbroken continuity of gray matter* from the lamina cinerea at the front of the third ventricle to the gray surrounding the central canal of the spinal cord. The lamina cinerea is connected in front not only with the callosum, but also with the gyri of the frontal lobe, and at its sides it joins the anterior per-

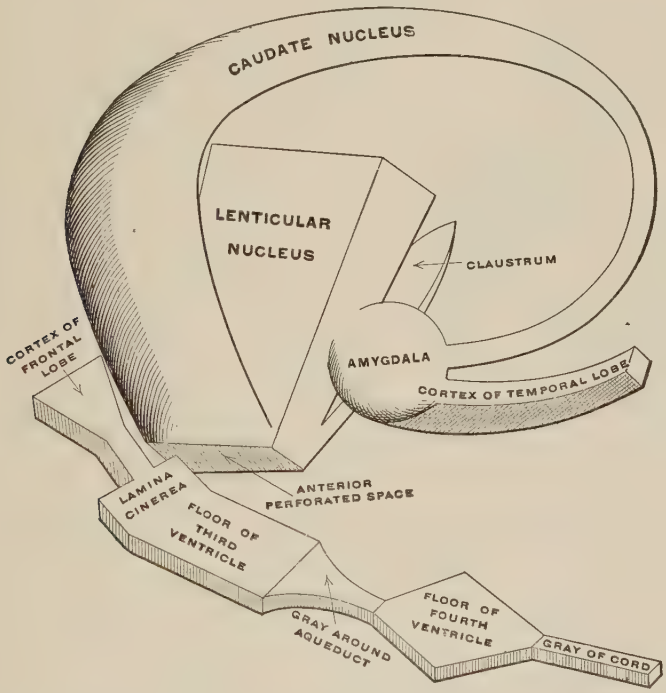

FIG. 632.—Diagram to show the continuity of the gray of the basal ganglia of the cerebral hemispheres, the cortex, and the lower segments of the cerebro-spinal axis. (F. H. G.)

forated space, which is the surface area of the lenticular and caudate nuclei and the claustrum; and these are connected with the gyri of the temporal lobe through the amygdala, which is fused with the lenticular nucleus. Keeping these facts in mind, it is easy to understand that the great ganglia are only local thickenings of the gray matter surrounding the cavity of the cerebro-spinal axis, which in the adult displays in the spinal cord the least change from the original condition.

The Subthalamic Region.—The mass upon which the thalamus rests is made

up mostly of a forward continuation of the tegmentum of the mesencephalon. Three layers are distinguished: the *stratum dorsale*, which is superior; the *zona incerta* ("the uncertain zone"), a reticulated, fibrous collection, the origin of which is doubtful and its boundaries obscure; and the *corpus subthalamicum* ("body under the thalamus"), derived from the locus niger, which lies between the tegmentum and crusta of the mesencephalon. Dorsal and mesial to the corpus subthalamicum is an extension of the red nucleus of the tegmentum. The subthalamic region thins out as it extends forward and outward, and finally becomes continuous with the anterior perforated space.

The Internal Capsule.

A horizontal section through the lenticular nucleus at any but its lowest levels displays this great ganglion surrounded by a thick layer of white substance. The portion of this enclosing material on the mesial side is the *internal capsule*, and that between the nucleus and the claustrum is the *external capsule*.

The internal capsule (Figs. 618, 627, 619, 633), as seen in horizontal section, following the mesial surfaces of the lenticular nucleus, forms a bend with its convexity toward the middle line. The part at the angle is the *genu*; that in front of it is the *anterior segment*; and that behind is the *posterior segment*. The anterior segment separates the lenticular nucleus from the caudate; the posterior divides it from the thalamus; and the genu comes up to the tænia semicircularis, pushing in between the caudate nucleus and the thalamus.

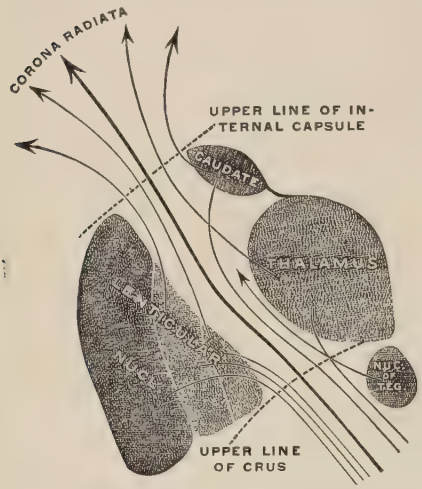

FIG. 633.—Diagram of the composition of the internal capsule. (Testut.)

The internal capsule is largely composed of fibres which run between the cortex of the hemisphere above and the crura cerebri below. But it has ingredients which connect these parts only indirectly. Some fibres enter it from the end, which do not leave it, but plunge into the surrounding ganglia—the thalamus, the caudate and lenticular nuclei. Others enter at its sides from the same gray masses, and emerge from the end. Certain fibres come to it from the subthalamic region, and still others from the hemisphere of the opposite side through the callosum. The general drift of its direction, however, is between the lowest and the highest centres of the cerebro-spinal axis—from below upward and outward. Tracing the fibres upward we find that, immediately on emerging from the capsule, they spread out in every direction toward the cortex, constituting the *corona radiata* ("the radiant crown").

The anterior segment is chiefly composed of fibres coursing longitudinally between the thalamus and the cortex of the frontal lobe. The hind portion of the posterior segment is a continuation of the lemniscus, and the remaining portions are connected with the region of the cortex about the central (Rolandic) fissure.

At various places, particularly in its anterior part, the internal capsule is streaked with cords of gray, which cross it between the caudate and lenticular nuclei.

The **External Capsule** (Fig. 618), which is situated between the lenticular nucleus and the claustrum, is united to the internal capsule below and behind. It is composed of fibres contributed partly by the anterior commissure, and partly by the subthalamic region.

Diagrammatic Description of the Lowest Parts of the Brain.—Before entering

upon the detailed study of the remaining structures of the brain, which are related to one another in a very intimate and complex manner, it is well to consider them in a schematic way, by which the principal features of their gross anatomy shall be presented clearly and form the groundwork for the more minute consideration of the subject (Fig. 634). This, in part, has been done on a previous page, but may profitably be reviewed at this stage.

The cerebral hemispheres and the parts in the region of the third ventricle, already described, are developed from the first and second encephalic vesicles. From the third vesicle is developed the mesencephalon, from the fourth the pons and cerebellum, and from the fifth the oblongata.

The *mesencephalon* is often called the isthmus of the brain, because it is the narrow neck by which the great cerebral mass above is connected with the structures below. Its ventral part is shaped like two pillars converging to the pons, and is called the crura cerebri; its dorsal protrudes in four tubercles, the corpora quadrigemina. Its cavity is the aqueduct.

The *cerebellum* is a large, solid body, the second of the brain-masses in size, and constitutes the dorsal portion of the wall of the fourth ventricle. It is connected above by the superior cerebellar peduncles with the quadrigemina; in front by the middle cerebellar peduncles with the pons; and below by the inferior cerebellar peduncles with the oblongata.

The *pons* is situated between the isthmus above and the oblongata below, and forms the upper portion of the ventral part of the wall of the fourth ventricle. It bulges in front and laterally, and runs back on each side into the middle cerebellar peduncle. Between the dorsal surface of the pons and the ventral surface of the cerebellum is the upper half of the fourth ventricle.

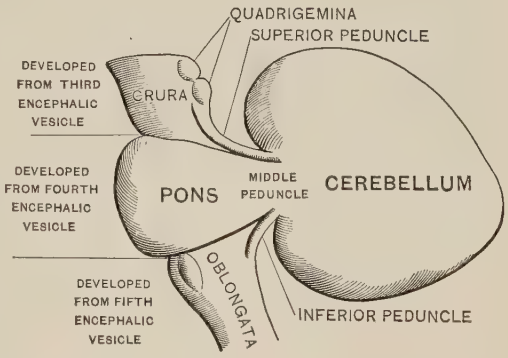

FIG. 634.—Diagram of the parts of the encephalon below the thalami, left side.

Below the pons is the *oblongata*, developed from the fifth vesicle. It is shaped like an irregular, inverted, truncated cone. It is continuous below with the spinal cord. The upper part of its cavity is the lower part of the fourth ventricle proper, and the rest of it is tubular and directly continuous with the central canal of the spinal cord.

The columns of fibrous nervous tissue are chiefly continued upward from the spinal cord through the oblongata, the pons, and the isthmus, to the higher levels of the brain; but some of them switch off dorsally to the cerebellum, thus constituting the inferior peduncle of that body. The gray nervous tissue, also, is continued upward from the cord, and a portion of it is thus connected with the highest collections of gray matter in the cerebrum; but in the oblongata considerable masses are detached by the intrusion and crossing from one side to the other of large bundles of white nervous tissue, and at various points are found new collections of nerve-cells, which are not the representatives of any nuclei at lower levels.

THE MESENCEPHALON—THE REGION OF THE AQUEDUCT.

Next below the thalamencephalon comes the mesencephalon, otherwise known as the *mid-brain*, from its situation, and as the *isthmus cerebri*, because it is the constricted bond of union between the parts which result from the development of the first and second encephalic vesicles and those which come from the fourth and fifth. Its direction is from before backward and a little downward. Viewed

from below it displays a ventral surface, which is marked by two short, thick, white columns, converging toward the pons, like the limbs of the letter V, and called the *crura cerebri* ("legs of the brain"), and also the *cerebral peduncles* ("little feet") (Fig. 637). Between the crura is a triangular area, already described as the hind part of the interpeduncular space (see page 549).

The dorsal surface is not visible until certain overlying structures have been removed. It then presents to view four prominent knobs, the *corpora quadrigemina* ("four-twin bodies"), and the upper portion of the superior cerebellar peduncles (Fig. 638). The quadrigemina are arranged in pairs, an upper (anterior) pair, sometimes called the *nates*, and a lower (posterior), known also as the *testes*. A median groove separates the right tubercles from the left, and ends above at the posterior commissure; and the superior are divided from the inferior by a transverse gutter. At the outer sides the quadrigemina run upward and forward into the brachia (Fig. 638). The quadrigemina are composed principally of gray matter, covered by a thin layer of white.

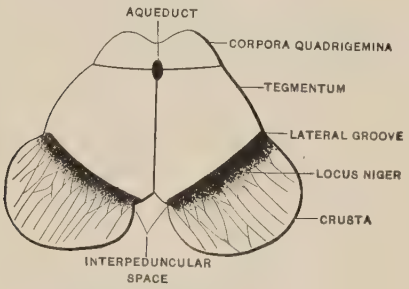

FIG. 635.—Transverse section of the mesencephalon. (Testut.)

A cross-section of the isthmus (Figs. 635, 636) shows that each lateral half is divided into two unequal parts by a band of nerve-cells, so deeply pigmented as to have received the names *locus niger* ("the black place") and *intercalatum* ("inserted between"). Ventrally to this is the column of white nervous tissue which forms a side boundary to the interpeduncular space, and is called the *crusta* ("crust"). Dorsally is a mass of mingled white and gray, the *tegmentum* ("covering"). At each border the locus niger comes to the surface at a groove, that which is mesial being the place of emergence of the third cranial

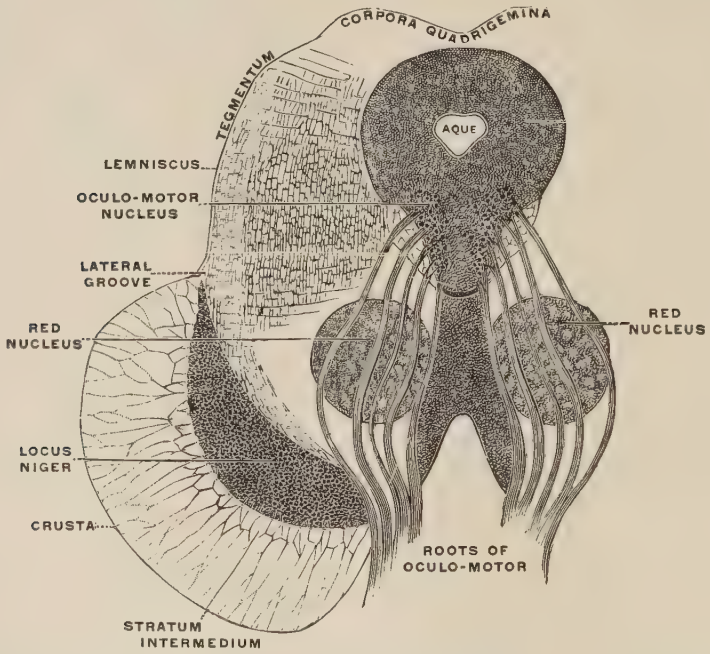

FIG. 636.—Transverse section through the anterior quadrigemina. (Testut, after Stilling.)

nerve, and the other, called the *lateral groove*, runs from the internal geniculate body to a point between the superior and middle peduncles of the cerebellum.

The crusta is composed largely of flat bundles of white tissue which present their edges at the free surface. The part of the crusta close to the locus niger is the *stratum intermedium*. The fibres of the crusta can all be traced upward through the internal capsule to the cerebral cortex—the innermost series to the frontal lobe, the outermost to the occipital and temporal lobes, and the intervening set to the region around the central fissure. Going downward, the inner group has an undetermined ending, the outer is followed to cells in the pons, and the intermediate to the ventral pyramid of the oblongata. The tegmentum extends from the locus niger up to the level of the aqueduct, and above this plane is the *lamina quadrigemina*, upon which the corpora quadrigemina rest. The tegmentum consists of a network of longitudinal and transverse white fibres in the meshes of which is much gray matter, the whole constituting the *formatio reticularis*. Some tolerably distinct white fasciculi are observed. Just dorsal to the locus niger and extending laterally upon the free surface is the *lemniscus*, which will be described best at a later point, as portions of it appear in several segments of the brain. Ventral to the gray around the aqueduct is the *posterior longitudinal bundle*, whose fibres are traceable from the subthalamic region to the ventral column of the cord. The white around the red nucleus is an extension of the greater part of the superior cerebellar peduncle of the opposite side—decussation taking place across the middle line in the *raphe*, and the fibers running to the thalamus. As a whole the white of the crura is a continuation of bundles from the internal capsule and subthalamic region. The *aqueduct* is a small canal, and is surrounded by a considerable thickness of gray, in which are embedded clusters of nerve-cells, which are connected with the roots of the third, fourth, and fifth cranial nerves. In the fore part of the tegmentum is a globular collection of cells, the *red nucleus*, through which pass the roots of the oculomotor (third) nerve. The anterior extremity of the tegmentum is convex, and slopes downward and forward, forming a part of the floor of the third ventricle. Upon this surface is extended the forward continuation of the gray of the aqueduct. The locus niger can be traced backward to the upper margin of the pons, and forward to the corpus albicans and the corpus subthalamicum.

THE EPENCEPHALON—THE REGION OF THE UPPER PART OF THE FOURTH VENTRICLE.

This segment of the brain comprises the parts developed from the fourth encephalic vesicle, namely, the pons and the cerebellum.

The Pons.

The pons, otherwise called *pons Varolii* ("bridge of Varolius") and *tuber annulare* ("annular protuberance"), consists largely of white nervous tissue, the greater part of which is divided into two groups of bundles, according to the direction in which they run (Figs. 637, 639). One set courses nearly vertically from the mesencephalon to the oblongata, occupying the central portion of the pons; the other, mainly superficial to this, is disposed horizontally, and is seen at the front and sides, projecting beyond the surface plane of the crura and the oblongata. The horizontal part gives the name to the whole, because it suggests the arch of a bridge connecting the lateral halves of the cerebellum. The ventral portion of the arch has the greatest vertical diameter, and the sides taper as they go dorsally, being smallest where they enter the cerebellum, constituting the middle peduncles of this organ.

By removing the cerebellum, a view is obtained of the dorsal aspect of the pons (Fig. 638). On each side is seen a superior peduncle of the cerebellum, running downward and outward from the quadrigemina. Between these two diverging masses is stretched a flat, triangular plate, consisting of two layers of nervous tissue, the ventral being white, the dorsal gray. This structure

is variously called the *valvula*, the valve of Vieussens, and the anterior or superior medullary velum. It forms the upper part of the dorsal wall or roof of the fourth ventricle, and is covered by folia of the lingula of the cerebellum. Cutting away the valvula we look into the fourth ventricle, and see the upper

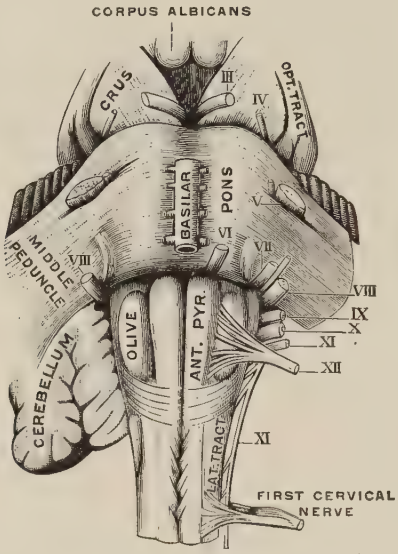

FIG. 637.—Ventral view of mesencephalon, pons, and oblongata. (Testut.)

portion of its ventral wall or floor, overlapped at its sides by the mesial borders of the superior cerebellar peduncles (Fig. 646). In the entire middle line of this triangular area is a groove, *sulcus longitudinalis medianus*, close to which and to the oblongata is a rounded projection, the *eminentia teres* ("the round eminence").

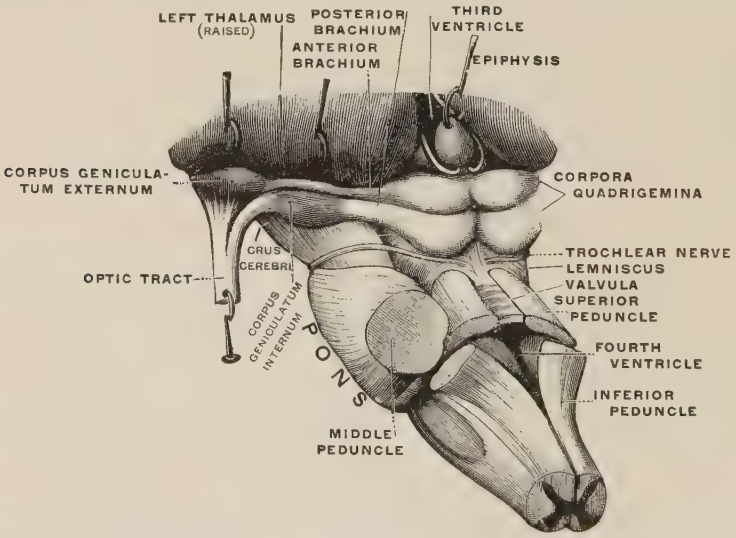

FIG. 638.—Dorsal view of the mesencephalon, pons, and oblongata. The cerebellum and metatela have been removed. The thalami and epiphysis are drawn upward, the optic tract downward. (Testut.)

Beside this is a shallow depression, the *fovea superior* ("the upper little pit"), and above the latter a deeply pigmented area, the *locus ceruleus* ("the blue place"). Between the eminentia teres and the fovea superior is a band of white fibres, the *conductor sonorus*.

A cross-section of the upper portion of the pons shows that the bulk of its

ventral and larger part is composed of transverse bundles, which, extended dorsally, form the middle peduncles. Some of their fibres cross to the opposite side, and are connected with cells which are intermingled with the white. On each side of the middle line, embedded in the mass, is a longitudinal bundle, which is a downward continuation of a part of the crusta, and extends into the ventral pyramids of the oblongata.

The dorsal and smaller part is called the *tegmentum*, because it is continuous above with the tegmentum of the mesencephalon, and below with that of the oblongata. In the median line is a *raphé* of crossing fibres. The greater part of the tegmentum is *formatio reticularis*, like that in the region above. Directly in front of this portion is a longitudinal bundle of white, the *lemniscus*, previously referred to, and toward the back is the *posterior longitudinal bundle*, a caudal extension of the tract of the same name in the segment above. In the lower part of the pons is a transverse bundle of fibres, the *trapezium*, occupying the front of the dorsal portion, and connected with the accessory auditory nuclei. Scattered through the reticular formation are several collections of cells—the superior olive, and nuclei of the fifth, sixth, seventh, and eighth cranial nerves. These centres will be dealt with in connection with the peripheral nerves.

The Cerebellum.

The cerebellum is the great, solid, nervous mass lying dorsal to, and on the same plane with, the pons, with which it is developed from the fourth encephalic vesicle (Fig. 639). It is situated in the posterior fossa of the cranium, and is

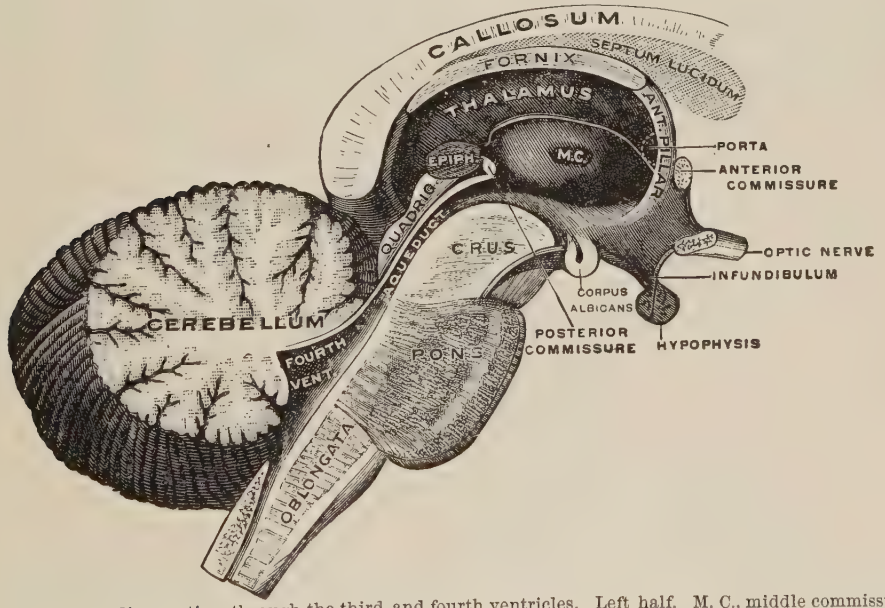

FIG. 639.—Median section through the third and fourth ventricles. Left half. M. C., middle commissure. (Testut.)

shielded from the pressure of the overlying cerebral hemispheres by a strong, tightly stretched prolongation of dura, called the tentorium. It has no cavity proper to itself, but it participates in the formation of the roof of the fourth ventricle. Its main portion consists of three parts, a median and two lateral, all continuous and of substantially the same structure.

The lateral parts are called *hemispheres*—a piece of nomenclature imitative of that of the great cerebral masses, rather than appropriate on account of its inherent descriptiveness. These bodies attain a size so greatly in excess of that

reached by the median portion, which is between them, that the latter is comparatively insignificant, and its obscuration by them on the lower aspect is almost complete in the normal position of the parts.

The median portion is called the *vermis* ("worm") or vermiform process, on account of the undulatory appearance of its irregular surface. On the upper aspect of the cerebellum the vermis and hemispheres are separated only by slight grooves; but on the under surface the vermis is sunk almost out of sight in a deep depression, the *vallecula* ("little vale"), which ends behind in a deep notch, in front in a shallow one.

The cerebellum is connected with other parts of the encephalon by six bands, three on each side. To the oblongata run the *inferior peduncles*, otherwise called the restes. To the quadrigeminal bodies of the isthmus stretch the *superior peduncles*, which have been seen to bound the pontile portion of the fourth ventricle laterally. To the pons go the *middle peduncles*, which spread out into its ventral protuberance. These peduncles constitute the chief connections of the cerebellum with other parts of the brain; but it is also joined to neighboring parts through the valvula, which stretching between the superior peduncles is overlapped by the lingula, and through the metatela, which is spread between the inferior peduncles, and is continued from the nodule.

The upper surface of the cerebellum is nearly flat, the lower surface decidedly convex. Both surfaces are marked with *fissures* which run in a generally transverse direction, and are so close together as to divide the cerebellar substance into layers or leaves, whence it is said to be laminated or foliated. These *folia* are very different in gross appearance from the gyri of the cerebrum, presenting a sharp border instead of a rounded surface; but they are homologous with these gyri in that they have a basis of white substance and upon this a covering (*cortex*) of gray. The clearest conception of the depth and arrangement of the folia is obtained by making sections, especially in a vertical direction, through the cerebellum at different planes (Fig. 640). It is then seen that the white substance

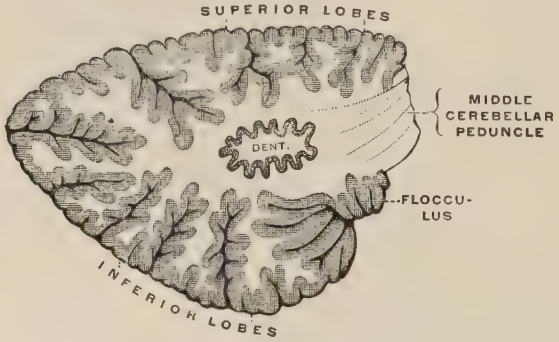

FIG. 640.—Sagittal section of left cerebellar hemisphere. (Testut.)

forms a large core or trunk, the *trapezium*, from which a number of primary branches are given off. Each of these in its turn divides, and, as the ultimate rami, as well as the original, are clothed in gray, an appearance is presented suggestive of a cedar tree, whence the name *arbor vitæ* ("tree of life"), which is given to it.

The upper and lower surfaces are separated by a rather prominent border, partly upon and partly near which runs the longest and deepest of the fissures, the *great horizontal* or *longitudinal fissure*.

The **upper surface** is marked in the middle line by the *superior vermis*, whose central and most pronounced prominence is the *monticulus* ("little mountain"). On each side of the vermis is a shallow groove, beyond which is a hemisphere. The deep fissures divide the entire upper portion of the cerebellum into segments, which are seen most favorably in sagittal sections. For each segment of the ver-

mis there is a corresponding and connected part of each hemisphere. These do not appear plainly in the picture (Fig. 641), but will be understood by reference to the schematic arrangement, in which the segments are named in order from before backward, with the fissures which separate them. The segments of the vermis are the *lingula* ("little tongue"), the *central lobe*, the *culmen* ("summit"), the *clivus* ("slope"), and the *cacumen* ("top"); and the parts of the hemisphere respectively corresponding are the *frenulum* ("little bridle"), the *ala* ("wing"), the anterior or *ventral crescentic lobe*, the posterior or *dorsal crescentic lobe*, and

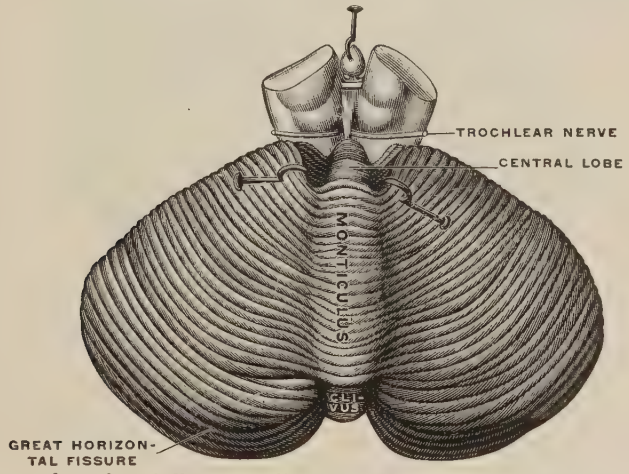

FIG. 641.—Upper surface of cerebellum. The lingula and cacumen are concealed by overhanging parts. The label "monticulus" is on the culmen. Compare with scheme of this surface. (Testut.)

the *dorso-superior lobe*. The fissures are named with reference to their situation in front of or behind the central lobe and the clivus—*precentral fissure*, *postcentral fissure*, *preclival fissure*, and *postclival fissure*.

SCHEME OF UPPER SURFACE OF CEREBELLUM, SHOWING THE MEDIAN PORTION AND THE RIGHT HEMISPHERE.

VERMIS.	HEMISPHERE.
LINGULA.	FRENULUM.
	PRECENTRAL FISSURE.
CENTRAL LOBE.	ALA.
	POSTCENTRAL FISSURE.
CULMEN.	VENTRAL CRESCENTIC LOBE.
	PRECLIVAL FISSURE.
CLIVUS.	DORSAL CRESCENTIC LOBE.
	POSTCLIVAL FISSURE.
CACUMEN.	DORSO-SUPERIOR LOBE.

The **under surface** presents in the mid-line the *inferior vermis*, separated superficially from the hemispheres by lateral grooves. Here, as on the upper aspect of the cerebellum, the deep fissures cut so far into the substance as to mark off segments; but the portions of the hemispheres are less easily seen to be related to correspondent parts of the vermis than in the former case. The fissures are not as regularly disposed, and the whole arrangement is complicated. Close examination, however, reveals a more systematic relation than casual inspection promises, and this is shown diagrammatically in the schematic table, which would

best be studied in connection with the picture (Fig. 642). From before backward are seen in the vermis the *nodule*, the *uvula*, the *pyramid*, and the *dorsal tuber* (tuber posterius); and in the hemisphere the *flocculus* ("little tuft of wool"), the *amygdala* ("almond"), the biventral or *digastric lobe*, the *slender lobe*, and the *dorso-inferior lobe*. The uvula and amygdalæ are so named on account of their

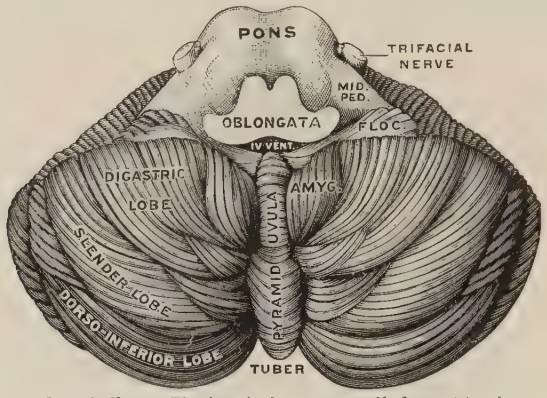

FIG. 642.—Under surface of cerebellum. The hemispheres are pulled apart to give a view of the inferior vermis. The nodule is between the uvula and the fourth ventricle. Compare with scheme of this surface. (Testut.)

resemblance to the parts of the same name in the pharynx, as seen through the open mouth. The fissures are named from their position with reference to the nodule, the pyramid, and the slender lobe—the *postnodular fissure*, the *prepyramidal fissure*, the *postpyramidal fissure*, and the *postgracile fissure*.

UNDER SURFACE OF CEREBELLUM.

VERMIS.	HEMISPHERE.
NODULE.	FLOCCULUS.
POSTNODULAR FISSURE.	
UVULA.	AMYGDALA.
PREPYRAMIDAL FISSURE.	
PYRAMID.	DIGASTRIC LOBE.
POSTPYRAMIDAL FISSURE.	
DORSAL TUBER.	SLENDER LOBE. *POSTGRACILE FISSURE.* DORSO-INFERIOR LOBE.

Embedded in each hemisphere is a nucleus, called the *corpus dentatum* ("toothed body") from its jagged outline (Fig. 643). Its centre is white, and on the mesial side near the front the gray wall is deficient. Near this are three other masses of gray of small size—the *nucleus emboliformis* ("pluglike"), the *nucleus globosus* ("spherical"), and the *nucleus fastigii* ("of the summit").

The general method of arrangement of the fibres traced into the cerebellum from its peduncles is shown in Fig. 644.

The *superior peduncle* is mainly made up of fibres from the corpus dentatum and the cerebellar cortex. The *middle peduncle* is composed of fibres from cells in the cortex. They run to cells on both sides of the pons, and do not, as gross appearances suggest, go around from one side of the cerebellum to the other. The *inferior peduncle* receives fibres from cells of the cerebellar cortex and the oblongata, from the direct cerebellar tract of the spinal cord, and from the nuclei gracilis and cuneatus.

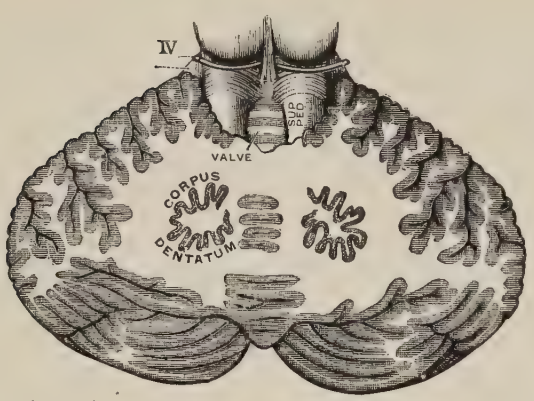

FIG. 643.—Cerebellum in nearly horizontal section—the upper surface of the lower section. (Testut.)

THE METENCEPHALON—THE REGION OF THE LOWER PART OF THE FOURTH VENTRICLE.

In describing this segment of the brain it is frequently necessary to mention correlated parts of the spinal cord, and, consequently, it is highly desirable that the student should have some knowledge of that portion of the cerebro-spinal axis at this stage of his work. He is, therefore, advised to familiarize himself with the diagram of the transverse section of the cord (Fig. 658). It is especially important to observe that the gray of the cord is in one discrete mass, centrally

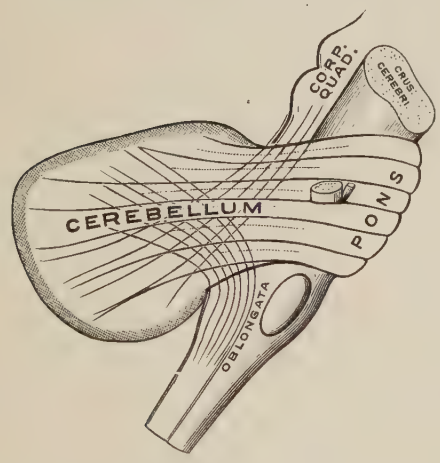

FIG. 644.—Semidiagram of the three cerebellar peduncles. (Testut.)

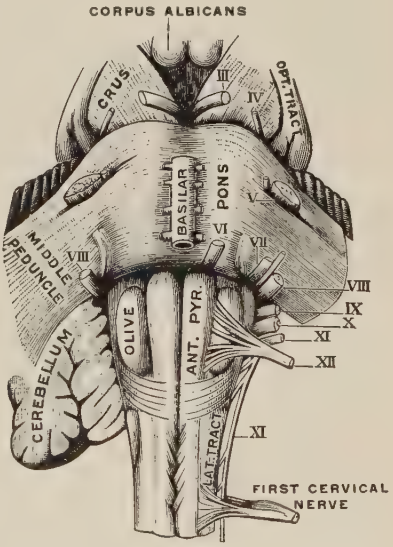

FIG. 645.—The pons and oblongata, ventral view. (Testut.)

located, bilaterally symmetrical, presenting two ventral and two dorsal horns; that the white is arranged on each side in three columns—ventral, lateral, and dorsal; that this white nervous mass consists of collections of bundles of nerve-fibres, some efferent and some afferent, and that these constitute paths by which sensory impressions are conducted brainward, and motor impulses in the other direction. All of these parts, both gray and white, are represented in the oblongata, being continued upward from the cord; but their relations to one another there are, in most cases, radically altered. The gray, instead of being in one mass, as in the cord, is broken up into a number of separate parts; and there are added several

nuclei, which have no homologues in the cord. The white of each part of the myelon seems to be continued upward into the corresponding portion of the oblongata; but this appearance is frequently deceptive, and the bundles are turned into new directions in a very intricate manner.

THE OBLONGATA.

The *oblongata*, also called *medulla oblongata* ("the oblong marrow"), and the *spinal bulb*, extends from the lower margin of the pons to a plane passing transversely just below the decussation of the pyramids, at which level the spinal cord begins. It is shaped somewhat like an inverted truncated cone, flattened ventro-dorsally, and is an inch long. It lies upon the basilar process of the occipital bone, the inclination of which indicates the attitude of the oblongata.

In various ways the gross appearance of the oblongata is suggestive of a segment of the cord of corresponding length. The resemblance is especially striking in its lowest part, which is tubular. Here the shape, the fissures, the origin of the nerve-roots, the columnar arrangement of the white nervous material on the surface, and even the disposition of the gray in the central parts, are nearly identical with those of the cord. But above this a great change is manifest. The dorsal columns are spread widely apart, with the result of bringing near the dorsal surface the gray, which but for this would be deep in the mass around the central canal. The cavity, however, which is thus shifted toward the rear, is not opened by this process; for while the nervous material, which, in the lower parts of the axis, covers in the canal behind, is here lacking, the endyma lining the ventricular cavity and the pia covering it remain, come in contact and form a *tela*, which stretches between the divergent margins, and thus roofs in the space, which is a part of the fourth ventricle. Besides the change of shape which is thus effected, an increase in bulk is produced by the addition of gray masses which have no counterparts in the myelon.

The cranial nerves below the fifth have their apparent origin in the oblongata. They are indicated by Roman numerals in Fig. 645. The first spinal nerve arises in the oblongata.

On the *ventral surface* is a longitudinal cleft, the *ventro-median fissure*, which begins above in a little pit, the *foramen cæcum* ("blind hole"), and is interrupted below by a criss-cross of nerve-bundles. On each side of the ventro-median fissure is a white body, gradually dwindling from above downward, and seeming to be directly continuous with the ventral column of the cord. These are the *ventral* (anterior) *pyramids*, and the interlocking of the bundles at their lower part across the ventro-median fissure (constituting the above-mentioned criss-cross) is called the *decussation of the pyramids*. At the outer side of each pyramid is a cleft, the *ventro-lateral fissure*, which is in line with the series of origins of the ventral roots of the spinal nerves, and in its upper part gives exit to the hypoglossal.

On each side the oblongata presents a vertical mass, the *lateral column*, or *lateral tract*, which is apparently continuous below with the lateral column of the cord, and above is encroached upon at the front part by a large ovoid mass, the *olive* (olivary body, inferior olive), whose presence crowds the column backward, and compresses it into a small band. The olive and lateral column are separated from the ventral pyramid by the ventro-lateral fissure, and from the dorsal structure of the oblongata by the *dorso-lateral fissure*, in which is seen a series of root-bundles of cranial nerves, ranged in line with the dorsal roots of the spinal nerves.

The *dorsal surface* (Fig. 646) of the oblongata is wide above and narrow below, and may well be described as consisting of upper and lower halves.

The *lower half* is cylindrical and is marked in the middle line by the *dorso-median fissure*, which is continuous with the dorso-median fissure of the spinal cord. Between this and the dorso-lateral fissure is the *dorsal column*. An

upward extension of the *dorso-intermediate fissure* of the cord marks off near the middle line a small portion of this column, which is called the *fasciculus gracilis* ("slender bundle"), and is continuous with the dorso-mesial column of the cord (the tract of Goll). The remainder of the dorsal column is divided by a slight groove into two parts—that next to the dorso-intermediate fissure being the *fasciculus cuneatus* ("wedge-shaped bundle"), and that next to the dorso-lateral fissure the *fasciculus of Rolando*. The fasciculus cuneatus is traced downward into the dorso-lateral column of the cord (the tract of Burdach). The fasciculus of Rolando seems to have no representative in the cord, but begins at the lower end of the oblongata as a small bundle, increases in size from below upward, and blends with the fasciculus cuneatus at the upper end of the lower half of the oblongata, the union of the two fasciculi seeming to form the restis. This appearance, however, will presently be shown to be misleading. At the upper end

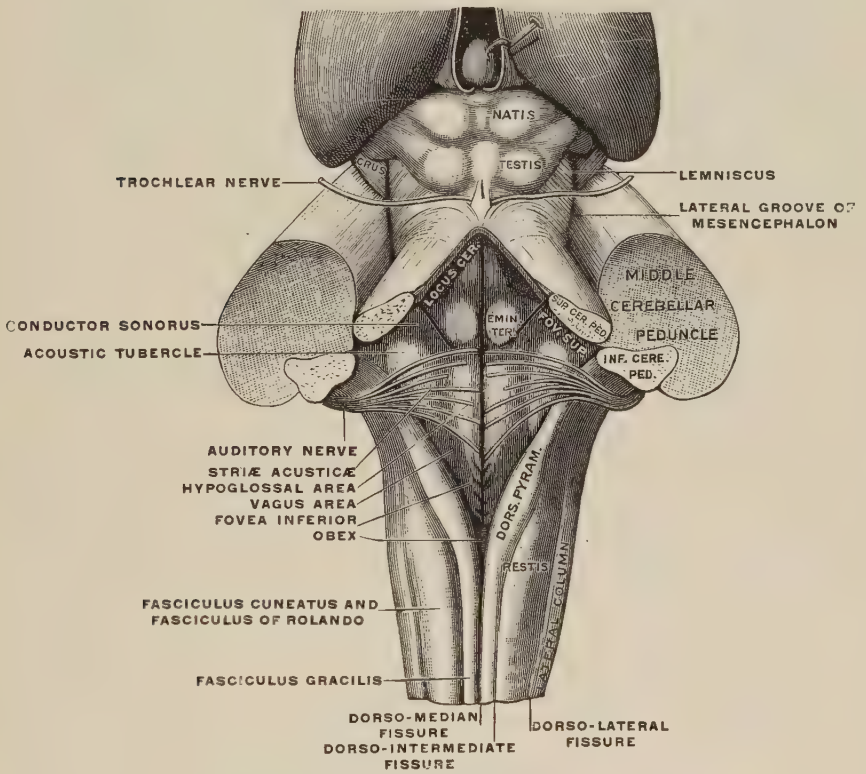

FIG. 646.—Fourth ventricle laid open by removal of its roof. (Testut.)

of the fasciculus of Rolando there is a slight swelling, the tubercle of Rolando, which contains the nucleus of Rolando. At about the junction of the upper and lower portions of the oblongata the fasciculi gracilis and cuneatus contain each a mass of gray, which is known as its nucleus. That of the former is called the *nucleus gracilis*, and corresponds to an enlargement known as the *clava* ("club"); that of the latter is named the *nucleus cuneatus*. The cavity of the lower half of the oblongata is tubular, like that of the cord into which it runs.

The *upper half* of the dorsal part of the oblongata presents lateral masses of nervous tissue, which diverge from a median point below, and are connected by a tela. At each side the edge of the nervous mass is formed by an upward prolongation of the fasciculus gracilis. This is largest below, in the region of the nucleus gracilis, and tapers to a point as it passes upward. It is named the *dorsal pyramid*. At the outer side of the dorsal pyramid is a column of white nervous material, the *restis* ("rope") or *restiform body*, which is traceable upward to the

cerebellum, forming the inferior peduncle. Although the gross appearance of the parts leads one to suppose that the restis is a direct upward continuation of the cuneate and Rolandic fasciculi, it is in reality composed of the arciform fibres (presently to be mentioned) and the direct cerebellar tract of the cord.

Emerging from the ventro-median and ventro-lateral fissures below the plane of the olive are bundles of white nervous tissue, which pass around the pyramid and the lower end of the olive, and enter into the composition of the restis. They are called the *arcuate* or *arciform fibres*. In front of the pyramid in this region is a little mass of gray, the *arciform nucleus*. The course of these fibres will be traced in connection with the study of the internal structure of the oblongata.

The dorsal pyramid and restis of each side together form a prominent ridge, and the two ridges, converging below, enclose a triangular space. Stretched across this space is a membrane, consisting of a ventral layer of endyma and a dorsal lamina of pia, the formerly intervening nervous tissue having completely disappeared. This membrane forms the principal part of the roof of the cavity of the metencephalon, and is called the *metatela* or *tela choroidea inferior*. From its ventral surface depend small clumps of blood-vessels, covered, of course, by endyma, and named the *choroid plexuses of the fourth ventricle*. Below its middle is a perforation—the *foramen of Magendie*, or *metapore*, through which the cerebro-spinal fluid mingles with the fluid in the serous cavity which surrounds the axis. In the embryo there is no other aperture of communication between the general ventricular cavity and the subarachnoid space; but, in the adult, at the extreme lateral angle of the metatela on each side is an opening, called the *foramen of Key and Retzius*, which results from the disappearance of the thin wall over a minute area. In connection with the membrane should be mentioned the *obex* ("bar"), a small layer of gray substance, which is stretched across the very apex of the triangle; and the *ligula* ("little tongue"), a small irregular lamina of white nervous tissue, which projects slightly over the membrane from each lateral border. Both of these structures are rudimentary.

If the membrane is removed, the cavity of the fourth ventricle is exposed, and we see the part of its floor which is directly continuous with the portion provided by the pons. The space presents a triangle, whose base is applied to that of the pons. The apex of the triangle has been likened to the nib of a pen, and, consequently, is referred to as the *calamus scriptorius* ("the writing pen"). The median cleft of the pons is continued down through the oblongata, and on each side of it are arranged from within outward three somewhat triangular areas—the internal white (the *hypoglossal area*), the middle gray (the *vagus area*), and the external white (the *auditory area*)—the first and third standing in relief. Running from the mid-line outward is a variable number of nervous threads, *striæ acusticæ* ("auditory stripes"), which turn around the restes, and end in the auditory nerve.

Internal Structure of the Oblongata.

Transverse sections of the oblongata at different levels show marked variations in the disposition of its constituent elements. It is manifest that the outline of these sections will be strikingly different, for, as we know, the uppermost portion is spread out laterally, while the lowest is bunched together into a compact cylinder. The change in the arrangement of the included parts follows this general trend, and is shown particularly well in the case of the gray masses—these being small and dispersed in the higher levels, and being gradually gathered together as they are traced downward, until they are united into a single, coherent mass of definite form, like the gray of the cord.

This arrangement of the gray and the events which lead to it will be most readily understood by studying transverse sections, beginning with the lowest and proceeding systematically upward. It will be seen that there is an addition of nuclei, and a breaking up and dispersion of the gray mass of the lowest level, and that the scattering is caused by the oblique crossing from one side to the

other of motor and sensory bundles. In these figures the motor nuclei are colored red, the sensory blue. The area of each section is divided into three parts, corresponding respectively to the ventral, lateral, and dorsal tracts of the surface, these being separated by the bundles of fibres of the nerves which have their origin in the oblongata—the hypoglossal between the ventral and lateral, the others between the lateral and dorsal, the first spinal presenting in both places at the lower end.

A cross-section made at the lowest level (Fig. 647) is practically identical in appearance with one at the uppermost plane of the cord. Above this the sections

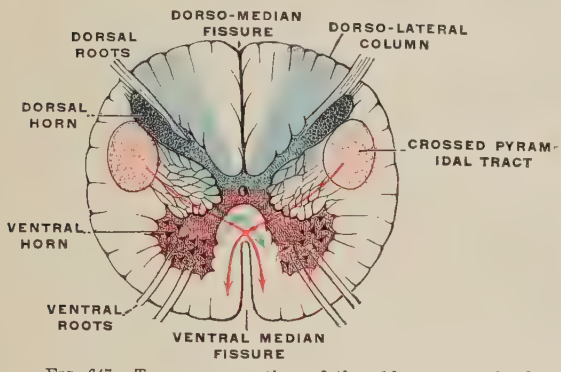

FIG. 647.—Transverse section of the oblongata at its lower end. (Testut.)

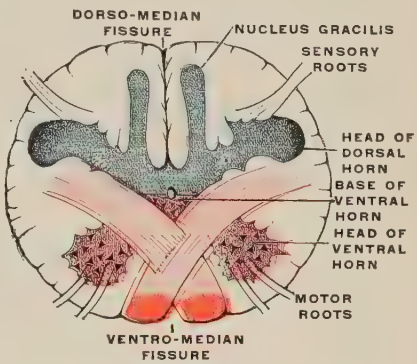

FIG. 648.—Transverse section of oblongata at the decussation of the pyramids. (Testut, after Duval.)

show a progressively increasing area, and a change from the nearly circular outline to the shield-shape.

At the decussation of the pyramids (Fig. 648) several features are altered. Each crossed pyramidal tract, instead of continuing upward, runs over the median line nearly horizontally to the ventral pyramid of the opposite side, crowding the direct pyramidal tract laterally. In its passage from one side to the other it amputates the head of the ventral horn. The dorsal horn is bulkier, and is more turned to the side. From the base of the dorsal horn projects backward a long process of gray—the nucleus gracilis. The dorso-median fissure remains as in

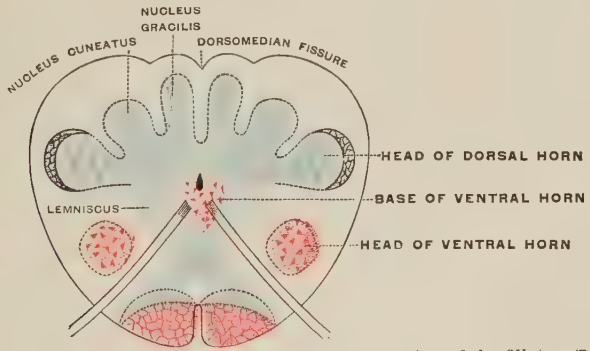

FIG. 649.—Transverse section of oblongata at the crossing of the fillets. (Testut.)

the myelon; the ventro-median loses most of its depth on account of its becoming occupied by the decussation. Nerve-roots are given off from the heads of both horns.

Above the plane of the decussation of the pyramids (Fig. 649) appears a new gray mass on each side—the nucleus cuneatus—placed lateral of the nucleus gracilis, and connected with the dorsal horn. From these two nuclei bundles

of fibres (the lemniscus or fillet) run ventro-mesially, cross the middle line, and, reaching the back of the pyramid, turn upward behind it. By the passage of these bundles the dorsal horns are decapitated, just as the ventral horns were cut off by the crossed pyramidal tracts. This constitutes the *sensory decussation*, called also the crossing of the fillets. The roots of the hypoglossal nerve are seen springing from the base of the ventral horn.

At the lower end of the olives (Fig. 650) the motor root of the vagus, as well as that of the hypoglossal, nerve is seen starting from the base of the ventral

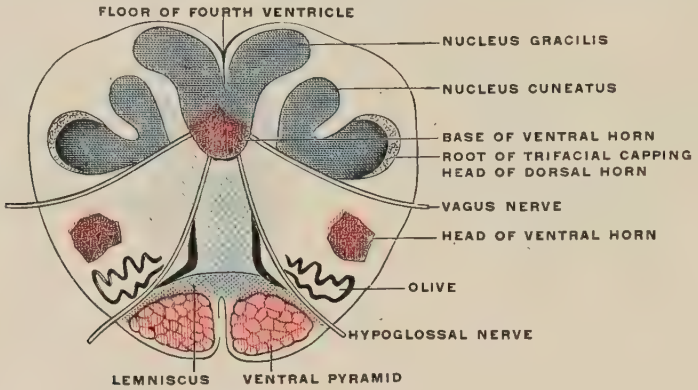

FIG. 650.—Transverse section of the oblongata at the lower end of the olives. The roof of the fourth ventricle is not represented. (Testut, after Duval.)

horn. The nucleus gracilis is larger, curves outward, and gets near the surface. The gray of the olive is arranged in a crinkled line, nearly surrounding an inner part or core of white. Its toothed appearance has led to its being called the *dentate nucleus*. An accessory olivary nucleus appears between the lemniscus and the hypoglossal nerve. The central canal has been replaced by a shallow

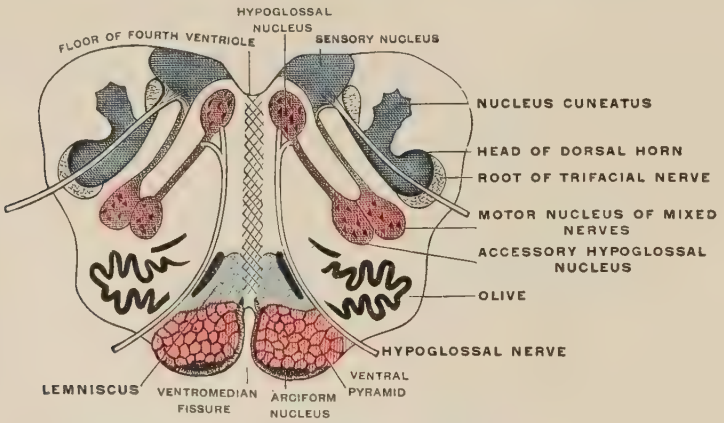

FIG. 651.—Transverse section of the oblongata at the middle of the olives. The roof of the fourth ventricle is not represented. (Testut, after Duval.)

cavity at the back of the oblongata, due to the spreading apart of the dorsal columns.

Half way up the olives (Fig. 651) a section displays the widening fourth ventricle at the rear; the nucleus gracilis and the base of the dorsal horn appear together in the floor of the ventricle as the sensory nucleus of the vagus and other nerves; the base of the ventral horn becomes the hypoglossal nucleus, which is connected with the head of this horn, here known as the accessory hypoglossal nucleus and nucleus ambiguus, the motor centre of certain mixed nerves;

the nucleus cuneatus is still connected with the dorsal horn, and the latter (as in two former sections) is capped by the ascending (sensory) root of the trifacial nerve; the olive is larger, and has a second accessory nucleus close to it at the rear; the ventral pyramid and lemniscus are larger; and between the vagus nucleus and the cuneate is a bundle called the solitary fasciculus. In front of the pyramid is the arciform nucleus.

Above the pyramidal decussation there is a ventro-dorsal raphe, composed of nerve-fibres and nerve-cells, the fibres running fore and aft, up and down, and obliquely.

In the ventral area are a little gray and a great deal of white, the latter being mostly the pyramids and the lemniscus. In the lateral and dorsal areas, besides the distinct nuclei, is a mixture of gray and white nervous matter, the *formatio reticularis* ("network formation"), sometimes called the tegmentum of the oblongata. This peculiar arrangement is largely caused by the crossing of the bundles which amputate the heads of the ventral and dorsal horns. The bundles are so loose that their component fibres insinuate themselves among the cells of the horns, and thus effect an intimate mingling, as the name implies. Besides these horizontal fibres others are found running lengthwise of the oblongata—many being derived from the association tracts of the cord, passing upward into the epencephalon and mesencephalon. The origin of others is not clearly made out. Finally, there are fibres, known as *arciform* or *arcuate*, which run backward and enter into the formation of the restis. Some of these fibres, the *internal*, come from the opposite side, cross the raphe, and pass in different directions. Certain of them are derived from the olive of the opposite side, enter the olive through the gap in the gray, run thence to the restis, and through it reach the cerebellum. Other fibres, the *external*, have a similar origin, but leave the olive, and get to the surface by way of the ventro-median fissure or by piercing the gray and white walls of the olive, and then course backward around the surface of the ventral pyramid and the adjacent olive to the restis. Some of the internal arciform fibres pass directly to the restis, and others to the nuclei gracilis and cuneatus.

At several points in the description of the lower segments of the brain, it has been necessary to refer to the lemniscus or fillet, but a complete account of its course could not be appreciated until the structures of which it formed a part were measurably understood. Now, however, it may be considered with profit.

The Lemniscus.

The lemniscus ("the fillet") (Figs. 646, 649–651) is a band of white nervous material, extending from the middle horizontal plane of the oblongata to the level of the quadrigemina. Its principal portion originates in the nuclei gracilis and cuneatus, which are situated in the dorsal part of the oblongata, and are the terminal stations of the funiculi gracilis and cuneatus, which are the upward prolongations of the dorsal tracts of the cord. It begins by running nearly horizontally forward and inward across the middle line of the oblongata, decussating with its opposite fellow above the plane of the pyramidal decussation, and reaching the dorsal surface of the pyramid. At this point it bends upward, and courses along close to the pyramid, being joined in this region by the fibres of the ascending lateral tract (Gowers) of the cord, which has come up through the lateral tract of the oblongata and the nucleus of Rolando. Thus it is seen that the lemniscus embraces all of the sensory fibres which pass from the cord to the cerebrum.

Passing into the pons, the lemniscus occupies the ventral stratum of the dorsal part, enters the mesencephalon, where a portion appears on the surface of the tegmentum, and almost all of it courses dorso-ventrally through this segment of the brain to the subthalamic region. There its fibres divide into two sets, one of which runs through the dorsal limb of the internal capsule, and thence passes to the cortex of the central area; while the second set, of greater size, enters the

thalamus, and ends there in arborizations around the cells—from which last, however, other fibres run to the gyri around the central fissure, like the first group. The essential difference between the two sets is that one goes directly, the other through a thalamic interruption, to the sensori-motor area of the cerebral cortex.

The Fourth Ventricle.

We have now studied separately the various structures enclosing the part of the encephalic cavity which is known as the fourth ventricle, sometimes called the *metepicele*, and it will be well to consider them in their natural connections as the continuous walls of this chamber.

The upper, wide-spread portion of the fourth ventricle (that part which is usually thought of when the ventricle is named) is nearly rhomboidal or lozenge-shaped. It presents a ventral part, called the *floor*; a dorsal part, the *roof*; an upper or anterior angle, a lower or posterior, and two lateral *angles*. The upper or anterior *sides* are formed by the superior cerebellar peduncles, the lower or posterior sides by the inferior cerebellar peduncles, all of which overlap the floor a little.

The Floor (Fig. 646).—The upper portion of the floor is furnished by the pons, the lower by the oblongata. In its whole extent the floor is cleft longitudinally by a median fissure, and a description of one half answers perfectly for the other.

In the Pontile Portion.—Sloping down from the upper angle, parallel with and close to the superior peduncle is a strip of bluish hue, the *locus ceruleus*. In

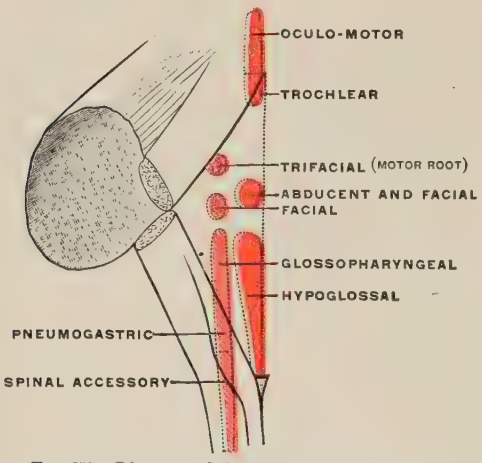

FIG. 652.—Diagram of the motor nuclei in and near the floor of the fourth ventricle. Only the left half of the ventricle is shown. (Testut.)

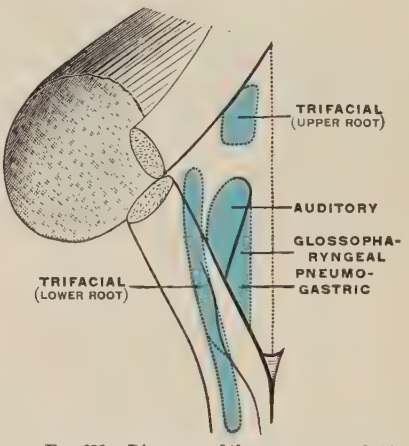

FIG. 653.—Diagram of the sensory nuclei in the floor of the fourth ventricle. Only the left half of the ventricle is shown. (Testut.)

line with this and below it at the lateral angle is a shallow depression, the *fovea superior*. Between the fovea and the middle line is a white tubercle, the *eminentia teres*.

In the Oblongatal Portion.—Below the eminentia teres and, like it, close to the median cleft, is another and larger white projection, forming a triangular ridge which extends nearly to the lower angle. It is the *hypoglossal area*. At the outer side of the last is the pneumogastric or *vagus area*, a gray, somewhat triangular space, the lowest part of which is slightly depressed, and is called the *fovea inferior*. Between the vagus area and the lateral angle is a white elevation, the *auditory area*, whose upper part is called the *acoustic tubercle*. Large white threads, the *striæ acusticæ*, pass outward from the mid-line, and are gathered into a bundle beneath the projecting restis, forming a root of the auditory nerve. At the lower angle is the *obex*.

The Roof (Fig. 639).—The roof is formed above by the *valvula*, which stretches between the superior peduncles; below by the *metatela*, which spans the space between the inferior peduncles. The lower edge of the valvula is continued downward and backward into a thin white layer, derived from the centre of the cerebellar vermis; and the upper border of the metatela is continuous with the pia and endyma, respectively covering and lining a similar layer which runs downward and backward from the white of the vermis. Thus, the roof is farthest from the floor, and forms a *tent*, at the point where these cerebellar laminæ separate—the one to go up (forward) to the valvula, the other to go down (backward) to end by a free edge of nervous tissue, from which the roof is continued by a membrane of vascular and serous tissues. In the centre of this membrane is an aperture, the *metapore*, or foramen of Magendie, and at each lateral angle an opening, the foramen of Key and Retzius.

It is interesting and very important to observe (Figs. 652, 653) how large a part of the cranial nerves have their deep (real) origin in and close to the floor of the fourth ventricle. This matter will be treated in connection with the description of these nerves in the succeeding chapter.

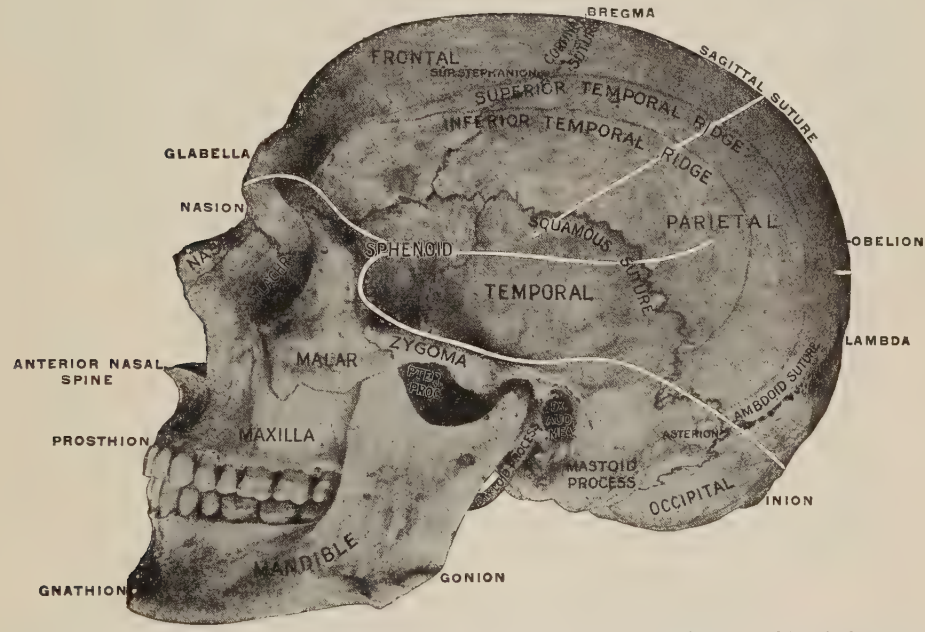

FIG. 654.—The relations of the principal fissures and of the lower borders of the cerebral hemisphere to the surface of the skull. The fissures and borders are not labelled, as the Sylvian, central, and parieto-occipital fissures cannot be mistaken. The inferior line does not show the lowest level reached by the temporal and occipital lobes, but the lowest parts of them that come close to the skull.

The lower portion of the fourth ventricle (that below the lozenge-shaped part) is tubular, and resembles the central canal of the myelon.

The *average weight* of the normal adult encephalon is in the region of 49 ounces for the male, and about 5 ounces less for the female.

THE SPINAL CORD (THE MYELON).

The *spinal cord* (Fig. 655) is the terminal portion of the cerebro-spinal axis, and is a direct continuation of the oblongata, having its upper limit at the lowest level of the pyramidal decussation. It is contained in the canal of the vertebral column. Like all other parts of the axis, it is bilaterally symmetrical. From it are given off almost all of the nerves which supply the voluntary muscles of the parts below the head, and to it go the sensory nerves of the corresponding regions.

Its *shape* approaches the cylindrical. It is slightly flattened ventro-dorsally, tapers at its caudal end, and presents a fusiform swelling in the cervical region, and another in the thoracico-lumbar region. The *cervical enlargement* extends from the third cervical vertebra to the second thoracic, and corresponds to the origin of the nerves of the upper limbs. The *lumbar enlargement*, which marks the origin of the nerves of the lower limbs, begins at the ninth thoracic vertebra, attains its greatest size at the twelfth, and thence rapidly dwindles in a *terminal cone*, from the apex of which extends a delicate prolongation, the *filum terminale* ("the end thread"), whose upper part presents the essential histologic elements of the cord (Fig. 656). It is customary, however, to regard the tip of the cone as the distal end of the spinal cord, as the filum is plainly only a rudimentary structure.

The cord presents two curves, which correspond to those of the parts of the column which it occupies: a *cervical curve*, with its convexity forward, and a *thoracic curve*, with its concavity forward. The cord proper extends from the plane of the occipito-atloid joint to that of the body of the second lumbar



FIG. 655.—Spinal cord, oblongata, and pons. Left-hand figure is ventral view, right-hand is dorsal. (Testut.)

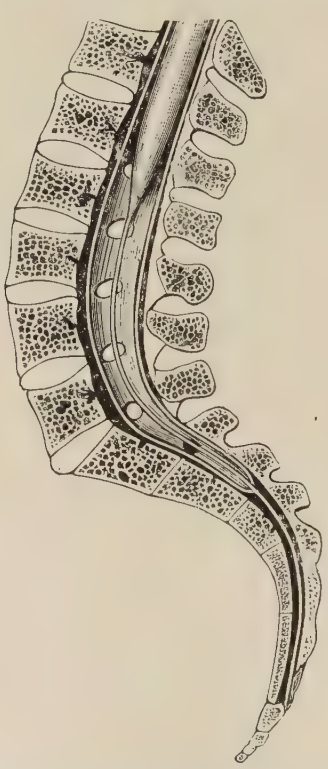

FIG. 656.—Sagittal section of the spinal canal, showing the lower end of the cord and the filum terminale. The dura is seen extending to the third sacral vertebra. (Testut.)

vertebra, and the filum continues from this point to the base of the coccyx. The *length* of the cord proper is about eighteen inches, its *transverse diameter* one-half inch or less, and its *weight* nearly an ounce.

Fissures and Columns.—As has been seen, the oblongata at its lowest part is composed of a collection of gray nervous tissue enclosed by a mass of white. This arrangement obtains in the entire length of the spinal cord—the gray is central, the white is peripheral. External inspection of the cord shows upon its surface a number of creases, running from end to end. In the middle line in front is a deep cleft—the *ventral* or *ventro-median fissure*; in the middle line behind a shallow one—the *dorsal* or *dorso-median fissure*; at each side of the latter, nearly a quarter of the way around to the front, is a shallow *dorso-lateral fissure*; and between the dorso-lateral and the dorso-median, and much nearer the latter, is the *dorso-intermediate fissure*. The dorso-lateral fissures are occupied by the *dorsal roots* of the spinal nerves. The *ventral roots* of the spinal nerves come off on each side from a vertical strip of the surface which is about as far from the ventro-median fissure as the dorsal roots are from the dorso-median fissure. Thus, each lateral half of the white of the cord is divided into three parts: one between the ventro-median fissure and the ventral roots—the *ventral* (anterior) *column*; a second between the ventral roots and the dorsal roots—the *lateral column*; and a third between the dorsal roots (or dorso-lateral fissure) and the dorso-median fissure—the *dorsal* (posterior) *column*, which is subdivided by the dorso-intermediate fissure into the *dorso-lateral column*, and the *dorso-mesial column*.

The Gray Matter of the Cord (Fig. 657).—A transverse section of the cord shows a mass of gray nervous tissue, enclosed by the white. The gray of each

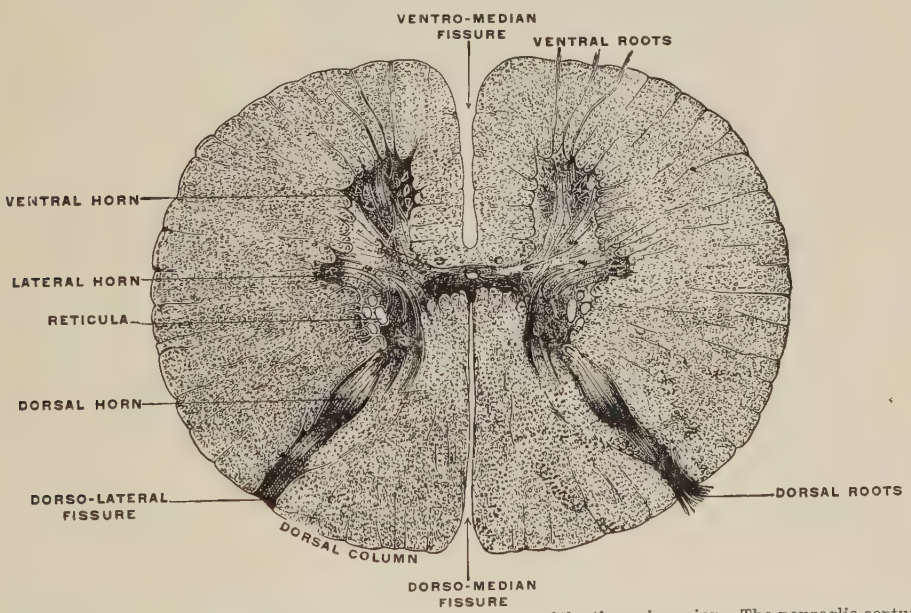

FIG. 657.—Transverse section of the spinal cord at the middle of the thoracic region. The neuroglia septum has been removed from between the dorsal columns. (Testut, after Pierret.)

side is somewhat crescentic in form, or the whole mass may perhaps be more aptly likened to two commas, one of which is reversed, the two placed back to back, and their convexities connected by a narrow band. The head of each comma is ventral, its tail dorsal. The two portions of each are called horns or *cornua*.[1] The *ventral horn* points forward and outward, but does not come nearly

[1] The term horn or cornu employed generally to designate a portion of the gray matter of the cord is strictly adapted only for use in the description of transverse sections; for it is manifest that the gray of the cord, equally with the white, is arranged in columnar masses. But, as practically we do not see the gray except in cross-sections, the word horn or cornu is sufficiently accurate and not misleading.

to the margin. The free end of it is the head, the attached part is the base. From the head project numerous spine-like processes; from the concave side of the base juts out a triangular mass—the *lateral horn*, which is most pronounced in the upper thoracic region. The *dorsal horn* is directed backward and outward, and quite or nearly reaches the periphery of the cord at the dorso-lateral fissure. It is divided into three parts: the base, which is continuous with that of the ventral horn; the head, which ends behind in a point, called the apex; and the neck, which connects the base and head. Near the hind part of the head is a crescentic portion, the *substantia gelatinosa* ("gelatinous substance"). From the concavity of the comma, at the base of the dorsal horn, projects a network of gray tissue, enclosing in its meshes little masses of white. This is the *processus reticularis* ("reticular process"), or *reticula*, and it is most marked in the upper cervical region. The base of the dorsal horn bulges toward the middle line of the cord, forming the *column of Clarke*, a structure found in the thoracic region and a little above and below it. The band connecting the two commas is the *gray commissure*, and it contains the *central canal of the spinal cord*, a minute channel, continuous with the fourth ventricle of the brain, from which it extends to the middle of the filum terminale. It is not patent in every part of its course.

The proportions of the gray and the white nervous material are not the same at any two levels of the cord, and the shapes of the two masses of tissue are subject to corresponding differences. Thus a part which is prominent in one plane is diminutive in another, and may be altogether lacking in a third.

The various fissures which have been mentioned are all seen to have little depth, excepting the ventro-median, which cuts far into the substance of the cord, and reaches almost to the gray commissure. Between the dorso-median fissure and the gray commissure is a septum of neuroglia, which separates the two dorsal columns from each other. The ventral and lateral columns are continuous around the head of the ventral horn, and, on this account, it is not uncommon to speak of them as a single structure—the *ventro-lateral column*. The two ventral columns are connected in their deepest parts by the *white commissure*, which is in contact with the gray commissure. These facts are shown diagrammatically in the left half of Fig. 658.

A knowledge of the obvious features which have been mentioned, while necessary for purposes of description, affords little practical help in the study of the physiology of the cord; and, consequently, it is essential to know the delimitations of the paths by which motor impulses and sensory impressions are conducted to and fro in this organ of intermediation between the highest centres of the cerebrum and the most distant areas of the periphery. To a large extent these paths have been ascertained, and will now be indicated. It will be seen that there is little in the gross appearance of the cord to give information as to the boundaries of these cables of telegraphic communication. The right half of the diagram (Fig. 658) will aid in the understanding of the few succeeding paragraphs.

The Conduction Paths of the Cord.—In the ventral column a narrow triangular area is marked off next to the ventro-median fissure. This is the *direct pyramidal tract*—"pyramidal," because it is a downward extension of a part of the pyramid of the oblongata; "direct," because this path is on the same side of the middle line in encephalon and in cord. It gradually diminishes in size from above downward, and disappears at the level of the root of the last lumbar nerve. The fibres of this tract begin in cells of the motor area of the cerebral cortex—that is, in the region of the central fissure. They pass through the corona radiata, the internal capsule, the crus, the pons, the ventral pyramid of the oblongata, here being crowded partly to the outer side by the decussation of the crossed pyramidal tracts, and partly to the rear behind the pyramid and olive, forming vertical bundles near the median line. In the cord they cross through the ventral white commissure to the ventral horn of the opposite side.

At the back part of the lateral column, close to the dorsal horn, is an oval area, the *crossed pyramidal tract*—"pyramidal," for the reason just given;

"crossed," on account of the decussation which occurs in the oblongata. It dwindles as it descends, and ceases at the third or fourth sacral nerve-root. Its constituents begin in cells of the motor area of the cerebral cortex, and follow a course similar to that of the direct pyramidal tract until the oblongata is reached. In the lower part of the ventral pyramid (to which it contributes three-fourths of the bulk) it decussates with its fellow opposite, crosses the median line obliquely backward, and descends in the lateral column of the cord, its fibres running thence to the ventral horn of the same side.

Between the outer side of the crossed pyramidal tract and the surface of the lateral column is the dorsal part of a long, narrow area, the *direct cerebellar tract*, so called because its fibres course upward through the oblongata as straight as

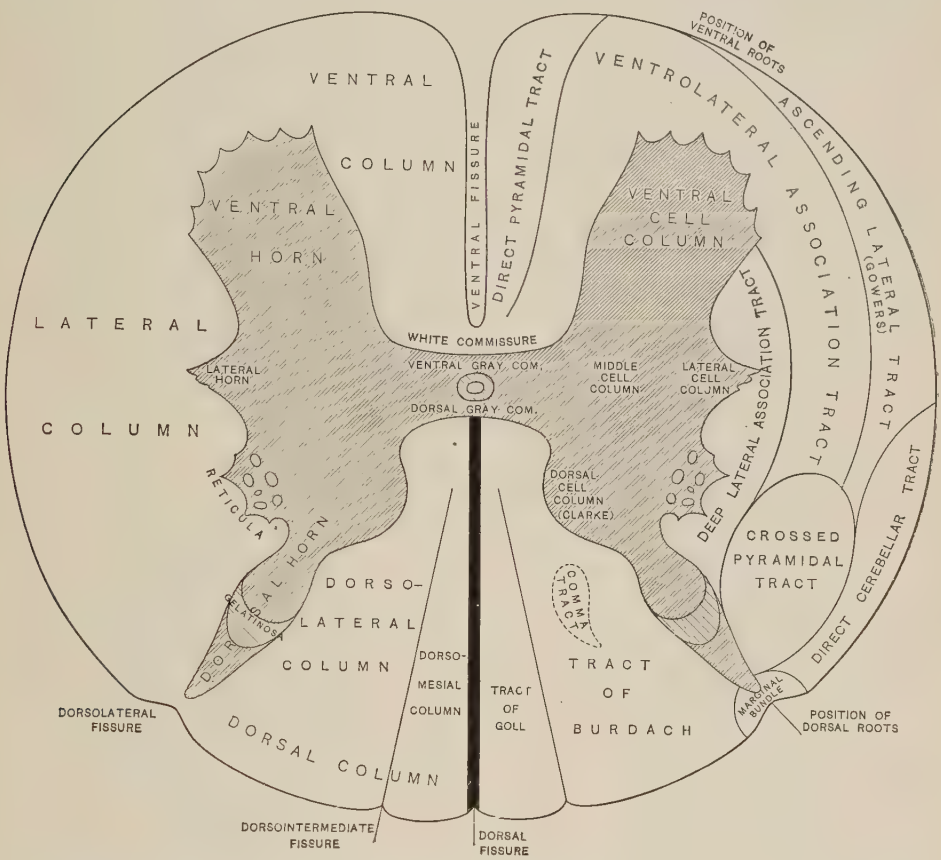

FIG. 658.—Diagrammatic ideal transverse section of the spinal cord. On the left side are shown the gross divisions; on the right side, the conduction paths. (F. H. G.)

possible to the cerebellum. It appears at the level of the eighth or ninth thoracic nerve-root, and progressively increases as it ascends. It begins in cells of Clarke's column, passes upward to and through the restis, and thence into the cerebellum.

Anterior to this is a somewhat triangular area, which extends to, perhaps beyond, the place of exit of the ventral roots, the *ascending lateral tract*, or the Gowers tract—named "ascending," from the direction in which it carries impressions; "lateral," from its position. It occupies the whole length of the cord, and increases in size from below upward. Its fibres originate in cells of the dorsal horn, cross to the opposite side in the ventral gray commissure, pass through the formatio reticularis of the oblongata and pons, and then go in two directions: some reach the cerebellum by way of the superior peduncles,

and the rest enter into the composition of the lemniscus. Mingled with the fibres of the ascending lateral tract are certain descending fibres from the cerebellum.

Lodged in the curve of the gray comma, and penetrated by the interlocking strands of the reticula, where the latter exists, is the *deep lateral association tract* (otherwise known as the mixed lateral). The first and second words in this title are self-explanatory; the third is chosen because it is descriptive of the function of the fibres composing this tract. These fibres originate in cells of the gray substance of the cord, run a short course, then turn into the gray, and end in arborizations around its cells. Thus, they act as longitudinal commissures, associating each part of the cord with parts a short distance above and below.

The remaining areas in the ventral and lateral columns are perfectly con-

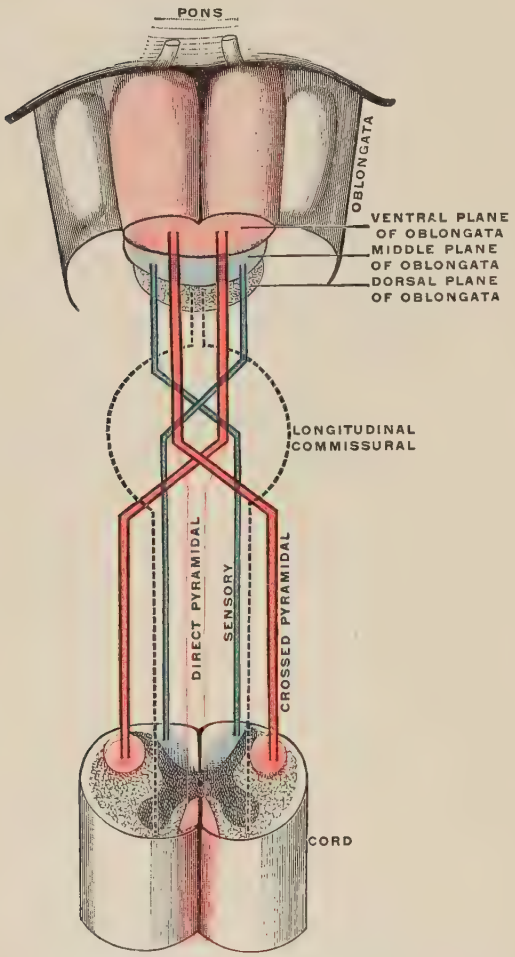

FIG. 659.—Diagram to show the crossing of the pyramids (red) and of the lemniscus (blue). (Testut.)

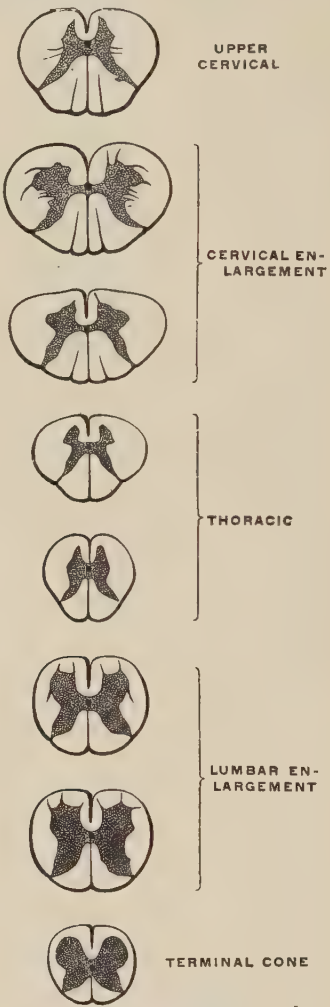

FIG. 660.—Transverse sections of the spinal cord at different levels. (Testut, after Erb.)

tinuous around the head of the ventral horn, except for the interruption occasioned by the passage of the ventral roots from the surface to the ventral horn. They are often called the fundamental tracts, or ground tracts of their respective columns; but a simpler and more instructive name is the *ventro-lateral association tract*—an appellation which indicates at once the location and the service of the structure, whose function is to connect parts of the cord situated at different

levels. They are longitudinally commissural. The association tracts are found in the whole length of the cord, and are subject to but slight variations of size.

In the dorsal column are two tracts, separated from each other by a line running from the dorso-intermediate fissure to a point near the junction of the neurogliar septum and the gray commissure. These tracts, then, correspond exactly to the dorso-mesial and the dorso-lateral columns, and are called respectively the *tract* (or column) *of Goll*, and the *tract* (or column) *of Burdach*. The Goll tract increases in size as it ascends; the Burdach tract varies but little from its average at different levels. The fibres of these two tracts begin in cells of the dorsal roots of the spinal nerves. Those in the tract of Goll pass upward and end in arborizations around the cells of the nucleus gracilis; those in the tract of Burdach terminate in the same way in the nucleus cuneatus. Excepting those in the upper portion of the tract, the fibres of Burdach drift into the tract of Goll.

Near the centre of the tract of Burdach in the cervical and thoracic regions is a small area, called from its shape the *comma tract*, and composed of fibres from the dorsal roots of the spinal nerves running downward to lower portions of the cord.

Finally, at the dorso-lateral fissure is a small irregular area, the *marginal bundle*, called also by the names of the men who simultaneously described it, the *Spitzka-Lissauer tract*. Its fibres are derived from the dorsal roots, and ascend to higher parts of the cord, where they end in the gray matter.

From what has been said it must be evident that the size and shape of the cord, and the absolute and relative amounts of white and gray matter vary greatly in different parts. This is shown pictorially in Fig. 660.

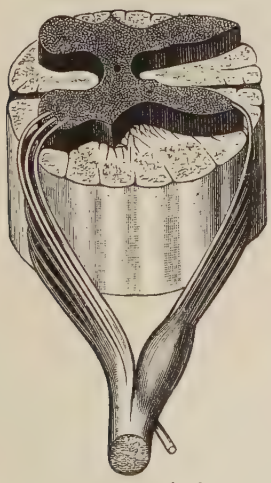

FIG. 661.—Formation of a spinal nerve. (Testut.)

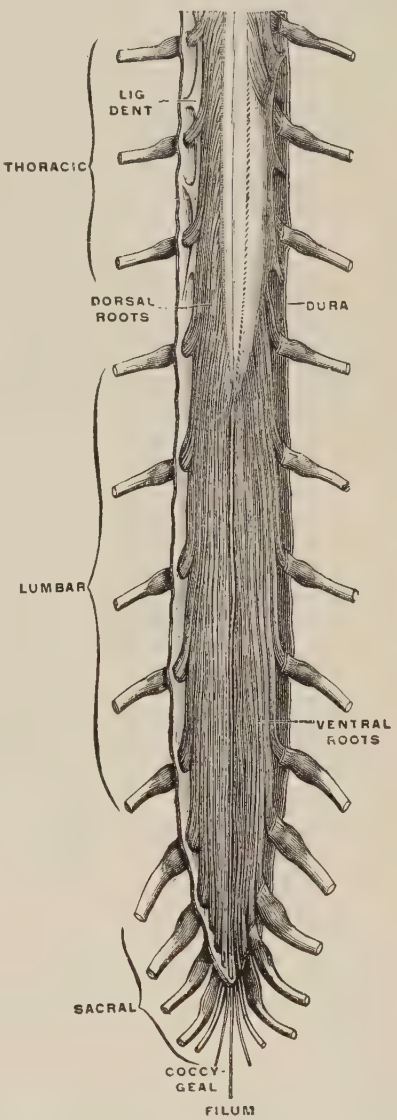

FIG. 662.—Lower end of the spinal cord and the cauda equina, dorsal aspect. The dorsal roots of the right side have been removed. (Testut.)

The Spinal Nerve-roots (Fig. 661).—The roots of the nerves which arise from the spinal cord are in two sets, dorsal and ventral. The *dorsal* leave the cord in a continuous series at the dorso-lateral fissure, the *ventral* along a narrow vertical strip of the surface nearest to the head of the ventral horn. At fairly regular intervals the roots in each series are bunched together, and then the fagot of the dorsal set is united to that of the ventral, the result being a single bundle, which is a *spinal nerve*. In this nerve the fibres from the two roots are intimately mingled, and thus the spinal nerves are *mixed nerves*. On the dorsal bundle of each nerve is a *ganglion*, situated at the distal part of the root and outside of the sheath of dura. The upper roots are short and horizontal, and those below these are progressively longer and more nearly perpendicular. The lowest come off from the tapering cone at the end of the cord proper, are very long, and perpendicular in direction. From its resemblance to a horse's tail the collection of these roots is called the *cauda equina* (Fig. 662).

THE MEMBRANES
of the Cerebro-spinal Axis.

The brain and spinal cord are enveloped in three membranes (*meninges*), of which the innermost is called the *pia*, the middle one the *arachnoid*, and the outermost the *dura*. Each of these is a covering for every part of the axis ; but they have such variations of structure and arrangement in different parts as to make it best to consider separately the membranes of the brain and those of the spinal cord.

The Membranes of the Brain.

The **Dura**, formerly called *dura mater* ("severe mother"), (*pachymeninx*), is a strong, thick membrane, composed of white fibrous tissue with a small admixture of yellow fibres, and lodging a great number of blood-vessels. It is arranged in two layers, which are closely united in most parts, the outer one being decidedly the more vascular. Externally the dura is firmly adherent to the inner surface of the bones which form the brain-case, and is for them the internal periosteum, known as *endocranium* ("within the cranium"). When the dura is peeled off from the bones its outer surface is seen to be flocculent, owing to the vessels which pass from it into the bone being pulled partly out of the channels in which they were lodged, and torn off, and to the similar treatment of certain small, fibrous processes of the membrane. Its inner surface is covered with epithelial cells, like those of a serous membrane. The endocranium is continuous with the pericranium at the margin of the various holes which perforate the skull. The dura extends outward through the basal foramina, and becomes continuous with the areolar sheath of the nerves which pass through them.

Several broad prolongations of the dura extend from the periphery toward the centre of the cavity of the brain-case. In their formation the inner layer of the dura separates from the outer along a definite line and projects centrally. Presently it comes in contact with a corresponding and opposite plate, which has been formed in the same manner, and the two blend, and, thus united, stretch toward the centre as a strong, partial partition. At the attached border of these shelf-like structures is left a prismoid space, whose base is bounded by the outer layer of the dura, and its sides by the prolongations from the inner layer. These spaces are lined by an extension from the tunica intima of the veins, and thus constitute the venous sinuses, already described.

The principal processes of the dura are the tentorium, the falx cerebri, and the falx cerebelli.

The **tentorium** ("tent") (Figs. 663, 664) springs from the borders of the superior petrosal and the horizontal part of the lateral sinuses. From this origin it rises toward the centre, and terminates in a free border, which extends forward and is attached on each side to the anterior and posterior clinoid processes. There

is thus left a large opening, in which is situated the mesencephalon. The tentorium is spread between the cerebellum and the occipital portion of the cerebrum, protecting the former from the superincumbent pressure of the latter.

The **falx cerebri** ("sickle of the brain") (Fig. 664) is so called from its shape. It is attached anteriorly to the crista galli, posteriorly to the median part of the upper surface of the tentorium, and for the rest of its extent to the ridges bounding the great longitudinal sinus. It dips into the great fissure between the hemispheres, deeply behind, and progressively less so as it is traced to the front. It thus forms a tightly stretched, median septum, which prevents the pressure of one

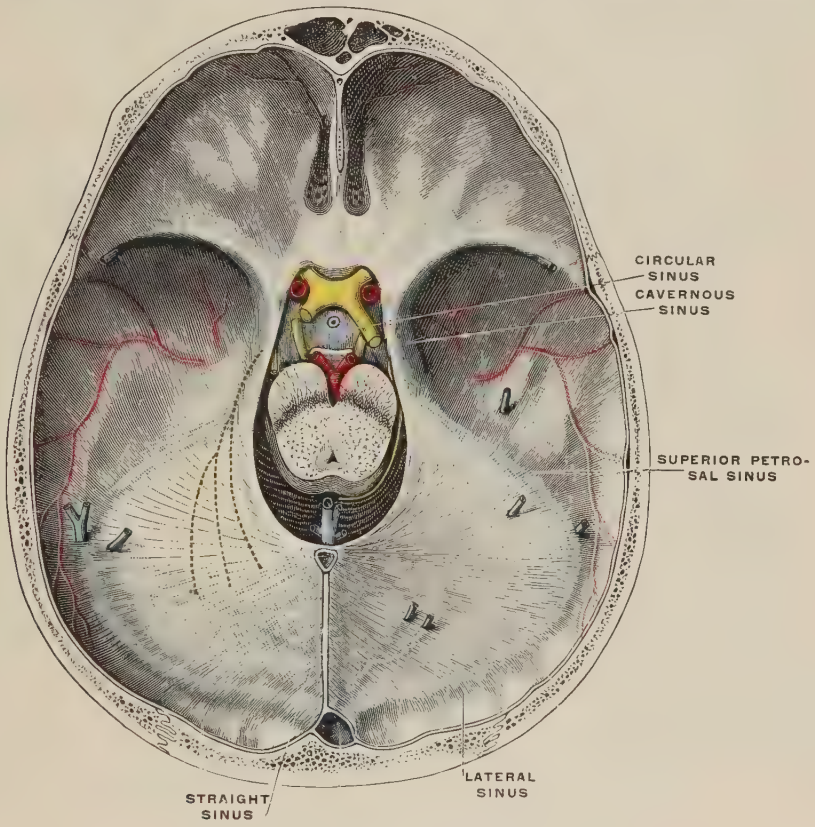

FIG. 663.—The tentorium, viewed from above. (Testut.)

hemisphere upon the other in the lateral movements of the head, just as the fore-and-aft partition in a vessel keeps the cargo from shifting from side to side in the lurchings of the craft at sea. The falx cerebri encloses the superior longitudinal sinus peripherally, the straight sinus in its tentorial attachment, and the inferior longitudinal sinus in its free border.

The **falx cerebelli** is a small median septum between the cerebellar hemispheres behind. It is broadest above, where it is attached to the under surface of the tentorium, and tapers rapidly as it descends. It encloses the occipital sinus in its posterior border.

Under the names of *diaphragm of the sella* and *tentorium of the hypophysis* a small double fold of the dura extends inward from all sides over the sella turcica, covering the hypophysis, and leaving a little aperture for the apex of the infundibulum. The presence of this fold accounts for the fact that the hypophysis is usually torn away when the brain is removed.

The arteries of the dura, called "meningeal," are branches of the occipital, vertebral, ascending pharyngeal, internal maxillary, internal carotid, and oph-

thalmic. Its nerves are derived from the trifacial, vagus, hypoglossal, and sympathetic.

The **Pia**, formerly called *pia mater* ("affectionate mother"), (*leptomeninx*), consists of blood-vessels arranged in the form of a membrane, and supported by areolar tissue. It is the nourishing tunic of the brain, and lies close to its surface everywhere, dipping down to the bottom of every fissure, and sending the branches of its arteries into the nervous substance. It is prolonged onto the roots of the nerves, and becomes continuous with their connective-tissue sheath. The velum interpositum and choroid plexuses, already described, are pial structures. The nerves of the pia are branches of the sympathetic, and the third, fifth, sixth, seventh, ninth, tenth, and eleventh cranial.

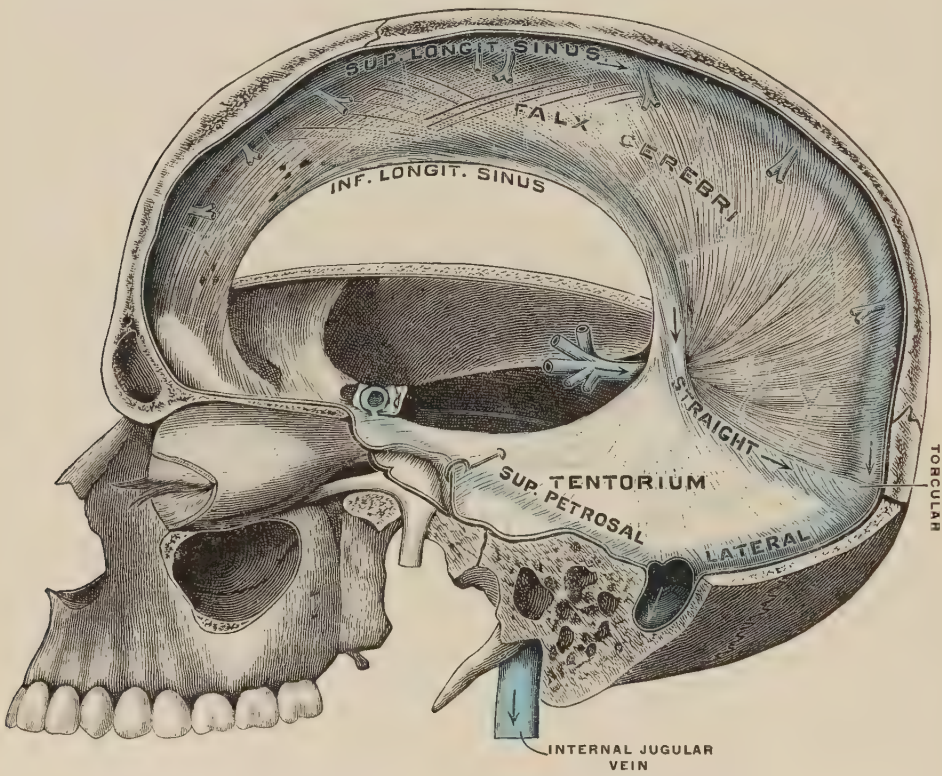

FIG. 664.—Falx cerebri and tentorium, left lateral view. (Testut.)

The **Arachnoid** ("like a spider's web") (Fig. 665) is a thin, delicate membrane, situated between the pia and the dura, much nearer the latter, and, for the most part, substantially parallel with it. It does not follow the pia into the fissures, except the great longitudinal. The external surface of the arachnoid is furnished with a single layer of flattened epithelial cells, which is continuous with the lamina of similar cells on the inner surface of the dura. Between them is a little serous fluid. Thus we have the elements of a serous membrane, and it is proper to consider the arachnoid such. The interval between the dura and the arachnoid is the *subdural space* or *arachnoid cavity*. It is crossed obliquely by little fibrous bundles, which connect the two membranes. The cavity is normally merely virtual, its opposite sides being in contact; but it may become actual in disease. The under surface of the arachnoid is connected with the outer surface of the pia by numberless trabeculæ of fibrous tissue, which form a delicate network. In some situations these are very abundant, in others much less so; but everywhere they are covered with flattened epithelial cells. The interval between the arachnoid and the pia is the *subarachnoid space*. It is

essentially lymphatic in character, and contains cerebro-spinal fluid. At certain places the subarachnoid space is quite deep, and the trabeculæ are comparatively few. Such enlargements are known as *cisternæ arachnoidales* ("arachnoid reservoirs"). The metapore (foramen of Magendie) in the roof of the fourth ventricle, and the openings in the lateral recesses, permit a communication between the ventricular cavity and the subarachnoid space. At irregular intervals, principally near the longitudinal sinus, the arachnoid buds out into tufts, which press upon the structures peripheral to themselves, and even produce marked pits in the inner table of the bones. These bodies are called *glandulæ Pacchionii*

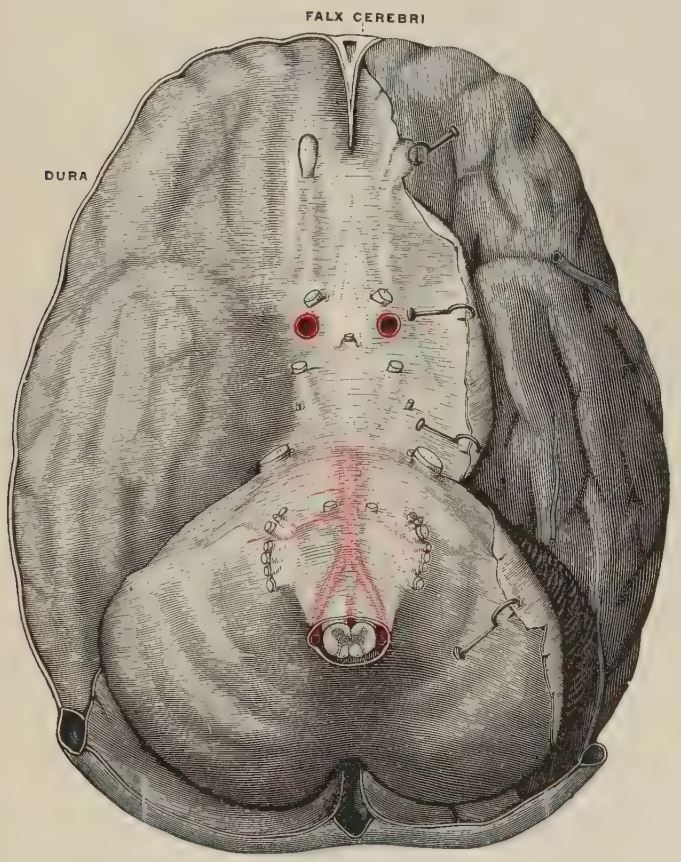

FIG. 665.—The arachnoid at the base of the brain. The membrane has been peeled off from the left hemisphere. (Testut.)

("little glands of Pacchioni"). Sometimes they contain minute hard particles, called *brain-sand*.

The Membranes of the Spinal Cord.

In considering the meninges which enclose the cord it will be sufficient to indicate the characteristics in which they are unlike the corresponding structures in the head.

The Dura.—The feature in which the dura of the cord differs most strikingly from that of the brain is in its not being the internal periosteum of the bones of the cavity in which it is contained. Each of the segments of the vertebral column has its own periosteum. The dura is reflected from the brain-case at the margin of the foramen magnum, and below this hangs as a long tube (*theca*, "case") between the periphery of the spinal canal and the surface of the spinal cord,

having attachments to the upper three cervical vertebræ and low down to the posterior common ligament. Between the dura and the vertebræ is the *epidural* ("upon the dura") *space* occupied by areolar tissue, in whose meshes are many fat-cells and a plexus of spinal veins. The outer, as well as the inner surface, is furnished with a single layer of epithelial cells.

The **Pia** is more fibrous and less vascular than that of the encephalon. From each side extends a long ribbon of connective tissue, the outer edge of which is marked by long, shallow notches

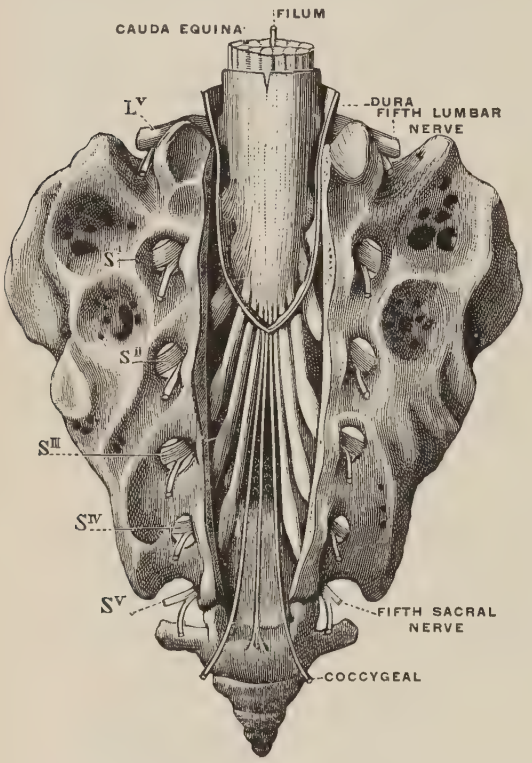

FIG. 666.—Pouch at lower end of spinal dura, and the sacral nerves. (Testut.)

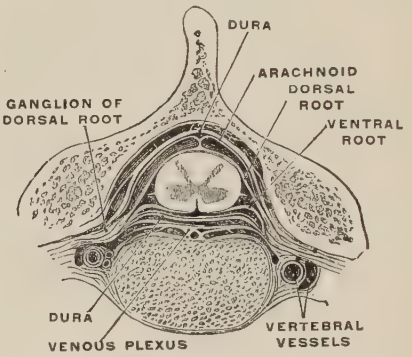

FIG. 667.—Horizontal section of vertebral column, showing spinal cord and its membranes. (Gegenbaur.)

and intervening sharp projections. From the appearance thus produced this structure has been called the *ligamentum denticulatum* ("toothed ligament"). The projections are attached to the dura between the places where the spinal nerves perforate that membrane.

The **Arachnoid** lies near the dura and far from the cord, and, consequently, the subdural space is small and the subarachnoid is large. The latter space has few trabeculæ as compared with the subarachnoid of the brain; but a dorsal median partition, the *septum posterius*, passes from the arachnoid to the pia, giving passage to vessels. The space is crossed also by the ligamenta denticulata.

THE NERVES.

By W. KEILLER.

IN this chapter will be described, first, the nerves which connect the brain and spinal cord with the skin, muscles, and viscera, and the nuclei in which these nerves take origin; and, second, the sympathetic system. The mode in which the nerves end in skin, muscles, and other organs is dealt with in the chapter on histology, or in the sections of the work describing the organs themselves.

THE CEREBRO-SPINAL NERVES.

The *cerebro-spinal nerves* are those which spring directly from the brain or spinal cord. Those which pass to their destination through foramina in the base of the skull are called *cranial nerves*. The rest are called *spinal nerves*, as they spring from the sides of the spinal cord and emerge through the intervertebral foramina, excepting the last spinal or coccygeal nerve, which passes through the lower extremity of the neural canal. The first spinal nerve, however, is somewhat exceptional, arising from the oblongata, and emerging from the neural canal between the occipital bone and the atlas. All these nerves are paired and symmetrically distributed, the apparent asymmetry of the vagus being due to developmental changes. As the nerves leave the brain or cord and pierce the membranes, they receive investments from the pia, arachnoid, and dura, which blend with the epi- and perineurium; but fluid, injected forcibly into the subarachnoid or subdural space, will find its way readily along the nerves for some distance. In the case of the optic nerve each sheath remains distinct as far as the eyeball.

Typical Constitution of a Cerebro-spinal Nerve.—All spinal nerves and most cranial nerves are mixed; that is, are both motor and sensory in function, the function of each fibre depending on its mode of origin and termination; and, since cranial nerves, though sometimes obscurely, follow the same plan of formation as spinal nerves, we shall take the latter as the type for study.

The diagrammatic representation of a spinal nerve in Fig. 668 shows that it arises by two roots from the spinal cord. The dorsal root is sensory, has a ganglion on it, and springs by one compact bundle from the dorsal horn of gray matter and dorso-lateral aspect of the cord. The ventral root is motor, has no ganglion, and springs by several bundles from the ventral horn of gray matter and the ventral aspect of the cord. The points by which these several bundles leave the cord form collectively the *superficial origin* of the nerve. Each fibre of the motor root is the axis-cylinder process of one of the nerve-cells of the ventral horn of gray matter, the finer branching processes of this cell connecting it with higher centres. While the nerve-cell lives, the fibre lives; when the cell dies the fibre dies. These cells of the ventral horn form collectively the *deep* or *nuclear origin* of the motor root, which their axis-cylinder processes unite to form.

The *ganglion* on the dorsal root contains the cells whose axis-cylinder processes form the sensory segment of the nerve. Though separated from the spinal

cord in the adult, it is an outgrowth from it in the embryo. The cells of this ganglion are bipolar, sending one process centrifugally into the nerve-trunk, and the other centripetally into the spinal cord. The latter bifurcates, one branch

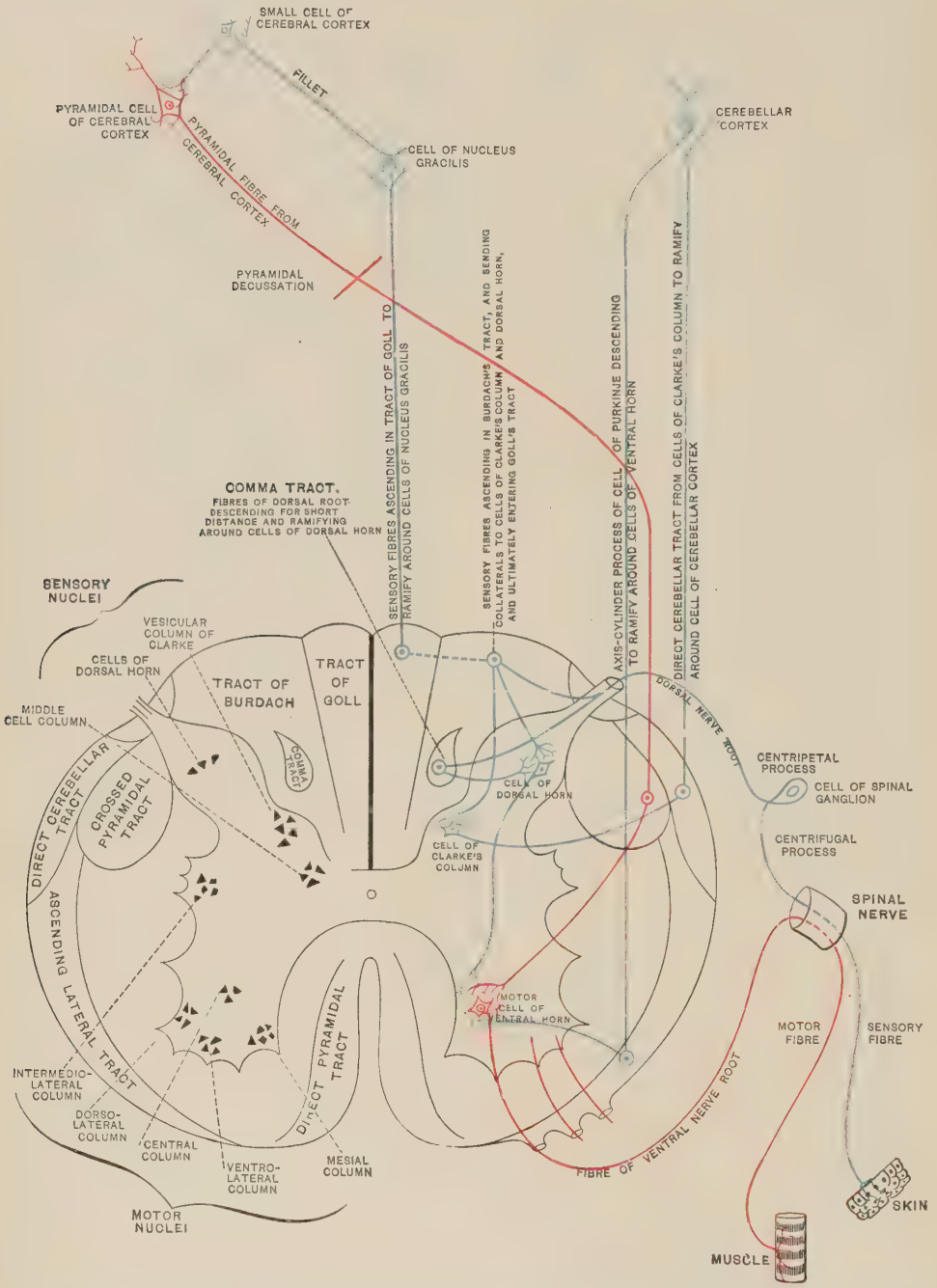

FIG. 668.—Diagram to explain the formation and connections of a spinal nerve. Motor tracts are red, sensory, blue. A circle with a central dot indicates where the nerve takes a vertical direction. (W. Keiller.)

descending in the cord to enter into relationship with the cells of the dorsal horn of gray matter, and the other ascending to form branching processes round the

cells of Clarke's column, and of the nucleus gracilis and nucleus cuneatus in the oblongata, and others which need not be mentioned.

Thus a dorsal nerve-root is related to two groups of cells, viz., those of its ganglion and a number of widely scattered cells of the gray matter of the spinal cord and oblongata. The ganglion is homologous with the Gasserian ganglion on the fifth cranial nerve, the jugular ganglion on the ninth, the ganglia of the tenth, and the nerve-cells of the olfactory bulb, retina, and spiral ganglion of the cochlea; and the cells of the dorsal horn of gray matter, with which the sensory fibres are related, collectively represent what are described as the *sensory nuclei* of the cranial nerves.

The mixed cranial nerves, such as the fifth, ninth, and tenth, follow this type very closely; the third, fourth, sixth, seventh, eleventh, and twelfth are purely motor nerves, and correspond developmentally with the motor root of a spinal nerve; while the first, second, and eighth are purely sensory, and are constituted like the sensory root of a spinal nerve.

THE CRANIAL NERVES.

The *classification of the cranial nerves* into twelve pairs is based upon their mode of distribution. It was proposed by Sœmmering, and is now generally adopted, in preference to the older classification of Willis into nine pairs, which had reference to their mode of piercing the dura. The following table gives at a glance the numerical and the ordinary name of each nerve, and a summary of its function and area of distribution.

Table of the Cranial Nerves.

Classification of Sœmmering.	Other Names.	Distribution.	Function.
First.	Olfactory.	Upper third of nasal cavity.	SPECIAL SENSE (Smell).
Second.	Optic.	Retina.	SPECIAL SENSE (Sight).
Third.	Oculomotor.	Muscles of eyeball (except external rectus and superior oblique).	MOTOR.
Fourth.	Trochlear.	Superior oblique of eyeball.	MOTOR.
Fifth.	Trifacial.	*Sensory part* to face, fore part of scalp, external ear, eye, teeth, gums, cheek, fore part of tongue. *Motor part* to muscles of mastication.	*ORDINARY SENSE.* MOTOR.
Sixth.	Abducent.	External rectus of eyeball.	MOTOR.
Seventh.	Facial.	Superficial muscles of face, frontalis, platysma, stylohyoid, and posterior belly of digastric.	MOTOR.
Eighth.	Auditory.	Membranous labyrinth of ear.	SPECIAL SENSE (Hearing and Equilibrium).
Ninth.	Glossopharyngeal.	Pharynx and hind part of tongue, some motor fibres.	SPECIAL SENSE (Taste). *ORDINARY SENSE.* MOTOR.
Tenth.	Vagus, or pneumogastric.	*Sensory* to external ear. *Motor* and *sensory* to pharynx, larynx, trachea, lungs, œsophagus, stomach, heart. Some fibres to liver.	*ORDINARY SENSE.* MOTOR.
Eleventh.	Spinal accessory.	Motor to trapezius and sternomastoid muscles. The rest is accessory to the pneumogastric.	MOTOR.
Twelfth.	Hypoglossal.	Muscles of the tongue.	MOTOR.

Superficial Origins (Fig. 669).—The cranial nerves spring from the under surface of the brain in the order of their names. Thus, the first appears in front of the anterior perforated spot; the second springs from the chiasma, the optic tracts being superficially traceable to the corpora quadrigemina; the third nerve arises from the inner side of the crus cerebri close to the pons; the fourth winds round

the outer side of the pons, and can be traced dorsally to the valvula, whence it emerges. The fifth arises by two bundles from the side of the pons, the smaller motor root being in front of and above the larger sensory root. The sixth springs from the groove between the pons and anterior pyramid, the seventh and eighth from the same groove but more laterally. A small bundle between the seventh and eighth, called the pars intermedia, furnishes an additional root to the seventh. The ninth, tenth, and eleventh arise as a series of small bundles from the side of the oblongata in a vertical line, dividing the restiform body from the olive and lateral column of the cord. The spinal portion of the spinal accessory emerges by numerous bundles from the side of the cord in a direct line with the rest of this group, extending as far down as the fifth, sixth, or even seventh cervical nerve. The twelfth nerve springs by ten or twelve small bundles from the groove between the olivary body and ventral pyramid, and thus lies ventral to the pre-

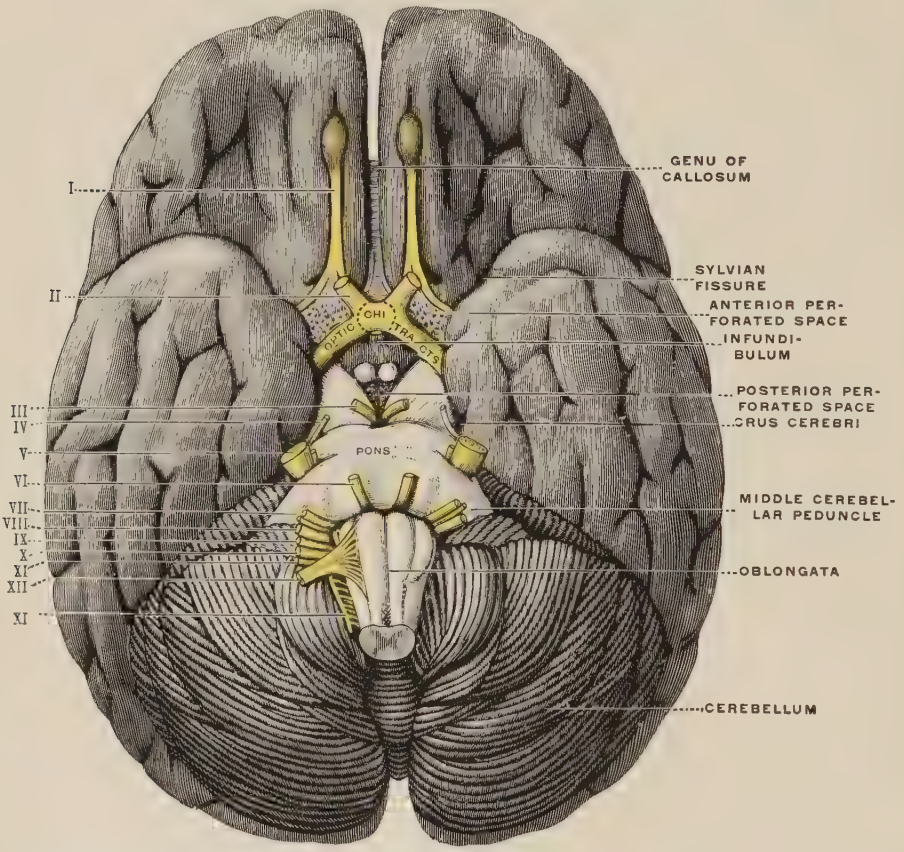

FIG. 669.—Under surface of the brain, showing the superficial origins of the cranial nerves. The Roman numerals indicate the nerves. (Testut.)

ceding series, and nearer the pons than the last of them. It lies in series with the ventral roots of the first spinal nerves.

Deep or Nuclear Origins of the Cranial Nerves.—Like the spinal nerves the cranial nerve-roots can be traced till they come into close relationship with certain groups of cells, which, for anatomical and physiological reasons, we regard as their deep origins. It is impossible for the student to study this subject till he has thoroughly mastered the anatomy of the brain and especially of the oblongata and pons; but, when he has learned the gross anatomy of the central nervous system, he will find much living interest in what is now known of this obscure but vitally important section.

Deep Origin of the First or Olfactory Nerve.—When we speak of the first or olfactory ("smelling") nerve, we usually mean the olfactory tract with its three roots and terminal bulb, and regard the twenty or more filaments, which spring from the bulb, as branches of the nerve. Embryology teaches us, however, that the tract is really a hollow outgrowth of the lateral ventricle, that the cells in the inferior segment of the bulb are homologous with the nucleus of a sensory nerve, and that the filaments which pierce the cribriform plate collectively represent the sensory nerve itself.

The **olfactory tract** is a flattened band which lies in the olfactory fissure on the orbital surface of the frontal lobe. On its under surface it is flat and lies on the olfactory groove of the sphenoid; superiorly it presents a ridge which fits into the olfactory fissure. Posteriorly it springs from the cerebral cortex in front of the anterior perforated space by three roots; anteriorly it ends in the olfactory bulb. Microscopically the tract presents on transverse section, (*a*) a thin, gray cortex, continuous with the cortex cerebri; (*b*) an inner layer of medullated nerve-fibres, thick inferiorly and thinning off above; and (*c*) some central gray substance consisting of neuroglia and fibrous tissue—the remains of the ependyma of the embryonic ventricular cavity, which in adult man is obliterated.

The **internal** or **mesial root** is a band of medullated nerve-fibres, running into the great longitudinal fissure, where it is lost in the anterior end of the callosal gyrus.

The **external** or **lateral root**, larger than the internal, is a white band which crosses backward and outward over the anterior perforated space toward the extremity of the temporal lobe, and ends in the hippocampal gyrus and perhaps the amygdala.

The **middle** or **gray root** is best called the *trigonum olfactorium*, being only a slight elevation in the angle between the two roots just mentioned, and containing no non-medullated band of fibres which could properly be called a gray root.

The **olfactory bulb** is oval in shape, about two-fifths of an inch long and a third as broad. Its upper surface presents a ridge continuous with the ridge of the olfactory tract, and like it received into the olfactory fissure of the frontal lobe. Its under surface is slightly convex, and lies on the cribriform plate of the ethmoid, and from it spring the twenty or more filaments which collectively form the olfactory nerve. The dorsal portion of the bulb consists of medullated nerve-fibres; its ventral segment contains the nerve-cells, whose axis-cylinder processes form the medullated nerves of the tract, and whose branching processes come into close relationship in the olfactory glomeruli with the branching ends of the olfactory filaments. These cells, therefore, form the nucleus of the olfactory nerve.

It will be convenient here to complete the description of the olfactory nerve.

The First or Olfactory Nerve.

This nerve (Figs. 670, 671) is represented by the twenty or more fine bundles of non-medullated fibres which spring from the under surface of the olfactory bulb. They pierce the foramina in the cribriform plate of the ethmoid bone, each receiving an investment of dura. Those piercing the inner line of foramina supply the upper third of the nasal septum (Fig. 670); the outer group supplies the lateral wall of the nose as low as the lower border of the superior turbinated bone (Fig. 671). The fibres communicate freely, forming a fine network. They commence as axis-cylinder processes of the olfactory cells of the Schneiderian membrane, and terminate by minutely branching processes in the glomeruli of the olfactory bulb.

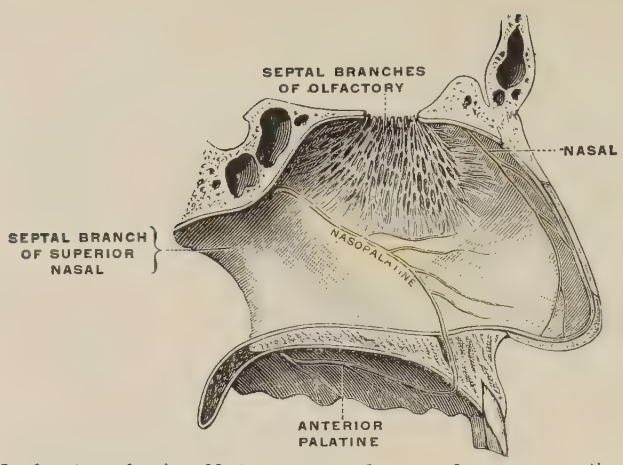

FIG. 670.—Nasal septum, showing olfactory nerves and nerves of common sensation. (Testut.)

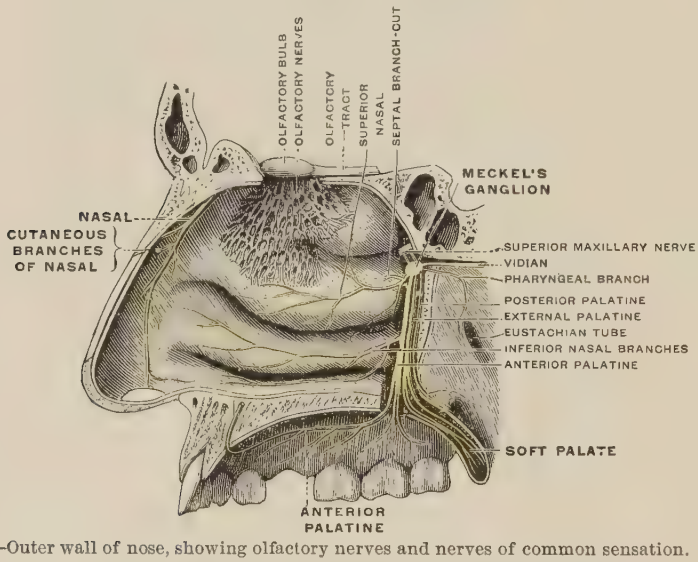

FIG. 671.—Outer wall of nose, showing olfactory nerves and nerves of common sensation. (Testut.)

The Second or Optic Nerve.

Traced backward from the eyeball the *optic* ("seeing") *nerves* (Fig. 672) are seen to meet on the under surface of the brain in the *optic commissure* or *chiasma*, where they partially decussate, and whence two flattened bands, the *optic tracts*, pass backward round the crura cerebri to the thalami and quadrigeminal bodies.

The **optic tract** (Fig. 672) arises by two roots from the pulvinar of the optic thalamus, the corpora geniculata, and the superior quadrigeminal body. Thence it bends round the upper end of the crus cerebri to which it is attached as a flattened, white band, and becoming more rounded, passes between the anterior perforated space and the interpeduncular space to end in the chiasma.

The **optic commissure** or **chiasma** ("like X, the Greek letter, *chi*") is oblong, the longest diameter being transverse. It rests on a groove above the olivary eminence of the sphenoid and has the internal carotid artery on either side of it. From its extremities in front spring the optic nerves.

The **optic nerve** enters the orbit by the optic foramen, accompanied by the ophthalmic artery, which lies below and external to it. In the orbit it runs forward, outward, and a little downward to the back of the eyeball,

which it pierces one-eighth inch to the inner side of the optic axis. Its fibres then radiate in all directions over the anterior surface of the retina. As the nerve enters the orbit it receives an investment from the dura, which sends a layer also to blend with the periosteum. The pial, arachnoid, and dural sheaths remain distinct as far as the sclerotic, with which they blend, and well-marked subdural and subarachnoid spaces can be demonstrated. In the orbit the nerve is closely surrounded posteriorly by the recti muscles; but farther forward is separated from them by fatty tissue. The ciliary vessels and nerves surround it, especially above and below, the ophthalmic artery and nasal nerve cross over it

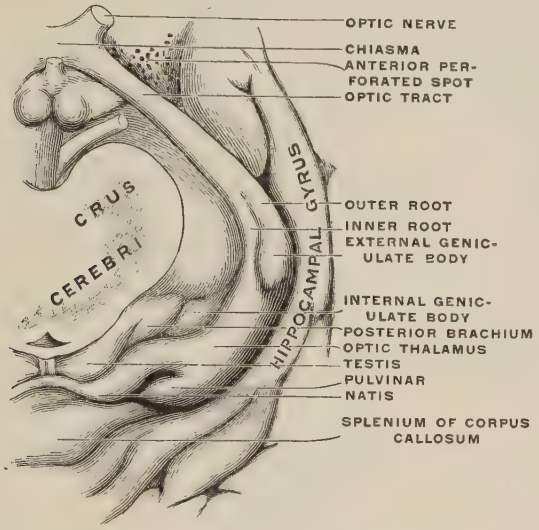

FIG. 672.—Origin and relations of optic tract. Part of the base of the brain: temporal gyri drawn aside, pia removed. (W. Keiller.)

from without inward, and the ciliary ganglion lies on its outer surface. It is pierced by the arteria centralis retinæ and its vein.

In *the chiasma* (Fig. 673) a partial decussation takes place. The outer fibres do not decussate, but connect the outer half of the retina with the geniculate and quadrigeminal bodies of the same side; the inner fibres decussate completely, connecting the inner half of the retina with these nuclei on the opposite side. Thus, the right optic tract conveys fibres from the right halves of both retinæ to the right side of the brain, and the left behaves similarly. The lateral portions of the chiasma consist of uncrossed fibres, the central portion contains intercrossed fibres from the nasal (inner) sides of both retinæ. Besides these the posterior part of the chiasma is occupied by a band of fibres which, after partial interruption in the cells of the internal geniculate bodies, unite the inferior corpora quadrigemina with each other. This is called Gudden's commissure, and appears to have nothing to do with sight.

The fibres of the optic nerve commence as axis-cylinder processes of the large ganglionic cells of the retina, and end in branching processes round the cells of the external geniculate body, superior quadrigeminal body, and optic thalamus, which cells, therefore, form the nucleus of the optic nerve; thence fibres pass by the optic radiation to the cuneus in the occipital lobe of the cerebrum. Imperfectly traced connections exist between the visual centres and the nuclei of the third, fourth, and sixth nerves.

General View of the Nuclei of the Third to the Twelfth Cranial Nerves (Figs. 674, 675).—The nuclei of the third to the twelfth cranial nerves inclusive lie in the central gray matter of the brain from the level of the posterior commissure to that of the decussation of the pyramids, the nucleus of the spinal accessory,

and the ascending vago-glossopharyngeal and fifth roots extending still lower down. In Fig. 674 the motor nuclei are represented (in red), in Fig. 675 the

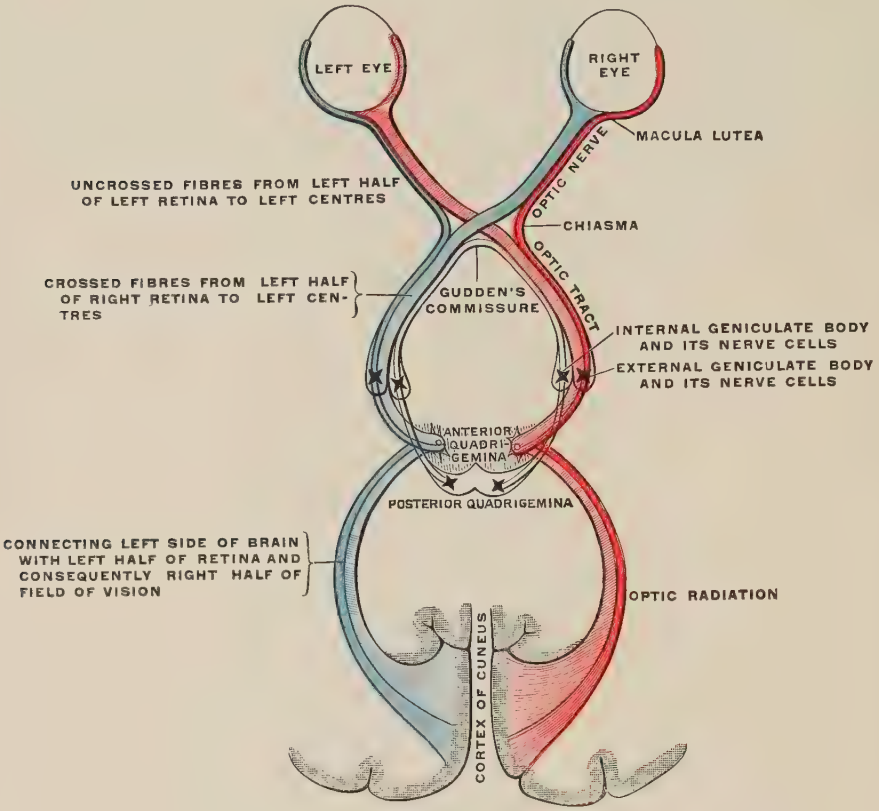

FIG. 673.—Diagram of the course of the optic fibres. (W. Keiller, after Testut.)

sensory nuclei (in blue). The *motor nuclei* are arranged in two interrupted columns, the third, fourth, sixth, and twelfth motor nuclei forming one column close to the middle line, and very near the floor of the aqueduct, fourth ventricle or central canal; while the motor nuclei of the fifth, seventh, ninth, tenth, and eleventh form another column, more deeply and more laterally situated than the first and deviating somewhat toward the side above, where the ventricle is widest. The fifth nerve has a well-marked ascending root, which is probably motor, as well as a crossed motor root. The spinal portion of the spinal accessory arises from the cells of the ventral horn of gray matter as low as the sixth or seventh cervical nerve.

Coming now to the *sensory nuclei*, each sensory nerve has an ascending root. Thus the fifth, eighth, ninth, tenth, and accessory portion of the eleventh have each an ascending root which appears to bring it into relation with the nucleus of the funiculus cuneatus and gelatinous substance of Rolando (compare the connection of the sensory roots of the spinal nerves with the same nuclei). Each nerve has in addition a special sensory nucleus—the eighth nucleus is divisible into three groups—near the level of its point of exit and dorso-lateral to the motor nuclei.

In *longitudinal extent* the nucleus of the third nerve occupies the floor of the aqueduct from the posterior commissure to the groove between the superior and inferior quadrigeminal bodies, the nucleus of the fourth lies ventrally to the testis, the fifth nucleus nearly corresponds to the lateral recess, the sixth lies under the eminentia teres, the eighth nuclei are on a level with the striæ acusticæ, and the

seventh on the same level, but more mesial. Lastly the ninth, tenth, and eleventh form two columns (sensory and motor), and the twelfth a third column, which extend almost the whole length of the oblongata.

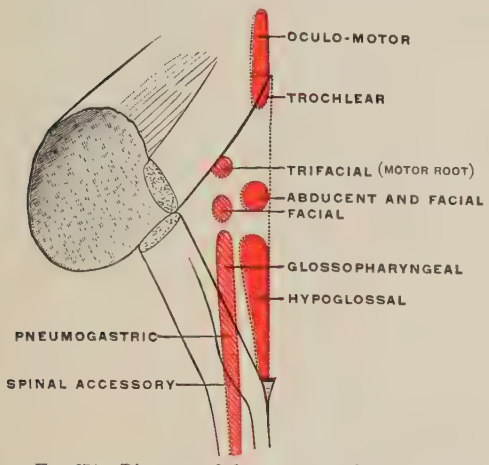

FIG. 674.—Diagram of the motor nuclei in and near the floor of the fourth ventricle. (Testut.)

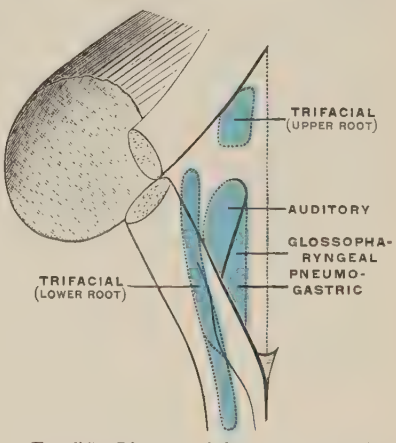

FIG. 675.—Diagram of the sensory nuclei in the floor of the fourth ventricle. (Testut.)

CONNECTIONS OF THE NUCLEI OF THE CRANIAL NERVES WITH THE CORTEX CEREBRI.

The cortical connections of the olfactory and optic nerves have already been described. The motor tract for the other cranial nerves seems to run from the motor area of the cerebral cortex, down through the genu of the internal capsule, pyramidal segment (middle third of the crusta) of the crus cerebri, and pyramidal tract of the pons and oblongata to nearly opposite their respective nuclei. It then crosses through the raphe and passes the formatio reticularis to the motor nuclei of the opposite side. Round the cells of the motor nuclei the pyramidal fibres end, and from these cells fresh fibres pass by the motor nerve-roots to the periphery. The cortical centre for the facial occupies the lower ends of the precentral and postcentral gyri; the hypoglossal centre is in the lower end of the precentral and posterior end of the inferior frontal gyri.

The sensory tract is less known but, on leaving the sensory nuclei, it appears to cross to the opposite fillet, and thus pass to the superior quadrigeminal body and subthalamic region or thalamus, some part of it going through the posterior third of the hind limb of the internal capsule to the cortex cerebri behind the motor area.

The *course of the nerve-roots* from their nuclei to superficial origins is as follows: The roots of the third, fifth, sixth, eighth, twelfth, and the sensory roots of the ninth, tenth, and eleventh, run in nearly straight lines ventro-laterally from nucleus to point of superficial emergence. The fourth is altogether exceptional (see special description). The motor roots of the seventh, ninth, tenth, and eleventh run at first dorso-mesially toward the floor of the ventricle and then bend outward, and lastly ventrally to join the sensory roots, the seventh running upward for some distance before it turns outward.

We now pass to a *particular description of the cranial nerves from the third to the twelfth*, inclusive of both. The first and second nerves have already been fully considered.

The Third or Oculo-motor Nerve.

The nucleus of the third nerve (Fig. 677), the oculo-motor ("eye-mover"), consists of several distinct groups of cells, lying on the floor of the aqueduct,

close to the middle line, and nearly corresponding in position to the superior quadrigeminal body. It is just dorsal to the posterior longitudinal fasciculus, which appears to connect it with the nuclei of the seventh and eighth, and with the sixth nucleus of the opposite side. From its nucleus the nerve issues in many small bundles, running ventrally through the posterior longitudinal bundle and red nucleus to the oculo-motor groove, on the inner side of the crus cerebri just above the pons. The nuclei of both sides communicate freely. The nerve so formed passes between the posterior cerebral and superior cerebellar arteries, forward and a little outward, piercing the dura on the outer side of the posterior clinoid process, and so entering the outer wall of the cavernous sinus, in

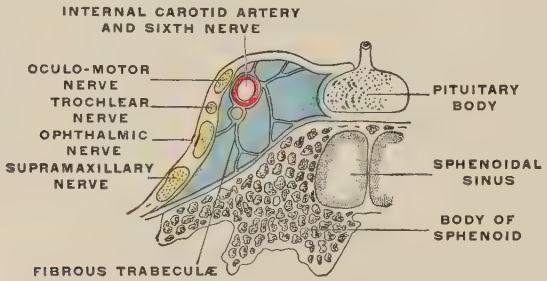

FIG. 676.—Cavernous sinus, as shown by transverse section through the middle of the sella turcica. (W. Keiller.)

which it is embedded (Fig. 676). Between layers of the dura it enters the sphenoidal fissure, having divided into a superior and inferior division. Thus it enters the orbit, passing between the two heads of the external rectus, the two divisions being separated by the nasal nerve.

The **superior division** is directed inward and forward over the optic nerve, and

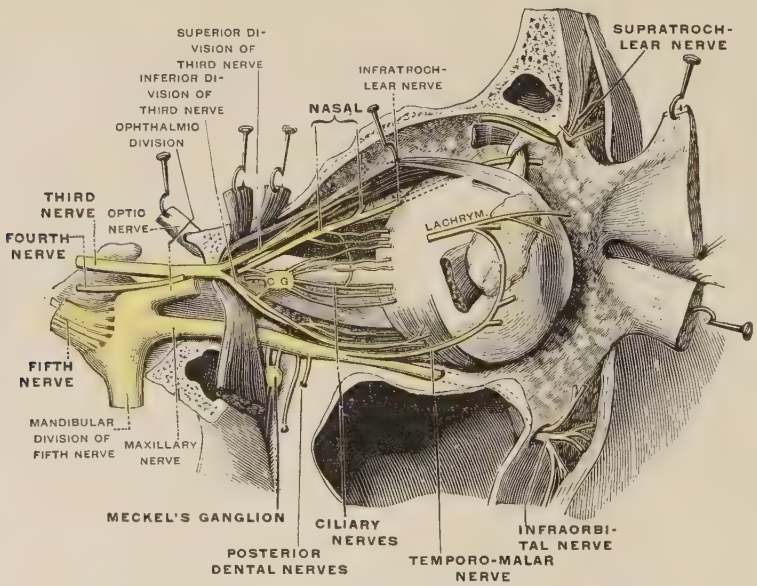

FIG. 677.—Oculo-motor nerve and ciliary ganglion (C. G.). (Testut.)

pierces the rectus superior to terminate in the levator palpebræ superioris, supplying these two muscles.

The **inferior division** splits into three branches. Of these, one supplies the internal rectus, another the inferior rectus, and the third, larger than either of the

others, passes between the inferior and external recti to enter the posterior border of the inferior oblique. This branch gives a short, thick offset to the ciliary ganglion, thus furnishing its motor root, and also contributes some twigs to the inferior rectus.

The third nerve supplies all the orbital muscles, except the superior oblique (supplied by the fourth nerve) and external rectus (sixth nerve). It also, through the ciliary ganglion, supplies the ciliary muscle and sphincter iridis. It is further to be noted that the nucleus of this nerve, through communication with the roots of the facial, supplies the orbicularis palpebrarum, occipito-frontalis, and corrugator supercilii; and that the fibres of the third nerve to the internal rectus are derived from the sixth nucleus of the opposite side. It may be well to note here that all the orbital muscles are supplied by their nerves on their surfaces next the eyeball, except the inferior oblique which is pierced by its nerve on its

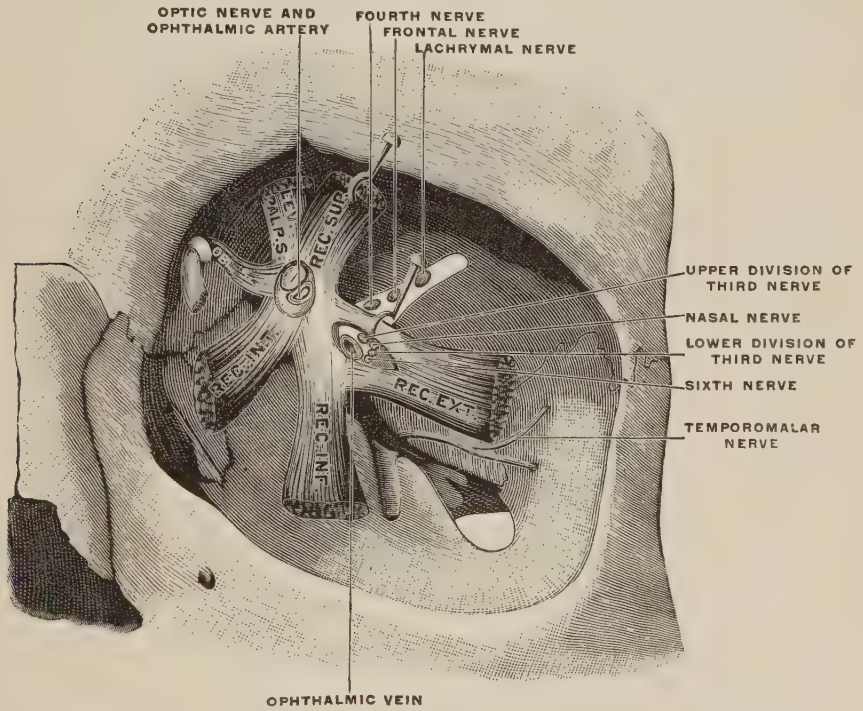

FIG. 678.—Back of the orbit, showing passage of nerves through sphenoidal fissure. (Modified from Testut.)

posterior border, and the superior oblique which is supplied by the fourth nerve on its orbital surface.

Observe here, also, the *relations of the orbital nerves in the cavernous sinus and sphenoidal fissure* (Fig. 678).

The third and fourth nerves and ophthalmic division of the fifth lie embedded in the outer wall of the *cavernous sinus*, while the sixth nerve and internal carotid artery pass through the sinus, the nerve lying beneath the artery, and both being separated from the blood of the sinus by an epithelial lining supported by delicate fibrous tissue.

In the *sphenoidal fissure* the fourth, frontal, and lachrymal nerves are arranged along its upper boundary in the order mentioned from within outward; the superior and inferior divisions of the oculo-motor, the nasal, and sixth nerves pass between the two heads of the external rectus, the nasal lying between the first two and the sixth most inferiorly. The ophthalmic vein leaves the orbit through this fissure internally to the sixth nerve.

The Fourth or Trochlear Nerve.

The fourth nerve (called *trochlear* because the tendon of the muscle which it supplies runs through a pulley) arises in a short column of cells almost continuous with the third nucleus, and commensurate with the inferior quadrigeminal body. Thence the root runs dorso-laterally, and after descending for a short distance crosses inward in the valvula, where it decussates with its fellow, and emerges as a slender round bundle immediately behind the testis on the opposite side from its nucleus.

It now passes outward across the superior peduncle of the cerebellum, and forward round the outer side of the crus cerebri to pierce the dura under cover of the free margin of the tentorium, external to the posterior clinoid process and third nerve. It is embedded in the outer wall of the cavernous sinus between the oculo-motor and ophthalmic nerves, afterward crossing the oculo-motor to lie in the inner angle of the sphenoidal fissure through which it reaches the orbit. Here it runs inward above the levator palpebræ superioris and is distributed to the obliquus superior on its upper (orbital) surface.

The Fifth or Trifacial Nerve.

The fifth nerve is called *trifacial* because it has *three* grand divisions, which are distributed to the *face*; and sometimes it is called *trigeminal* ("three double" or "three twins"), referring to the arrangement of the divisions on the two sides of the head. It is mixed in function, closely resembling a spinal nerve in that the motor and sensory roots arise separately from the encephalon, the sensory root possessing a ganglion similar in constitution and development to that of a posterior spinal nerve-root, while the motor root joins the nerve on the distal side of the ganglion.

The *motor root* arises from a group of cells lying deeply in the floor of the fourth ventricle at a point corresponding to the lateral recess. It is joined by the *descending root* which appears to arise from cells in the aqueduct and by a *crossed motor root* of doubtful connections.

Most of the fibres of the sensory portion are traceable into the so-called *ascending root* which appears as a crescentic band of fibres outside the head of the dorsal horn. The fibres appear to arise as axis-cylinder processes of the cells of the Gasserian ganglion and to terminate as minutely branching processes round the cells of the gelatinous substance and funiculi gracilis and cuneatus (compare sensory spinal nerve-root). Many sensory fibres end in the *superior sensory nucleus*, which lies just outside the motor nucleus. The crossed sensory and cerebellar roots are imperfectly understood.

Thus, then, two roots can be seen coursing through the pons from whose ventral surface they emerge near its anterior border. The larger, sensory root (portio major) being ventro-lateral to the smaller, motor root (portio minor).

The larger root runs forward beneath the tentorium, where, just under the fourth nerve and near the apex of the petrous portion of the temporal bone, it enters a recess between the two layers of the dura (Meckel's space). Here the larger root spreads out, forming a plexiform network, and enters the Gasserian ganglion.

The smaller root, from being dorsal to the portio major at its origin, winds spirally round the latter, gaining its inner and then its ventral (under) surface, and crosses beneath the Gasserian ganglion to join the third division only, which emerges from that structure.

The Gasserian or Semilunar Ganglion.—This body lies on a special depression on the anterior surface of the petrous bone; it is crescent-shaped, the convexity being directed forward. Its surfaces are adherent to the dura, flattened, and much striated; and it is rich in ganglionic cells. It is joined by filaments from the carotid plexus of the sympathetic, and sends recurrent fibres to the dura.

From its convex border the sensory portion of the trifacial emerges in three trunks, the ophthalmic, superior maxillary, and inferior maxillary or mandibular. The third of these alone is joined by the motor root after its emergence.

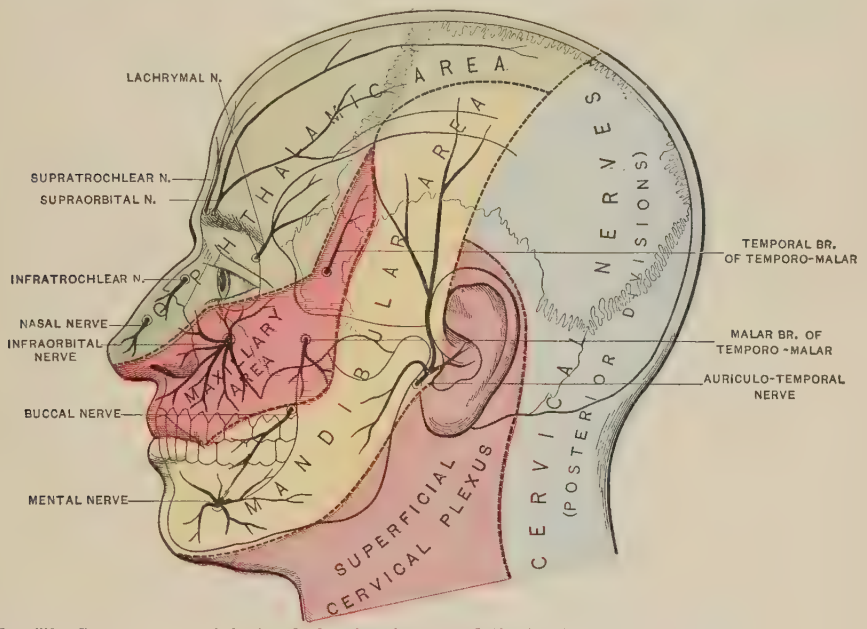

FIG. 679.—Sensory areas of the head, showing the general distribution of the three divisions of the trifacial nerve. (Modified from Testut.)

A general idea of the cutaneous distribution of these nerves will be got from a glance at Fig. 679.

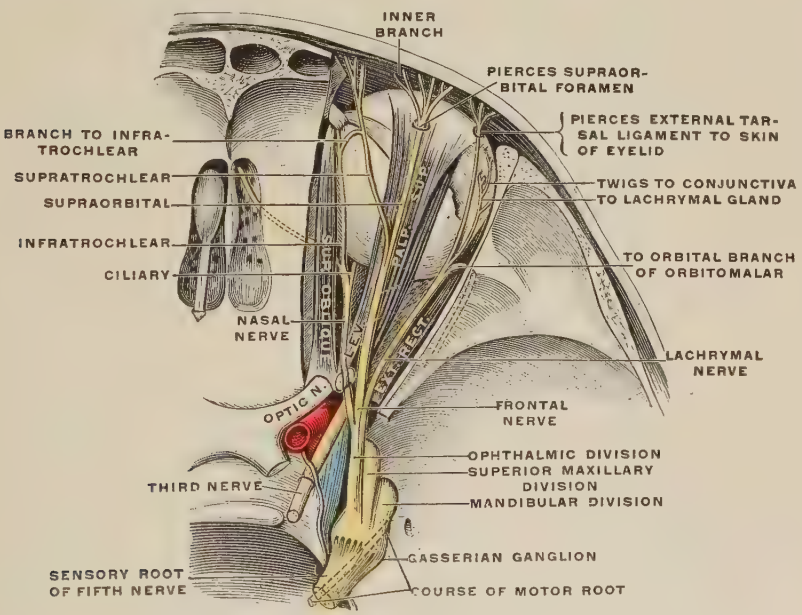

FIG. 680.—Ophthalmic division of the trifacial nerve. (Testut.)

First or Ophthalmic Division of the Fifth Nerve (Fig. 680).—The first or ophthalmic ("eye") division of the fifth nerve is a flattened trunk, one inch long,

which runs forward and upward in the outer wall of the cavernous sinus under the fourth nerve. Between layers of dura it reaches the sphenoidal fissure, which it passes through in three divisions, the lachrymal, frontal, and nasal. It gives offsets to the third, fourth, and sixth nerves, as these enter the orbit.

The **Lachrymal Nerve** is the outermost of these three divisions. It occupies a separate sheath of dura, and passes by the outer angle of the sphenoidal fissure into the orbit. Here it runs along the upper border of the external rectus to the outer and the upper angle of the cavity to reach the lachrymal ("tear") gland. Just behind the gland it gives off a *branch to join the orbital* branch of the superior maxillary nerve, and *branches to the lachrymal gland* and conjunctiva, and terminates by piercing the external tarsal ligament to supply the *skin of the upper eyelid*, where it communicates with the facial nerve.

The **Frontal Nerve**, the middle and largest division of the ophthalmic, also enters the orbit close to the roof of the sphenoidal fissure. It runs forward on the levator palpebræ superioris, between it and the periosteum. Midway in its passage through the orbit it gives off the *supratrochlear nerve*, and then, assuming the name *supraorbital*, runs straight to the supraorbital foramen. Through this foramen it leaves the orbit accompanied by the supraorbital branch of the ophthalmic artery, and divides into an internal and an external branch, the external branch being the larger. These pierce the orbicularis palpebrarum and frontalis very obliquely, supplying the skin of the front part of the scalp, the external branch being traceable as far as the lambdoidal suture.

The *supratrochlear nerve*, springing from the frontal, as above described, runs forward and inward toward the pulley of the superior oblique. Near the pulley it sends a twig to join the infratrochlear branch of the nasal; and then, passing over the superior oblique tendon, it lies between the orbicularis palpebrarum and the bone, as it passes over the inner angle of the orbital arch. Here it supplies twigs to the eyelid and conjunctiva, and then pierces the frontalis to reach the skin of the forehead over the glabella. It is accompanied by the frontal artery. These, like all other sensory branches of the fifth nerve, communicate with the facial.

The **Nasal Nerve** enters the orbit between the two heads of the external rectus and two divisions of the oculo-motor nerve. At first on the outer side of the optic nerve, it crosses it obliquely beneath the rectus superior to reach the anterior internal orbital canal, through which, accompanied by the anterior ethmoidal vessels, it enters the cranium. In the orbit it gives off the sensory root to the ciliary ganglion, two long ciliary nerves, and the infratrochlear nerve.

In the cranium it runs forward on the cribriform plate of the ethmoid and passes to the nasal fossa through the nasal slit. In the roof of the nose it gives off an internal or septal branch, and an external branch, and passes onward as the anterior or superficial branch in a groove on the nasal bone to become cutaneous by passing between that bone and the lateral cartilage of the nose.

Branches.—(*a*) The *branch to the ciliary ganglion* is a slender filament, one-quarter inch long, which is given off where the nasal nerve lies between the heads of the external rectus. It furnishes the sensory root of the ganglion.

(*b*) One or two *long ciliary nerves* pierce the sclerotic near the optic nerve.

(*c*) The *infratrochlear nerve* runs forward beneath the superior oblique, receives a communicating branch from the supratrochlear, and, passing beneath the pulley to the inner canthus, supplies the conjunctiva, caruncle, lachrymal sac, and skin of the eyelids and nose.

(*d*) The *internal* or *septal branch* supplies the mucous membrane on the upper and anterior part of the nasal septum.

(*e*) The *external branch* supplies the outer wall of the nose, including the anterior ends of the middle and inferior turbinated bones.

(*f*) The *anterior* or *superficial branch* pierces the compressor naris and is distributed to the skin of the lower part of the nose.

Sporadic Ganglia connected with the Fifth Nerve.—There are four small gan-

glia connected with the fifth nerve—the ophthalmic, sphenopalatine, otic, and submaxillary. Each of these has three roots, derived from motor, sensory, and sympathetic nerves respectively, and a varying number of branches of distribution. Their cells are multipolar, thus resembling the cells of sympathetic ganglia, and differing from those of the ganglia of the posterior spinal nerve-roots and Gasserian ganglion.

The Ophthalmic, Ciliary, or Lenticular Ganglion (Fig. 677).—The ciliary ganglion is a small reddish body about the size of a large pin-head (one-twelfth of an inch in long diameter), compressed laterally, and quadrilateral in shape, presenting four angles. It lies at the back of the orbit, between the external rectus and the optic nerve, and is often in contact with the ophthalmic artery.

Its long (sensory) root is derived from the nasal nerve, entering its superoposterior angle. Often incorporated with this or entering the ganglion by its side is the sympathetic root, derived from the cavernous plexus; and its motor root is a short, comparatively thick offset from the branch of the third nerve to the inferior oblique, which enters the postero-inferior angle of the ganglion.

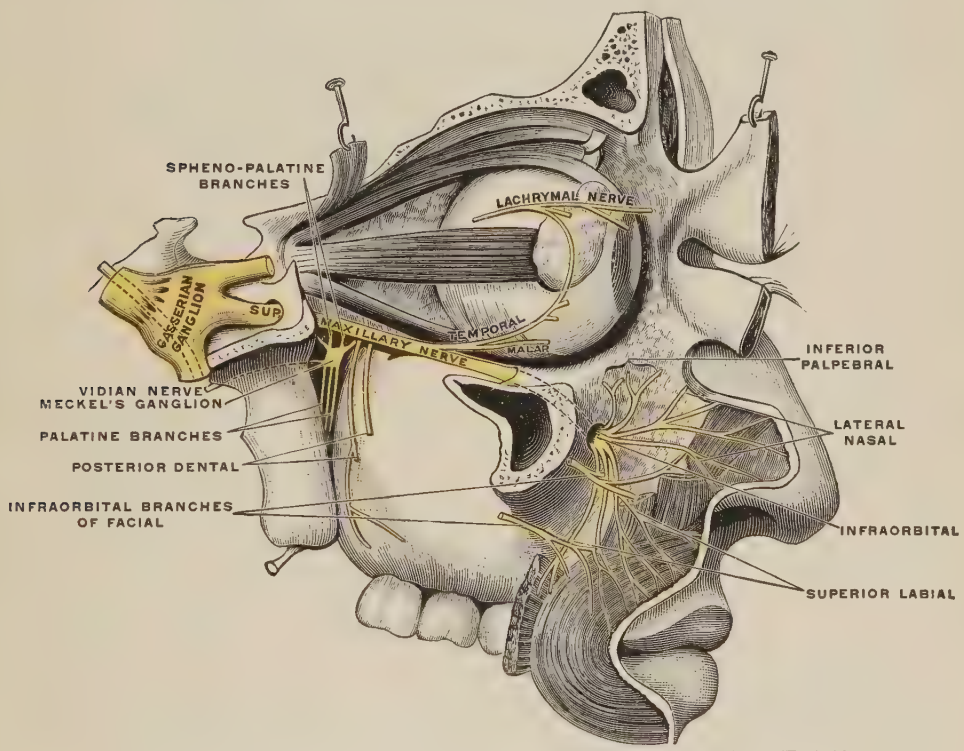

FIG. 681.—Maxillary division of the trifacial nerve and Meckel's ganglion. (Testut.)

From the anterior angles of the ganglion spring its branches of distribution called the *short ciliary nerves*. There are at first six to eight of them, arranged in two groups, superior and inferior, the inferior group being joined by the long ciliary nerves from the nasal. They pass along the upper and lower surfaces of the optic nerve, subdividing until about twelve to eighteen fine filaments reach the sclerotic, and pierce it in a circle round the optic nerve. They supply nerves of ordinary sensation and trophic nerves to the eyeball (derived from the nasal), motor nerves to the ciliary muscle and sphincter iridis (derived from the oculomotor), and sympathetic nerves to the dilatator fibres of the iris. Experiments on the dog, cat, and ape make the following conclusions approximately correct for man. Two or three of the upper thoracic spinal nerves send efferent pupillodilator fibres to the corresponding thoracic ganglia of the sympathetic, which

ascend in the sympathetic trunk to the superior cervical ganglion. Here they form branching processes round sympathetic nerve cells, whence new fibres pass by the nasal branch of the ophthalmic division of the fifth and long ciliary nerves, and perhaps by the cavernous plexus of the sympathetic, ciliary ganglion, and short ciliary nerves to the dilatator fibres of the iris. The sphincter pupillæ and ciliary muscle are supplied by fibres of the third nerve, which end in arborizations round the nerve cells of the ciliary ganglion, whence new fibres pass by the short ciliary nerves to these muscles.

The Second or Maxillary Division of the Fifth Nerve (Fig. 681).—The *maxillary* (*superior maxillary*) *nerve* is intermediate in size and position between the two other divisions of the fifth nerve, and like the first is purely sensory. After a very short intracranial course it passes through the foramen rotundum, crosses the sphenomaxillary fossa, and enters the orbit through the sphenomaxillary fissure to occupy the infraorbital groove in its floor. It is here joined by the infraorbital branch of the internal maxillary artery, and together they enter the infraorbital canal to reach the face beneath the orbit, where the nerve divides into its terminal branches.

Branches.—(*a*) **Recurrent branch.** Within the cranium it gives a *recurrent* branch to the dura and middle meningeal artery.

(*b*) The **orbital branch** (*temporo-malar nerve*) is given off in the sphenomaxillary fossa. It enters the orbit through the sphenomaxillary fissure, and divides into two branches, *temporal* and *malar*.

The *temporal branch* runs upward along the outer wall of the orbit, gives a communicating filament to the lachrymal nerve, and passing obliquely through the periosteum enters the temporal canal of the malar bone. It thus passes to the temporal fossa, where, running upward between the temporal muscle and the bone, it pierces the deep and superficial layers of the temporal fascia very obliquely, and emerges subcutaneously one inch above the zygoma, where its twigs perforate the orbicularis palpebrarum to the skin, communicating with the facial and auriculo-temporal nerves.

The *malar branch* (*ramus subcutaneus malæ*) runs forward in the fat of the orbit, and pierces through the malar canal to the skin of the face over the malar bone.

(*c*) The **sphenopalatine branches** are two short, stout twigs to Meckel's ganglion, with which they will be described.

(*d*) The **posterior superior dental nerves** (Fig. 682), the last branches given off in the sphenomaxillary fossa, are usually two in number, or may arise together. Running downward on the back of the superior maxilla, in the grooves which lead to the posterior dental canals, they give fibres to the gums and buccal mucous membrane (nervuli gingivales) and then enter these canals to supply the molar teeth and antrum.

(*e*) The **middle superior dental nerve** is given off in the hind part of the infraorbital canal. It descends in a minute canal or groove in the outer wall of the antrum to supply the bicuspid teeth.

(*f*) The **anterior superior dental nerve** commences in the fore part of the infraorbital canal. It also descends in the wall of the antrum, dividing into two branches: a *nasal branch* which supplies the mucous membrane of the anterior part of the inferior meatus and floor of the nasal fossa; and a *dental branch* to the incisor and canine teeth.

These three dental nerves form loops (the superior dental plexus) in the minute canals provided for them in the maxilla, and from the loops filaments pass to the foramina at the tips of the fangs, and supply the dental pulp.

(*g*) **Infraorbital Nerve.**—From the time the maxillary nerve enters the infraorbital canal it is called the *infraorbital nerve*, and under that name it emerges on the face, where it lies deeply under cover of the levator labii superioris proprius. Here it divides into seven or more branches. Two of these, called *inferior palpebral*, turn upward to the skin and conjunctiva of the lower eyelids; two or

three pass inward between the fibres of the levator labii superioris alæque nasi to the side of the nose (*lateral nasal*); and three or four *superior labial* branches run downward, piercing the fibres of the elevators of the upper lip and angle of the mouth to the skin of the lips and cheek, and sending large twigs to the mucous membrane.

These infraorbital nerves communicating with the facial form the infraorbital plexus.

The Sphenopalatine or Meckel's Ganglion (Figs. 682, 683).—The *sphenopala-*

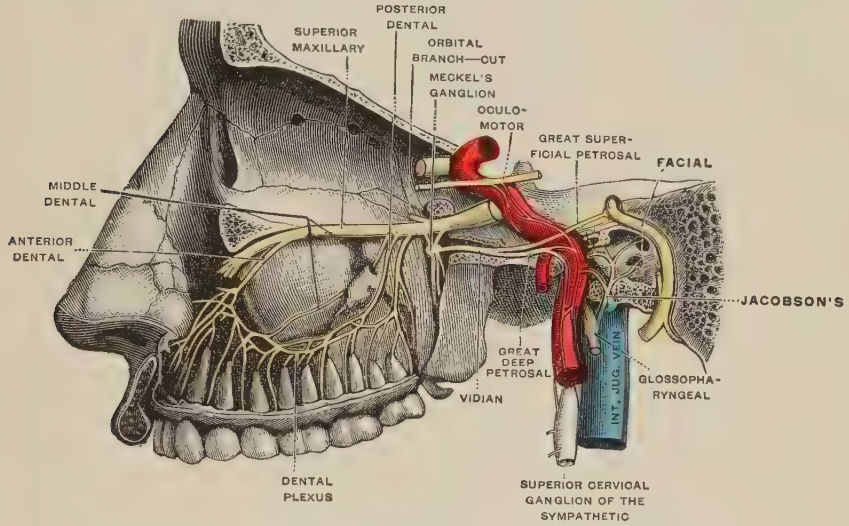

FIG. 682.—Dental branches of superior maxillary nerve and sphenopalatine ganglion. (Testut.)

tine, or *Meckel's ganglion*, is a small, reddish, triangular body, one-fifth of an inch in its long diameter, and flattened at the sides. It is situated in the upper part of the sphenomaxillary fossa, just under the superior maxillary nerve, where it is embedded in fat and surrounded by the terminal branches of the internal maxillary artery. Only its posterior segment contains nerve-cells.

Its *sensory root* is represented by two short, stout nerves, which attach its two superior angles to the superior maxillary nerve, forming its *sphenopalatine branches*. The greater part of these roots passes on without interruption in ganglion-cells into the palatine, nasal, and pharyngeal branches of the ganglion.

Its *motor and sympathetic roots* are contained in the *Vidian nerve*.

The **Vidian Nerve** is a compound nerve, formed by the junction of the *great superficial* and *great deep petrosal* nerves. Tracing the *Vidian nerve* backward to its sources, it leaves the postero-superior angle of the ganglion, passes through the Vidian canal (accompanied by the artery of the same name) in which it gives off small twigs to the back of the nose and pharynx, and divides into two branches. Of these the *great superficial petrosal nerve* enters the cranium through the cartilage which closes the foramen lacerum medium by the outer side of the internal carotid artery, and, passing backward and outward in a groove on the petrous bone under the Gasserian ganglion, enters the hiatus Fallopii to join the geniculate ganglion of the facial nerve. It receives a twig from the tympanic branch of the glossopharyngeal. The *great deep petrosal nerve*, which joins this to form the Vidian nerve just outside the Vidian canal, can be traced to the plexus of the sympathetic on the internal carotid artery. Some works describe this as the carotid branch of the Vidian, and give the name of great deep petrosal to the twig from the glossopharyngeal which joins the great superficial petrosal. The *branches of distribution of Meckel's ganglion* are grouped as ascending, internal, descending, and posterior.

(*a*) **Ascending branches.**—These are the *orbital branches*, two or three exceedingly minute twigs which pass through the sphenomaxillary fissure to the periosteum of the orbit, and the mucous membrane of the posterior ethmoidal and sphenoidal sinuses.

(*b*) **Internal branches** are partly derived from the ganglion ; but are largely traceable over its inner surface into the sensory roots. They are *superior nasal* and *nasopalatine.*

The *superior nasal nerves* are several small twigs which enter the nose through the sphenopalatine foramen, to supply the mucous membrane over the upper and back part of the superior and middle turbinated bones and septum, as well as the posterior ethmoidal cells.

The *nasopalatine nerve* (Fig. 670) passes to the nasal septum, also through the sphenopalatine foramen. It runs downward and forward in a groove on the vomer

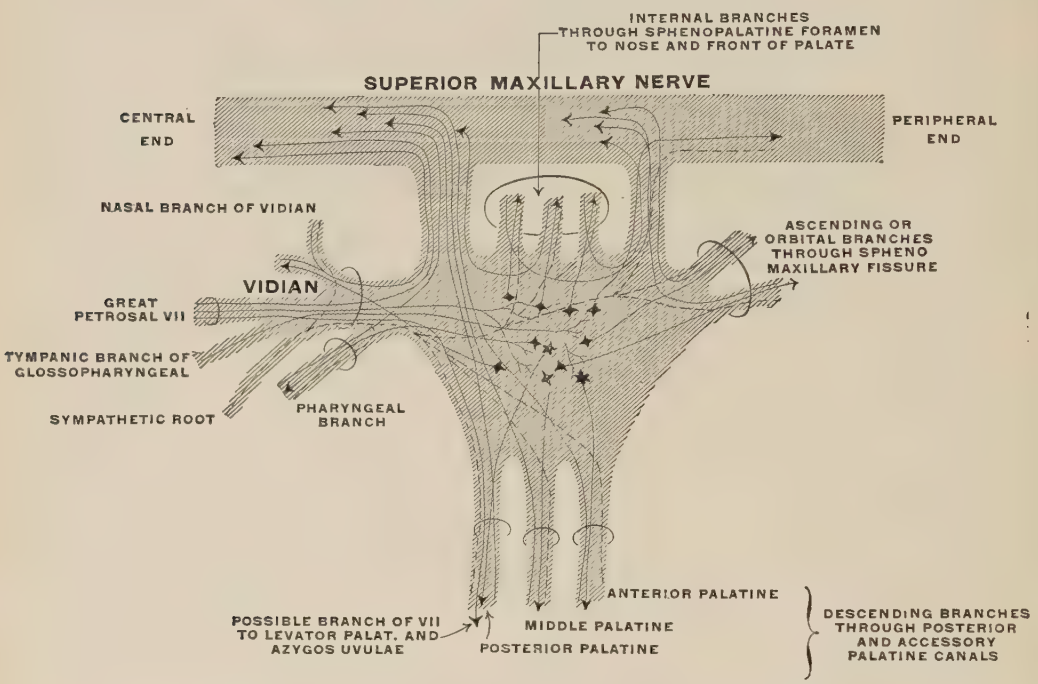

FIG. 683.—Diagram of constitution of sphenopalatine ganglion. (W. Keiller.)

between the periosteum and mucous membrane, contributing some small septal branches and communicating with the nasal branch of the anterior superior dental nerve. The two nasopalatine nerves, one on each side of the nasal septum, thus reach the median segments of the anterior palatine canal (foramina of Scarpa), through which they pass to the roof of the mouth, the left nerve occupying the anterior foramen.

In the lower part of the anterior palatine canal they unite in a plexiform network, and are then distributed to the mucous membrane behind the incisor teeth, communicating with the anterior palatine nerve.

(*c*) **Descending branches** (Fig. 671).—These are the three palatine nerves, anterior or great, posterior or small, and external. They are frequently given off as one trunk.

The *great* or *anterior palatine nerve*, springing from the lower angle of Meckel's ganglion, descends in the posterior palatine canal, and runs forward, in grooves, on the hard palate, supplying the gums and roof of the mouth, and communicating with the nasopalatine nerve. It contributes *inferior nasal*

branches to the back part of the inferior turbinated bone and middle and inferior meatus.

The *small* or *posterior palatine nerve* descends in one of the accessory palatine canals to the tonsil, uvula, and soft palate, and through it motor fibres possibly pass from the facial nerve to the levator palati and azygos uvulæ, though the pars accessoria ad vagum is now regarded as supplying these muscles.

The *external palatine nerve* occupies another accessory palatine canal, in which it descends to the soft palate and tonsil. It is occasionally absent.

(*d*) **Posterior branches.**—The twigs supplied by the Vidian in the Vidian canal to the upper part of the nose are derived from the sphenopalatine roots of the ganglion, and only accompany the Vidian nerve.

The *pharyngeal branch* springs from the ganglion beside the Vidian, with which it may be incorporated. It runs backward in the pterygopalatine canal with the vessel of that name to the posterior nares and nasopharynx, Eustachian tube, and sphenoidal sinuses.

What is known of the physiologic connections of the sphenopalatine ganglion may with a fair amount of accuracy be condensed as follows (see Fig. 683): (1) The nasal branch of the Vidian, pharyngeal, descending, internal, and ascending branches all convey ordinary centripetal fibres to the superior maxillary nerve. (2) The sympathetic root sends fibres, represented in the figure by dotted lines, through all the nerves mentioned to the mucous membrane supplied by them. None of these first two groups of nerves are interrupted in the ganglion. (3) The facial and glossopharyngeal nerves send vasodilator and secretory fibres by way of the Vidian, which form arborizations around the cells of the ganglion. (4) From the cells of the ganglion fresh fibres arise, which go to the mucous membrane of the nose, soft palate, tonsils, uvula, roof of the mouth, upper lip and gums, and upper part of the pharynx, through the internal, ascending, descending, pharyngeal, and nasal branches of the ganglion and the superior maxillary nerve. Thus vaso-dilator and secretory impulses suffer interruption in the cells of the ganglion. (5) There are reasons for believing that taste sensation from the front of the tongue finds its way by the chorda tympani to the facial, thence by the Vidian through the sphenopalatine ganglion to the superior maxillary division of the fifth nerve, and so to the brain.

The Third, Inferior Maxillary, or Mandibular Division of the Fifth Nerve (Fig. 684).—The *mandibular division of the fifth nerve* is larger than either of the others, and is formed by the third segment of the sensory root with the entire motor root, the two leaving the cranium through the foramen ovale, and uniting almost immediately afterward to form a single mixed nerve-trunk. About one-fourth of an inch below the base of the skull this short trunk divides under cover of the external pterygoid muscle into a smaller or anterior, and a larger or posterior, division.

Before it divides, the trunk gives off a recurrent nerve, and the nerve to the internal pterygoid.

The *recurrent branch* enters the cranium through the foramen spinosum, and sends a twig to the lining membrane of the mastoid cells, and another to the substance of the petrous bone.

The *nerve to the internal pterygoid* passes under the posterior border of that muscle supplying it on its deep surface. Near the origin of the nerve and lying on it is the otic ganglion, to which it contributes its sensory root.

The **smaller** or **anterior division** of the mandibular trunk is mainly motor in function. Its branches are as follows:

(*a*) The *deep temporal nerves, anterior* and *posterior*. Of these the posterior frequently springs from one common trunk with the masseteric nerve. They run upward over the upper border of the external pterygoid muscle and between the temporal muscle and the bone, supplying the latter muscle on its deep surface.

(*b*) The *masseteric nerve*, frequently starting in common with the posterior

deep temporal nerve, passes over the upper border of the external pterygoid, and through the sigmoid notch of the mandible behind the insertion of the temporal muscle, accompanied by the masseteric vessels. It enters the deep surface of the masseter muscle. It supplies a filament to the temporomandibular articulation.

(*c*) The *external pterygoid nerve* is given off from the *long buccal* nerve, which also contributes some fibres to the temporal muscle.

(*d*) The *long buccal nerve*, with the exception of those branches just mentioned, is purely sensory. It passes between the two heads of the external pterygoid muscle, and runs downward and forward under cover of the temporal muscle and anterior border of the masseter to the buccinator. Between the masseter and buccinator it divides into branches to the skin and mucous membrane of the cheek, the latter piercing the fibres of the buccinator. It communicates with the facial, forming a plexus around the facial vein called the buccal plexus.

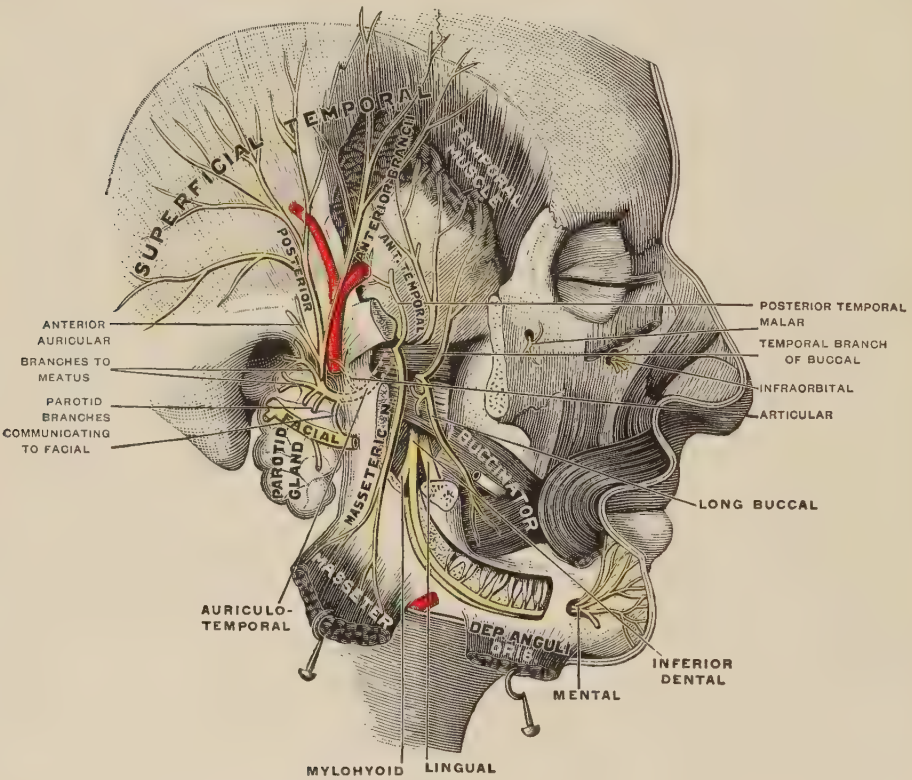

FIG. 684.—Mandibular division of the trifacial nerve. (Testut.)

The **larger** or **posterior division** is almost entirely derived from the sensory root, the only motor fibres it contains passing along the inferior dental nerve to form its mylohyoid branch. Its branches are as follow:

(*a*) The *Auriculotemporal Nerve* arises by two roots which usually enclose the middle meningeal artery. It passes backward and outward close under the temporomaxillary articulation, then upward between it and the external auditory meatus, under cover of the upper part of the parotid gland. Emerging from under the gland it crosses the root of the zygoma with the superficial temporal artery slightly behind which it lies, and divides into superficial temporal branches to the skin of the temple.

In this course it gives off (1) *articular twigs*, one or two fine filaments to the temporomaxillary articulation.

(2) *Communicating branches*, consisting of one or two stout branches to the facial nerve; and slender filaments to the otic ganglion, which latter are im-

portant because they conduct secretory fibres from the glossopharyngeal nerve to the parotid gland, by way of the lesser petrosal nerve, otic ganglion, and parotid branches of the auriculotemporal.

(3) Two nerves *to the meatus* pass between the bony and cartilaginous part of the external auditory meatus, and supply the skin of the meatus, contributing a twig to the tympanic membrane.

(4) Several *parotid branches* pass from the nerve itself, or its communicating branches to the facial nerve, into the gland substance.

(5) Two *anterior auricular branches* supply the skin over the tragus and upper part of the pinna.

(6) The *superficial temporal nerve* is the termination of the auriculotemporal. The posterior division breaks up into branches which cross the posterior branch

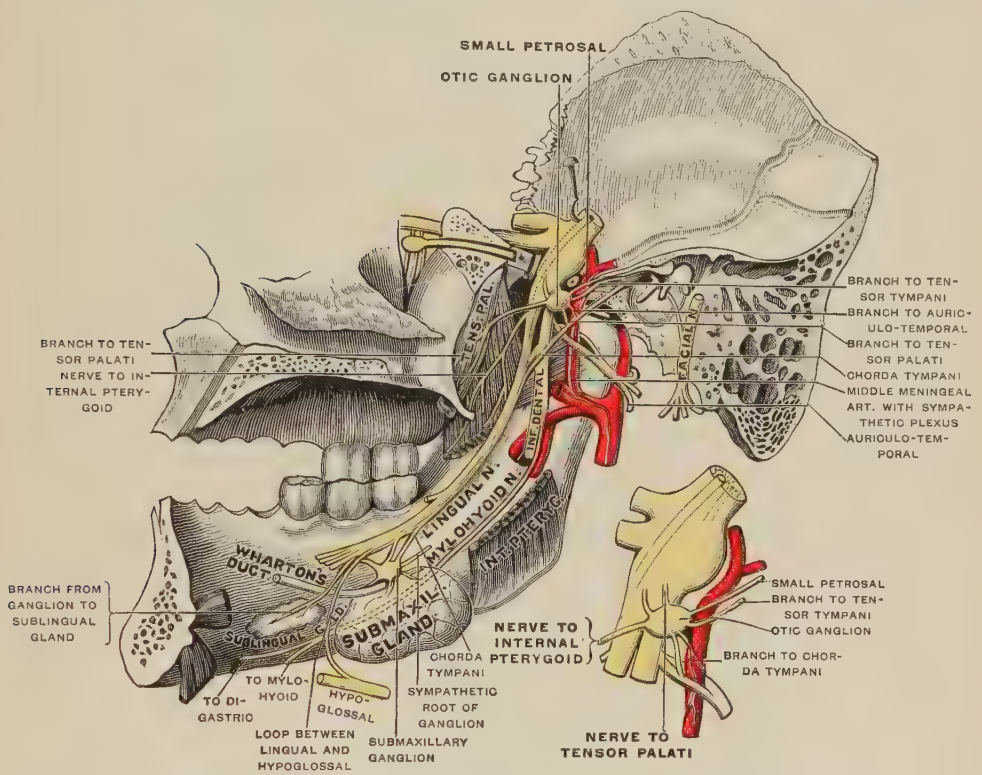

FIG. 685.—Mandibular division of trifacial nerve, seen from the middle line. The small figure is an enlarged view of the otic ganglion. (Testut.)

of the temporal artery, the anterior division communicates with the temporal branches of the facial nerve. They supply the skin of the temporal region.

(*b*) The *Inferior Dental Nerve* (Fig. 685) is the largest branch of the mandibular division of the fifth nerve. It emerges from under the lower border of the external pterygoid muscle, and running downward upon the internal lateral ligament of the lower jaw, with the inferior dental artery behind and the lingual nerve in front of it, it enters the inferior dental canal. Before entering the canal it gives off the mylohyoid nerve.

In the inferior dental canal it runs forward toward the symphysis menti, supplying *branches to the teeth and gums,* and opposite the mental foramen it divides into a mental and an incisive branch. The *incisive branch* runs forward in the continuation of the dental canal to supply the canine and incisor teeth and corresponding part of the gums; while the *mental branch* appears on the face by issuing through the mental foramen with a companion artery, and, under cover of the depressor anguli oris, divides into a descending branch to the integument

of the chin, and two ascending branches to the skin and mucous membrane of the lower lip. It communicates with the supramandibular division of the facial nerve.

The *mylohyoid branch* of the inferior dental nerve is rather to be regarded as coming straight from the motor root and only accompanying the inferior dental in its sheath as far as the inferior dental canal. It occupies the mylohyoid groove with an artery of the same name, and runs in the recess under the mylohyoid

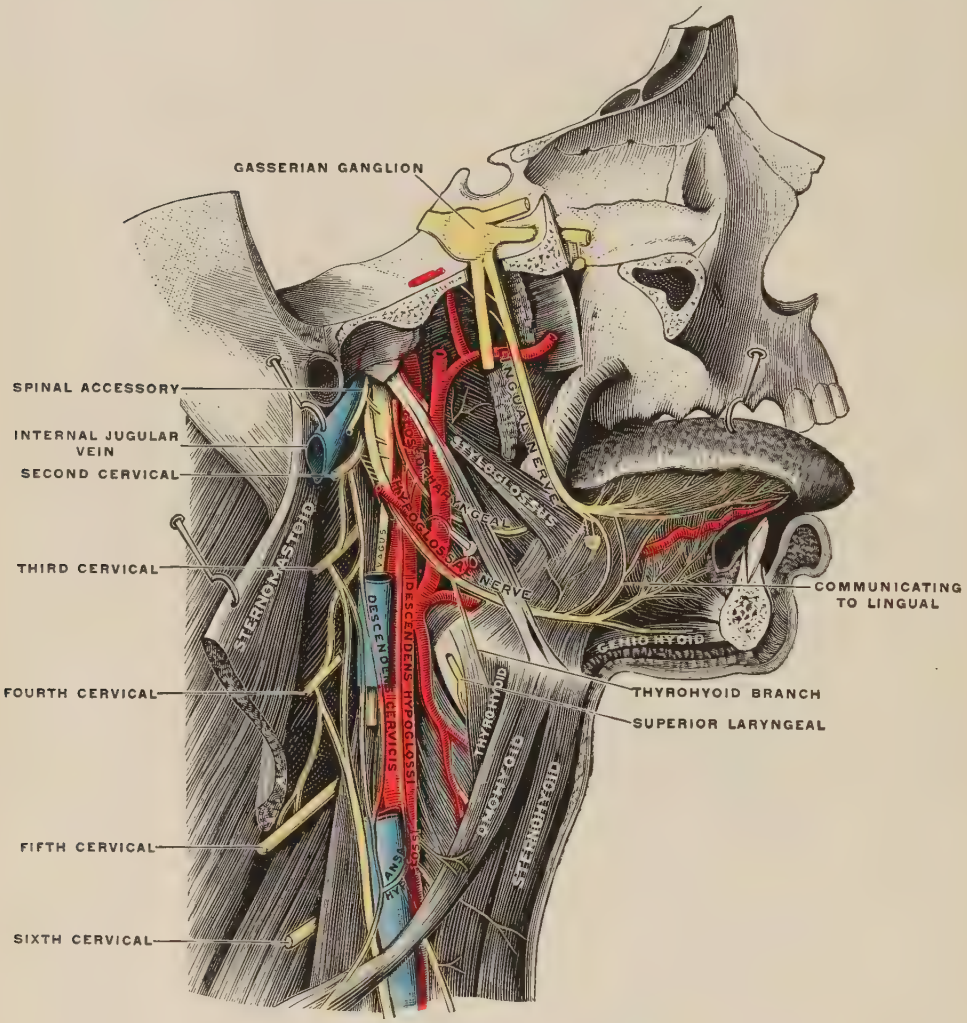

FIG. 686.—Nerves of the tongue. (Testut.)

muscle and between it and the mandible, supplying that muscle and the anterior belly of the digastric.

(*c*) The *Lingual* (wrongly called the gustatory) *Nerve* (Figs. 685, 686) lies at first under cover of the external pterygoid muscle, in front of and a little deeper than the inferior dental nerve, to which it is connected by a short branch. Here, also, it is joined at an acute angle by the chorda tympani nerve from the facial. It runs downward and forward on the internal pterygoid muscle and mandibular attachment of the superior constrictor of the pharynx, and reaches the inner side of the lower jaw, close under the last molar tooth, where it lies immediately under the mucous membrane, and may be readily reached by the surgeon, or injured in careless dentistry. It then lies between the hyoglossus and mylohyoid

muscles above the deep portion of the submaxillary gland, and crosses Wharton's duct obliquely as it bends upward toward the tip of the tongue.

Its *communicating branches* are those above mentioned—namely, to the inferior dental, and by the chorda tympani to the facial nerve, in addition to which there are the motor and sensory roots to the submaxillary ganglion, and one or two filaments which, under the mylohyoid muscle, join it with the hypoglossal nerve.

It distributes twigs to the mucous membrane of the floor of the mouth between the tongue and the gums, a branch to the sublingual gland (from the chorda tympani nerve), and ends by breaking up into fibres for the anterior two-thirds of the tongue, supplying chiefly the fungiform and filiform papillæ.

The Submandibular (Submaxillary) Ganglion (Fig. 685).—In a small triangular space under cover of the mylohyoid muscle, having the lingual nerve above, Wharton's duct below, and the submaxillary gland behind, lies a reddish body about the size of a pin-head, the *submandibular (submaxillary) ganglion*. *Its roots* are represented by one branch (or several) running downward and forward to it from the lingual, conveying to it chorda-tympani and trifacial fibres (motor and sensory), and by filaments which join it from the sympathetic plexus round the facial artery. It *distributes* branches to the submaxillary gland and Wharton's duct, and a branch to the sublingual gland, which reaches the gland by joining the lingual, assuming the appearance of another root. While this is the ordinary anatomical description of the submandibular ganglion and its connections, physiologic experiments on the dog and cat demonstrate the following connections, which are probably approximately correct for man: White rami communicantes from the second to the fifth thoracic nerves, pass to the corresponding ganglia of the sympathetic (see Sympathetic), but ascend in the sympathetic trunk without interruption till they reach its superior cervical ganglion. Here they form branching processes around sympathetic nerve-cells, from which new fibres spring, which reach the submandibular ganglion through the sympathetic plexus or the facial artery. These pass through the ganglion without change, and finally come into direct communication with the vessels and secreting cells of the submandibular and sublingual glands. Chorda fibres to the submandibular gland pass through or beside the submandibular ganglion without interruption to form branching processes around nerve-cells in the hilum of the submandibular gland, from which nerve-cells fresh fibres run to the vessels and secreting cells of the gland. The chorda fibres to the sublingual gland form branching processes around the nerve-cells of the submandibular ganglion, whence a new relay of fibres pass to the vessels and epithelial cells of the sublingual gland. Other fibres from this ganglion supply the anterior part of the tongue and floor of the mouth with vasodilator and secretory fibres.

The Otic Ganglion (Fig. 685).—The *otic* ("ear") *ganglion* is a small reddish-gray oval body, compressed from side to side, and about one-sixth of an inch in its long diameter. It is closely attached to or may surround the nerve to the internal pterygoid muscle, lying on the inner side of the mandibular trunk, close to the foramen ovale. Behind it is the middle meningeal artery, and on its inner side are the Eustachian tube and tensor palati muscle.

Its *motor* and *sensory* roots reach it through the nerve to the internal pterygoid muscle; but it is also connected with the facial and glossopharyngeal nerve through the small superficial petrosal nerve. From the plexus round the middle meningeal artery it receives its *sympathetic* root.

It *distributes* branches to join the auriculotemporal, by which route the parotid gland is supplied from the glossopharyngeal nerve; also muscular twigs to the tensor palati and tensor tympani, and a communicating filament to the chorda tympani nerve. Of the muscular fibres, most may be traced to the trunk of the mandibular division of the fifth nerve, without interruption in the ganglion-cells.

Physiologic experiments appear to show that the facial and glossopharyngeal roots of the otic ganglion form arborizations round the nerve-cells of this ganglion, and that from these cells fresh fibres pass by the auriculotemporal nerve

to the parotid gland, and possibly by the ophthalmic division of the fifth and buccal nerve to the lachrymal gland and mucosa of the cheek, respectively. The vasoconstrictor and sympathetic secretory connections of the parotid gland are similar to those of the submandibular gland (see Submandibular Ganglion).

The Sixth or Abducent Nerve.

The sixth nerve (Fig. 678) is purely motor, supplying the external rectus muscle of the eyeball. Its nucleus consists of a compact group of cells in the floor of the fourth ventricle, which forms the prominence known as the eminentia teres, and is in series with the third, fourth, and twelfth nuclei. Its most important connection is with the opposite oculomotor root by fibres which cross over and ascend in the posterior longitudinal bundle; and thus the nucleus of the sixth nerve supplies the external rectus of its own side directly, and the internal rectus of the opposite side indirectly, through the opposite third nerve.

The nerve roots run ventrolaterally through the pons to emerge as a flattened band from the groove between the oblongata and pons, just external to the ventral pyramid. This soon becomes rounded and pierces the dura at the side of the dorsum sellæ, behind and internal to the fifth nerve. It passes through the cavernous sinus, lying under the carotid artery, and gains the orbit through the sphenoidal fissure, where it lies between the two heads of the external rectus, beneath the inferior divison of the third nerve, and above the ophthalmic vein. It then runs forward on the inner surface of the external rectus muscle, which it supplies. In the cavernous sinus the sixth nerve receives filaments from the carotid plexus of the sympathetic, and, as it enters the orbit, it communicates with the ophthalmic division of the fifth.

The Seventh or Facial Nerve.

The seventh nerve (Fig. 687), excepting what will be described as the pars intermedia and chorda tympani, is purely motor to the face muscles. Its nucleus lies deeply embedded in the pons on a level with the striæ acusticæ. It is in line with the motor nuclei of the fifth and ninth. The root of this nerve pursues a very circuitous course through the pons, running first dorsally, then upward, next laterally above, and finally ventrally on the outside of the sixth nucleus. It emerges from the groove between the pons and oblongata, external to the olivary body and in the same transverse plane as the eighth nerve. Between its superficial origin and that of the eighth nerve, springs a small bundle called by Wrisberg the *pars intermedia*. The seventh, eighth, and pars intermedia run together outward into the internal auditory meatus, the seventh nerve lying in a groove on the upper and fore part of the auditory nerve, the pars intermedia being between them.

The *pars intermedia*, in spite of some apparent connections with the eighth nerve, has no real continuity with it. It arises from the upper part of the glossopharyngeal nucleus, joins the facial nerve immediately after the latter enters the aqueductus Fallopii, and is directly connected with the cells of the geniculate ganglion, described below. It appears to represent the sensory root of the seventh nerve, and forms the main constituent of the chorda tympani.

At the bottom of the internal auditory meatus the facial nerve enters the aqueductus Fallopii. In this canal it runs first outward between the cochlea and vestibule till it abuts on the inner wall of the tympanum; backward in the substance of the inner tympanic wall, above the fenestra ovalis, being here separated from the tympanum by a thin lamina of bone and the lining membrane of the middle ear; and lastly it turns somewhat acutely downward behind the pyramid and posterior tympanic wall to appear at the base of the skull through the stylomastoid foramen.

At the point where it bends sharply backward the bend is capped by a somewhat conical swelling called the *geniculate ganglion*.

On issuing from the petrous bone the facial nerve runs downward and for-

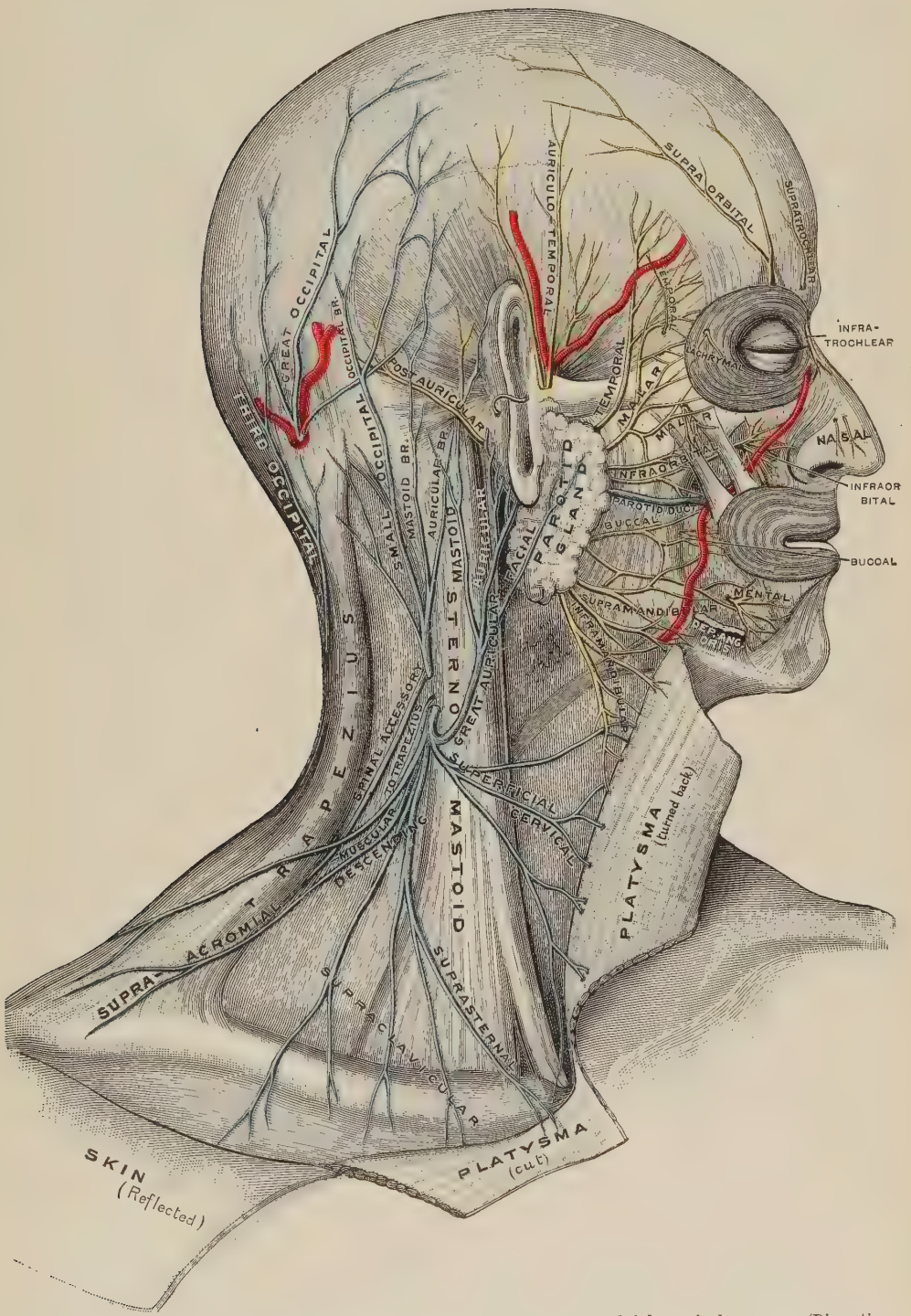

FIG. 687.—Facial nerve, cutaneous branches of fifth nerve, and superficial cervical nerves. (Dissection and drawing by W. Keiller.)

ward through the substance of the parotid gland, superficial to the external carotid artery, and behind the ramus of the lower jaw divides into a superior or *temporofacial* and an inferior or *cervicofacial division*, which break up into the numerous branches distributed to the face and submandibular region.

The *branches* of the facial nerve may be divided into three groups: (*A*) those given off in its course through the petrous bone, (*B*) those arising from the trunk at the base of the skull, and (*C*) those springing from its two great terminal divisions.

(*A*) Branches of the Facial Nerve in its Course through the Petrous Bone.—(*a*) Filaments connect the geniculate ganglion with the vestibular division of the auditory.

(*b*) The **great superficial petrosal nerve** is the largest of the three branches given off from the geniculate ganglion. It has been described with Meckel's ganglion, of which it forms the motor root.

(*c*) The **small superficial petrosal nerve** is also given off from the geniculate ganglion. It traverses a canal just external to the hiatus Fallopii, where it is joined by a branch from the tympanic plexus of the glossopharyngeal. It goes to the otic ganglion, leaving the cranium in the interval between the great wing of the sphenoid and petrous bone, or through a small canal beside the foramen ovale.

(*d*) The **external superficial petrosal nerve**, the last of the three branches from the geniculate ganglion, traverses a small canal in the petrous bone, and passes to the sympathetic plexus on the middle meningeal artery. It is not constant.

(*e*) A **branch to the stapedius** muscle is given off from the facial nerve as it descends behind the pyramid.

(*f*) The **chorda tympani nerve**, given off from the facial at the lower end of the aqueductus Fallopii and containing nearly the whole pars intermedia, enters the back part of the tympanum, crosses that cavity on the inner side of the handle of the malleus under a covering of the lining membrane, and gains the base of the cranium by a canal at the inner side of the Glaserian fissure. It runs downward and forward under cover of the external pterygoid muscle, and joins the lingual nerve, after receiving twigs from the otic ganglion. It is conducted by the lingual nerve to the submaxillary ganglion, and to the anterior two-thirds of the tongue. Its function is sensory to the tongue, and vasodilator and secretory to the submaxillary and sublingual glands.

(*g*) Just before leaving the aqueductus Fallopii the facial nerve gives a twig to the auricular branch of the pneumogastric, as it courses through the temporal bone.

(*B*) Branches given off between the Base of the Skull and its Final Division.—(*a*) The **posterior auricular nerve** commences just after the facial nerve has appeared at the base of the skull. It passes backward in the deep recess between the mastoid process and the external ear, communicating with the auricular branch of the pneumogastric, and sends a *vertical branch* upward to the retrahens aurem, attollens aurem, and small muscles on the cranial surface of the auricle, and a *horizontal branch* backward over the temporal bone to the occipitalis.

It communicates with the great auricular and small occipital nerves.

(*b*) Just below the preceding nerve arises the *nerve to the posterior belly of the digastric*. One of its branches frequently joins the glossopharyngeal nerve.

(*c*) The *nerve to the stylohyoid muscle* may be given off along with the last in one common trunk or separately at the same level.

(*d*) A **lingual branch** is described. It passes on the outer side of the stylopharyngeus muscle to the side of the pharynx, where it is joined by twigs from the glossopharyngeal. It then passes between the palatoglossus and the tonsil, and at the base of the tongue divides into filaments to the mucous membrane and palatoglossus and styloglossus muscles.

(*C*) The two great Terminal Divisions of the facial are distributed in a manner which may be summarized as follows:

Running forward in the substance of the parotid gland, in which they cross superficially to the external carotid artery and temporo-maxillary vein, the *temporofacial* division after receiving a stout branch from the auriculo-temporal nerve, subdivides into *temporal*, *malar*, and *infraorbital* branches, and the *cervicofacial division* into *buccal*, *supramandibular*, and *inframandibular* branches; the parotid duct separating the infraorbital from the buccal nerve. Leaving out the inframandibular nerve, these branches spread all over the face, each occupying mainly the region which its name indicates. They form, by interlacing with each other and with the various cutaneous branches of the fifth nerve, an intricate network called the *pes anserinus* ("goose's foot"), and supply all the face-muscles, including the buccinator, the frontalis, and the anterior muscles of the auricle.

The **inframandibular branch** emerges from the parotid gland behind the angle of the lower jaw, runs downward and forward under the platysma over the inframandibular and adjacent region of the neck, communicating freely with the great auricular and superficial cervical nerves, and supplying the platysma on its under surface.

It should further be said that the zygomatic muscles and levator labii superioris lie superficial to the infraorbital branch, and the risorius, depressor anguli oris, and depressor labii inferioris cross the supramandibular branch; but with these exceptions the branches of the facial nerve are superficial.

Branches from the Temporofacial Division.—The **temporal branch** of the temporofacial division of the facial nerve passes upward through the parotid gland, over the zygoma, and divides into branches, which supply the orbicularis palpebrarum, frontalis, corrugator supercilii, attrahens and attollens aurem, and small muscles of the front of the pinna. Its branches form numerous communications with each other, with the malar branch, and with the auriculotemporal, temporal, lachrymal, and supraorbital branches of the fifth nerve.

Note.—The branches to the frontalis and orbicularis palpebrarum are derived from the nucleus of the third nerve.

The **malar branch** runs forward over the malar bone, and is distributed mainly to the orbicularis palpebrarum. It sends filaments to both eyelids and communicates freely with the temporal and infraorbital branches of the facial, and the supraorbital, lachrymal, malar, and infraorbital branches of the fifth nerve.

The **infraorbital branch** emerges from the anterior border of the parotid gland just above the parotid duct, and divides into branches which radiate to the region of the face between the orbit and the mouth. They pass under the zygomatic muscles and the levator labii superioris, under the latter muscle forming with the infraorbital branch of the fifth nerve the *infraorbital plexus*. It communicates also with the neighboring facial branches (malar and buccal) and with the buccal, malar, nasal, and infratrochlear branches of the fifth; and supplies the zygomatic muscles, levator anguli oris, levator labii superioris, levator labii superioris alæque nasi, pyramidalis nasi, compressor naris, and depressor alæ nasi; also the buccinator and orbicularis oris.

Branches from the Cervicofacial Division.—The *cervicofacial division* runs downward and forward in the parotid gland crossing the external carotid artery. In the substance of the gland it receives fibres from the great auricular nerve. It divides into the following three branches:

The **buccal branch** emerges from the parotid gland under the parotid duct, crosses the masseter muscle, and breaks up into twigs to the buccinator and orbicularis oris. It communicates with neighboring branches of the facial and with the long buccal nerve.

The **supramandibular branch** crosses the masseter muscle and facial vessels on the body of the mandible, and under the risorius and depressors of the lower lip passes toward the chin. It supplies the risorius, depressor anguli oris, depressor labii inferioris, and levator menti, and communicates with the buccal and inframandibular branch of the facial and with the mental branch of the inferior dental nerve.

The **inframandibular branch** has already been sufficiently described.

(*Note.*—The fact that the frontalis, orbicularis palpebrarum, and corrugator supercilii, escape in cortical facial paralysis, furnishes clinical evidence of a connection between the facial nerve and the oculo-motor nucleus, which probably takes place through the posterior longitudinal bundle. The association of the movements of the lips and tongue, and the involvement of the orbicularis oris in bulbar paralysis suggest that this muscle is supplied from the hypoglossal (twelfth) nucleus. This is probably effected by a communication from the nucleus of the twelfth to the facial nerve through the posterior longitudinal fasciculus.)

The Eighth or Auditory Nerve.

Nucleus of the Eighth or Auditory Nerve (Fig. 688).—The auditory nerve springs from the lower border of the pons, just external to the facial, by two bundles. The more lateral or posterior of these is mainly distributed to the

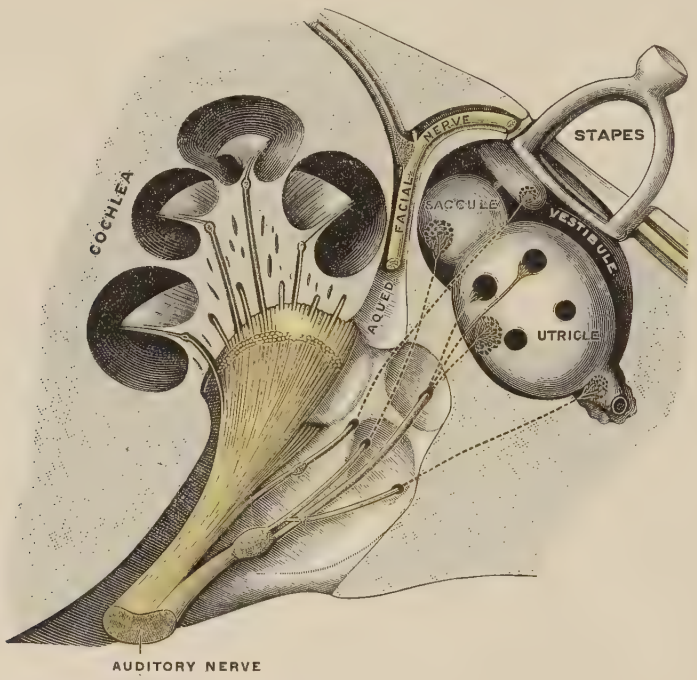

FIG. 688.—Distribution of the auditory nerve. (Semidiagrammatic.) (Testut.)

cochlea, and is regarded as the true nerve of hearing; the mesial or anterior bundle supplies the semicircular canals (except the posterior) and its function is to convey the sense of equilibrium. As these roots plunge into the pons, they separate so as to pass one on each side of the restiform body.

The *lateral* or *cochlear root* is divisible into several parts. The outer fibres pass dorsally along the outer side of the restiform body, and enclose a large number of cells, similar to those of a spinal ganglion, which form the *ganglion of the cochlear root.* Thence fibres pass dorsally to end in the dorsal nucleus and striæ medullares. The more mesial fibres of the cochlear root come into relation with a triangular group of cells, which lies ventral to the restiform body and forms the *accessory* or *ventral auditory nucleus.* Other fibres pass by the trapezium to the superior olive of the same and opposite sides. It is also connected with the flocculus. The *mesial* or *vestibular root* passes to the inner side of the restiform body, between it and the ascending root of the fifth nerve. When it reaches the dorsomesial side of the restiform body, most of its fibres bend caudally, and run

along the inner side of the restiform body and cuneate nucleus forming the *ascending root.* The fibres of this ascending root probably end in arborizations round the cells of the cuneate nucleus. The rest of the fibres of the vestibular root pass dorsally to end in the *internal auditory* or *dorsal nucleus,* which is a large group of cells corresponding in position to the tuberculum acusticum, and lying close to the floor of the ventricle dorsomesially to the restiform body. This nerve is homologous with the dorsal root of a spinal nerve, and the ganglion radicis cochlearis, spiral ganglion of the cochlea, and vestibular ganglion together represent an intervertebral ganglion. On emerging from the pons the two roots unite to form one trunk, again dividing at the bottom of the internal auditory meatus. The trunk runs upward, outward, and forward round the middle cerebellar peduncle to the internal auditory meatus, where it becomes concave on its upper surface and lodges the facial nerve, pars intermedia, and internal auditory artery in the groove so formed. It is united to these structures by loose connective tissue, which contains no nerve-fibres. At the bottom of this canal it divides into an upper, *vestibular division* to the utricle and ampullæ of the superior and external semicircular canals, and a lower, *cochlear division* to the saccule, ampulla of the posterior semicircular canal, and cochlea.

Ninth, Tenth, and Eleventh Nerves.

Nuclei of the Ninth, Tenth, and Vagus-accessory Portion of the Eleventh Nerves.—The various origins, motor and sensory, of these three nerves being all continuous columns or series of cells and fibres, they are best described together, the distinction between the nerves being a matter of higher or lower point of origin and ultimate distribution.

The *sensory nucleus* is an elongated column of cells mainly corresponding in position to the inferior fovea and trigonum vagi (or ala cinerea) in the floor of the fourth ventricle. It extends the whole length of the oblongata. In the lower part it lies dorsally to the twelfth nucleus, and dorso-laterally to the central canal; but as the central canal opens out into the fourth ventricle, it is shifted so as to lie laterally to the nucleus of the twelfth nerve, and close to the floor of the ventricle. From it bundles of fibres pass ventro-laterally to emerge from the side of the oblongata, between the olivary and restiform bodies, or further down between the last named structure and the lateral column. The upper bundles form the sensory fibres of the glossopharyngeal nerve, the lower are grouped into the pneumogastric and pars accessoria ad vagum.

The *ascending vago-glossopharyngeal* root (funiculus solitarius, fasciculus rotundus) is a well-marked rounded bundle of fibres, which ascends on the outer side of the sensory nucleus from the funiculus gracilis and gelatinous substance of Rolando. Its main connections seem to be with the funiculi graciles of both sides and with the opposite fillet. It contributes fibres to the pneumogastric, but mainly emerges as the upper bundle of the glossopharyngeal nerve.

The *motor nucleus* (nucleus ambiguus) is a column of large multipolar cells, undoubtedly representing part of the ventral horn of the spinal cord. It lies deeply in the formatio reticularis of the oblongata in line with the nucleus of the facial nerve. From it the motor roots of the three nerves under consideration pass in bundles, first dorsally toward the floor of the ventricle, and then outward and ventrally in line with the sensory bundles.

Connection of the Vagus-accessory with the Twelfth Nucleus.—The involvement of the palate and vocal cords in bulbar paralysis appears to indicate that the motor fibres to these structures, which reach them through the vagus-accessory, are derived from the nucleus of the twelfth nerve.

Nucleus of the Spinal Portion of the Eleventh Nerve.—The spinal portion of the spinal accessory is a purely motor nerve. It arises from a distinct column of cells in the ventral horn of the cervical spinal cord. From this bundles of nerve-fibres pass upward for a little way, then dorso-laterally through the gray

matter, to emerge from it at the junction of the two horns ; thence outward through the crossed pyramidal tract and direct cerebellar tract to their superficial origin, between the ligamentum denticulatum and dorsal nerve roots. It extends as low as the sixth or seventh cervical nerve.

The Ninth or Glossopharyngeal Nerve.

The *glossopharyngeal* ("tongue-pharynx") *nerve* (Fig. 689) is formed by the union of the upper five or six bundles of nerve-fibres, which arise from the side of the oblongata between the restis and the upper part of the lateral tract.

It passes outward in front of the flocculus to the jugular foramen, by the middle compartment of which it leaves the cranium antero-internally to the vagus and spinal accessory, and in a special sheath of dura. In this foramen it lies in a groove or canal on the posterior border of the petrous bone, and here it possesses two successive gangliform enlargements, the jugular ganglion and petrous ganglion, respectively. It then passes for a short distance downward between the internal carotid artery and internal jugular vein, lying at first close to the vagus. It soon winds forward, under the styloid process and its muscles and superficial to the internal carotid artery, till, reaching the lower border of the stylopharyngeus muscle, it runs forward on it to the back of the tongue, where, under cover of the hyoglossus, it breaks up into its terminal branches.

The **jugular ganglion** is situated at the upper margin of the jugular foramen. It is very small, not constant, only involves the posterior fibres of the nerve, and gives off no branches. It is regarded as a displaced portion of the lower ganglion, and together they are taken to represent the ganglion on the sensory root of a spinal nerve.

The **petrous ganglion** lies in a groove on the petrous bone at the lower margin of the jugular foramen. It is not more than one-fourth of an inch long, and involves the whole nerve. It gives off the tympanic nerve, and twigs which communicate with the pneumogastric and sympathetic.

Branches.—(*a*) **Meningeal branches** are distributed to the pia and arachnoid membranes within the cranium.

(*b*) The **tympanic branch** (*nerve of Jacobson*) is a minute but important nerve, which is given off from the petrous ganglion. It enters the tympanum through a small foramen situated on the ridge between the carotid canal and jugular fossa, and on the promontory divides into several branches, which form the *tympanic plexus*. Of these the principal branch pierces the roof of the tympanum *to join the small petrosal nerve*, of which it probably forms the main constituent. By this means glossopharyngeal fibres pass to the otic ganglion and so to the parotid gland. Another filament joins the great superficial petrosal nerve ; and a twig called the *small deep petrosal nerve* joins the carotid plexus of the sympathetic. In addition to these, filaments are distributed to the lining membrane of the *mastoid cells*, the *fenestra ovalis*, *fenestra rotunda*, and *Eustachian tube*.

(*c*) Three **communicating branches** arise from the petrous ganglion, namely, filaments to the upper cervical ganglion of the sympathetic, the auricular branch of the vagus, and to the root-ganglion of that nerve. Immediately below the petrous ganglion a twig is given off to the lingual branch of the facial nerve.

(*d*) A **muscular branch** is supplied to the stylopharyngeus, which also sends filaments to the mucous membrane of the pharynx.

(*e*) **Pharyngeal branches**, two or three in number, spring from the nerve just below the petrous ganglion. The main branch passes downward over the internal carotid artery, and joins the pharyngeal branch of the vagus to form the pharyngeal plexus with the assistance of branches from the superior cervical ganglion of the sympathetic.

(*f*) The **tonsillar branches** are two or three nerves which ascend under the hyoglossus to form a plexus on the tonsil called the *circulus tonsillaris*, from which twigs proceed to the soft palate.

(*g*) The **lingual branches** supply the posterior third of the dorsum of the tongue, and the side of the tongue over its posterior half, where they join the lingual nerve. The circumvallate papillæ receive the most minute nerve-supply.

The posterior branches also supply the anterior surface of the epiglottis.

Testut describes, in addition to the above, *carotid branches* to join the carotid plexus and *muscular twigs* to the digastric, stylohyoid, and styloglossus muscles.

The Tenth, Vagus, or Pneumogastric Nerve.

The tenth, *vagus* ("wandering"), or pneumogastric ("lung-stomach") nerve (Fig. 689) is formed by the junction of from ten to fifteen filaments, which arise from the oblongata between the restiform body and lateral tract, in series with and just below the roots of the glossopharyngeal nerve.

They form together a flattened band which passes outward and a little forward beneath the flocculus to reach the jugular foramen, through which it leaves the cranium between the inferior petrosal and lateral sinuses, in the same sheath of dura as the spinal accessory, and external to and a little behind the glossopharyngeal nerve. In the jugular foramen its *root-ganglion* is found, and half an inch below this is a second ganglion called the *ganglion of the trunk*. This last is formed as the nerve runs downward from the base of the skull between the internal jugular vein and the internal carotid artery. In this situation, that is, immediately below the cranial base, the hypoglossal nerve winds spirally round the vagus, lying first internally, then passing behind and round across its outer side. They are united to each other by fibrous tissue and some nerve-fibres which pass between the trunk ganglion and the hypoglossal nerve. Here also the superior cervical ganglion of the sympathetic and spinal accessory lie behind the vagus, and the glossopharyngeal nerve in front of it. The pneumogastric now passes downward, behind and between the internal carotid artery and internal jugular vein, and lower down maintains the same relation to that vein and the common carotid artery, being enclosed within the same fibrous sheath as these vessels.

From the level of the clavicle downward the courses of the two nerves differ considerably, the differences, however, being readily explained by the mode of development of the great vessels, stomach, etc.

The **Right Pneumogastric Nerve** enters the thorax by passing in front of the first portion of the subclavian artery, and between it and the right brachiocephalic vein. Bending backward to the side of the trachea, it gains the posterior surface of the root of the right lung, on which it breaks up into a coarse meshwork which forms, with fibres from the sympathetic, the *posterior pulmonary plexus*. From this plexus two distinct cords represent the continuation of the vagus to the right side of the œsophagus.

Around this tube a new plexus is formed, called the *œsophageal plexus*, in which a free interchange of fibres occurs between the nerves of both sides.

Again converging to form a single trunk the right vagus passes to the back of the œsophagus at its lower extremity, and, entering the abdomen through the œsophageal opening in the diaphragm behind that tube, spreads out on the posterior surface of the stomach.

The **Left Pneumogastric Nerve** enters the thorax between the left common carotid and left subclavian arteries, and behind the left brachiocephalic vein, and then passing a little backward crosses the root of the subclavian artery and the left side of the aortic arch under cover of the pleura. Reaching the back of the root of the left lung, it behaves on the left side as its fellow does on the right side; but its terminal trunk lies in front of the œsophagus, and its final branches supply the front of the stomach.

The *ganglion of the root* is formed within the jugular foramen and is about one-sixth of an inch long. It has branches by which it communicates with the petrous ganglion of the glossopharyngeal, the spinal accessory nerve, the superior

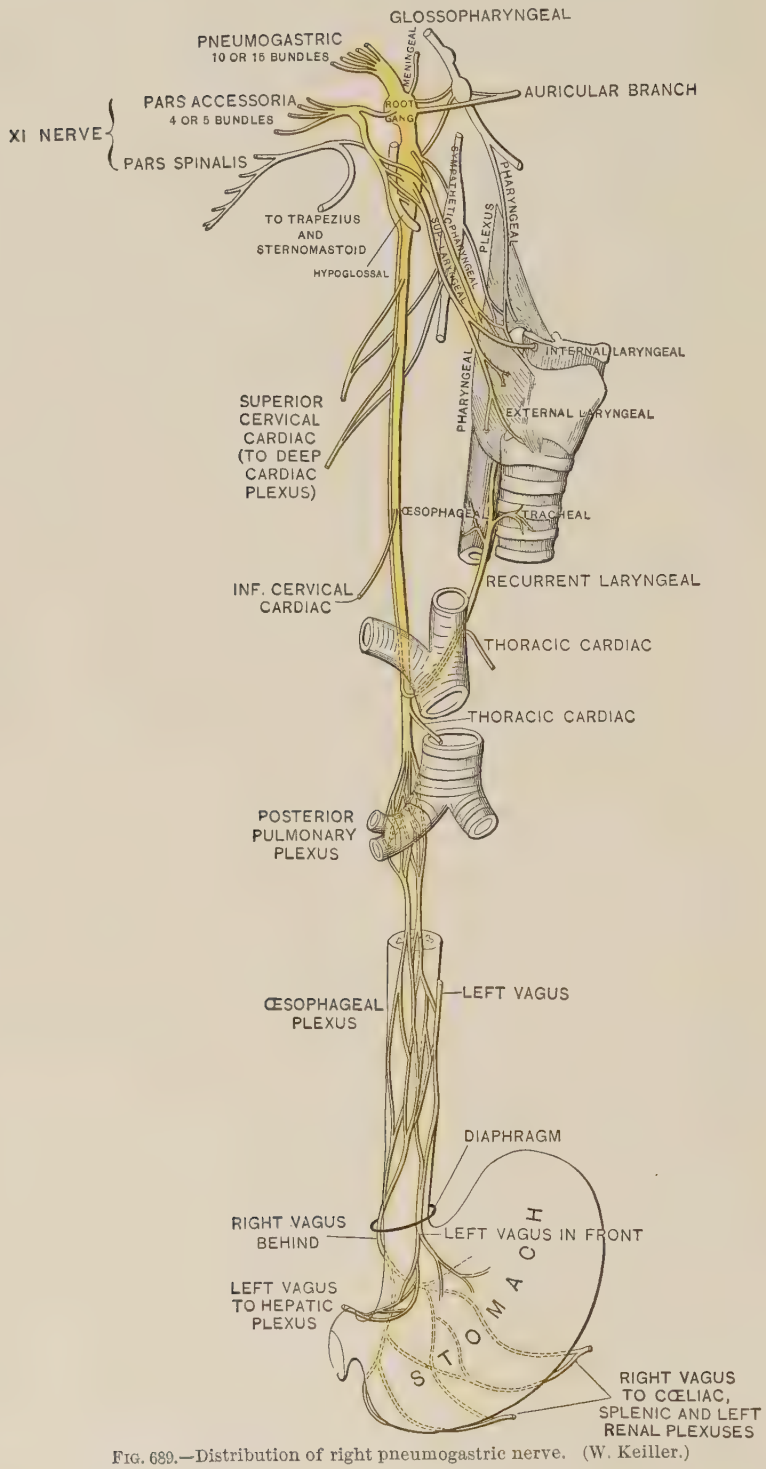

FIG. 689.—Distribution of right pneumogastric nerve. (W. Keiller.)

cervical ganglion of the sympathetic, and two branches of distribution, namely, a recurrent filament to the dura and Arnold's nerve.

The *ganglion of the trunk* is fusiform in shape, one-half to three-quarters of an inch long, and about one-sixth of an inch thick. The spinal accessory nerve is closely applied to it, communicates with it by branches entering its substance, and contributes fibres to the pharyngeal and superior laryngeal nerves, which course over its outer surface. The hypoglossal nerve winds round it and communicates with it. It also communicates with the superior cervical ganglion of the sympathetic, and with the loop between the first and second cervical nerves; and the pharyngeal and superior laryngeal branches of the pneumogastric are derived partly from this ganglion, partly from the spinal accessory.

BRANCHES.—(*a*) The **communicating branches** have just been sufficiently noticed with the two ganglia.

(*b*) The **recurrent branch** is given off from the root-ganglion. It is distributed to the dura round the jugular foramen.

(*c*) The **auricular branch**, or *nerve of Arnold* (Fig. 690), arises from the root-ganglion. After receiving a filament from the petrous ganglion of the glossopharyngeal, it passes backward on the outer surface of the jugular sinus, and enters a small canal in the jugular fossa of the petrous bone. In this canal it arches backward close to the inner side of the aqueductus Fallopii, communicating with the facial nerve, and curving downward, issues from the temporal bone through the auricular fissure, between the external auditory meatus and the mastoid process. It now divides into two parts, one of which joins the posterior auricular branch of the facial nerve, while the other supplies the lower and back part of the external auditory canal and the skin on the back of the pinna.

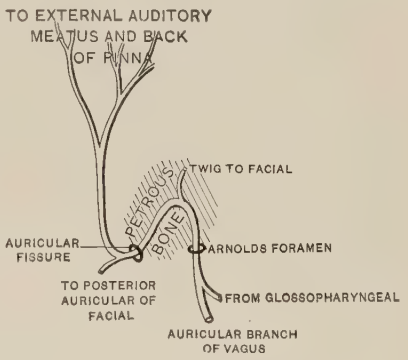

FIG. 690.—Plan of Arnold's nerve. (W. Keiller.)

(*d*) The **pharyngeal branch** may be single, or represented by two or three, of which one is usually large. It comes off from the trunk-ganglion, and is largely formed of fibres derived from the pars accessoria of the eleventh nerve. Running downward and forward superficial to the internal carotid artery, it winds inward behind the external carotid artery to the back of the pharynx, where it joins the pharyngeal plexus.

(*e*) The **superior laryngeal nerve**, springing also from the ganglion of the trunk, is, like the last, derived largely from accessory fibres. It is much larger than the pharyngeal branch, and passes downward and forward on the deep surface of the internal and external carotid arteries. After receiving communicating branches from the superior cervical ganglion of the sympathetic and pharyngeal plexus, it divides into the internal and external laryngeal nerves.

The *internal laryngeal branch* perforates the thyrohyoid membrane under cover of the thyrohyoid muscle, accompanied by the laryngeal branch of the superior thyroid artery. It breaks up into diverging branches which supply the mucous membrane on both surfaces of the epiglottis, the interior of the larynx, and the back of the cricoid cartilage, the descending branch forming a loop behind the ala of the thyroid cartilage with the recurrent laryngeal nerve.

The *external laryngeal branch* runs downward under the sternothyroid muscle to end mainly in the cricothyroid muscle, supplying on the way branches to the inferior constrictor of the pharynx, pharyngeal plexus, laryngeal mucous membrane, and a twig which joins one of the cardiac branches of the sympathetic.

(*f*) The **inferior or recurrent laryngeal nerve** differs somewhat in its course on the two sides of the body (Fig. 691).

On the *right side* it arises at the root of the neck, in front of the subclavian artery, winds beneath, and then upward and inward behind that vessel, and behind the common carotid and inferior thyroid arteries, to the recess between the œsophagus and trachea. At the lower border of the cricoid cartilage it enters the pharynx by passing beneath the inferior constrictor.

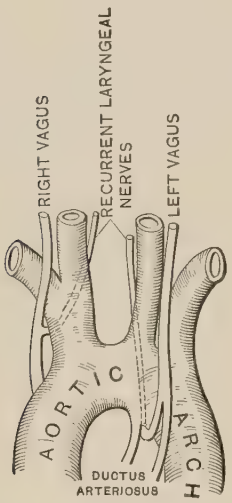

FIG. 691.—Relations of pneumogastric and recurrent laryngeal nerves to the great vessels. (W. Keiller.)

Under cover of the ala of the thyroid cartilage it divides into branches to all the intrinsic laryngeal muscles except the cricothyroid, and to the mucous membrane of the larynx below the rima glottidis, joining the internal laryngeal nerve.

In its course upward it gives off thoracic cardiac branches, twigs to the inferior cervical ganglion of the sympathetic, œsophageal and tracheal branches, and muscular twigs to the inferior constrictor of the pharynx.

The *left recurrent laryngeal nerve* springs from the vagus as it crosses the arch of the aorta, winds round the concavity of the arch just behind the ductus arteriosus, and runs upward behind the origin of the left common carotid artery to reach the œsophagus. The rest of its course is similar to that of the right nerve.

(*g*) **Cervical cardiac and thoracic cardiac branches** are given off by each pneumogastric nerve. There are usually two superior cervical cardiac branches, one inferior cervical cardiac, and two or more thoracic cardiac branches—the latter arising from the trunk and recurrent nerve on the right side, from the recurrent nerve only on the left side. These for the most part join cardiac branches of the sympathetic, and all, with one exception, go to the deep cardiac plexus, the left inferior cervical cardiac nerve being the only one which goes directly to the superficial cardiac plexus.

The *superior cervical cardiac nerves* join the corresponding branches of the sympathetic beneath the carotid sheath.

The *left inferior cervical cardiac nerve* descends on the left of the horizontal portion of the aortic arch, having the left phrenic nerve in front of it and the superior cervical cardiac branch of the sympathetic behind it. It joins the superficial cardiac plexus.

The *right inferior cervical cardiac nerve* runs downward on the side of the brachiocephalic artery and trachea to the deep cardiac plexus.

The *right thoracic cardiac nerves*, two or three in number, arise from the vagus trunk and from the recurrent laryngeal nerve. They run inward to the bifurcation of the trachea, where the deep cardiac plexus is formed. *On the left side* the thoracic cardiac branches spring from the recurrent laryngeal nerve only.

(*h*) The **pulmonary branches** form two plexuses, one in front of and one behind the root of the lung.

The *anterior pulmonary plexus* is small, consisting of a few filaments which spring from the vagus above the root of the lung, and form a meshwork in front of the bronchus, uniting with sympathetic fibres from the pulmonary artery.

The *posterior pulmonary plexus* is large and important, involving the whole trunk of the nerve. Behind the root of the lung the vagus spreads out into an intricate network and is supplemented by fibres from the second, third, and fourth thoracic ganglia of the sympathetic; from these plexuses branches accompany the bronchi in all their ramifications. A free interchange of fibres takes place between the plexuses of the two sides.

(*i*) **Œsophageal Branches.**—Above the pulmonary plexus many small twigs are distributed to the œsophagus both from the trunk of the vagus and from its recurrent laryngeal branch. Below that point the right and left vagi unite in forming a long-meshed plexus round the tube, from which its muscular and mucous coats get their nerve supply.

(*j*) **Abdominal Branches.**—The *left vagus* distributes fibres all over the front of the stomach, large branches accompanying the coronary artery on its small curvature, and so joining the hepatic plexus of the sympathetic. The *right vagus* supplies the posterior surface of the stomach, sending branches to the cœliac, splenic, and left renal plexuses of the sympathetic.

The Pharyngeal Plexus.—Two or three twigs from the superior cervical ganglion of the sympathetic, the pharyngeal branches of the glossopharyngeal and vagus, and branches from the external and recurrent laryngeal nerves, unite in forming a plexus on the surface of the constrictors of the pharynx, from which the pharyngeal muscles and mucous membrane are supplied, as well as the levator palati and azygos uvulæ. The motor nerves are derived from the pars accessoria.

The Eleventh or Spinal Accessory Nerve.

The *eleventh nerve* (Fig. 689) consists of two parts, an *accessory portion to the pneumogastric* (pars accessoria ad vagum) and a *spinal portion* (pars spinalis).

The **Accessory Portion** is formed by some four or five fasciculi, which spring from the oblongata in series with the pneumogastric roots. They unite to form a trunk which, with the spinal portion, to which it is united by some fibres or with which it may be entirely joined for a short distance, leaves the cranium in the same sheath of dura with the pneumogastric. In the jugular foramen it sends fibres to the root-ganglion of the vagus, and then partly joins the trunk-ganglion of that nerve; but many of its fibres are continued over the surface of the trunk-ganglion into the pharyngeal and superior laryngeal nerves, and down the vagus trunk itself into the recurrent laryngeal nerve. It will be seen that most of the motor fibres of the pneumogastric are derived from its accessory portion.

The **Spinal Portion** of the spinal accessory arises by a long series of roots from the lateral column of the spinal cord extending as low as the sixth or seventh cervical nerve-roots. They issue from the lateral column between the attachment of the ligamentum denticulatum and the posterior nerve-roots, approaching closer to the latter as they ascend. They join to form an ascending trunk, which enters the cranium, and unites wholly or partly with the accessory portion; but, beneath the jugular foramen, leaves the pars accessoria and bends acutely backward, usually superficially to the internal jugular vein, to enter the deep surface of the sternomastoid muscle, which it supplies, and where it communicates with a branch from the second cervical nerve. Emerging from the posterior border of the sternomastoid, it crosses the posterior triangle of the neck obliquely to end under the trapezius, a short distance above the clavicle. On the deep surface of the trapezius it is joined by fibres from the third and fourth cervical nerves, thus forming the subtrapezial plexus, from which that muscle is supplied.

The Twelfth or Hypoglossal Nerve.

The twelfth or hypoglossal ("under the tongue") nerve (Fig. 686) is exclusively motor in function, and its nucleus lies in series with those of the third, fourth, and sixth nerves. Its upper part lies close to the floor of the fourth ventricle near the median sulcus in the elevation known as the trigonum hypoglossi; lower down it lies ventro-lateral to the central canal. It extends the whole length of the oblongata, and its cells are large and multipolar like those of the anterior horn. The fibres spring in two vertical series of small bundles from the ventral aspect of

the nucleus, and running ventrally and a little outward through the inferior olive (with which, however, they have no connection) emerge in a linear series of from ten to twelve fasciculi along the groove between the olive and ventral pyramid.

Connections of the Hypoglossal.—Its main connections are as follow: 1. Commissural fibres join the nuclei of the two sides; 2. Motor fibres pass from the nucleus of the hypoglossal by the posterior longitudinal bundle to join the pars accessoria ad vagum and the genu of the facial nerve of the same side; 3. Fibres pass to the opposite posterior longitudinal bundle.

The roots of the twelfth nerve pass outward above the vertebral artery, and opposite the anterior condylar foramen pierce the dura through two distinct foramina in two bundles. In its passage through this foramen the two bundles unite to form one trunk, which at first lies very deeply on the inner side of the internal carotid artery and pneumogastric nerve. It descends in a spiral manner round the trunk-ganglion of the latter nerve, and between the internal jugular vein and internal carotid artery, being closely united to the ganglion by fibrous tissue, and receiving some communicating branches from it. It now appears at the lower border of the digastric muscle, and curves forward under the occipital artery (by the sternomastoid branch of which vessel it is kept in place) and across the external carotid artery. It reaches the upper border of the great cornu of the hyoid bone, where it lies on the middle constrictor of the pharynx and above the lingual artery. Passing under cover of the posterior belly of the digastric and the stylohyoid muscles, it lies on the hyoglossus muscle just above the central tendon of the digastric. Here it is accompanied by the lingual vein, and is separated from the lingual artery by the hyoglossus. Passing beneath the mylohyoid, it curves upward on the genioglossus, communicating in a loop with the lingual nerve and terminating beneath the tip of the tongue.

The branches of this nerve are divisible into two sets, namely, true hypoglossal branches which are distributed exclusively to the extrinsic and intrinsic muscles of the tongue, and branches which are really derived from the cervical plexus, and are only adherent to the hypoglossal nerve for some part of their course.

True Hypoglossal Branches.—(*a*) *Communicating branches* unite the hypoglossal nerve with the trunk-ganglion of the vagus and superior cervical ganglion of the sympathetic, and in a manner to be explained later, with the loop between the first and second cervical nerves. At the tip of the tongue it communicates with the lingual nerve, and a small twig, called the *lingual branch of the vagus*, joins it from the pharyngeal plexus.

(*b*) The *meningeal branch* is given off in the anterior condylar foramen, and enters the cranium to supply the dura round the foramen magnum and diploë of the occipital bone.

(*c*) *Muscular branches* are distributed beneath the mylohyoid to the hyoglossus, styloglossus, genioglossus, and geniohyoid, and also to the intrinsic muscles of the tongue.

Branches of the Cervical Plexus adherent to or associated with the Hypoglossal Nerve (Fig. 698).—A considerable branch from the loop between the first and second cervical nerves joins the hypoglossal just beneath the base of the cranium. It is incorporated with the hypoglossal nerve till it winds round the occipital artery, where part of the cervical branch leaves the hypoglossal under the name of the *descendens hypoglossi*. A smaller branch is given off lower down to supply the thyrohyoid muscle, and the remainder of this cervical nerve accompanies the hypoglossal under the mylohyoid to supply the geniohyoid muscle.

The *descendens hypoglossi* springs from the trunk of the twelfth nerve where it crosses the occipital artery, and passes downward and a little forward on the sheath of the great vessels and beneath the sternomastoid for a variable distance, but usually to nearly on a level with the cricoid cartilage. Here it forms a loop with the *ramus cervicalis descendens* (communicans hypoglossi), which is formed by the union of two branches from the second and third cervical nerves respectively.

This loop is called the *ansa hypoglossi* or *ansa cervicalis*. From the descendens hypoglossi a twig is given to the anterior belly of the omohyoid. From the loop, branches are given to the sternohyoid, sternothyroid, and posterior belly of the omohyoid, the last twig passing backward through the loop of deep cervical fascia, which binds down the central tendon of its muscle. The nerves to the sternohyoid and sternothyroid enter the posterior borders of these muscles low down, and may extend into the thorax and communicate with the phrenic nerve.

THE SPINAL NERVES.

In introducing the subject of the cranial nerves we entered pretty fully into the mode of formation of a spinal nerve, taking it as the type on which the

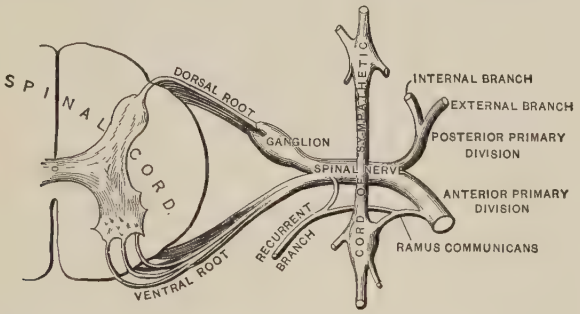

FIG. 692.—Plan of the constitution of a spinal nerve. (W. Keiller.)

cranial nerves, also, are more or less closely planned. We refer the student again to page 581, and here supplement what is there said by additional matter necessary to the present subject.

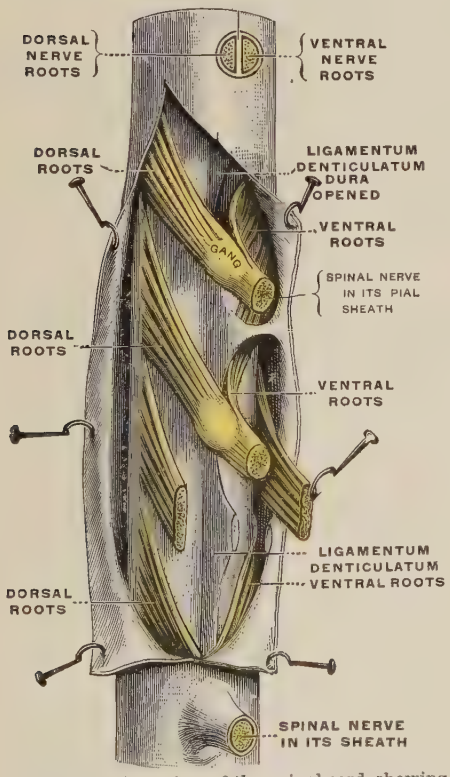

FIG. 693.—A portion of the spinal cord, showing its right lateral surface. The dura is opened and arranged to show the nerve-roots. (Testut.)

Fig. 692 illustrates the mode of origin and constitution of a spinal nerve. It is seen to spring from the spinal cord by two roots, ventral and dorsal.

The *ventral root* is *motor* in function, and springs from the ventro-lateral aspect of the cord by from four to six bundles. They unite to form two strands, which enter a sheath of dura, in which they are at first separated from the dorsal root by a fibrous septum. Within the sheath and as they traverse the intervertebral foramen, the ventral root unites with the dorsal to form a spinal nerve.

The *dorsal roots*, usually larger than the ventral, are *sensory* in function, and spring from the dorso-lateral aspect of the cord by from six to eight fasciculi, which with their fellows are arranged in a single linear series all down the cord. They unite to form two bundles and within the dural sheath enter a ganglion, from which they emerge as one bundle, and immediately join the ventral root to form a spinal nerve.

A *spinal ganglion* is an ovoid body, bifid at its proximal extremity where the

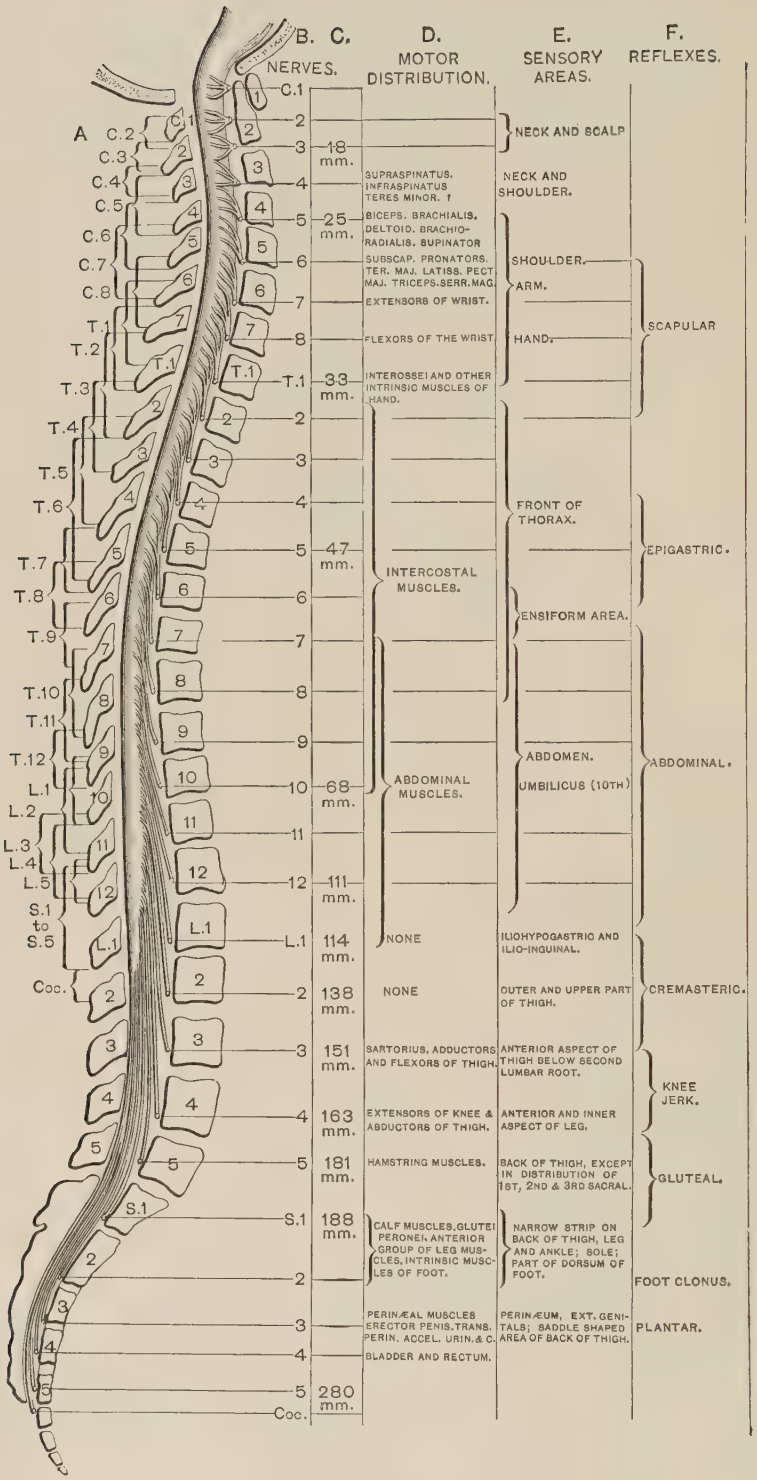

FIG. 694.—Topography and distribution of the spinal nerve-roots.

two bundles of dorsal nerve-roots enter it. It consists of bipolar nerve cells, one pole or process of each cell forming the peripheral portion of a sensory nerve fibril, the other pole or process forming its central continuation. With the exceptions to be mentioned, they are placed in the intervertebral foramina immediately beyond the point where the roots enter the dural sheath provided for them by the theca vertebralis.

The ganglia of the first and second cervical nerves lie on the laminæ of the atlas and axis respectively; those of the sacral and coccygeal nerves are found within the spinal canal, at a variable distance from their points of emergence from it.

The *course of the nerve-roots* within the spinal canal varies considerably at different levels, the growth of the spinal cord not being equal to that of the vertebral column; for, while the cord occupies the whole length of the canal in the fœtus, it only reaches as low as the body of the first lumbar vertebra in the adult. Thus the first spinal nerve ascends slightly to reach the space between the atlas and occipital bone, through which it leaves the spinal canal; the second and third are nearly horizontal; the fourth runs obliquely downward and outward, and the obliquity of the others within the vertebral canal steadily increases from here downward till the nerve-roots of the lumbar and sacral nerves run vertically downward for an increasing distance, thus forming the cauda equina. This will be easily appreciated by a glance at Figures 694 and 695.

Topographical Anatomy of the Cord and Spinal Nerve-roots (Fig. 694).—It is important for surgical purposes to determine the relationship between the bony landmarks furnished by the spines of the vertebræ, and the superficial origins of the spinal nerves. The main surgical data are graphically described in Fig. 694. The brackets in column A show the extreme limits between which in different subjects examined by Reid each group of nerve-roots was found to arise. B shows each nerve cut off at the level of its intervertebral foramen, thus affording a ready estimate of the obliquity of its course in the neural canal; C gives the vertical distance in millimeters which in Testut's case of a subject of eighteen years of age separated the superficial origin of each of the nerves marked from its intervertebral foramen; and the other columns will be readily intelligible to the senior student. It is be noted that the distribution marked in D, E, and F is only broadly true and does not pretend to anatomical minuteness; but it is for that reason all the more valuable for clinical purposes.

Nomenclature (Fig. 695).—There are thirty-one pairs of the spinal nerves, namely, eight cervical, twelve thoracic, five lumbar, five sacral, and one coccygeal. It will be noted that these numbers correspond with the number of vertebræ in each region except the cervical nerves, which are one in excess. The first cervical nerve leaves the vertebral canal above the dorsal arch of the atlas, between it and the occipital bone; the eighth passes through the intervertebral foramen between the seventh cervical and first thoracic vertebræ. Thus the first seven cervical nerves are named from the vertebræ below them; the eighth cervical has no corresponding vertebra, and the thoracic, lumbar, and other nerves are named from the vertebræ above them.

Mode of Distribution.—A spinal nerve, formed as above by the union of a motor and a sensory root, is a short trunk, which, immediately after its exit from the intervertebral foramen, gives off a small recurrent branch, and then divides into a ventral and a dorsal primary division (Fig. 692).

The *dorsal primary divisions*, except those of the first and second cervical nerves, are smaller than the ventral. They pass backward and divide into two branches, external and internal. They supply the skin of the back of the head, neck, trunk, and gluteal region, and the muscles which act directly upon the spinal column.

The *ventral primary divisions*, with the two exceptions above mentioned, are larger than the posterior. Each ventral division is joined by one or two *branches from the neighboring sympathetic ganglion* by which it receives non-medullated

fibres for distribution to the vessels which it innervates, and contributes medullated fibres to the sympathetic trunk. The ventral primary divisions of the thoracic nerves (except the first) form intercostal nerves, and are distributed each to its own area, but in all the other regions intricate plexuses are formed by neighboring nerves before their branches of distribution are given off.

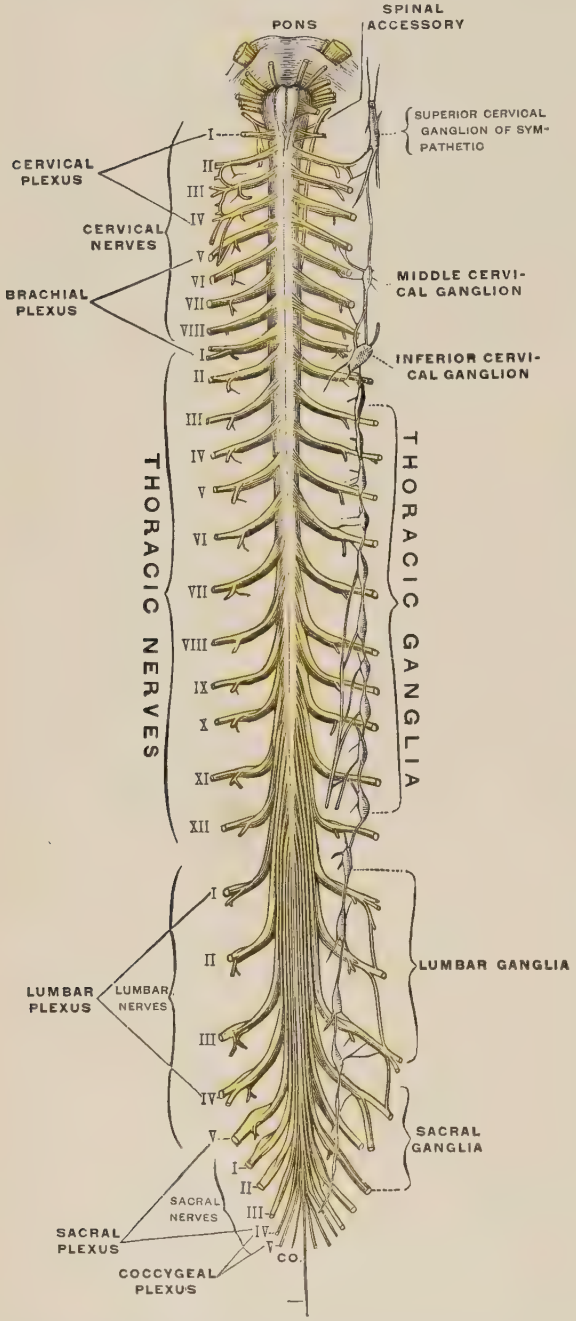

FIG. 695.—Anterior surface of the spinal cord, showing the spinal nerves and their connections with the sympathetic trunk on one side. (Testut.)

The *recurrent branch* is a small twig given off from the nerve immediately after it leaves the intervertebral foramen. It receives a communication from the sympathetic and re-enters the spinal canal to supply the meninges and blood-vessels.

Dorsal Primary Divisions of the Spinal Nerves.—*General Statement.*—The dorsal primary divisions of the spinal nerves (Fig. 696) are destined for the supply of the skin of the back of the scalp, neck, trunk, and gluteal region, and the muscles of the posterior spinal group, except those connected with the upper limb, the serrati posteriores, and the levatores costarum. With the few exceptions mentioned below, each nerve passes backward between the transverse processes of the adjacent vertebræ and spinal muscles, dividing into an internal and an external branch. From the sixth thoracic nerve upward the internal branches are larger and are mainly cutaneous, the external branches are smaller and purely muscular; below that point the arrangement is reversed, the external branches being the larger, and mainly distributed to the skin, the internal branches small and chiefly distributed to the erector spinæ and deeper spinal muscles.

Exceptions to this general type are as follow:

The dorsal primary division of the first cervical (suboccipital) nerve does not divide, is usually purely muscular, and requires special description.

The dorsal divisions of the fourth and fifth sacral nerves and the coccygeal nerve do not divide, but form loops with each other, and are purely cutaneous.

The dorsal divisions of the sixth, seventh, and eighth cervical nerves divide like the others into internal and external branches; but both these branches are distributed to muscles only.

The Dorsal Primary Division of the First Cervical or Suboccipital Nerve (Fig. 697).—The first cervical or suboccipital nerve leaves the cranio-vertebral canal by passing between the occipital bone and the dorsal arch of the atlas. The dorsal division, slightly larger than the ventral, passes backward under the vertebral artery, and enters the suboccipital triangle. This space is bounded by the rectus capitis posterior major internally, the obliquus inferior infero-externally, and the obliquus superior supero-externally. Here the nerve divides into the

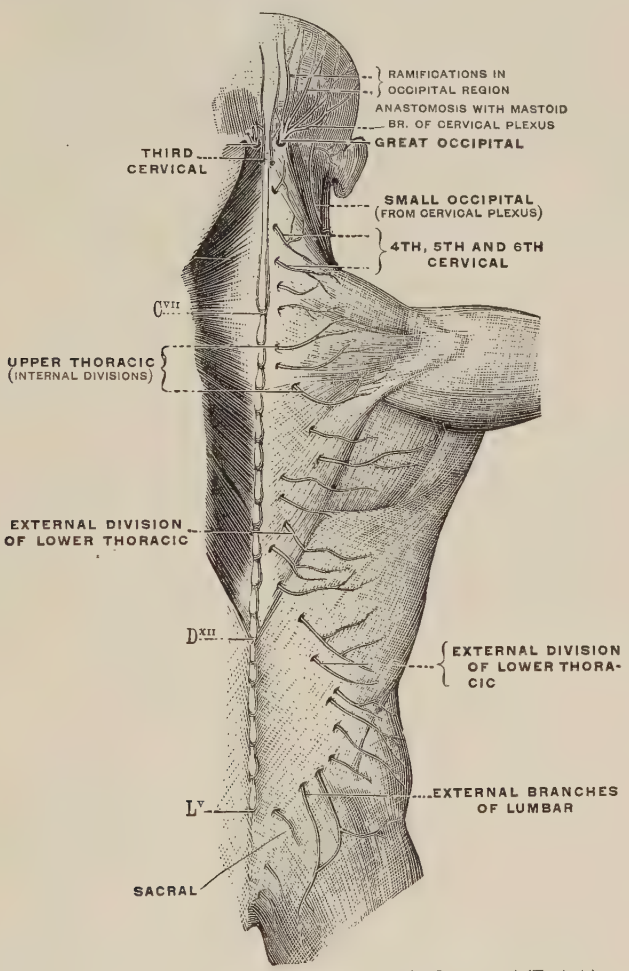

FIG. 696.—Dorsal primary divisions of the spinal nerves. (Testut.)

following four branches: (*a*) a branch to the obliquus inferior which furnishes an anastomotic filament to the great occipital nerve; (*b*) a branch running upward to the recti capitis posteriores major and minor; (*c*) a third branch enters the obliquus superior; (*d*) and a fourth branch supplies the complexus on its deep surface.

The Great Occipital Nerve (Figs. 696, 697).—The dorsal primary division of the *second cervical nerve* is three or four times as large as the ventral division. Its *external branch* is small and is distributed to the inferior oblique, complexus, and trachelomastoid; but the *internal branch* is large, and from its size and distribution is called the *Great Occipital Nerve.* After communicating with the first and

third cervical nerves, and thus forming what has been called the dorsal cervical plexus, it winds upward over the obliquus inferior, supplies a twig to the complexus, and then pierces it and the trapezius to become cutaneous beneath the superior curved line of the occipital bone, about one inch from the middle line. Accompanied by branches of the occipital artery, it supplies the skin over the upper

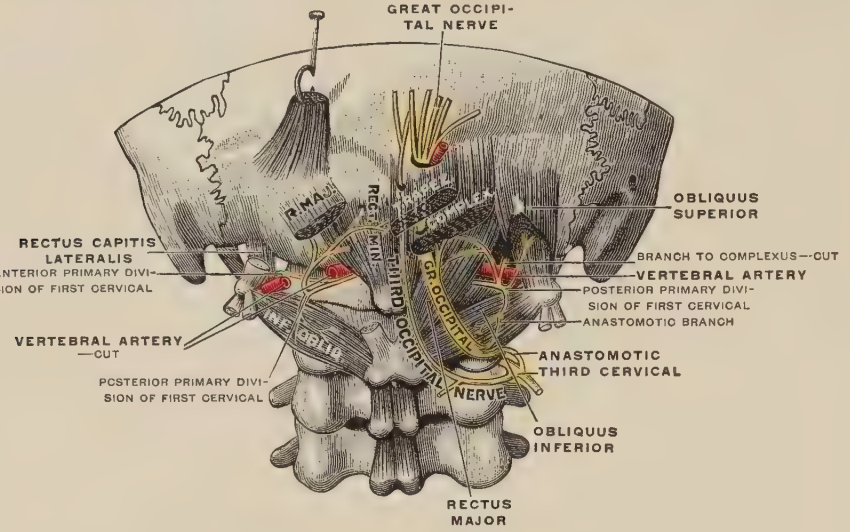

FIG. 697.—Dorsal primary divisions of the upper three cervical nerves. (Testut.)

part of the occipital bone and posterior parietal region, interlacing with the small occipital externally, and with the cutaneous branch of the third cervical nerve (third occipital nerve) internally.

The Third Occipital Nerve.—The internal branch of the dorsal division of the third cervical nerve is directed upward beneath the complexus to reach the skin of the occiput internally to the great occipital, with which it communicates. Its distribution has led to its being called the *third occipital nerve*.

The Ventral Primary Divisions.

CERVICAL NERVES.

The *upper four cervical nerves* unite to form the *Cervical Plexus* (Fig. 698), and supply the skin and muscles of the neck. The lower four unite with the first thoracic nerve to form the brachial plexus by which the upper limb is supplied.

The Cervical Plexus.

The first cervical nerve (ventral division), after leaving the vertebral canal in the groove on the dorsal arch of the atlas, winds round to the front on the inner side of the vertebral artery and bends downward over the transverse process to join the second nerve. The ventral division of the second nerve leaves the vertebral canal behind the articular process of the axis; those of the rest of the cervical nerves pass outward in the intervertebral foramina, behind the vertebral artery and between the rectus capitis anterior major and the scalenus medius.

On the surface of the levator scapulæ and scalenus medius, and under cover of the sternomastoid these four nerves form three loops; and from these loops, or from the nerves themselves, spring the branches of the plexus. These are divisible into a superficial cutaneous set, and a deep series, including muscular and communicating nerves.

Superficial Branches (Fig. 687).—These are ascending, transverse, and descending.

ASCENDING BRANCHES.

1. The **Small Occipital Nerve** is derived from the second cervical nerve. It passes backward under the sternomastoid muscle to its dorsal border, then upward along that border, dividing at about the level of the mastoid process into an *auricular branch* to the skin of the dorsal and upper part of the pinna, a *mastoid branch* to the skin over the mastoid region, and an *occipital branch* to the occipital area. It communicates with the great auricular and great occipital nerves.

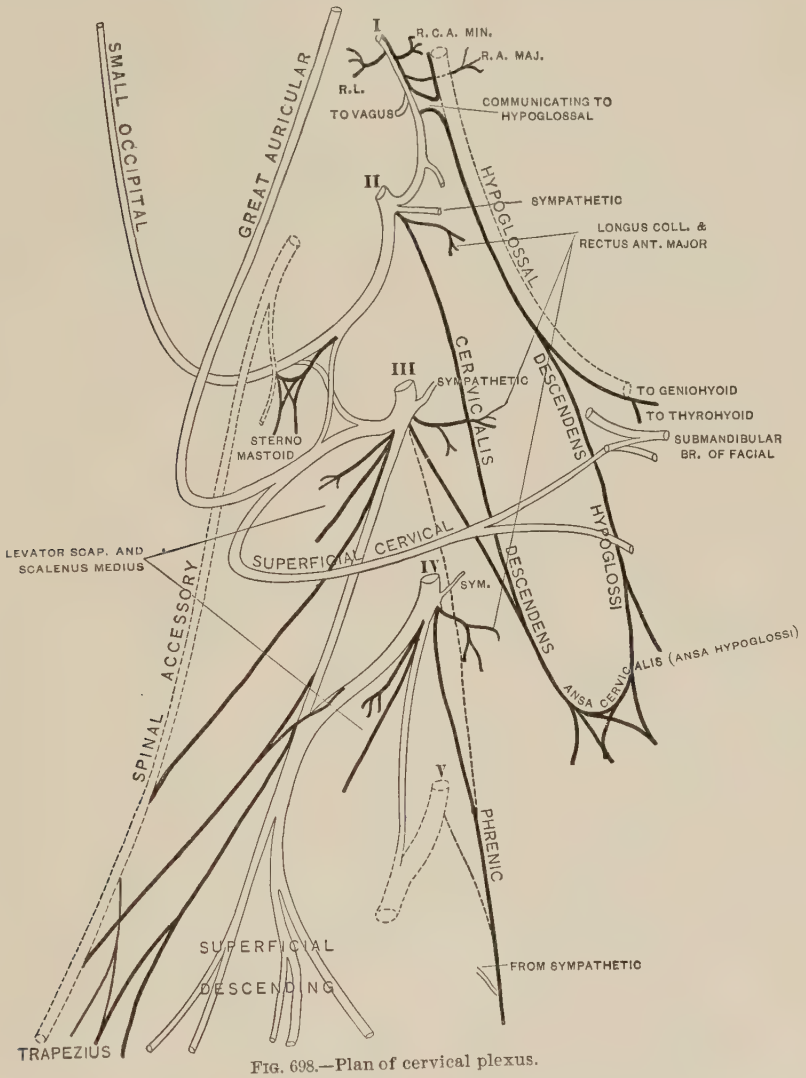

Fig. 698.—Plan of cervical plexus.

2. The **Great Auricular Nerve** springs by two roots from the second and third cervical nerves. Reaching the dorsal border of the sternomastoid, it crosses it diagonally in running upward to the back of the auricle. It supplies a small *mastoid branch* to join the mastoid branches of the small occipital nerve, numerous large *auricular branches* to the back of the pinna in its lower two thirds, one or two of these piercing the cartilage to the front of the lobule and helix; and a

small *facial branch* to the skin of the parotid, masseteric, and buccal regions. These branches join the facial nerve.

TRANSVERSE BRANCH.

The **Superficial Cervical Nerve,** rising with the last from the second and third cervical nerves, curves round the dorsal border of the sternomastoid muscle about its middle and spreads out into branches, which ramify between the platysma and deep fascia over the carotid triangle. Its ascending branch forms one or more loops with the inframandibular branch of the facial nerve. It supplies the skin of the front of the neck from chin to sternum.

DESCENDING BRANCHES.

Branches from the third and fourth nerves form a large trunk, which pierces the deep fascia at the dorsal border of the sternomastoid and just below its middle. This soon divides into three or four branches, which descend between the platysma and deep fascia to the skin of the *sternal, clavicular,* and *acromial regions* respectively, and are named according to that distribution.

Muscular branches to the trapezius are usually associated with this trunk.

Deep Branches.—The deep branches may be conveniently divided into muscular and communicating.

Muscular Branches are distributed to the rectus capitis lateralis and recti anteriores from the loop between the first and second nerves. A branch to the sternomastoid from the second nerve enters the under surface of that muscle near the mastoid process, and there communicates with the spinal accessory nerve.

From the second and third nerves two branches join to form the *ramus cervicalis descendens,* already described with the hypoglossal nerve. It supplies the depressors of the hyoid bone. From these nerves also twigs pass to the longus colli. The levator scapulæ receives two or three branches from the third and fourth nerves, and the *scalenus medius* receives branches from the same trunks. Branches to the trapezius are derived from the descending cutaneous trunk (third and fourth nerves), and these unite under the trapezius with the termination of the spinal accessory nerve, thus forming the *subtrapezial plexus.*

The **phrenic nerve** is the most important branch of the cervical plexus. Its most constant root is from the fourth nerve, but it may have other roots from the third or fifth, or both. Where the root from the fourth nerve is absent, it usually receives a twig from the nerve to the subclavius. In addition to these, it receives a communication from the cervical sympathetic. It takes a very constant and definite course downward and forward over the scalenus anterior, and beneath the omohyoid muscle and transversalis colli and suprascapular arteries, and, on the left side, the thoracic duct. Passing behind the subclavian vein it enters the thorax, the internal mammary artery crossing behind it to reach the sternum. On the *right side* it now descends on the outer side of the right brachio-cephalic vein, superior cava, and pericardium in front of the root of the lung and between these structures and the pleura, to the diaphragm, which it pierces and supplies on its abdominal surface. On the left side it crosses the second part of the arch of the aorta and descends on the pericardium in front of the root of the lung to the diaphragm, being covered, of course, by pleura.

Branches.—Twigs are supplied to the pleura and pericardium, and on the right side it communicates with the diaphragmatic plexus of the sympathetic, forming a small ganglion.

Communicating Branches of the Cervical Plexus.—From the loop between the first and second nerves branches pass to the vagus and hypoglossal, the branch to the hypoglossal being destined for hyoid muscles. The muscular branches from the second to the sternomastoid and from the third and fourth to the trapezius communicate with the spinal accessory; and each nerve is connected with the superior cervical ganglion of the sympathetic.

The Brachial Plexus.

The anterior primary divisions of the fifth, sixth, seventh, and eighth cervical nerves join with the first thoracic nerve to form the brachial plexus (Fig. 699). Communications are also received from the fourth cervical and second thoracic nerves. The cervical nerves emerge from the grooves on the transverse process of the vertebræ, between the scaleni medius and anterior, and run downward in front of the former muscle. The first thoracic nerve emerges from between the first

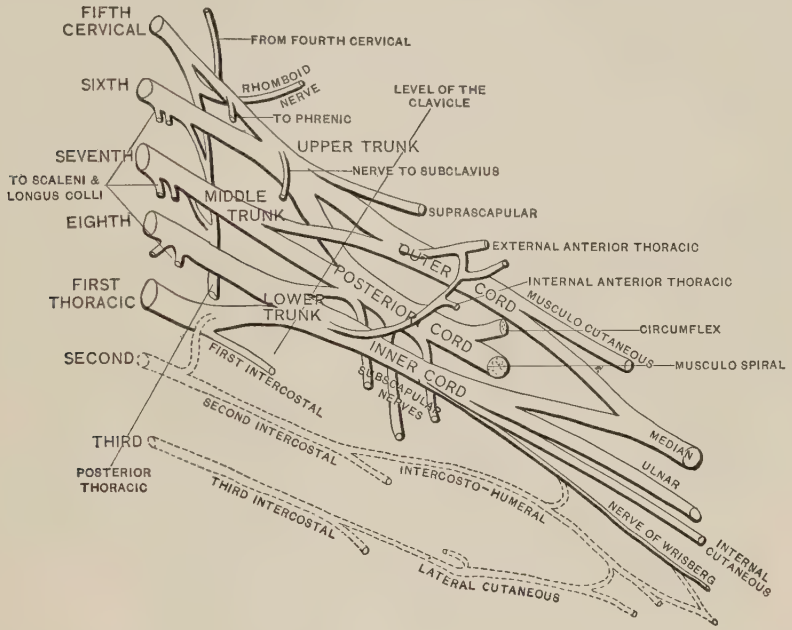

Fig. 699.—Plan of brachial plexus.

and second thoracic vertebræ, gives off a small branch to the first intercostal space, and ascends over the first rib to join the eighth cervical nerve. On the surface of the scalenus medius three primary trunks are formed, the fifth and sixth nerves uniting to form the *upper trunk*, the seventh alone forming the *middle trunk*, and the eighth cervical and first thoracic nerves forming the *lower trunk*. These run together downward and outward in the subclavian triangle above the subclavian artery. In this situation each trunk splits into an *anterior* and *posterior division*. The anterior divisions of the two upper trunks unite to form the *outer cord*; the *inner cord* is the continued anterior division of the lower trunk; and the three posterior divisions together form the *posterior cord*. These three cords lie to the outer side of the first part of the axillary artery, distribute themselves round its second part in such positions as their names designate, and at the level of the third part of the vessel each cord has divided into separate nerves, which bear to the artery the same relations as the cords from which they spring.

This is the usual arrangement, but there are numerous variations.

The branches of the brachial plexus are classified into *supraclavicular* and *infraclavicular*.

Branches Given off Above the Clavicle.

1. The **nerve to the rhomboids** (5. c.)[1] is a long, slender branch which springs from the fifth cervical nerve, close to the intervertebral foramen and in common

[1] In the parenthetical abbreviations employed after the names of nerves, the letters indicate the regions in which nerves originate; the numerals, the nerves concerned in their composition. Thus, "(8. c., 1. th.)" means that the fibres of the nerve can be traced back to the eighth cervical and first thoracic nerves.

with the first root of the posterior thoracic nerve. It enters the substance of the scalenus medius and emerges from its external border. Passing beneath the levator scapulæ, it supplies some twigs to that muscle, and reaches the deep surface of the rhomboids, where it is joined by the posterior scapular artery. It ends in the rhomboid muscles.

2. The **nerve to the subclavius** (5. c.) springs from the upper trunk. As a long slender filament it descends in front of the plexus and subclavian artery to supply the muscle from which it is named. It frequently contributes a filament to the phrenic nerve.

3. The **suprascapular nerve** (5. c.) (Fig. 700), also derived from the upper trunk, runs downward, outward, and backward over the scalenus medius and under the trapezius and omohyoid. It passes through the suprascapular notch, beneath the transverse ligament, and, after supplying a twig to the shoulder-joint,

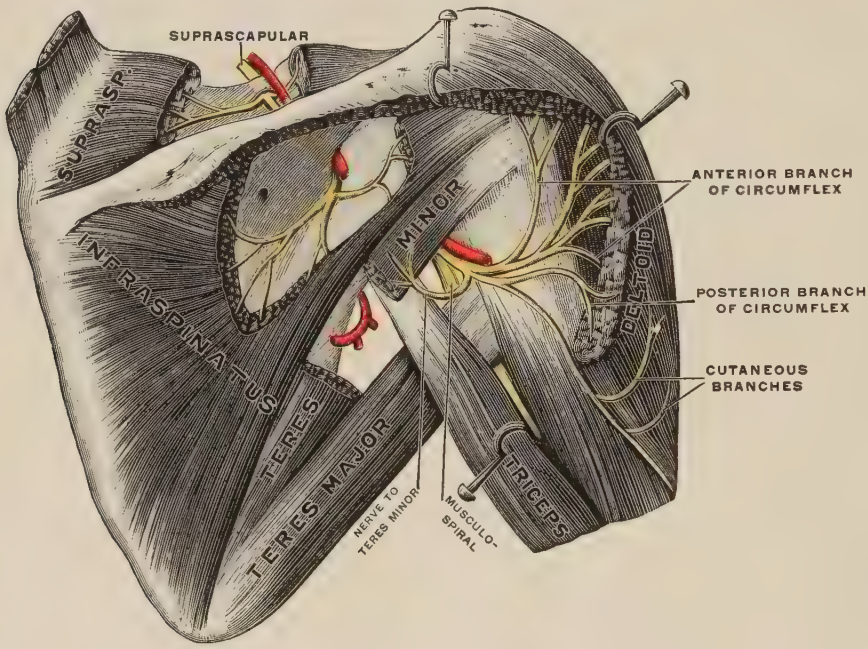

FIG. 700.—Suprascapular and circumflex nerves of right side, seen from behind. (Testut.)

divides into branches to the supraspinatus and infraspinatus, the former turning outward into its muscle, and the latter passing round the great scapular notch, and terminating in the infraspinatus.

4. The **posterior thoracic nerve** (5. 6. 7 ? c.) (*external respiratory nerve* of Bell) is formed by the union of three roots, from the fifth, sixth, and seventh cervical nerves, respectively. The first two roots pierce the scalenus medius and supply twigs to the upper digitations of the serratus magnus. They are afterward joined by the root from the seventh nerve, which passes in front of the scalenus medius. The nerve descends behind the brachial plexus and the first portion of the axillary artery, and runs along the chest wall on the serratus magnus, rather behind the lateral prominence of the ribs, sending a twig to each digitation of that muscle.

5. The **scaleni** and **longus colli** are supplied by twigs from the lower three cervical nerves.

Branches Given off Below the Clavicle.

Of these, the *external* and *internal anterior thoracic* and three subscapular nerves are distributed to parts about the axilla; the rest supply the arm, forearm, and hand.

1. The **External Anterior Thoracic Nerve** (6. 7. c.) springs from the outer cord, pierces the costo-coracoid membrane above the pectoralis minor, and supplies the pectoralis major.

2. The **Internal Anterior Thoracic Nerve** (8. c., 1. th.) is derived from the inner cord. It passes forward between the axillary artery and vein, and enters the deep surface of the pectoralis minor. After supplying this muscle, it pierces it to reach the pectoralis major, in which it ends. Thus the pectoralis major is supplied by two nerves.

These two nerves are usually united by a loop which crosses in front of the axillary artery.

3. The **Subscapular Nerves** supply the muscles which form the posterior axillary wall, and are all branches of the posterior cord.

The **upper subscapular** (5. 6. c.), sometimes represented by two branches, lies high in the axilla. It is very short and plunges at once into the upper part of the subscapularis.

The **middle** or **long subscapular nerve** (7. c.) accompanies the subscapular artery and supplies the latissimus.

The **lower subscapular nerve** (5. 6. c.) sends twigs to the lower part of the subscapularis muscle and ends in the teres major.

Terminal or Long Branches.—The *outer cord* divides into the musculo-cutaneous and outer head of the median; the *inner cord* into the small internal cutaneous, internal cutaneous, ulnar and inner head of the median, and the *posterior cord* into the circumflex and musculo-spiral. These branches are arranged around the third part of the axillary artery in the same manner as their parent cords, except that the small internal cutaneous nerve is separated from the artery by the axillary vein, and the internal cutaneous nerve and inner head of the median lie in front of the vessel.

4. The Musculo-cutaneous Nerve.

The musculo-cutaneous nerve (5. 6. c.) (Figs. 701, 708, 709), arising from the outer cord of the plexus, lies first on the outer side of the axillary and afterward of the brachial artery. It sends some fibres to the coraco-brachialis, and its main trunk perforates that muscle in a downward and outward direction near the lower border of the axilla. Passing obliquely across the arm between the biceps and brachialis it gives branches to both these muscles, and reaches the surface at the outer border of the biceps a little above the bend of the elbow. Here it perforates the deep fascia, and divides into an *anterior* and a *posterior division*, which supply the skin on the anterior and posterior aspects of the radial side of the forearm. Of these, the anterior division is large, and reaches as far down as the thenar eminence; the posterior division is shorter, and reaches only as low as the wrist. Both divisions communicate with the radial nerve. At the bend of the elbow the nerve is crossed by the median cephalic vein.

5. The Median Nerve.

The median nerve (6. 7. 8. c., 1. th.) (Figs. 701, 702, 703, 705, 708, 709) arises by two heads, one from the inner and one from the outer cord. The inner head crosses in front of the third part of the axillary artery to join the outer head, and the resulting nerve runs down the arm on the outer side of the axillary and brachial arteries, and slightly under cover of the biceps. Near the middle of the humerus it crosses in front of the brachial artery to reach its inner side, which it keeps till the vessel bifurcates. It then passes between the two heads of the pronator teres, crossing the ulnar artery but separated from the vessel by the ulnar head of the muscle, and courses down the middle of the forearm on the flexor profundus digitorum under the flexor sublimis. At the wrist it is found beneath the deep fascia between the flexor sublimis and flexor carpi radialis and

just to the outer side or under cover of the palmaris longus. It now passes behind the anterior annular ligament, emerges as a flattened band, and divides into inner and outer terminal divisions.

Branches.—The median nerve gives no branches to the arm, but supplies the *elbow-joint*, all the anterior group of forearm muscles (except the flexor

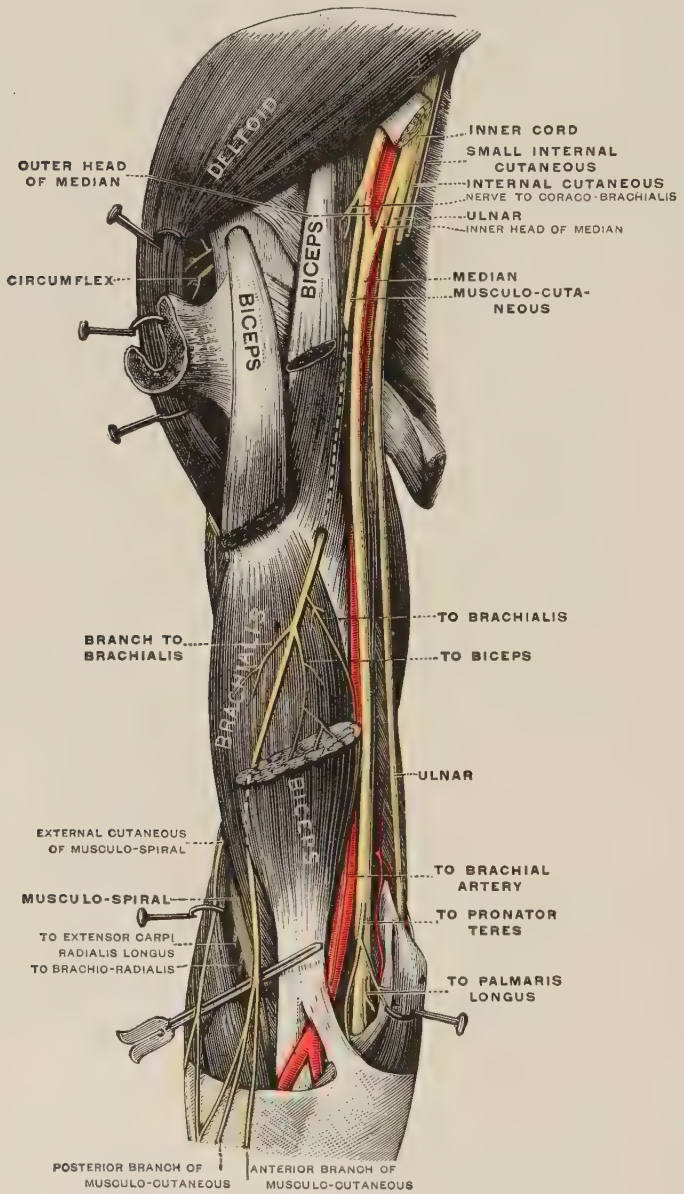

Fig. 701.—Deep nerves of the front of the right arm. (Testut.)

carpi ulnaris and half of the flexor profundus), and the short muscles of the thumb that are on the radial side of the flexor longus pollicis. Its cutaneous branches supply the hollow of the palm, the thumb, index, middle and half of the ring fingers on their palmar aspect and nail-beds, and the outer two lumbrical muscles.

Muscular Branches.—The branch to the pronator teres (6. c.) is given off just above the bend of the elbow, those for the palmaris longus (7. 8. c., 1. th.), flexor carpi radialis (6. c.), and flexor sublimis digitorum (7. 8. c., 1. th.) a little lower down.

The **anterior interosseous nerve** (7. 8. c., 1. th.) (Figs. 702, 705) is the muscular

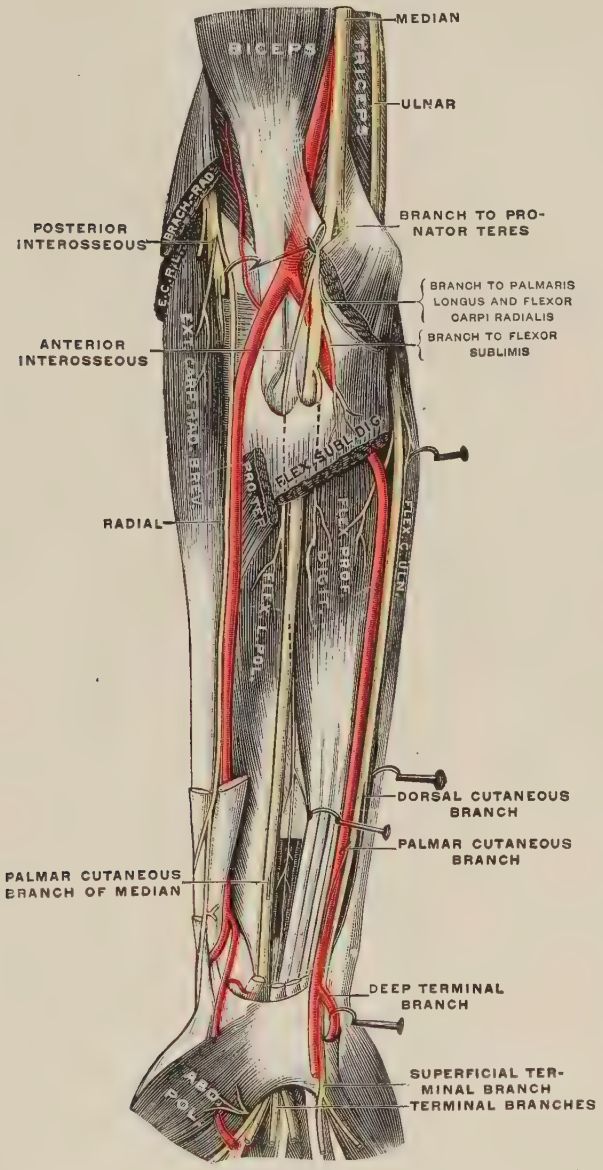

FIG. 702.—Deep nerves of the front of the right forearm. (Testut.)

branch of the median to the deep muscles of the forearm. Commencing opposite the bicipital tuberosity of the radius, it accompanies the anterior interosseous artery and lies on the interosseous membrane between the flexor profundus digitorum and flexor longus pollicis. It supplies branches to both these muscles, that to the flexor profundus communicating with the corresponding branch of the ulnar nerve. The nerve accompanies the artery under the pronator quadratus; but, instead of following the vessel through the interosseous mem-

brane to the back, terminates by supplying the pronator quadratus and wrist joint.

The muscular branch to the abductor pollicis, flexor ossis metacarpi pollicis, and outer head of the flexor brevis pollicis is a short, stout twig derived from the external terminal division.

The **Cutaneous Branches** of the median are the palmar cutaneous and two terminal divisions.

The **palmar cutaneous branch** is a small twig given off above the anterior annular ligament. It crosses in front of that ligament and supplies the palm and

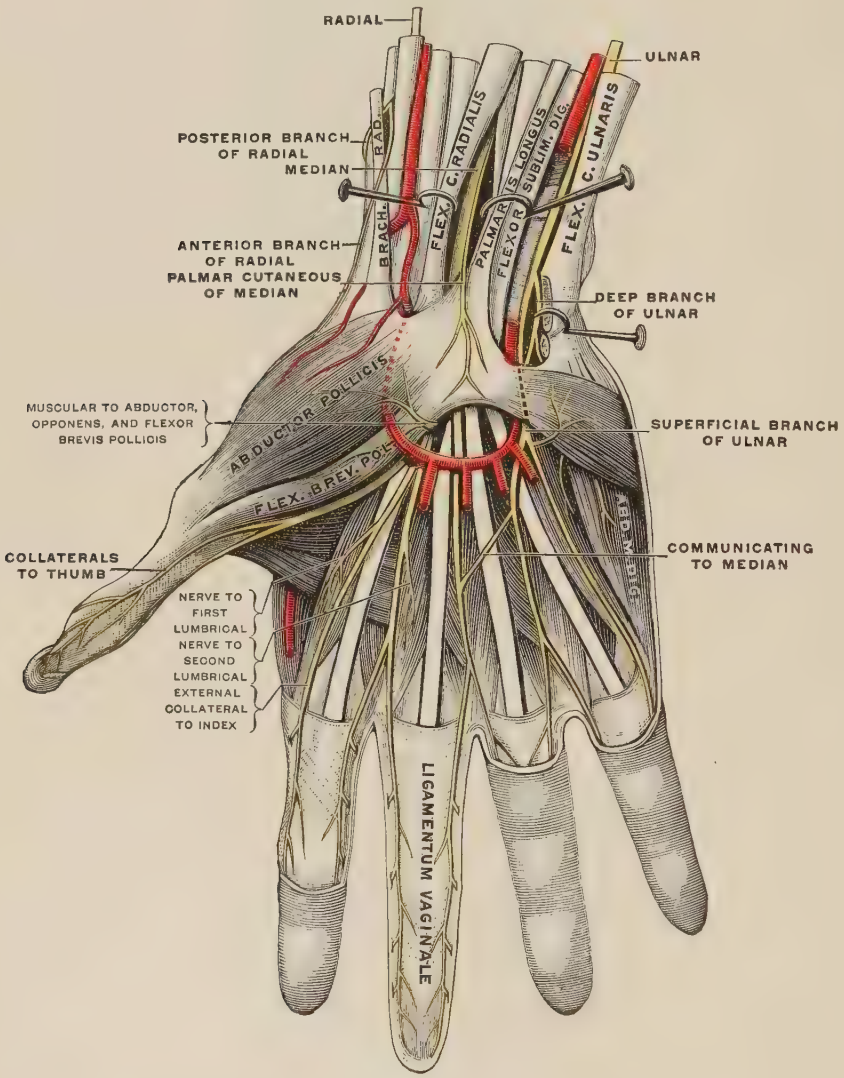

FIG. 703.—Superficial palmar nerves. (Testut)

inner side of the thenar eminence, communicating with the musculo-cutaneous nerve.

The **external terminal division** divides into an outer branch which crosses the flexor longus pollicis to the outer side of the thumb, and an inner branch which sends collaterals to the inner side of the thumb and outer side of the index finger and intervening skin.

The **internal terminal division** splits into two branches which proceed to the next two finger clefts, passing under the superficial palmar arch, but superficial to the tendons. At the level of the metacarpo-phalangeal joints they appear between the divisions of the palmar fascia and split into collaterals to the contiguous sides of the index and middle, and middle and ring fingers respectively. Each of these nerves supplies the palmar surface of the finger to which it belongs and gives a dorsal twig to the nail matrix. Twigs from the digital branches supply the outer two lumbrical muscles, and the innermost digital branch communicates with the ulnar nerve.

6. The Small Internal Cutaneous Nerve.

The small internal cutaneous nerve (Figs. 701, 708), or *nerve of Wrisberg* (1. th.), arises from the inner cord of the plexus, and descends on the inner side of the axillary vein, and then under the fascia, which it pierces on the inner aspect of the arm about the middle. It bends backward and supplies the skin over the olecranon and lower third of the arm. In the axilla it forms loops with the intercostohumeral, and sometimes also the lateral cutaneous branch of the third intercostal nerve.

7. The Internal Cutaneous Nerve.

The internal cutaneous nerve (8 c., 1. th.) (Figs. 701, 708, 709) springs from the inner cord below the last. It descends in front of the axillary and brachial arteries, pierces the deep fascia with the basilic vein about two-thirds down the arm, and divides into an anterior and posterior branch. About the middle of the arm it gives a twig to the skin over the biceps. The *anterior branch* is the larger. It passes in front of or behind the median basilic vein, and supplies the anterior ulnar area of skin as low as the wrist. The *posterior branch* descends in front of the internal condyle, and winds sharply backward to supply the posterior ulnar region.

8. The Ulnar Nerve.

The ulnar nerve (8. c., 1. th.) (Figs. 701–709), which is the largest branch of the inner cord, descends between the axillary artery and vein, and along the inner side of the brachial artery in the upper third of the arm. It then pierces the internal intermuscular septum with the inferior profunda artery, and descends beneath the deep fascia to the interval between the internal condyle and the olecranon process, where it passes between the two heads of the flexor carpi ulnaris to run between that muscle and the flexor profundus digitorum. It joins the ulnar artery and lies on the inner side of that vessel in the lower two-thirds of the forearm, crossing the anterior annular ligament with it immediately external to the pisiform bone. In the palm it divides, like the artery, into a superficial and a deep division.

Branches.—As of the median nerve the first branches of the ulnar are *articular filaments* to the elbow joint, which are given off as it passes between the heads of the flexor carpi ulnaris. In the forearm it supplies *muscular branches* (8. c., 1. th.) to the flexor carpi ulnaris and inner half of the flexor profundus digitorum.

The **palmar cutaneous branch** is given off near the middle of the forearm. It descends in front of the ulnar artery, supplies twigs to that vessel, and terminates in the skin of the palm.

The **dorsal branch** (8. c.) arises about two inches above the wrist joint, passes backward beneath the flexor carpi ulnaris, and is distributed to the skin on the dorsum of the hand, little finger, and inner side of the ring finger, communicating with the radial.

The **superficial terminal branch** of *the ulnar nerve* (1. th., or 8. c. 1. th.) behaves similarly to the median nerve, with which it communicates; but it supplies no muscles. It is distributed to the little and inner side of the ring finger.

The **deep branch** (8. c.) accompanies the deep branch of the ulnar artery

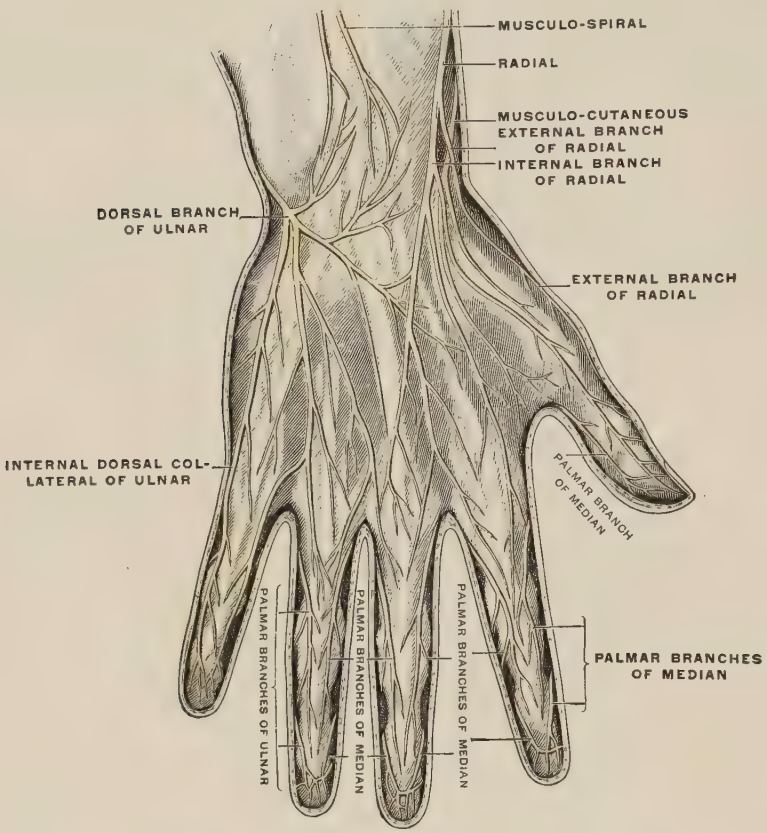

FIG. 704.—Cutaneous nerves of the dorsum of the hand. (Testut.)

between the abductor and flexor brevis minimi digiti. It supplies all the short muscles of the little finger, all the interossei, the inner two lumbricals, and those thumb muscles, which are on the inner side of the flexor longus pollicis.

9. The Circumflex Nerve.

The circumflex nerve (5. 6. c.) (Figs. 700, 706, 708, 709) is one of the terminal divisions of the posterior cord. It turns round the lower border of the subscapularis, and accompanies the posterior circumflex artery to the back of the shoulder, through the quadrilateral space, bounded by the subscapularis, teres major, triceps, and the surgical neck of the humerus. It gives an *articular* twig to the shoulder-joint, and divides into an anterior and a posterior branch.

The **anterior branch** winds round the humerus with the posterior circumflex artery, and sends many branches into the anterior part of the deltoid, some of which reach the skin.

The **posterior branch** sends a nerve to the teres minor, which has an ovoid, gangliform swelling on it, and supplies the posterior part of the deltoid muscle and skin over the lower deltoid region.

10. The Musculo-spiral Nerve.

The musculo-spiral nerve (6. 7. 8. c.) (Figs. 706, 701, 704, 708, 709) is the terminal and largest branch of the posterior cord. Placed at first behind the third part of the axillary artery and upper part of the brachial, it soon leaves the latter vessel, and, accompanied by the superior profunda artery, pierces the internal

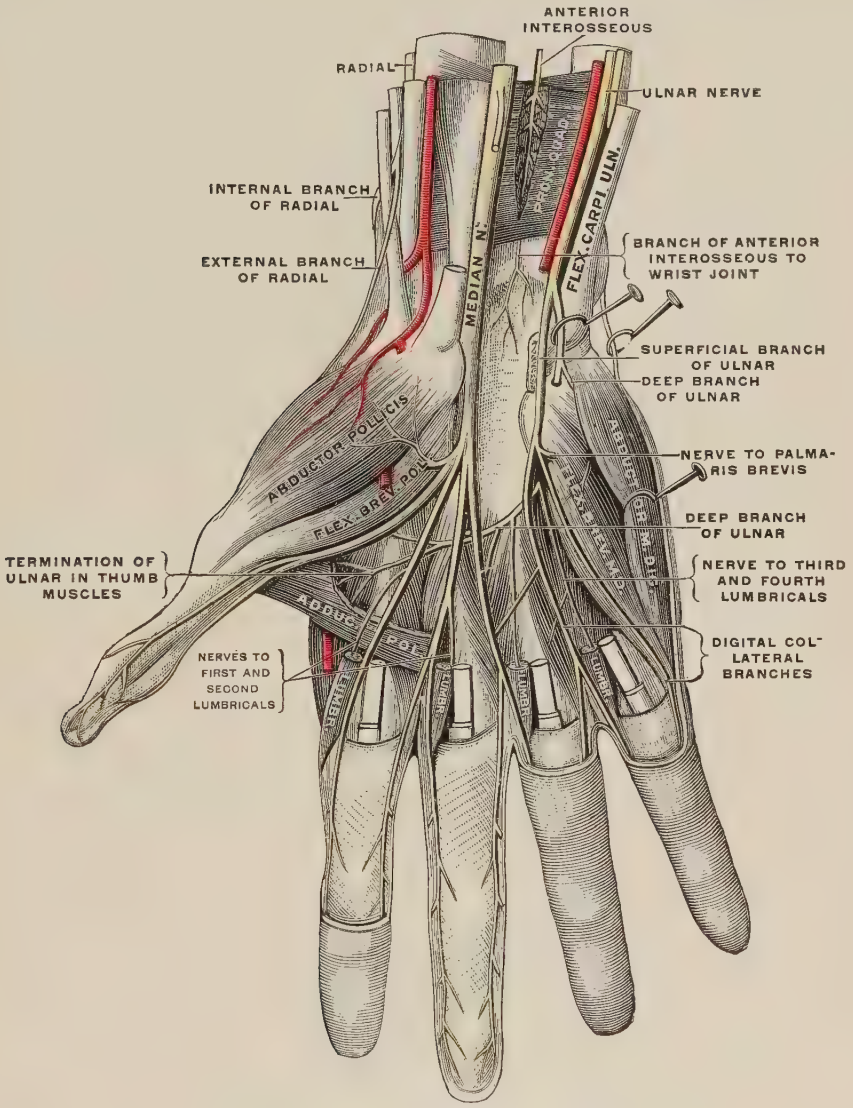

FIG. 705.—Deep palmar nerves. (Testut.)

intermuscular septum, winds obliquely round the humerus in the spiral groove between the triceps and the bone, and reaching the external intermuscular septum, pierces it to gain the interval between the brachialis anterior and brachio-radialis, where it divides into the radial and posterior interosseous nerves.

Before its final division it gives off an internal and an external cutaneous, and muscular branches to the triceps, anconeus, brachialis anterior (6. c.), brachio-radialis (6. c.), and extensor carpi radialis longus (6. 7. c.). Of the muscular branches those to the last three muscles are given off between the brachio-radialis and brachialis

anterior, branches to the inner and outer heads of the triceps and anconeus arise while the nerve is in the spiral groove, and important branches are contributed to the middle and inner heads of the triceps, while the parent nerve lies behind the brachial artery. One of these last, called by Krause the *ulnar collateral*, accompanies the ulnar nerve for some distance.

The **internal cutaneous branch** (8. c.) arises within the axilla, and supplies a

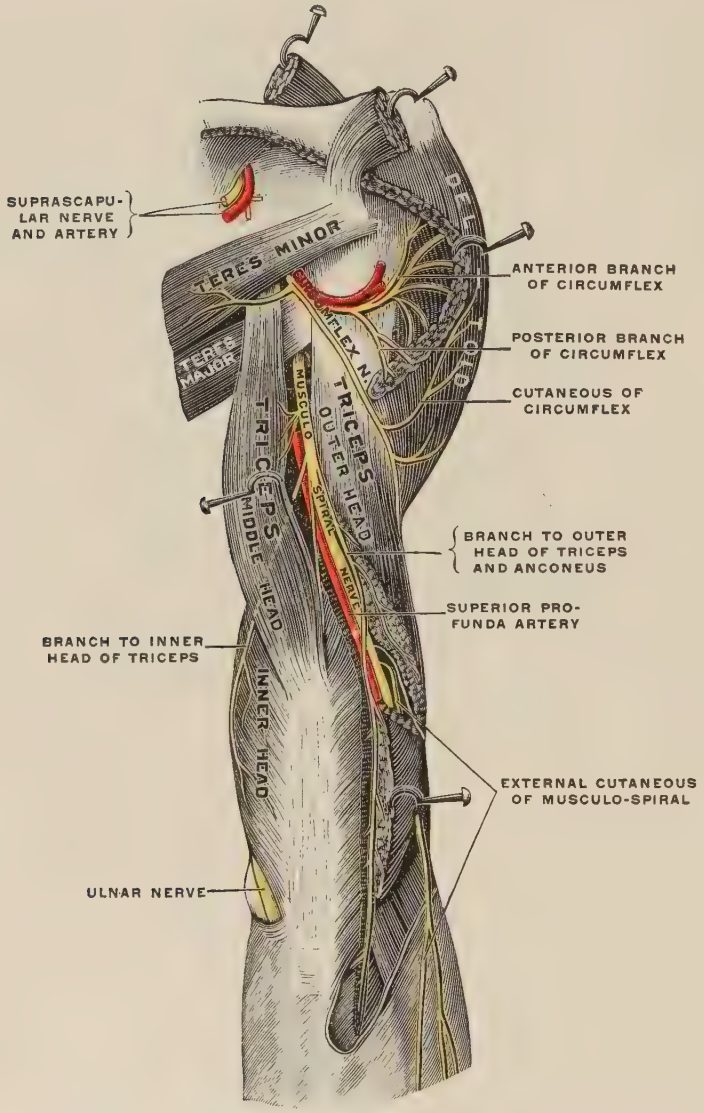

FIG. 706.—Musculo-spiral and circumflex nerves of right side. (Testut.)

strip of skin down the inner side of the arm, between the intercosto-humeral and circumflex areas.

The **external cutaneous branches** are two in number, the *upper* (6. c.) being the smaller. It pierces the deep fascia in the line of the intermuscular septum, and supplies the skin over the lower and outer part of the biceps. The *lower branch* (6. 7. 8. c.), becoming superficial a little below the last, descends behind the external condyle, and supplies the skin of the posterior radial region from elbow to wrist.

The **posterior interosseous nerve** (6. 7. c.) (Fig. 707), which is the *terminal musculo-articular branch* of the musculo-spiral, is destined for the posterior group of forearm muscles. It descends between the brachialis and extensor carpi radialis longus, where it gives branches to the extensor carpi radialis brevis and supinator (6. 7. c.), and then enters the substance of the latter muscle, in which it winds round the radius to gain the interval between the superficial and deep muscles on the back

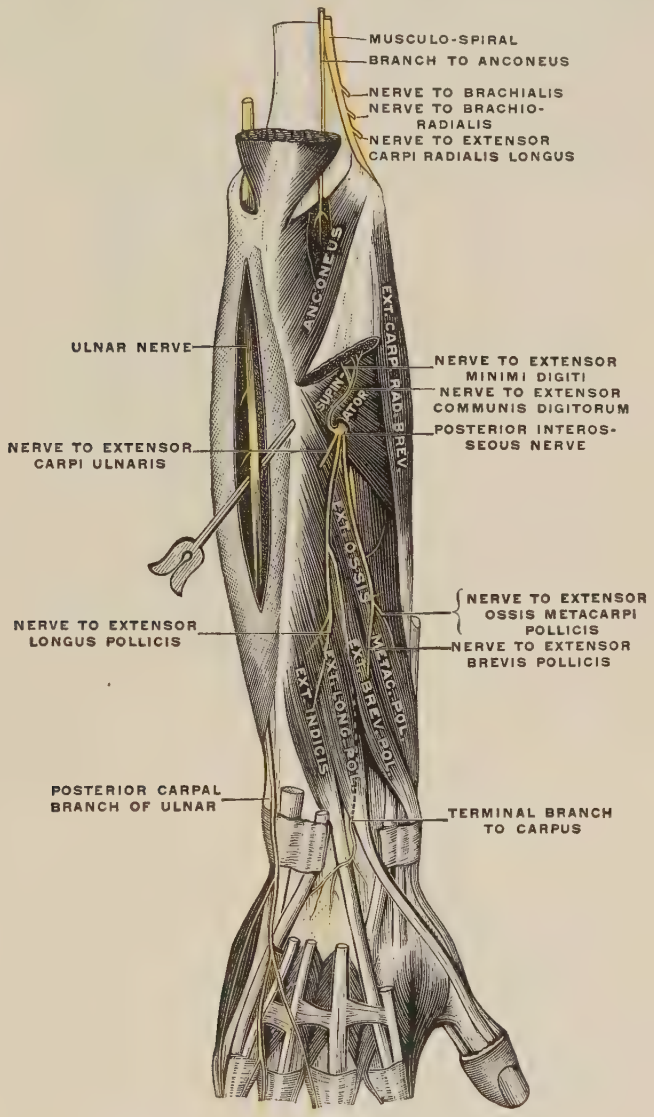

FIG. 707.—Posterior interosseous nerve. (Testut.)

of the forearm. Here it joins the posterior interosseous artery, sending branches to all the surrounding extensors (7. c.), while a deep branch descends between the extensor brevis and extensor longus pollicis, and after joining the terminal dorsal branch of the anterior interosseous artery on the interosseous membrane, accompanies it through the groove for the extensor communis, and expands on the back of the carpus into a gangliform enlargement, from which branches are supplied to the carpal joints.

The **radial nerve** (6. c.) (Figs. 702, 703, 704, 708, 709) is the other terminal division of the musculo-spiral, and is *purely cutaneous* in its distribution. It

descends beneath the brachio-radialis, and joins the radial artery, on whose outer side it runs in the middle third of the forearm. It then turns sharply backward beneath the brachio-radialis tendon. Piercing the deep fascia two inches above the styloid process of the radius, it sends a twig to the outer side of the thumb

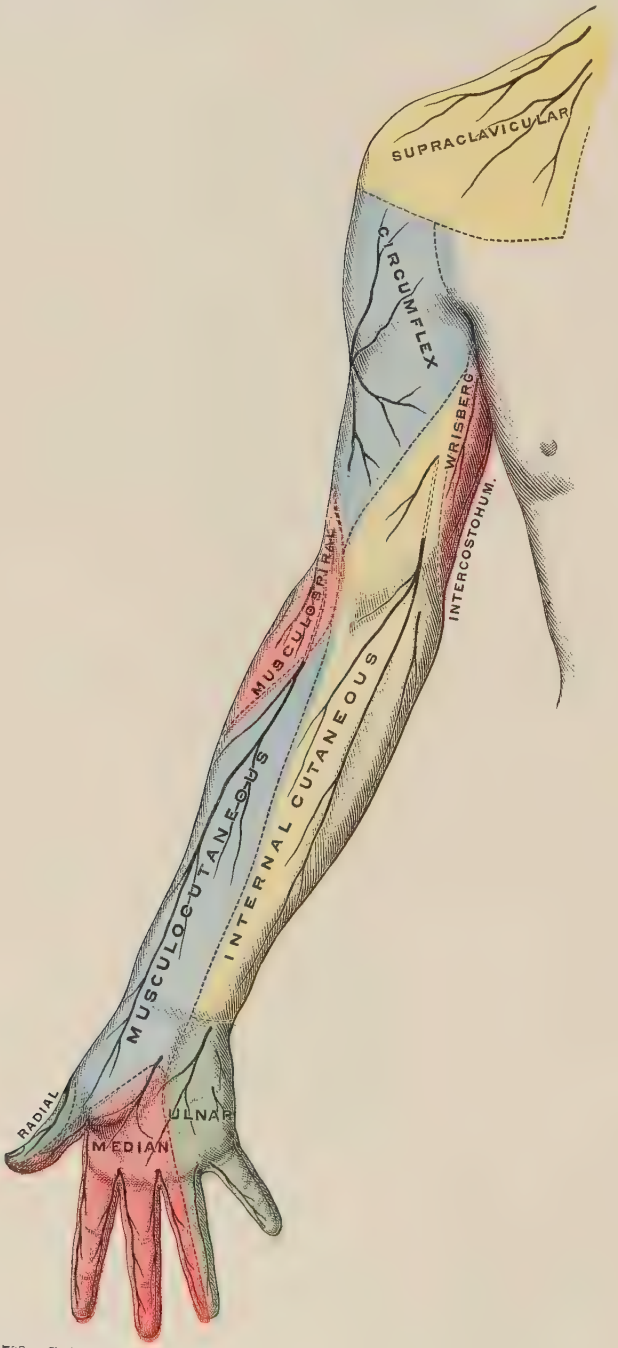

FIG. 708.—Cutaneous nerves of the upper limb, ventral aspect. (W. Keiller.)

and divides into four branches, which spread fan-like over the back of the hand and fingers, supplying the outer three and a half digits up to, but not including, the terminal phalanges. It is joined here by the ulnar nerve.

Observe that the nail matrices and surrounding skin are supplied by the palmar nerves, that the little finger and inner side of the ring finger are supplied on both aspects by the ulnar nerve, and that the rest of the fingers are supplied by the median on the palmar, and by the radial on the dorsal surface.

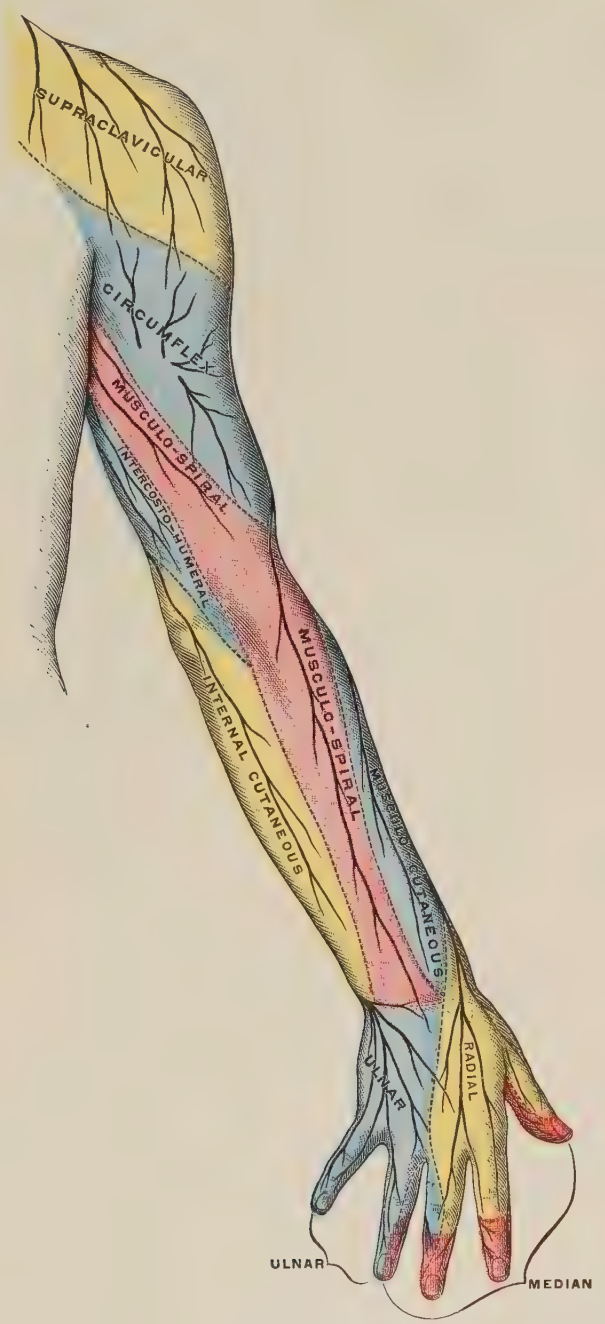

FIG. 709.—Cutaneous nerves of the upper limb, dorsal aspect. (W. Keiller.)

On the dorsum of the hand the radial and ulnar nerves overlap considerably.

For a general view of the cutaneous nerve-supply of the arm compare Figures 708 and 709.

THE THORACIC NERVES.

The thoracic nerves differ from all the other spinal nerves in that they enter into the formation of no plexus; but each is distributed to a transverse segment of the trunk, corresponding to the vertebræ from between which it emerges.

The *first thoracic nerve* sends a small branch to the interval between the first and second ribs, the main trunk, ascending in front of the first rib to join the brachial plexus. Its intercostal branch behaves like the others about to be described, but with rare exceptions has no lateral cutaneous branch.

The upper six thoracic nerves run round the chest wall in the spaces between the vertebro-sternal ribs; the remaining six pursue a transverse course through the abdominal wall where the ribs are deficient in front.

A **typical intercostal nerve** (Fig. 710), after receiving two *rami communicantes* from the corresponding ganglion of the sympathetic, passes outward between the

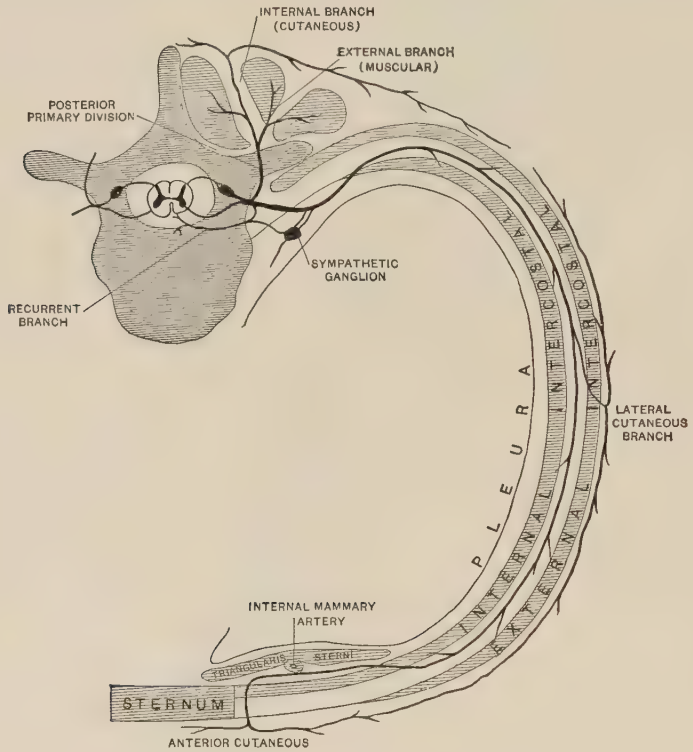

FIG. 710.—Plan of a typical intercostal nerve. (W. Keiller.)

posterior intercostal aponeurosis and the pleura, beneath the intercostal artery. It enters the interval between the internal and external intercostal muscles, and runs in it till the external intercostal muscle becomes deficient in front. It then dips under the internal intercostal muscle, and, between it and the internal mammary artery and triangularis sterni, reaches the side of the sternum, where it pierces the chest wall to become cutaneous.

The *lower intercostals*, from the seventh to the eleventh inclusive, enter the interval between the transversalis and internal oblique muscles, where the ribs are deficient in front. They run forward in the abdominal wall, enter the sheath of the rectus abdominis, and pierce that muscle near the middle line to supply the skin.

Lateral Cutaneous Branches (Figs. 711, 712).—The first intercostal nerve has no lateral cutaneous branch.

The *lateral cutaneous branch of the second intercostal nerve* is called the *intercosto-humeral*. It crosses the floor of the axilla just under the deep fascia, joins the small internal cutaneous nerve, and supplies a strip of skin on the mesial and dorsal aspect of the arm.

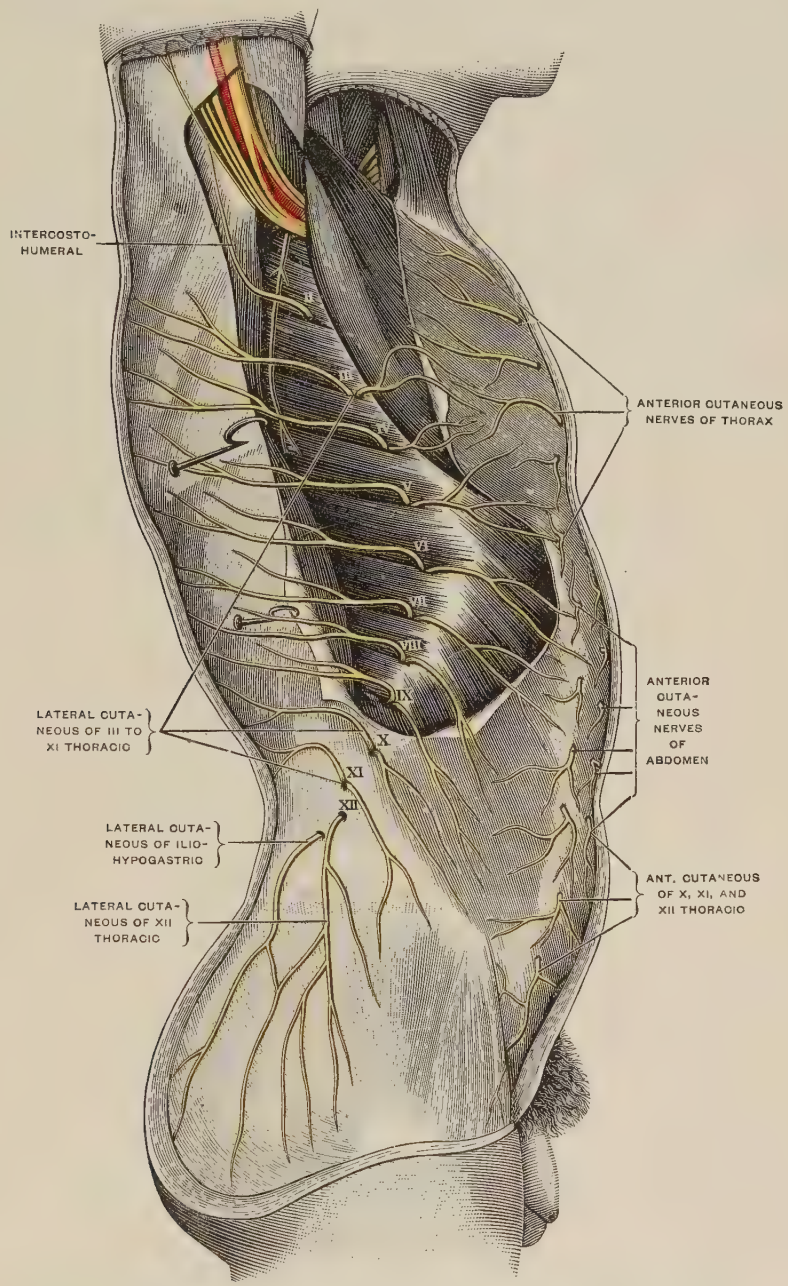

FIG. 711.—Cutaneous distribution of thoracic nerves. (Testut.)

The *lateral cutaneous branch of the third intercostal nerve* has a small anterior branch which passes forward over the pectoralis major, and a large posterior branch, which, after communicating with the intercosto-humeral nerve, is distributed to the skin of the axilla and dorsum of the scapula, a small branch reaching the arm.

The *lateral cutaneous branches* of the rest of the intercostal nerves (except the twelfth) pierce the superficial thoracic or abdominal muscles, in a vertical line a little behind the pectoral border of the axilla. Each divides into an *anterior* and a *posterior branch* for the supply of the skin over an intercostal space or corresponding area. The lateral cutaneous branches of the abdominal intercostals supply the external oblique muscle.

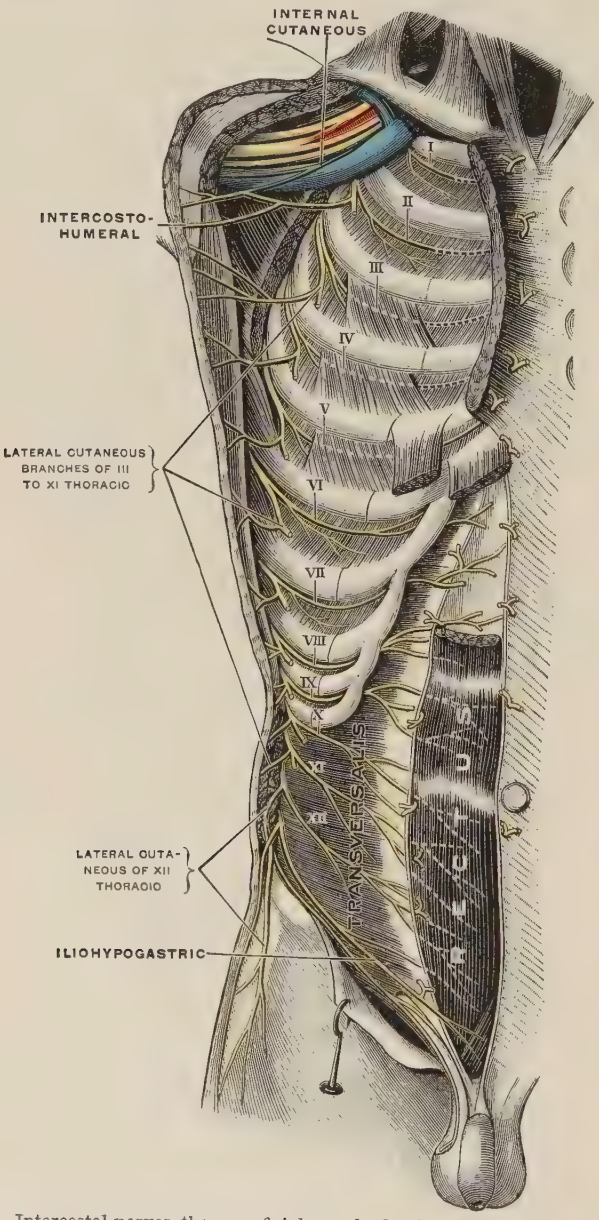

FIG. 712.—Intercostal nerves, the superficial muscles having been removed. (Testut.)

The *anterior cutaneous nerves of the thorax and abdomen* are the terminations of the intercostals. They reach the surface close to the middle line and turn outward. Those of the abdomen are small and pierce the sheath of the rectus rather irregularly. The tenth thoracic nerve supplies the skin about the umbilicus.

The **twelfth thoracic nerve** after communicating with the sympathetic and

sending a branch to join the first lumbar nerve, passes outward beneath the external arcuate ligament of the diaphragm and enters the abdomen. It runs along the lower border of the last rib, and enters the space between the transversalis and internal oblique, and is afterward arranged as one of the lower intercostals. Its lateral cutaneous branch remains undivided and is distributed to the gluteal region a little behind the anterior superior iliac spine.

The **muscles supplied by the intercostal nerves** are the levatores costarum, serrati posteriores, intercostals, subcostals, triangularis sterni, transversalis abdominis, external and internal oblique, rectus, and pyramidalis.

THE LUMBAR NERVES.

The anterior divisions of the five lumbar nerves increase in size from above downward. They communicate with the sympathetic by rami communicantes which reach them by running along the sides of the lumbar arteries under the fibrous arches from which the psoas muscle takes origin. Of these five nerves the upper three, with a communication from the twelfth thoracic and a considerable part of the fourth lumbar nerve, form the *lumbar plexus*, and the rest of the fourth lumbar nerve, with the whole of the fifth, join the sacral nerves in forming the sacral plexus.

The Lumbar Plexus.

This plexus is found embedded in the substance of the psoas muscle, which must be removed piece by piece for its proper demonstration.

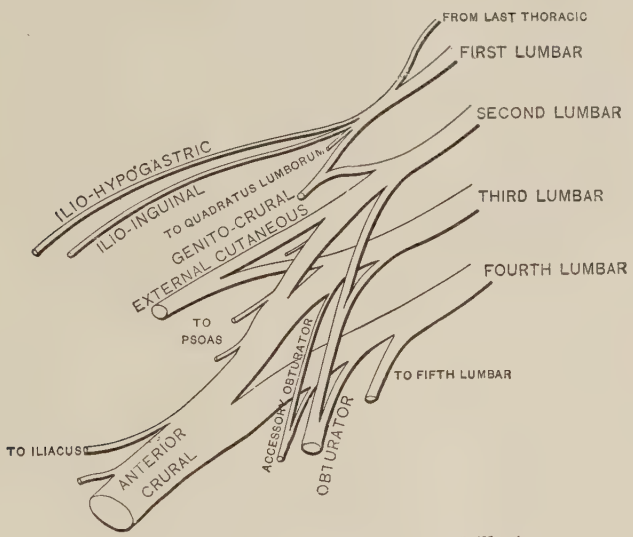

FIG. 713.—Plan of lumbar plexus. (W. Keiller.)

A glance at the diagram (Fig. 713) will show its general constitution. From the *first lumbar* nerve spring the *iliohypogastric* and *ilioïnguinal* nerves, from the *first* and *second* the *genitocrural*, from the *second* and *third* comes the *external cutaneous*, while large sections of the *second*, *third*, and *fourth* nerves form the *anterior crural*, and smaller more anterior sections of the same trunks unite to form the *obturator nerve*. The *accessory obturator* is a small, inconstant branch derived from the *third* and *fourth* nerves, and branches supply the *psoas* and *quadratus lumborum* from nearly all the nerves in a somewhat irregular manner.

Regarding their relations to the psoas muscle, the iliohypogastric, ilioïnguinal, external cutaneous, and anterior crural nerves emerge from its outer border, the last nerve running down its outer side to pass under the inguinal (Poupart's)

ligament; the genitocrural nerve pierces the anterior surface of the muscle and descends to the pelvis in its sheath; and the obturator and accessory obturator nerves and the lumbar contribution to the sacral plexus cross the pelvic brim along its inner side.

1. The Iliohypogastric Nerve.

The *iliohypogastric nerve* (Figs. 714, 720) arises in common with the *ilioïnguinal* from the first lumbar, and occasionally blends with it to form one nerve. Emerging from the outer border of the psoas it crosses the quadratus in the subperitoneal areolar tissue, and enters the space between the transversalis and inter-

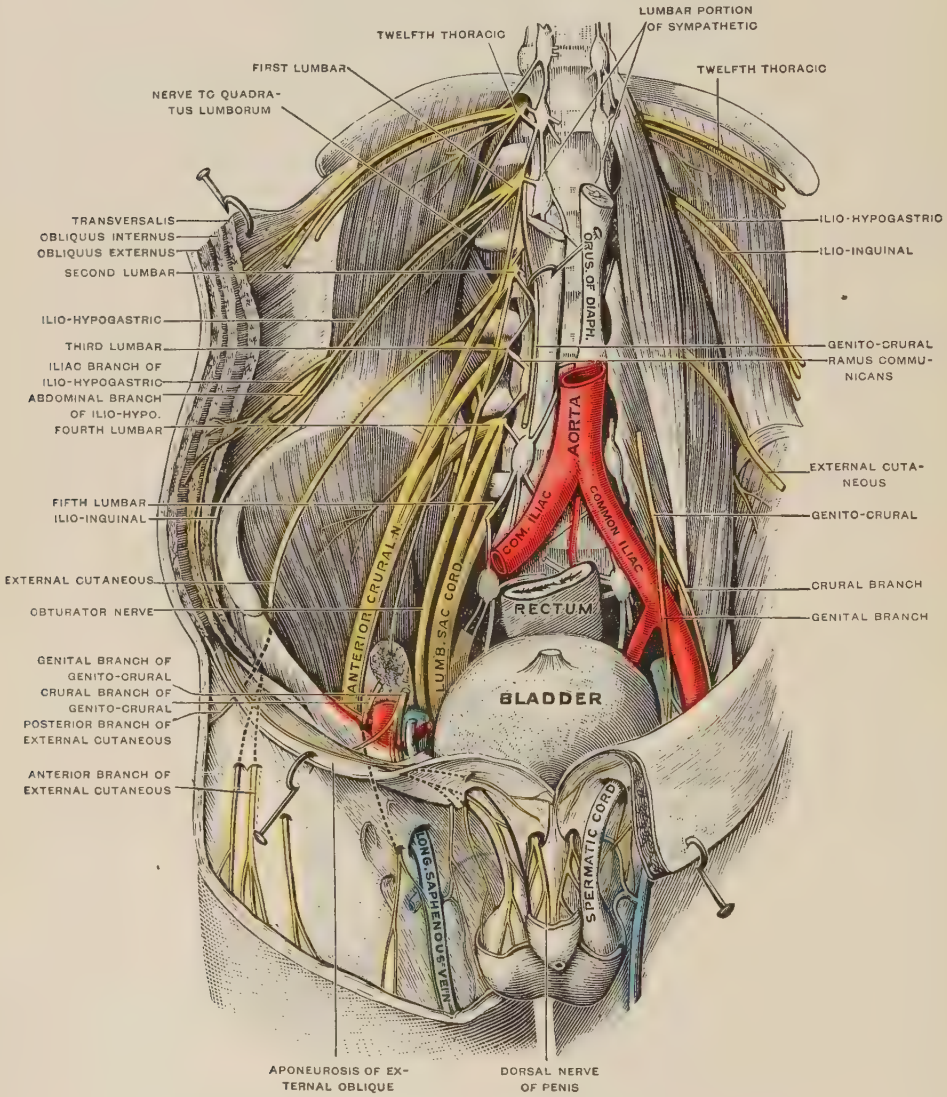

FIG. 714.—Deep and superficial dissection of the lumbar plexus. (Testut.)

nal oblique. It runs parallel with the iliac crest and, about two and a half inches behind the anterior superior iliac spine, gives off its *iliac branch*. Continuing onward the nerve pierces the internal oblique near the iliac spine, and becomes cutaneous about an inch above the external abdominal ring.

Its **iliac branch** pierces the abdominal muscles and, like the corresponding

branch of the last thoracic nerve, crosses the iliac crest to the gluteal region, supplying the skin between the crest and the great trochanter.

2. The Ilioïnguinal Nerve.

The *ilioïnguinal nerve* (Figs. 714, 715, 727, 728) arises in common with the last and accompanies it as far as the iliac spine but a little lower, uniting with it in a plexiform manner. It gains the inguinal canal and appears at the external abdominal ring in front of the spermatic cord, dividing into branches to the inner side of the thigh, and the scrotum or labium majus according to sex. These two nerves supply twigs to the muscles of the abdominal wall.

3. The Genitocrural Nerve.

The *genitocrural nerve* (Figs. 714, 715, 719, 727, 728) arises from the first and second lumbar nerves. It appears on the anterior surface of the psoas muscle, on which it descends, dividing into two branches near the commencement of the external iliac artery or anywhere above this point.

The **internal or genital branch** joins the external iliac artery, to which it contributes a twig, and then enters the inguinal canal. It is found on the back of the cord and is distributed to the *cremaster* muscle. In the female it is small and accompanies the round ligament.

The **external or crural branch** accompanies the psoas under the inguinal ligament and pierces the deep fascia just outside of the common femoral artery to supply the skin in front of the thigh.

4. The External Cutaneous Nerve.

The *external cutaneous nerve* (Figs. 714, 715, 717, 720, 727, 728), derived from the second and third lumbar nerves, pierces the outer border of the psoas and descends across the iliacus and under the fascia iliaca to the notch beneath the anterior superior iliac spine. Here it enters the thigh under the inguinal ligament and divides into a small *posterior branch* to the skin in front of the great trochanter, and a large *anterior branch* which descends for some distance in a sheath of fascia lata, and is distributed to the skin on the outer side of the thigh as low as the knee, where it joins the plexus patellæ.

5. The Anterior Crural Nerve.

The *anterior crural nerve* (Figs. 714, 715, 717) is the largest trunk formed by the lumbar plexus. It springs from the second, third, and fourth lumbar nerves, the roots uniting in the substance of the psoas muscle to form one trunk, which descends along its outer side to accompany the muscle under the inguinal ligament to the thigh. In the thigh the nerve is separated from the common femoral artery by about half an inch, and divides immediately into a large number of branches which may conveniently be classified as cutaneous and muscular, some of the latter furnishing articular twigs to the hip and knee-joints.

(*a*) The *nerves to the iliacus* are given off in the abdomen as the nerve crosses the muscle.

(*b*) The *nerve to the pectineus* arises immediately below the inguinal ligament, and crosses inward to its muscle behind the common femoral vessels.

(*c*) The *nerves to the rectus and vastus externus* run downward and outward beneath the former muscle, that *to the vastus internus* runs parallel with the long saphenous nerve as far as Hunter's canal. Of these the nerve to the rectus sends a twig to the hip-joint and each of the others sends articular branches to the knee.

(*d*) The **middle cutaneous nerve** (Figs. 715, 716, 717, 727, 728) consists of two strong branches, one of which pierces and supplies the sartorius. They

perforate the deep fascia half way down the thigh, and supply the skin in front as far down as the knee-joint, joining the plexus patellæ.

(*e*) The **internal cutaneous nerve** (Figs. 717, 727, 728, 730, 732) crosses obliquely over the superficial femoral artery in Scarpa's triangle, and divides into an *anterior* and a *posterior branch*, which follow the anterior and posterior borders of the sartorius respectively. They pierce the fascia lata in the lower third of the thigh and supply the skin on its inner aspect as low as the knee. The anterior branch joins the plexus patellæ, and the posterior branch the subsartorial plexus.

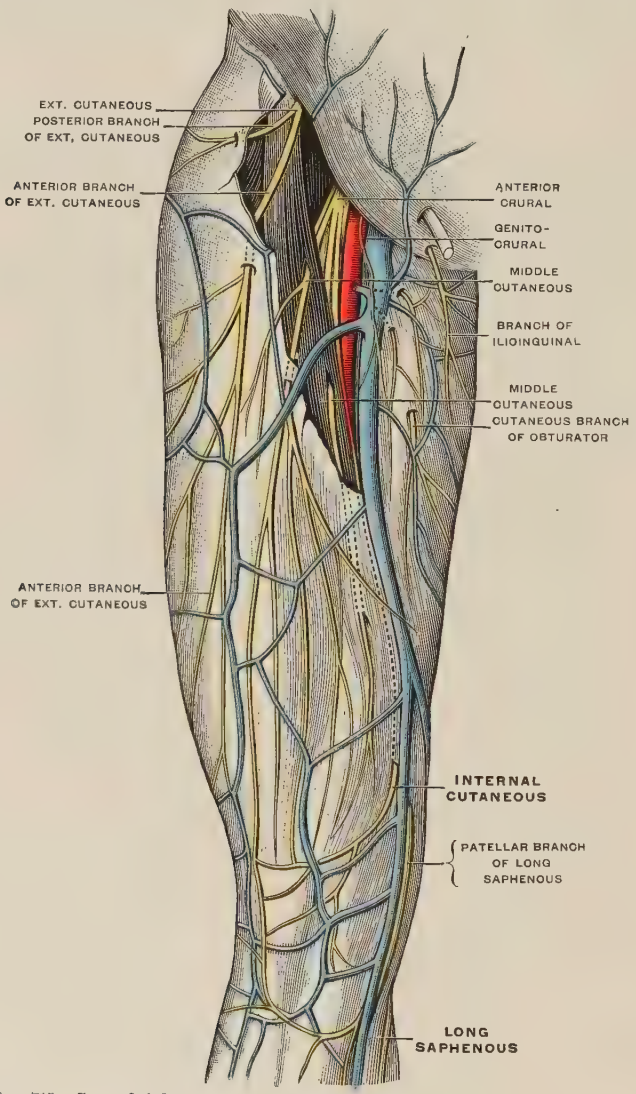

FIG. 715.—Superficial nerves of the anterior surface of the thigh. (Testut.)

(*f*) The **internal** or **long saphenous nerve** (Figs. 716, 717, 722, 725, 726, 727, 728, 730, 732) accompanies the nerve to the vastus internus to the apex of Scarpa's triangle. Here it enters Hunter's canal, in which it descends in front of the femoral artery. At the lower end of the canal it seeks the surface, by passing with the superficial branch of the anastomotica magna artery between the sartorius and gracilis, and piercing the deep fascia just below the knee. It then joins the long saphenous vein, distributes branches to the skin all down the

inner side of the leg, and, descending in front of the internal malleolus, ends on the inner side of the ball of the great toe.

Its **patellar branch** is given off as it leaves Hunter's canal. It perforates the sartorius and supplies the skin on the inner side of the knee-joint, joining the plexus patellæ.

6. The Obturator Nerve.

The *obturator nerve* (Figs. 714, 715, 717, 719) arises from the second, third, and fourth lumbar nerves. It descends on the inner side of the psoas muscle to the pelvic brim, and then between the peritoneum and pelvic fascia to the obturator foramen, through which it passes where the membrane is deficient, the obturator artery lying below it. In the obturator foramen it divides into an anterior and a posterior branch.

(*a*) The **anterior branch** passes in front of the obturator externus and adductor brevis, and behind the pectineus and adductor longus. It supplies the hip-joint, the adductor longus and brevis, the gracilis, and occasionally the pectineus, and terminates by becoming cutaneous to the inner side of the thigh, and joining the subsartorial plexus.

(*b*) The **posterior branch** pierces the fibres of the obturator externus, and descends on the adductor magnus and behind the adductor brevis. It supplies the hip-joint, obturator externus, and adductor magnus, and terminates in a long slender fibre, which enters the popliteal space on the inner side of or behind the femoral artery, and, after giving a twig to accompany the superior internal articular artery, ends by piercing the posterior ligament of the knee-joint.

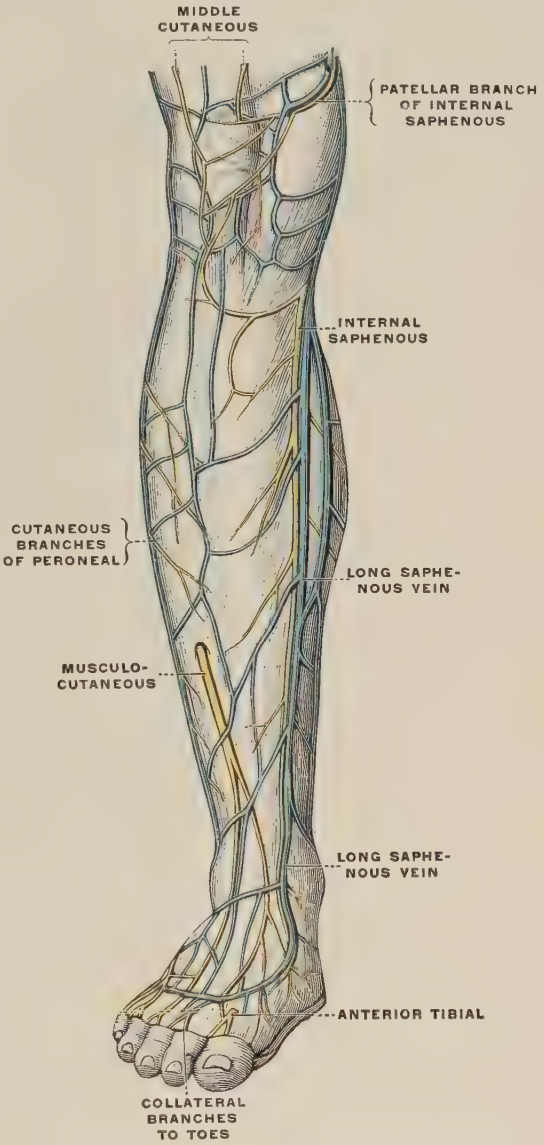

FIG. 716.—Superficial nerves of the front of the leg. (Testut.)

7. The Accessory Obturator Nerve..

The *accessory obturator nerve* is a small inconstant branch, derived from the obturator or from the same lumbar nerves. It crosses the horizontal ramus of the os pubis under the pectineus, and supplies that muscle and the hip-joint, forming a loop with the anterior branch of the obturator.

The Plexus Patellæ.—The external, middle, and internal cutaneous nerves and

patellar branch of the long saphenous interlace with each other as they supply the skin round the patella.

The **subsartorial plexus** is formed under the sartorius, in the lower third of the thigh by interlacing branches of the internal cutaneous, obturator, and long saphenous nerves.

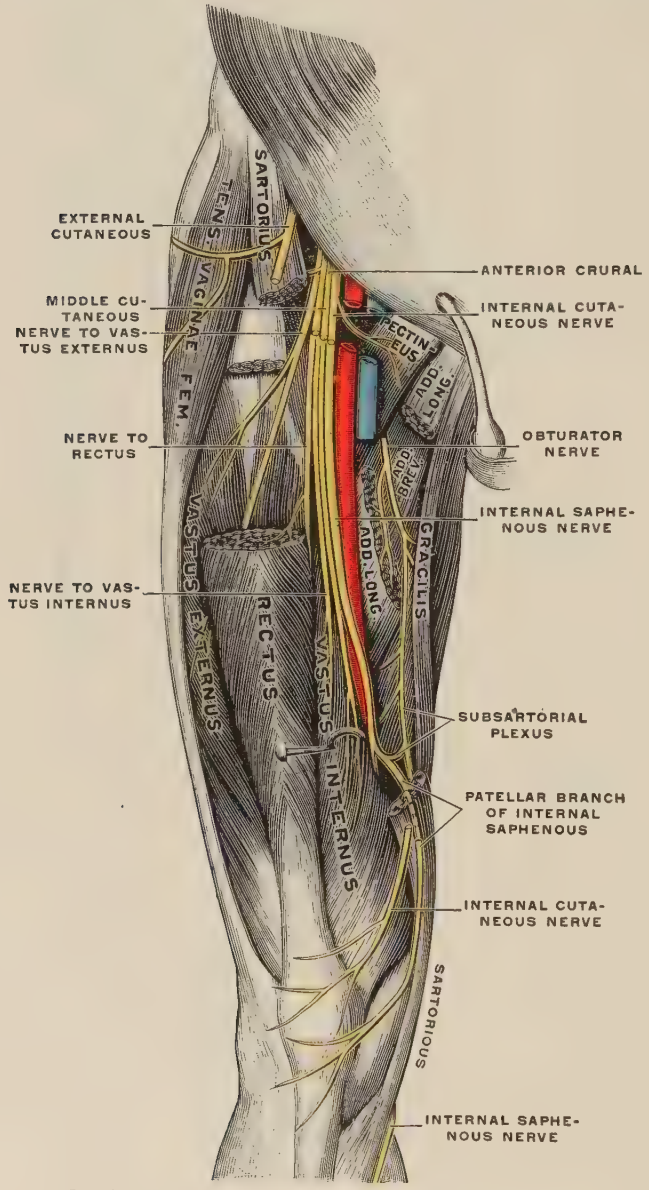

FIG. 717.—Deep nerves of the front of the thigh. (Testut.)

THE SACRAL AND COCCYGEAL NERVES.

The anterior divisions of the upper four sacral nerves enter the pelvic cavity through the anterior sacral foramina, the fifth sacral nerve passes forward between the sacrum and cornu of the coccyx, and the coccygeal nerve leaves the spinal canal through its terminal opening. The upper three sacral nerves join with part of the fourth and the whole of the fifth lumbar nerves, and part of the fourth

sacral nerve to form the sacral plexus; the rest of the fourth sacral and remaining nerves form the coccygeal plexus.

The Sacral Plexus.

A variable portion of the fourth lumbar nerve joins the fifth lumbar to form the lumbo-sacral cord. This trunk crosses the brim of the pelvis, pierces the pelvic fascia, and under cover of this fascia joins the sacral nerves on the ventral

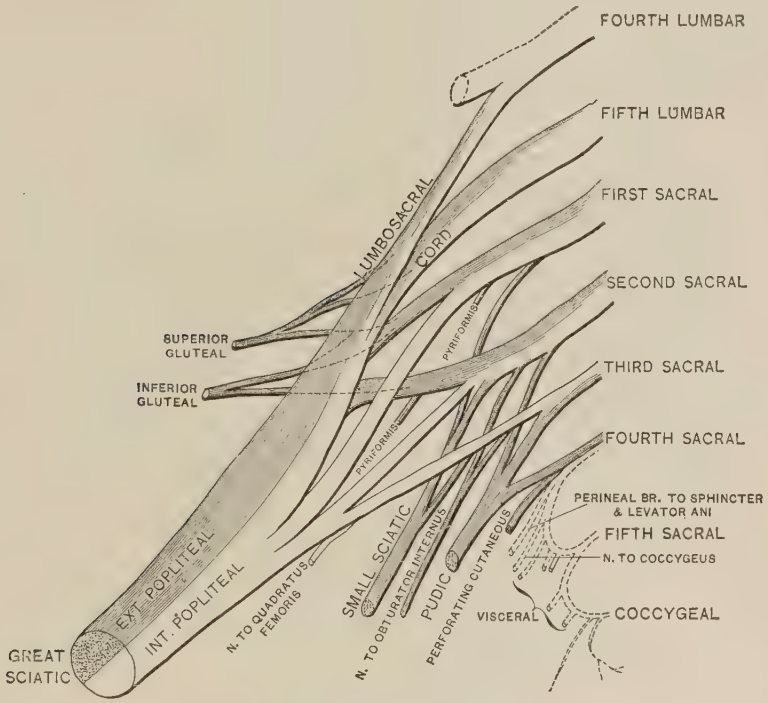

FIG. 718.—Plan of sacral plexus.

surface of the pyriformis muscle. With the first and second and greater part of the third sacral nerves the lumbo-sacral cord forms a great compound nervous trunk called the great sciatic nerve. A small band from the second sacral unites with the remainder of the third sacral and with the fourth sacral nerves to form the internal pudic nerve. Thus the two main or terminal trunks are formed; but, in addition to these, numerous collateral branches are given off: the superior gluteal, the inferior gluteal, the small sciatic, the perforating cutaneous, and nerves to the pyriformis, obturator internus, gemelli and quadratus femoris. The branches of this plexus are divisible into a dorsal and a ventral set. In the diagram the dorsal set are shaded. They spring from the back of the plexus and supply the extensor aspect of the limb; the ventral set spring from the anterior surface of the plexus and supply the flexor muscles.

COLLATERAL BRANCHES.

The twigs *to the pyriformis* are derived from the first and second sacral nerves.

The nerve *to the quadratus femoris* lies on the ventral surface of the plexus, its fibres springing from the lumbo-sacral cord and first sacral nerve. On the hip it is seen descending under the obturator internus and gemelli to reach the ventral surface of the quadratus, distributing on its way branches to the inferior gemellus and hip-joint.

The nerve *to the obturator internus*, from the fifth lumbar and upper two sacral nerves, appears on the hip beneath the pyriformis, crosses the spine of the ischium outside the internal pudic vessels, and passes through the small sacrosciatic foramen to the obturator internus, supplying the superior gemellus as it passes.

The **superior gluteal nerve** (Figs. 719, 721), springing from the back of the lumbo-sacral cord and first sacral nerve, leaves the pelvis through the great sacro-

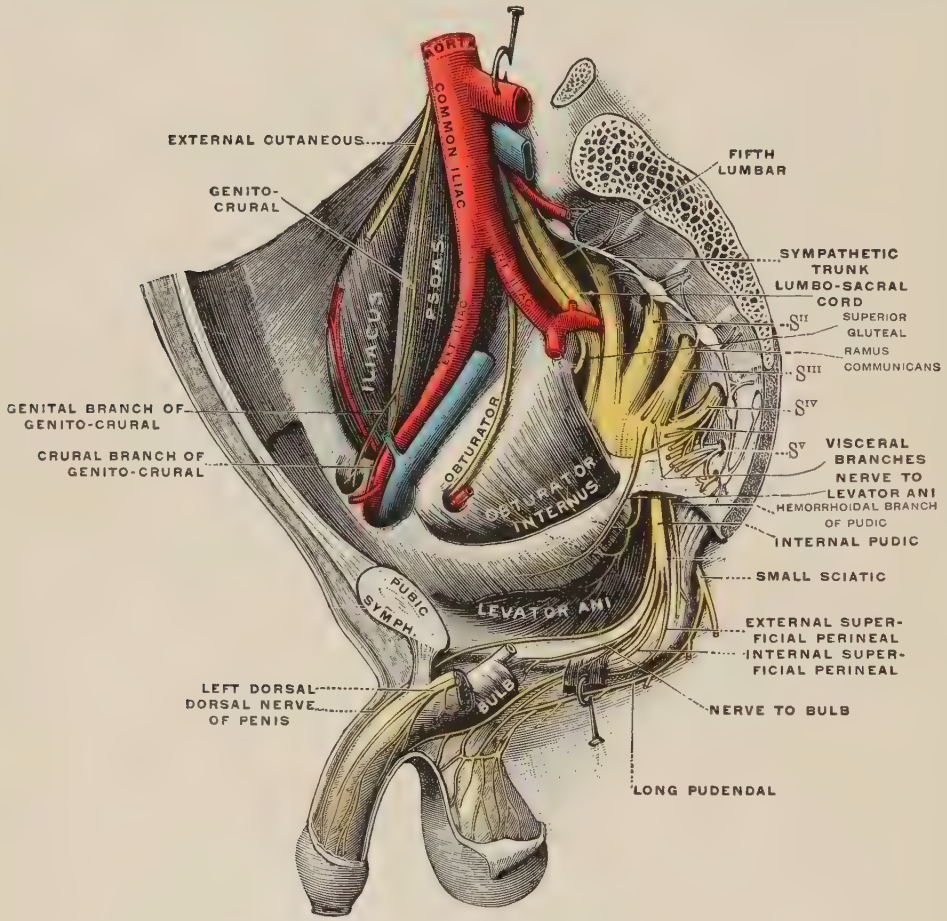

FIG. 719.—Sacral plexus of the right side. (Testut.)

sciatic foramen with the gluteal vessels, and under the gluteus medius divides into a small superior branch to that muscle, and a larger inferior branch, which accompanies the inferior branch of the gluteal artery and is distributed to the gluteus medius and minimus, and tensor vaginæ femoris.

The **inferior gluteal nerve** (Fig. 721) arises from the lumbo-sacral cord and first and second sacral nerves, and is frequently closely associated with the small sciatic nerve. It emerges from the great sacrosciatic foramen beneath the pyriformis, and enters the deep surface of the gluteus maximus, which it supplies.

The **small sciatic nerve** (ischiatic nerve) (Figs. 719, 720, 721, 729, 730) is a purely cutaneous nerve, supplying the skin of the buttock, perineum, and back of the thigh and popliteal region. It springs from the back of the upper three sacral nerves, and appears on the buttock beneath the pyriformis, and on the surface of the great sciatic nerve. At the lower border of the gluteus maximus it lies under the deep fascia on the middle line of the back of the thigh. Distributing cutaneous filaments as it descends, its terminal fibres pierce the deep fascia

at the bend of the knee, and end in the skin of the calf, joining the external saphenous nerve. Its *cutaneous branches to the gluteal region* are two or three in number, and bend upward over the lower border of that muscle to the skin of the lower and outer part of the buttock.

Its *inferior pudendal branch* turns inward beneath the tuber ischii and pierces

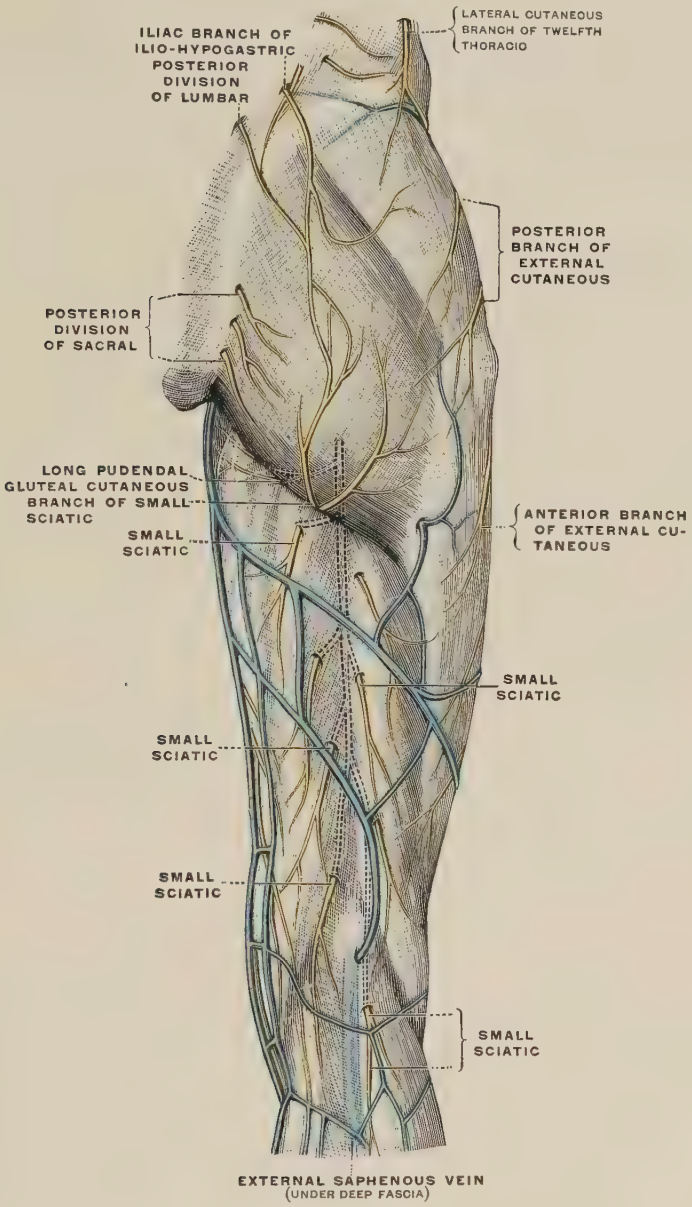

FIG. 720.—Superficial nerves of buttock and back of thigh. (Testut.)

the fascia lata on the inner side of the thigh about one inch in front of the tuberosity. It supplies the skin in this region, and passes forward and inward to the scrotum or labium majus, joining the external superficial perineal branch of the internal pudic nerve.

The **perforating cutaneous nerve** is a small twig from the second and third

sacral nerves, which pierces the great sacrosciatic ligament to reach the skin over the lower and inner part of the gluteus maximus.

TERMINAL BRANCHES.

The Pudic Nerve.

The greater part of the third sacral nerve is augmented by contributions from the second and fourth to form the pudic trunk (Figs. 719, 721), which emerges from the pelvis through the great sacrosciatic foramen, hooks round the small sacrosciatic ligament on the inner side of the pudic vessels, and enters the outer wall of the ischiorectal fossa, where it accompanies the vessels just mentioned. At the back of the fossa it gives off its inferior hemorrhoidal branch, and about one inch farther forward divides into the perineal nerve and the dorsal nerve of the penis.

The **Inferior Hemorrhoidal Nerve** pierces the obturator fascia well back under cover of the gluteus maximus, and crosses inward through the fat of the ischiorectal fossa, distributing its branches in fan-like manner to the sphincter ani externus and the skin round the anus.

The **perineal nerve** consists of a superficial and a deep division. The *superficial division* forms two nerves. The *posterior* or *external superficial perineal nerve* crosses the transversus perinei superficially, and runs forward in the scrotum or labium majus outside the superficial perineal vessels. It interlaces with the inferior pudendal and internal superficial perineal nerve. The *anterior* or *internal superficial perineal nerve* enters the ischiorectal fossa in front of the preceding, pierces the transversus perinei muscle, and passes forward on the inner side of the superficial perineal vessels to the scrotum or labium majus, interlacing with the nerve preceding. The *deep division* crosses inward parallel with the transversus perinei, and distributes branches to the external sphincter, levator ani, transversus perinei, ischio-cavernosus, and bulbo-cavernosus, and to the corpus spongiosum and urethral mucous membrane.

The **dorsal nerve of the penis** passes with the internal pudic vessels between the layers of the triangular ligament. Here it sends twigs to the constrictor urethræ and corpus cavernosum, and then pierces the inferior layer of the triangular ligament, appearing on the dorsum of the penis on the outer side of the dorsal vessels. It is distributed to the skin covering the corpus cavernosum and glans, communicating with sympathetic fibres.

In the female a similar but much smaller nerve is distributed to the clitoris.

The Great Sciatic Nerve.

The great sciatic nerve (Figs. 721, 723) is a compound trunk consisting of two great divisions—the peroneal (external popliteal) and the popliteal (internal popliteal). With the latter are associated the nerves which supply the hamstrings and adductor magnus. These are usually united to form one great trunk, which divides into popliteal and peroneal a little below the middle of the thigh; but they may be actually separate, or easily separated by dissection, as far as their constituent elements in the sacral plexus. Thus analyzed, the popliteal segment is seen to consist of ventral portions of the lumbosacral cord and upper three sacral nerves, and the peroneal nerve is traceable to the dorsal surface of the lumbosacral cord and upper two sacral nerves.

The great sciatic nerve appears on the buttock at the lower border of the pyriformis, and crosses the gemelli, obturator internus, and quadratus femoris under cover of the gluteus maximus. At the lower border of the last muscle it is found midway between the tuber ischii and the great trochanter in an angle formed by the gluteus maximus and biceps. It now descends on the adductor

magnus, and is crossed obliquely by the long head of the biceps, dividing at a variable distance down the thigh into the (internal) popliteal and peroneal nerves.

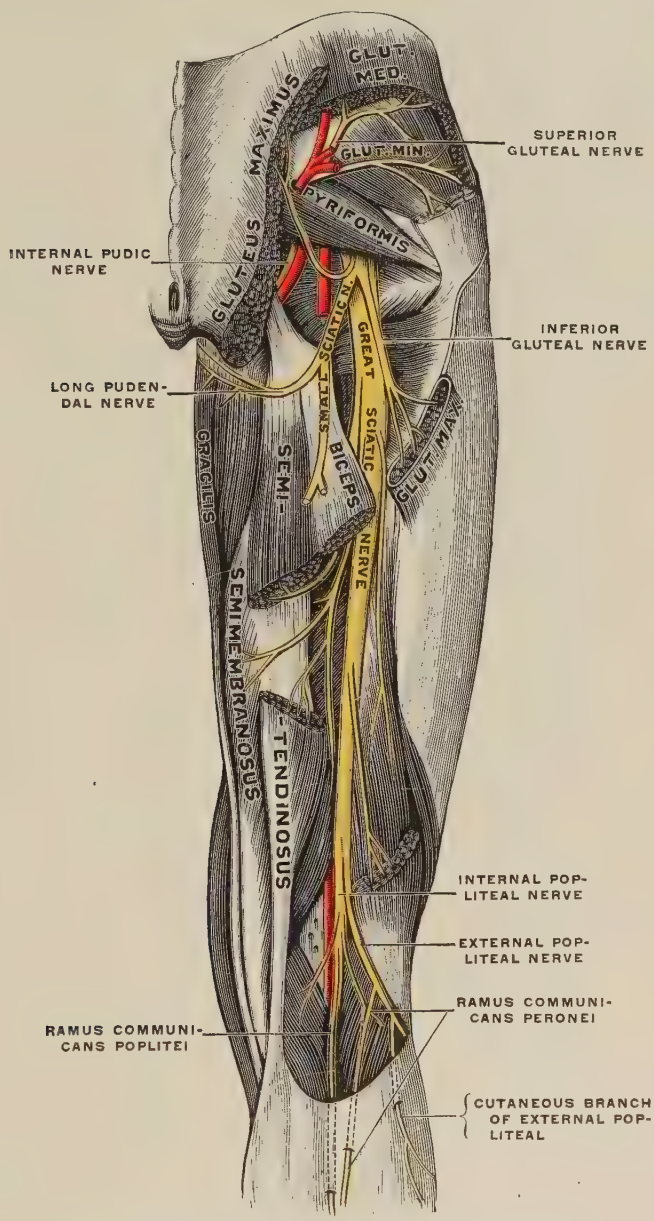

FIG. 721.—Deep nerves of buttock and back of thigh. (Testut.)

It gives off four branches, viz., one to the semitendinosus, one to the semimembranosus and adductor magnus, and one to each head of the biceps.

The Internal Popliteal Nerve.

The internal popliteal (nervus tibialis) (Figs. 721–723) descends vertically in the middle of the popliteal space, till, reaching the lower border of the popliteus muscle, it is named the *posterior tibial nerve.* At first it is some distance

on the outer side of the popliteal vessels; but where these vessels reach the middle line it is closely adherent to the posterior surface of the vein, tending toward the inner side below.

Branches.—The **articular branches**, usually three in number, accompany the superior and inferior internal articular, and azygos articular arteries to the knee-joint. The upper is frequently absent.

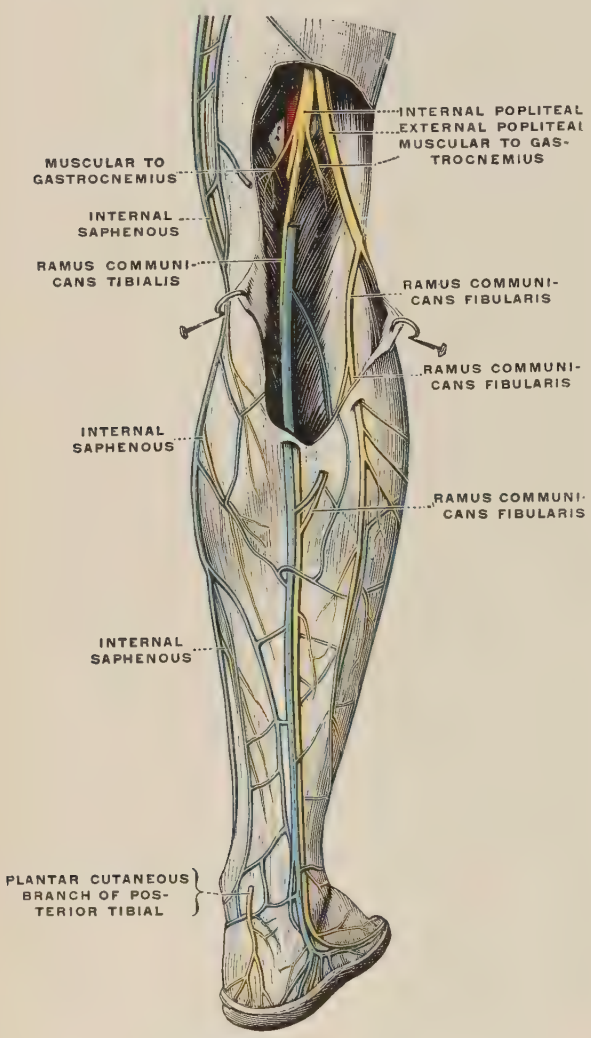

Fig. 722.—Superficial nerves of the back of the leg. (Testut.)

The **muscular branches** are distributed to the gastrocnemius (1. 2. s.), plantaris (4. 5. l, 1. s.), soleus (5. l, 1. 2. s.), and popliteus (4. 5. l, 1. s.). Of these the nerve to the popliteus is given off under the gastrocnemius and descends on the outer side of the popliteal vessels to reach the lower border of its muscle. It winds beneath it and supplies the muscle on its anterior surface, giving also a branch to the tibia accompanying its medullary artery, one to the interosseous membrane and inferior tibiofibular joint, and another to the superior tibiofibular articulation.

The **cutaneous branch** (ramus communicans tibialis vel poplitei) descends along the middle of the leg in the groove between the heads of the gastrocnemius, and pierces the deep fascia about half way down, to be joined by a similar branch from the peroneal nerve (ramus communicans peronei). Together they form the short or external saphenous nerve, which now accompanies the short saphenous vein beneath the external malleolus to the outer side of the foot, where it supplies the outer side of the foot and little toe, communicating with the musculocutaneous. It distributes branches to the skin on the back of the leg, external calcanean branches to the outer side of the heel, and articular branches to the ankle and astragalo-calcanean joints.

The Posterior Tibial Nerve.

At the lower border of the popliteus muscle the popliteal nerve is called the posterior tibial (Fig. 723). It passes down the middle of the leg on the deep muscles, and beneath the deep transverse sheet of fascia. The posterior tibial artery is at first on the outer side of the nerve, but, after giving off the peroneal artery it crosses abruptly a little inward beneath the nerve, and then descends

on its inner side. Between the internal malleolus and the inner tuberosity of the os calcis the posterior tibial divides into the internal and external plantar nerves.

Branches.—(*a*) **Muscular branches** (5. 1., 1. 2. s.) supply the tibialis posterior, flexor longus digitorum, and flexor longus hallucis; besides which there is a supplementary branch to the soleus.

(*b*) The **fibular branch** accompanies the peroneal artery, supplying these vessels, the fibular periosteum and the medulla of that bone.

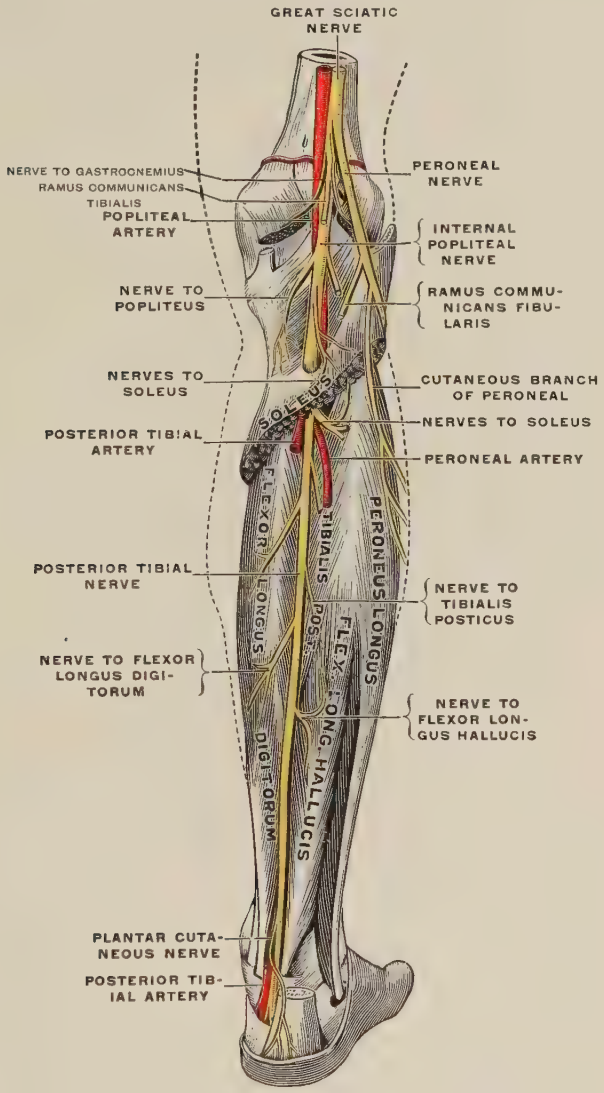

Fig. 723.—Deep nerves of the back of the leg. (Testut.)

(*c*) The **calcaneo-plantar** nerve (1. 2. s.), arising from the posterior tibial in the lower fourth of the leg, becomes cutaneous by piercing the internal annular ligament. It then divides into *internal calcaneal* branches to the skin of the heel, and *plantar cutaneous* branches to the inner side of the sole.

(*d*) **Articular filaments** supply the ankle-joint.

The **Internal Plantar Nerve** (Figs. 724, 726, 728, 731, 732) (4. 5. 1., 1. s.) is slightly the larger of the two terminal divisions of the posterior tibial. It distributes cutaneous nerves to the inner three and a half toes, and supplies the

abductor hallucis, flexor brevis digitorum, flexor brevis hallucis, and inner lumbrical muscle. It passes forward under the origin of the abductor hallucis, then in the groove between that muscle and the flexor brevis digitorum, accompanying the internal plantar artery. Under cover of the plantar fascia it divides into *four digital nerves*. Of these the innermost passes undivided to the inner side of the great toe, giving a branch on its way to the flexor brevis hallucis, the remaining three nerves, emerging between the processes of plantar fascia, divide each into two collateral branches for the adjacent sides of the corresponding toes, the digital nerve to the first cleft supplying the inner lumbrical muscle, and the most external branch communicating with the external plantar nerve. The *muscular branches* to the abductor hallucis and flexor brevis digitorum are given

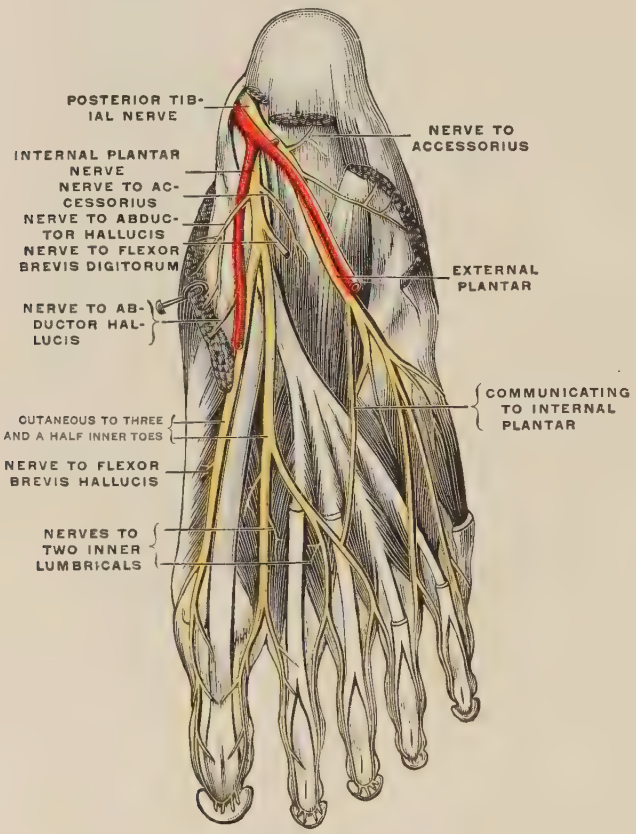

FIG. 724.—Plantar nerves. (Testut.)

off near the commencement of the nerve, *articular* fibres supply some of the joints of the foot, and *plantar cutaneous* twigs are distributed to the sole. As in the case of the corresponding nerve of the hand, the plantar digital nerves supply the skin on the dorsum of the ungual phalanx and the bed of the nail.

The **External Plantar Nerve** (Figs. 724, 726, 731, 732) accompanies the external plantar artery between the flexor brevis digitorum and flexor accessorius, till, gaining the hollow between the former muscle and the abductor minimi digiti, it divides into a superficial and a deep branch. Before dividing, it gives branches to the flexor accessorius and abductor minimi digiti.

The *superficial terminal* branch sends one digital branch to the outer side of the little toe, and a second, which, passing beneath the plantar fascia to the cleft between the fourth and fifth toes, divides into collateral branches to their adjacent surfaces, first communicating with the internal plantar nerve. The outer digital

branch supplies a twig to the flexor brevis minimi digiti, and occasionally supplies the interosseous muscles of the fourth space.

The *deep branch* of the external plantar nerve continues to accompany the external plantar artery beneath the long flexor tendons. It supplies branches to all the interosseous muscles (except occasionally those of the fourth space), the outer three lumbricals, and the adductor obliquus and adductor transversus hallucis; as well as articular filaments to the tarso-metatarsal and metatarso-phalangeal joints.

The External Popliteal or Peroneal Nerve.

This nerve (4. 5. 1; 1. 2. s.) (Figs. 722, 721, 723, 716, 725, 728, 730) descends obliquely along the outer boundary of the popliteal space following closely the inner border of the biceps muscle and its tendon as far as the fibula, thus crossing the outer head of the gastrocnemius. Beneath the head of the fibula it winds round the outer side of that bone, piercing the peroneus longus, and in its substance dividing into the musculocutaneous and anterior tibial nerves. Shortly after its formation it gives off, frequently by one common trunk, two *external articular branches*, which accompany the superior and inferior external articular arteries to the knee-joint. A *recurrent articular branch* is given off just before the nerve bifurcates. It passes under the peroneus longus and extensor longus digitorum to join the anterior tibial recurrent artery. Many of its fibres end in the upper end of the tibialis anterior, but some pass to the superior tibio-fibular joint, the periosteum over the outer tuberosity of the tibia and the knee joint.

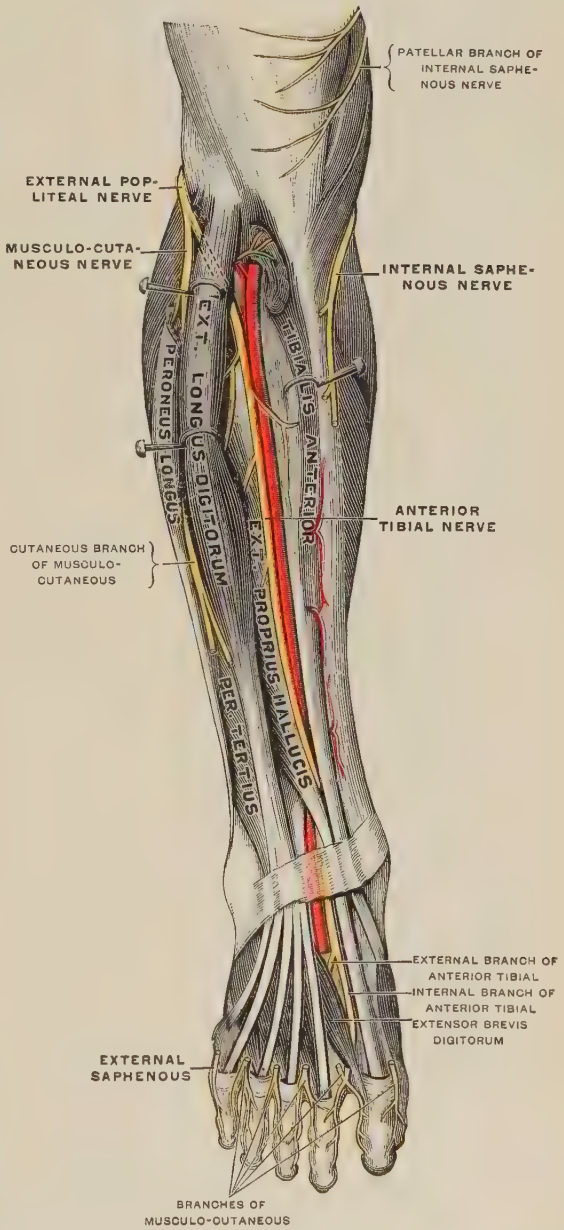

FIG. 725.—Deep nerves of the front of the leg. (Testut.)

Of the two *cutaneous branches* (5. 1., 1. 2. s.) the *ramus communicans peronei* or *fibular communicating branch* joins the tibial, communicating below the middle of the leg to form the short saphenous nerve. Sometimes they do not join, and then this nerve usually ends on the heel or outer side of the foot. The *lateral cutaneous branch* of the peroneal nerve supplies the skin along the outer side of the upper two thirds of the leg.

The **Musculocutaneous Nerve** (4. 5. l., 1. s.) (Figs. 716, 725, 726, 727, 728) descends obliquely beneath the peronei muscles, and between them and the extensor longus digitorum, supplies *muscular branches* to the peroneus longus and brevis, and pierces the deep fascia near the middle line of the leg near its lower fourth. It then divides into two branches, internal and external, which descend in the superficial fascia to the dorsum of the foot, supplying filaments to the skin on the front of the leg, as they proceed downward.

The **internal branch** sends a branch to the inner side of the great toe, communicating with the long saphenous nerve, a second branch to join the anterior tibial nerve as it divides into collaterals to the contiguous side of the first and second toes, and a third branch to supply collaterals to the second and third toes.

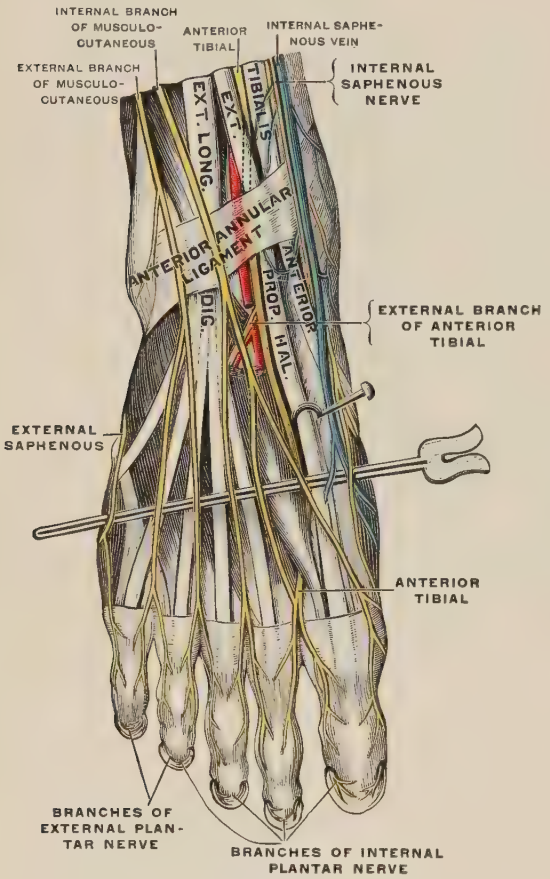

FIG. 726.—Nerves of the dorsum of the foot. (Testut.)

The **external branch** supplies digital nerves to the contiguous sides of the third and fourth, and fourth and fifth toes, and communicates with the short saphenous nerve.

It will thus be seen that the short saphenous nerve supplies the outer side of the little toe, the anterior tibial supplies the contiguous surfaces of the first and second toes, and the musculocutaneous nerve supplies all the rest of the dorsum of the foot; the long saphenous nerve stopping short at the ball of the great toe.

The **Anterior Tibial Nerve** (4. 5. l., 1. s.) (Figs. 716, 725, 726, 727, 728) descends obliquely through the peroneus longus and extensor longus digitorum to lie on the interosseous membrane and anterior tibial artery. It reaches the side of that vessel about the junction of the upper and second fourths, descends a short distance on its outer side, and then in front of it, to be again placed on the outer side (occasionally inner side) of the vessel beneath the anterior annular ligament. Here it divides into an internal and an external branch.

BRANCHES.—(*a*) *Muscular branches* supply the tibialis anterior, extensor longus digitorum, extensor proprius hallucis, and peroneus tertius.

(*b*) An *articular filament* supplies the ankle-joint.

(*c*) The **external branch** crosses outward under the extensor brevis digitorum, becomes enlarged like the posterior interosseous in the hand, and breaks up into branches, which supply the extensor brevis digitorum and the tarsal joints.

(*d*) The **internal branch** appears to be the direct continuation of the nerve, as it accompanies the dorsalis pedis artery, lying usually on its outer, sometimes on its inner side. Opposite the tarso-metatarsal joint it communicates with the musculo-cutaneous, and divides into branches to the outer side of the great, and inner side of the second, toe.

The Fourth and Fifth Sacral and the Coccygeal Nerves.

The Fourth Sacral Nerve.—As already described, a small portion of the fourth sacral nerve ascends to join the sacral plexus. The remainder divides into visceral and muscular branches and a communicating filament to the fifth sacral.

The *visceral branches* descend on the pelvic surface of the coccygeus and levator

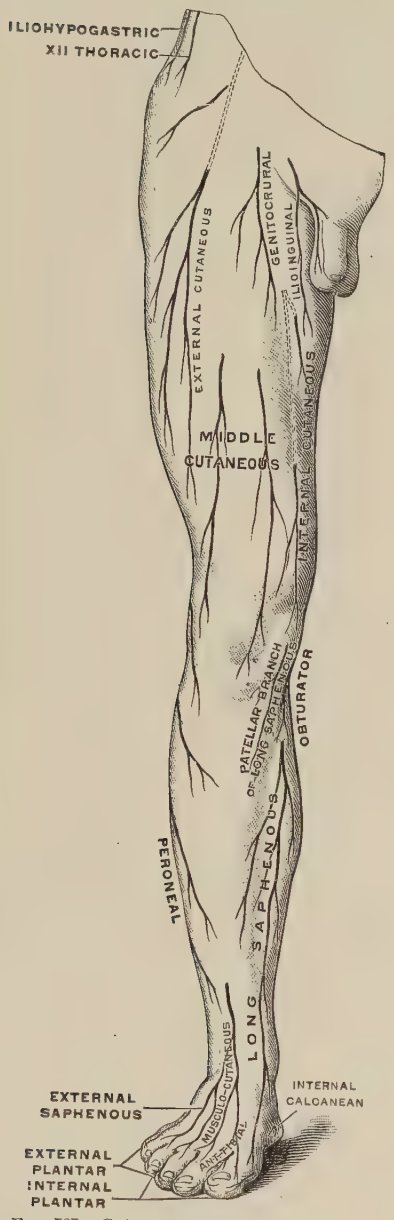

Fig. 727.—Cutaneous nerves of the front of the lower limb. (W. Keiller.)

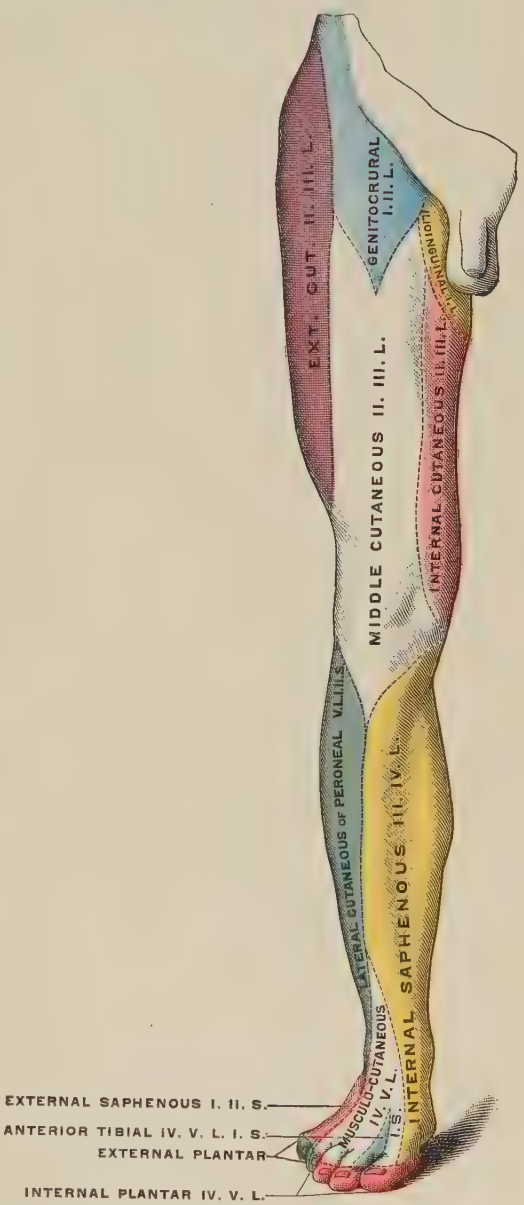

Fig. 728.—Areas of distribution of cutaneous nerves of the front of the lower limb. (W. Keiller, after Testut.)

ani to the bladder, rectum, and, in the female, the uterus and vagina. They communicate freely with the pelvic sympathetic and visceral branches of the third sacral nerve.

The *muscular branches* supply the levator ani and coccygeus on their pelvic surface, and a twig to the external sphincter (perineal branch) pierces the coccy-

geus or passes between it and the levator ani to the postero-internal angle of the ischio-rectal fossa, thus reaching its muscle and supplying it and the skin around the anus.

The **Fifth Sacral Nerve**, emerging from the spinal canal between the sacrum and cornu of the coccyx, enters the pelvis, and on the pelvic surface of the coccygeus muscles gives an *ascending filament* to join the fourth sacral, a *descending filament* to unite with the coccygeal nerve. It then descends on the coccygeus toward the tip of the coccyx, supplies twigs to the coccygeus muscle, and finally pierces that muscle to end in the skin over the coccyx.

The **Coccygeal Nerve** is an exceedingly small filament, which emerges from the lower end of the spinal canal, and pierces the sacrosciatic ligaments and coccygeus muscle to join the fifth sacral nerve.

The connection between the fourth and fifth sacral and coccygeal nerves is called the *coccygeal plexus*.

THE SYMPATHETIC NERVES.

The sympathetic system consists of two chains of ganglia, lying one on each side of the spinal column, which are developed as outgrowths from the spinal cord, and remain permanently connected with the spinal nerves. Its function is to innervate the viscera, glands, heart and blood-vessels, and the unstriped muscles of the body generally. This system presides in fact over the vital or vegetative, as contrasted with the voluntary or exclusively animal functions of the body, remaining, however, under control of the central nervous system.

If we take the arrangement in the thorax as typical, the ganglia should correspond in number with the spinal nerves; but in the neck there are only three ganglia, several being fused into one, and in the abdomen also the number is short; so that, while there are 31 spinal nerves on each side, there are only 20 to 23 ganglia. *Each ganglion* is reddish-gray in color, somewhat fusiform in shape and softish in consistence, but enclosed in a strong fibrous sheath. It is connected with that above and below it by *an ascending* and *a descending trunk*, and with at least one spinal nerve by one or two *rami communicantes*. Each ganglion distributes *rami efferentes*, which either directly or through the intervention of a secondary plexus supply blood-vessels or viscera, the efferent branches to the limbs and body-wall, however, joining the spinal nerves by the gray rami communicantes, and thus reaching their destination.

The gangliated cords are connected superiorly with the upper cranial nerves by branches which enter the cranium with the internal carotid artery, and inferiorly they converge over the front of the sacrum to meet in a single ganglion in front of the coccyx.

In addition to these two chains the following also belong to the sympathetic system:

1. **Sporadic ganglia**, namely the ciliary, Meckel's, otic, and submandibular, connected with cranial nerves and described with them.

2. The great **prevertebral plexuses**, consisting of aggregations of nerves and ganglia, which are connected with the gangliated cords and cerebro-spinal nerves on both sides of the body, and meet in front of the vertebral axis. These are, the *cardiac plexus*, lying above the heart and supplying it; the *solar plexus*, situated in the abdomen behind the stomach, and supplying most of the abdominal viscera and their vessels; and the *hypogastric plexus*, which is placed between the two common iliac arteries, and supplies the pelvic viscera.

3. **Secondary plexuses.**—Many of the viscera possess minute secondary gangliated plexuses of their own, the ganglia being often microscopic in size; *e. g.*, the heart, suprarenal bodies, uterus, and intestines.

The ganglia of the sympathetic cords (vertebral ganglia) (Fig. 733) consist of nerve-cells, and medullated and non-medullated nerve-fibres. The medullated

nerve-fibres are derived probably wholly from the motor roots of spinal or cranial nerves, and form the white rami communicantes. They terminate in arborizations round the cells of the vertebral ganglia, or pass through these without interruption to enter into relationship with the cells of the prevertebral plexuses.

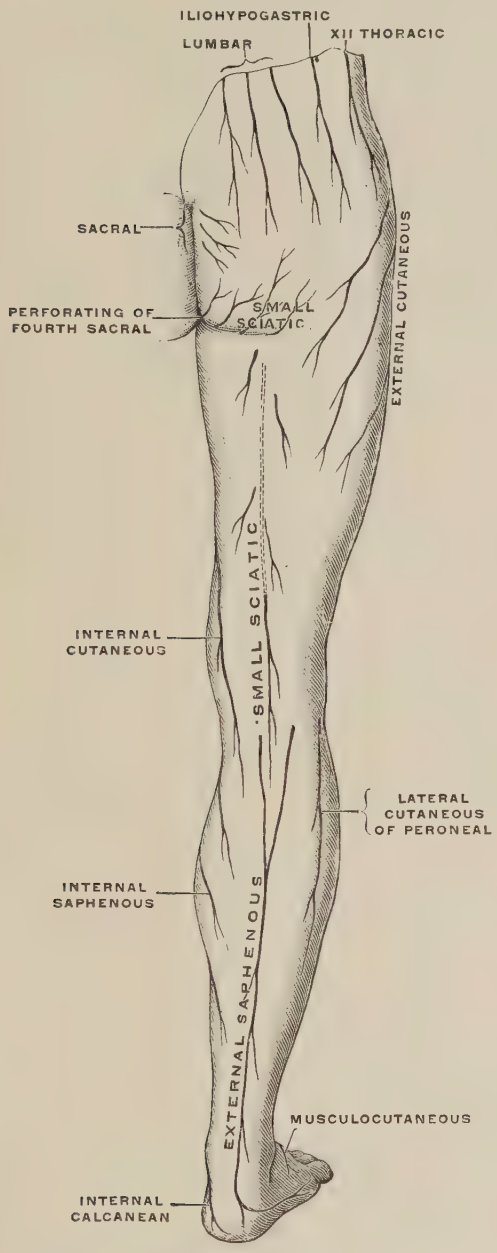

FIG. 729.—Cutaneous nerves of the back of the lower limb. (W. Keiller.)

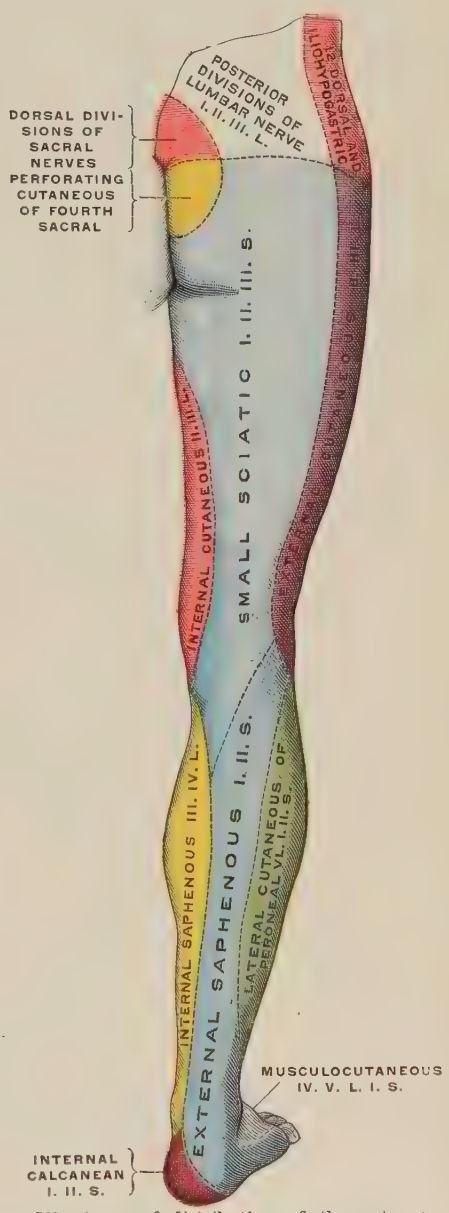

FIG. 730.—Areas of distribution of the cutaneous nerves of the back of the lower limb. (Testut.)

Medullated nerves (forming white rami communicantes) are not furnished to the sympathetic cords by all the cerebro-spinal nerves. In man white rami communicantes are derived from the thoracic and the first (and perhaps the second) lumbar nerves; while the short root of the ciliary ganglion from the third nerve, the visceral branches of the facial, glossopharyngeal, vagus, and spinal accessory, and

the visceral branches of the second, third, and fourth sacral nerves may be classed in the same category, though most of these join the subsidiary plexuses and not the gangliated cords.

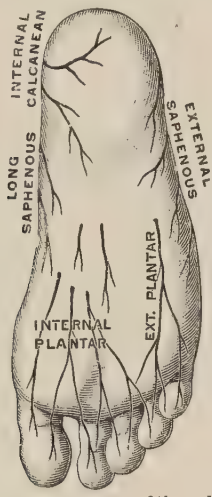

FIG. 731.—Cutaneous nerves of the sole. (W. Keiller.)

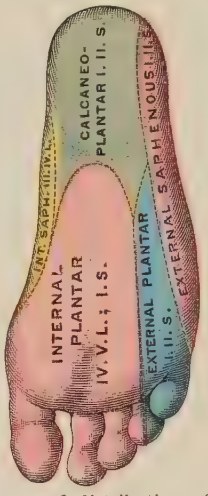

FIG. 732.—Areas of distribution of the cutaneous nerves of the sole. (W. Keiller.)

The *non-medullated nerves* commence as axis-cylinder processes of the ganglion cells. Some are distributed in gray rami communicantes to spinal nerves, and in them reach the vessels, fasciæ, bones, etc., for which they are destined;

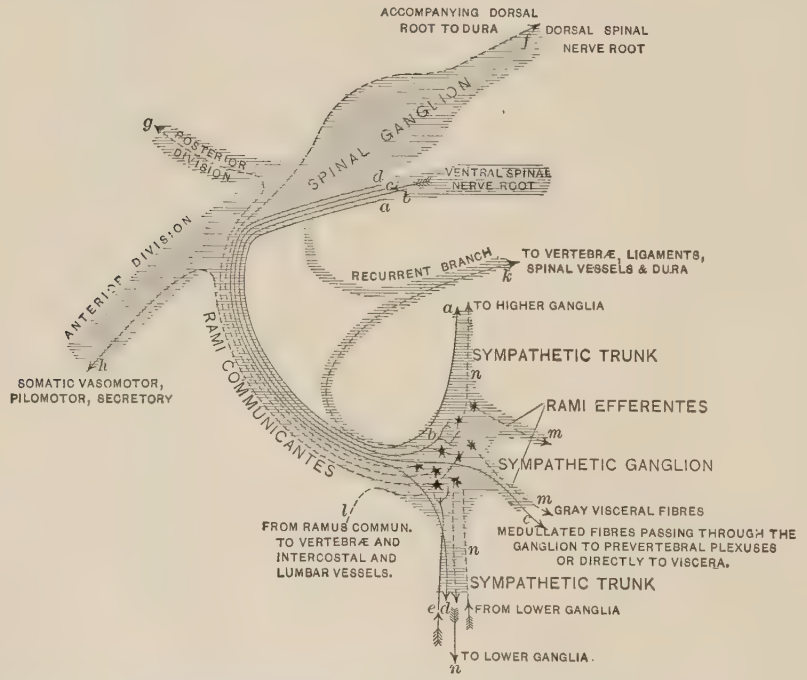

FIG. 733.—Plan of a vertebral ganglion of the sympathetic cord and its connections. Medullated fibres represented by continuous lines, non-medullated fibres by interrupted lines. For references to letters see text. (W. Keiller.)

some join neighboring ganglia, and others pass in rami efferentes directly to viscera and vessels or to the prevertebral plexuses.

These connections will be better understood by examining the plan drawn out in Fig. 733. There *a* represents a medullated nerve-fibre from a ventral nerve-root, passing by a white ramus communicans through the ganglion directly connected with that spinal nerve to a ganglion higher up, where it will form an arborization round a nerve-cell, like *e*; *b*, a medullated nerve-fibre forming an arborization round a cell of the ganglion of its own segment; *c*, a fibre passing through the ganglion without interruption and leaving it by one of its efferent branches to a prevertebral plexus or directly to some viscus; *d*, a fibre passing through the ganglion to some lower ganglion, there to end round some nerve-cell, or pass out through an efferent ramus; *e*, a medullated nerve from a lower ganglion, behaving as *a*.

The dotted lines are non-medullated nerves. The fibre, *f*, arises as the axis-cylinder process of a ganglion cell, and passes by a gray ramus communicans along the sheath of the posterior nerve-root to the spinal meninges; *g* passes by the posterior division to supply sympathetic fibres to its area of distribution; *h* enters the anterior division and is similarly distributed; *k* joins the spinal recurrent branch to supply the interior of the vertebral canal, and *l* passes for a little way along the gray ramus communicans, but leaves it to be distributed to the sides of the vertebræ and intercostal or lumbar vessels. Gray fibres to the prevertebral plexuses, vessels, or viscera, are represented by *m*, *m*; and *n*, *n* are non-medullated fibres joining neighboring ganglia. In addition to these, sensory fibres from the ganglia of the posterior spinal nerve-roots pass through the sympathetic ganglia to viscera without interruption.

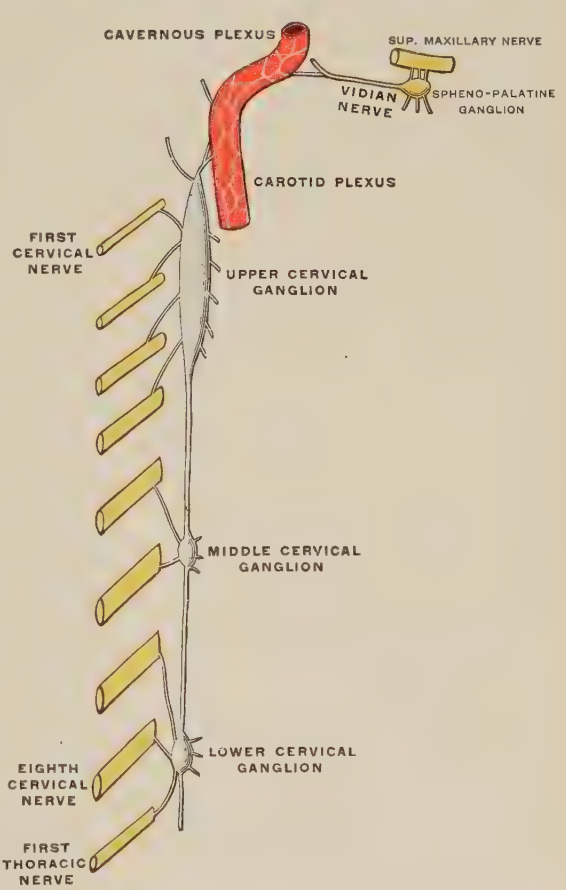

FIG. 734.—Diagram of the cervical sympathetic. (Testut.)

The Sympathetic in the Neck.

In the neck there are only three ganglia (Fig. 734). The upper one, however, is an inch or more in length, and is frequently constricted at intervals. It is connected with the four upper cervical nerves and appears to consist of four ganglia fused together.

The second ganglion is small, but is connected with two nerves; and the third ganglion, intermediate in size, is connected with the lower two cervical nerves. These ganglia and their intervening cord lie in front of the transverse processes of the cervical vertebræ, being separated from them by the rectus capitis anterior major above and longus colli below with the prevertebral fascia. The common and internal carotid arteries and the carotid sheath lie in front of them, and the vagus nerve lies to the outer side.

The Superior Cervical Ganglion.—This ganglion is fusiform in shape, reddish-

gray in color, an inch to an inch and a half long, and is placed in front of the transverse processes of the second and third cervical vertebræ, and rectus capitis anterior major. In front of it is the internal carotid artery, and to its outer side the vagus nerve.

Connections.—Its *ascending branch* enters the cranium; its lower end is connected to the second ganglion. Gray *rami communicantes* pass from it to the four upper cervical nerves, while its medullated connections with the spinal cord take a circuitous course, being derived from the upper thoracic nerves, and ascending to join it through the sympathetic trunk.

Besides connections with cranial nerves, through its ascending branch (about to be described), it is joined by filaments to the lower ganglion of the vagus and the hypoglossal nerve; and a small *jugular branch* ascends to the jugular foramen, and there divides into two, one branch going to the root ganglion of the pneumogastric, and the other to the petrosal ganglion of the glossopharyngeal.

It distributes pharyngeal branches to the pharyngeal plexus, filaments to the upper cervical vertebræ and their ligaments, and branches to blood-vessels; and from it also springs the upper cardiac nerve.

The Ascending Branch.—The *ascending* or *carotid branch* runs upward on the inner side of the carotid artery to the carotid canal where it divides into an inner and an outer division. Each division gives off some special branches, and then they both ascend on the termination of the carotid artery, supply that vessel, and terminate in plexuses on the ophthalmic and anterior and middle cerebral arteries.

The *outer division*, as it ascends on the outer side of the carotid trunk, receives one or two *carotico-tympanic* filaments from the tympanic branch of the glossopharyngeal, and then forms the *carotid plexus* on the carotid artery, as it lies in the carotid canal. This plexus gives a *twig to the sixth nerve* as the latter crosses the carotid artery, some filaments to the *Gasserian ganglion*, the *large deep petrosal nerve* to the Vidian, and the *small deep petrosal nerve* to the tympanic plexus.

The *inner division* ascends on the inner side of the carotid artery, and forms a plexus on that vessel as it lies in the wall of the cavernous sinus, which is hence called the *cavernous plexus*. From this plexus filaments are given to the *third nerve* near its bifurcation, and to the *fourth nerve* as it runs in the outer wall of the cavernous sinus. The *sympathetic root of the ciliary ganglion* and filaments to the *pituitary body* are also derived from this plexus.

The *pharyngeal branches* of the sympathetic arise from the fore part of the ganglion. They descend on the side of the pharynx and unite with the pharyngeal branches of the pneumogastric and glossopharyngeal to form the *pharyngeal plexus*.

The *superior cardiac branch* of the sympathetic springs by two or more branches from the ganglion and sometimes from the sympathetic trunk below it. It descends behind the carotid sheath on the longus colli muscle and prevertebral fascia, crosses over or beneath the inferior thyroid artery, and beneath the recurrent laryngeal nerve. As they enter the thorax the two nerves differ in their courses. The *right nerve* runs in front of or behind the subclavian artery and along the brachio-cephalic artery to the back of the aortic arch, where it joins the deep cardiac plexus. It is usually joined by the superior cardiac branches of the right vagus.

The *left superior cardiac nerve*, behaving similarly to the right nerve in the neck, enters the chest along the side of the left common carotid artery, and crosses the aortic arch to join the superficial cardiac plexus. Occasionally it passes behind the aortic arch to the deep cardiac plexus.

Besides the branch described to the internal carotid artery, this ganglion supplies filaments, which form a *plexus on the external carotid artery* and its various branches. From the plexus on the facial artery a branch is sent to the *submaxillary ganglion*; and the plexus on the middle meningeal artery supplies the otic ganglion with its sympathetic root, and sends a filament to the geniculate ganglion of the facial nerve.

The Middle Cervical Ganglion.—The middle cervical ganglion is much the smallest of the three. It is sometimes absent and occasionally double. When single it is usually situated where the cord crosses the inferior thyroid artery opposite the sixth or seventh cervical vertebra. It is joined by gray rami communicantes to the fifth and sixth cervical nerves. It gives off *thyroid branches*, which run on the inferior thyroid artery to the thyroid gland, communicating with the recurrent and external laryngeal and the upper cardiac nerves.

The *middle cardiac branch* of the sympathetic, springing from this ganglion on the *right side*, descends in front of or behind the subclavian artery and on the side of the trachea to the deep cardiac plexus, communicating with the upper cardiac nerve and recurrent laryngeal branch of the vagus.

On the *left side* this nerve descends between the left carotid and subclavian arteries to the deep cardiac plexus, uniting on its way with the left inferior cardiac nerve.

The Inferior Cervical Ganglion.—The inferior cervical ganglion is larger than the last, and irregular or semilunar in shape. It lies just over the neck of the first rib and under cover of the vertebral artery. To the middle cervical ganglion it is united by two or more cords, one usually passing behind the vertebral artery, one in front of it, and one forming a loop round the subclavian artery (ansa subclavia Vieussenii). It may blend with the first thoracic ganglion or be united to it by a short intervening cord. Gray *rami communicantes* pass from this ganglion to the seventh and eighth cervical nerves. Its *efferent* branches are the inferior cardiac nerve and offsets to blood-vessels.

The *inferior cardiac nerve*, springing from this ganglion or the first thoracic, on the right side communicates behind the subclavian artery with the middle cardiac and recurrent laryngeal nerves, on the left side usually forms a common trunk with the middle cardiac nerve. Both go to the deep cardiac plexus.

The vascular branches of this ganglion and the first thoracic unite in forming the plexus on the vertebral artery, and ascend on that vessel to the basilar artery and its branches within the cranium.

(*Note.*—The gross anatomy of the cervical sympathetic gives no idea of its true anatomical relations as revealed by physiological experiments and pathological phenomena. The physiological connections as at present understood may be summarized as follows:

1. Pupillo-dilator fibres pass by white rami communicantes from the first, second, and third thoracic nerves, ascend in the sympathetic cord to the superior cervical ganglion to form arborizations round its cells. Thence gray fibres pass to the Gasserian ganglion and reach the eyeball by the ophthalmic division of the fifth and long ciliary nerves.

2. Motor fibres to the involuntary muscles of the orbit and eyelids from the fourth and fifth thoracic nerves follow a similar course.

3. Vasomotor fibres to the head, secretory fibres to the submaxillary gland, and pilomotor fibres to the head and neck are derived from the upper thoracic nerves and reach their areas of distribution after similar interruption in the superior cervical ganglion.

4. The accelerator fibres of the heart are derived from the upper thoracic spinal nerves, and end similarly in the middle and lower cervical ganglia, gray fibres in the cervical cardiac nerves completing the connection.)

The Thoracic Portion of the Gangliated Cord.

In the thorax the sympathetic cord (Fig. 735) presents eleven, seldom twelve, ganglia, the first thoracic ganglion frequently blending with the last cervical. When existing separately the first ganglion lies beneath the head of the first rib; the rest, with the exception of the twelfth, lie on the heads of the ribs, under cover of the pleura, the intervening cord lying in front of the intercostal vessels. The twelfth thoracic ganglion approaches nearer to the middle line, lying on the

side of the twelfth thoracic vertebra, between it and the diaphragm, and from it the cord descends into the abdomen through the crus of the diaphragm to unite the last thoracic to the first lumbar ganglion.

Rami Communicantes.—Two rami communicantes, sometimes called the *external branches*, unite each ganglion to its corresponding spinal nerve. Of these one is usually white, the other gray.

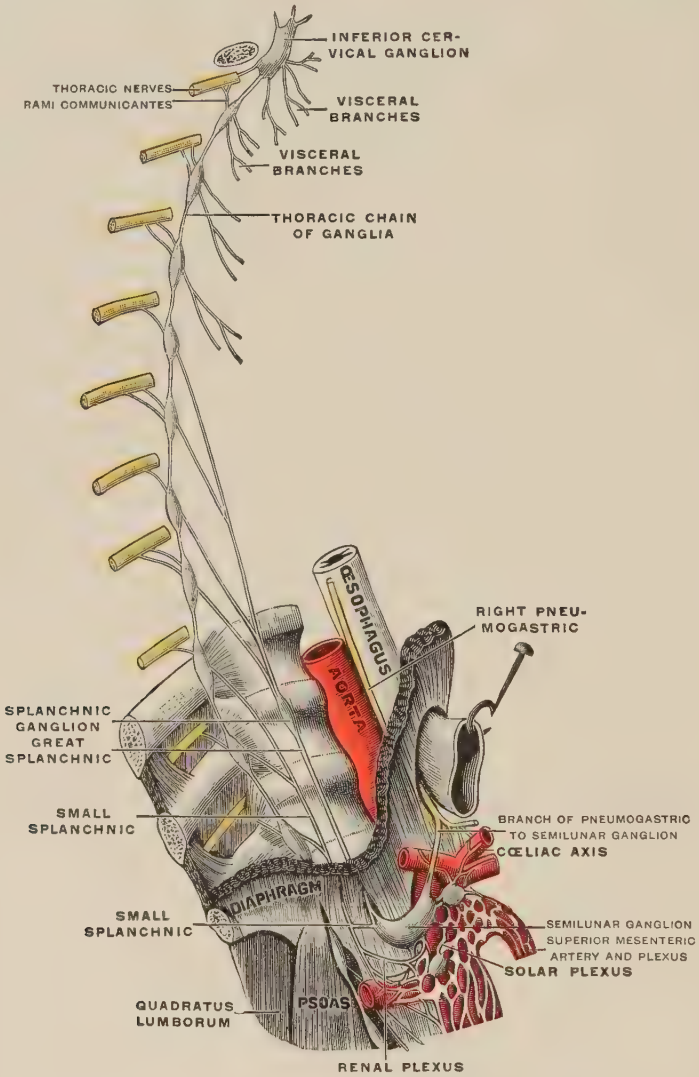

FIG. 735.—Plan of right sympathetic cord and splanchnic nerves. (Testut.)

The *rami efferentes*, called the *internal branches*, are divisible into an upper and a lower series. The *upper series* proceeds from the upper four or five ganglia to the aorta, forming with branches from the splanchnic the thoracic aortic plexus. Other slender filaments supply the vertebræ and ligaments, and the second, third, and fourth ganglia send branches to the posterior pulmonary plexus.

The *lower series* includes the internal branches of the lower six or seven ganglia. They form the great, small, and least splanchnic nerves.

The **great splanchnic (visceral) nerve** is formed by the convergence on the sides of the vertebræ of the internal branches of the fifth or sixth to the ninth or tenth ganglia inclusive. These branches and the resulting trunk distribute fila-

ments to the vertebræ and aorta as they descend, the trunks then piercing the crus of the diaphragm, and entering the upper angle of the semilunar ganglion. It occasionally sends fibres to the suprarenal body and renal plexus. This nerve largely consists of medullated fibres, some of which may be traced in the sympathetic cord till they join the third thoracic nerve.

The **small splanchnic nerve**, rising from the ninth and tenth, or ninth, tenth, and eleventh ganglia, passes beneath the crus or internal arcuate ligament of the diaphragm, to the aortico-renal ganglion, and sometimes sends fibres to the renal plexus.

The **least splanchnic nerve**, from the last thoracic ganglion, descends beneath the internal arcuate ligament to the renal plexus.

(*Note.*—It should be remembered that most of the white rami communicantes, which pass from the spinal cord to the sympathetic trunk, do so by the thoracic nerves; but that they do not by any means all end in thoracic ganglia. For example, the pupillo-motor fibres, vasomotor fibres of the head and neck, secretory fibres of the submaxillary gland and accelerator fibres of the heart leave the spinal cord by upper thoracic nerves and ascend in the sympathetic trunk to form arborizations round the cells of the cervical ganglia.

In the dog and cat the white rami communicantes from the thoracic nerves have been shown to contain, in addition to the above, vaso-constrictor fibres of the pulmonary vessels, and of the vessels of the fore and hind limbs, and secretory fibres to the sweat glands and pilo-motor fibres to the hair of both limbs, as well as viscero-inhibitory fibres to the stomach and intestines, and vasomotor nerves to the abdominal vessels.)

The Lumbar Portion of the Gangliated Cord (Fig. 736).

There are usually four lumbar ganglia, which lie in front of the vertebral bodies on the inner side of the psoas muscles, the left trunk and its ganglia being overlapped by the aorta, and the right by the inferior vena cava.

The ganglia are generally connected somewhat irregularly by white and gray rami communicantes with the lumbar nerves, which reach the ganglia by passing beneath the fibrous arches of the psoas muscle. Efferent branches join the aortic and hypogastric plexuses, and small filaments pass to vertebræ and ligaments.

(*Note.*—The lumbar sympathetic is connected with the lower limb, rectum, penis, bladder, uterus, and vas deferens, while the other abdominal viscera are connected through the solar plexus with the lower six thoracic nerves.)

From these ganglia and the intervening meshwork are given off plexuses, which correspond in name and distribution to the upper branches of the abdominal aorta. Thus the *diaphragmatic* or *phrenic plexuses* spring from the upper part of the semilunar ganglia. They accompany the phrenic arteries, and are joined by the phrenic nerves. A ganglion is formed at their junction on the right side (wanting on the left side) whence branches pass to the vena cava, suprarenal body, and hepatic plexus.

Suprarenal plexuses accompany the arteries of the same name from the phrenic artery, aorta, and renal artery. They are thus derived from the phrenic, solar and renal plexuses. They contain many minute ganglia.

The *renal plexus* springs from the aortico-renal ganglion, and solar and aortic plexuses, and receives the small and least splanchnic nerves. It accompanies the renal artery to the kidney substance, and gives branches to the suprarenal body, spermatic plexus and ureter, and on the right side the vena cava.

The *spermatic plexus* springs from the renal and aortic plexuses and accompanies the spermatic artery to the testis, receiving an accession from the pelvic sympathetic along the vas deferens.

In the female it is represented by the *ovarian plexus* to the ovary and uterus.

The *cœliac plexus* is large in accordance with the size and extensive distribution of the cœliac axis. It gives off secondary plexuses corresponding in names

and distribution to the branches of that vessel. Of these plexuses the hepatic and coronary are joined by branches of the left pneumogastric, and the splenic plexus is reinforced from the right pneumogastric.

The *superior mesenteric plexus* is derived from the solar plexus, superior mesenteric ganglion, and right pneumogastric. It is distributed to the intestine, at first following the branches of its artery closely; but its finer filaments leave the vessels.

The *aortic plexus* is formed of two cords and an intervening network, which descend on the abdominal aorta beneath the superior mesenteric artery. It is

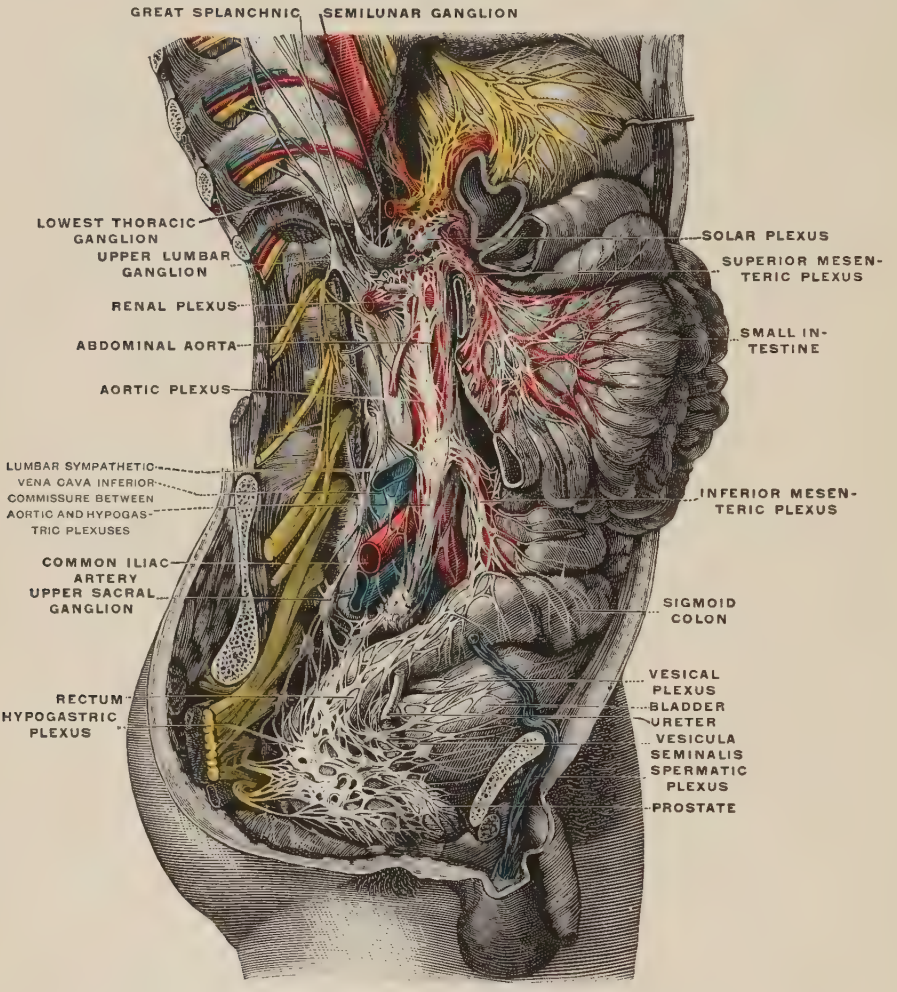

FIG. 736.—Lower half of right sympathetic cord. (Testut, after Hirschfeld.)

joined by branches from the lumbar ganglia, gives off the inferior mesenteric plexus and branches to the spermatic plexus and inferior vena cava, and ends below in the hypogastric plexus.

The *inferior mesenteric plexus* is derived from the aortic. It corresponds in distribution and communications with the artery of the same name.

The Sacral Portion of the Gangliated Cord.

In the pelvis the sympathetic trunks, much diminished in size, descend on the inner sides of the anterior sacral foramina, a ganglion usually appearing for

each of the four upper sacral nerves. In front of the coccyx the two cords unite in one ganglion, called the *ganglion impar*, which is usually connected with both coccygeal nerves.

Short rami communicantes connect each of these ganglia with one or more of the sacral nerves, and rami efferentes join the pelvic plexus, while others form a plexus on the middle sacral artery or pass to the sacrum and coccyx and their ligaments. Through the pelvic plexus the pelvic viscera are supplied with motor, vasomotor, and secretory fibres.

The Prevertebral Plexuses of the Sympathetic.—These plexuses are named respectively the cardiac, solar, hypogastric, and pelvic. Each plexus is single and median, and is composed of nerves derived from both sympathetic trunks, with others derived from the cerebro-spinal nerves. Ganglia are developed in their meshes and from them subsidiary plexuses are formed.

The Cardiac Plexus.—Beneath and behind the aortic arch is a meshwork of nerve-fibres, which for convenience of description is divided into a superficial and a deep portion, though the two form one continuous plexus. The nerves entering into this plexus are the superior and inferior cervical cardiac branches of the vagi, the thoracic cardiac branches of the same nerves, and the superior, middle, and inferior cardiac branches of the sympathetic.

Of these nerves the superior cardiac branch of the left sympathetic trunk, and the lower cervical cardiac branch of the left pneumogastric form, in the concavity of the aortic arch, the *superficial cardiac plexus*. In its meshes is a small ganglion, the *ganglion of Wrisberg*. It sends branches to the right coronary plexus and left anterior pulmonary plexus, the latter accompanying the left branch of the pulmonary artery.

All the other cardiac nerves above mentioned join in forming the *deep cardiac plexus* which lies in the bifurcation of the trachea behind the aortic arch. From it branches are distributed to both auricles, both coronary plexuses, and both pulmonary plexuses.

Of the *coronary plexuses* the right is the smaller. It is derived from both cardiac plexuses, its branches surrounding the root of the aorta. It descends on the right coronary artery, sending filaments to ramify between the pericardium and muscular wall of the heart, the ultimate fibres entering the muscle substance.

The left coronary plexus is derived from the deep cardiac plexus. It passes between the pulmonary artery and left auricular appendix, and accompanies the left coronary artery.

The Solar or Epigastric Plexus.—Lying in front of the crura of the diaphragm and at the sides of the aorta, just after that vessel appears in the abdomen, are two large ganglionic masses united to each other by a coarse network of nerve fibres, which surrounds the origins of the cœliac axis and superior mesenteric arteries. This is the *solar* or *epigastric plexus*. It lies behind the stomach, above the pancreas, and between the suprarenal bodies.

Each ganglionic mass presents one large irregular body at its upper part, called the *semilunar ganglion*, which receives the great splanchnic nerve at its upper angle.

Continuous with the semilunar ganglion, but marked off from it by a constriction, is a smaller body, the *aortico-renal ganglion*, which receives the small splanchnic, and gives off the greater part of the renal plexus; while a still smaller body, lying to the right of the superior mesenteric artery, forms the *superior mesenteric ganglion*.

Through this plexus the abdominal viscera above the pelvis are connected with the lower six thoracic ganglia and thoracic spinal nerves, and it is significant that these last supply the abdominal wall.

The Hypogastric Plexus.—Branches from the aortic plexus descend on the aortic bifurcation to the front of the fifth lumbar vertebra, where they are joined by strong fibres from the lower lumbar sympathetic ganglia, which cross over the common iliac arteries. These form together in front of the fifth lumbar vertebra

a coarse meshwork invested in dense fibrous tissue, called the hypogastric plexus. It contains no ganglia. In front of the sacrum it splits into two lateral portions, which join the pelvic plexuses.

The Pelvic Plexus.—Lying on each side of the rectum and bladder in the male, and of the rectum, vagina, and bladder in the female, is a network, rich in ganglia where the fibres interlace, formed by the continuation of the hypogastric plexus, offsets from the upper sacral ganglia, and branches from the second, third, and fourth sacral nerves. This is the *inferior hypogastric* or *pelvic plexus.* From this branches are distributed to the pelvic viscera, which at first follow the branches of the internal iliac artery, their terminal twigs leaving the vessels and entering the substance of the organs. Thus the following secondary plexuses are formed, viz :

The *hemorrhoidal plexus,* derived from the upper part of the pelvic plexus, accompanies the middle hemorrhoidal artery and joins with the plexus on the superior hemorrhoidal vessels in supplying the rectal wall.

The *vesical plexus* is a close network, rich in spinal fibres, which is best marked over the sides and base of the bladder. It gives off plexuses to the vasa deferentia and vesiculæ seminales, of which the former join the spermatic plexuses and the latter receive communications from the prostatic plexus.

The *prostatic plexus,* lying between the prostate and levator ani, sends fibres backward to join the plexuses on the vesiculæ seminales and forward through the triangular ligament to the corpus cavernosum.

The *vaginal plexus* is largely composed of spinal nerves. It supplies the mucous membrane and erectile tissues of the vagina, and sends twigs to the clitoris.

The *uterine plexus* is mainly derived from the pelvic continuation of the hypogastric plexus and third and fourth sacral nerves. It enters the broad ligament, communicates there with the ovarian plexus, and is mainly distributed over the neck and lower part of the body of the uterus. It contains numerous ganglia. The apparent hypertrophy of these nerves in pregnancy is due to thickening of their fibrous sheaths.

THE ORGANS OF THE SPECIAL SENSES.

THE five senses of touch, taste, smell, hearing, and sight have as their special organs the skin, the tongue, the nose, the ear, and the eye respectively. Of the five the commonest, the least specialized sense is that of touch, and its organ is of the greatest extent and the smallest differentiation. The other senses display progressively increasing delicacy in the order as named above: touch is excited only by the impact of some body; taste requires the contact of the solution of a sapid substance; smell is produced by the impression of volatilized materials; hearing results from the agitation of the endolymph (a fluid contained in the ear), whose wavelets beat upon the auditory surface; and sight is called into being only by the undulations of the ether which is believed to pervade all space. The organs of the senses above the tactile are either localized, inward extensions of the integument or inversions of it, which have become completely isolated. In every case there is a modification of the epithelium of the area concerned, amounting to a specialization. These epithelial cells have already been mentioned, as forming the variety called *neuro-epithelium* for the reason that they are so peculiarly related to specialized portions of the nervous system. From all of these facts it will be seen that tactile sensibility is the humble progenitor of every other sense, and that, unlikely as it seems to one who does not consider everything which is involved, sight is but touch glorified.

THE SKIN.

By W. KEILLER.

AS one of the main functions of the skin is *the sense of touch*, it may be conveniently described among the sensory organs; though, in addition to serving this function, it is protective, and excretory, and an important regulator of the body temperature.

It consists (Fig. 737) of a deep layer, called the *true skin* or *corium*, which contains nerve endings, vessels, sweat glands, hairs, and sebaceous glands, embedded in a fibrous matrix; and a superficial, epithelial layer, the *epidermis or cuticle*, which covers and protects the whole, and furnishes the epithelial elements of the glands and hairs just mentioned.

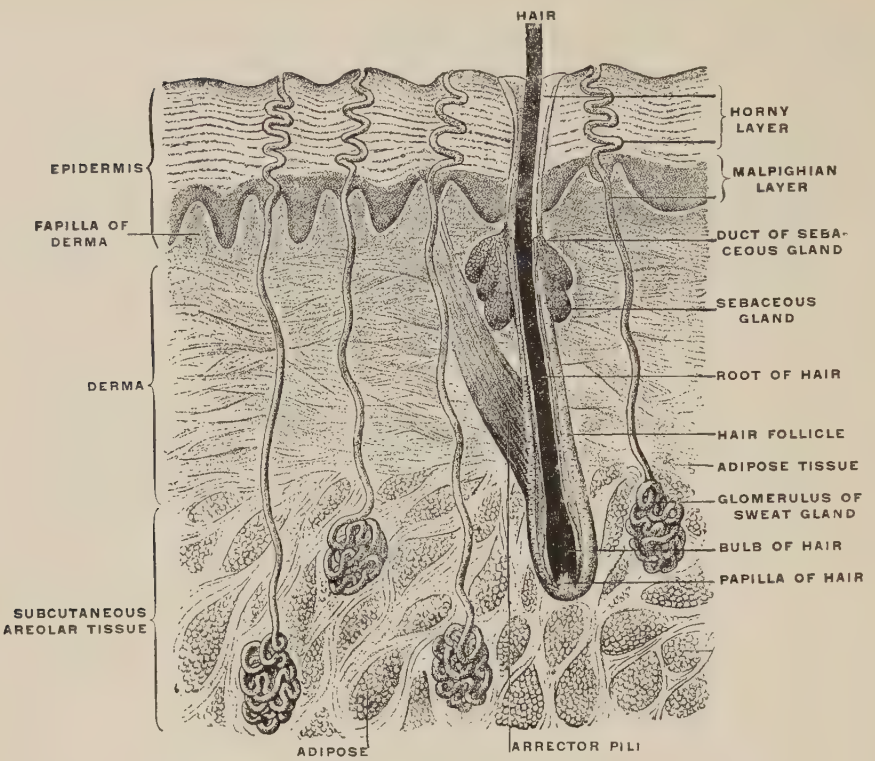

FIG. 737.—Vertical section of the skin. (Testut.)

Examined on the surface the skin varies much in texture, being rough and thick on the palms of the hands and soles of the feet, even of the newborn child; of medium thickness on the scalp and dorsal surface of the trunk, and thinnest on the ventral surface of the trunk and inner surfaces of the limbs. It is marked throughout by furrows which differ in character. Over most of the body the furrows are like those on the back of the hand, shallow and intersecting each other so as to enclose angular areas, the hairs usually springing from intersecting points. On the palm and sole the furrows run in parallel lines, forming definite patterns (Fig. 738), which, while they correspond in the main, are peculiar to each individual, and never change throughout life in spite of the passage of the soft palm of babyhood into the horny hand of age and toil. Hence the value of the hand impression in wax as a means of identification. These ridges and grooves are formed in the true skin on which the cuticle is accurately moulded. Deep and long grooves subtend the joints. The true skin blends with the loose subcutaneous tissue, and by its agency is made freely movable on the deep fascia. On the palms, soles, scalp, and pinna, however, the skin is closely bound to the deeper aponeurotic structures. The hairs and nails are modified epidermis, the sweat and sebaceous glands epithelial invaginations.

FIG. 738.—Arrangement of the papillary folds on the palmar surface of the distal segment of the thumb. (Testut.)

The **Epidermis** (cuticle, scarfskin) is formed of stratified epithelium in many layers. It varies from $\frac{1}{240}$ to $\frac{1}{24}$ of an inch in thickness, being thickest on the palms and soles. It is roughly divisible into two strata, the *Malpighian layer*

(which includes the four deep layers to be described) and a superficial, *horny layer*. Next to the true skin is a single layer of *columnar cells*, the parent cells of the rest; then come *polyhedral cells* to a considerable depth, each communicating with its neighbors by strands of protoplasm, giving them a prickly appearance (hence the term "prickle cells"). This stratum is covered by two thin strata, which exhibit changes antecedent to their assuming the characters of the horny layer, namely the *stratum granulosum* and the *stratum lucidum*. Their peculiar appearance is due to a progressive accumulation in droplets of a substance called eleidin. Superimposed on these is the horny layer (*stratum corneum*), the cells of which become gradually more flattened toward the surface, lose their nuclei, and have their substance converted into keratin. During life the superficial cells of this layer are being constantly shed and renewed from those beneath. The pigment in the skin of the negro, as well as that of the nipple and elsewhere in white races, is found in the deepest cells of the Malpighian layer.

The **True Skin** (*cutis vera*, *derma*, *corium*) consists of a fibrous matrix with vessels, lymphatics, and nerves embedded therein. It blends gradually with the superficial fascia, in which, with the exception of that on the penis, scrotum, labia minora, and eyelids, clusters of fat cells are accumulated. This loose areolar subcutaneous layer enables the skin to move freely on the deep fascia. The true skin is formed of interlacing bundles of white fibrous tissue with numerous elastic fibres and connective-tissue corpuscles. In connection with the hairs, and in the cutis vera of the scrotum, penis, perineum, areola of the nipple, and the nipple itself, smooth muscular fibres are found in fasciculi. The free surface of the corium is raised to form the ridges already described as seen on the surface of the skin, and on their summits simple and compound *papillæ* are developed, which are received into pits on the deep surface of the cuticle (Fig. 739). These papillæ are most numerous where sensation is most acute, as on the

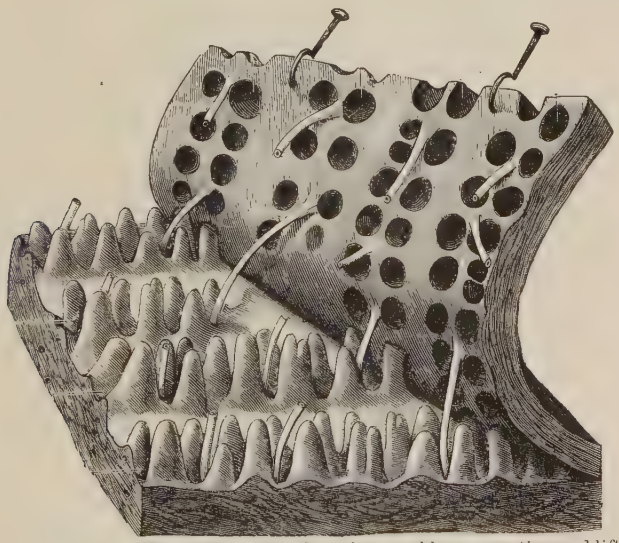

FIG. 739.—Papillæ of the skin. The epidermis has been loosened by maceration and lifted off, and its under surface shows the pits into which the papillæ fitted. Sweat-glands are stretched or broken across. (Testut.)

pulp of the fingers. On the palm, sole, and nipple they are numerous and measure from $\frac{1}{200}$ to $\frac{1}{100}$ inch in height. They are few and small on the face, and in some parts are altogether absent. Some of these papillæ have vascular loops prolonged into them, some have touch-corpuscles (Fig. 740).

The *bloodvessels* of the skin are found in the cutis vera only. They form a capillary network from which branches pass to the hairs, glands, and fat, and capillary loops project into the papillæ. The *lymphatics* form a deep and super-

ficial network accompanying the vessels. As in other tissues they originate in the intercellular spaces.

The **cutaneous nerves** form a subepithelial plexus, from which twigs are given

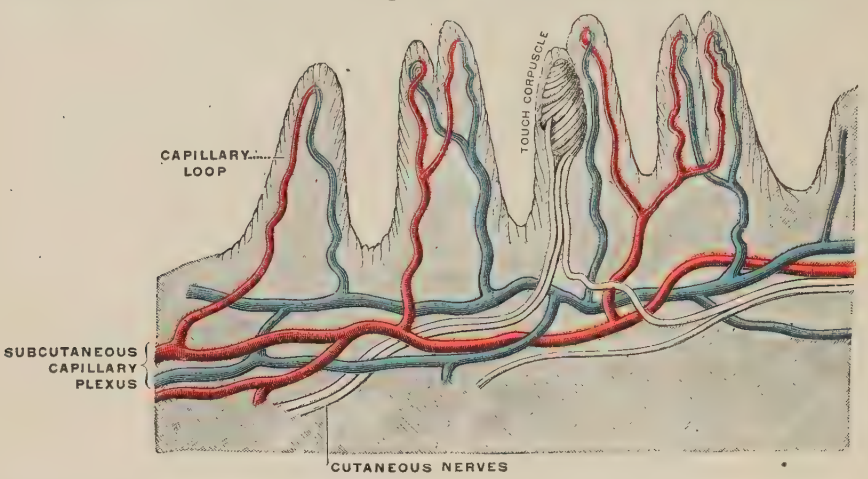

FIG. 740.—Papillæ of the skin, showing the arrangement of the vessels and nerves. (Testut.)

off to end in special terminal bodies of varied character, or, again, each fibre may divide and redivide dichotomously, soon losing its medullary sheath, the axis cylinder ultimately breaking up into its constituent fibrils, which end in minute

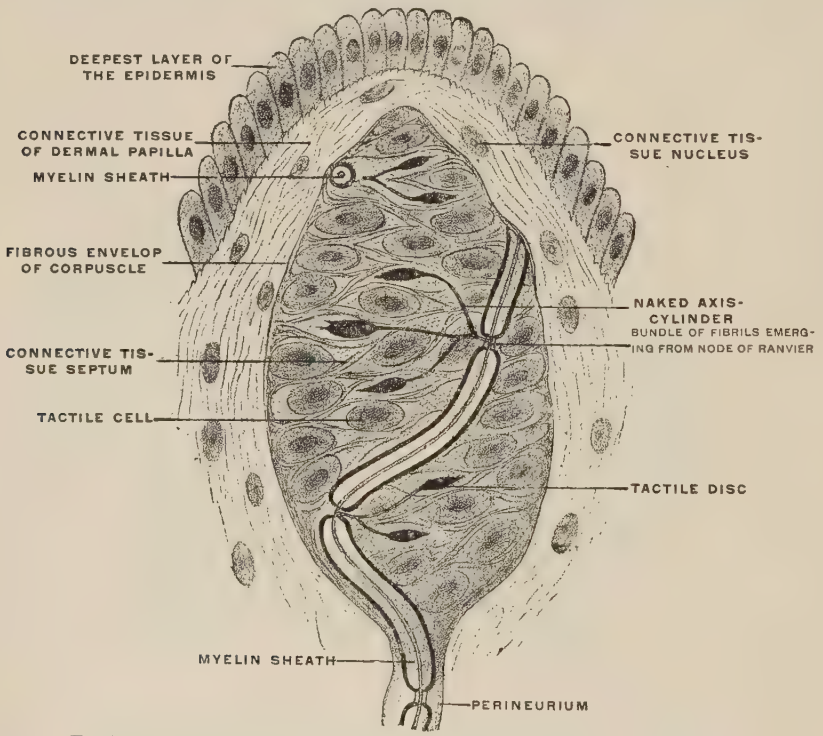

FIG. 741.—Touch-corpuscle in vertical section. Semidiagrammatic. (Testut.)

knob-like processes among the cells of the Malpighian layer. The forms of end organs are very numerous, but we will describe only those known as touch-corpuscles, end bulbs, and Pacinian bodies.

Touch-corpuscles (Fig. 741) are found in the dermal papillæ of the palm and sole, nipple, conjunctiva, lips, and tip of the tongue. They are ovoid bodies with

a fibrous capsule sending septa into the interior. One or more medullated fibres either at once enter the corpuscle, or first wind round it several times. On entering, the nerve loses its medullary sheath, and its axis cylinder breaks up into fibrils, which ramify minutely through the corpuscle, oval swellings forming on the branches.

End bulbs of spheroidal form are found in the papillæ of the skin of the lips, of the glans penis and glans clitoridis, in the conjunctiva, in the mucous membrane of the cheeks, soft palate, tongue, epiglottis, and rectum. Similar organs are found in the sheaths of nerve trunks. These bodies consist of a connective-tissue capsule containing nucleated cells, among which the axis cylinder of the nerve terminates.

Pacinian Corpuscles (Fig. 742) are small, seed-like bodies, $\frac{1}{15}$ to $\frac{1}{10}$ of an inch long, and $\frac{1}{26}$ to $\frac{1}{20}$ of an inch thick, found in clusters on the digital nerves of the hand and foot, and in many other situations. A Pacinian corpuscle is lamellated like an onion, having in some cases 40 to 60 coats, the inner laminæ thinner and more closely packed than the outer. The lamellæ are fibrous in character,

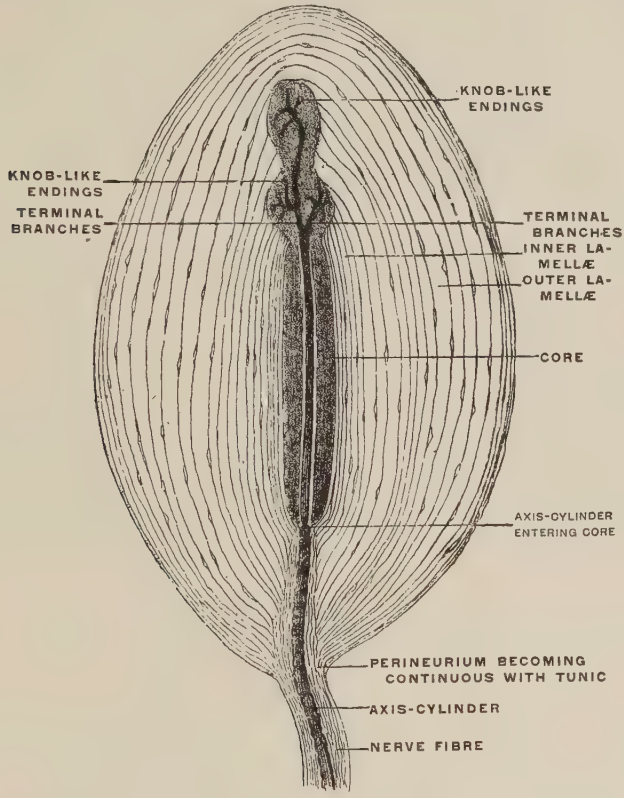

FIG. 742.—Pacinian corpuscle in vertical section. (Testut.)

continuous with the layers of the perineurium, and have lymph-spaces between them. In the centre of the body is an elongated, homogeneous core, into which the nerve penetrates. It courses along the middle of the core till it approaches the opposite end of the corpuscle, and then divides into processes, which end in bulbous extremities. Each corpuscle is supplied with a small capillary vessel, and has a distinct fibrous capsule.

NAILS AND HAIRS.

The nails and hairs are formed of modified epithelium on a special dermal substratum.

Nails.

Each nail (Figs. 743–745) consists of a *body*, which is translucent, showing readily the red glow of the underlying capillary vessels, except at its proximal extremity, where it is more opaque over a crescentic area called the *lunula*. The opacity and consequent whitish color are due to the greater thickness of the Malpighian layer in this situation. The *free edge* of the nail overhangs the tip of the digit; its *root* is embedded proximally in a deep groove in the skin, from which an epidermal *mantle* projects over the lunula. Its lateral *borders* are sunk in furrows, which have an overhanging *nail-wall* of upfolded skin. From free edge to lunula the nail is closely adherent to an epidermal *nail-bed*, but from the lunula to the proximal margin of the root this bed is called the *matrix*, because it is here only that the growth of nail takes place. The *nail-substance* consists of flattened, closely-packed cells, which, on addition of an alkali, swell up and are seen to retain their nuclei; hence they represent a condensed stratum lucidum. The nail-bed is essentially the Malpighian layer, its cells being more heaped up over the matrix, as already stated. The dermal constituent of the matrix is exceedingly vascular, and studded with large vascular papillæ, while the derma under the nail-bed is raised into parallel longitudinal ridges.

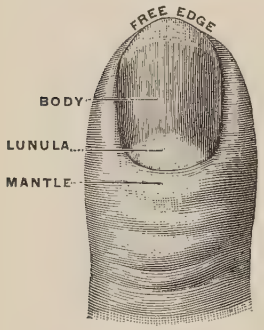

FIG. 743.— Thumb-nail. (Testut.)

Hairs.

With a few exceptional areas the whole skin is studded with hairs (Figs. 746, 747), varying in texture from the fine down (*lanugo*), scarcely projecting beyond

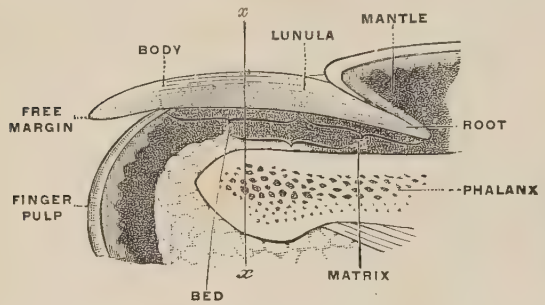

FIG. 744.—Nail in longitudinal section. The line *xx* indicates the plane of the section shown in the following figure. (Testut.)

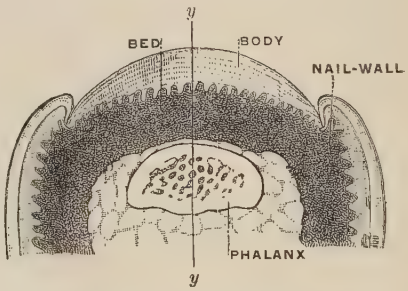

FIG. 745.—Nail in transverse section. The line *yy* indicates the plane of the section shown in the preceding figure. (Testut.)

the hair follicles, found on the eyelids and inner surface of the labia majora, to the long hairs of the scalp, and short, crisp, thick hairs of the beard and pubes. The skin of the palms and soles, the dorsal surfaces of the third phalanges of the fingers and toes, the inner surface of the prepuce in the male, the labia minora in the female, the glans penis and glans clitoridis are devoid of hairs. In straight-haired races the hairs are thick, coarse, and cylindrical; in crisp-haired races, thin and flattened, being oval on section. Dark hairs are coarser than those of lighter color.

The portion of a hair projecting beyond the surface is its *shaft* or *stem*, that embedded in the skin is its *root*. The root ends in a *bulbous enlargement*, which is implanted on a dermal *papilla*. It is contained in an invaginated tube of skin, called a *follicle*, which furnishes it with an outer *dermic* and an inner *epidermic coat*. The roots of many of the strong hairs extend down into the subcutaneous areolar tissue, the portion below the true skin being ensheathed in a prolongation of the follicle.

A hair has on its surface a single layer of thin, imbricated, scale-like cells,

their free margins pointing outward. These form the hair *cuticle*. Next comes the *cortical substance*, some hairs having in addition a medulla or pith. The cortical substance consists of closely set elongated cells, which still retain a trace of a nucleus. The cells and intercellular spaces contain pigment, varying in amount with the color of the hair. Between the cells are air-spaces, the air being most abundant in white hair. In the thick, short hairs of the pubes, the hair of the beard, and in white hair in the scalp there is a central *pith*. It is composed of irregular, polyhedral cells, containing many air-spaces. The pith does not extend to the point of the hair, is not present in children under five years of age, and is not found in the colored hairs of the scalp, or in fine hairs.

Toward the bulb the cells which form the hair become polyhedral, and resemble the cells of the Malpighian layer. The bulb expands to enclose a vascular papilla of cutis vera.

The **hair follicle** (Fig. 747) has dermic and epidermic constituents. The dermic coat consists of three layers. The outer layer is formed of longitudinally

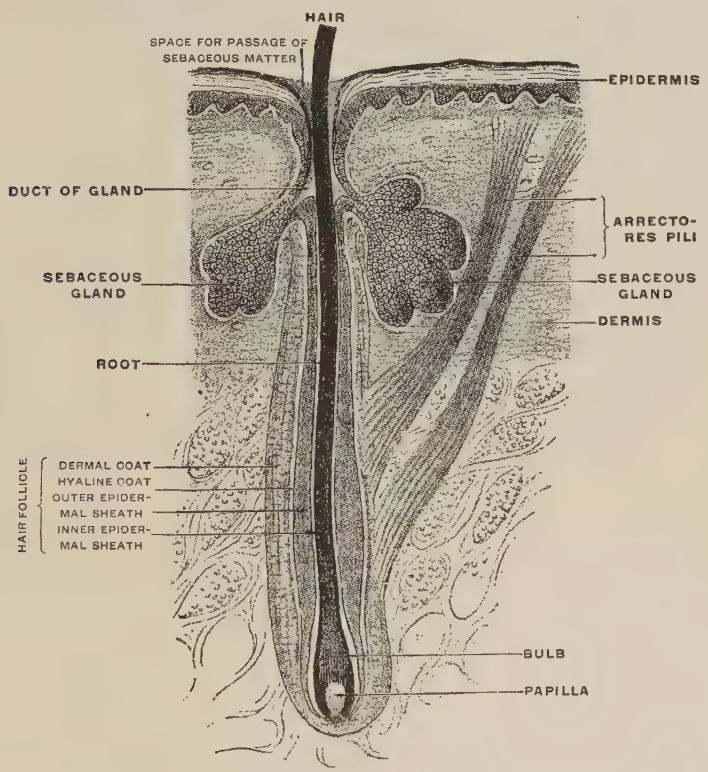

FIG. 746.—Vertical section of the skin, showing a hair and its follicle. (Testut.)

arranged white fibres with connective-tissue corpuscles, and numerous vessels and nerves. It is continuous with the reticular layer of the corium. Within this is a layer of circular fibres, which appears to represent the papillary layer of the corium, and within these is a structureless lamina (the hyaline layer), representing the basement membrane of fœtal skin. These two inner layers extend out from the bottom of the follicle to the openings of the sebaceous glands. The *epidermic coat* is divisible into two parts, the *outer root-sheath*, which is simply the Malpighian stratum of the epidermis, and the *inner root-sheath*, which may be taken as representing the stratum lucidum, and presents three characteristic layers. On the outside, and next to the outer root-sheath is *Henle's layer*, a single layer of non-nucleated, flattened cells; then comes *Huxley's layer*, consisting of polyhedral cells, two or three deep; and lastly the *cuticle of the root-sheath*, a

single layer of flattened cells, imbricated on each other, so as to fit into the depression on the hair cuticle, their free edge thus being directed downward. All the layers of the root-sheath blend at the bottom of the follicle, and become continuous with the cells of the hair bulb. The inner root-sheath ceases where the sebaceous gland enters the hair follicle. Lastly the stratum corneum dips a little way into the mouth of the follicle.

The **hair-papilla** is a fungiform process, consisting of connective tissue with

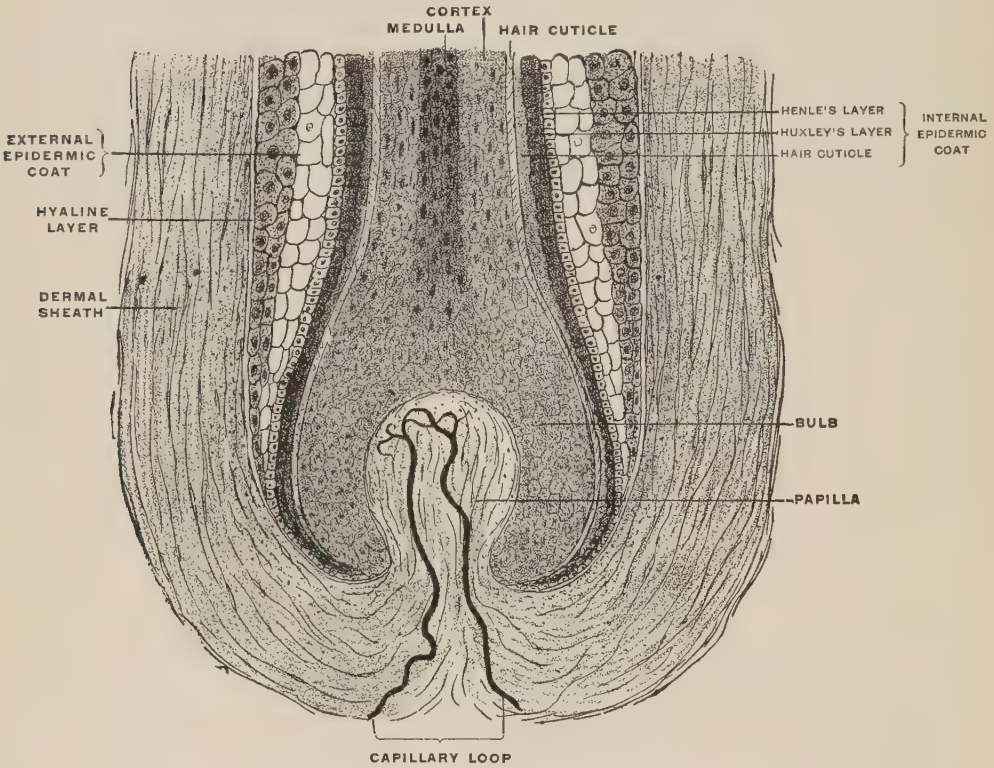

FIG. 747.—Vertical section of the root of a hair. (Testut.)

pigment cells and blood-vessels, which projects into a cup-shaped cavity in the bulb.

Muscles of the Hairs.—Slender bundles of unstriped muscle, the *arrectores pilorum* ("erectors of the hairs"), arise from the superficial layers of the corium and run obliquely inward to be attached to the fibrous coat of the hair follicles on the side toward which the hairs lie. They cause the hairs to stand erect.

Nerves are supplied to the fibrous coat and outer root-sheath, and perhaps to the papilla. They form a delicate plexus round the root-sheath. The nerves to the arrectores are called *pilomotor* ("hair-moving").

The Sebaceous Glands.

The sebaceous ("fat") glands (Fig. 746) usually open into the hair follicles, and are found wherever hairs are. But in addition they occur on the labia minora, prepuce, glans penis and glans clitoridis, the red edge of the lips, and, in a modified form, as Meibomian glands, in the eyelids. They are small on the head, large on the nose and most of the face, mons Veneris, labia majora, and scrotum. They are seldom simple, usually compound, saccular glands with short ducts, and lie between the hairs and their arrector muscles; thus the contraction of the arrectors promotes the expulsion of their oily secretion. The number of acini in a single gland varies from four or five to twenty.

The Sweat-Glands.

Except in the depths of the external auditory meatus and on the tympanic membrane, sweat-glands (Fig. 737) are found over the whole integument. They are most numerous on the palms of the hands and soles of the feet, 2800 to the square inch; on the back of the neck and trunk there are only 400 to 600 in the same area. They vary much in size, being largest in the axilla and groin. Krause estimates their total number as about two millions.

A *sweat-gland* is an invaginated, epithelial tube, which sinks through the corium into the subcutaneous fatty tissue, and there coils up into a ball. Thus it is a simple tubular gland, the coiled-up extremity being the secreting portion, the straight tube its excretory duct. In the epidermis the *duct* is a simple channel with no definite walls, and where the horny layer is thick it twists in cork-screw fashion. As it passes through the corium, the duct derives from it a richly vascular fibrous coat, within which is a basement membrane. The duct, much smaller than the coiled, secreting portion of the tube, is lined by small polyhedral cells, two deep, whose free surface is condensed into an appearance suggesting a delicate cuticle. In the *secreting segment* a layer of smooth muscular fibres, longitudinally arranged, is placed next the basement membrane, and on this a single layer of columnar cells with nuclei near their attached extremities. The ceruminous glands of the ear and the glands of Moll in the eyelid are modified sweat-glands. The sweat-glands in the axilla and round the anus and, of course, the ceruminous glands have an oily secretion; the rest secrete a colorless, slightly turbid, aqueous fluid, the perspiration.

THE TONGUE.

By F. H. GERRISH.

THE tongue has various functions. It is necessary for articulate speech, performs valuable service in the processes of mastication and deglutition, possesses tactile sensibility to a high degree, and is the principal organ of taste. It is only in its sensory relations that it will be considered in this place. Its other features will be described in connection with the other parts of the mouth and pharynx.

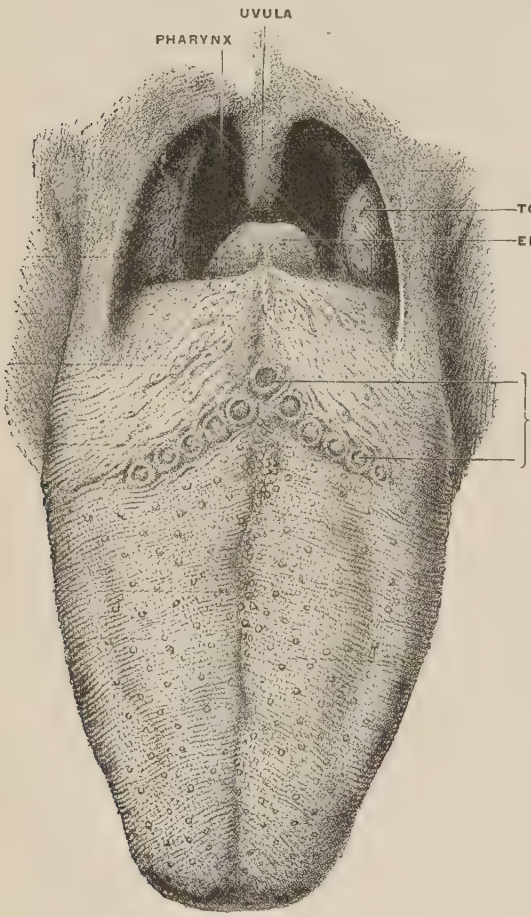

FIG. 748.—Dorsal surface of the tongue. (Testut.)

The *mucosa of the dorsum* (Fig. 748) is the only part of the tongue having gustatory capacity. The anterior two-thirds of this surface presents in the mouth, the posterior third in the pharynx, the boundary between the two being marked by a line of large projections, the *circumvallate papillæ*, arranged like an inverted V, with widely spread branches.

The *oral part* of the dorsum is besprinkled with smaller processes, the *fungiform papillæ*, and elsewhere this surface is completely covered with closely set ranks of a third variety, the *filiform papillæ* marshalled for the most part, especially behind, in lines nearly parallel on each side with the circumvallate.

The *pharyngeal part* of the dorsum is occupied by mucous glands, and small lymphoid masses, structurally similar to the tonsils, and arranged in lines parallel with the circumvallate papillæ.

The **Circumvallate** ("walled-around") **Papillæ** (Fig. 749) vary in number from seven to twelve. The base of each is broad, its summit wider still. Its core is a prolongation of the corium of the mucous membrane, and many *secondary*

papillæ project from its top. A thick, stratified epithelium, similar to that of the skin, covers the papilla completely, the superficial layers giving no evidence of the existence of papillæ beneath. Around the main papilla at a little distance is a circular rampart, whose top is as high as that of the papilla, and its structure identical with that of the latter. Occupying the entire thickness of the epithelium of the lateral surface of the papilla is a multitude of flask-shaped bodies, called *taste-buds* (Fig. 750). They are composed of two kinds of epithelial cells, gustatory and sustentacular, packed together closely.

FIG. 749.—Circumvallate papilla in vertical section, showing arrangement of the taste-buds and nerves. (Testut.)

A *gustatory cell* is slender, except at its centre, which is bulged in every direction by a large nucleus. Its proximal end is often branched, and extends to the corium; its distal extremity is surmounted by a stiff cilium, which reaches almost to the surface. The *sustentacular cells* are fusiform, and are mostly situated in the peripheral parts of the taste-bud, though some of them are mingled with the gustatory. They furnish mechanical support to the other cells, and form a firm casing to the bud. The stratified, flattened epithelium, which clothes the papilla, presents a perforation, called a *gustatory pore*, at the spot where the distal extremity of the taste-bud approaches the surface, and thus the hairs of the gustatory cells can be affected by the direct contact of sapid solutions.

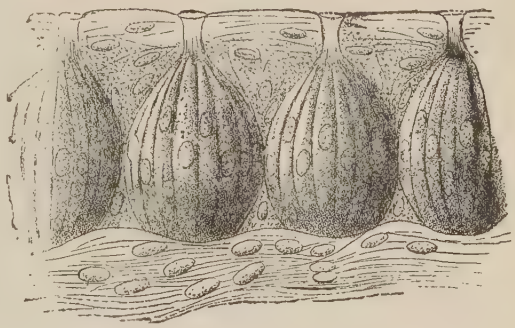

FIG. 750.—Taste-buds. (After Engleman.)

Taste-buds are found, also, in the wall surrounding the papilla, presenting their open ends toward the intervening ditch, as do those of the papilla itself.

The **Fungiform** ("mushroom-shaped") **Papillæ** (Fig. 751) are pediculated knobs, upon the rounded upper surface of which are many *secondary papillæ*. In the fungiform are found many taste-buds.

The **Filiform** ("thread-shaped") **Papillæ** (Fig. 751) are small, somewhat cylindrical, and bear *secondary papillæ*, upon which the epithelium is particularly dense, and drawn out into long, tapering threads.

To all of the varieties of papillæ *nerves* are supplied, entering through their bases, and sending filaments between the epithelial cells, but not establishing absolute continuity with them. The glossopharyngeal furnishes the hind third of the mucosa of the dorsum of the tongue and the sides of its posterior half, the lingual the remainder.

Taste-buds are scattered over the dorsal surface independently of papillæ, and are especially numerous in the posterior part.



FIG. 751.—Semidiagrammatic view of a portion of the mucous membrane of the tongue. Two fungiform papillæ are shown. On some of the filiform papillæ the epithelial prolongations stand erect, in one they are spread out, and in three they are folded in. (Testut.)

Other Organs of Taste.

Although the tongue is the principal organ of the sense of taste, it has not a monopoly of this peculiar endowment. Taste-buds are found in the mucosa of the back part of the hard palate, on the anterior surface of the soft palate, and to some extent in other parts of the pharynx.

THE NOSE.

By W. KEILLER.

THE *nose* is the organ of *the sense of smell.* It forms on the face a prominence partly bony, partly cartilaginous. Its *root* springs from the *naso-frontal groove,* except in the Grecian type, where the dorsum of the nose is in a straight line with the forehead. The mesial ridge is called the *dorsum,* of which the upper bony segment forms the *bridge.* It ends below in the *tip,* which is continuous with the horizontal free edge of the septum, called the *columna nasi.* The sides of the nose form an angle with the face, which increases as it descends (the *naso-facial angle*). The rounded, lateral boundary of the nostril is called the *ala.*

The **Nasal Cavity** consists of two *fossæ,* separated from each other by a mesial *septum.* They open anteriorly by the two *nostrils* or *anterior nares,* and posteriorly by the *posterior nares* or *choanæ* ("funnels") into the upper part of the pharynx. The anterior nares are guarded by hairs, *vibrissæ,* which spring from their inner surface. Each expands into a smooth-walled, front chamber called the *vestibule,* the rest of the nasal cavity being divisible into three channels called *meatuses.* The width of the nostrils bears in different races a very varying relation to its length measured vertically.

The *skin* of the nose is fine and movable over the bony part, thick, adherent, and closely studded with large sebaceous glands over the tip and alæ. It is reflected inward at the margin of the nostrils, and lines the vestibule. Its *vessels*

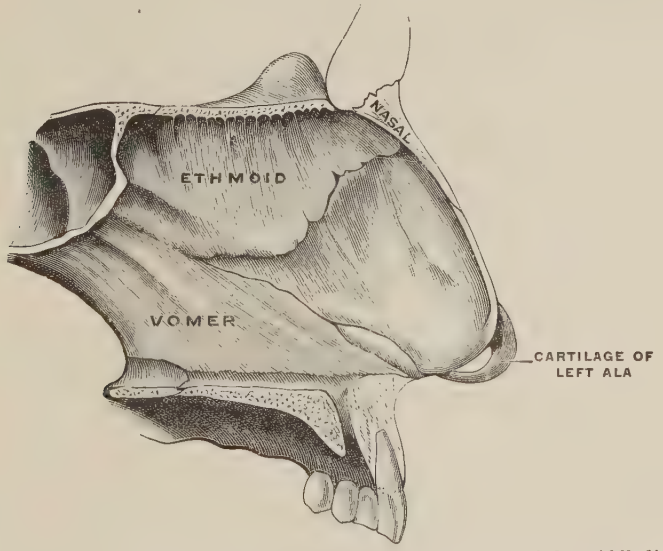

FIG. 752.—Septal cartilage of the nose, seen in sagittal section at the right of the middle line. (Testut.)

are derived from the ophthalmic and facial, and, being terminal, readily indicate the state of circulation. The lymphatics drain into the submaxillary nodes. The *sensory nerves* are derived from the infratrochlear, nasal, and infraorbital branches of the fifth; the *motor nerves* from the seventh. The *muscles* have been described among the muscles of the face.

The Nasal Cartilages.

At least two-thirds of the facial portion of the nose, and one-third of its septum have a framework of cartilage. Beginning with the *cartilage of the septum* (Fig. 752), the mesial plate is quadrilateral in form, completing the nasal septum. It articulates above with the nasal bones, behind with the vertical plate of the ethmoid, postero-inferiorly with the vomer, and nasal spine of the maxillæ, and antero-inferiorly with the septal portion of both lower lateral cartilages. In the fœtus, and occasionally in the adult, it sends a long limb or *processus posterior* into the ethmo-vomerine suture. The *upper lateral cartilages* (Fig. 753) are two lateral wings of the septal cartilage, which bend over to form part of the sides of the nose. They are triangular in shape, continuous with the septal cartilage in the middle line above, but separated from it below by a fissure, and articulate posteriorly with the free margins of the nasal bone and nasal processes of the maxillæ, small islets of cartilage sometimes intervening (cartilagines epactiles). Inferiorly they articulate with the lower lateral cartilages. Each *lower lateral cartilage* consists of two plates joined at an acute angle along the dorsum of the nose. The mesial plate is placed in apposition with its fellow to form the antero-inferior angle of the septum and part of the columna, a deep groove separating them in the middle line in front, while above they articulate with the cartilage of the septum. The lateral plate forms the lower part of the side of the nose, articulating above with the upper lateral cartilage, and posteriorly with the superior maxilla, two or three separate cartilages (*minor* or *quadrate cartilages*) being placed in the fibrous tissue which joins them. The lateral cartilages keep the anterior nares expanded. The ala contains no cartilage, but consists of skin and fibrous tissue only. Tough fibrous tissue fills in the interstices of this framework, and is continuous with periosteum and perichondrium. Two small strips of cartilage, not always separate from the septal cartilage, are interposed between the latter and the vomer. They enclose the organ of Jacobson, and are relatively large in the fœtus and in animals in whom the organ of Jacobson is well developed.

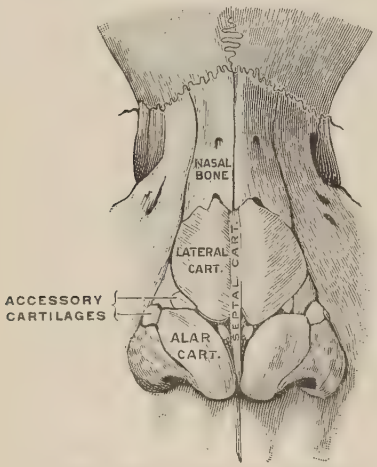

Fig. 753.—Front view of the skeleton of the nose. The upper lateral cartilage is labelled "lateral cart.," the lower, "alar cart." (Testut.)

THE NASAL FOSSÆ.

The *nasal fossæ* (Figs. 754, 755) have a very different appearance as seen with their mucous covering from that of their bony framework as described in the section on osteology. This difference is mainly due to the thickness of the mucous membrane, the complete closure of nervous or vascular foramina, and the narrowing of those openings which conduct to the air sinuses.

The upper part of each fossa, which corresponds in extent to the superior turbinate, is narrowed above at the roof, expanded below. It is the only part of the fossa which possesses the olfactory function. Below this the walls are nearly parallel. The anterior part of the fossa is unbroken by irregularities, and forms an expanded *vestibule*, into which the anterior aperture or nostril leads. Behind this each fossa has three awning-like processes projecting from its outer wall, formed by the turbinate bones, which, when covered with mucous membrane, nearly meet the septum. Thus three passages are formed. The *inferior meatus* is horizontal, lies along the floor half covered by the inferior turbinate, and extends from the vestibule to the pharynx. The *middle meatus* is overhung by

the middle turbinate, and is shorter and more oblique than the inferior; and the *superior meatus*, beneath the superior turbinate, is very short and oblique, and

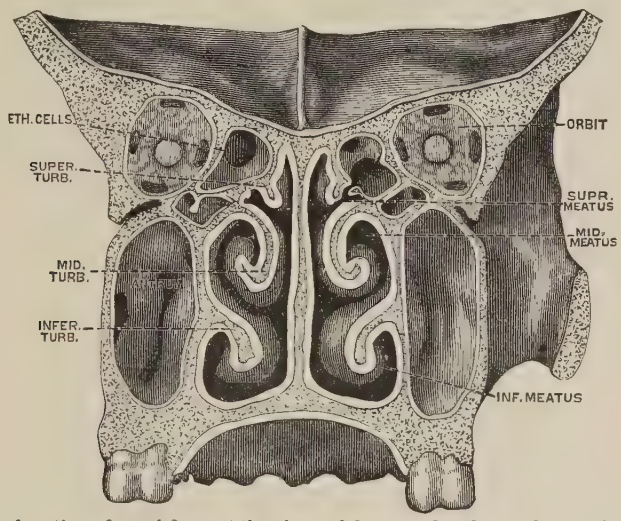

FIG. 754.—Coronal section of nasal fossæ at the plane of the second molar tooth, seen from behind. (Hirschfeld.)

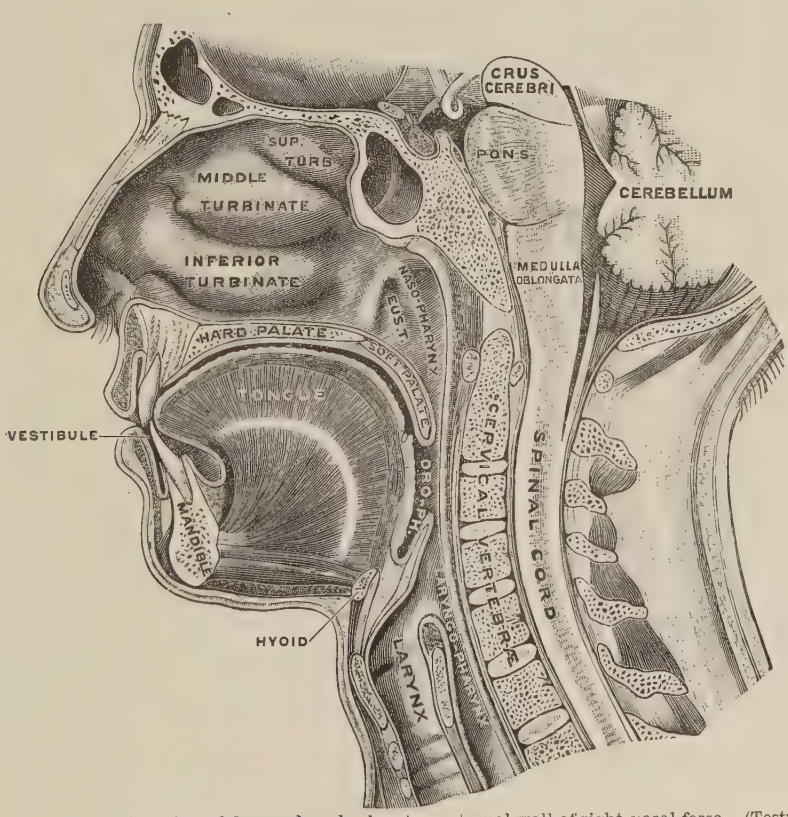

FIG. 755.—Sagittal section of face and neck, showing external wall of right nasal fossa. (Testut.)

confined to the supero-posterior angle of the fossa. Above the superior turbinate and between it and the sphenoid is an angular recess called the *spheno-ethmoidal recess*.

Cavities Opening Into the Nasal Fossæ.

Various passages open into the nasal fossæ (Fig. 756). Under cover of the anterior end of the inferior turbinate is the inferior opening of the *nasal duct*. It is guarded by a single or sometimes double fold of mucous membrane. In the floor of the nose, at the site of the nasopalatine canal, is a funnel-shaped tube of mucous membrane of varying depth called *Stenson's canal*. It is the relic of the

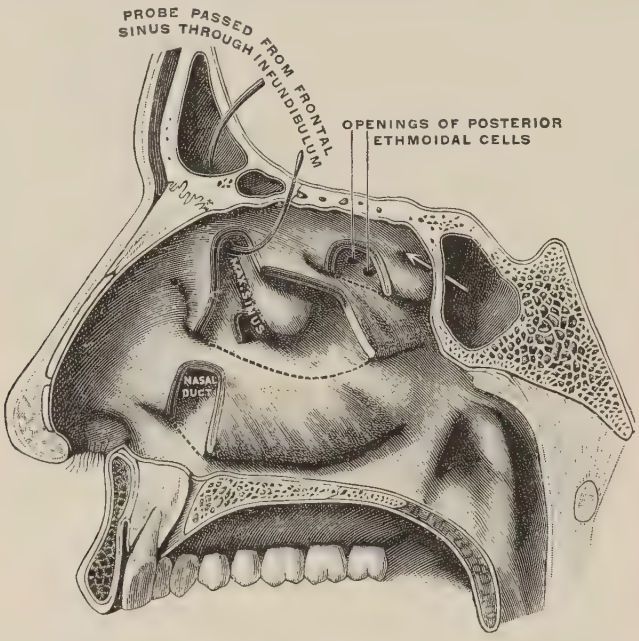

FIG. 756.—External wall of right nasal fossa, parts of the turbinates having been cut away to show the orifices of the sinuses which open into the meatuses. (Testut.)

communication between the nasal and buccal cavities, found in the early fœtus and permanent in some animals. Just above this there is sometimes seen on the nasal septum a depression leading into a minute canal, which runs backward for a short distance. This is the rudimentary *organ of Jacobson*. Under cover of the anterior extremity of the middle turbinate is a deep depression, the *hiatus semilunaris* ("half-moon gap"), which leads up to the *infundibulum* and thus into the *frontal sinuses*. In the bottom of the hiatus semilunaris is the *opening of the anterior ethmoidal cells*, the *maxillary sinus*, or *antrum* communicating with the nose by the same aperture, or by a separate opening a little farther back. Above this is the orifice of the *middle ethmoidal cells*. Into the superior meatus the *posterior ethmoidal cells* open by one or two apertures, and the *sphenoidal antrum* communicates with the *spheno-ethmoidal recess*.

The **Pituitary Membrane** (*Schneiderian*) is the mucous lining of the nose. It is inseparably united with the periosteum and perichondrium over which it lies. In the nostril it is continuous with the skin. It is prolonged into the maxillary, frontal, ethmoidal, and sphenoidal sinuses. By the nasal duct and lachrymal canaliculi it is continuous with the conjunctiva, and behind it joins the mucous membrane of the pharynx, and communicates by the Eustachian tube with the middle ear and mastoid cells.

The *thickness and vascularity* of the membrane and the character of its epithelium vary in different situations. It is thickest and most vascular over the turbinates and septum, not so thick on the floor of the nose, and thin and pale in the sinuses. The character of the epithelium and the distribution of the nerves divide the nose into an upper, olfactory part, comprising the upper turbinate and

a corresponding area of the septum, and a lower, respiratory part, from the level of the lower border of the upper turbinate downward. The vestibule is lined with a continuation of the external skin, which presents a stratified, squamous epithelium, with hairs, sebaceous glands, and sweat-glands. The rest of the respiratory area of the nose is covered with stratified, ciliated, columnar epithelium, with goblet cells, on a delicate basement membrane. The *tunica propria* of the mucosa is composed of white fibrous tissue, rich in leucocytes, and traversed by a wide venous plexus, so that it resembles cavernous tissue. Compound, racemose glands open freely on the surface, and between them is much lymphoid tissue, sometimes accumulated into nodules, and some plain muscular fibres. The various air-cavities (ethmoidal, frontal, etc.) are very sparingly supplied with glands, and in them the tunica propria is very thin.

The mucosa of the olfactory area is yellowish brown in color. Its epithelium presents two kinds of cells, namely sustentacular and olfactory. The *sustentacular cells* are columnar in form, possess no cilia, have their nuclei oval and arranged in a single row near their embedded extremities, and end in branching processes, which fill the spaces between the expanded, nucleated portions of the olfactory cells. The *olfactory cells* are thickly set between those just described. Each cell has an expanded portion in the middle enclosing a round nucleus, and from this two processes project. A thicker rod-like process extends forward toward the surface between the sustentacular cells, ending in the frog in a tuft of fine hairs, and described by some observers as possessing in man exceedingly short hair-like processes. From the proximal end of the nucleated expansion a fine varicose filament courses through the tunica propria, and is continuous with a nerve-fibril, which joins the plexus formed by the olfactory nerve, and thus ends in arborizations in the glomeruli of the olfactory bulb. The nuclei of the olfactory cells are situated at various depths, so that the zone of spherical nuclei is of considerable thickness. Beneath these and lying directly on a thin basement membrane some observers describe a layer of small polygonal cells. The submucous tissue is rich in veins, which here also give the mucous membrane almost a cavernous character; and many tubular glands, either simple or only slightly branched, called the *glands of Bowman*, are embedded in the submucous tissue.

Nerves.—The olfactory region is supplied by the olfactory nerve (Figs. 670, 671) and by branches of the fifth; the respiratory area by branches of the fifth only. The fifth nerve forms fine terminal ramifications among the epithelial cells. For the further description of these nerves see the section on the peripheral nerves.

The *organ of Jacobson* is an accessory olfactory organ, well developed in the rabbit, guinea-pig, and some other mammals, but rudimentary in man. It lies, as already described, embedded in the cartilage of Jacobson on each side of the septal cartilage near the floor. In man sustentacular cells only are found, but no true olfactory cells.

Vessels.—Branches of the internal maxillary, ophthalmic, and facial arteries supply the mucous membrane. The veins form so marked a plexus in the deeper parts of the mucosa as to cause it to resemble cavernous tissue. This is most pronounced over the lower turbinate, lower and hind part of the middle, and hind end of the upper turbinate, and the lower and hind part of the septum, and over the nasal duct. The lymphatics are very numerous. They join the lymph-spaces round the olfactory nerve, and thus communicate with the subdural and subarachnoid spaces

THE EAR.

By F. H. GERRISH.

THE ear is the organ of the sense of hearing. In the animal in which it occurs in its simplest form it is merely a sac, lined with a sensitive membrane and filled with fluid. Agitation of the medium in which the animal lives causes waves in the fluid of the sac, their striking upon the sensitive membrane produces a thrill in the nerve, and this, being transmitted to the nerve-centre, is there interpreted as sound.

Next higher in the scale is an ear, which, in addition to the elements above named, has minute stony bodies in its cavity. The effect of these particles is to heighten the impression which the waves of fluid bearing them produce upon the sensitive nerve.

The human ear is an extremely complicated organ, but the essential part of it is constructed on precisely the plan of this primitive ear. The organ consists of three portions, named respectively the *internal ear*, the *middle ear*, and the *external ear*. Of these only the first, the internal ear, is of indispensable importance; the others are merely accessory to it.

THE INTERNAL EAR OR LABYRINTH.

The essential part of the internal ear is a *sac, lined with a sensitive membrane, and filled with a fluid, in which are hard particles.* The sac is so very intricate that it is called the *labyrinth*, and, to distinguish it from the bony cavity in which it is lodged, the adjective *membranous* is applied to it. The membranous labyrinth is situated in the petrous portion of the temporal bone. It does not completely fill the excavation which it occupies, but between it and the surrounding bony wall there is a space, which is filled with a fluid, called *perilymph* ("the water around").

The Membranous Labyrinth (Figs. 757, 759).

General Description.—The membranous labyrinth is a closed bag of fantastic shape, consisting of several segments, which have received distinguishing names. At the middle of the series are two sacs, of which the larger and posterior is called the *utricle*, and the smaller and anterior, the *saccule*. From the utricle extend three long loops, the *semicircular canals*; from the saccule one long, coiled process, the *canal of the cochlea*; and from each of the sacs a minute tube, which unites with its fellow, and thus completes the continuity of the labyrinthine cavity. The fluid which fills this unbroken series of chambers and tubes is called *endolymph* ("the water within").

The membranous labyrinth has a basis of fibrous tissue, and is lined throughout with epithelium, which is simple and flattened, except over the areas where the branches of the auditory nerve are distributed, and in these places it is especially modified. The membrane is serous.

The Utricle.—The utricle is a sac of irregular shape. Upon that part of its inner surface to which a branch of the nerve of hearing is distributed is an area, called the *macula acustica* ("auditory spot"), in which the wall is thickened, and the epithelium peculiarly modified, being changed from flattened into *neuro-epithelium*. Some of the cells become conoidal and have upon their free ends each a strong, stiff hair; and others, longer than these and resting upon the basement

membrane, act as mechanical supports for the hair-cells. Among the cells are twined many ultimate filaments of the auditory nerve. On the free surface of the macula is a plate of gelatinous material containing a vast number of crystals of carbonate of lime, called *otoliths* ("ear-stones"). These, being driven by the waves of endolymph forcibly against the projecting hairlets, produce a much more profound impression than would the waves, if their impact was not thus accentuated.

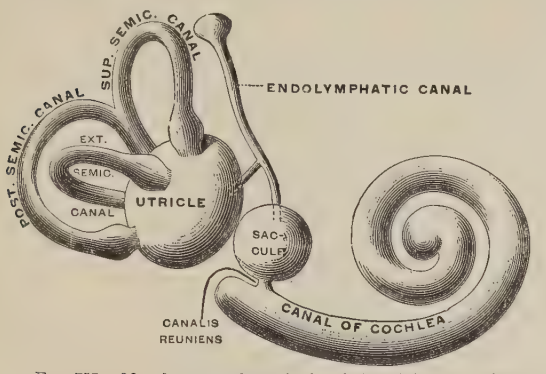

FIG. 757.—Membranous labyrinth of the right ear, viewed from the outer side; semidiagrammatic. (Testut.)

The Semicircular Canals.—From the utricle the three semicircular canals are given off. They are named from their position the *superior*, the *posterior*, and the *external*. The superior and posterior extend upward and backward, but the planes of their curves are nearly at right angles to one another; the external passes horizontally outward. Each of these canals is dilated at one end into an *ampulla* ("a wine-jug"). At the other end the superior and posterior unite before reaching the utricle, and enter it by a common opening. Thus, there are but five apertures in the utricle for the three semicircular canals. In each ampulla is a marked ridge, the *septum transversum*, due to a thickening of the wall, and this is surmounted by the *crista acustica* ("auditory crest"), made up of peculiar neuro-epithelial cells (Fig. 758). From the top of each of these cells projects a very long, rigid, hairlike process, the series of them spreading out widely like an opened fan, and reaching half-way or more to the opposite side of the ampulla. Below these *hair-cells* are *sustentacular cells*, which support them on every side; and between the cells of both kinds are filaments of the auditory nerve, which, though in contact with the cells, have no continuity of tissue with them.

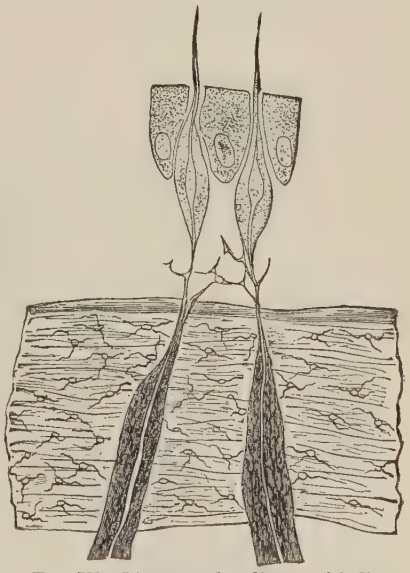

FIG. 758.—Diagram of auditory epithelium, and the mode of termination of the nerves of the ampullæ. (M. Schultze.)

The Saccule.—The saccule is much smaller than the utricle, and is situated farther forward and a little lower, but very close to it. It has a *macula acustica*, which is so like that of the utricle that it needs no separate description.

A minute tube, the *canalis utriculo-sacculari*s, is prolonged from the utricle, and a mate to it is given off from the saccule. The two unite and form the *ductus endolymphaticus*, a long tube, which ends in a bulbous expansion, the *saccus endolymphaticus*. Thus, though the utricle and saccule do not communicate directly, their cavities are connected by means of these ducts. From the saccule another tube gives a communication with the canal of the cochlea.

The Canal of the Cochlea[1] (Fig. 760).—The canal of the cochlea (also called

[1] In describing the cochlea, it is a matter of convenience to ignore its actual attitude, and to speak as if its summit were upward, its base downward; and this plan, which is conventional, will be followed here.

ductus cochlearis, and *scala media* ("the middle staircase") is a tube which, if straightened, would measure nearly one inch and a half in length. It communicates with the saccule through a short, narrow tube, the *canalis reuniens* ("the

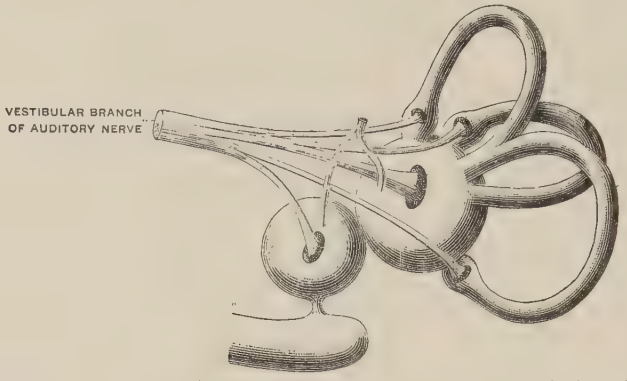

FIG. 759.—Saccule, utricle, and semicircular canals, viewed from the mesial side, showing points of entrance of the auditory nerve. (Testut.)

reuniting canal"). In shape it is prismoid, blunt at each end, tapering from its beginning to its apex, and coiled into a spiral. Of its three sides the upper is flat, and is made by the thin *membrane of Reissner*. Its outer wall is somewhat

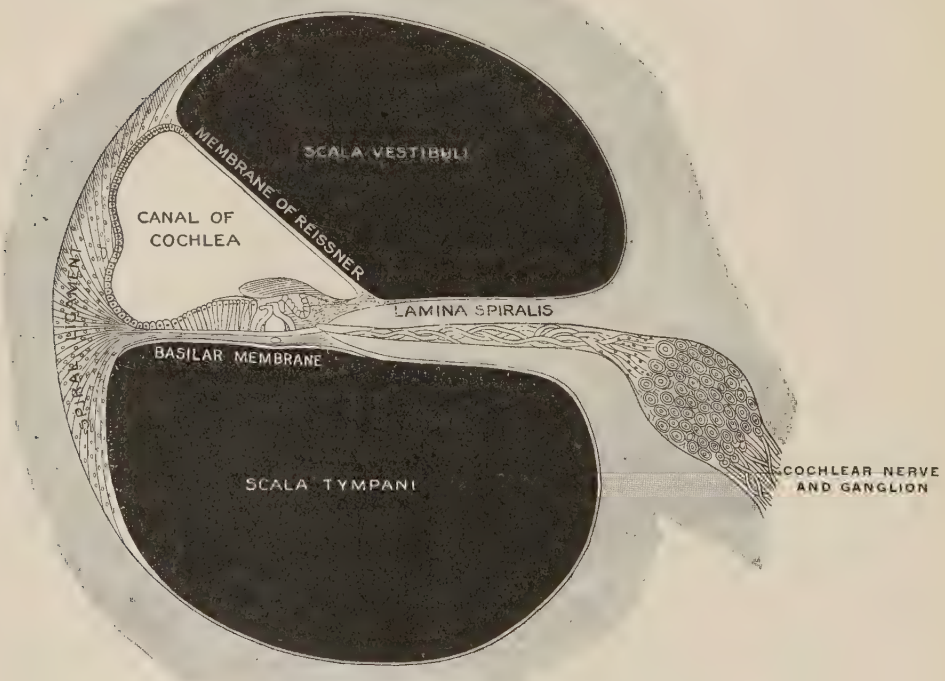

FIG. 760.—Cochlea in transverse section. Observe especially the canal of the cochlea, which is a part of the membranous labyrinth. (Testut.)

curved, with its concavity inward. The lower side is flat, and is composed mostly of a strong, fibrous sheet, called the *basilar membrane*, between which and the membrane of Reissner the angle is acute. Upon the basilar membrane are

located the structures which give the canal of the cochlea its peculiar interest. In the main these are especially modified epithelial cells, to which the principal part of the nerve of hearing is distributed. The greater portion of these cells

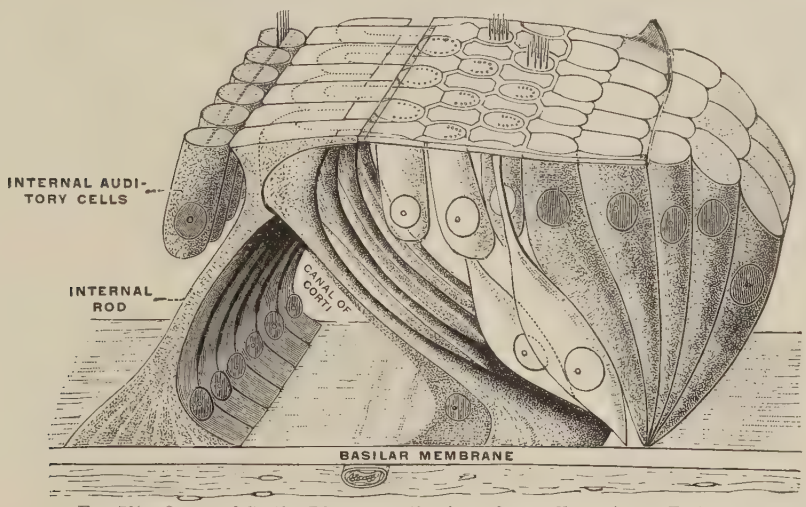

FIG. 761.—Organ of Corti. Diagrammatic view of a small portion. (Testut.)

constitute the *organ of Corti* (Fig. 761), and the parts of this around which the other elements are grouped are the *rods of Corti.* They are called *inner rods* and *outer rods*, according as they are nearer to or farther from the acute angle of the

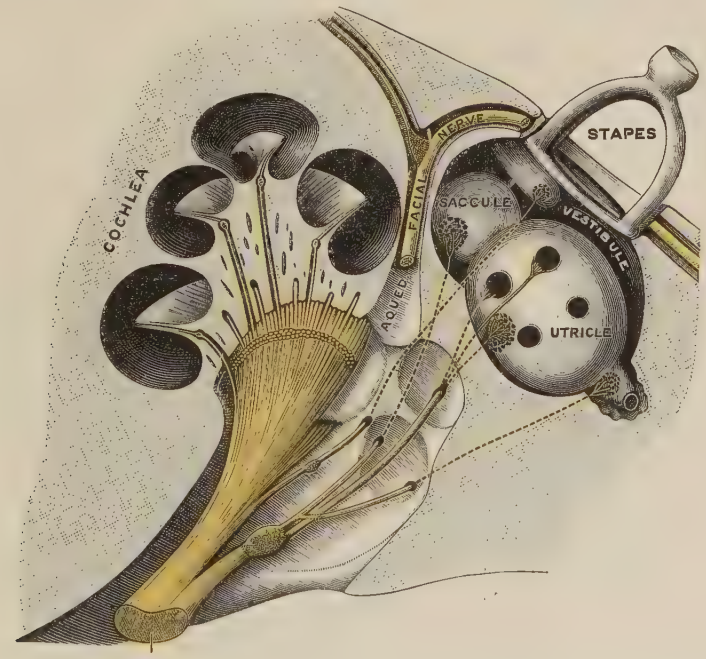

FIG. 762.—Distribution of the auditory nerve. Semidiagrammatic. (Testut.)

tube. The bases of these cells are broad, and securely fastened to the basilar membrane; their shafts are slender, and their upper ends enlarged, that of the inner suggesting the proximal extremity of the ulna, that of the outer looking considerably like the head of a swan. The rods of each set constitute a continuous row from end to end of the canal. The two sets incline toward each other

and meet above, a tunnel thus being formed, to which the name, *canal of Corti*, is given. Certain cells, called *basilar*, are attached to the bases of the rods on the side which presents toward the cavity, and seem to serve as buttresses to them. At the inner side of the inner rods is a row of short cells, from the upper end of which project stiff cilia, and from these circumstances they are called *inner hair-cells* (internal auditory cells), beneath which are roundish, protoplasmic cells. On the farther side of the outer rods are several rows of cells similar to the inner hair-cells, and called the *outer hair-cells*, these being supported by the *cells of Deiters*, which are fusiform and send long processes upward between the hair-cells to the surface. Still farther toward the outer side are conoidal cells, the *cells of Claudius*, each row of which is of less height than that toward its inner side, until the level of the undifferentiated cells lining the cavity generally is reached. Similar, but less numerous, cells of Claudius are arranged next to the inner hair-cells. Over the outer hair-cells and some adjacent rows is spread a membranous network, the *reticular lamina*, through which the hairs protrude. At the inner side of the internal cells of Claudius is a groove, the *sulcus spiralis*, running parallel with the organ of Corti. From a line near the acute angle of the cochlear canal starts a fold, at first thin, but soon enlarging into a thick pad, which stretches out over, and rests upon, the rods and hair-cells. It is called the *tectorial* ("covering") *membrane*. Likeness has been suggested between this membrane and the gelatinous pads, loaded with otoliths, which cover the maculæ acusticæ of the utricle and the saccule.

Branches of the auditory nerve (Fig. 762) enter among the structures which compose the organ of Corti, some being distributed to the inner hair-cells, while others end between the inner rods, and others still cross the canal of Corti and go to the outer hair-cells. Endolymph occupies the canal of the cochlea and also the canal of Corti and all of the spaces between the cells of the organ of Corti.

The Osseous Labyrinth (Figs. 763, 764).

The membranous labyrinth is situated in the petrous portion of the temporal bone. The part of the osseous tissue which immediately surrounds it is extremely

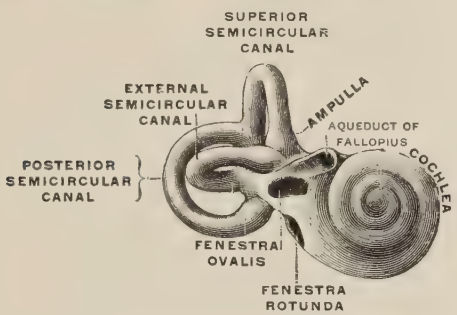

FIG. 763.—Osseous labyrinth, isolated and viewed from the outer side. (Testut.)

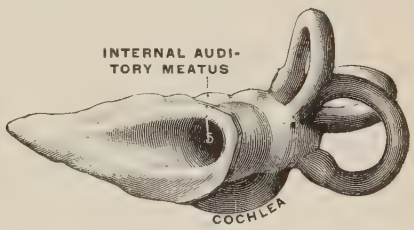

FIG. 764.—Osseous labyrinth, isolated and viewed from the mesial side. (Testut.)

dense, forming a rigid, protective shell for it. This is the *osseous labyrinth*. Its shape corresponds in the main to that of the complicated membranous labyrinth. But, although it is, as it were, a tunic for the latter, the fit is a very loose one. The membranous labyrinth in most parts occupies not more than a third, in places only a fifth, of the diameter of the cavity of the osseous labyrinth. The membranous, however, does not lie free in the cavity of the osseous, but at every part of its course is fastened to its containing case, usually as much as a quarter of its circumference being thus attached. Where the nerve-bundles enter the membranous labyrinth, it is always closely applied to the osseous. The osseous labyrinth is *lined with periosteum*, and where the membranous comes in contact with it, bands of fibrous tissue are added, and serve to confine it in place.

Fibrous trabeculæ cross from the membranous labyrinth to the opposite side of the osseous in various parts, and assist in the fixation. The *free surface of the periosteum* is covered with delicate, flattened cells, developed from fibrous-tissue corpuscles, and the free external surface of the membranous labyrinth and of the fibrous trabeculæ is similarly clothed.

The Vestibule.—The central portion of the osseous labyrinth is a chamber of sufficient size to give lodgment to the utricle and saccule. It is called the *vestibule*. On its outer side is an opening, the *fenestra ovalis* ("oval window"), which looks into the middle ear; but it is always closed in the recent condition. A depression at the front part of the mesial wall, called the *fovea hemispherica*, lodges the saccule; and another hollow, the *fovea hemielliptica*, behind and above



FIG. 765.—Constituent parts of the osseous cochlea—the modiolus, the coiled tube, the spiral lamina—isolated in the first three pictures, and combined in the fourth. Diagrammatic. (Testut.)

the last, holds the upper part of the utricle. Between the two is a ridge, the *crista vestibuli*, which divides below, and encloses a little pit in which lies the lower extremity of the canal of the cochlea. Close to this is the opening of the *aqueductus vestibuli*, holding the ductus endolymphaticus. Behind are the five apertures of the three *semicircular canals*. The canals bear a close resemblance in shape and direction to those of the membranous labyrinth which they enclose. The *scala vestibuli* of the cochlea begins at a large opening in the front and lower part of the vestibule.

The Bony Cochlea (Figs. 765, 766).—In front of the vestibule the osseous labyrinth presents the *cochlea*, which looks very like a coiled shell, as its name

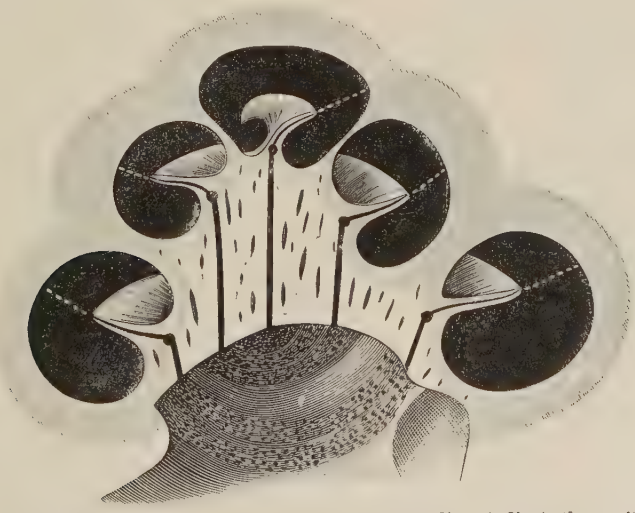

FIG. 766.—Osseous cochlea in vertical section. The broken, white lines indicate the position of the basilar membrane of the canal of the cochlea. Semidiagrammatic. (Testut.)

implies. Its base faces inward, forward, and upward, its apex in the opposite direction. It is in reality, as in appearance, a tube, gradually diminishing in size from base to apex, and twined nearly three times around a central, conical core, the *modiolus* ("nave"). From the side of the tube nearer the modiolus a thin shelf of bone, the *lamina spiralis*, projects about half way across its lumen.

Like other portions of the osseous labyrinth the cochlea is lined with *periosteum*. Upon the upper surface of the bony, spiral lamina, however, the periosteum is greatly modified, being much thickened, and ending above the free border of the lamina in a deeply grooved edge, the *sulcus spiralis*, already mentioned. This pad of modified periosteum is the *limbus* ("border"). Along the free edge of the spiral lamina the basilar membrane of the canal of the cochlea is attached, and stretches straight across to the opposite wall, where the periosteum is very thick and projects to meet it, constituting the *spiral ligament*. The membrane of Reissner is attached to the upper surface of the limbus. Thus it is seen that the lamina spiralis and the canal of the cochlea together divide the lumen of the bony cochlea into two unequal parts—one, the smaller, above, called the *scala vestibuli*, because it opens into the vestibule; and the other, and larger one, below, called the *scala tympani*, because its lower end presents at the *fenestra rotunda* ("round window"), where it would be in continuity with the tympanum (the drum of the ear), were it not for the complete closure of this window. It is now clear why the canal of the cochlea, which is between the scalæ vestibuli and tympani, is sometimes called the *scala media*.

The scalæ vestibuli and tympani have communication only by a small opening, the *helicotrema* ("hole of the coil") at the highest point, the *cupola*, of the cochlea.

From the scala tympani near its large end a little canal, the *aqueductus cochleæ*, gives passage to a little vein into the inferior petrosal sinus near the jugular fossa.

The Auditory Nerve.—The base of the modiolus presents toward the internal auditory meatus, from which it receives a large part of the auditory nerve. The fibres of the nerve run in the modiolus to the attached edge of the spiral lamina, and then through this to its free edge, whence they are distributed to the organ of Corti, as previously detailed. The fibres destined for the lower turn of the spiral are at the outside of the bundle, those for the apex in the centre. Within the lamina the nerves pass through a mass of cells, constituting the *spiral ganglion*.

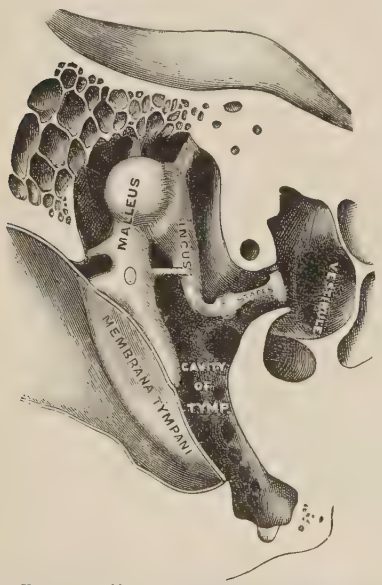

FIG. 767.—Chain of ossicles and their ligaments, seen from the front in a vertical, transverse section of the tympanum. (Testut.)

As has been already stated, the space between the membranous labyrinth and the osseous labyrinth is filled with perilymph. This space communicates through the sheath of the auditory nerve with the subdural and subarachnoid spaces, whose fluid is lymphatic in character, like that of all serous membranes. Communication has also been shown to exist between the cavity of the membranous labyrinth and the subdural space by means of the saccus endolymphaticus.

THE MIDDLE EAR OR TYMPANUM.

The middle ear (Figs. 767, 768) is situated at the outer side of the inner ear or labyrinth, and between the latter and the external ear. It is known as the *tympanum* or *drum of the ear*, and various features of its structure justify the name. Like the labyrinth the tympanum is located in the petrous portion of the temporal bone. It is a fore-and-aft cleft, deep, long, and narrow. Its roof is formed by a rather thin plate of bone, which separates its cavity from that of the cranium. Its external and internal walls present the greatest expanses of surface, and converge to its floor, which has hardly any width. The tympanum is lined

throughout with mucous membrane, which covers every object contained in the cavity.

The **outer wall** is composed almost entirely of a broad, fibrous sheet, the *membrana tympani* ("membrane of the drum"), and the rim of bone to which it is attached. The membrana tympani has as its basis a firm layer of white fibrous tissue. On its inner side is a lining of mucosa, and on its outer a coat of skin. The membrane is moderately tight everywhere except at the very top, where there is a small area, which is comparatively flaccid. The membrane is not flat, but its centre presents a prominence upon the mesial side. It slopes markedly from above downward and inward.

The **inner wall** of the tympanum has a very uneven surface. The most marked prominence is the *tuber cochleæ*, produced by the protrusion of the first turn of the cochlea. Below this is a round hole, the *fenestra rotunda*, closed by a fibrous membrane, but for which communication would be established between the tympanum and the scala tympani. The membrane is called the *secondary membrane of the tympanum*—the second head to the drum. At a little higher level than the tuber is the *fenestra ovalis*, also stopped with a fibrous membrane, to which is attached an ossicle, presently to be described. Above this oval window is a ridge, which shows the situation of the aqueduct of Fallopius, in which is the facial nerve.

At the rear and upper part the tympanum communicates through a large hole with a series of irregular and connected cavities in the mastoid portion of the temporal bone, the most considerable and the nearest of these being the *mastoid*

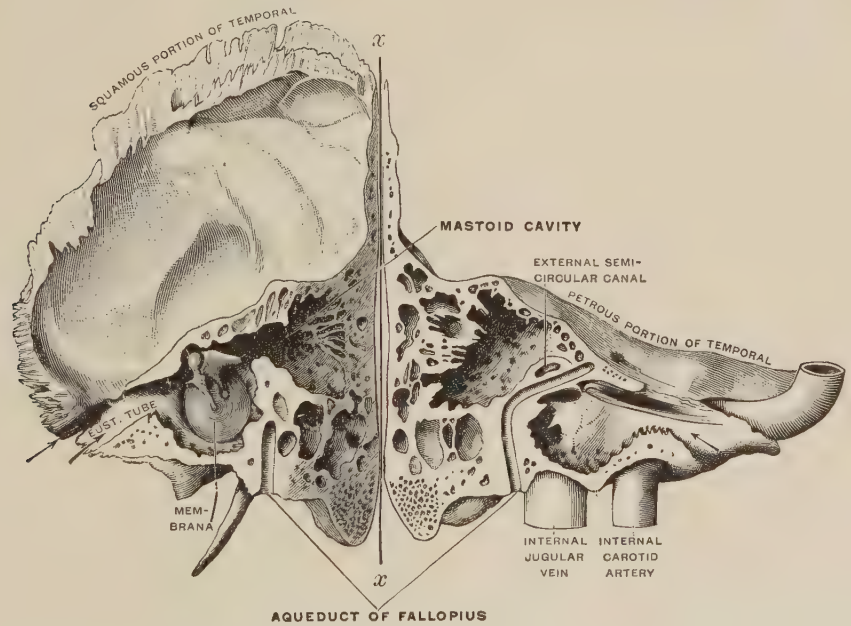

FIG. 768.—Coronal section of the right temporal bone, passing through the Eustachian tube and the middle of the tympanum. Both surfaces of the section are shown, the parts being hinged on the line *xx*. (Testut.)

antrum, the others being the *mastoid cells*. These cavities are all lined with mucous membrane, continued into them from the tympanum. Lower down on the hind surface is a prominence of bone, called from its shape the *pyramid*, from the apex of which projects the tendon of the stapedius muscle.

In front and below, the tympanum slopes into a long channel, the *Eustachian tube*, the distal end of which opens into the pharynx. Through this tube air is admitted to and expelled from the middle ear, and thus atmospheric pressure on the inner and outer sides of the membrana tympani is equalized. The tube does

the service to the tympanum that is rendered by the hole in the side of the kind of drum which is accounted a musical instrument.

The **Eustachian tube** (*tuba auditiva*) (Fig. 769) is about an inch and a half long. It extends downward, forward, and inward, and its lower end presents a

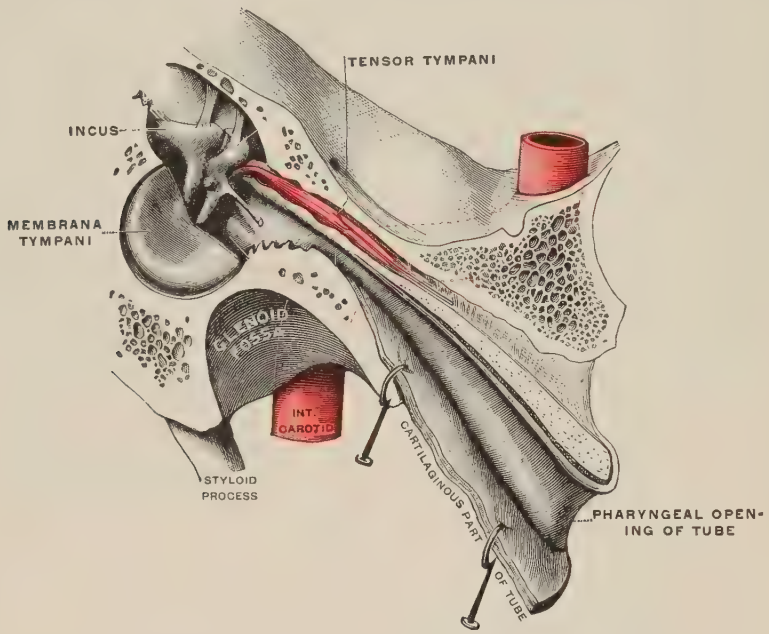

FIG. 769.—Eustachian tube, laid open by a cut in its long axis. (Testut.)

projecting margin on the lateral wall of the pharynx, close by the inferior meatus of the nose. Its upper part is bony, its lower is cartilaginous. It is lined with mucous membrane.

Above and parallel with the Eustachian tube is a *bony canal*, lodging the tensor tympani muscle, whose tendon projects into the tympanic cavity.

The Ossicles (Fig. 767).—Extending across the tympanum from side to side is a chain of three little bones, the *ossicula auditus* ("ossicles of hearing"). From without inward they are the malleus, the incus, and the stapes. The malleus is attached to the membrana tympani, the stapes to the membrane of the fenestra ovalis, and the incus is between and connects the others, with each of which it has a movable articulation.

The **malleus** ("hammer") has a roundish *head*, which is upward, a constricted *neck*, and a long tapering *handle* (*manubrium*), which extends downward and a little backward, and is attached to the membrana tympani. A *long process* runs downward and forward from below the neck to the Glaserian fissure; and a *short process* passes outward to the membrana tympani.

The **incus** ("anvil") presents a *body*, upon the anterior surface of which is an articular area by which it is jointed to the malleus; a *short process*, which runs to the posterior wall near the opening of the mastoid antrum; and a conical, *long process*, which extends at first downward and at last mesially, ending in a knob, the *orbicular process*, which articulates with the stapes.

The **stapes** ("stirrup") bears a remarkable resemblance to the object from which it is named. Its *base*, the foot-piece, is broad and very nearly fills the fenestra ovalis, to whose membrane it is attached. The side-pieces, *crura*, converge to the *neck*, beyond which is the *head*, cupped on its outer surface, and articulating with the orbicular process of the incus.

Besides the attachment of the malleus to the membrana tympani and that of

the stapes to the membrane of the fenestra ovalis, *ligaments* running to different parts of the bony walls serve to hold the ossicles in place.

Muscles of the Tympanum.—Two muscles are connected with the series of ossicles, the tensor tympani and the stapedius.

The **tensor tympani** ("tightener of the drum") (Fig. 769) is principally situated in the canal above the Eustachian tube. Its tendon bends outward on escaping from the canal, and is inserted into the handle of the malleus near the neck. Contraction of the muscle pulls the membrane of the drum inward, and thus tightens it.

The **stapedius** arises in the cavity of the pyramid, from the apex of which its tendon passes forward into the tympanic cavity, and is inserted into the neck of the stapes. This muscle rocks the base of the stapes in the fenestra ovalis, and thus causes pressure upon the perilymph of the labyrinth.

The **mucous membrane** of the tympanum projects from the roof into the cavity in several folds, which are very variable in number, form, and size. The epithelium of the mucosa is partly columnar and ciliated, and for the rest flattened and not ciliated.

Just below the pyramid the *chorda tympani* nerve enters the middle ear, and runs forward across the handle of the malleus to its aperture of exit near the Glaserian fissure. Like the other intratympanic structures it is invested with mucosa.

THE EXTERNAL EAR.

The external ear comprises (1) the external auditory meatus, the tube leading from the outer wall of the tympanum to the surface of the head, and (2) the auricle or pinna, the flaring body, which projects from the side of the head.

The **External Auditory Meatus** (Fig. 770) is about an inch long. It is of

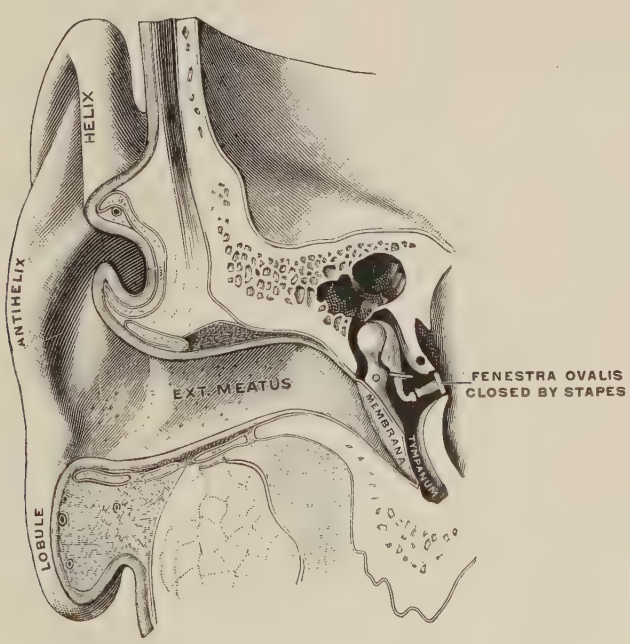

FIG. 770.—Vertical section through the external auditory meatus and tympanum, passing in front of the fenestra ovalis. (Testut.)

greatest diameter near its outer end, and of least near its middle part. Its direction varies in different portions. As it is traced inward, it goes at first forward and upward, then backward, and finally forward and downward; but its dominant trend is inward and forward. The tube rises toward the middle of its course,

and beyond this it descends. Its floor is longer than its roof on account of the obliquity of the position of the membrana tympani.

The mesial portion has a basis of *bone*, its peripheral, one of *yellow fibro-cartilage*, pieced out with fibrous tissue. The flexibility of the latter portion renders it practicable to make the meatus nearly straight by pulling the pinna (with which it is continuous) upward and backward.

The meatus is lined throughout with *skin*. In the cartilaginous part and the adjacent portion of the osseous there is a great number of glands, which structurally are identical with ordinary sweat-glands, only larger; but, instead of secreting perspiration, they form *cerumen*, commonly called "ear-wax"—a substance thought to be offensive to insects, and, consequently, a defence against their intrusion. The glands are called *ceruminous*. Near the outer end of the tube are many short *hairs* and *sebaceous glands*. The skin which clothes the membrana tympani is very delicate, and is free from hairs and glands.

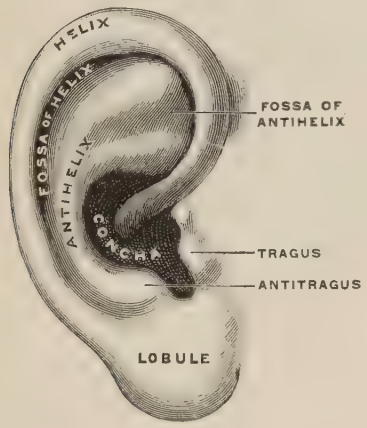

FIG. 771.—Right pinna. (Testut.)

The **Pinna** (Fig. 771) is of irregularly oval shape, and is an abrupt expansion of the meatus. Its central portion is shell-like in form, and hence is called the *concha*. Beginning near the middle of the concha is a ridge, which runs forward and upward to the front margin of the pinna, whence it continues around nearly to its lowest part, forming a prominent rim, called the *helix* ("coil"). The rim of the concha itself begins at its front and lower part in a prominent tubercle, the *antitragus* ("opposite the tragus"), and runs backward, then upward, and lastly forward, dividing at the junction of its hind and upper parts into two branches, which enclose a triangular hollow. This margin of the concha is the *antihelix* ("opposite the helix"), and the area embraced by its division is the *fossa of the antihelix*. Between the antihelix and the helix is the *fossa of the helix*, overlapped by the incurved lip of the helix. In front, between the origins of the helix and antihelix, is a backward projecting plate, which covers the orifice of the meatus at a little distance, and is called the *tragus*. The lowest portion of the pinna is a flat, soft, pendulous body, the *lobule*.

All portions of the pinna, except the lobule, are composed almost entirely of *yellow fibro-cartilage*, which is continuous with that in the peripheral part of the meatus, and clothed with *skin*. Except upon the convexity of the helix, the skin is very thin and closely adherent to the cartilage. The lobule has no cartilage, and is merely a bag of skin, containing areolar and adipose tissues.

The pinna is attached to the cranium by *ligaments* which run forward to the root of the zygoma and backward to the mastoid process.

The *shape of the pinna* is practically the same all through life, changing less than that of any other feature; and, as no two ears are exactly alike, the recognition of this maintenance of the characteristic peculiarities of each individual ear has established what is probably the surest method of physical identification.

Muscles.—Half a dozen muscles, called *intrinsic*, connect different parts of the pinna with one another. They are the helicis major, helicis minor, tragicus, antitragicus, transversus auris, and obliquus auris. But, as they are all rudimentary in man, are, indeed, often impossible of demonstration, and never of any practical importance, they will receive no further attention.

There are three *extrinsic muscles* (Fig. 427) which require mention, though almost always imperfectly developed and incapable of action. Occasionally, however, there is an individual who possesses in a measure the ancestral capacity of moving his ears voluntarily.

The **attollens aurem** ("lifting the ear") or *auricularis superior*, the largest

of the trio, arises from the lower border of the epicranial fascia, narrows as it descends, and is inserted into the mesial surface of the helix and the prominence, which is collocated with the fossa of the antihelix.

The **attrahens aurem** ("drawing the ear toward," *i. e.*, forward) or *auricularis anterior*, the smallest of the group, arises from the epicranial fascia below the front part of the preceding muscle, passes backward, and is inserted into the fore part of the helix.

The **retrahens aurem** ("drawing back the ear") or *auricularis posterior*, arises from the mastoid process of the temporal bone, passes forward, and is inserted into the back of the concha.

The *arteries* of the pinna are the posterior auricular and the superficial temporal. The *nerves* are the great auricular, posterior auricular of the facial, the auriculo-temporal of the fifth, and the small occipital.

It is interesting to note that the membrane lining the inner ear is *serous*, that lining the middle ear *mucous*, and that of the external ear *cutaneous*.

THE EYE.

By W. KEILLER.

THE *eyeball*, which is the essential *organ of the sense of sight*, is a somewhat spherical body, occupying the cavity of the orbit, where it lies embedded in a mass of fat and loose connective tissue. From the posterior two-thirds of the surface of the eye this bed is walled off by a membrane known as the *capsule of Tenon* (Fig. 772) between which and the globe of the eye there is a lymph-space

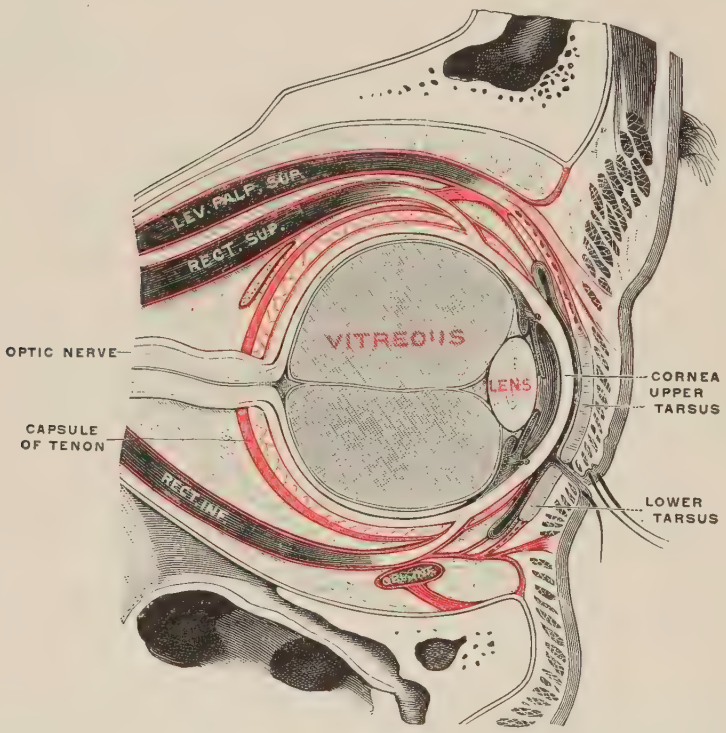

FIG. 772.—The right eye in sagittal section, showing the capsule of Tenon. Semidiagrammatic. (Testut.)

occupied by very loose areolar tissue, the whole forming a pliable socket, within which the eye rotates with the utmost freedom. The anterior third is covered by the *conjunctiva*, a mucous membrane reflected onto the globe from the deep aspect of both eyelids. The surface of the globe is pierced by numerous vessels and nerves, and gives attachment at certain points to the muscles, by which the movements of the eyeball are accomplished.

A lateral view of the eye on the living subject reveals the fact that its surface is not all uniformly curved. In such a view the anterior, clear portion, known as the *cornea*, will be seen to bulge out appreciably beyond the normal curve of the posterior, white, or *sclerotic* portion. It thus appears that the eye-

ball is not strictly a sphere, but is composed of segments of two unequal spheres, an anterior, smaller segment (of a smaller sphere), forming about one-sixth of the whole, superposed upon a posterior, larger segment (of a larger sphere), forming the remaining five-sixths.

For descriptive purposes certain points and lines in relation to the eyeball must be defined. The *anterior pole* is the centre of the front surface of the cornea; the *posterior pole* is the centre of the back surface of the sclerotic; a straight line joining these poles is the *sagittal axis*. The *equator* of the eyeball is a line around its surface equally distant at all points from the two poles; its plane divides the globe into *anterior* and *posterior hemispheres*. The inner side of the eye is appropriately termed the *nasal side*; the outer, the *temporal*.

To prevent misconception, it is necessary to say here that, even if its segmented formation be disregarded, the eyeball is still not a perfect sphere. The transverse diameter (about one inch) is the greatest, the antero-posterior slightly less, and the vertical the least. It may be added that, in an antero-posterior, vertical section of the eyeball, passing through the sagittal axis, the inner or nasal division will be slightly smaller than the outer or temporal.

Anatomically considered, the eye may be regarded as a hollow sphere (Fig. 773), whose wall is composed of three tunics and whose cavity is filled by three refracting media. The three tunics are (1) an outer, *fibrous tunic*, consisting of

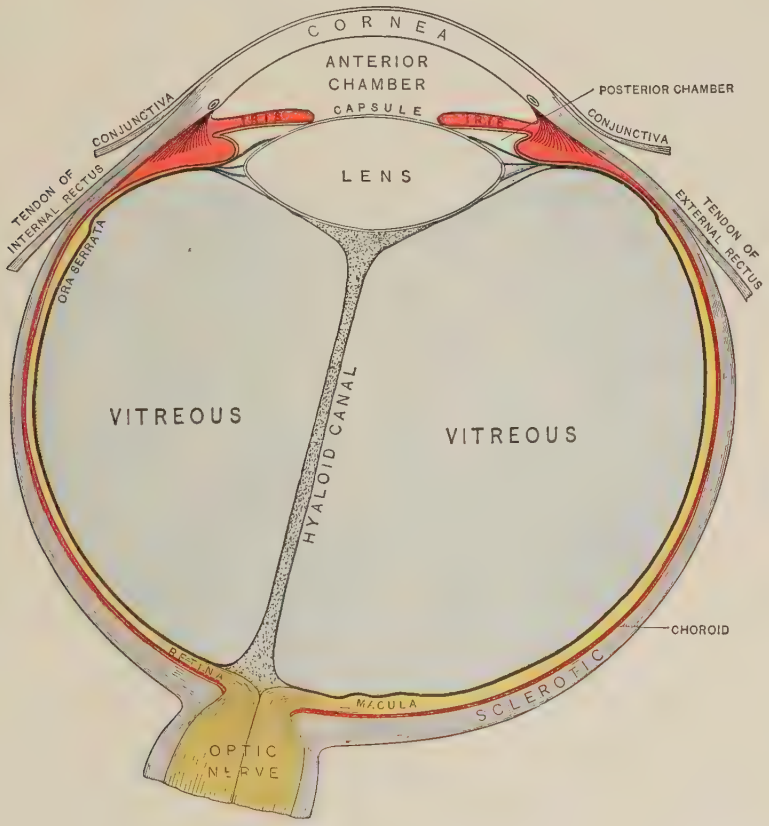

FIG. 773.—The right eye in horizontal section, showing the upper surface of the lower segment. Diagrammatic. (Testut.)

sclerotic and cornea; (2) a middle, *vascular tunic*, comprising choroid, ciliary zone, and iris; (3) an inner, *nervous tunic*, the retina. The three refracting media are the *aqueous humor* in front, the *vitreous humor* behind, and the *lens* between the two others. Each of these will be considered in turn.

THE EXTERNAL OR FIBROUS TUNIC.

The two parts of the outer, fibrous tunic, though continuous in structure, differ much in appearance, the cornea in front being perfectly clear and transparent, and the sclerotic behind, white and opaque. Both are dense and firm, and serve to preserve the form of the eyeball. At their junction all around is a wide, shallow depression, the *scleral sulcus*.

The Sclerotic.

The posterior surface of the sclerotic is pierced by the optic nerve, an eighth of an inch internal to the posterior pole. Here the dural sheath of the nerve blends with the sclerotic, and the nerve fibres, in many small bundles, enter through distinct minute pores. The part of the sclerotic thus perforated is called the *lamina cribrosa* ("sieve-like layer"). Around the optic nerve-entrance, and more or less adjacent to it, the sclerotic is pierced by the ciliary nerves, and the long and short posterior ciliary arteries; while, farther toward the equator, four or five apertures transmit the large veins called from their mode of formation the *venæ vorticosæ* (Fig. 774). A little way ($\frac{1}{12}$ inch) behind the corneo-scleral junction the sclerotic is pierced by the anterior ciliary arteries. Somewhat anterior to the equator it gives attachment to the four recti muscles, the two obliqui being attached behind.

On the deep surface of the sclerotic, between it and the choroid, there is a layer of loose, pigmented connective tissue, the *lamina fusca* ("brown layer"), which imparts to its inner surface a dingy, brownish hue. This tissue really occupies a lymph-space between the two tunics. Thus the sclerotic has a lymph-space on each side of it, and the surface that looks toward each space is covered by epithelium.

The sclerotic consists of bundles of white fibrous tissue, containing elastic fibres, and having connective-tissue corpuscles lodged in cell spaces. The tissue is disposed in laminæ, in some of which the fibers run longitudinally and in others transversely. The laminæ are not separable owing to a frequent interchange of fibres.

The scant blood-supply of the sclerotic is derived from the short ciliary and the anterior ciliary arteries, and its more scant nerve-supply, from the ciliary nerves.

The Cornea.

The cornea, devoid of blood-vessels and perfectly transparent, is the window which admits light to the interior of the eye. It is set in the sclerotic in much the same way as a watchglass is set in its frame. Here the resemblance ends, however, for the sclerotic and cornea are perfectly continuous. Viewed from behind, the cornea is perfectly circular, but a front view shows its transverse slightly greater than its vertical measurement. This is due to the sclerotic's overlapping it more above and below than laterally. The cornea is always more curved than the sclerotic, but its curvature varies in different individuals and at different periods of life, being greatest in youth and diminished in old age. Its outer surface is covered by conjunctival epithelium of the stratified flattened variety, several cells deep. Its posterior surface is lined by a firm, elastic, homogeneous membrane, the *membrane of Descemet*, structurally distinct from its own proper substance. Shreds of this membrane stripped off of the cornea tend to curl up with the attached surface inward. Around the margin of the cornea the membrane of Descemet becomes fibrillar, and breaks up into bundles, some of which attach themselves to the sclerotic and choroid, while others bridge over the irido-corneal angle, and attach themselves to the front of the iris. These latter constitute the *ligamentum pectinatum iridis* ("the combed ligament of the iris") or pillars of the iris. The sponge-like formation, produced around its border

by the breaking up of the membrane of Descemet, contains a number of minute spaces, *the spaces of Fontana*, which communicate with the aqueous chamber on the one hand, and, on the other, with a minute venous sinus contained in a canal in the sclerotic, which encircles the margin of the cornea. This is the *canal of Schlemm*.

The *substantia propria* of the cornea is composed of many superposed layers of connective tissue, the fibres of contiguous layers having different directions, and all being inseparably held together, as in the sclerotic, by many interchanges of fibres. Between the layers, and even between the bundles and fibrils of which they are composed, there is an interstitial cement substance, in which are found lymph-spaces, occupied, but not filled, by the corneal corpuscles, and all directly or indirectly communicating so as to provide for a very complete lymph-vascular circulation.

Unlike the sclerotic, the cornea is richly supplied with nerves, which are derived from the ciliary. They first form a plexus around its margin; then, losing their medullary sheath, they form another plexus in the laminated structure; from this branches proceed to form a third plexus on the corneal surface beneath the conjunctival epithelium; finally, fibrils pass in among the epithelial cells, and reach their terminal distribution almost at the free surface of the conjunctiva.

THE MIDDLE OR VASCULAR TUNIC.

In the vascular tunic, or *uveal tract*, of the eye (Fig. 774) three parts may be distinguished: the *choroid* behind, the *iris* in front, and the *ciliary zone*, or *body*,

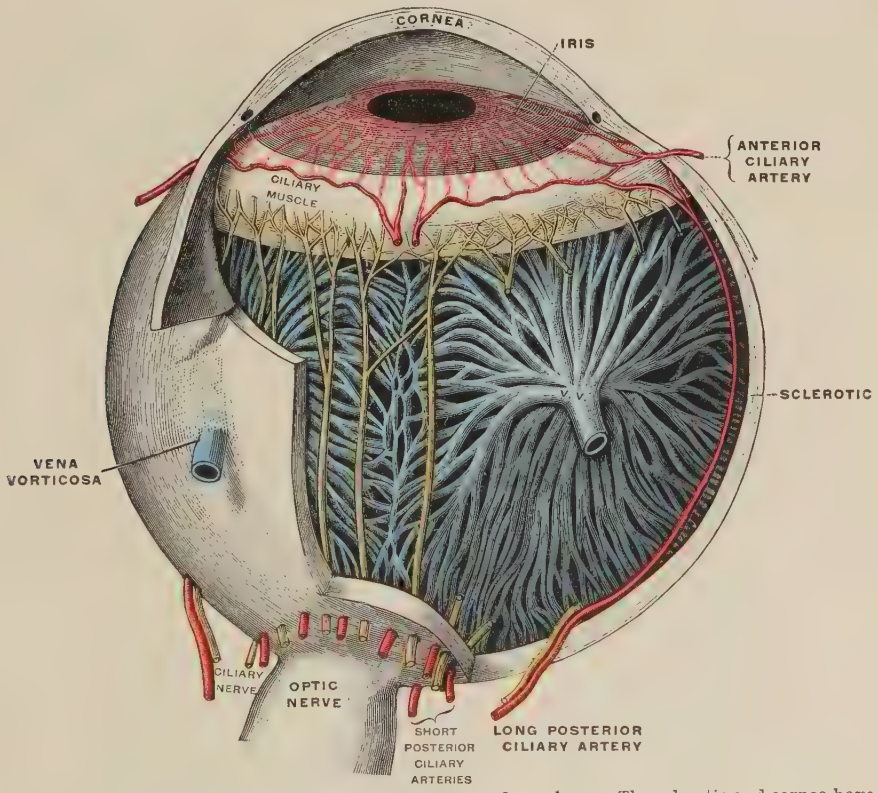

FIG. 774.—Vessels and nerves of the choroid and iris, seen from above. The sclerotic and cornea have been largely removed. (Testut.)

between. The choroid and ciliary zone are applied to the inner surface of the sclerotic; but, except at the optic nerve entrance and the attachment of the ciliary

muscle to the sclerotic, the adhesion between them is very loose, a lymph-space, as already stated, being left between them. The iris, attached only at its circumference, hangs vertically in the aqueous humor about $\frac{1}{10}$ inch behind the cornea, its pupillary margin resting lightly against the lens. The choroid is pierced behind by the optic nerve. On its outer surface the ciliary nerves, about fifteen in number, and the two long posterior ciliary arteries, after piercing the sclerotic, run forward to the iris.

The Choroid.

The choroid is a dark brown structure, whose stroma consists of blood-vessels, held together by delicate connective tissue, containing pigmented cells. The stroma is limited on both surfaces by non-vascular membranes, the pigmented *membrana suprachoroidea* on the outside, and the unpigmented *vitreous lamina* on the inside. The vessels of the stroma exhibit two well-marked layers, a superficial venous layer formed of the vasa vorticosa, and a deep, closely-packed, capillary layer, the *chorio-capillaris*. Between these layers the short ciliary arteries run forward, giving off as they go the vessels of the chorio-capillaris and terminating in those of the ciliary processes.

The Ciliary Zone.

The *ciliary zone* or *ciliary body* differs from the choroid, not so much in the composition of its vascular stroma, as in the fact that it contains a deposit of muscle-tissue, the *ciliary muscle* (Fig. 775), and presents on its deep surface a

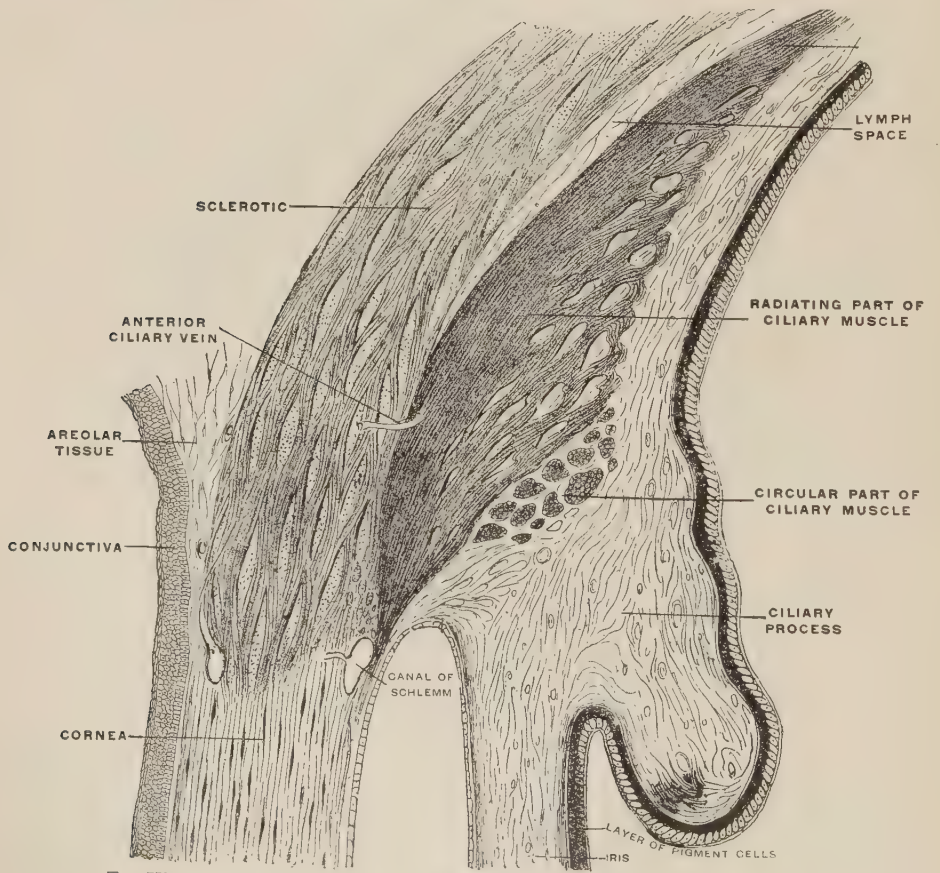

FIG. 775.—Meridian section of the eye in the region of the ciliary muscle. (Testut.)

series of radial thickenings or ridges, the *ciliary processes* (Fig. 777), about seventy in number, which, rising gradually from the anterior limit of the choroid, reach their greatest elevation a little behind the corneo-scleral junction, where they terminate abruptly in a series of prominences, the *corona ciliaris*. Superficial to these lies the ciliary muscle, containing both radiating and circular fibres. The former arise from the deep surface of the sclerotic near the cornea, where they are attached to the bundles of the membrane of Descemet already referred to. Extending backward they are inserted into the outer surface of the ciliary body and choroid. The circular fibres are placed on the deep surface of the radiating portion, and form a muscular ring around the circumference of the iris. When the ciliary muscle contracts, it draws forward the choroid and ciliary body, thus relaxing the suspensory ligament, which allows the lens to become more convex for near accommodation.

The Iris.

The *iris* ("rainbow") (Figs. 776, 777) is the colored membrane which hangs like a screen in the aqueous chamber behind the cornea. In its centre is the aperture called the *pupil*, which, through the contractile power of the iris, varies in size and is thus adapted to regulate the amount of light admitted to the retina. At its circumference the iris is continuous with the ciliary body, and, through the ligamentum pectinatum iridis, with the cornea also. Faint, wavy lines on its anterior

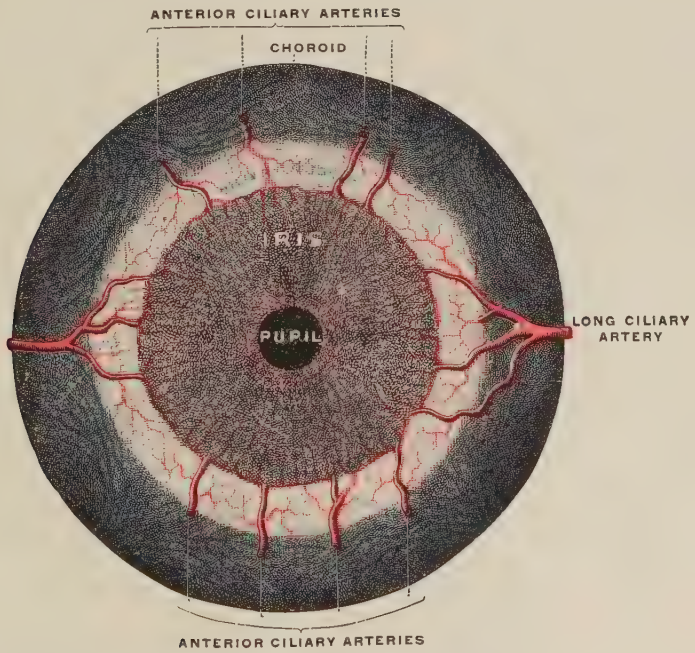

FIG. 776.—Iris, front view. (Testut.)

surface, converging toward the pupil, mark the situation of subjacent blood-vessels. Its posterior surface is covered by a layer of dark pigmented epithelium, which belongs morphologically to the retina. Its stroma is formed of delicate connective tissue, containing a variable number of pigmented cells, and carrying numerous vessels and nerves. The color of the iris depends partly on the pigment cells of the stroma, and partly on the retinal layer behind. When the pigment is abundant in the stromal cells, it controls the color,—some shade of gray, brown, or black; but when it is scanty or absent, that of the retinal cells behind showing through the stroma imparts to the iris one of the various shades of blue.

Near the pupillary border of the iris there lies embedded in the stroma a circular band of smooth muscle-fibres, the *sphincter iridis*, whose action contracts the pupil. On the deep surface of the sphincter is a membrane formed of straight fibres, stretching from the circumference of the iris to the sphincter. Whether these are muscle-fibres or merely elastic is still unsettled, but the view prevails that they cause dilatation of the pupil.

FIG. 777.—Segment of the iris, ciliary body, and choroid, view from the internal surface. (Testut.)

Vessels and Nerves of the Iris.—The two *long ciliary arteries* run forward along the outer and inner aspects of the globe, between the sclerotic and choroid, to the attached border of the iris. Here each divides into a superior and an inferior branch, which, by anastomosing with one another and with the *anterior ciliary arteries* (from the muscular branches of the ophthalmic), form a vascular ring in this situation, the *circulus major iridis*. From this branches are given off, which converge toward the pupil, where, by dividing and anastomosing, they form the *circulus minor iridis*. The arrangement of the veins corresponds to that of the arteries. They communicate with the sinus in the canal of Schlemm.

The *ciliary nerves*, after furnishing a gangliated plexus to the vessels of the choroid, enter the ciliary muscle, where they form another plexus. From this latter filaments pass into the iris, where they follow the course of the blood-vessels, finally ending in the sphincter iridis.

THE INNER OR NERVOUS TUNIC.

The **Retina** (Fig. 778) constitutes the innermost coat of the ocular wall. It is everywhere in close contact with the uveal tunic. Developmentally it is laid

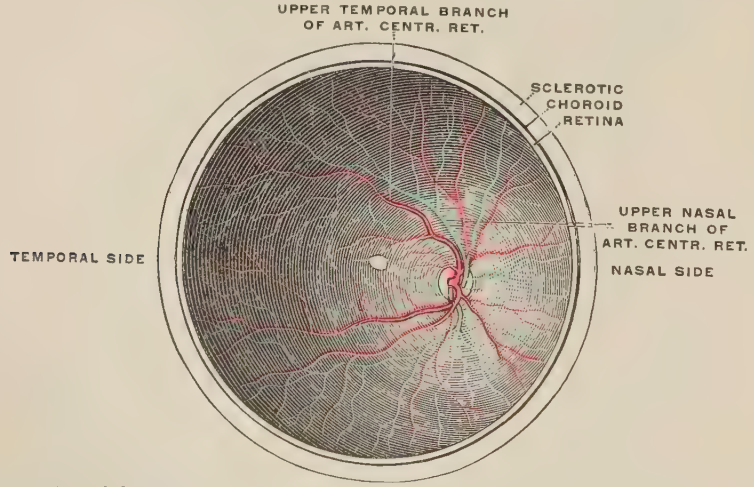

FIG. 778.—Retina of the right eye, front view. The macula lutea is seen in the middle, and the porus opticus at the right of it. (Testut.)

down in two strata, an outer pigmented stratum, which lines the inner surface of the middle coat, and an inner stratum, which differs in different parts.

Beneath the choroid is the *retina proper*, the part directly engaged in vision. It reaches from the optic entrance to the outer or posterior limit of the ciliary zone, where it terminates in an indented border, the *ora serrata*. Beyond this the inner stratum exists as a single layer of unpigmented, columnar epithelium, with no admixture of nerve-fibres, and is called the *pars ciliaris retinæ*. It reaches to and over the tips of the ciliary processes, whence it is continued as a pigmented layer, *pars iridica retinæ*, to the pupillary border of the iris. Here it doubles outward upon itself and becomes continuous with the outer pigmentary stratum. Thus there is on the hind surface of the iris a double layer of pigmented epithelium, belonging developmentally to the retina.

The inner surface of the retina proper rests upon the vitreous body. In its centre, and hence in the axis of the eyeball, is the *macula lutea* or *yellow spot*, the point of acutest vision. The *fovea centralis* is the name given to a dimple or depression in the middle of the macula lutea. About $\frac{1}{8}$ inch to the nasal side of the yellow spot is the pale disc of the *porus opticus* ("optic passage"). Here the optic nerve appears through the retina, and spreads out to form its innermost layer. From the centre of the porus opticus the *arteria centralis retinæ* emerges, dividing into an upper and a lower branch. These again divide and subdivide dichotomously giving offsets to the retina till they reach the ora serrata. Their ramifications anastomose neither with one another nor with any other vessels. The corresponding veins converge toward the porus opticus, where they enter the optic nerve in two divisions, which soon unite. Retinal vessels are absent near the macula lutea.

All these objects, but not the retina itself, are visible in an ophthalmoscopic view of the fundus of the eye. The veins appear darker and larger than the arteries. The general, red reflex which pervades the interior comes from the vessels of the chorio-capillaris.

The retina is a very complex membrane, consisting of several layers of nerve-cells, and specialized nerve-epithelium, all held together by sustentacular fibres (of Müller), which pass vertically through the layers from the inner almost to the outer surface.

The limits of this book preclude a detailed account of the structure of this interesting organ, but some idea of its complexity may be gathered from Fig. 779. What is definitely known and what may usefully be introduced here are embraced in the following statements:

1. The layer of rods and cones and the overlying pigmented cells are the only parts molecularly affected by light.

2. Except between the nerve-fibres of the innermost layer and the nerve-cells of the adjacent layer, there is no direct anatomical continuity between the elements of the different strata. An *apparent* exception occurs in the case of the outer nuclear layer; but it is only apparent, for here the granules are not separate elements, but swellings on the axis-cylinder processes of the rods and cones.

3. The retina with the optic nerve may practically be regarded as a nerve chain of three links establishing connection between the rods and cones (the special sensory cells of the retina) and the brain cells, from which the fibres of the optic nerve come off. These links are—

(1) The rods and cones with their axis-cylinders (including the outer granules).

(2) The bipolar cells of the inner nuclear layer with their axis-cylinders.

(3) The ganglionic nerve-cells and the optic nerve-fibres which, as before intimated, are in direct anatomical continuity.

4. The two molecular layers mark the situations at which connections are made between these nerve links. Thus, in the outer molecular layer the axis-cylinders of the rods and cones connect by arborization and interlacement with

cylinders of the rods and cones connect by arborization and interlacement with processes from the cells of the inner nuclear layer. In the inner molecular layer the processes from the opposite ends of the same cells connect similarly with those from the ganglionic cells. These being in direct continuity with the fibres of the optic nerve, are thus connected with cells of the visual centres in the brain.

5. The internal and external limiting membranes mark the inner and outer limits of the sustentacular fibres. They are not separate or independent structures, and the external, at least, is more imaginary than real as a membrane. The internal membrane is formed by contact of the expanded bases of the fibres of Müller.

6. All the layers become extremely thin over the fovea centralis, both the



FIG. 779.—Diagram of the retina, showing its layers. (Kallius.) I., pigmented epithelial layer; II., layer of the rods and cones; III., external limiting membrane; IV., outer granular layer; V., outer molecular layer; VI., inner granular layer; VII., inner molecular layer; VIII., ganglionic layer; IX., layer of nerve fibres. *z*, pigmented epithelial cells; *a*, at the bottom of the external limiting membrane, rods; *b*, cone cells; *c-n*, ganglion-cells of the sixth layer connecting the fourth layer with the eighth; *i*, horizontal cell sending a process into the seventh layer; *k-q*, "spongioblasts," or neurons of the third type; *rc*, ganglion-cells of the eighth layer; *x*, sustentacular cell of Müller, with striated upper end forming a part of the external limiting membrane; *y*, *y*, neuroglia cells. It should be borne in mind that in sections of the retina numerous elements of the various sorts here represented are crowded together to form a compact tissue. The centrifugal fibres which reach the retina from the cerebrum are omitted from this diagram. They are distributed in the inner granular or sixth layer. The light entering the eye passes through the layers represented in the lower part of this figure before it can affect the rods and cones. The internal limiting membrane, which separates the retina from the vitreous, is not represented.

layer of nerve-fibres on the inside and the rods on the outside being completely wanting. Around the border of the fovea they rapidly thicken, however, and over the rest of the macula lutea are thicker than anywhere else in the retina. At the ora serrata all the layers disappear abruptly, and only the layer of columnar epithelium before referred to takes their place in the pars ciliaris retinæ.

THE MEDIA.

As already stated, the vitreous body, the lens, and the aqueous humor completely fill the cavity of the eyeball. The aqueous is perfectly fluid, the vitreous semi-fluid, and the lens solid. All are transparent and colorless.

THE VITREOUS.

The *vitreous* ("glassy"), also called "vitreous humor" and "vitreous body" (Fig. 773), fills the posterior four-fifths of the globe. It is composed of gelatinous tissue (see page 50), and is enclosed in a thin, *hyaloid membrane*, which has some attachment to the retina at the porus opticus, and furnishes a suspensory ligament to the lens. Elsewhere it is perfectly separable from its surroundings. Through the centre of the vitreous body a canal lined by a tube of the hyaloid membrane, runs from the porus opticus to the back of the lens, where it ends blindly. It marks the course of a vessel, which, in the fœtus, passed from the central artery of the retina to the capsule of the lens. It is known as the *canal of Stilling*. Beyond the ora serrata the surface of the vitreous body is grooved by the ciliary processes, while, anteriorly, it presents a deep concavity, the *fossa patellaris*, for the posterior convexity of the lens.

Subjacent to the ciliary zone the hyaloid becomes thick and fibrous, and adheres closely to the pars ciliaris retinæ. Here it splits, giving off from its under surface the true hyaloid, which is continued over the fossa patellaris, while the outer fibrous portion, the *zonula of Zinn*, stretches inward and forward as a distinct membrane to gain attachment to the capsule of the lens a little in front of its equator. Some scattered bundles from the zonula are attached at the equator and some on the posterior surface also. The free portion of the zonula between the ciliary processes and the lens-capsule constitutes the *suspensory ligament* of the lens. A space around the circumference of the lens, bounded by the suspensory ligament in front and by the vitreous (covered by hyaloid) behind, is the *canal of Petit*. It is filled with fluid, which may reach it from the aqueous chamber through extremely fine clefts, which have been demonstrated in the suspensory ligament.

THE LENS.

The *lens* (Fig. 773) is a biconvex body occupying the fossa patellaris in front of the vitreous. Its anterior surface looks toward the aqueous chamber, and is in light contact with the pupillary margin of the iris. The circumference or equator all round looks toward the ciliary processes. In this position the lens is safely anchored by the suspensory ligament already described.

The posterior surface is considerably more curved than the anterior, and the curvature of each varies with the period of life. In the fœtus, the lens is almost spherical; in the adult, of medium convexity; and in the aged, considerably flattened. Besides this the curvature is constantly changing for near or distant accommodation.

The lens is inclosed in a structureless, elastic, non-vascular *capsule*, which is much thicker in front than behind. When ruptured or cut through, this membrane shows a tendency to curl outward away from the lens. The lenticular substance immediately beneath the capsule is soft and gelatinous, but deeper it becomes hard and firm. The central hard core is sometimes called the *nucleus* of the lens, while the outer soft part is known as the *cortex*.

THE AQUEOUS.

The *aqueous humor* is a watery fluid, occupying the space which is bounded by the cornea in front and by the lens, suspensory ligament and ciliary body behind. This space is known as the *aqueous chamber* (Fig. 773). The iris partially divides

it into an anterior and a posterior chamber, which, however, are continuous through the pupil. The aqueous humor is thought to be secreted in the posterior chamber, whence it finds its way through the pupil into the anterior chamber. From this it is drained away through the spaces of Fontana into the canal of Schlemm.

Although the vitreous, the aqueous, and the lens are commonly spoken of as the "refracting media" of the eye, it should be understood that of the three the lens alone has any considerable effect in changing the direction of the rays of light, which enter the eye, and furthermore, that the cornea, often referred to as if it had an indifferent influence in this regard, is really very powerfully refractive.

THE MUSCLES OF THE EYEBALL.

There are seven muscles (Fig. 780) in the cavity of the orbit, but only six are attached to the eyeball. These are arranged in three opposing pairs, viz., the *superior* and *inferior recti*, the *internal* and *external recti*, and the *superior* and *inferior obliqui*. All except the inferior oblique arise from the immediate vicinity of the optic foramen, either from the bone-surface or from an aponeurotic ring, the *ligament of Zinn*, which is attached around the upper, inner, and lower edges of the foramen, and bridges over the sphenoidal fissure. The external rectus is attached to this latter part, as well as to the bones on each side of the fissure. Hence the

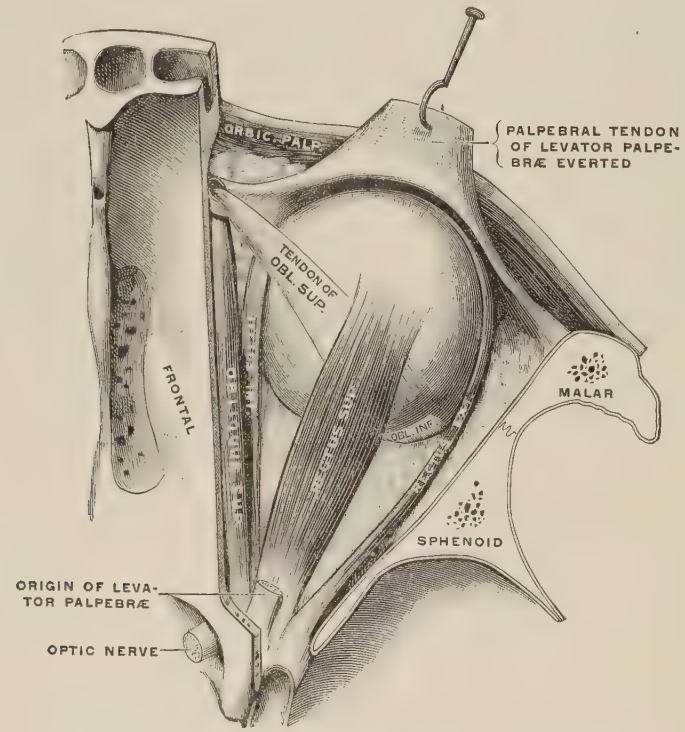

FIG. 780.—Muscles of right eye, viewed from above. (Testut.)

two heads, from which it is said to arise, are really continuous. The superior rectus has some attachment to bone above the foramen and to the sheath of the optic nerve, as well as to the aponeurotic ring referred to. The superior oblique arises wholly from bone beyond the ring and above the inner edge of the foramen.

Diverging as they come forward, the *four recti* go straight to their insertions into the sclerotic in front of the equator, and on the aspects of the eyeball corresponding to their names. The *superior oblique* courses upward, inward, and forward to the supero-internal angle of the orbit, where it passes through a fibro-

cartilaginous loop or pulley, attached to the orbital surface of the internal angular process of the frontal bone. It then bends back at an acute angle, and passes downward, backward, and outward beneath the superior rectus to its insertion in the sclerotic behind the equator, between the superior and external recti.

The *inferior oblique* arises from the orbital plate of the superior maxilla just outside the lower end of the lachrymal groove, whence it passes backward and outward beneath the inferior rectus (*i. e.*, between it and the orbital floor); then, turning slightly upward, it reaches its insertion into the sclerotic between the optic entrance and the attachment of the external rectus.

Action.—These muscles rotate the eye in different directions, but without changing its position in the orbit. Omitting refinements for the present, it may be stated that the superior and inferior recti rotate the eyeball on a transverse axis, thus raising and depressing the cornea; the internal and external recti rotate it on a vertical axis, thus turning the cornea inward and outward, *i. e.*, adducting and abducting it; and the superior and inferior obliques rotate it on a sagittal axis, thus turning the cornea round like a wheel on its axis.

Besides its main action, the superior rectus adducts and slightly rotates the cornea inward, and to correct this tendency is the special function of the inferior oblique. Again, the inferior rectus in addition to its main action, tends to adduct the cornea and rotate it outward; but the superior oblique opposes both these tendencies. What has been described as their main actions are the sole actions of the two lateral recti.

The *levator palpebræ superioris* ("lifter of the upper lid") may appropriately be described in this connection. It arises from the small wing of the sphenoid above the origin of the superior rectus, and passing forward close to the roof of the orbit, is inserted by a broad aponeurosis into the tarsus of the upper lid. It also sends a more superficial fibrous expansion forward among the fasciculi of the orbicularis palpebrarum, and this gains an attachment to the skin of the eyelid. Its action is to elevate the lid.

Nerve-supply.—The superior oblique is supplied by the fourth cranial nerve, the external rectus by the sixth, and all the rest by the third in two divisions. The superior division is given to the levator palpebræ and superior rectus; the inferior to the inferior and internal recti and the inferior oblique.

THE SUPERFICIAL APPENDAGES OF THE EYE.

Under this head come the eyelids, conjunctiva, and lachrymal apparatus.

The Eyelids.

The *eyelids* (*palpebræ*) are two loose, tegumentary folds, which when brought together, cover the front of the eyeball. The upper is larger and more movable than the lower, and takes by far the greater part in opening and closing the eye. About half an inch above its free margin a transverse wrinkle, the *superior palpebral fold*, divides it into an upper or *orbital portion* and a lower or *palpebral portion*. Over the former part the skin is extremely loose, and lends itself readily to subcutaneous hemorrhage and conditions of œdema. Over the lower part it is closely adherent to the subjacent tissue. There is an *inferior palpebral fold* in the skin of the lower lid, but it is not as well marked, unless the eye is widely open. The space between the free margins of the lids, the *palpebral aperture*, varies a good deal in different individuals, and even in the same individual according as the pupil is directed upward, downward, or straight forward. In the first position the space is greatest, in the second, least. The angles formed by the lids at their inner and outer ends are called the *canthi*, of which the outer is sharp, the inner rounded. The free margins of the lids are flat, and present an anterior rounded angle and a sharp posterior one in contact with the eyeball. Along the anterior angle project two or three rows of short, strong

hairs, the *cilia* or *eyelashes*, which curve away from the palpebral aperture. Behind these and nearer to the posterior angle are the openings of the ducts of the *Meibomian glands*, twenty or thirty in number and more numerous in the

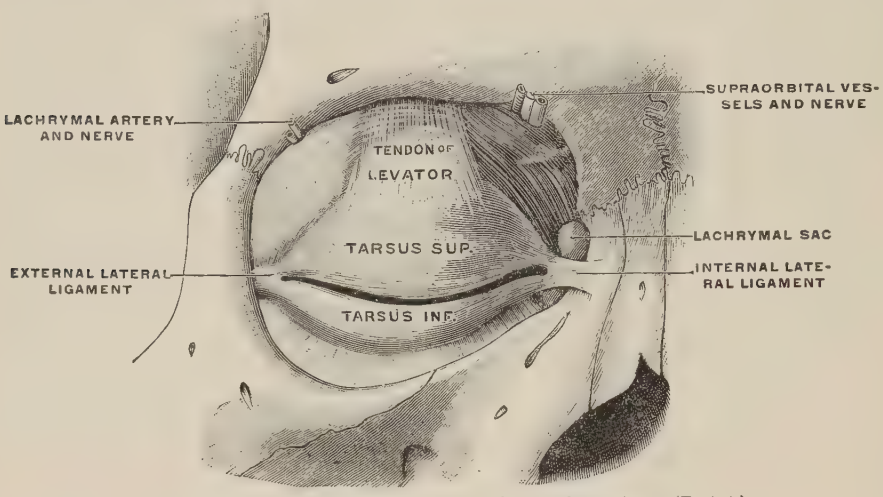

FIG. 781.—The tarsi and their ligaments—right eye, front view. (Testut.)

upper lid than in the lower. There are also modified sweat and sebaceous glands in this situation, the former being the glands of Moll.

For the first fifth inch out from the inner canthus the divergence of the lids is very gradual and then suddenly becomes more marked. Along this part the lids have no cilia and are not in contact with the eyeball. Nestling in between them in this situation, and resting against the globe of the eye, is a little fleshy protuberance, the *caruncula lachrymalis* ("the little fleshy body pertaining to tears"), which has all the characteristics of true skin, although quite isolated from the adjacent integument. The depression here between the lids, from the bottom of which the caruncle protrudes, is known as the *lacus lachrymalis* ("lake of tears").

Just at the points where the divergence of the lids becomes suddenly more pronounced a small prominence may be noticed on the margin of each lid. This is the *papilla lachrymalis*, and on its summit is the minute opening, *punctum lachrymale* of the *lachrymal canal*, leading into the *lachrymal sac*. The lower punctum is slightly farther out than the upper. The puncta are applied to the surface of the globe and are not seen unless the lids are slightly everted.

Structure of the Eyelids (Fig. 782).—On their superficial aspect the eyelids have a covering of *skin*, very thin and delicate, and containing fine hairs, sebaceous follicles, and sweat glands. On their posterior surface they are covered by a *mucous membrane*, called the *conjunctiva*, which, at a certain distance back from the free margin, is reflected onto the eyeball. Between these two coverings various other structures enter into the formation of the lid. Immediately beneath the skin is a layer of loose, fatless, *areolar tissue*, which provides for the laxity of the integument. Embedded in this tissue is the *orbicularis palpebrarum muscle*, the sphincter of the palpebral aperture, serving by its contraction to approximate the lids, and thus close the eye. Deeper than this is the *tarsus* (often, though improperly, called "tarsal cartilage") (Fig. 781), a thin plate of dense, fibrous tissue devoid of cartilage cells, which strengthens the margin of the lid, and stretches from the inner to the outer orbital wall. The upper tarsus is much stronger and thicker than the lower, and about twice as wide. Each tarsus is thickest at its free border and widest in the middle. They thin off toward the attached edges above and below, and taper toward the ends. Their attachments to the inner and outer orbital margins are known as the *inner*

and *outer palpebral ligaments.* The former, which is much the stronger and more marked, is often called the *tendo oculi.* It is attached to the nasal process of the superior maxilla in front of the lachrymal groove, and to the ridge on the lachrymal bone. Between these points it arches round the front and outer walls of the lachrymal sac. Where the two tarsi blend into this ligament it gives origin to the palpebral portion of the orbicularis muscle, and when this muscle contracts, closing the lids, it produces an enlargement of the cavity of the lachrymal sac thus causing it to suck in the tears from the lacus lachrymalis. To the upper edge

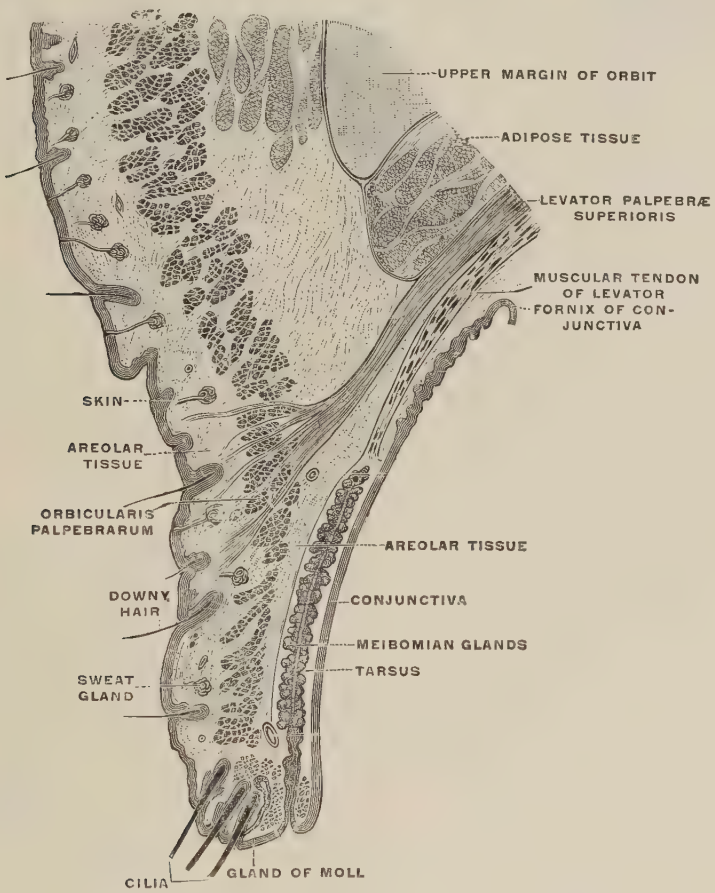

FIG. 782.—Upper lid in sagittal section. (After Merkel.)

of the superior tarsus is attached the wide tendon of the levator palpebræ, and to the lower edge of the inferior tarsus a fibrous expansion from the sheath of the inferior rectus. Embedded in the deep surface of each tarsus are the Meibomian glands, longer and more numerous in the upper lid than in the lower. On everting the eyelid they may be noticed as faint pearly lines running beneath the conjunctiva toward the free margin of the lid. They are a variety of sebaceous glands and their secretion prevents any adhesion between the lids, and keeps the tears from flowing over onto the face until considerably heaped up in the palpebral aperture.

The Conjunctiva.

The *conjunctiva* ("conjoined," because it unites the lids with the globe) (Fig. 783) is a mucous membrane, which, as before stated, lines the inner surface of the eyelids (*palpebral conjunctiva*) and is reflected from them onto the surface of the eyeball (*ocular conjunctiva*). The fold of reflection is the conjunctival

fornix. It is deeper in the upper than in the lower lid. To that part of the lid to which the skin is closely adherent on the outside the conjunctiva is equally adherent on the inside. Over the rest of the lid, and over the eyeball as far as the cornea it is comparatively loose. On the cornea it adheres firmly. The palpebral conjunctiva is thick, vascular, and highly sensitive. On the sclerotic the ocular conjunctiva becomes thin and transparent, and in the healthy condition is only slightly vascular. On the cornea it becomes reduced to a layer of stratified, flattened epithelium, several cells deep.

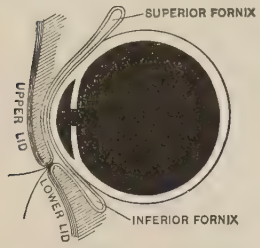

FIG. 783.—Sagittal section of eye, showing superior and inferior fornices of the conjunctiva. (Testut.)

Just outside the caruncula lachrymalis there is a semilunar fold of conjunctiva stretching between the lids with its concavity toward the cornea. This is the *plica semilunaris*, the rudimentary homologue of the membrana nictitans, or third eyelid, in birds.

The Lachrymal Apparatus.

The *lachrymal gland* (Fig. 784) is situated in the upper, outer, and anterior part of the orbital cavity, occupying a fossa in the orbital plate of the frontal bone at the inner side of the external angular process. It rests upon the upper and outer aspect of the eyeball (separated from it by conjunctiva) between the attachments of the superior and external recti. It consists of two portions, partially separated by a fibrous septum, an upper, larger part lying against the orbital roof, and a smaller, lower part, which reaches forward almost to the margin of the orbit, and outward as far as the external canthus. The ducts of the gland, seven or eight in number, open in a row on the upper and outer part of the palpebral conjunctiva near the fornix. The progressive closure from without inward of of the lids in winking disperses the lachrymal secretion over the whole surface of the eye, and tends to collect it in the lacus lachrymalis. Here it is sucked into the lachrymal canals through the puncta, which are applied closely to the surface of the eye, and is conveyed by them to the lachrymal sac, into which they open separately, or by a common tube. From this it is conveyed downward through the nasal duct into the inferior meatus of the nose, where it helps to moisten the inspired air.

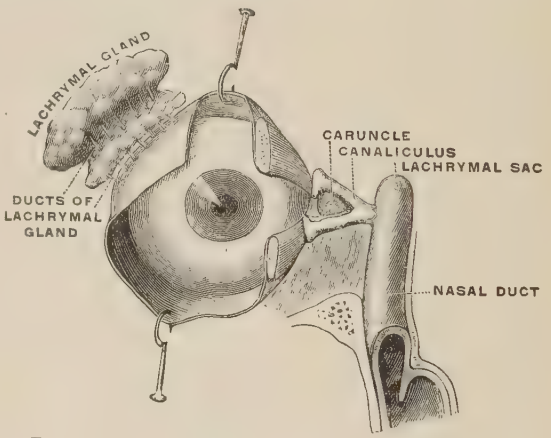

FIG. 784.—The lachrymal apparatus of the right eye. (Testut.)

The *lachrymal canals* are first vertical in direction in both lids, then horizontal and convergent inward—points to be remembered in attempts to pass a probe or bristle. The *lachrymal sac* is the upper enlarged end of the nasal duct. Its upper extremity is blind, and reaches higher than the openings of the canals. It is lodged in the groove formed by the lachrymal bone and superior maxilla, and is continuous below with the *nasal duct*. Both form a tube of mucous membrane, which is continuous with that of the nose below and with the conjunctiva above. The bony canal in which this tube lies is lined throughout by periosteum, between which and the mucous membrane there is a layer of areolar tissue. This is particularly abundant around the lachyrmal sac, thus allowing considerable distention of that organ.

THE ORGANS OF DIGESTION.

By F. H. GERRISH.

IN the lowest forms of animal life there is no differentiation of organs, each part of the body being equally capable of performing every kind of work within the sphere of the creature's possibilities. The little animal called *amœba* furnishes a good illustration of this fact. The whole creature may be regarded as a minute mass of living protoplasm. A particle of nutritious material coming in contact with the sensitive surface of an amœba is seized by little protrusions which are thrust out around it, and is presently enclosed completely by the prolongations. In the containing cavity thus formed the particle is held until the animal has absorbed all of the food which it can get from this source. Then the little projections which have enwrapped the nutrient material are withdrawn, the cavity which they formed is thus obliterated, and the residue of the bit of pabulum is released. Soon, it may be, the very portion of the amœba, which was just now a recess, becomes a protrusion, fastens to some fixed object, and by its contractile power pulls the bulk of the animal up to the point of attachment, itself becoming effaced in the process. Thus, it will be seen that a single portion of the creature's body can serve as an organ of sensation, an organ of prehension, an organ of absorption, and an organ of locomotion: feeling, grasping, abstracting, moving from place to place are all in turn shown to be capabilities of one small part, which in no way differs from every other part. Each of these organs was merely temporary: the impact-perceiving surface was transformed into seizing hands; these presently became a stomach; this soon turned into a leg; and the leg disappeared by flattening itself out into a sensitive surface, capable of appreciating the touch of a particle brought in contact with it.

Differentiation of Organs.—In animals a little higher in the scale of being a depression is seen at some point of the surface, forming a permanent recess, into which minute bits of pabulum are received and deprived of their nourishing material, after which process the unserviceable remnants are expelled by the door which gave them admission (Fig. 785). A step farther up we find the receptacle deeper, more capacious, and capable of effecting such changes in the food introduced into it as will make a larger proportion available for absorption into the system. In the next grade beyond this, the cavity becomes so long as nearly to reach the surface opposite to that at which its opening is located. One slight additional extension in the direction of previous growth results in perforation of the tissues intervening between the cavity and the surface; and, thus, the deep depression is converted into a tube, reaching from one end of the animal to the other, and permitting the expulsion of the unused portion of the food by an opening other than that by which it was introduced.

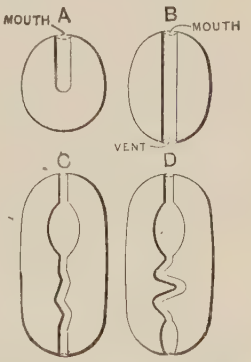

FIG. 785.—Diagram to illustrate the gradual development of the alimentary tube. (Testut.)

This tube, short and simple, is the type upon which is constructed every *alimentary canal*, however complicated. *Elaboration* of this structure is accomplished in several directions: (1) *by enlargement longitudinally*, so that the length of the canal becomes in some animals many times greater than that of a straight

line between its two extremities, thus furnishing an immensely more extensive surface, without corresponding increase in the size of the individual; (2) *by dilatation at various places*, and by the formation of transverse folds projecting into the bore, by which is gained not only augmentation of area, but also, what is of great advantage, temporary detention of the contents so that they may be modified in ways which would be impossible during their rapid passage; (3) *by the addition of certain structures* and materials to the walls of the tube, which thus can effect the comminution of introduced material, furnish solvent fluids of different kinds, and influence the acceleration or retardation of the current of the matters contained in the canal; (4) *by the development of accessory organs*, which, though originating as mere buds from the sides of the tube, grow and develop until they attain considerable —perhaps immense—size, and supply secretions of essential importance; and (5) *by the formation of a reservoir*, in which waste matters can be stored until it is convenient to void them.

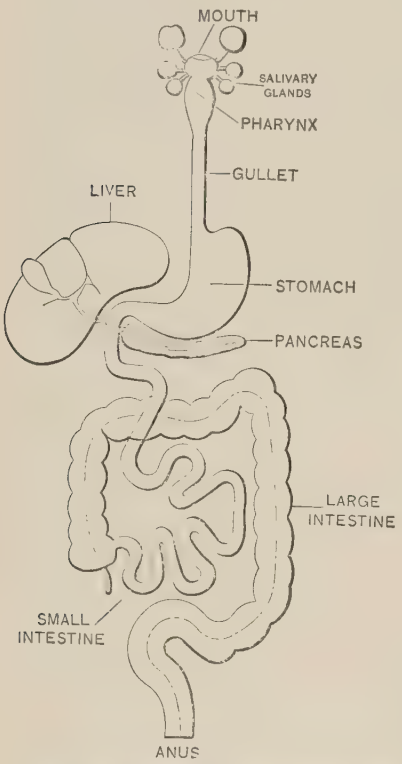

FIG. 786.—Diagram of the alimentary tube and its appendages. (Testut.)

The Human Alimentary System (Fig. 786).—These features are all illustrated in the human alimentary system. *The tube measures* thirty feet from the aperture of introduction, the mouth, to the opening of expulsion, the vent or anus; but the distance between these points in a direct line is not more than the same number of inches. Connected with the initial segment of the canal is *an apparatus, which minces and crushes* hard masses of aliment, thus prodigiously increasing the surface of the matters to be acted upon by the solvent fluids, and, consequently, expediting the liquefactive process. *The lining membrane* of the entire tube is of the mucous variety; but it does much more, in the greater part of its course, than furnish a protective smear, for it is so modified by the formation in its very substance of a numberless *multitude of peculiar glands*, that it affords various juices, by whose agency important changes in the preparation of food for absorption are brought about. From one end of the canal to the other its walls contain *muscle*, which by its contraction carries the contents onward with sufficient speed. A short distance from its beginning the tube expands into a *large cavity*, the stomach, which delays the swallowed food, as a pond in the course of a river causes a diminution in the rapidity of the current. Throughout the most of the remainder of the canal we find *little shelves*, extending into the lumen from the sides, and causing at once increase of surface and retardation of the stream. There are also *glands* —the salivary, the pancreas, the liver—which, although entirely outside of the limits of the alimentary tube in their developed condition, originate from it, discharge their peculiar products into it, and are thus accessory in their action to the glands which make a part of the walls of the canal itself. Finally, the last great segment is so constructed that it acts as a *receptacle* in which unappropriated parts of the food and certain effete substances from the system can be retained until the arrival of suitable times for their evacuation.

Segments of the Alimentary Tube.—The alimentary canal is naturally divided into a number of segments, which occur in the following order, beginning at the

upper end: mouth, pharynx, gullet, stomach, small intestine, large intestine, anal canal. It is usual to reckon the anal canal as a part of the large intestine; but, later in this chapter, it will be seen that there is good reason for giving it a place as a separate segment, since it should be regarded as a tubular passage rather than as a mere opening. The small and large intestines are popularly called *bowels*.

Tunics of the Alimentary Canal.—Every portion of the inner surface of the canal is covered by *mucous membrane*, with the exception presented by the crowns of the teeth. Even this, to the philosophical anatomist, does not seem an exception; for he recalls the fact that the teeth, though so dense and white as to afford a very striking contrast to the soft and reddish membrane from which they project, are epithelial in their mode of development, and that the glistening, dry enamel, which encrusts their crowns, is strictly and wholly epithelium, originally like that which surmounts the dull and moist mucosa. Outside of this inner, mucous tunic is one of *areolar tissue*, almost everywhere very distinct, but, in a few places of no great extent, very condensed. Still another coat is found external to the areolar, the *muscular*, usually arranged in two layers, an internal, whose fibres are circular in direction, and an external, in which they run longitudinally. Finally, in that portion of the canal, which lies below the diaphragm, there is almost everywhere a fourth tunic, composed of *serous membrane*.

The Service of each Tunic.—Calling to mind the character and functions of these various membranes and tissues, as described in the chapter on histology, we shall quickly obtain a general idea of the physiological capabilities of the tube whose wall they compose.

Mucous membrane is a soft, moist structure, secreting a glairy fluid, which serves to smear the surface, and thus at once prevents its becoming dry, and protects from the injury which the contact of foreign substances might otherwise occasion. In the larger part of the alimentary canal the membrane contains great numbers of small, tubular glands, which, instead of secreting mucus alone, as is the case with the corresponding structures in the respiratory tubes, the urinary bladder, and other organs, manufacture different fluids, possessed of such qualities that they can effect important changes in food which is taken, and put it in condition to undergo absorption into the blood and incorporation into the tissues of the body. Mucosa is not an elastic structure: it will bear very little stretching without harm. But we find that, where it lines hollow organs, which are liable to become distended, it is, at almost every part of the surface, so loose in the collapsed condition of the viscus that it is deeply wrinkled, and lies in well-marked folds. When the cavity is filled, these loose ridges are smoothed out and disappear, and the mucosa is evenly spread, but not rendered tense; and, thus, it suffers no harm.

This passive movement of the membrane would not be practicable except for the *areolar coat*, which connects it with the muscular. Areolar tissue is strong, flexible, elastic, and full of spaces in the meshes of its network. It, therefore, holds the mucosa firmly but gently in place at all times, regulating its wrinkling so that its folds are evenly distributed, and permitting its extension without displacement from its proper relation to the muscular coat.

The areolar coat affords an easy and safe bed for the vessels and nerves, whose twigs, and rootlets, and filaments form networks throughout the two tunics, between which this coat is situated.

The *muscular coat* is that by which active movements of the tube are produced. Its tissue is nearly all of the involuntary variety. Its movements are mostly of a vermicular kind, and serve to carry the contents of the canal from the upper to the lower end.

The *serous membrane* clothes the tube in its abdominal portion—that in which there is the largest variation in the size of the organs, the greatest necessity for activity of movement, and the most frequent liability to pressure from without. But all of these things—distention, contraction, peristalsis, compression—can take place without making trouble, for the organs have so slippery an outer sur-

face that they glide freely on one another during the less movements, and slide elusively out of the way of extraneous force.

Gas in the Alimentary Tube.—The tube in the larger part of its course generally contains more or less gas, which, by keeping the opposite walls somewhat separated from each other, prevents the injury which would probably come from the prolonged rubbing together of these soft and delicate surfaces. In some regions, however, as in the gullet, the opposite surfaces of the membrane are in contact nearly all of the time; but in these cases the structure is very different from that in the stomach and intestines, especially as regards the epithelium, which, instead of being tender and in a single lamina, as in the latter organs, is hard and stratified, and capable of withstanding the influence of incessant pressure and friction.

THE MOUTH.

The mouth (*os*) (Fig. 787) is the organ in which are accomplished wholly or in part the functions of prehension, mastication, insalivation, gustatory sensation, and articulation.

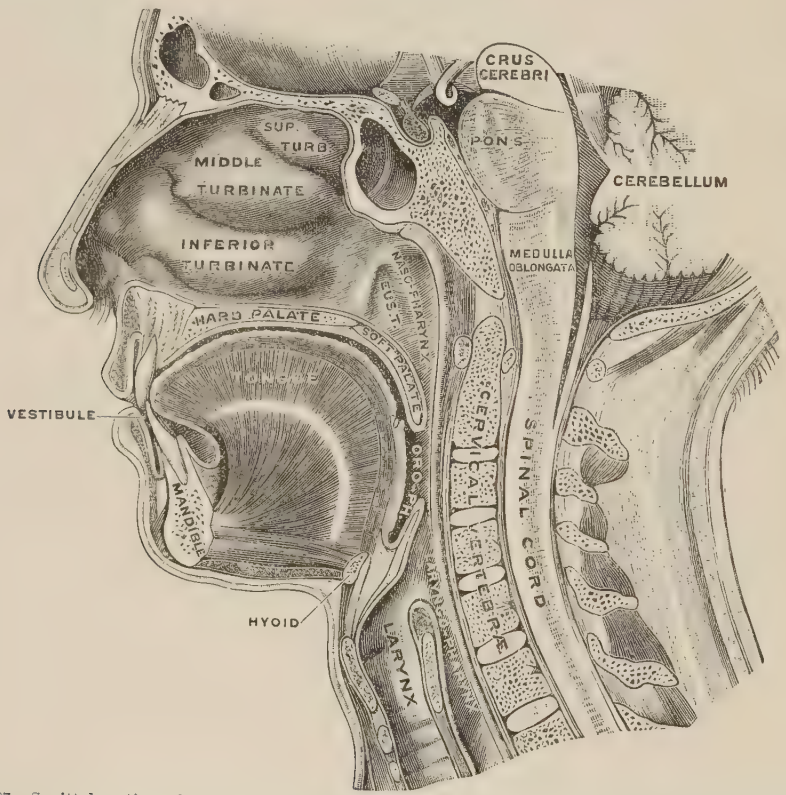

FIG. 787.—Sagittal section of the face and neck, showing the first portions of the alimentary and respiratory tracts. (Testut.)

Its name is applied popularly not only to the cavity in the face, which constitutes the initial segment of the alimentary canal, but also to the aperture of entrance and to the lips; but anatomists use it only in the first sense. It is not always an actual cavity—a fact demonstrated in sagittal frozen sections, in which commonly its floor and roof are in contact, and its side walls hug the dental arches. Between this merely potential cavity and that of wide expansion is a great distance, within which are countless variations in shape; but the mouth may conventionally be regarded as a rather oval, horizontal slit, presenting marked irregularities of size and form. Its virtual cavity is made real by separation of

the lips or cheeks from the teeth, by the flattening of the tongue, or by the depression of the lower jaw. The oral space is divided by the apposed dental arches into the vestibule and the mouth proper. The former, *vestibulum oris*, has in front the lips, at the sides the cheeks, and its opposite boundaries are made by the outer surface of the gums and teeth; the latter, *cavum oris*, is bounded above by the hard palate, below by the tongue and the sublingual space, in front and at the sides by the inner surface of the gums and teeth, and behind by the soft palate and the aperture beneath it by which the mouth opens into the pharynx. The two portions communicate with one another by the gaps between the teeth and by the considerable space behind the last molar teeth.

The Lips.

The lips (*labia*), upper and lower, are musculo-membranous folds, enclosing the transverse slit which is the front aperture of the mouth. Each is attached to a jaw-bone just beyond the base of the alveolar process. The external limits have been given on page 23. From before backward they are composed of skin, muscle, areolar tissue containing glands, and mucous membrane, the last forming the free border as well as the lining. The skin, adherent to the muscle, presents no especial peculiarities, except the growth of strong hairs in the adult male. The muscular layer is mostly formed by the orbicularis oris, into which other muscles from various regions of the face are inserted. The areolar lamina is occupied by an almost continuous layer of racemose *glands*, called *labial*, which are practically identical in structure with the salivary glands. The mucous membrane is smooth and moist, and is reflected from the lips to the gums. A fold of it in the middle line at the junction with the gums forms a bridle, *frænum labii*, for each lip. On its free border the lip is abundantly supplied with papillæ. Everywhere its epithelium is flattened and stratified.

The Cheeks.

The surface-limits of the cheek have been detailed on page 23. A considerable part of its surface is attached to the bones of the face; only the central portion is free, and clothed with mucous membrane, this being continuous with that of the lips, and, like it reflected to the gums. Five layers go to compose the cheek: skin, areolar tissue, deep fascia, muscle, and mucosa. The skin is continuous with that of the lips, and in the adult male is, to a large extent, covered with strong hairs. The areolar tissue is usually laden with fat-cells, these being most numerous in children and young women, and least abundant in the aged. The next layer is formed by the fasciæ of the masseter and buccinator, which muscles constitute a large part of the fourth lamina. The mucous membrane, continued from that of the lips, is similar to it, but there is no glandular layer connected with it, as in the labial region. There are, however, a number of *mucous glands*, called *buccal* and *molar*, on the outer surface of the buccinator, each of which sends its excretory duct through the mucous membrane, and pours its fluid into the mouth. Here, too, the mucosa is perforated by the duct from the parotid gland.

The Hard Palate.

The hard palate (*palatum durum*) forms the roof of the mouth. Its basis is made by the palate processes of the upper jaw-bones and the horizontal plates of the palate bones, which, immovably united and bordered in front and laterally by the drooping alveolar process, make a flattened vault of horse-shoe shape. Mucous membrane, smooth, tough, and continuous with that of the gums, lines the roof, being closely adherent to the periosteum at the alveolar margin and mid line; but, where such attachment does not exist, there is a compact layer of racemose glands, called *palatine glands*, resembling the salivary, and embedded in areolar tissue, which hugs the periosteum. Each of these glands sends its duct through

the mucosa, so that the latter is plentifully dotted with their minute openings. The surface is roughened, especially in front, with low, obliquely transverse ridges, has numerous small papillæ, and displays a median raphé, at whose anterior end is a tubercle, which marks the inferior orifice of the anterior palatine canal.

The Soft Palate (Fig. 788).

Attached to the hind border of the hard palate, and drooping obliquely backward from it with perfect continuity of surface, is the soft palate (*palatum molle*), also called the *velum pendulum palati* ("pendulous veil of the palate"), which extends from side to side, and terminates below in an arched border, from the centre of which dangles a teat-like process, the *uvula* ("little grape"). From the base of the uvula on each side the lower edge of the velum is, as it were, split, one part going outward, downward, and forward to the side of the tongue, the other outward, downward and backward to the side of the pharynx, leaving between them on the side wall of the region a triangular recess with its base toward the tongue. The former ridge is the *anterior pillar of the palate*, the latter the *posterior pillar*. The irregular opening bounded by the anterior pillars and the dorsum of the tongue is the *isthmus of the fauces*, the aperture by which the mouth communicates with the pharynx. The front (antero-inferior) surface, therefore, of the velum marks the posterior limit of the mouth, and all of the cavity behind this plane belongs to the pharynx. The free edges of the posterior pillars are nearer together than are those of the anterior pair, and hence both sets are seen distinctly, if the mouth is widely opened, and the tongue depressed.

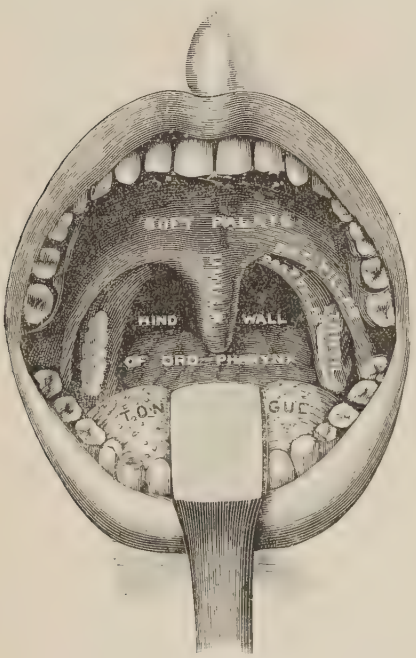

FIG. 788.—The soft palate and tonsillar regions. (Testut.)

Structure of the Soft Palate.—The soft palate is built upon a fibrous framework, which hangs down from the hind border of the hard palate. Into this are inserted various muscles, which constitute the bulk of the organ. Mucous membrane covers every part of it, that visible from in front being like the buccal, smooth, rosy, covered with stratified, flattened epithelium, while that on the opposite surface resembles the nasal mucous membrane, being uneven, red, and clothed with ciliated, cylindrical epithelium, except at its lowest part, where the cells are like those in front. Beneath the mucosa are many glands, the majority being on the oral side, and continuous with those of the hard palate.

During swallowing the veil is lifted backward to the hind wall of the pharynx; but in suction it is drawn down to the tongue. In articulation it is made to assume every attitude between these extremes.

Muscles of the Soft Palate.

The muscles of the soft palate are the palatopharyngeus, palatoglossus, levator palati, tensor palati, and azygos uvulæ.

Palatopharyngeus (Fig. 789) ("the palate-pharynx muscle").—*Situation*, at the side and back of the soft palate. *Origin*, in the velum, embracing the levator palati and azygos uvulæ. *Direction*, downward, outward, and back-

ward. *Insertion,* the upper and hind borders of the thyroid cartilage (mingling with the stylo-pharyngeus), and the lower part of the pharynx, extending to the middle line. *Action*: the pair lifts the larynx and the tongue, pulls down the velum, and approximates the posterior pillars, shutting off the oro-pharynx from the naso-pharynx. *Nerve,* probably from the eleventh cranial through the pharyngeal plexus. Covered by mucous membrane, it forms the posterior pillar of the soft palate. This is joined by a fasciculus arising from the cartilage of the Eustachian tube, which has been described as a separate muscle, under the name of the *salpingo-pharyngeus*—the first part of the title referring to the trumpet-shape of the end of the tube.

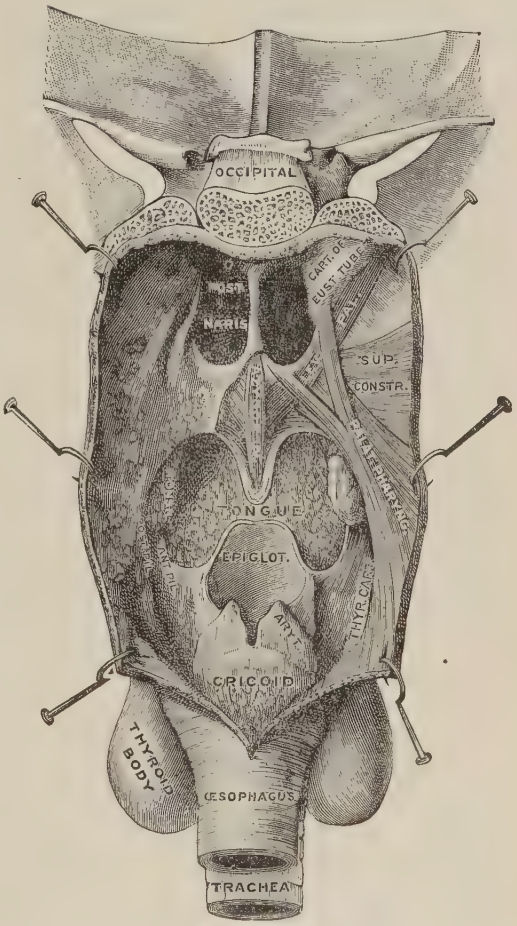

FIG. 789.—Muscles of the soft palate, viewed from behind. The dorsal wall of the pharynx has been laid open. (Testut.)

Palatoglossus (Fig. 801) ("the palate-tongue muscle").—*Synonym,* constrictor isthmi faucium, "the constrictor of the isthmus of the fauces." *Situation,* at the side and front of the soft palate. *Origin,* in the velum, being continuous with its opposite fellow. *Direction,* downward, outward, and forward. *Insertion,* at the side of the tongue. *Action*: it lifts the tongue, pulls down the velum, and approximates the anterior pillars, closing the pharynx from the mouth. *Nerve,* probably from the eleventh cranial through the pharyngeal plexus. Covered by mucous membrane, it forms the anterior pillar of the soft palate.

Levator Palati (Fig. 789) ("the lifter of the palate").—*Situation,* in the upper part of the velum. *Origin,* the under surface of the petrous portion of the temporal bone, in front of the carotid canal. *Direction,* downward, inward, and forward. *Insertion*: it blends with its opposite fellow. *Action,* lifting the velum. *Nerve,* probably the spinal accessory, through the pharyngeal plexus.

Tensor Palati ("the tightener of the palate").—*Synonym,* circumflexus, "the muscle which bends around." *Situation,* in the velum. *Origin,* the root of the internal pterygoid plate, the spine of the sphenoid, the Eustachian tube. *Direction,* downward to the hamular process, then inward. *Insertion,* the middle of the soft palate, and the under surface of the palate bone. *Action,* tightening the velum. *Nerve,* the third division of the fifth.

Azygos Uvulæ (Fig. 789) ("the unyoked (not-paired) muscle of the uvula," —a misnomer, as there are two muscles).—*Situation,* in the soft palate, close to the mid-line. *Origin,* the posterior nasal spine. *Direction,* downward. The muscles of the two sides unite below, and terminate in a free, dangling end, making the bulk of the uvula. *Action,* shortening the uvula. *Nerve,* probably the spinal accessory, through the pharyngeal plexus.

THE TEETH.

The teeth are dense, white structures, firmly implanted in sockets in the alveolar processes of the jaw-bones. They are essential parts of the chewing-apparatus, and are concerned in articulation. Each consists of three portions—a root or fang, a neck, and a crown. The surface toward the tongue is called "inner" or "lingual," and the opposite one is called "outer" or "labial" when in the lip-region, "buccal" when in the cheek-region.

FIG. 790.—The teeth of the right half of the upper jaw in their sockets, viewed from below.

The *root* is embedded in the bone, has a tapering shape, and fits accurately in its socket—an arrangement which ensures a distribution of pressure over the surface, and the removal of pressure from the tip of the fang, where the vessels and nerves pass to and from the tooth-cavity. The socket (alveolus) is lined with periosteum, here called *pericementum*, from its close attachment to the cementum, which forms the outer layer of the root. The *crown* is the portion which projects beyond the gum. The *neck* is a narrow strip between the fang and crown, is slightly, if at all, constricted, and is embraced by the border of the gum.

A tooth is composed principally of dentine, enclosing a cavity, in which is the *pulp*. The pulp is made up of vessels, nerves, and cells, supported on an areolar framework. The pulp-

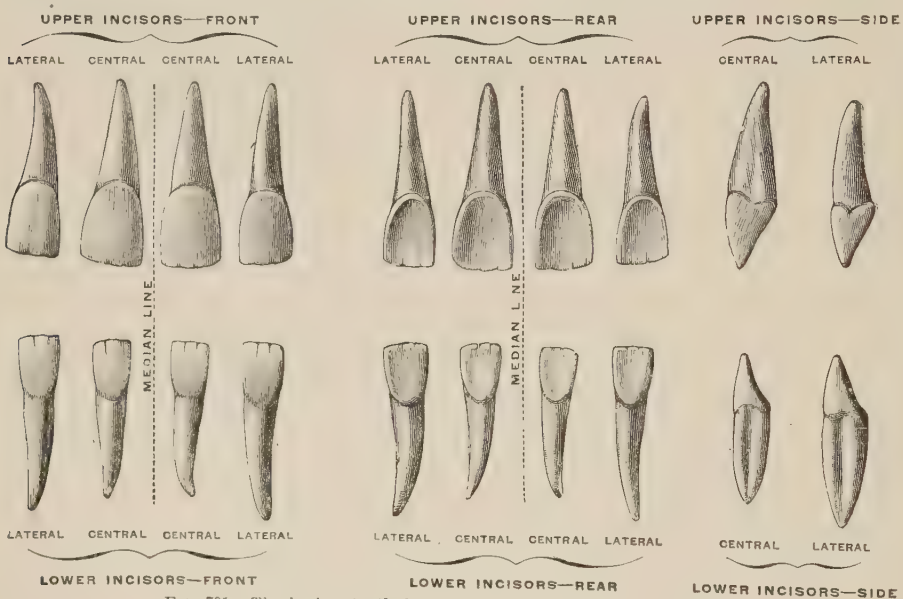

FIG. 791.—The incisor teeth from different points of view. (Testut.)

cavity is lined by a layer of odontoblasts, and it has an opening at the apex of the root, through which the vessels and nerves pass. The crown has an external layer of *enamel*, composed of stratified, columnar epithelium, the cells of which are calcified, and constitute the hardest material in the body. The root has an external lamina of osseous tissue, the *cementum*.

In each jaw are sixteen teeth, arranged with bilateral symmetry, and all set obliquely, except the two nearest the middle line in the mandible. Classifying them according to their shape, and reckoning from the median line, we find in each lateral half of each jaw two incisors, one canine, two bicuspids, and three molars (Fig. 790).

The **Incisors** (Fig. 791) ("cutters") are the teeth by which portions of food are bitten off. The root of an incisor is a long cone; its crown presents an anterior, slightly convex surface, and a posterior, slightly concave surface, the two meeting in a sharp free edge. The central incisors (those nearest the mid-line) of the upper set are larger than the lateral; but the central incisors of the lower jaw are smaller than their laterals, indeed, the smallest of all.

The **Canine** (Fig. 792), so called from its prominence in animals of the dog-tribe, has a fang longer than that of an incisor, and so large as to cause a marked ridge on the surface of the bone. Its crown terminates in a sharp point, technically a *cusp*, from which comes the name, "cuspidate," occasionally employed. An upper canine, larger than the lower, is vulgarly called an *eye-tooth*, and a lower a *stomach-tooth*, each from the direction of its fang.

A **Bicuspid** (Fig. 793), as its name implies, has two prominences or cusps on its crown, an outer (buccal), and an inner (lingual). From its situation in front of the next group it is also called *premolar*. Its root shows an attempt at division.

Molars ("millstones") (Figs. 794, 795) are thus named from their being concerned in grinding the food, and are also called *multicuspids* from their having three or more cusps on their summits, *double teeth* from their size, and *jaw-teeth* from the room which they occupy. In the upper set the molars have three fangs each, one lingual, and two buccal; their mates in the lower have but two each, one in front of the other. The third molar is, with fine irony, called the *wisdom-tooth*, because it does not appear until the late teens. Its fangs are frequently blended into one. The absence of this tooth about once in eight times, and its crowded condition in many cases, when present, point to the gradual lessening of the size of the jaws in proportion to the diminution of the work required of them in civilized life.

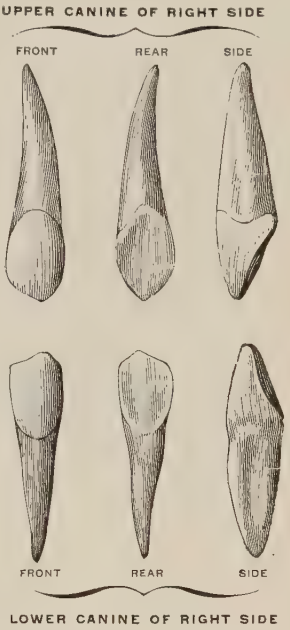

FIG. 792.—The canine teeth from different points of view. (Testut.)

Excepting the last upper molar and the lower central incisor, *each tooth touches two in the opposite set*, when the jaws are closed (Fig. 796). The upper dental arch is a little larger than its fellow, and overlaps it in front, so that the cutting edge of the superior incisors glides downward on the anterior surface of the lower, as one blade of a pair of scissors acts upon the other.

Sets of Teeth.

The teeth grow in two series, the one in infancy, the other in childhood and youth. The former are displaced by the latter, and, therefore, are named *temporary*, or *first teeth*. They are also called *deciduous*, because they are shed, and *milk-teeth* on account of their development during the period of lactation. Those of the later set are called *permanent*, or *second* teeth, and it is they which have just been described (Fig. 797).

The **Temporary Teeth** are twenty in number, there being five in each lateral half of each jaw, namely two incisors, one canine, and two molars. It will be observed that there are no bicuspids, and no third molar. The bicuspids of the permanent set take the place of the temporary molars, and the jaw grows sufficiently to give room for the permanent molars, which are the successors of no other teeth.

Eruption of the Teeth.—The temporary teeth usually begin to appear when the baby is about seven months old, and he has his full score by the time that he is two years of age. Before any of the milk-teeth are shed, the first grinders of the second set are fully developed. They are called the *six-year molars* in cele-

bration of the time of their advent. The others of the series consume a dozen years in their "cutting," as their protrusion through the gum is commonly called.

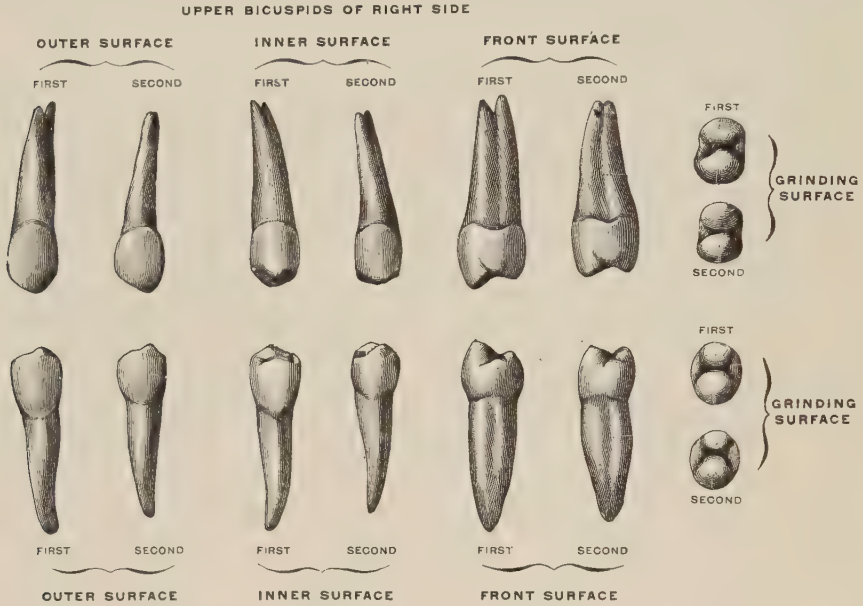

FIG. 793.—The bicuspid teeth from different points of view. (Testut.)

There are so many exceptions to any rule, which states the precise date of appearance of the teeth, that it is well nigh useless to present such a formula.

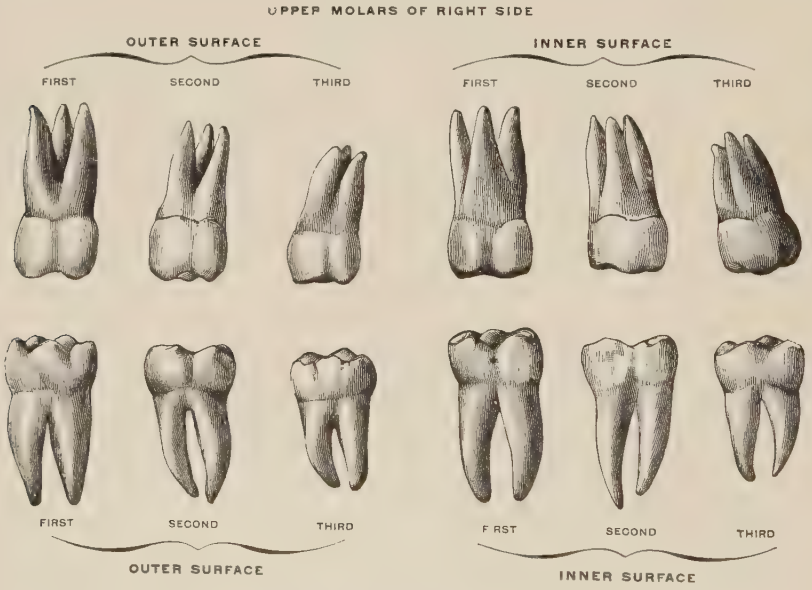

FIG. 794.—The molar teeth viewed from the outer and inner sides. (Testut.)

But it is desirable to know the order in which they may be expected, and this is presented in Fig. 797. The diagram also gives the position in the dental arch of the teeth of each set and shows what kind of permanent tooth succeeds each temporary tooth. It is to be noted, however, that the permanent teeth appear in

the jaw on the lingual side of the temporary, and not, as might be inferred from this diagram, on the labio-buccal side. The lower tooth of a given kind usually is cut just before its mate above appears.

Method of Displacement of Temporary Teeth.—The temporary teeth are replaced by the permanent in the following manner: the tooth which is to succeed the deciduous tooth is pushed upward by the continual growth of the dentine of its fang. Its enamel is crowded against the root of the milk-tooth, cuts off its nutrition, and, by the incessant pressure of its dense substance upon the less hard materials composing the root of the tooth above, causes the latter to dwindle away, particle by particle, the molecules disappearing by absorption, until all of

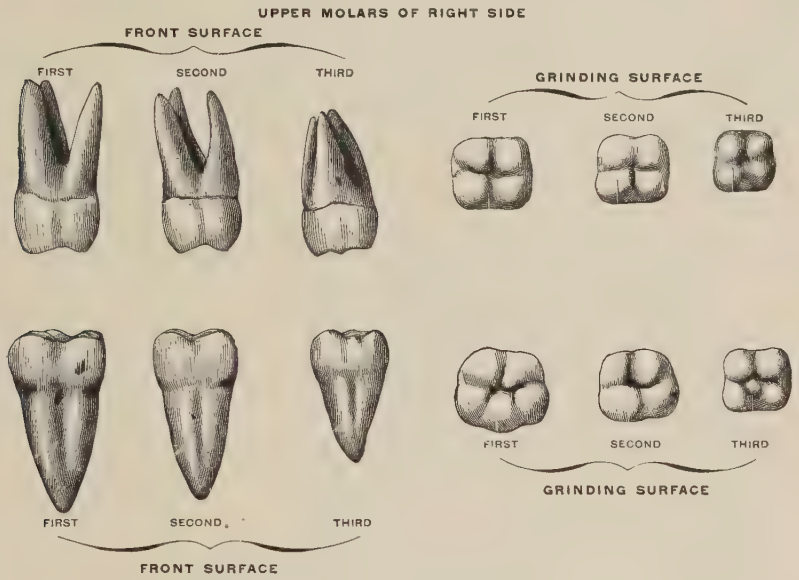

FIG. 795.—The molar teeth—their front and grinding surfaces. (Testut.)

the root has vanished, and the only support of the crown is that afforded by the adhesion of the gum to the neck. Then the crown is knocked off by some slight force, and in its place appears that of its permanent successor. When the permanent tooth is not aimed accurately at the root of the temporary, but shoots by it, the latter remains undisturbed.

Morphological Character of a Tooth.—A tooth, though intimately connected

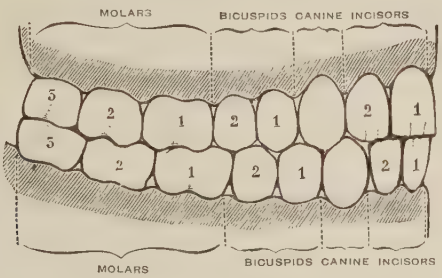

FIG. 796.—Diagram of the dental arches, seen from the right side, showing their reciprocal relations. (Testut.)

with the bony skeleton, is really a calcified papilla of the mucous membrane. A portion of the alveolar process grows around its base, and furnishes a snug socket for it; but, in spite of its density and the solidity of its implantation, it is comparable with other papillæ, such as that of a hair-follicle. The changes in the

epithelium of the hair-papilla are unlike those which take place in that of the tooth-papilla, and, consequently, the result is very different, although in both cases the modification is in the direction of hardening; but, philosophically con-

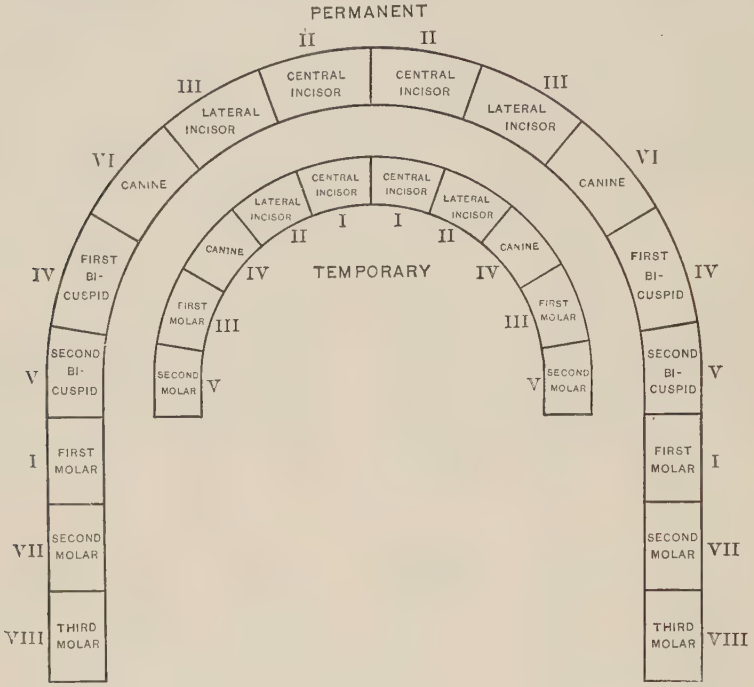

FIG. 797.—Diagram showing what permanent tooth replaces each temporary tooth, and also the order of succession of the teeth of each set. (F. H. G.)

sidered, the hair and the teeth are closely related, as will be seen, if one studies the development of the two.

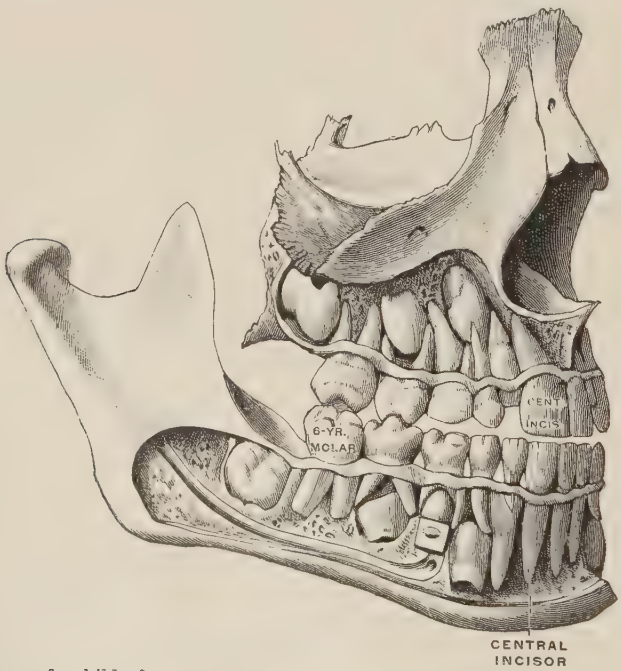

FIG. 798.—The jaws of a child of seven and a half years, the external table of bone having been cut away to show the stage of second dentition. (Testut.)

Just before the six-year molars are erupted from the gum, forty-eight teeth in various stages of formation and retrogression can be recognized in the two jaws —twenty of the temporary set, and twenty-eight of the permanent. The four wisdom-teeth at this time are only embryonic buds (Fig. 798).

The Gums.

The gums (*gingivæ*) are dense, smooth mucous membrane, fused upon the periosteum of the alveolar processes. They are very resistant to pressure, and have comparatively slight sensitiveness.

The floor of the mouth is formed mainly by the tongue, in small part by the sublingual structures.

THE TONGUE.

The tongue (*lingua*) (Fig. 799) is composed mostly of voluntary muscles, which give it protean power of changing its shape. Its upper surface can be convexed or concaved; its point can be thrust forward beyond the lips, drawn backward nearly or quite to the junction of the hard and soft palates, swept over the entire surface of the vestibule above and below; in short, the free portion of this organ can be made to assume such a multitude of forms as to defy description. This capacity accounts for its varied usefulness in the processes of prehension, chewing, swallowing, speech, touch, taste, and expression.

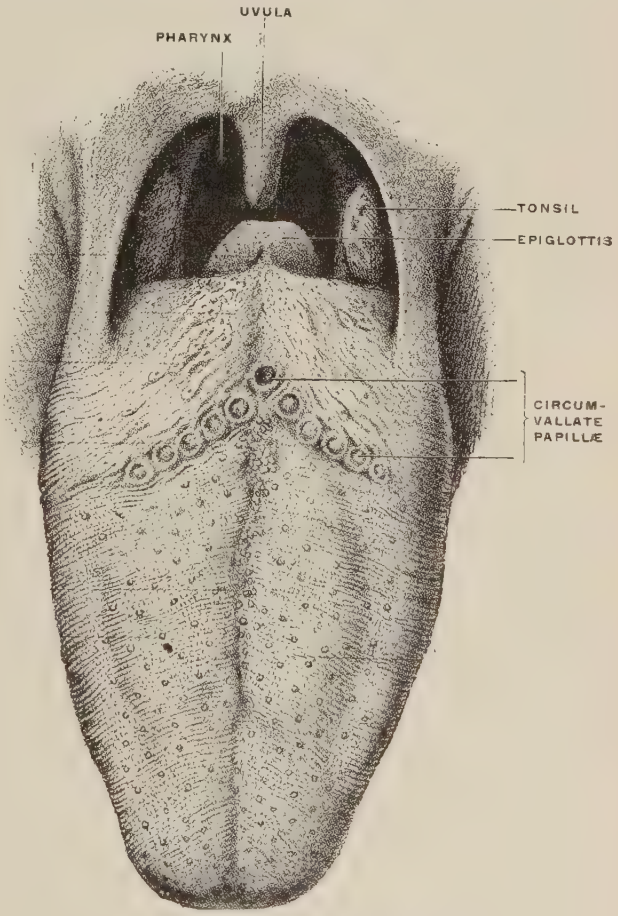

FIG. 799.—Dorsal surface of the tongue. (Testut.)

The part of the tongue which presents a free surface upward and backward is called the *dorsum*. The anterior two-thirds of this is in the floor of the mouth, the posterior third in the front wall of the pharynx. The pharyngeal part of the dorsum forms the very sloping floor of the space marked off on each side by the two pillars of the soft palate. It has a mammillated appearance, caused by the presence of numerous racemose glands and lymphoid masses. Just behind the apex of the series of circumvallate papillæ (described on a previous page) is a little aperture, the *foramen cæcum* ("blind hole"), the remnant of the duct of the thyroid gland in the fœtus. At the lowest part of the pharyngeal surface the mucosa is raised into three sagittal folds connecting the tongue with the larynx, the central one being the largest, and inserted into the upper surface of the epiglottis. The oral portion of the dorsum, when entirely

at rest, is convex in every direction. It ends anteriorly in a somewhat pointed *tip*. Its mucosa is specialized, and has been described in the chapter on the organs of the special senses.

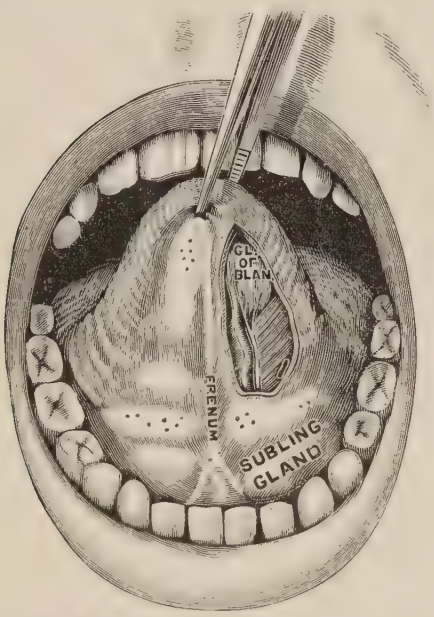

FIG. 800.—Under surface of tongue and the sublingual space, showing openings of salivary ducts. The mucosa of the left side is partly removed, and shows the ranine artery, the lingual nerve, and the gland of Blandin. (Testut.)

The Sublingual Space (Fig. 800).—Lifting up the tip of the tongue we obtain a view of the sublingual space. We see that the mucous membrane of the under side of the tongue is smooth, and not furnished with such specialized papillæ as mark the upper surface. A fore-and-aft fold, the *frænum linguæ* ("bridle of the tongue"), in the mid line, connecting the tongue with the jaw, limits the backward movements of the apex. On each side of this bridle opens a duct from the submaxillary salivary gland. The sublingual salivary gland forms an elongated elevation in the gutter between the tongue and the jaw on each side, and its many ducts open upon the overlying mucosa. Beneath the rest of the mucous membrane in this space are various lingual muscles.

Structure of the Tongue.—As previously stated the tongue is made up largely of muscles. These are arranged in pairs with bilateral symmetry, and when we speak of the action of a given muscle, we shall imply the simultaneous contraction of its fellow of the opposite side.

Mingled with the muscles of the tongue are fibrous, and adipose tissues, and many vessels and nerves. Its framework consists of a vertical, median, fibrous plate, extending from the hyoid bone to the tip of the tongue, and a fibrous lamina near the surface of the dorsum and edges in each lateral half.

The muscular part of the tongue comprises two groups—the intrinsic and the extrinsic muscles. The distinction between them is somewhat arbitrary. If the connections of the tongue with the hyoid bone, the styloid process of the temporal, the mandible, the velum palati, and the pharynx be severed (the muscles in each case being traced to their attachments) and the organ be then removed, we shall see that there is a firm central portion of definite shape, tapering from behind forward, and that from this body project a number of muscular bands of various forms and sizes. The intrinsic muscles are found only in the central mass; the projecting bands are parts of the extrinsic muscles, the other parts being embedded in the central mass, in which their fibres decussate with those of the intrinsic muscles.

The Lingualis Muscle.—The intrinsic mass or tongue proper is sometimes spoken of as the *lingualis muscle*; but it is convenient to divide it into four portions—the superior, the inferior, the transverse, and the vertical. They are all supplied by the hypoglossal nerve.

The **superior lingualis** consists of longitudinal fasciculi, which lie near the upper surface from the hyoid to the apex, attachments being made all along with the submucous tissues. Its action produces shortening of the tongue, and longitudinal grooving of its dorsum.

The **inferior lingualis** is a large bundle on each side, which runs under the edge of the tongue in its whole length, between the hyoglossus and the genioglossus. It shortens the tongue and rounds up its dorsum.

The **transverse lingualis** is made up of fibres which arise in the median septum

and run to the dorsum and margin, where they are inserted into the fibrous lamina. It diminishes the width and increases the length of the organ.

The **vertical lingualis** is composed of small fasciculi, which course from the

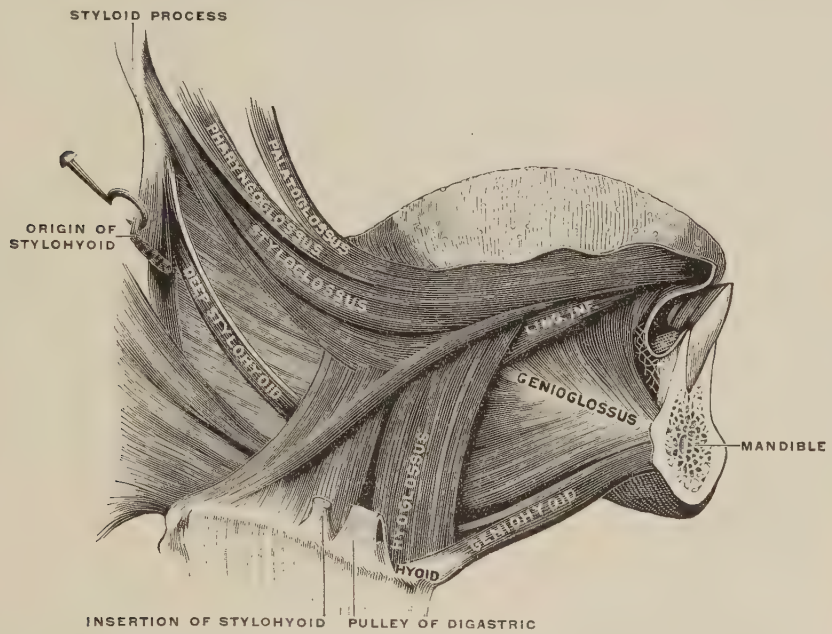

FIG. 801.—Muscles of the tongue, viewed from the right side. The label of the hyoglossus is upon the front part only of the muscle. (Testut.)

dorsum to the under surface, curving with their concavity outward. Its fibres are interlaced with those of the transverse lingualis. It broadens and flattens the tongue.

The Extrinsic Muscles of the Tongue.

The extrinsic muscles of the tongue are the genioglossus, the hyoglossus, the styloglossus, and the chondroglossus. To this list is sometimes added the palatoglossus; but it seems better to include this with the muscles of the soft palate, already described.

Genioglossus (Fig. 801) ("the chin-tongue muscle").—*Synonym*, geniohyoglossus, "the chin-hyoid-tongue muscle." *Situation*, in the middle line of the tongue. *Origin*, the upper genial tubercle. *Direction*, divergent—backward, upward, and to all points between. *Insertion*, the hyoid bone and the whole length of the tongue in and at the side of the mid line. *Action*: the back part thrusts the tongue forward; the front part retracts the tip of the tongue; the part between the apex and the base depresses the mid line, thus forming a gutter. *Nerve*, the hypoglossal.

Hyoglossus (Figs. 801, 802) ("the hyoid-tongue muscle").—*Situation*, between the hyoid and the side of the tongue. *Origin*, the great cornu and the body of the hyoid. *Direction*, upward and forward. *Insertion*, the side and dorsum of the tongue, blending with the styloglossus. *Action*, retraction and depression of the tongue. *Nerve*, the hypoglossal.

Styloglossus (Figs. 801, 802) ("the styloid-process-tongue muscle").—*Situation*, between the side of the base of the skull and the side of the tongue, outside of the pharynx. *Origin*, the front of the styloid process of the temporal bone, and the stylomandibular ligament. *Direction*, forward, downward, and a little inward. *Insertion*, the whole length of the side and under part of the tongue. Its fibres blend with those of the hyoglossus and palatoglossus. *Action*: it draws the tongue backward, and lifts its base. *Nerve*, the hypoglossal.

Chondroglossus.—"The cartilage-tongue muscle," so called from its attachments to the small cornu (which is usually cartilaginous) of the hyoid and to the tongue. *Situation*, at the side of the tongue below, under cover of the hyoglossus. *Origin*, the small cornu and body of the hyoid. *Direction*, upward and forward. *Insertion*, the dorsum of the tongue. *Action*: it retracts and depresses the tongue. *Nerve*, the hypoglossal.

THE PHARYNX.

Behind the nasal passages, the mouth, and the larynx, beneath the base of the skull, and above the upper end of the gullet, is a hollow organ of irregular shape, which belongs not only to the alimentary tube, but to the respiratory system, also. It has no name in our vernacular, but is known technically as the *pharynx* (Fig. 787). The upper part, behind the nose, is the *naso-pharynx*; the middle portion, back of the mouth, is the *oro-pharynx*; and the lowest segment, dorsal to the larynx, is the *laryngo-pharynx*. The anterior lower limit of the naso-pharynx is at the border of the hard palate; of the oro-pharynx at the upper level of the hyoid bone; and of the laryngo-pharynx at the lower level of the cricoid cartilage, which nearly coincides with that of the fifth cervical vertebra.

Food passes from the mouth into the oro-pharynx, through the laryngo-pharynx, and into the gullet; and inspired air goes from the nose into the naso-pharynx, through the oro-pharynx, and enters the larynx. Thus the middle segment of this organ is common to the alimentary and respiratory systems, and the tracks followed by the food and the air cross obliquely in it.

Like the mouth the pharynx is bilaterally symmetrical. It is widest (nearly one inch and a half) in the upper laryngeal portion, and narrows above and below, having its least diameter (half an inch) at its junction with the gullet. Ventro-dorsally its measurement is everywhere small, only opposite the mouth being more than four-fifths of an inch. It is about five inches long. In short, the cavity of the pharynx may fairly be regarded as a wide side-to-side chink, in front of the upper five cervical vertebræ.

Openings of the Pharynx.—In the naso-pharynx are four openings—one at each side for the Eustachian tube, leading to the middle ear, and one forward for each of the lateral halves of the nose,—the posterior nares. In the oro-pharynx is the opening from the mouth, the isthmus of the fauces, between the anterior pillars of the palate. The laryngo-pharynx opens at its lower end into the gullet, and at its upper, anterior part into the larynx.

The pharynx is firmly fastened to the neighboring parts at its summit, and in the front part of its nasal and oral portions; but its attachments elsewhere are areolar and loose, so that its lower third can be elevated, and its rear wall advanced, as in swallowing.

Tunics of the Pharynx.—Here, as elsewhere in the alimentary tube above the diaphragm, the wall is composed of three coats; but the middle one is so much condensed that its areolæ are largely obliterated, and the tunic is more like a fascial layer and is called the *pharyngeal aponeurosis*. It is stout and strong above, and becomes gradually thin and weak as it is traced downward.

The **mucous membrane**, continuous with that of the nose, middle ears, mouth, larynx, and gullet, is covered with ciliated cells as far down as the level of the hard palate, but below this is flattened and non-ciliated. On the back (dorso-superior surface) of the soft palate the cells are ciliated, except at the free edge. In and beneath the mucosa are many racemose, mucous glands. The corium is particularly rich in lymphoid tissue, and at the pharyngeal vault there is an accumulation of this material, which, from the similarity of its structure to that of the tonsil, has been named the *pharyngeal tonsil*. Dorsal to the Eustachian tube is another collection on each side, called the *tubal tonsil*. High up in the middle line, and running upward and backward to the base of the skull is a blind depression, called the *pharyngeal bursa*.

The **muscular tunic** is composed of five pairs of muscles, of which three are constrictors—upper, middle, and lower—having for their function the diminution of the calibre of the pharynx, and the others—the stylo-pharyngeus and palato-pharyngeus—are elevators, which lift up the pharynx and larynx. The last of these has been described in connection with the soft palate.

Relations of the Pharynx.—Behind is the deep cervical (prevertebral) fascia, and at each side are the styloid process and the muscles connected with it, and also the great vessels and nerves of the neck (Fig. 803).

Muscles of the Pharynx.

Constrictor Inferior (Figs. 802, 803) ("the lower constrictor").—*Situation*, at the side and back of the lower part of the pharynx. *Origin*, the cricoid and thyroid cartilages of the larynx. *Direction*, backward, inward, and upward, diverging from its origin. *Insertion*, the median tendon, common to it and its fellow opposite, extending nearly to the basilar process of the occipital bone. It overlaps the middle constrictor. *Action*: it compresses the pharynx, mainly ventro-dorsally; it also moves the larynx upward and backward. *Nerves*, from the pharyngeal plexus, and the external and inferior laryngeal.

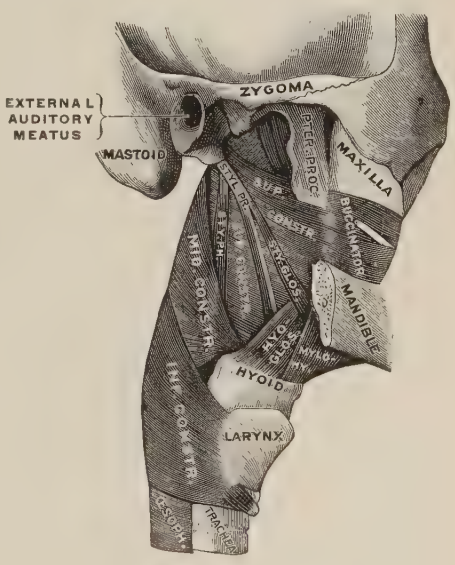

Fig. 802.—Muscles of the pharynx, viewed from the right side. (Testut.)

Constrictor Medius (Figs. 802, 803) ("the middle constrictor").—*Situation*, at the side and back of the middle part of the pharynx. *Origin*, the cornu of the hyoid, and stylohyoid ligament. *Direction*, divergent—all portions backward and inward, the inferior downward, and the superior upward. *Insertion*, the common tendon in the middle line in almost the entire length of the pharynx. *Action*: it compresses the pharynx, chiefly ventro-dorsally; and it draws the hyoid backward and upward. *Nerves*, from the pharyngeal plexus.

Constrictor Superior (Figs. 802, 803) ("the upper constrictor").—*Situation*, at the side and back of the upper part of the pharynx. *Origin*, the side of the tongue, the mucosa of the mouth, the mylohyoid ridge, the pterygomandibular ligament (which extends from the apex of the internal pterygoid plate to the hind end of the mylohyoid ridge), and the lower fourth of the hind border of the internal pterygoid plate. *Direction*, divergent—all parts backward and inward, the superior upward, and the inferior downward. *Insertion*, the common tendon in the middle line from the basilar process half way, or more, to the gullet. *Action*, approximation of the lateral walls of the upper part of the pharynx. *Nerves*, from the pharyngeal plexus.

The name *pharyngoglossus* (glossopharyngeus) (Fig. 801) is applied to certain fasciculi which extend from the superior constrictor to the tongue—the upper losing itself in the palatoglossus and styloglossus, the lower merging into the hyoglossus, genioglossus, and lingualis.

Stylopharyngeus (Figs. 802, 803) ("the styloid-process-pharynx muscle").—*Situation*, at the side of the pharynx, and mesial to the middle and lower constrictors. *Origin*, the styloid process of the temporal bone. *Direction*, downward and inward. *Insertion*, the upper and hind borders of the thyroid cartilage, mingling with the palato-pharyngeus. *Action*, lifting the pharynx and larynx. *Nerve*, the glosso-pharyngeal.

The Tonsils (Fig. 788).

In the recess formed by the divergence of the pillars of the palate on each side is a flattened, ovoid body, the tonsil (*tonsilla*) or almond (*amygdala*), whose mesial face can easily be seen, when the mouth is widely opened and the tongue depressed. Its position is internal to that of the angle of the jaw. Its external

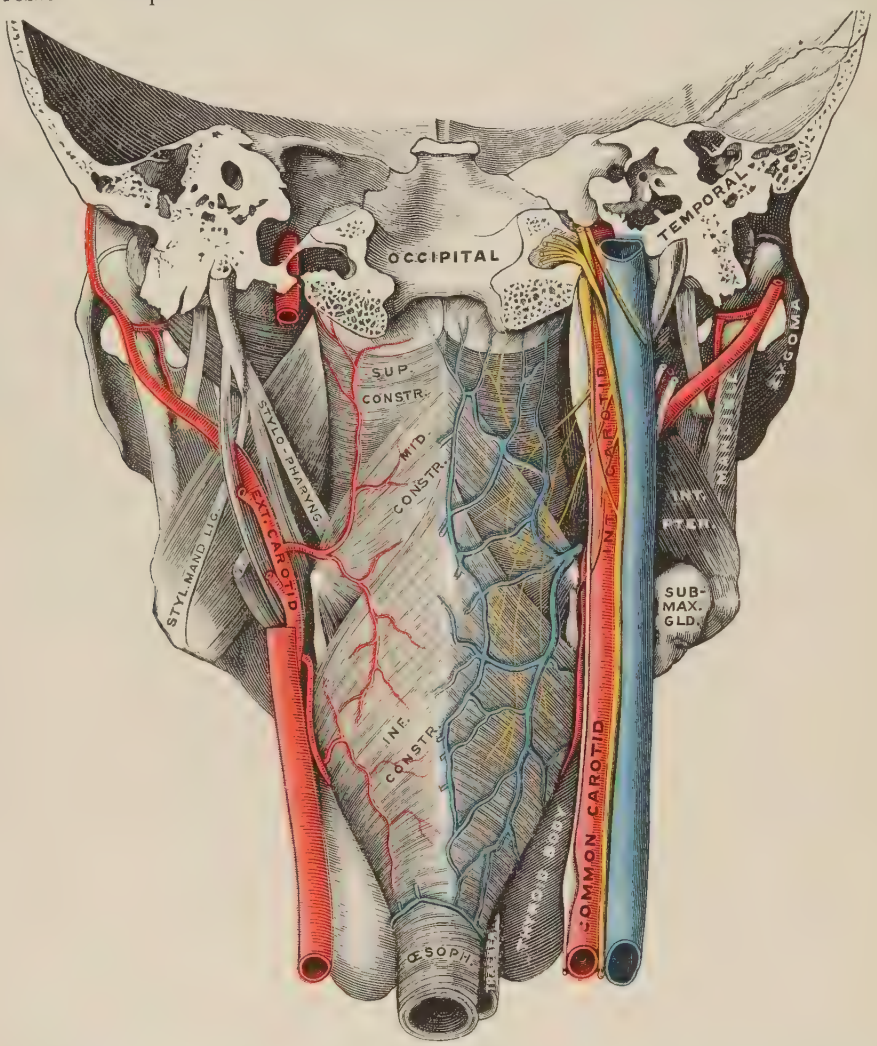

FIG. 803.—Muscles of the pharynx, viewed from behind, together with the associated vessels and nerves. (Modified from Testut.)

surface is attached to the upper constrictor by areolar tissue. Dorso-externally is the internal carotid artery (Fig. 472).

The tonsil is substantially a collection of lymph-nodules, with a distinct capsule on its attached surface, and a continuation of the mucosa of the pharynx on its exposed surface, which is irregularly pitted with blind holes of varying size. Mucous glands open into these pits, and with their secretion are mingled great numbers of lymph-cells, many of which appear in the spittle as *salivary corpuscles*.

The *blood-supply* of the tonsil comes from branches of the lingual, facial, internal maxillary, and ascending pharyngeal. Its *lymph* flows into an upper deep cervical node, and its *nerves* are branches of the trifacial and glossopharyngeal.

Mention has been made of lymphoid masses upon the pharyngeal portion of the tongue, of similar accumulations at the vault of the pharynx, and on its

posterior wall near the Eustachian tubes. These, taken in connection with the true or faucial tonsils, constitute what Waldeyer has called the *tonsillar ring.*

THE GULLET.

Between the levels of the upper border of the sixth cervical vertebra and that of the eleventh thoracic—a distance of about ten inches—extends the *gullet* or *œsophagus* ("carrying eatables"), the tube connecting the pharynx and the stomach (Fig. 804). From the arch of the teeth to the upper end of the gullet is about six inches. The direction of the gullet is nearly that of the part of the spinal column near which it runs—slightly curved with its concavity forward. It is at first in the middle line; but, as it passes downward, it swerves slightly to the left, then turns back toward the median line, which it reaches opposite the fifth thoracic vertebra. In its lower part it bends again to the left and forward, pierces the diaphragm, and ends in the stomach. It is slightly contracted at its beginning, gradually expands at its lower part, and then is a little constricted at its passage through the diaphragm. Excepting during the passage through it of distending substances, its condition is one of collapse, its dorsal and ventral walls being in contact, its mucosa folded into longitudinal rugæ, and the bore of the tube obliterated.

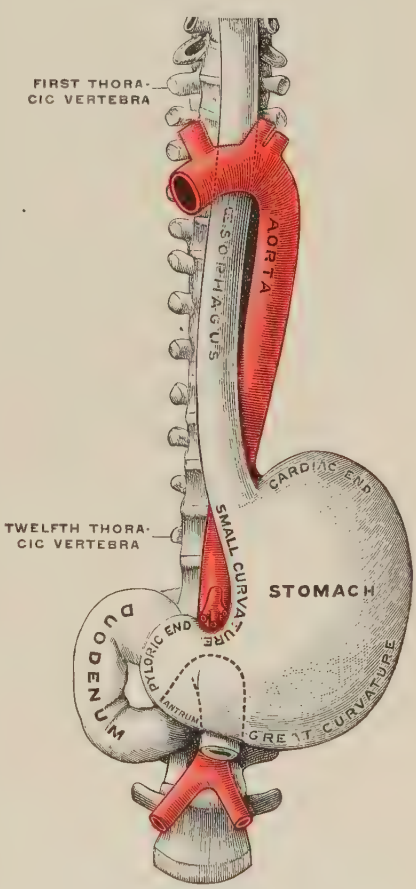

FIG. 804.—Œsophagus and stomach in their natural relations to the vertebral column and the aorta. (Testut.)

The *mucosa*, like that in the succeeding portions of the alimentary canal, is limited in its depths by a muscularis mucosæ. Its free surface has a stratified, flattened epithelium. The *areolar coat* is thick, and contains many mucous glands, which open into the lumen. The *muscular tunic* displays a peculiar transition from the striated variety, which alone is seen in the pharynx, to the smooth, which is the only kind occurring in the stomach. For a short distance from the beginning we find only striped muscle; then for a little way a mixture of the two varieties; and, finally, in the lower half, nothing but the muscular tissue of organic life. The inner layer is circular and is continuous with the inferior constrictor of the pharynx; the outer is longitudinal. The gullet is connected with the structures in the midst of which it lies by a sheath of areolar tissue, and there may be muscular bands attaching it to the trachea, the pericardium, the left pleura, and the left bronchus.

Relations of the Gullet.—The left longus colli and the prevertebral fascia separate it behind from the vertebral column. The trachea is in front as far down as its bifurcation opposite the fourth thoracic vertebra. The pleuræ are right and left respectively. The thoracic duct is behind the lower part of the gullet, and above is between it and the left pleura. The lobes of the thyroid gland extend backward to the sides of its upper part. The left bronchus lies across the front about half way down. The pericardium is in front below. The transverse portion of the arch of the aorta lies at the left, and the thoracic aorta runs down at

first on the left side and finally gets behind. The left carotid and subclavian arteries are at the left anteriorly, and the right carotid at the right. The right aortic intercostals are behind, as also are the smaller azygos veins—the greater azygos vein being at the right. The recurrent laryngeal nerves lie in the grooves, right and left, between the gullet and the trachea. The right vagus is at the right and behind, the left is in front.

The *arteries* of the gullet are the œsophageal from the thoracic aorta and inferior thyroid, and branches from the gastric of the cœliac axis, the intercostals, and perhaps the phrenic. Its *nerves* are from the recurrent laryngeal and the sympathetic.

THE ABDOMINAL CAVITY.

The portion of the alimentary canal which is below the thorax is contained in the abdomen, and it is desirable to consider the principal features of this cavity before proceeding to the study of the viscera which it holds.

The term *abdomen* is properly applied to the whole of the body-cavity below the thorax. The portion of this space, however, below the brim of the true pelvis is called the *pelvic cavity* for convenience of description.

The bony framework of the lower portion of the trunk, and the muscles and fasciæ which, attached to this osseous staging, form the greater part of the abdominal walls, have already been considered, excepting the muscles of the perineum, and these are described in connection with the organs of generation. It is sufficient here to call attention to a few facts, which will assist in the study of the organs contained in the abdomen.

The principal abdominal viscera belong to the alimentary system, and are the stomach, intestines, liver, and pancreas. There are also in the abdomen the principal urinary organs, and, in the female, the chief genital; and finally the spleen, and the suprarenal capsules.

The abdominal cavity is lined with the largest of the serous membranes, the *peritoneum*. At various places this membrane is reflected from the wall onto the contained viscera, to some of which it furnishes a slight, to others, a considerable, and to others still, a practically complete outer tunic, thus justifying its name, which means literally something "stretched around." Until the anatomy of the abdominal viscera is learned, a description of the peritoneum cannot be appreciated; and, therefore, further consideration of the subject will be deferred until the discussion of the digestive organs has been completed.

Apertures in the walls of the abdomen give passage to numerous organs: the aorta, inferior vena cava, gullet, thoracic duct, vena azygos major, and vagi, above; the rectum, urethra, spermatic cords (or round ligaments of the uterus), the vessels and nerves of the lower limbs, and, in the female, the vagina, below. Besides these, there should be mentioned the openings of the oviducts (Fallopian tubes) of the female, by means of which the peritoneal cavity is put in communication with the surface of the body—the serous membrane here being continuous with the mucous membrane of the genito-urinary system, and furnishing an exception to the rule that a serous membrane is a shut sac.

The boundary between the thorax and abdomen is made by the diaphragm. This muscle forms a dome over the belly-cavity, its highest part rising to the level of the junction of the fourth costal cartilage with the sternum, and, consequently, the abdomen greatly encroaches upon the space, which a superficial inspection of the thoracic cage would lead one to assign to the chest. The cubic capacity of the thorax is very small compared with that of the abdomen, largely owing to this invasion of its (expected) territory.

Regions of the Abdomen (Fig. 805).

For generations it has been customary to divide the abdomen into nine regions for convenience of description: one near the centre, called *umbilical*, with a *lumbar* on each side; above the umbilical, the *epigastric* ("upon the stomach"),

with a *hypochondriac* ("under the cartilage") on each side; and below the umbilical, the *hypogastric* ("under the stomach"), with an *iliac* on each side. The delimitation of these regions is not uniformly made by authors. The writer called attention to this fact and to the need of agreement among anatomists some years ago, and embodied his suggestions in a paper read to the Association of American Anatomists in 1892. Having seen no proposition which appears more reasonable and useful in the premises, he presents his plan here.

A line is drawn around the body at the level of the *anterior superior spinous processes* of the ilium, and another at the *lowest point of the tenth costal cartilages.* These lines stand for the peripheries of horizontal planes, which completely divide the abdomen into three sections. Each section is cut into three by a vertical plane running ventro-dorsally through *the middle of each inguinal* (Poupart's) *ligament.*

These are superficially indicated on the front of the abdomen in Fig. 805.

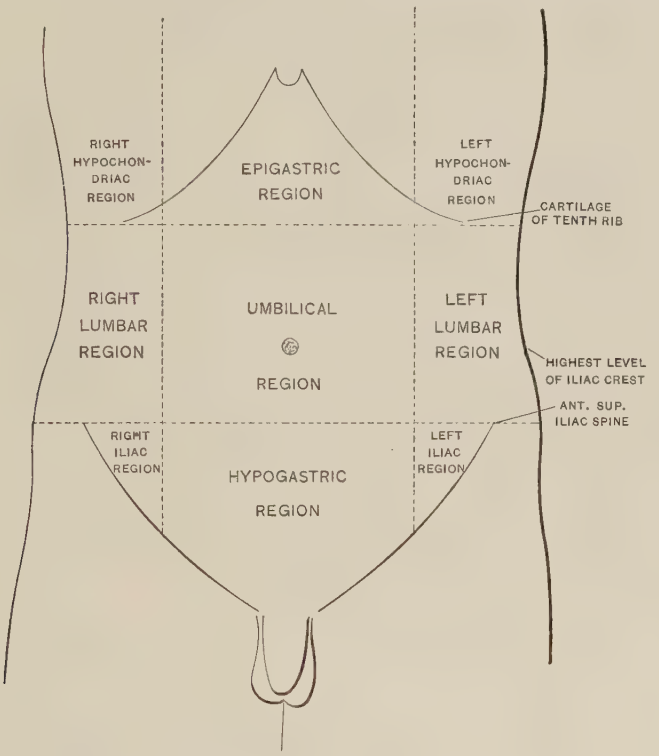

FIG. 805.—Regions of the abdomen, delimited by the author's method. (F. H. G.)

The advantages of this method are that it brings the umbilicus wholly into the umbilical region, which is rather rarely the case, when the lower horizontal is drawn at the level of the iliac crests; that the guide to the upper horizontal is a prominence easily found through the integuments, and that this plane divides the part of the abdomen above the lower horizontal more equally than does that usually given; and, finally, that the perpendicular plane on each side starts from a prominent landmark, and fairly apportions each of the three zones.

THE STOMACH.

The gullet perforates the diaphragm, and almost immediately ends in the stomach (*stomachus, gaster*), the tube expanding into a great bag (Fig. 806). The stomach is just beneath the diaphragm and behind the anterior abdominal wall, in the epigastric and left hypochondriac regions. Its *shape* and *attitude* are

worthy of especial attention. It looks somewhat like a pear with the large end up, and the small end bent sidewise to the right. Its front and rear surfaces are moderately convex. Looking at it from before, it is seen that a continuation of the right margin of the œsophagus downward coincides with the upper two-thirds of the right border of the stomach, the remaining third of this border bending sharply to the right and backward, thus completing what is known as the small curvature. The great curvature begins at the end of the gullet on the opposite side, making a somewhat acute angle with the left border of this tube. It then

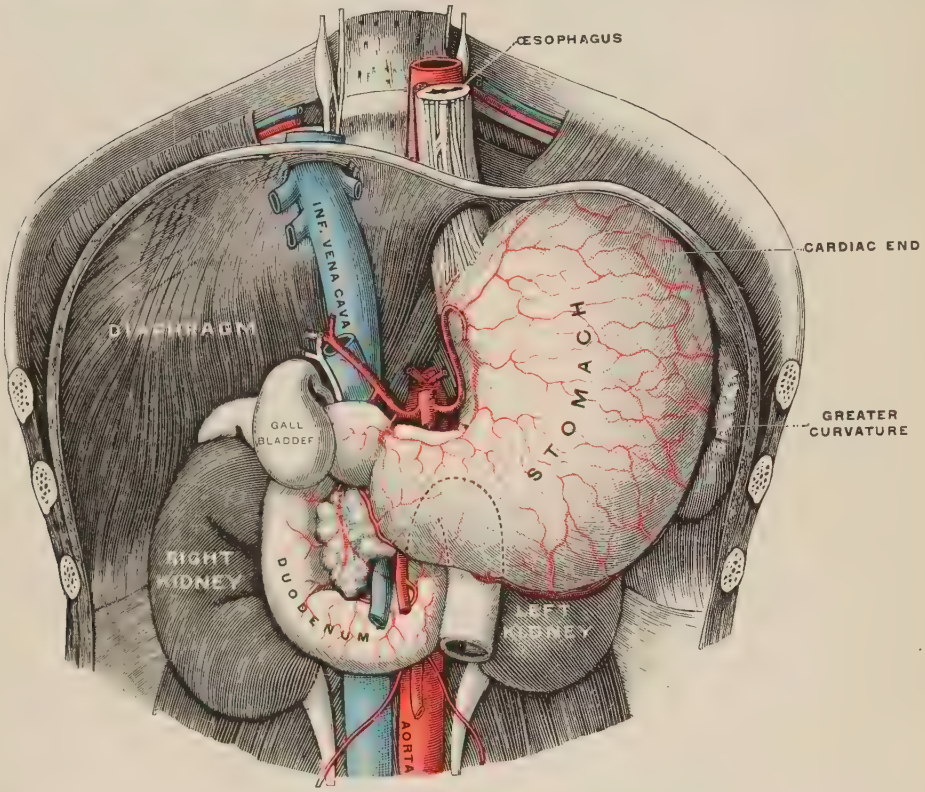

FIG. 806.—Stomach and duodenum, the liver and most of the intestines having been removed. The pyloric end of the stomach should be represented as turned directly backward. (Testut.)

passes upward and to the left to the diaphragm, is in contact with the under surface of the latter for some distance, sweeps downward in a generous curve with its convexity to the left, continues in a somewhat flattened line to the right, is here a little indented, and finally turns abruptly up and back, terminating at the outlet-end, close to the small curvature.

Particular attention is called to the following facts: the general direction of the long axis of the stomach is vertical; the small curvature faces mostly to the right; the great curvature is directed mainly to the left; the aperture of entrance (œsophageal opening) is but slightly to the left of the middle line of the body, and looks downward; the hole of exit (intestinal opening) is on a lower plane, close to the mid line, and looks directly backward—a point not well shown in Fig. 806. The curvatures or borders are the lines of reflection of the peritoneum.

The preceding statements apply to the organ when it is not distended; but, *when it is distended*, some differences are observed. Then the great curvature is tilted toward the front, the small end is moved two inches or more toward the right, and the pressure on the diaphragm may be such as to interfere seriously with the freedom of action of the heart, which is situated in part immediately over the stomach on the upper surface of the diaphragm.

The large end of the stomach is called, on account of its nearness to the heart, the *cardiac end*, or simply the *cardia*, and sometimes the *fundus*; the small is named the *pyloric end*, from the pylorus, presently to be described.

The before-mentioned indentation of the great curvature near the lower end is a part of a slight constriction, and the portion of the cavity between it and the intestinal opening is called the *antrum pylori cum* ("pyloric cave").

Relations.—The œsophageal opening is opposite a point on the left seventh costal cartilage, about an inch from its articulation with the sternum, and on a level with the tenth or eleventh thoracic vertebra. The pyloric opening is opposite a point an inch below the sternum and about that distance to the right, and is on the plane of the upper part of the first lumbar vertebra. The small curvature extends from the level of the tenth or eleventh thoracic vertebra to that of the first lumbar. The uppermost limit of the great curvature is on the plane of the articulation of the sixth costal cartilage with the sternum. The anterior surface presents to the left lobe of the liver, the arching surface of the diaphragm, and that part of the anterior abdominal wall which is in the upper two-thirds of the left half of the epigastric region, as delimited by the scheme on page 733, excepting a small area above, which is occupied by the liver. Behind the stomach are the pancreas, the spleen, the left kidney and suprarenal capsule, the transverse mesocolon, and the diaphragm. Above are the liver, the diaphragm, and the small omentum; below, the transverse colon, and the great omentum.

The Tunics of the Stomach.

The tunics of the stomach conform to the rule previously stated.

The Serosa.—Passing from the transverse fissure of the liver are two layers of serous membrane, which constitute the *gastro-hepatic* ("stomach-liver") *omentum*. After continuing downward for about two inches, they reach the small curvature of the stomach, where they divide, clothe respectively the front and back surfaces of this viscus, meet along the great curvature, unite again, and continue downward to help form the great omentum. A very narrow strip of uncovered surface may be found along each of the two curvatures, indicating respectively the places of separation and reunion of the peritoneal lamellæ. The adhesion of the serosa is closest at the centre of the front and back surfaces, but gradually becomes looser toward the borders.

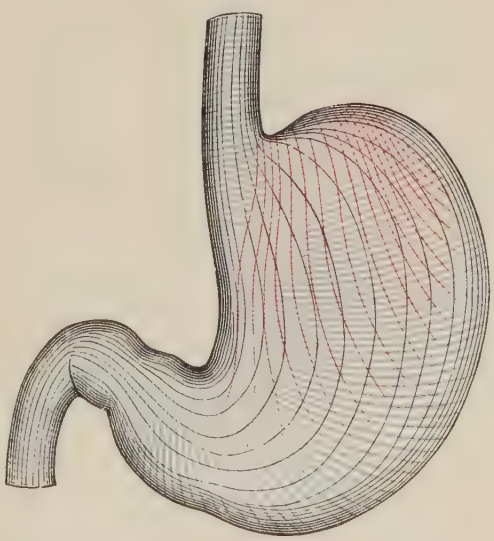

FIG. 807.—Diagram to show the direction of the fibres in the three muscular layers. (Testut.)

The **Muscular Coat** has two complete layers—an outer, longitudinal, and an inner, circular (Fig. 807). Besides these two distinct layers some oblique fasciculi are found, internal to the circular. This criss-cross arrangement of the layers contributes greatly to the strength of the stomach-walls. The circular layer increases in thickness toward the small end, and there is such an augmentation of its fibres around the intestinal opening as to constitute a thick, circular sphincter, called the *pylorus* ("gate-keeper"), the side toward the stomach sloping, and that toward the bowel being abrupt. The aperture is the *pyloric orifice* (Fig. 808).

The **Areolar Coat,** called also submucous and vascular, is loose, and its meshes are largely occupied with the vessels and nerves going to and from the coats between which it lies.

The **Mucous Membrane** is thrown into irregular, longitudinal folds (*rugæ*) when the organ is flaccid, but becomes smooth during distension. Its corium is mostly occupied by tubular glands, between which is fibrous tissue, containing capillaries and nerves; and beneath these structures is a muscularis mucosæ, which sends some of its fibres up between these follicles. The surface epithelium consists of a single layer of columnar cells, many of which are goblet. The glands are all tubular depressions of the surface, and their length is but a trifle less than the thickness of the membrane. They are of two varieties, one, the *cardiac glands* or proper gastric glands, being found in the large end and middle third of the stomach; and the other, the *pyloric glands*, in the region of the small end. They are arranged in little groups, which are bounded by minute elevations of the surface.

The **cardiac glands** (Fig. 809) are simple tubular depressions, consisting of a *duct*, *neck*, and *fundus* or body. The duct is short, has a wide mouth, and is lined with columnar epithelium, a continuation of that upon the general, free surface. Its cells overlap one another a little. In the neck the cells become short and broad. The fundus is wavy or spiral, and is furnished with two kinds of *cells*: the *central*, rather conoidal, and more numerous; the *parietal*, larger, usually not reaching the

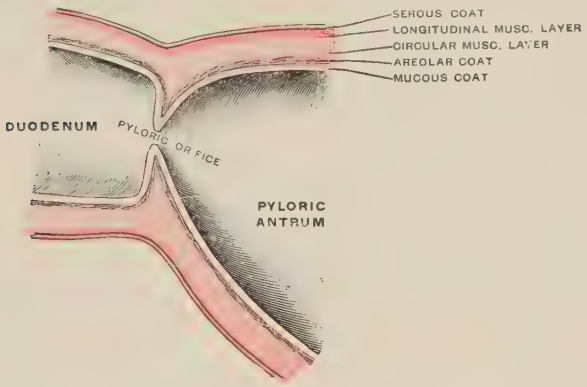

FIG. 808.—Vertical section at the junction of the stomach and duodenum, showing the disposition of the coats. Semidiagrammatic. (Testut.)

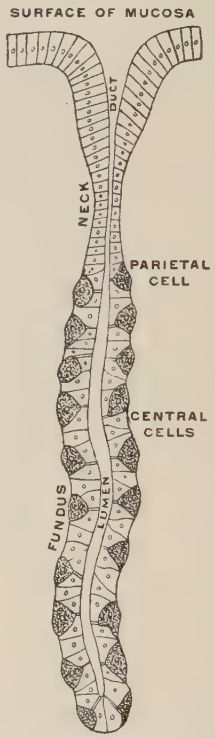

FIG. 809.—Cardiac gland in longitudinal section. (F. H. G.)

bore of the tube, but communicating with it through minute cracks between the overlying central cells.

The **pyloric glands** have a very wide and deep duct, into the bottom of which open several divisions (funduses), which are wavy or even tortuous. The epithelium is in all parts very similar to that on the surface of the mucosa. Between the divisions is the true corium material, and at frequent intervals are irregular masses of lymph-adenoid material.

Vessels and Nerves.—The stomach is supplied with blood from the gastric, pyloric, and both gastro-epiploïc arteries, and the vasa brevia of the splenic. The blood from the region of the small curvature is carried to the portal vein directly by the pyloric and coronary veins; that from the region of the great curvature goes first into the right and left gastro-epiploïc, and then to the portal by way of the superior mesenteric and splenic respectively. The nerve-supply of the stomach is received from the vagi—the right being distributed on the dorsal surface, the left on the ventral—and from the sympathetic.

THE SMALL INTESTINE.

The small intestine (*intestinum tenue*) (Fig. 822) is that portion of the alimentary canal which begins on the distal side of the pyloric valve, and ends on the proximal side of the ileo-cæcal. In other words, it extends between stomach above and large intestine below. Its average length is twenty feet or more; and, as it is all contained in the abdominal cavity, which also lodges many other organs, it is necessarily subjected to numerous bendings, and consequently, when the anterior wall of the belly is laid open, presents the appearance of inextricably tangled convolutions.

From above downward it gradually diminishes in size, thickness of wall, and complexity of structure. Its diameter near its beginning is nearly two inches, but becomes steadily less, and is hardly an inch at its lower end. Its loss in structural elaborateness will be described in detail later on.

It occupies the umbilical and hypogastric regions and the adjacent portions of the lumbar, being to a large extent within the area bounded by the colon.

Parts of the Small Intestine.—It is usually described as consisting of three parts—the duodenum, jejunum, and ileum. The first of these is limited by distinct natural boundaries, and is strikingly different from the rest in other respects. The second and third are not thus differentiated, and there is no manifest advantage in continuing the attempt to distinguish them from one another. But as the names are fastened in our nomenclature, they will be used to designate respectively the uppermost and lowermost portions of the small intestine distal to the duodenum, without the suggestion of a definite line or even region of demarcation between them; and the name *jejuno-ileum* will be employed to indicate the continuous, undivided whole which the two constitute.

Tunics of the Small Intestine.

The small intestine has four tunics, which correspond in general character and arrangement with those of the stomach.

The **Serous Coat** (Fig. 810) furnishes a practically complete covering for the whole tube, excepting the duodenum, which is but scantily clad with it. This membrane is reflected from the dorsal wall of the abdomen, runs forward for a distance, which varies in different parts, reaches the intestine, which it closely enwraps, and, returning almost to its line of first contact, turns toward its parietal origin, keeping in practical apposition with its outgoing layer, until it arrives at its starting-point, where it is reflected toward the opposite side of the body. Thus is formed not only a snug investiture for the gut, but also a double-layered mooring, fastened at one end to the hind wall of the abdomen, at the other to the intestine, and permitting large freedom of movement. This structure is the *mesentery* ("in the midst of the intestines"), and between its two layers are the arteries, veins, lymphatic vessels, and nerves required by the bowel, a great number of lymph-nodes, and usually a quantity of adipose (Fig. 811). The proximal (attached, parietal, dorsal) border of the mesentery extends from the left side of the second lumbar vertebra to the right mesocolon, its direction being from above downward and to the right, and its measurement eight or ten inches. The distal (free, intestinal, ventral) border is vastly longer, being frilled out to the length of the jejuno-ileum, and thus sug-

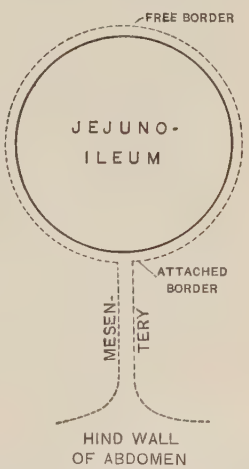

FIG. 810.—Diagram to show the relation of the peritoneum (broken line) to the greater part of the small intestine.

gestive of a widely opened fan. Its sides are right or superior, and left or inferior. Its length is from the attached to the free border, and varies from one inch to ten inches.

The **Muscular Coat** lies just within the serous, which covers it perfectly, except for a very narrow strip between the lines of attachment of the mesenteric layers. This bare area marks what is called the *attached border* of the intestine,

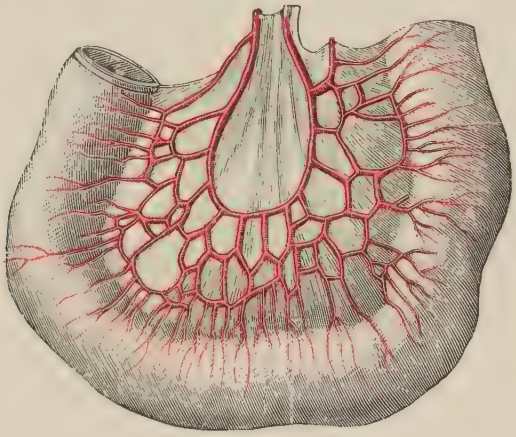

FIG. 811.—A loop of small intestine, showing the mode of distribution of the arteries. (Testut.)

and the exactly opposite portion of the gut is known as the *free border*. The *outer layer* of the muscular tunic is complete, thin, composed of bundles arranged lengthwise, and thickest in the region of the free border. The *inner layer*, also, is complete, but is thicker, and its fasciculi are transverse, forming a circular layer. This coat thins out gradually as the intestine approaches its lower end.

The Areolar Coat.—Inside of the muscular is the areolar (submucous, vascular) coat, in whose meshes are networks of blood-vessels, lymphatics and nerves.

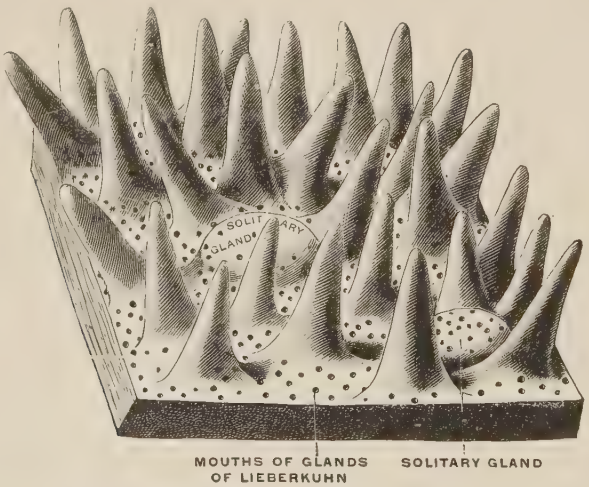

FIG. 812.—Free surface of the mucous membrane of the small intestine, showing villi, solitary glands, and openings of the intestinal glands. Semidiagrammatic. (Testut.)

The Mucous Coat.—Finally, we reach the mucous membrane, which is attached by its outer aspect to the areolar tunic, and presents a free surface to the bore of the tube. Its corium contains lymphoid tissue, with many leucocytes, and a rich supply of vessels and nerves. Outside of this is a distinct muscularis mucosæ, with an inner plate of circular, and an outer plate of longitudinal fibres. Inside

of the corium is a basement membrane, surmounted by a single layer of prismatic, columnar, epithelial cells, which are characterized by the presence of a delicate plate on the free end of each, marked with vertical lines. Among these epithelial cells are many of the goblet variety.

The Villi (Fig. 812).—A peculiarity, which distinguishes the mucous membrane of the small intestine is the presence everywhere of minute projections, called *villi*, which are so abundant as to give a velvety appearance to the surface. They are organs of absorption. Their number has been variously estimated at from four to ten millions. In the upper part of the intestine they are so closely set as to seem to leave no space between. The tallest are scarcely one twenty-fifth of an inch in height. In shape they are commonly cylindrical; but conical, filiform, mammillary, and lamellar varieties are observed. A lymph-vessel (lacteal) occupies the centre of the villus, a plexus of capillary blood-vessels surrounds this, a few threads of smooth muscle run up from the depths of the membrane, all these are embedded in a mass of nucleated cells, and the whole villus is covered by the columnar epithelium already mentioned.

The Valvulæ Conniventes.—Another feature which characterizes this tunic and is observed from an inch or two below the pylorus to within a foot or more of the end of the gut, is the presence of transverse folds of mucous membrane, each strengthened internally by a projection from the areolar coat. They are called *valvulæ conniventes* ("winking-valves"). Unlike the rugæ of the stomach, which are effaced when that organ is filled, they are not obliterated by the distension of the intestine. This permanency is due to several causes. First, these projections are not produced by a wrinkling of the membrane during relaxation, as are the ridges of the stomach, but are actual outgrowths of the mucosa, giving it an immense increase of surface, even during distension. Second, the valves do not extend completely around the circumference, but only a quarter, half, or (rarely) three-quarters way round, one considerably overlapping the lines of its next neighbors, and thus guarding against the effacement which might occur during extreme stretching, if each of them described a complete circle. In other words, an internal pressure, which might be able to unfold a perfect ring, is thwarted by a device which distributes that force to several separate segments and to a considerable extent of surface. And, third, the transverse arrangement of the valves is more favorable to their continuance than the longitudinal would be, as the stretching of the tube from within takes place almost altogether laterally and but slightly lengthwise, and, consequently, these folds are subjected to hardly any strain in these circumstances.

The valvulæ conniventes are somewhat crescentic in shape, may be as much as a fourth or third of an inch deep in the middle, and diminish in depth toward the ends, which often bifurcate, and finally shade off into the surrounding surface. There are usually eight or nine hundred of them.

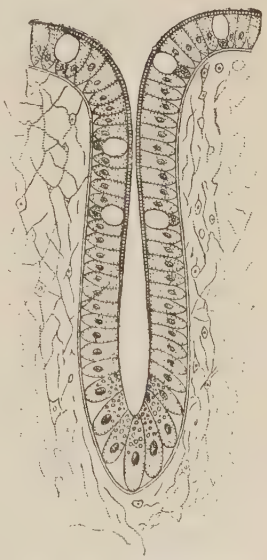

Fig. 813.—Intestinal gland in longitudinal section. (Testut.)

Glands in the Mucosa.—Almost the entire substance of the corium is occupied by tubular depressions, which are lined with epithelium, very similar to that on the exposed surface, being columnar with frequent interruptions by goblet cells. These are the *intestinal glands*, more frequently called the follicles or *crypts of Lieberkühn* (Fig. 813). Their secretion is chiefly intestinal juice, though they furnish also some of the mucus, which is always present.

Lymph-structures in the Mucosa.—Embedded in the mucous coat and often encroaching upon the areolar are little globular or ovoid bodies, one-twelfth inch or less in diameter, which are structurally closely related to the lymph-nodes,

being composed of a multitude of leucocytes, held together by an adenoid reticular framework, and drained by lymphatic vessels. They are sprinkled rather uniformly throughout the length of the viscus, though in some spots they are scarce, in others very numerous. They are the *solitary lymph-nodules*, but they are most frequently called *solitary glands* (Fig. 814), though no more entitled to the name than are the nodes, which occur in the course of lymphatic vessels, having no secreting apparatus. We may fairly regard them as the picket-line of the great army of nodes, which occupy the mesentery.

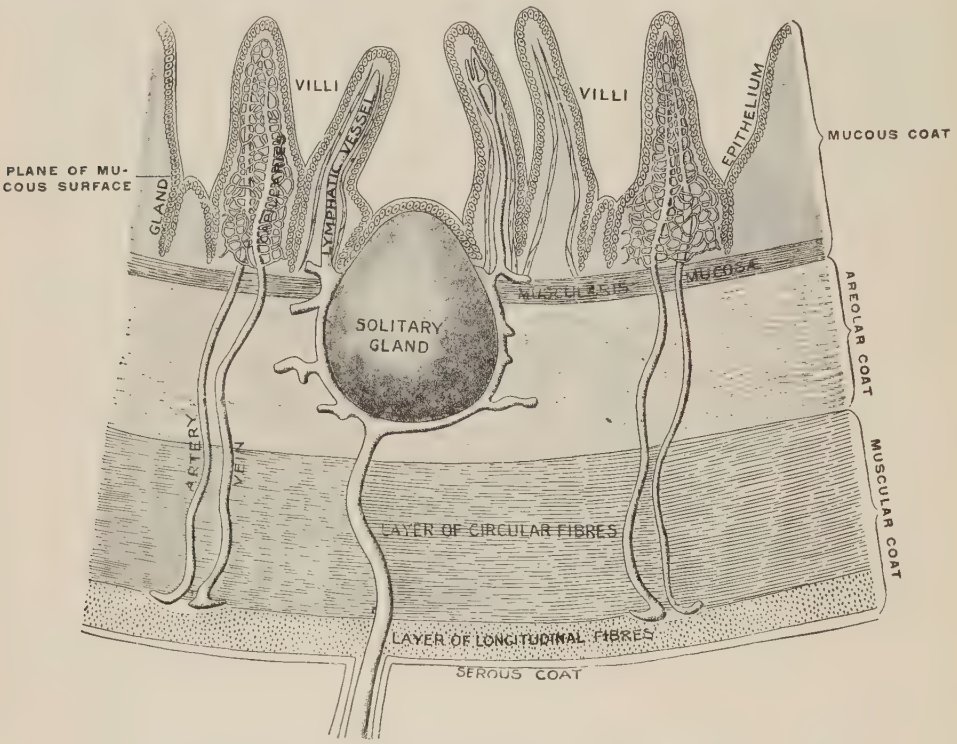

FIG. 814.—Mucosa of small intestine in ideal vertical cross-section. (Testut, after Heitzmann.)

Having now considered the features common to the whole of the small intestine, we will study each portion of it in detail.

THE DUODENUM.

The duodenum (Fig. 815) differs from the jejuno-ileum in many respects. It is much wider, thicker in wall, more deeply situated, more complex in structure, contains certain glands peculiar to it, and is the part into which the ducts from the liver and pancreas discharge; but it is much shorter, far less mobile, has only a scanty serous covering, and has none of the aggregated lymph-nodules. Its length is ten inches or less, its width two inches or less. It extends in a tortuous course from the pyloric opening to the point where the mesentery first embraces the gut, that is, at the left side of the second lumbar vertebra. It is conveniently divided into four portions, of which the first, about two inches long, runs back, up, and to the right under the quadrate lobe of the liver to the neck of the gall-bladder; the second descends for about three inches along the right edge of the head of the pancreas, to the level of the lower border of the third lumbar vertebra; the third passes to the left horizontally two inches and a half, which brings it to the middle of the vertebral column, where it is crossed by the superior

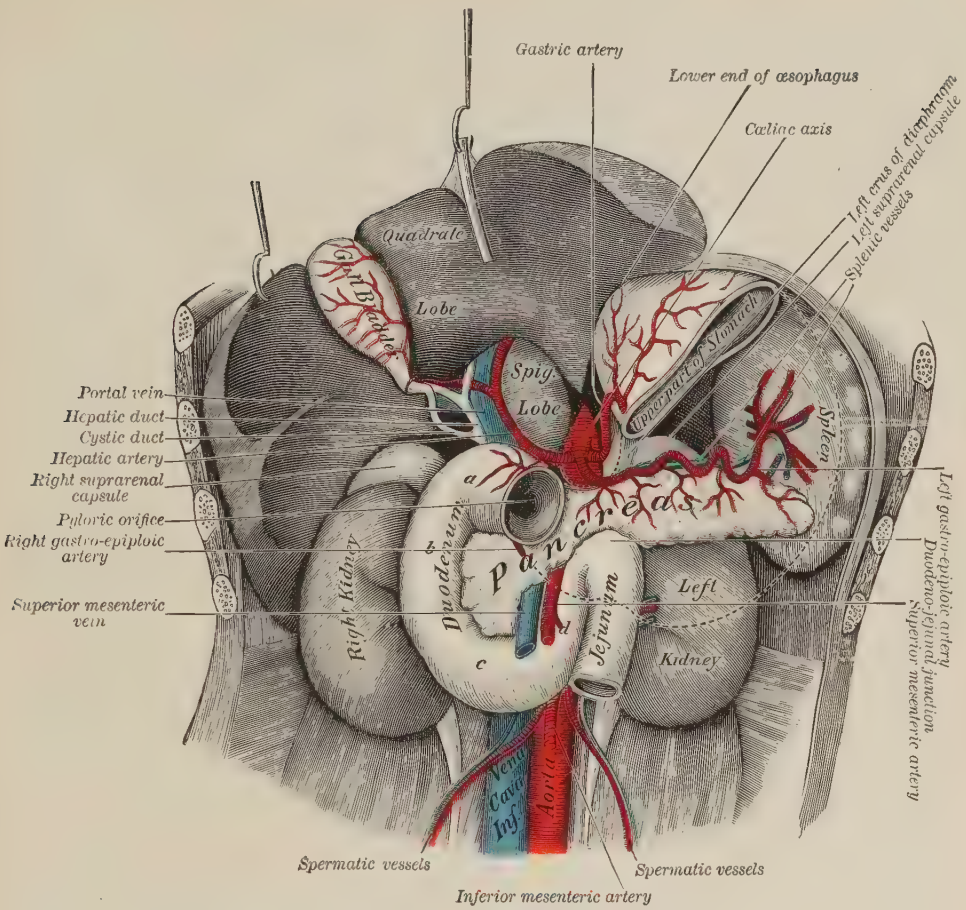

FIG. 815.—The duodenum, its four parts marked *a*, *b*, *c*, *d*. The liver is lifted up; the greater part of the stomach is removed, broken lines indicating its former position. (Testut.)

mesenteric vessels; and the fourth ascends on the left of the column and ends in the jejuno-ileum, which descends from the line of junction very abruptly. Thus,

FIG. 816.—Diagram of cross-section of the first part of the duodenum, to show its peritoneal relations.

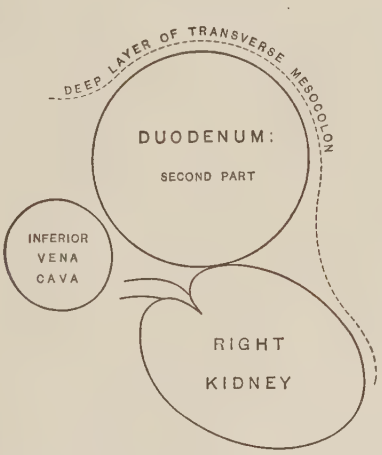

FIG. 817.—Diagram of cross-section of the second part of the duodenum, to show its peritoneal relations.

the duodenum, after describing an irregular curve, suggestive of an imperfect circle, almost returns to its starting-point.

Its *serous coat* is incomplete and irregularly applied. The first part is covered like the stomach; the second is clothed in front; the third above, below, and in front; the fourth in front and partly at the sides. The second part is closely adherent to the front of the right kidney and the head of the pancreas, and includes in its wall the terminal portions of the common bile-duct and the pancreatic duct; the third part is attached to the vena cava inferior, the aorta, and the right crus of the diaphragm; and the fourth is fastened to the left side of the vertebral column, the left kidney and its vessels. The relations of the peritoneum to each of the parts of the duodenum will be seen easily by consulting the diagrams, Figs. 816–819. The first part is somewhat movable, but the others are so bound down by the peritoneum and their close connections with other structures as to be practically fixed in their places. Still another agency contributes to this immobility—the *suspensory muscle*, a delicate, flat, fibro-

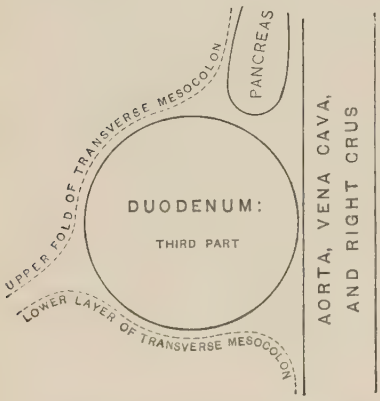

Fig. 818.—Diagram of the third part of the duodenum, to show its peritoneal relations.

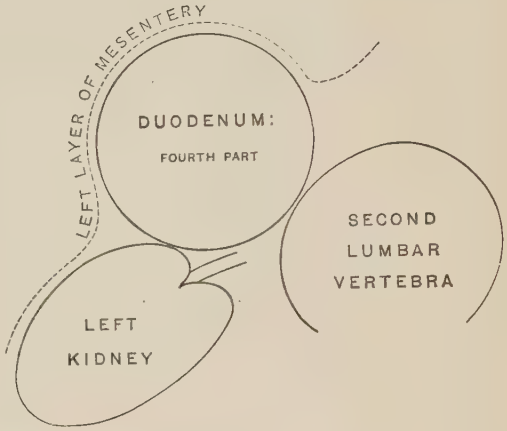

Fig. 819.—Diagram of the fourth part of the duodenum, to show its peritoneal relations.

muscular band, which starts from the left crus of the diaphragm, and runs downward to its insertion on the duodeno-jejunal angle and the dorso-mesial aspect of the fourth part of the duodenum.

Relations.—The first part has the quadrate lobe of the liver and the gall-bladder above; the portal vein, hepatic vessels, and common bile-duct behind; the pancreas below. The second part has the transverse colon in front; the vena cava inferior and the right kidney with its vessels behind; the common bile-duct and the head of the pancreas mesially; and the colon in the region of its hepatic flexure at the right. The third part is crossed in front by the superior mesenteric vessels; the aorta, vena cava inferior, and right crus of the diaphragm are behind; the pancreas and superior mesenteric artery lie above. The fourth part has the aorta and second and third lumbar vertebræ mesially; and the left kidney with its vessels, and the left crus of the diaphragm behind.

The *valvulæ conniventes* are particularly well developed in this bowel. In the areolar coat are situated many spheroidal, compound, racemose glands, which open upon the free surface. They form an almost complete layer under the true mucosa at the upper part of the duodenum. They are peculiar to this portion of the small intestine, and hence are called *duodenal glands*, although they are often known as the *glands of Brunner* (Fig. 820).

About the middle of the concave side of the descending (second) part is the common *opening of the pancreatic and bile ducts*.

FIG 820.—Duodenal gland. (Frey.)

THE JEJUNO-ILEUM.

The principal features of the small intestine having been presented, the jejuno-ileum, which is the main part of it, requires but little special attention.

Beginning at the termination of the duodenum, it is thrown into convolutions so numerous and so irregular in their disposition that it is impossible to lay down a rule by which sight alone can distinguish a proximal from a distal portion. However, in general there is some probability that its proximal half is located above and at the left, its distal below and at the right.

To determine whether a knuckle of intestine is proximal or distal to another, one is assisted by digital examination of the part of the mesentery belonging to each. The convolution whose mesentery is the higher is nearer the stomach. This method not only is more expeditious, but it prevents the injury which the bowels may suffer from prolonged manipulation.

The last portion of the jejuno-ileum reaches the large intestine from the left and below.

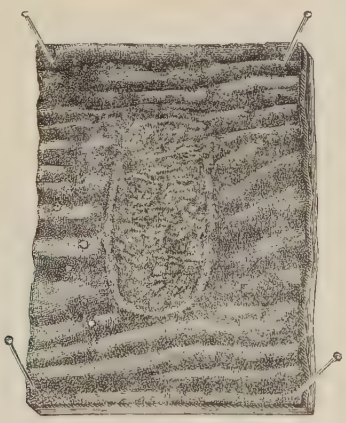

FIG. 821.—Aggregated lymph-nodule (Peyer's patch). (Testut.)

The jejuno-ileum begins with a diameter of nearly an inch and a half, with closely set villi, long, deep, and numerous valvulæ conniventes, and a fairly thick muscular coat; it ends with a cross-measurement of hardly an inch, with

scanty villosities, no connivent valves, and a thinner musculature. In a single direction only has it made a gain—the addition of the *aggregated lymph-nodules*, otherwise called the agminated glands and the *patches of Peyer* (Fig. 821). These are local accumulations of bodies in all essential respects like the solitary lymph-nodules, which are scattered throughout the length of the small intestine—they are colonies of lymph-nodules. They produce scarcely any elevation of the surface, but are not crossed by connivent valves; they are always situated at the free border of the tube, with their greater diameter lengthwise of it; are rarely found in the upper half, and become larger and more numerous as the large intestine is approached; vary in size from a half inch in both directions to a width of about an inch and a length of ten inches, or possibly more; are thirty or more in number on the average; and tend to disappear gradually after middle life, so that in old people they may be recognizable only as areas of discoloration. They are the seat of the lesion in enteric (typhoid) fever.

The **blood-supply** of the jejuno-ileum is derived from the superior mesenteric artery, whose branches course between the two layers of the mesentery, are distributed beneath the serous coat, anastomose on the free border, and perforate the muscular layers, forming a rich plexus in the areolar tunic, from which the mucous and muscular are furnished with their supply of arterioles and capillaries. The *veins* correspond. Ordinary *lymphatics*, originating in the other parts, are joined by those from the villi (lacteals), and leave by way of the mesentery to empty into the receptaculum. The duodenum gets a part of its arterial blood from the superior mesenteric, and the rest through branches of the hepatic.

The **nerves** of the small intestine come from the superior mesenteric plexus, accompanying the vessels, and form one network between the layers of the muscular tunic, another in the areolar. Their exact terminations are not understood.

THE LARGE INTESTINE.

The largeness which gives a name to the next grand division of the alimentary canal is in its transverse, not in its longitudinal, diameter; for it is hardly more than a quarter as long as the small intestine, but is much wider, being two and a half inches across in its broadest part.

The large intestine (*intestinum crassum*) (Fig. 822) is divided for description into three parts—cæcum, colon, and rectum—and has so little mobility that the location and relations of each of these segments are fairly constant—a respect in which it materially differs from the small intestine.

It begins in the right and lower portion of the abdomen, passes upward and backward to the under surface of the liver, thence across the belly to the spleen, from this point downward and forward to the left and lower part of the abdomen, here makes a number of curves, and finally plunges into the pelvis at its back part, and ends close to the perineum, near the inner opening of the anal canal.

Tunics of the Large Intestine.

Its wall is thicker than that of the small intestine. Its tunics are four in number, and have the same names and the same order of arrangement as do those of the stomach and small intestine. The serous coat of each portion will be described in connection with it; the areolar presents no peculiarities requiring especial mention.

The **Muscular Coat** (Fig. 823) of all but the last few inches of the length is remarkable in that its *outer, longitudinal layer*, instead of being disposed in an unbroken sheet, as is that of the small intestine, is almost wholly gathered into

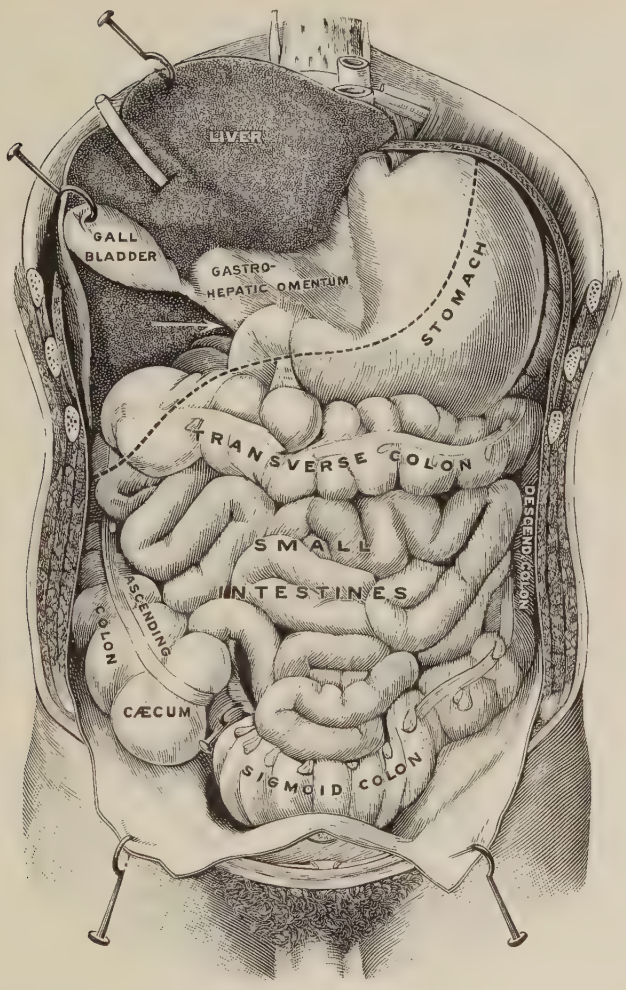

FIG. 822.—The stomach and intestines, front view, the great omentum having been removed, and the liver turned up and to the right. The dotted line shows the normal position of the anterior border of the liver. The dart points to the foramen of Winslow. (Testut.)

three equal, ribbon-like bands (*tæniæ coli*), one-third of an inch, or a little more, in width, which are placed lengthwise at equidistant intervals, the small remaining portion being spread in a delicate lamina over the residue of the tube. The *inner, circular layer*, like the subjacent areolar and mucous tunics, forms an even tube from end to end; but these outer strips of muscle are much shorter than this musculo-areolo-mucous tube, and, as their extremities are attached to its corresponding extremities, there necessarily ensues a great puckering included in their grasp. Between the bands are deep, transverse creases, each bounded by prominent bulges; and an inspection of the bore of the tube shows a sharp ridge (*plica sigmoidea*), corresponding to each depression of the outer surface, and a large recess (*haustrum*), collocated with each external protrusion. This saccula-

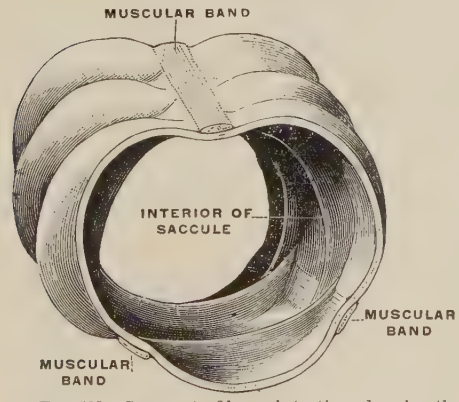

FIG. 823.—Segment of large intestine, showing the characteristic features of its structure. (Testut.)

tion and the cause of it are characteristic. Whenever one is in doubt as to whether a given knuckle belongs to large or small intestine, the presence or absence of the longitudinal ribbons will settle the question at once.

Although the ridges, which encroach upon the lumen of this gut, look like overgrown valvulæ conniventes, their structural character is radically different. A connivent valve (Fig. 824) is merely a fold of mucous membrane, strengthened by a thin plate of areolar tissue; but a plica sigmoidea (Fig. 825) is the result of an infolding of everything inside of the muscular ribbons. Remove

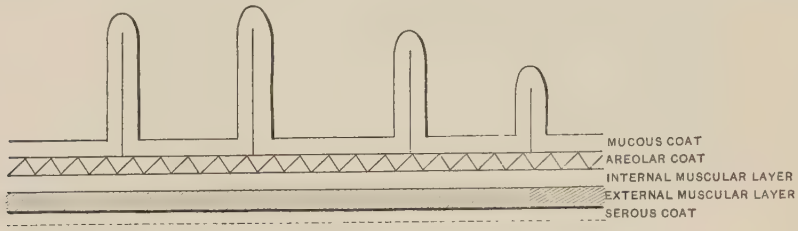

FIG. 824.—Diagram to show the structure of the valvulæ conniventes. Compare with next cut. (F. H. G.)

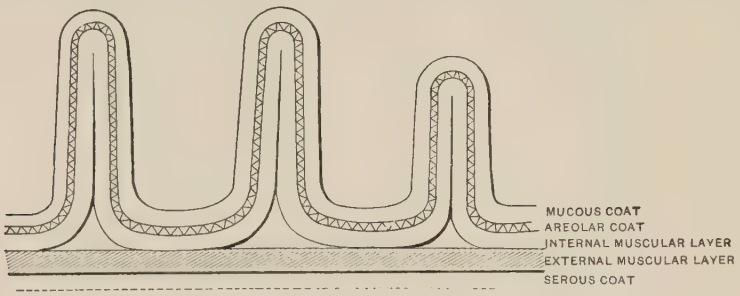

FIG. 825.—Diagram to show the structure of the plicæ sigmoideæ. Compare with the preceding cut. (F. H. G.)

these bands from the bowel, and straighten it, and the plicæ will disappear, leaving an even, uninterrupted bore; but no such result will ensue, if you dissect off the longitudinal lamina of muscle from the small intestine: the little valves will remain exactly as before.

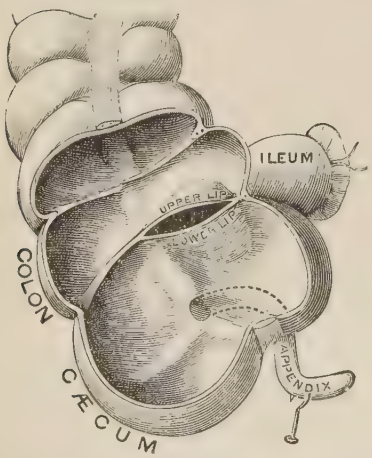

FIG. 826.—Cavity of the cæcum, its front wall having been cut away. The ileo-cæcal valve and the opening of the appendix are shown. (Testut.)

The **mucous membrane** is paler, somewhat firmer, and much simpler than that of the small intestine: there are no connivent valves, no villi, no glands of Brunner, no patches of Peyer. But there are many so-called solitary glands, though they are less numerous than in the upper bowel; and the thickness of the mucosa is occupied by simple, tubular glands, larger than those met with previously, and containing a much greater proportion of goblet cells. Indeed, in not infrequent cases, it is found that the majority of the epithelial cells are of this variety.

THE CÆCUM.

The cæcum (*cæcus*, "blind") (Figs. 826, 828) is thus named because it is a pouch, a no-thoroughfare. It is situated in the right iliac and hypogastric regions, just above the middle of the inguinal (Poupart's) ligament, and behind the anterior abdominal wall. Its blind end points downward, its open end upward, passing

directly into the colon, of which this gut seems to be the beginning, justifying its old name, *caput coli*, "the head of the colon." The line of separation between them is at the opening from the small intestine, on the left side and behind, about two and a half inches from the lower end. Here is the *ileo-cæcal* or *ilio-colic valve*, which protects the ileum against the backward flow of fæces from the large intestine. If the extremity of the ileum was simply attached to the margin of a circular hole of its own diameter in the side of the large intestine, there would be a frequent reflux from the latter, and the

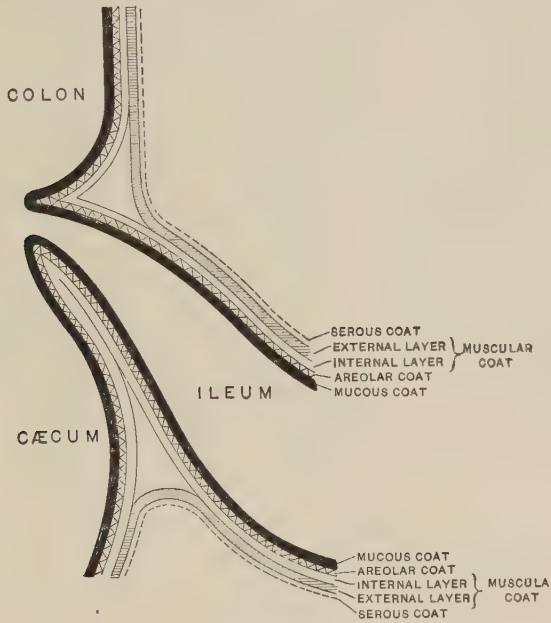

FIG. 827.—Diagram of a vertical section of the ileo-cæcal valve, showing its structure. (F. H. G.)

lower ileum would be only a receptacle for excrement. But, at the junction of the two guts, the ileum is flattened from above downward, and the serous coat and the outer layer of the muscular coat are so shortened that the other tunics are thrust into the cavity of the large intestine, forming two lips, an upper and a lower, with a horizontal cleft, like a button-hole, between them (Fig. 827). The permanency of the lips is maintained by the shortness of the outer muscular layer. The ileum enters the large intestine obliquely from below; and thus, when there is an accumulation of fæces in the cæcum, the two lips will be pressed together, and regurgitation prevented; but there is nothing in the conformation of the valve to interfere with the passage of material in the other direction. From each commissure of the lips extends a ridge, the *frænum*, which, after going part way round the bowel, shades off into the general surface. Upon that aspect of these lips which is contributed by the small intestine are villi; that which is furnished by the large intestine is devoid of them. The cæcum has a complete investment of serous membrane, but it has no mesentery.

The Appendix.

Springing from the rear of the cæcum toward its inner aspect is a blind tube, about as thick as an ordinary lead-pencil, and varying from three to six (or even more) inches in length, called the *appendix vermiformis cæci* ("the worm-like appendage of the blind gut") (Fig. 828). It has a mesentery for about half its length; its serous, muscular, and areolar coats are similar to those of the small intestine; its mucous coat has intestinal glands, and so many so-called soli-

tary glands as to constitute a nearly complete layer in and just beneath the mucosa. Its attitude varies enormously: it may stand up behind the colon, hang down behind the cæcum, lie forward toward the surface of the belly, curve to the outside, or twine around the ileum. Its development is peculiar. The cæcum is relatively much longer in the fœtal than in the adult condition. At birth it is a long cone, hardly suggesting the shape which it finally assumes. The portion nearest the colon grows and develops equally with the latter; but the remainder ceases to develop, and, being vastly outgrown and overshadowed by the upper portion, becomes an appendage to what was originally the smaller part of the blind gut. We see, therefore, that this worm-like organ has reached its present condition as the result of arrested development, and not of degeneration. Its blood-supply is from the ileo-colic artery.

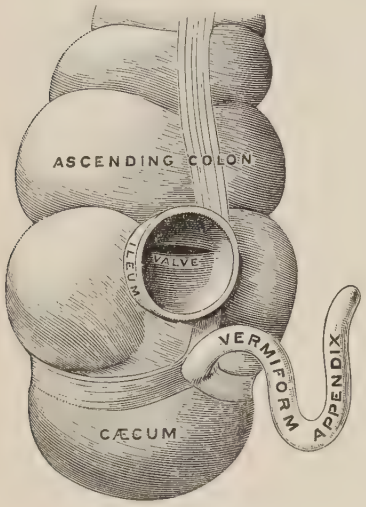

FIG. 828.—The cæcum, dorso-mesial view, showing the ileum-side of the ileo-cæcal valve, and the beginning of the three muscular ribbons. (Testut.)

The three *ribbons of muscle* previously described begin at the attached end of the appendix. One runs up close behind the ileo-cæcal junction; another curves downward, inward, and then upward on the front; and the third turns downward, outward, and then upward. From their position they are called respectively posterior, anterior, and inner. The appendix would be at the lowest extremity of the cæcum, in the adult as it is in the fœtal condition, but for the bulging of the front part of the latter downward, and especially outward, a change which brings the opening of the appendix behind and toward the middle line of the body.

THE COLON.

The colon comprises all but a mere span of the large intestine. It diminishes in size gradually from its beginning to its end. It presents four well-marked segments: the ascending colon, the transverse colon, the descending colon, and the sigmoid colon. Its serous membrane is marked at irregular intervals along the line of one of the muscular bands by little tassel-like protrusions, the *appendices epiploïcæ* ("omental appendages"), containing adipose tissue. They do not appear until after childhood, and are pronounced in proportion to the fatness of the individual. The band upon which these appendages are located is internal (mesial) in the ascending and descending portions, and underneath in the transverse.

The Ascending Colon.

The ascending colon (Fig. 829) begins at the level of the ileo-cæcal valve, passes upward and backward, and ends at the under surface of the right lobe of the liver, where it is received in the colic impression. It has no inherent peculiarities to distinguish it from other segments except in its serous tunic. The disposition of this coat determines the mobility or fixity of the part. Generally only the front and sides are clad in peritoneum, which is reflected laterally to the abdominal wall; but in a quarter of the cases a distinct mesentery, here called *ascending mesocolon*, is found. In the former case this part is immovable; in the latter its mobility is regulated by the length of its mesentery. Behind it are the quadratus lumborum, the transversalis, and the right kidney; in front,

the abdominal wall in the lower part, and, usually, some coils of jejuno-ileum in the upper.

The Transverse Colon.

The transverse colon (Fig. 829) begins at the *hepatic flexure*, which is the angle made between it and the preceding portion, and passes almost horizontally to a nearly corresponding point on the left side, where it terminates in a bend, the *splenic flexure*, between it and the descending colon. In crossing the trunk, however, it does not go in a straight line, but, keeping close to the anterior wall, describes a curve with its concavity backward, and displays thrice the length that it would, if it ran directly from side to side. It often sags a little in the middle. This part of the colon is provided with a mesentery, the *transverse mesocolon*, which varies greatly in length in different subjects. Its proximal border is fastened to the hind wall of the abdomen, its distal is attached to the gut along the line of the postero-inferior muscular band. The antero-inferior band is decorated with appendices epiploïcæ, and the superior is the base from which depend the hind layers of the great omentum. The liver, gall-bladder, stomach, and spleen are above; small intestine below; the great omentum and abdominal wall in front; the duodenum and part of the jejuno-ileum behind.

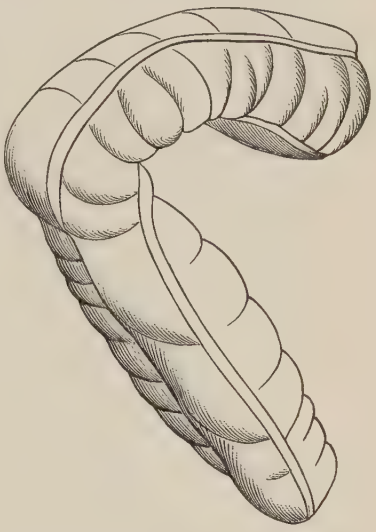

FIG. 829.—Ascending and transverse colons, viewed from the right side. (Drawn from the His cast. F. H. G.)

The Descending Colon.

The descending colon is situated in the left hypochondriac and lumbar regions. It is almost the exact counterpart of the ascending colon; but it is a little smaller in bore, a trifle longer—the great thickness of the liver preventing the ascending colon from reaching quite as high a plane as that from which the descending starts—and somewhat farther back in its upper portion. It ends at the level of the crest of the ilium—an arbitrary and conventional limit, there being no inherent, natural mark of separation between it and the next division. It is furnished with a mesentery, the *descending mesocolon*, in about one-third of all cases, the hind surface having no serous covering in the rest. A fold of peritoneum, the *phreno-colic ligament*, extends from the diaphragm near the spleen to the left side of the colon near the splenic flexure, and assists in keeping the bowel in place.

The descending colon is related behind to the diaphragm, the quadratus lumborum, and the left kidney; and coils of the small intestine cover a considerable portion of it in front.

The Sigmoid Colon.

The sigmoid colon (Figs. 830–832) is often called the sigmoid flexure; but as the term "flexure" is used to designate the bends between the horizontal and the two vertical portions—mere angles in, and not parts of, the tube—it is confusing to have the same name applied to a portion of the bowel, which, while the seat of complicated flexions, includes a considerable length of the intestine. "Sigmoid colon" signifies a part of this intestine, whose form is so tortuous as to suggest the Greek letter sigma, and seems, on the whole, to be the best of its numerous titles.

The Limits of the Sigmoid Colon.—The sigmoid colon is the most movable and the most variable of the divisions of the large intestine. It is continuous below with the rectum, and most authors fix the dividing line between the two opposite the joint of the left hip-bone with the sacrum. But the result of many careful observations shows that, while the large intestine crosses this articulation in some

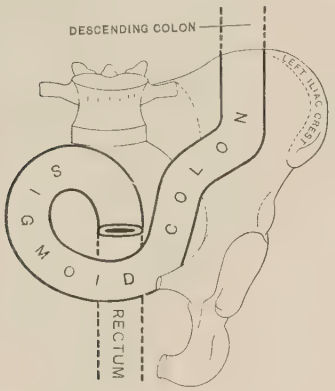

FIG. 830.—Sigmoid colon, front view. Semidiagrammatic. (Testut.)

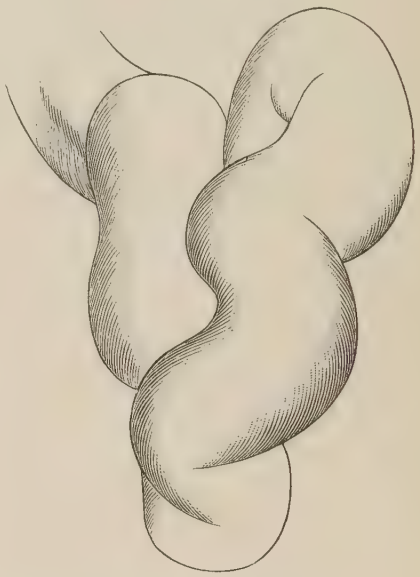

FIG. 831.—Sigmoid colon, dorsal view. (Drawn from the His cast. F. H. G.)

cases, in the majority this condition does not obtain. Even if the classical description were in accordance with the fact, there would seem to be little wisdom in separating these two territories of intestinal surface by this extraneous and purely arbitrary boundary, thus depriving the sigmoid colon of a portion of intestine exactly like its major part in structure, and bestowing it upon the rectum, from which it materially differs. A few recent writers, recognizing the expediency of adopting the intrinsic dividing line, which nature has established, have discarded the extrinsic and artificial boundary, and confine the application of the name "rectum" to that portion of the bowel below the brim of the true pelvis which has no mesentery. This method is here adopted.

The sigmoid colon (Fig. 830) begins on the plane of the crest of the left ilium, and thence usually passes down to within an inch and a half of the inguinal (Poupart's) ligament, bends sharply toward the middle line, crosses the psoas magnus muscle, dips into the cavity of the true pelvis, rises to the brim on the right side, and thence curves backward, downward and inward to about the third sacral vertebra at the median line, where it becomes continuous with the rectum. It is 14 or more inches long. For its uppermost three inches it has a serous covering on its front and sides only, except in those cases where the descending colon has a mesentery; but below this it has a mesocolon in its entire length. The *sigmoid mesocolon* is much longer in the middle portions than toward the ends. Its proximal attachment crosses the psoas, passes in front of the bifurcation of the iliac arteries and then runs downward to the third segment of the sacrum. The diameter of this part of the intestine is less than that of the preceding, and constantly, though gradually, diminishes toward its lower end. The three longitudinal bands are continued on the sigmoid colon for most of its course; but as the end is approached, those which are behind spread out and unite into one, and at the last part the anterior has extended sidewise, and joined its fellows, so that the rectum begins with a uniform outer layer of its muscular tunic.

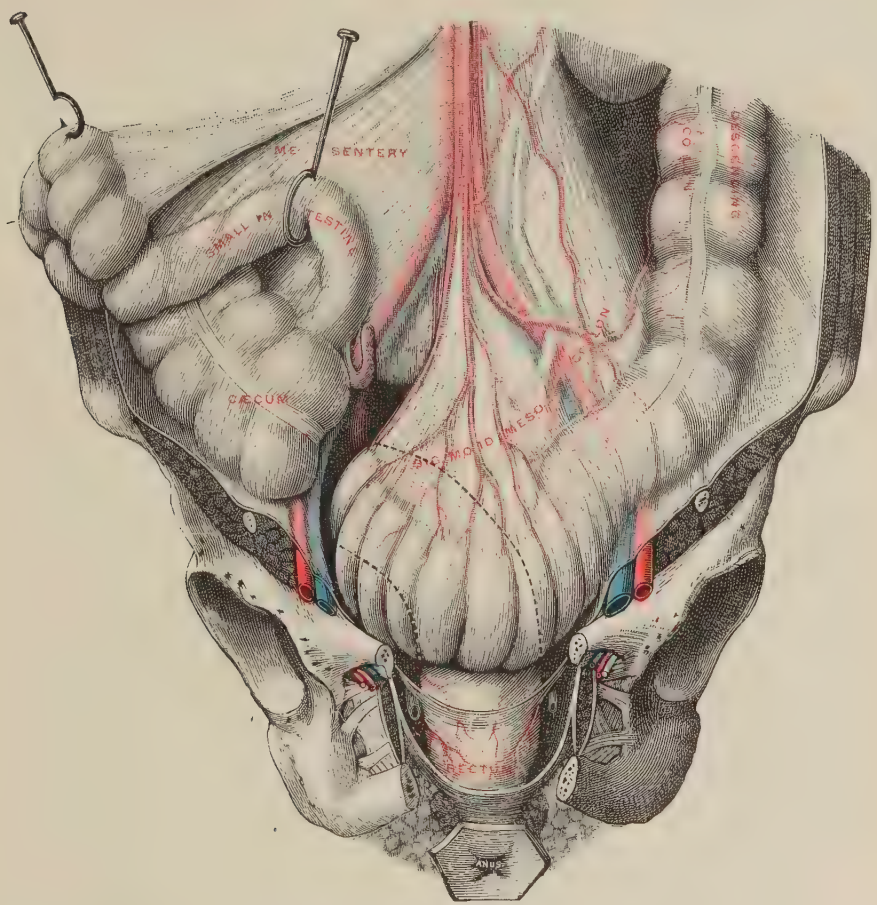

FIG. 832.—Sigmoid colon and rectum, front view. The broken lines indicate the situation of the concealed part of the sigmoid colon. The small intestine is drawn away, and the anus is turned forward. (Testut.)

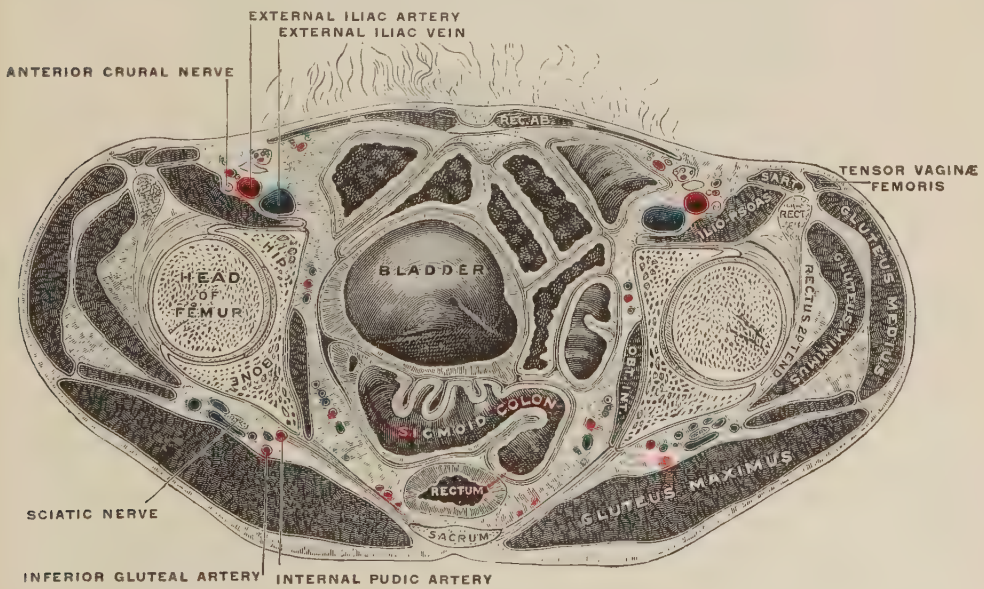

FIG. 833.—Horizontal section three inches below the sacral promontory. The upper surface of the lower segment. (Testut.)

THE RECTUM.

The rectum (Figs. 834, 835) begins at the point where the large intestine ceases to be provided with a mesentery, that is, in general, at the front of the third sacral vertebra in the middle line. Its name, which means "straight," is

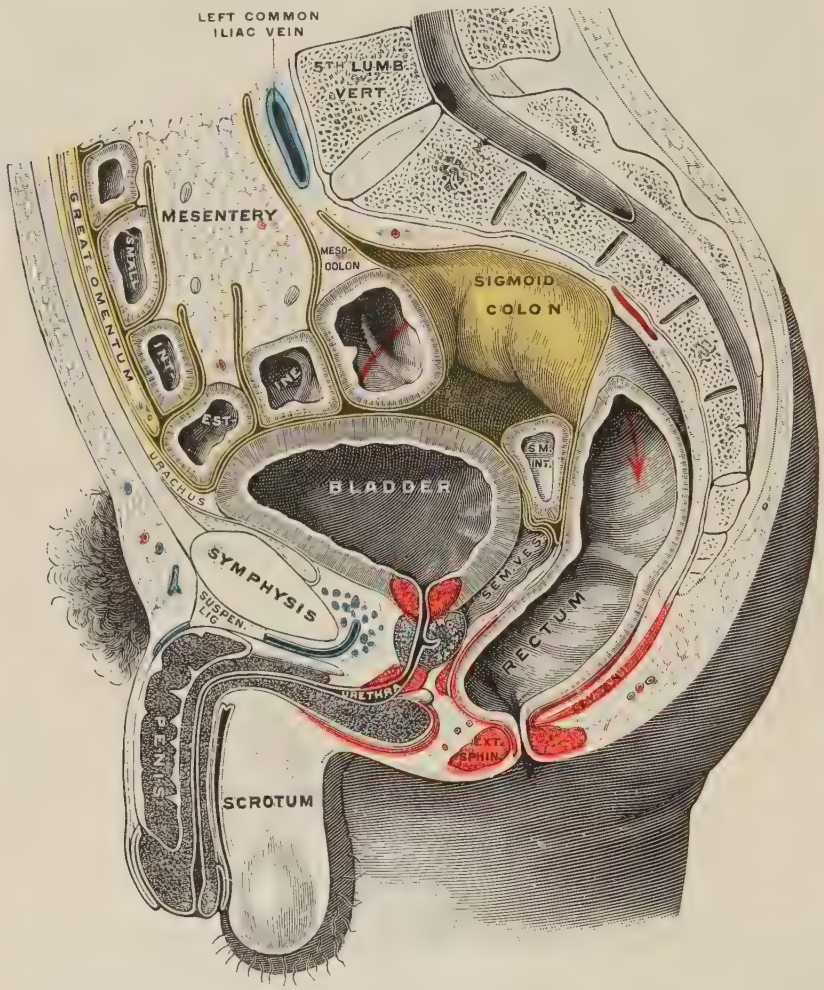

FIG. 834.—Sagittal section of the lower part of a male trunk, the right segment. (Testut.)

made less absurd by the adoption of our present plan of delimitation of the intestines in this region, than it was when this segment was made to start at the sacro-iliac joint; for then it was crooked from every point of view, while now, when looked at from in front, it comes near deserving its title.

It occupies the middle line, and is divided into an upper part, which is furnished with a covering of peritoneum, and a lower, which is not. The *upper part*, about three inches long, extends from the third sacral vertebra to the tip of the coccyx, and its shape conforms to the curve of these bones, to which it is attached behind. The *lower part*, shorter than the upper, is continued with the same dorsoventral curve, and terminates in a forward pouch, which is close to the prostate gland in the male and to the lower part of the vagina in the female.

If the lower opening of the alimentary canal were made at the end of this pouch, and in the line of its curve, the anus would be situated in the male just back of the attachment of the scrotum and in the female near the vaginal entrance. The curve of the rectum, thus extended, would present an even sweep from its

FIG. 835.—Sagittal section of the lower part of a female trunk, right segment. (Testut.)

upper to its lower end. The opening, however, is not thus placed, but is located in the under side of the rectum, considerably to the rear of its blunt end. The part of the intestine in front of this opening is called the *rectal ampulla*.

The **muscular coat** is thick and strong at all points, and consists of two layers, the external being the longitudinal, the internal the circular, and both evenly spread.

The **serous tunic** covers only a portion of the first part, and none of the second. This coat is most extensive in front, and is absent behind; and the line at which it leaves the gut slopes from above downward and forward very rapidly. It is reflected onto the bladder in the male, and the vault of the vagina and the uterus in the female. The peritoneum may extend down upon the rectal surface of the bladder to an inch above the prostate. Where there is no serous coat the rectum is covered with strong areolar tissue.

The **mucous membrane** is thicker and denser than that of the colon, and its hue

deepens to a decided red in the lower part. It usually presents from one to three permanent transverse folds, *plicæ recti* (Houston's valves), which may go a third of the way around the lumen. The most constant of these shelves is near the lower part of the bladder, and extends dorsally about half an inch. At the margin of the opening from the rectum to the anal canal are five or six small crescentic loops, *semilunar valves* (Fig. 836), separated by vertical ridges, the *anal columns*, upon which are little protrusions due to hemorrhoidal veins.

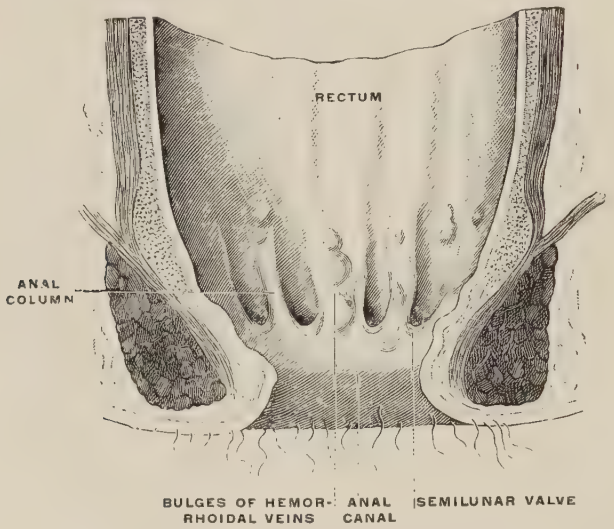

FIG. 836.—The anal canal and lower part of the rectum, laid open. (Testut.)

Blood-supply of the Large Intestine.—The rectum receives its blood from the superior hemorrhoidal branch of the inferior mesenteric artery, the middle hemorrhoidal of the internal iliac, and the inferior hemorrhoidal of the pudic. The other parts of the large intestine are supplied by the inferior and superior mesenteric. The veins are the inferior and superior mesenteric, which empty into the portal. The lymphatics are similar to those of the small intestine, and this, also, may be said of the nerves.

THE ANAL CANAL.

The anal canal (Figs. 834–836) is the channel by which the rectum is placed in connection with the external surface of the body. It is an inch long, and runs downward and backward. It is lined with a membrane, which is mucous at the upper end, cutaneous at the lower, and a cross between the two elsewhere. Outside of this lining is an embracing muscle, the *internal sphincter*, composed of bundles of smooth fibres, arranged circularly. The lateral walls of the tube are in contact, and the lining membrane is disposed in small, longitudinal folds. The distal aperture is the *anus*, and around it the skin is dark brown, and puckered in radiating lines.

GLANDS ACCESSORY TO THE ALIMENTARY TUBE.

In the development of the digestive canal bud-like processes grow out from it at several points, and ultimately become glands, furnishing abundant secretions, which are discharged into the tube through ducts. These glands are the salivary, the pancreas, and the liver, and they will now be considered in the order given.

THE SALIVARY GLANDS.

The *saliva* is a compound fluid, resulting from the mixture of the secretions of a number of glands, which discharge their products into the mouth. There are many *mucous glands*, two collections of which on each side require mention. One is at the hind part of the oral portion of the tongue, at the side and below, and is called the *gland of Weber* (Fig. 837, GL. W.). The other is near the under side of the tip, and is known as the *gland of Blandin* (Fig. 837, GL. B., and Fig. 800). The so-called salivary corpuscles are derived from the *tonsils*. But the great volume of the saliva is furnished by three pairs of glands—the parotid, the submaxillary, and the sublingual. Of these the first produces a watery (serous) secretion, the third a glairy (mucous) one, and the second a fluid which is between the two others in consistency.

The Parotid Gland.

The parotid ("near the ear") gland (Fig. 837) is the largest salivary gland, and is situated in the side of the face, extending from the zygoma to the angle of

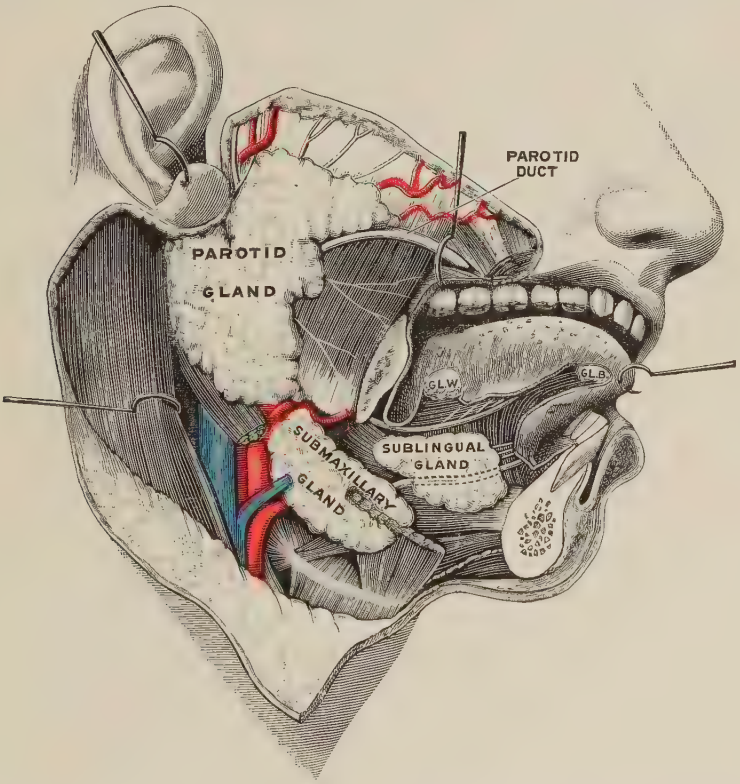

FIG. 837.—The salivary glands. The right half of the body of the mandible has been removed. GL. W., gland of Weber. GL. B., gland of Blandin. (Testut.)

the mandible, and from the external auditory meatus and the sterno-cleido-mastoid muscle forward upon the masseter, dipping deeply between the ramus and the mastoid, and pushing in between the pterygoid muscles. It is bound down by the masseteric fascia. The *parotid* (Stenson's) *duct*, a fibro-muscular tube, lined with mucous membrane, by which the saliva is discharged, leaves the gland at its front border, and passes forward horizontally about three-quarters of an inch below the zygoma for two and a half inches. On reaching the anterior margin

of the masseter, it turns mesially, and perforates all of the buccal layers, except the mucosa, on the outer surface of which it then courses forward until it reaches a point opposite the second upper molar tooth, where it pierces the membrane, and ends in a contracted orifice. Usually an appendage, the *glandula socia parotidis*, lies above the first part of the duct, and pours its secretion into it.

The parotid gland is in close relation with many important structures. In its substance the external carotid artery divides into the internal maxillary and the temporal, and these give off branches before emerging from the gland; the temporo-maxillary vein is formed and divides; the facial nerve radiates into its branches; and here are found branches of the great auricular nerve, the auriculo-temporal nerve, and several lymph-nodes. On its outer surface are a few lymph-nodes, and its deep surface is close to the internal carotid artery, the internal jugular vein, and the ninth, tenth, and eleventh cranial nerves. It reaches upward to the glenoid fossa, and downward to the stylo-mandibular ligament, by which it is parted from the submaxillary gland. Its blood-supply is derived from branches of the external carotid, its veins run to the temporo-maxillary, its lymphatics empty into the upper deep cervical, and its nerves are derived from the facial, auriculo-temporal, great auricular, and carotid sympathetic plexus.

The Submaxillary Gland.

The submaxillary gland (Fig. 837) is about a third as large as the parotid. It is lodged in a chamber of the deep cervical fascia, mostly below the body of the mandible, and upon the mesial side of its angle. The stylomandibular ligament runs between it and the parotid, and the mylohyoid muscle separates it from the sublingual gland. The facial artery grooves its back and upper border. The *submaxillary duct* (Wharton's) is two inches long, runs forward and inward beneath and mesial to the sublingual gland to the side of the frænum linguæ, where it ends in a constricted orifice, close to its fellow of the opposite side. It lies in a part of its course on the hyoglossus muscle between the hypoglossal and lingual nerves.

The submaxillary gland is supplied with blood by branches of the facial and lingual arteries. Its nerves come from the submandibular ganglion and the sympathetic.

The Sublingual Gland.

The sublingual (Fig. 837) is the smallest of the salivary glands. It lies upon the mylohyoid muscle in the gutter between the side of the tongue and the mandible, forming a long elevation beneath the mucous membrane of this part of the floor of the mouth. It has twenty or less ducts, which open for the most part directly above the gland, a few perhaps into the duct of the submaxillary. The sublingual and submental arteries supply it with blood, and its nerves come from the lingual.

Structure of the Salivary Glands.—All of the salivary glands are of the compound racemose variety. They consist of lobules, which are held together by a variable amount of areolar tissue. Each lobule is an aggregation of acini ("grapes") or alveoli, which are the globular or tubular sacs, constituting the active part of the organ. These sacs are so nearly filled with secreting epithelial cells that the central channel is extremely small. The ducts nearest the acini are the radicles of the great stem which finally emerges from the gland.

THE PANCREAS.

The pancreas ("all flesh") (Figs. 838, 839) so closely resembles the parotid that it is sometimes called the *abdominal salivary gland*. In some lower animals it is known as the *sweetbread*. It lies across the front of the first and second

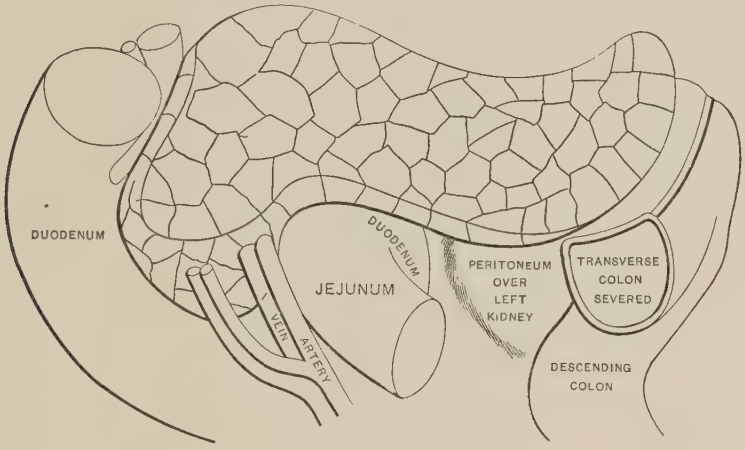

FIG. 838.—The pancreas, ventral view. The superior mesenteric vessels are seen at the lower part of the head. (Drawn from the His cast. F. H. G.)

lumbar vertebræ, and behind the stomach in the epigastric and left hypochondriac regions. It is covered anteriorly by the upper of the two layers of peritoneum, which go to form the transverse mesocolon. Its numerous lobes are held together so loosely that the whole mass is flabby, and can easily be moulded into shapes which are only remotely suggestive of the normal, which was not known until

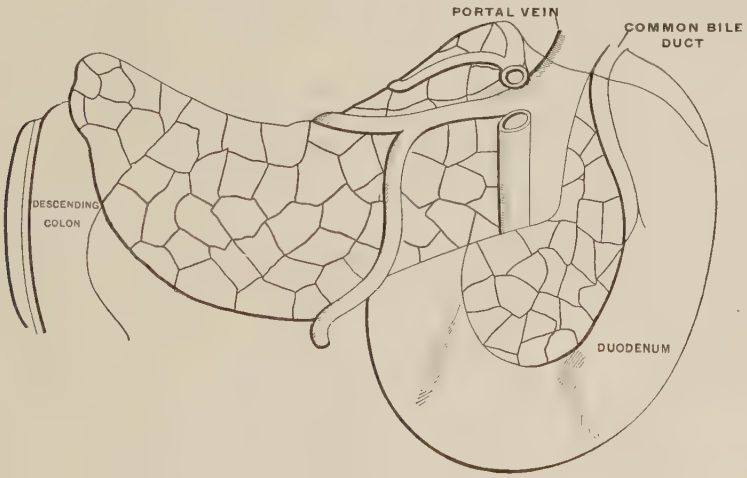

FIG. 839.—The pancreas, dorsal view. The head is seen in the embrace of the duodenum. The portal vein and superior mesenteric artery lie behind the neck. (Drawn from the His cast. F. H. G.)

revealed by modern methods. It is a body of irregular form, flattened from before backward, and curved from right to left over the vertebral column. We recognize anterior and posterior surfaces of considerable extent, a narrow lower surface, an upper border, and right and left extremities. Its right end spreads out into a *head*, which fills the curve of the duodenum, to which it is firmly attached. Its left extremity is the *tail*, and reaches into the left hypochondriac

region, even to the spleen. The intervening portion is the *body*, and on its hind surface is marked off from the head by a vertical depression, sometimes called the *neck*, in which are lodged the portal vein and the superior mesenteric vessels. All of the pancreas except the head is quite movable.

The *color* of the gland is pinkish, its *weight* between two and three ounces, its *length* about six inches, its *breadth* two inches, and its *thickness* half an inch or a little more. In infancy and early youth it grows rapidly, and in old age it undergoes atrophy.

Relations.—The stomach lies in front of the body of the pancreas, and the transverse colon and its mesentery cross the lower end of the head, which is also in relation to the superior mesenteric vessels. Behind the gland are the portal and superior mesenteric veins, the superior mesenteric artery, the inferior vena cava, the aorta, the crura of the diaphragm, the left kidney and suprarenal capsule. Below are the jejunum, the jejuno-duodenal junction, and the splenic flexure of the colon. Above the neck is the pyloric end of the stomach, and the splenic artery runs along the upper margin of the body. At the right the common bile-duct lies between the gland and the duodenum. At the left is the spleen.

The Structure of the Pancreas (Fig. 840).—Structurally it is a compound acinous gland, consisting of minute tubes, coiled up in little masses, called lobules. These are bunched together into lobes, and all the parts are held in more or less close relation to one another by areolar tissue, which spreads out over the surfaces everywhere, and is also continuous with that of the immediate neighborhood.

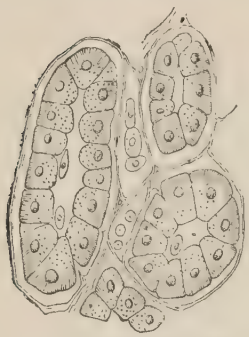

Fig. 840.—Cross section of pancreatic acini. (Testut.)

The *secretory cells* are commonly short cones, whose apices point toward the lumen of the tube. Besides these are certain cells of spindle-shape, lying against the free ends of the first mentioned, and protruding into the bore —called the centro-acinous cells.

The **excretory ducts** at their beginning are fine tubes, consisting of a single layer of flattened epithelium, and lying in the delicate connective tissue. The union of these forms larger ducts, and these in turn join to make those of greater size, until a single great channel, the *pancreatic duct*, results. As the tubes increase in size, a fibrous coat is added outside of the epithelial, and this is thickest in the largest ducts.

The **pancreatic duct** (Fig. 841) runs from the tail to the head, in the very centre of the gland, and then bends downward, leaves the pancreas, enters the wall of the duodenum in the concavity of its second portion, unites with the common bile-duct, and the compound duct perforates the mucous membrane. An *accessory duct* is usually found, springing from the main duct at about the neck of the gland, and emptying into the duodenum an inch above the other. The duct is composed of fibrous tissue, lined with mucous membrane.

Development.—The pancreas begins in the embryo as a sprout from the intestine, and this initial tube and its branches become the ducts of the mature organ, the true gland tissue budding from these little stalks as leaves form upon a twig.

The vessels follow the interlobular connective tissue, and, as in all glands, are supplied as capillaries to the secreting organism.

The *arteries* of the pancreas are branches of the splenic and hepatic, and the inferior pancreatico-duodenalis from the superior mesenteric. Its *nerves* come from the solar plexus.

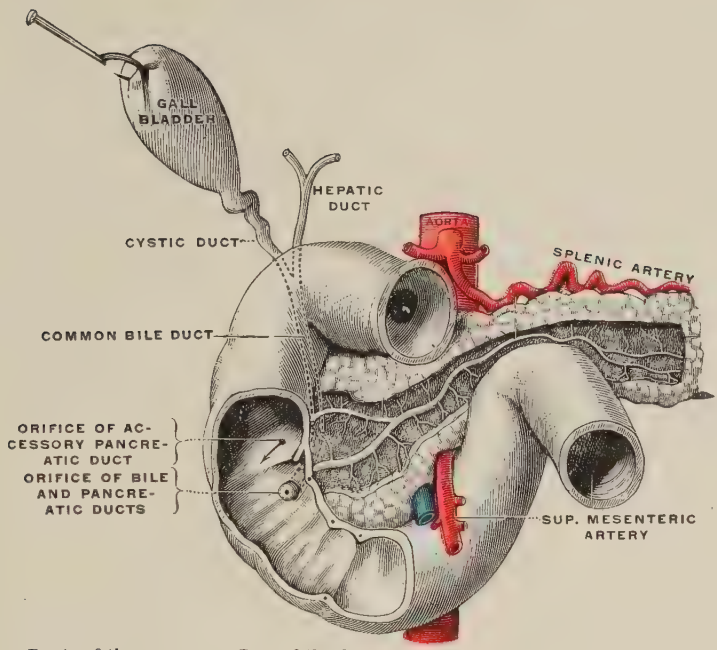

FIG. 841.—Ducts of the pancreas. Part of the front wall of the duodenum is cut away. (Testut.)

THE LIVER.

The largest and most complex of the appendages of the alimentary tube is the liver (*hepar*). Starting as a bud from the duodenum in the second week of embryonic life, it grows with such rapidity that by the second month its weight is one-third of that of the entire body. Though not retaining this relative magnitude, it remains as the greatest gland of the body, and the most intricate.

PHYSIOLOGICAL ANATOMY OF THE LIVER.

Physiologically considered it is a community of minute livers, all substantially alike; and thus a comprehension of one of them is sufficient to put us in possession of the anatomical facts requisite for understanding the functions of the entire system.

We are assisted in our study of the liver by comparing it to a great manufacturing town, made up of a vast number of establishments, each of which is identical with every other in its organization, size, facilities for work, and the quality and quantity of its products. Formerly it was supposed that the only service of the liver was the formation of bile; and although it is now known that the secretion of this fluid is only one of several offices performed by this organ, it is convenient for our present purpose to take bile-making as the type and representative of the entire group of functions.

A Typical Lobule.

We will begin by studying a single factory, that is, a separate *lobule of the liver*. It is an irregular, polyhedral body, a twelfth of an inch or less in diameter. As in every other true gland, the secreting cells are the essential part of the lobule, and of these there is a multitude, packed together so closely that only enough room is left between them to permit the passage of the minute vessels and nerves. The *hepatic cells* are the workmen of the factory. To them the materials

out of which they are to make bile are brought in the blood of the *portal vein*. Unlike veins generally, the portal divides into a vast number of branches, and a network of these encloses the lobule. From these embracing vessels, which are very minute, capillaries are sent inward between the cells of the lobule in such abundance that each cell is surrounded by them, and is thus plentifully supplied with blood containing the raw materials which the cell is capable of working over into a new product, the bile. The cells having abstracted the stuff which they require in their manufacturing processes, the blood passes on, and, at the centre of the lobule, to which point all of the capillaries converge, it enters a vein which runs perpendicularly to the course of the peripheral vessels, and carries the blood away from the lobule.

Beginnings of the Bile-ducts.—The surfaces of the cells are grooved in such a manner that the gutters on the adjacent surfaces of two cells fit together and make a cylindrical channel; and into this passage-way, which may be regarded as a drain-pipe, the bile is poured as soon as it is formed by the cell. These channels form a network among the cells throughout the lobule, as intricate as the plexus of blood-vessels; and from this network the bile is discharged into ducts, which ramify abundantly upon the surface of the lobule.

The Supply of Nutrient Blood.—When we remember that the blood furnished to the lobule by the portal vein is venous, we perceive that, however rich it may be in the materials necessary for the making of bile, it is not adapted to the nourishing of the lobule; it does not contain the substances needed for the repair of the factory or the feeding of the operatives. These nutritious and restorative matters are furnished by a separate vessel, the *hepatic artery*, which sends to each lobule branches which course over its surface and give off capillaries inward between the cells; and thus another plexus is formed in the lobule. There is not, however, a separate vein devoted to the task of removing from the lobule the blood introduced by the branches of the hepatic artery: its capillaries enter the plexus of portal-vein capillaries near the centre of the lobule, and the hepatic-artery blood mingles with the venous, flowing out with it through the central, perpendicular vein.

Lymphatics.—Besides the materials of various kinds which are carried away from the bile-factory by the channels already mentioned, there are certain unconsumed nutritious substances and certain waste products, which are removed by lymphatic vessels. These originate in irregular spaces in the lobule, form a network around it, and their current is in the direction of the stream of outflowing bile, that is, toward the portal at which the blood is introduced into the liver. Finally, there are *nerves* by which a regulation of the different processes is effected and harmony maintained among them.

Arrangement of the Vessels.

As previously remarked, the lobule is physiologically a minute liver—it is the hepatic unit; and the liver itself is merely an enormous aggregation of countless lobules, packed together as solidly as is consistent with the presence of the numerous tubes required for its nutrition and the performance of its work. But this intimate association of a multitude of lobules necessitates some modification of the description which has been given of a single one. The branches of the portal vein and of the hepatic artery, and the radicles of the bile-ducts and lymphatics, all of which have been described as ramifying upon the outside of the lobule, are seen, when the lobules are packed together, to be between the lobules; for the close approximation of a number of lobules brings the networks of vessels on the surface of each in contact with the similar plexuses on the surfaces of all of its immediate neighbors. Thus, one set of vessels can be made to supply the lobules on both sides of it, as easily as upon one side, and this is exactly what obtains. As the vessels are between lobules, they receive the name implying this, *interlobular*; the capillary networks inside of the lobule are called *intra-*

lobular ("within the lobule"), and the same name is applied to the central vein which carries away from the lobule the blood which is brought to it both by the portal vein and by the hepatic artery (Fig. 842). The *intralobular veins* in a given region discharge into a very much larger vein, upon whose outer surface rest a vast number of lobules; and, therefore, the name *sublobular* ("under the lobule") is given to this kind of veins. These last empty into still larger veins, the *hepatic*, the greater part of them converging to a few large trunks, which terminate in the *inferior vena cava*, where it lies embedded in the posterior surface of the gland, and the remainder of them reaching the same destination directly.

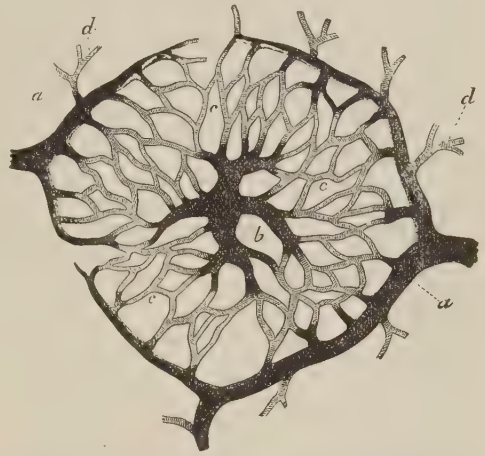

FIG. 842.—Hepatic lobule in transverse section, showing the distribution of its blood-vessels. *a*, *a*, interlobular veins; *b*, intralobular vein; *c*, *c*, *c*, plexus of capillary blood-vessels within the lobule; *d*, *d*, twigs of interlobular vein, passing to the adjacent lobules. (Dalton.)

Thus it is seen that the blood which enters the portal vein and passes through the liver, by way of any lobule, must traverse the following vessels in succession: portal vein, interlobular vein, intralobular capillary plexus, intralobular vein, sublobular vein, hepatic vein, inferior vena cava. The nourishing blood passes by way of the following vessels: hepatic artery, interlobular artery, its own intralobular capillaries, portal intralobular capillary plexus, intralobular vein, sublobular vein, hepatic vein, inferior vena cava,—its course beyond its own plexus being identical with that pursued by the portal blood.

The **Hepatic Cells**, which are the essential elements in the lobule,—the active workers in the bile-factory—are irregular bodies, with flattened sides, and each measures about one thousandth of an inch in diameter. They are composed of granular protoplasm, have no cell-wall, but each has a single, clear, central nucleus.

The Form of the Liver.

Although the liver is a solid organ, its consistency is not sufficient to prevent its changing its shape materially when it is removed from the body. If placed upon a board, its weight so causes it to sprawl in different directions as to produce an exaggerated idea of its lateral and antero-posterior dimensions, and an inadequate conception of its greatest thickness. When it is made to rest upon its upper surface, its mass sags to such an extent that the proper distinction between its inferior and posterior surfaces is obliterated, and the two seem to be one. To obtain a correct view of the liver, it should be hardened by some process while in its natural relations with contiguous organs. The pictures of its surfaces here given have been drawn from a cast of a liver frozen *in situ*. If the student will but remember that the vena cava inferior, which is for some inches actually embedded in the liver, always pursues a substantially perpendicular course, he will have no difficulty in seeing that the part of the viscus containing this great vessel must be behind and not beneath. Vesalius, the father of modern anatomy, described and figured the posterior surface in his great folio of 1555; but the correct view was lost sight of, and the grossly perverse presentation has been allowed to pass muster without question until very recent years, and even now the hind surface is not universally recognized.

The liver is located in the uppermost part of the abdomen, immediately beneath the diaphragm, and more on the right than on the left.

The liver has *three surfaces:* an upper, or superior, an under, or inferior, and

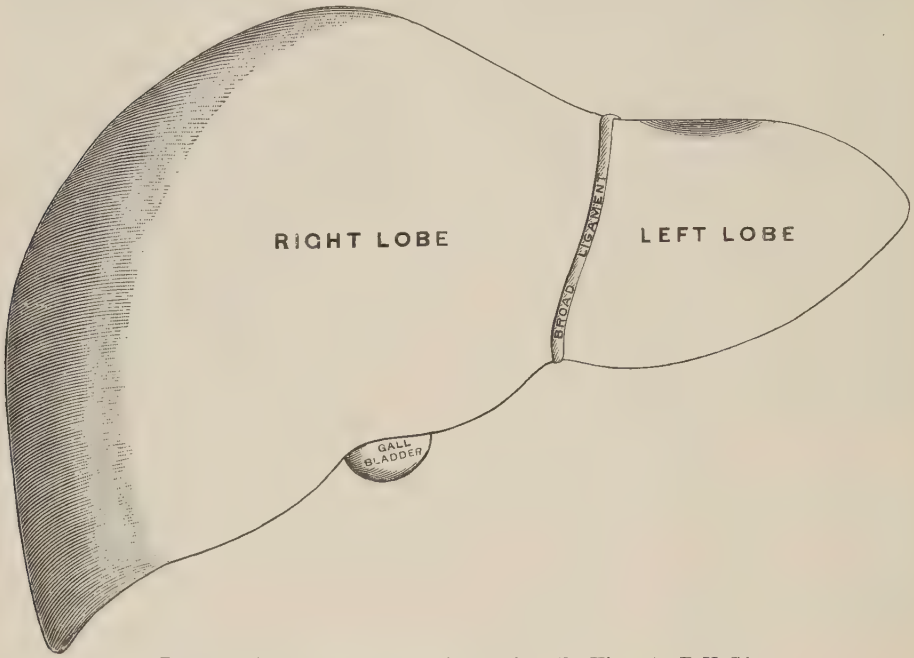

FIG. 843.—The liver, front view. (Drawn from the His cast. F. H. G.)

a hind, or posterior; *three borders*, an anterior, a postero-superior, and a postero-inferior; and *two extremities*, a right, and a left.

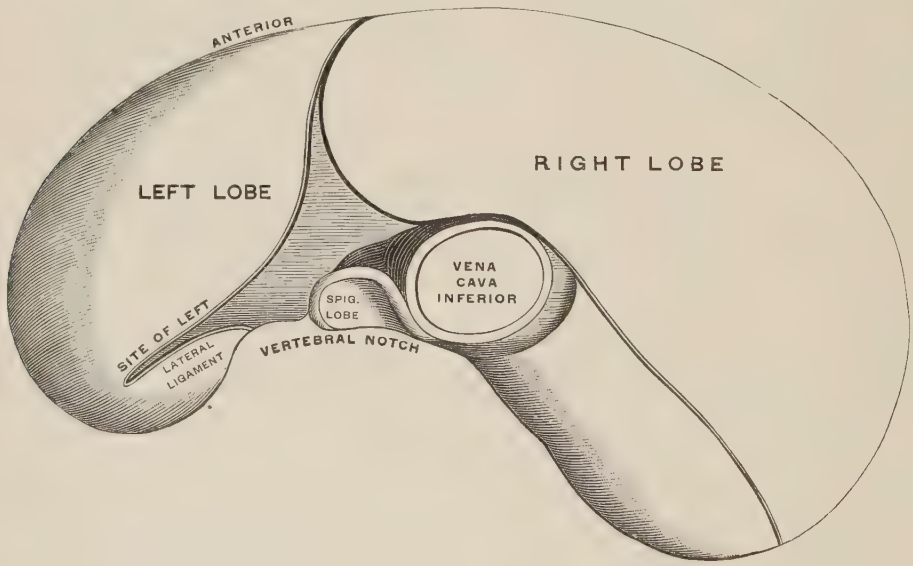

FIG. 844.—The liver, upper surface. (Drawn from the His cast. F. H. G.)

The Surfaces of the Liver.

The **Upper Surface** (Fig. 844) is smooth, and is applied evenly to the under surface of the diaphragm from the extreme right side to about half way between the middle line and the left abdominal wall. This surface, consequently, is markedly convex on the right, slightly concave near the middle of the body,

where the heart causes a sagging of the diaphragm, and moderately convex at the left. It is covered with serous membrane—a reflection of the peritoneum—excepting a very narrow strip running from before backward, and marking the line along which the membrane from the right side and that from the left meet and turn upward, and form the suspensory ligament, which thus divides the upper surface into two very unequal parts, a *right lobe* of extensive area, and a *left lobe*, which is much smaller. This division of the liver into right and left portions is observed on the hind and under surfaces also, and is made by a continuation upon them of the line marked out by the suspensory ligament. Thus, if a cord is carried directly around the organ in this plane, it will nearly coincide on the under surface with the umbilical fissure, and on the hind surface with the ductus-venosus fissure. On these surfaces, however, all of the right portion is not called right lobe, for certain subdivisions are recognized, upon each of which distinctive titles have been bestowed.

The **Under Surface** (Fig. 845) is very irregular and unevenly concave. It is divided into right and left portions by a groove, which, beginning at a notch in the anterior border, runs backward on a line substantially beneath the attachment

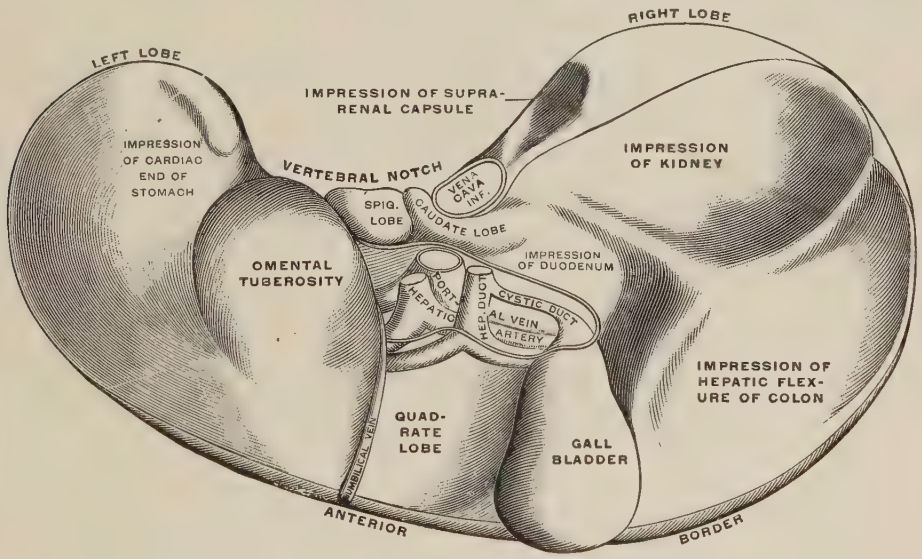

FIG. 845.—The liver, lower surface. (Drawn from the His cast. F. H. G.)

of the suspensory ligament on the upper surface. This groove gives lodgment to the shriveled remains of the umbilical vein—an important fœtal structure—from which fact it is named the *umbilical fissure*. The part of the surface at the left of this crease is the *left lobe*; that at the right is subdivided into three lobes, by two grooves. Near the hind edge of this surface is a broad gutter, which runs laterally from and at a right angle to the umbilical fissure; and from the right end of this a wide, shallow depression runs to the anterior border, parallel to the umbilical fissure. The first of these is called the *transverse fissure*, from its lateral direction; the *portal fissure*, from its being the opening or doorway at which vessels, ducts, and nerves pass into and out of the viscus; and sometimes the *hilum*, a name often given to similar inlets in other glands. The second groove is named the *gall-bladder fissure*, from the reservoir of the bile, which occupies it. Between the umbilical fissure at the left, the portal fissure behind, the gall-bladder fissure at the right, and the anterior border in front, is a squarish area, which is called the *quadrate lobe*, from its shape. At the right of the gall-bladder fissure is a large, uneven area, the *right lobe*. Behind the left portion of the portal fissure appears the lower edge of the *Spigelian lobe*, the

main portion of which is visible only from behind. Finally, a narrow ridge behind the portal fissure connects this inferior border of the Spigelian lobe with the right lobe, and is dubbed the *caudate lobe*, from its fancied resemblance to the tail of an animal. About one-half the area of the right lobe at the front and right is notably concave and receives the hepatic flexure of the colon. At the left of this, and obliquely behind the gall-bladder, is a small impression in which a knuckle of the duodenum is located; behind both of these areas is a somewhat rhomboidal hollow which is occupied by the upper end of the right kidney; and dorso-mesially from the last is a dimple in which is lodged the right suprarenal capsule. A considerable part of the surface of the left lobe is concave and fits the bulging fundus of the stomach; but there is a prominent protuberance at the right and behind (the tuber omentale) against which lie the gastro-hepatic omentum, and the smaller curvature of the stomach.

The **Hind Surface** (Fig. 846) presents two parallel, vertical grooves: one, narrow and shoal, connecting the umbilical fissure of the under surface with the

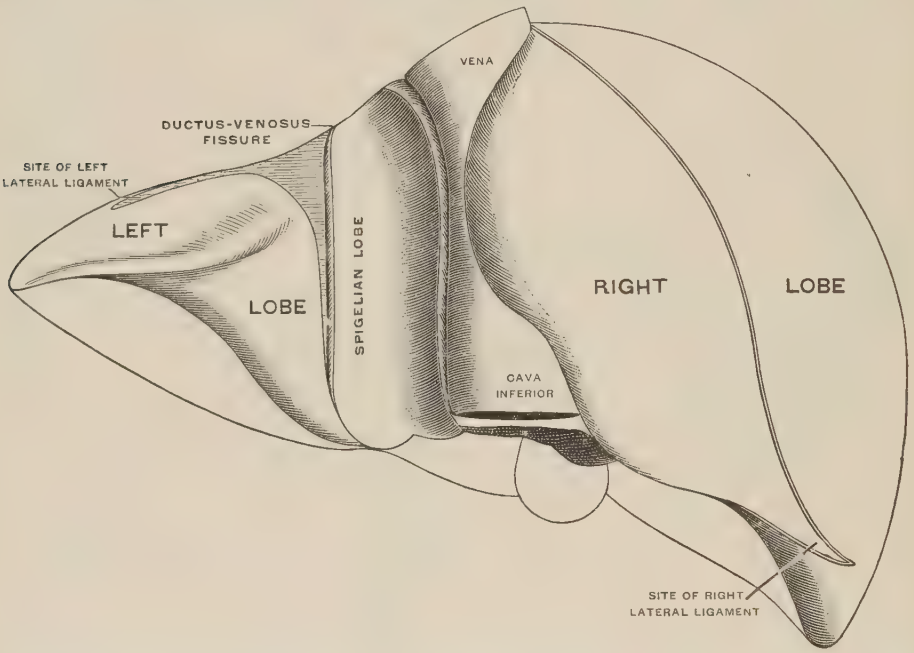

FIG. 846.—The liver, posterior surface. A part of the under surface is seen from the rear view, and this is shown merely in outline. There is no serous tunic on the area marked RIGHT, or on the shaded area at the left of the Spigelian lobe. (Drawn from the His cast. F. H. G.)

posterior end of the space between the two layers of the suspensory ligament on the upper side, and containing the shrunken remnant of the *ductus venosus* of fœtal life; the other, broad and deep, corresponds to the gall-bladder fissure of the under side, at the lower end is separated from it only by the breadth of the caudate lobe, and furnishes a spacious lodging for some inches of the *vena cava inferior*. These fissures are known by the names of the structures which are embedded in them. Between them lies a rectangular space called the *Spigelian lobe*, whose lower margin is seen on the inferior surface, and whose upper edge is visible from above. At the right of the vena-cava fissure is the large, convex *right lobe*; and at the left of the ductus-venosus fissure is the *left lobe*, small in extent, somewhat triangular in shape at the right, and rapidly tapering at the left and becoming a mere margin, which is directly continuous around the left extremity of the liver with the anterior border. On this surface the right lobe has no serous covering.

Borders of the Liver.

The **Anterior Border** separates the upper and under surfaces in front. It is thin, sharp, and bevelled at the expense of the inferior surface. It is continuous around the right and left extremities of the viscus with the postero-inferior border. It is slightly notched at the beginning of the umbilical fissure, and more widely so where the gall-bladder touches it.

The **Postero-inferior Border** separates the hind and under surfaces. It is well defined, except upon the left lobe between the Spigelian lobe and the place where the posterior surface is lost in the margin.

The **Postero-superior Border**, that between the hind and upper surfaces, is marked far less distinctly than the others by any conformation of hepatic substance. At the left of the vena cava the upper end of the Spigelian lobe and a ridge from it to the beginning of the posterior margin indicate sufficiently the line of separation; but on the other side of the vein the dome-like superior surface of the right lobe slopes without break to the back of the organ. There is, however, a line along which the serous covering of the upper surface is reflected to the hind wall of the abdomen—a line seen with equal distinctness from above and from the rear—and this is taken as the natural delimitation of the surfaces in question.

The Extremities of the Liver.

The **Right Extremity** is massive, evenly convex above, and terminated below by a sharp edge, which is bevelled at the expense of the under surface.

The **Left Extremity** is thin, flattened horizontally, convex above, concave below, and margined by a very distinct edge.

Tunics of the Liver.

The liver is closely invested by a delicate *areolar membrane*, which is reflected inward at the portal fissure upon the vessels and ducts passing through this opening, and encloses them even to their interlobular ramifications. This wrapping of the hepatic tubes is known as the *capsule of Glisson*. It is not found in connection with any vessels of the hepatic vein series, because it ceases between the lobules, and at least half of the diameter of each of these bodies intervenes between the interlobular space and the intralobular vein, which is the initial rootlet of the system of hepatic veins. These last vessels are, as it were, channeled in the substance of the liver, and are so intimately adherent to it that, unlike most veins, they show no tendency to collapse, when cut across. The walls of the branches of the portal vein, on the other hand, tend to fall together when severed, the investment of areolar tissue not holding them open. The fibrous coat of the liver is most distinct at the areas over which there is no serous membrane.

Like most other organs in the abdomen the liver has a *serous tunic*, derived from the peritoneum. From the small curvature of the stomach there passes to the portal fissure the double peritoneal layer which is known as the gastro-hepatic omentum, one layer coming from the front, the other from the hind surface of the stomach. The anterior of these spreads out upon the under surface of the liver, turns up over the anterior border and the two extremities, and then covers the upper surface, except small areas at the back edge of the right and left lobes, and except, also, where the membrane which comes from the right end meets that from the left. Here a very narrow strip of surface, widening into a triangular area behind, is left bare; and on each side the membrane is reflected upward to the diaphragm, on reaching which the layers turn to the right and left respectively, and line its under surface. This double membrane is prolonged forward and downward to the anterior abdominal wall as far as the navel, and in the free edge (the hind border) of the part of it below the liver is included the obliterated

umbilical vein. Thus is formed the *suspensory ligament*, a sickle-shaped structure, with the *round ligament* in that part of its cutting edge which projects beyond the anterior border of the liver (Fig. 847).

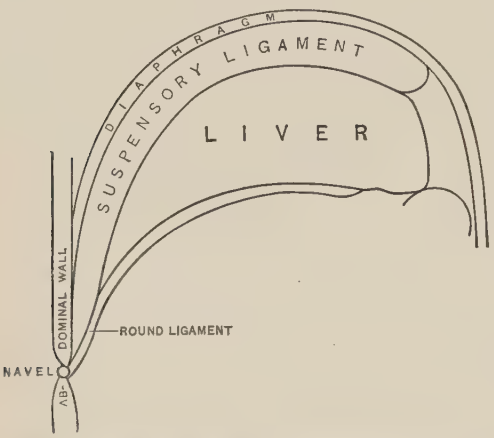

FIG. 847.—Diagram to show the relations of the suspensory and round ligaments to the liver and the abdominal wall. (F. H. G.)

The posterior layer of the gastro-hepatic omentum spreads out upon the hind surface of the liver, but does not nearly cover it, the back of the right lobe being entirely bare. This layer is reflected onto the rear wall of the abdomen, along an irregular line, extending from just above the lower end of the right lobe behind, along the postero-inferior border to the vena cava, in front of this vessel, up by its left side, and then on the upper surface of the left lobe slightly in front of its posterior margin, thus constituting the lower portion of the *coronary ligament*. The upper portion of this large ligament is made by the corresponding reflection of the serous membrane from the upper surface.

Supports of the Liver.

The liver is held in place by various agencies. Probably the most important of these is its intimate connection with the *vena cava inferior*. This great vessel, passing upward to the heart, is closely adherent to the back wall of the abdomen, is deeply lodged for some inches of its upper portion in the substance of the liver, and receives from this viscus the few great and many small hepatic veins, some of which come to it from a distance of nearly two inches. The support afforded by the *underlying hollow viscera*—the stomach and bowels—is not to be ignored. Usually these are occupied to a considerable extent by gas, and thus act as a sort of air-cushion upon which their bulky associate can repose. The fibrous cord, which results from the atrophy of the umbilical vein of intrauterine life, and is known as the *round ligament* of the liver, does something in steadying the organ. Its upper part is firmly fastened in the umbilical fissure, from the front end of which it passes down, close to the anterior abdominal wall, enclosed in the free edge of the falciform ligament, and terminates in the navel, with the cicatricial tissue of which its end is fused. Finally, there are four ligaments formed by folds of peritoneum. Of these the superior has already been described in connection with the serous tunic. It is called *suspensory*, because the liver seems to hang from it; *broad*, in comparison with its fellows; and *falciform*, from its resemblance to the blade of a sickle. The *coronary ligament* is so named because it encloses or crowns an area, which results from the backward reflection of the serous covering of the upper and under surfaces to the hind walls of the abdomen. This ligament is short, and its two layers come together at the right and also at the left. Just beyond each of the points of junction of these layers and continuous with them there is a small, triangular, double fold of peritoneum, which lies between the liver and the diaphragm, and can be best seen by drawing the adjacent side of the muscle away from the viscus. These are the *lateral ligaments*, the right and the left.

Vessels of the Liver.

The vessels of the liver are the portal vein, the hepatic artery, the hepatic veins, and the lymphatics. The first two of these pass from between the layers

of the gastro-hepatic omentum into the liver at the transverse fissure, their branches are embraced by the capsule of Glisson, and they are distributed as has been already stated, the one contributing material upon which the hepatic cells are to act, the other furnishing nourishing blood to the various structures of the liver. The hepatic veins receive the blood from the capillaries both of the portal vein and the hepatic artery, and discharge it into the ascending vena cava.

The *lymphatics* of the liver are both deep and superficial. The deep are divided into a set associated with the portal vessels, and a set accompanying the hepatic veins. The former emerge through the portal fissure, and pass through the hepatic nodes on their way to the cœliac; the latter empty into the vena-caval nodes. The superficial lymph-vessels of the under surface are tributaries of the hepatic nodes, while those from the upper and hind surfaces drain into the anterior mediastinal and vena-caval.

The *nerves of the liver* are derived from the left pneumogastric, and from the solar plexus, the latter being distributed mainly to the hepatic artery, though to some extent to the portal vein.

The areolar tissue (capsule of Glisson) between the lobules furnishes an elastic bed for the interlobular structures, and constitutes a series of channels, called *portal canals*, each containing a branch of the portal vein, a branch of the hepatic artery, a lymphatic radicle, a tributary of the bile-duct, and a branch of a nerve.

The Bile-ducts.

The minute, intralobular bile-channels empty into delicate interlobular tubes, lined with very thin cells, which are continuous with the bile-secreting cells. These ducts unite and form larger tubes, lined with columnar epithelium, and constitute an interlobular plexus. Passing toward the portal fissure in the capsule of Glisson, they attain great size, and present a distinct mucous lining and a thick fibrous coat, in which are many circular and longitudinal bundles of smooth muscular tissue, irregularly disposed. One trunk from the left and one from the right unite in the portal fissure and form the *hepatic duct*, which runs two inches downward and to the right, and there joins the *cystic* (gall-bladder) *duct*, thus forming the *common bile duct* (*ductus communis choledochus*), a tube about three inches long, which passes downward and backward to the second part of the duodenum, where it pierces the muscular wall of that bowel, runs in the submucous space for a half-inch or more, and opens in conjunction with the pancreatic duct into the lumen of the duodenum, about four inches below the pylorus. The gastro-hepatic omentum encloses the hepatic duct and the upper part of the common duct, the lower part of the latter running between the pancreas and the duodenum.

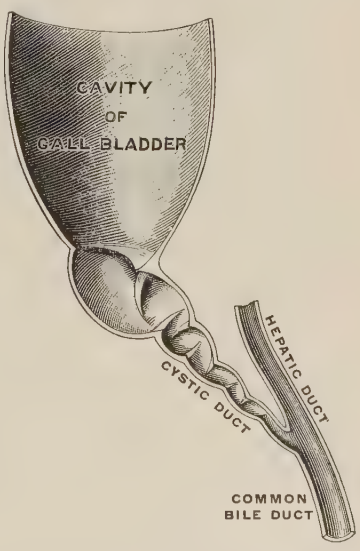

FIG. 848.—The cystic duct in section, with part of the gall-bladder, hepatic and common bile ducts. (Testut.)

The Gall-bladder.

The gall-bladder (*vesica fellea*) (Fig. 848), the reservoir of the bile, is a pear-shaped bag, nearly four inches long, an inch and a half wide, and with a capacity of rather more than an ounce. It lies in the wide fissure to which it gives its name, sometimes projecting a little beyond the front margin of the liver, covered on its blunt (forward) end, its sides, and its under surface by serous membrane, which is stretched across from the right lobe to the quadrate. Occasionally it has a complete serous investment of peritoneum, and then hangs suspended by a mesentery. Its principal coat is com-

posed of condensed areolar tissue, in which are irregularly disposed many bundles of unstriped muscle. The lining of mucous membrane has a honeycomb appearance. The tube of discharge, the *cystic duct*, about an inch long, has a structure like the other bile ducts, but presents the peculiarity of a number of oblique folds of its mucous membrane, which project into the bore and suggest the thread of a screw. All through the large bile ducts and in the gall-bladder there are mucus-secreting glands.

The blunt end (*fundus*) of the gall-bladder presents at the abdominal wall below the ninth costal cartilage, just outside of the external edge of the rectus muscle. Below the gall-bladder are the transverse colon and the duodenum—possibly the pyloric end of the stomach.

Size and Weight of the Liver.—The adult liver measures 10 or 12 inches from end to end, 6 or 7 inches fore-and-aft, 3 or 4 vertically in the thickest part. Its weight is from three to four pounds. Its weight relatively to that of the entire body varies enormously at different periods, being one-third when the embryo is two months old, and one thirty-sixth or less in middle life. It diminishes in size and weight as old age creeps on. It is brownish-red in color, often presenting a mottled appearance. It is firm to the touch, but rather friable; and, when torn across, the exposed surface is seen to be distinctly granular on account of the presence everywhere of the lobules.

Situation of the Liver (Fig. 849).—The position of the liver in the right hypochondriac, epigastric, and left hypochondriac regions is not entirely unchangeable, but is modified by a number of circumstances, particularly by respiration, the

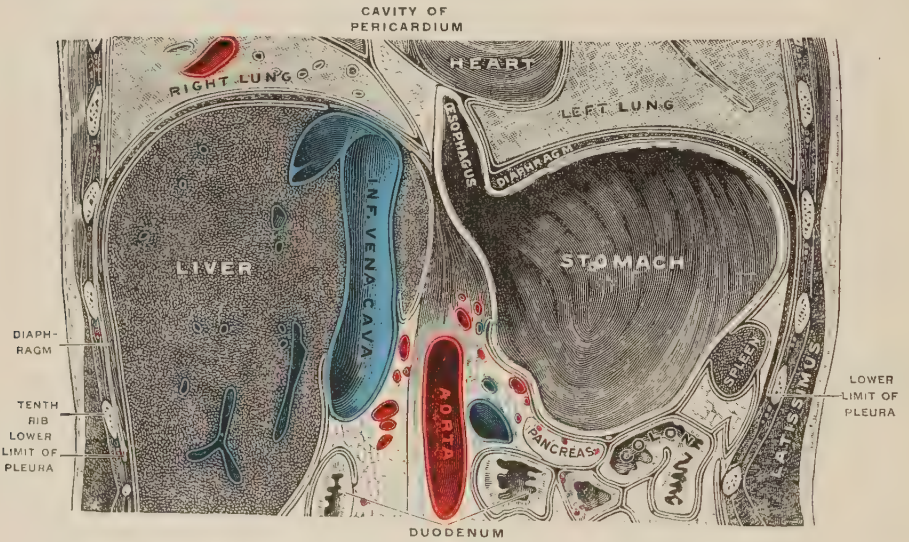

FIG. 849.—Coronal section of trunk, showing relations of thoracic and abdominal viscera. Front surface of rear segment. (Testut.)

attitude of the body, the distension or emptiness of stomach and colon, and the tightness of the clothing of the thorax. To these influences, which are not pathological, may be added various others, which result from disease. In forced inspiration the dome of the right lobe may be driven down to the level of the ninth thoracic vertebra; in forced expiration it may rise as high as the upper border of the eighth thoracic vertebra. If a knife were to be inserted horizontally into the thorax on the plane of the fourth costo-chondro-sternal junction, it would be likely to shave the summit of the hepatic dome. This gives one a good idea of the greatness of the encroachment of the abdomen upon the space which the lower margins of the thoracic cage suggest to the casual observer as belonging to the chest cavity.

Relations of the Liver.—The liver is in relation above with the diaphragm, which separates it from the heart and lungs, the first of these organs making its position apparent by a shallow depression on the top of the left lobe, and the others, more yielding in their nature, indicating their location by the great bulges which they permit the liver to make into their under surfaces. Its upper surface is also in contact with the anterior wall of the abdomen above a line drawn from the ninth costal cartilage on the right to the middle of the eighth on the left; for this surface slopes markedly forward and downward, and justifies the name which is sometimes given it—the antero-superior surface. The anterior border at the right nearly coincides with the lower margin of the chest-wall. The Spigelian lobe lies against the right crus of the diaphragm, opposite the tenth and eleventh thoracic vertebræ. The right lobe rests on the colon at the hepatic flexure, the right kidney and suprarenal capsule, and the duodenum. The quadrate lobe is above the pylorus and the duodenum. The left lobe lies on the stomach.

Partial Summary.—Some of the principal facts of gross, hepatic anatomy may be tabulated for mnemonic purposes as follows:

- **Five Fissures**
  - Umbilical Fissure
  - Gall-bladder Fissure
  - Portal, or Transverse Fissure
  - } on under surface.
  - Ductus-venosus Fissure
  - Vena-cava Fissure
  - } on hind surface.
- **Five Lobes**
  - Left.
  - Right, subdivided into
    - Quadrate
    - Caudate
    - } on under surface.
  - Spigelian on hind surface.
- **Five Sets of Vessels**
  - Branches of Portal Vein.
  - Branches of Hepatic Artery.
  - Radicles of Hepatic Veins.
  - Bile Ducts.
  - Lymphatics.
- **Five Ligaments**
  - Suspensory, Broad, or Falciform.
  - Coronary.
  - Right Lateral, or Right Triangular.
  - Left Lateral, or Left Triangular.
  - } Peritoneal Folds.
  - Round—obliterated Umbilical Vein.

THE PERITONEUM.

In the preceding descriptions of the abdominal digestive organs it has been necessary to make frequent reference to their serous coat. In every case this covering is a part of the *peritoneum*; and, although one organ which is completely invested, and several which are only partly clothed by it, are yet to be considered, it seems best at this stage to present an account of this great membrane as a whole.

It may be well for the student to refresh his memory by referring to what is said of serous membranes in general on page 66, and of the development of the intestines on page 88.

The peritoneum is by far the most extensive and most complicated of the serous membranes. Its extreme complexity is due to changes in the position of the viscera in their development, and to obliterations which have taken place on account of the adhesion of certain apposed surfaces. It does not meet all of the requirements of a typical serous membrane, because in females it is not a shut sac, there being a continuity of its surface and that of the mucous membrane lining the oviduct, and, consequently, a communication between its cavity and the surface of the body.

Between it and the parietal structures which it lines is a variable amount of *areolar tissue* called *subperitoneal*, sometimes containing fat-cells. This permits a degree of motion of the peritoneum upon subjacent parts. The connection between the serosa and its viscera is usually much closer. The appendices epiploïcæ have been described in connection with the colon.

The viscera are connected to the abdominal parietes and to each other by folds of peritoneum. These have received various names, as mesenteries, omenta, and ligaments.

Mesenteries.

A *mesentery* is a double fold of peritoneum, enclosing the vessels, nerves, etc., devoted to a portion of intestine. Specifically, and always when used alone, the name refers to the mesentery of the small intestine, described on page 737; but the term is often employed in a larger and generic sense to indicate a similarly constituted structure, attached to any organ. Thus, we may speak of the mesentery of the gall-bladder, seen in cases where this reservoir, instead of being held close to the liver, as is usually the fact, hangs away from it at some little distance, depending from a double, serous fold, which encloses its vessels and nerves.

The mesenteries of portions of the large intestine are called by specific names, as *transverse mesocolon*, *sigmoid mesocolon*; and exceptionally we find an *ascending mesocolon*, or a *descending mesocolon*. The mesentery of the vermiform appendix is called the *mesenteriolum* ("the little mesentery").

The **Mesentery proper** extends from the left side of the second lumbar vertebra obliquely downward to the right iliac fossa. The transverse mesocolon crosses the abdomen horizontally at the level of the second portion of the duodenum. The sigmoid mesocolon begins in the left iliac fossa, passes downward and to the right until it reaches the middle line of the sacrum, in which it then goes downward to the third segment. The occasional *ascending mesocolon* lies behind the portion of intestine to which it belongs, and the same is true of the *descending mesocolon*.

Omenta.

Omentum (epiploön) is a term applied to a fold of peritoneum connecting the stomach with some other viscus.

The **gastro-hepatic** ("stomach-liver") **omentum** or *small omentum* extends from the small curvature of the stomach and the adjacent first part of the duodenum to the portal fissure of the liver, and encloses the tubes which enter and leave this opening (Fig. 822).

The **gastro-colic** ("stomach-colon") **omentum** or *great omentum* (Fig. 850) connects the great curvature of the stomach and the adjoining first part of the duodenum with the transverse colon. This omentum is far more voluminous than is necessary to establish a bond of union between the stomach and colon: it hangs downward in front of the mass of small intestines like an apron, and carries in the interstices of its structure an amount of adipose tissue, which varies according to the fatness of the individual. This protective organ, so serviceable in keeping the bowels warm, justifies the alleged origin of its name, which makes it mean "coverlet."

The **gastro-splenic** ("stomach-spleen") **omentum** is a double fold of peritoneum, passing from the dorsal surface of the stomach, near its left border, backward to the hilum of the spleen. It runs below into the gastro-colic omentum. It is often called the gastro-splenic ligament.

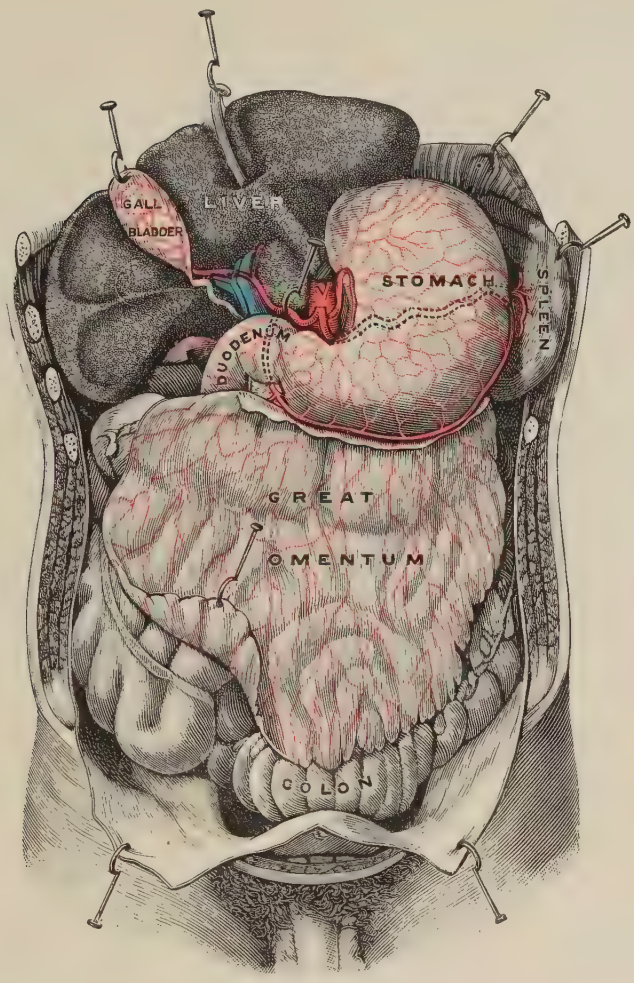

FIG. 850.—The great omentum as seen from the front. (Testut.)

Ligaments.

Other folds of peritoneum, connecting two viscera, or a viscus with the abdominal wall, are called *ligaments.*

The name *hepato-duodenal ligament* is sometimes applied to the right, free margin of the gastro-hepatic omentum, which connects the liver and duodenum.

The ligaments of the liver, which are formed from peritoneum—suspensory, coronary, lateral—have already been discussed.

The *lieno-renal* ("spleen-kidney") *ligament*, including the *lieno-pancreatic ligament*, which is its ventral layer, will be described in connection with the spleen. The peritoneal ligaments of the bladder and the uterus will be more fittingly treated of in the chapters on the urinary and the reproductive organs.

The *phreno-colic* ("diaphragm-colon") *ligament*, also called *costo-colic*, is a small fold stretching from the diaphragm near the tenth or eleventh rib of the left side to the colon near the spleen, and giving mechanical support to the last-named organ.

General View of the Peritoneum.

The *peritoneum as a whole* is to be regarded as a bag, constricted to a mere passage-way at one point, so that there are formed two cavities, a great one and a small one, communicating through a narrow throat.

The *small sac* of the peritoneum lies behind the large sac, and furnishes the serous surface for the back of the stomach, the Spigelian lobe of the liver, and the

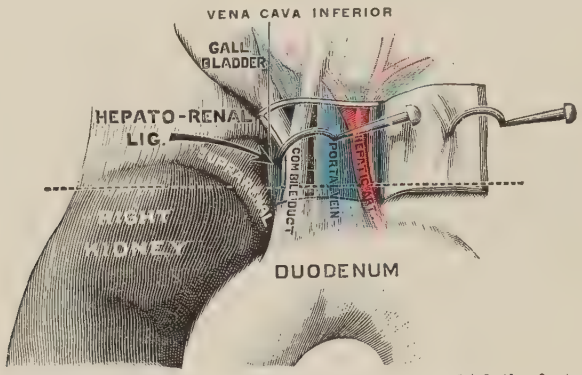

FIG. 851.—Dissection to show relations of the foramen of Winslow, to which the dart points. The front of the right portion of the gastro-hepatic omentum has been cut and turned off to the left, and the liver lifted up and back, displaying the objects in the front wall of the foramen. The horizontal broken line marks the position of the section from which the next picture was made. (Testut.)

front of the pancreas. The other abdominal viscera have their serosa from the *great sac*.

The narrow strait between the great and small cavities of the peritoneum is called the *foramen of Winslow*, and *foramen epiploïcum* (Figs. 851, 852). It is bounded in front by the vessels entering and leaving the portal fissure of the liver,

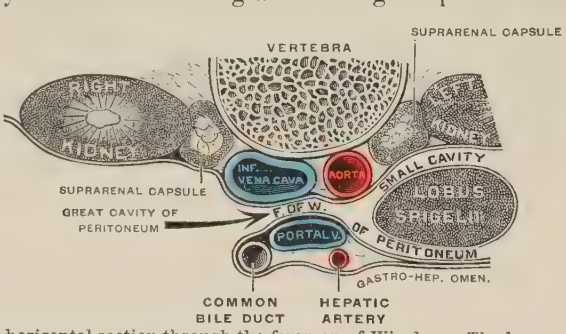

FIG. 852.—Transverse horizontal section through the foramen of Winslow. The lower end of the Spigelian lobe has been shaved off, and the upper surface of the piece is seen. (Testut.)

behind by the vena cava inferior, above by the caudate lobe of the liver, and below by the duodenum. It is large enough to admit two fingers.

The Small Sac of the Peritoneum (Figs. 853, 854).—In the embryo the small sac reaches at first but little lower than the stomach, forming the inner layer of the *mesogastrium*, the fold which connects the stomach with the dorsal wall of the abdomen; but afterward it enlarges rapidly by extension downward, and forms a pouch, which hangs from the great curvature of the stomach in front of the intestines, and contracts adhesion to and blends with the front part of the serous coat of the transverse colon, thus establishing a connection between the stomach and colon, which is called the *gastro-colic omentum*, on account of the organs which it unites, and *great omentum*, because it is so much larger than the gastro-hepatic. It is thus seen that the name "cavity of the great omentum" is synonymous with "the small cavity of the peritoneum."

Not only does the small sac become adherent to the colon, but its posterior double layer becomes attached to and merged with the anterior (upper) surface of the transverse mesocolon; and so intimate is this connection that this part of the colon seems to be entirely surrounded by the rear wall of the sac. Furthermore, adhesion takes place between the layers of the pouch which are below the level of the transverse colon, absorption occurs at many points, and the four-layered

apron is converted into a coarse lace-work, in whose meshes a considerable deposit of fat appears.

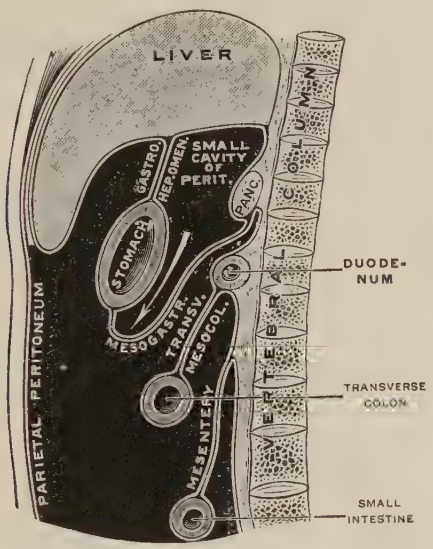

FIG. 853.—Diagram of a sagittal section of the abdomen of an embryo, showing the reflections of the peritoneum in the great cavity and the small cavity. (Testut.)

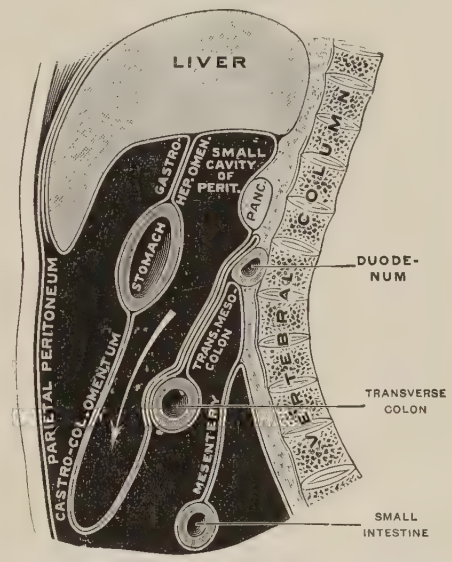

FIG. 854.—Diagram of a sagittal section of the abdomen of an adult, showing the growth of the small cavity, and the application of its rear wall to the transverse colon and mesocolon. Compare with preceding figure. (Testut.)

It is useful to trace the course of the peritoneum at different planes in order to obtain a comprehension of its continuity, the relations which it sustains to the abdominal viscera, and the relations which it maintains between them.

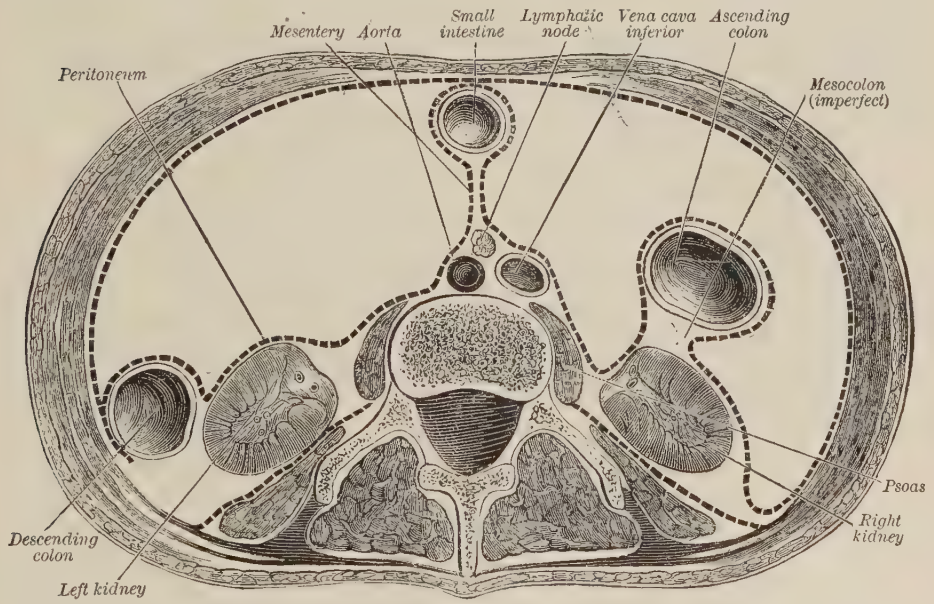

FIG. 855.—Course of the peritoneum, as seen in a horizontal section above the iliac crests. Semidiagrammatic. (Tillaux.)

If we make a horizontal section of the abdomen a little above the iliac crests, and inspect the upper surface of the lower segment, we shall obtain such a view as is presented in the semidiagram, Fig. 855. Beginning at the descending colon,

we trace the peritoneum over its left side, front, and part of its right side, but not upon its back, for it has no mesentery; thence it extends to the face of the left kidney, which, like its mate, lies entirely behind the serosa, in other words is retroperitoneal; from this organ the peritoneum stretches over the psoas magnus and onto the vertebral column and the aorta, which rests on its ventral surface; then it passes forward as the left side of the mesentery, covering the vessels, nerves, nodes, and fat which are the essential parts of that structure, envelops the small intestine, and returns to the vertebral region as the right side of the mesentery; here it partially coats the inferior vena cava, runs onto the right psoas, touches the right kidney, and turns around the ascending colon, giving it a larger covering than it favored the descending colon with, though it leaves its dorsal part nearly or quite bare; thence it again reaches the right kidney, whose anterior aspect it partially clothes, and from this is reflected to the abdominal wall, and sweeps around to the starting point in a great expanse of parietal peritoneum.

If we examine the surface of this anterior wall at a lower level (Fig. 856), we shall observe a median ridge from the bladder to the umbilicus, due to the urachus;

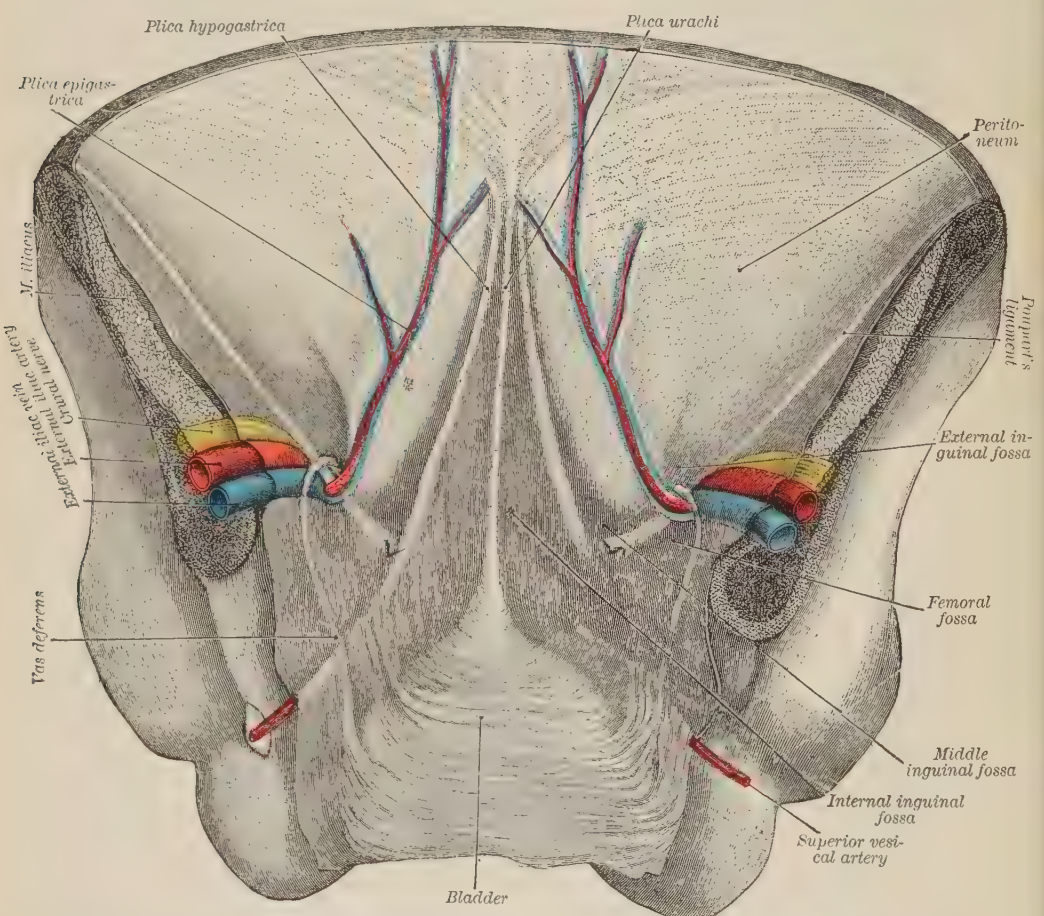

FIG. 856.—Posterior view of the anterior abdominal wall in its lower half. The peritoneum is in place, and the various cords are shining through. (After Joessel.)

on each side of this a ridge, sloping down and outward from the navel, these being caused by the obliterated hypogastric arteries; nearly parallel with these and further to the side, are slight elevations, which are produced by the epigastric vessels; and, running down and inward from the iliac spines, the inguinal liga-

ments. In the angle between the epigastric vessels and the inguinal ligament is a slight depression, the *external inguinal fossa*, marking the internal abdominal ring, the beginning of the inguinal canal; in the angle between the hypogastric ridge and the inguinal ligament is the *middle inguinal fossa*; below this, toward the side and beneath the inguinal ligament, is the *femoral fossa*; and between the urachus and the hypogastric artery is the *internal inguinal fossa.*

If we trace the peritoneum vertically, beginning on the superior surface of the liver, we pass down to its anterior border, back and upward on its inferior surface to the portal fissure, where we come in contact with the small omentum, which guides us downward to the front of the stomach, passing over which we reach the anterior surface of the great omentum, and this, being followed over its lower edge and posterior aspect, leads to the transverse colon; thence beneath the transverse mesocolon the course lies upward and backward to the third part of the duodenum, where an abrupt change of direction occurs, and the membrane is traced downward over the mesentery and jejuno-ileum, and back on the other side of the mesentery to the hind wall of the abdomen, which is again left to form the serous part of the sigmoid mesocolon and the outer tunic of the sigmoid colon. After this the course is different in the two sexes. In the male the peritoneum goes from the rectum to the bladder a short distance above the prostate gland, forming the *recto-vesical pouch*, covers the superior surface, and thence extends to the front abdominal wall. In the female it passes from the rectum to the upper extremity of the vagina and the uterus, forming the *recto-vaginal* or *recto-uterine pouch*, called also the *cul-de-sac of Douglas*; then covers the supravaginal part of the uterus, from which it extends to the bladder, and then to the anterior wall of the abdomen. Its course upward requires no especial mention, other than that already given it, until the navel is reached. Above this there runs upward and slightly to the right a ridge which ends above at the anterior border of the liver, and encloses the round ligament of the liver. At the sides of this elevation the peritoneum is traced smoothly over the anterior belly-wall and onto the under surface of the diaphragm, from which it turns to the upper surface of the liver, where the excursion was begun.

Variations from these two simple tracings occur, as the planes of the sections are made in different directions; but these examples give a correct idea of the chief features of the peritoneal complications.

Retroperitoneal Fossæ.

At certain places the peritoneum is marked by the presence of one or more crescentic folds, bordering the openings of distinct pouches or fossæ, which are of practical interest as being the sites of retroperitoneal herniæ. They occur in the regions of the duodenum, the sigmoid colon, and the cæcum.

About the duodenum, three of these pits are recognized. The most common is the *inferior duodenal fossa*, situated in the lower and external portion of the fourth part of this intestine, its mouth directed upward. The *superior duodenal fossa*, also in connection with this part, opens downward, its orifice facing that of the inferior fossa. Both of the preceding are frequent. The *duodeno-jejunal fossa* is rare. It begins on the back of the jejunum, and extends upward to the duodeno-jejunal junction.

The *intersigmoid fossa* begins in the left iliac fossa at the proximal part of the sigmoid mesocolon, and runs upward behind the peritoneum of the dorsal abdominal wall.

In the cæcal region a number of fossæ may be found, of which the most important is the *postcæcal fossa*, which extends upward behind cæcum and ascending colon for a variable distance. It may include the proximal part of the appendix vermiformis, and cause annoyance in operations upon this organ.

THE ORGANS OF RESPIRATION.

By F. H. GERRISH.

PHYSIOLOGICAL ANATOMY.

RESPIRATION is a dual function, consisting of the simultaneous expulsion of certain waste matters and appropriation of a nourishing material. The substance which is introduced in this process is gaseous, and the things which are eliminated are either gaseous or vaporized. The double performance is popularly called breathing.

The *apparatus* necessary for respiration consists of a thin, moist membrane, exposed on one side to air, and on the other to a moving stream of blood (Fig. 857). Each of these fluids gains something from, and loses something to, the

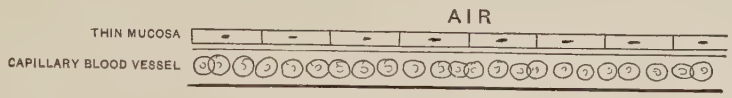

FIG. 857.—Diagram of the essentials of a respiratory apparatus. (F. H. G.)

other: the air parts with oxygen and takes on a load of effete materials; while, at the same time, the blood gives up certain waste products and appropriates the oxygen—the most important item of the body's income—these various substances passing readily through the delicate membrane, which is mucous.

In different classes of animals the necessary structural conditions are afforded in various ways. In some aquatic creatures the respiratory membrane is spread over the surface of a plume-like organ that projects from the body and waves about in the water, which always contains air (Fig. 858). A more common device is that of gills, in which the mucous membrane is disposed in layers, between which the air-laden water is drawn, being taken in at the mouth and ejected at the sides of the head. In the tadpole, which lives entirely in the water, the breathing organs are gills; but the frog, into which the tadpole develops, has a very different apparatus. Gradually the structural peculiarities of the aquatic animal are lost, and those of the amphibian are acquired; and, synchronously with the shrinkage of the fish-like tail, and the growth of the limbs, is observed the development of a new breathing-apparatus, unfit for abstracting oxygen from the air which is contained in water, but capable of taking the gas directly from the ordinary atmosphere. It is a sac, wholly contained in the trunk, and into it, at brief intervals, a quantity of air is drawn, permitted to remain a short time, and then expelled by the channel of entrance. This sac is lined with a delicate

FIG. 858.—Head and gills of Menobranchus. (Dalton.)

mucosa, with the attached surface of which a network of capillaries is in contact. It is a very simple kind of lung, and yet is the type on which the most complex respiratory organ is constructed.

An animal which requires, on account of the rapidity of his tissue-changes, a very large supply of oxygen, would find locomotion impracticable, if his respiratory membrane was at the surface, projecting like a tree, or arranged like gills; but it is manifest that there is not sufficient room in the entire body for a simple sac, whose lining would afford a surface large enough to meet the requirements of the case. The problem presented is that of providing a great extent of surface within a limited cubic space. It is the same question as that which confronts the librarian, whose books are vastly too numerous to be accommodated by the entire available area of the walls of the room. He neither appropriates more apartments, nor builds an addition to the house; but he constructs partial partitions, projecting from the walls toward the centre of the room, making alcoves of the intervening spaces, and thus enormously multiplies the shelving capacity. Nature adopts this plan in the lung, and, by forming alcoves at the periphery of the original sac, augments its available surface without increasing its cubic capacity. The lung of the frog illustrates this fact; a sectional view (Fig. 859) shows that the mucosa is folded into partial partitions, between which are little recesses around the periphery, all opening into a clear, central passage.

FIG. 859.—Lung of frog, cut open, showing its internal surface. (Dalton.)

The complex lung of man is built upon this type. But the complexity of the human lung arises not largely from elaboration of the plan, but from immense multiplication of the structure. The great size of the human being and his relatively greater activity require not a different kind of lung, but a host of lungs of the same kind. Therefore, the human lung may well be regarded as a vast community of batrachian lungs, with the addition of such accessories as the immensity of the collection makes necessary.

The alcoves—to repeat the library simile—are called *air-vesicles, alveoli,* or air-cells—the last name being objectionable on account of the different use of the word "cell" in histology. A collection of alveoli around a central hall constitutes an *infundibulum,* so called from its funnel-shape. A group of closely related infundibula makes a *lobule.* A great community of lobules is a *lobe.* Two or three lobes make a *lung.*

In mode of development and general appearance a lobule bears a striking resemblance to a racemose gland. The stem of a lobule is an air-duct, and from this, within the lobule, branch the more minute tubes, which serve as stems for the infundibula, three of the latter often being connected with one of the former.

The duct of the lobule unites with another of like size, making a larger one; this last joins with its equal, and so on progressively until tubes of considerable size are reached, which either pursue this method, or enter the sides of those which are larger. Finally, for each of the two lungs a single tube results, and the two combining form a great median pipe. Beyond this the air-channels do not have the regularity of shape which has characterized the system up to this point. They are the larynx, the pharynx, and the passages of the nose.

Tracing the air-ducts in reversed order from the surface of the body to the depths of the lung, we have—

1. The nasal passages.
2. The upper and middle portions of the pharynx.
3. The larynx.
4. The trachea (the windpipe).
5. The two bronchi—one bronchus for each lung.
6. The bronchia (bronchial tubes, bronchioles) of all sizes from the largest to the smallest.

The *nasal passages*, as cavities in the skull, are treated of in the chapter on osteology; as olfactory structures, in the chapter on the organs of the special senses. The *pharynx*, being an alimentary as well as a respiratory organ, has already been presented as a part of the digestive tract. The *larynx*, which is the organ of voice, is the highly specialized upward continuation of the trachea, and its description would best be deferred until the simpler structures have been considered.

Besides the organs just enumerated, many bones and muscles are needed for the performance of the function of respiration in man; but, as these have already been considered in other connections, it is not important to review them here.

We now have before us an outline of the physiological anatomy of the breathing apparatus, and are prepared to study the structures in detail. This can most profitably be done by beginning with the windpipe and proceeding in an unbroken course to the air-vesicles.

THE TRACHEA.

The *trachea* (so-called from the Greek word for "rough," on account of the marked inequalities felt on its surface), or *windpipe* (Fig. 860), is a straight tube, situated in the middle line of the lower and front part of the neck and the upper part of the thorax, in front of the œsophagus, extending from the lower border of the larynx downward and backward to its division in the bronchi, and from the plane of the sixth cervical to that of the fourth or fifth thoracic vertebra. When the face is directed forward, the trachea is a little more than four inches in length; but this measurement may be increased by the forcible extension of the neck and diminished by sharp flexion, the variation between the shortest and longest measurements exceeding one and a half inch. Its average transverse diameter in the cadaver is four-fifths of an inch, the antero-posterior a trifle less; but both are smaller during life on account of the activity of the muscular part of the pipe. It is convex and rigid in front and at the sides, flat and flexible behind.

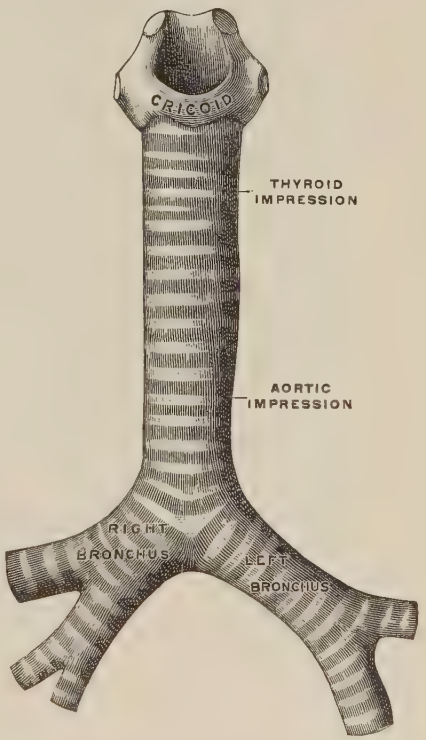

FIG. 860.—Trachea and bronchi, front view. (Testut.)

Relations.—The gullet is behind, excepting at the lower end of the trachea, where the former bends to the left, and thus lets the windpipe rest against the vertebral column. The thyroid gland embraces the trachea, its lateral lobes being at the sides, its isthmus across the front opposite the second, third, and fourth cartilages, and its pyramid extending upward on the ventral surface. Some branches of the superior thyroid arteries are above the isthmus, and below it are the inferior thyroid veins, vestiges of the thymus, and the occasional thyroidea ima artery. The aortic arch crosses the trachea obliquely in its lower part, and of the great vessels springing from the arch the brachio-cephalic and the left common carotid are at first in front, the former moving to the right as it ascends, the latter to the left. The recurrent laryngeal nerve on each side lies in the groove between the trachea and the gullet. The vagi are at the right and left respectively. The

deep cardiac plexus lies at the bifurcation, and on the same plane the superior vena cava is at the right in front. The right pleura is close to the trachea at the right.

The *framework* of the trachea consists of mixed white and yellow fibrous tissue, and strips of pure cartilage, the latter being embedded in the front and sides of the tube made by the former. The *pieces of cartilage* are very irregular in shape—some being of nearly uniform width from one end to the other, some bifurcating at one end, some having a branch near the middle; but their general direction is horizontal, and, seen from the front or side, they produce the effect of nearly parallel bands. But they are not rings, though often so called; for they do not encircle the trachea, but always end at the border of its flat, hind surface. They vary in number from fifteen to twenty. The highest one is wide and firmly attached to the lowest cartilage of the larynx; the lowest sends a spur downward and backward from its centre, between the origins of the bronchi. The fibrous mass in which the cartilages are embedded is caused by them to bulge in transverse lines, thus being produced the irregularities which give the trachea its name. Calcification of the cartilages begins at forty or fifty years of age.

The flat, *hind wall*, instead of being stiffened with cartilage, is made contractile by a continuous sheet of *unstriped muscle* which it encloses. The bundles of muscular fibres run horizontally, and are attached to the ends of the cartilages where these exist, and to the fibrous wall in the interspaces. In front of the muscle are conspicuous longitudinal bundles of yellow fibrous tissue.

The *cartilages* serve the purpose of preventing the collapse of the trachea from external pressure or from sudden internal suction. The necessities of human respiration require permanence of the lumen of the pipe, a condition which would not be satisfied by a less rigid material than cartilage. The elasticity of the *yellow fibrous tissue* permits the considerable elongation which movements of the head demand, and ensures perfect restoration and even some shortening beyond the average length. The *white fibrous tissue* gives strength, flexibility, and toughness. The *muscular tissue* in the flat, hind portion causes approximation of the ends of the cartilages under nervous stimulus, and diminution of the calibre of the tube.

The *lining* of the trachea is smooth *mucous membrane*, the epithelium of which is columnar, stratified, and ciliated. The deepest layer of the corium is composed almost wholly of yellow fibrous tissue. The submucous, *areolar coat*, connecting the mucosa with the fibrous tunic (in which, as has been already said, are the cartilaginous and muscular elements), contains many racemose *mucous glands*, the ducts of which discharge into the tube. The greater part of these glands are in the spaces between the cartilages and in the hind wall.

The principal *arteries* of the trachea are the inferior thyroid, its *veins* are radicles of the thyroid plexus, its *lymphatics* are tributaries of the bronchial and deep cervical nodes, and its *nerve-supply* is derived from the vagus, recurrent laryngeal, and great sympathetic.

The trachea lies in the midst of an abundant mass of areolar tissue, which is so loose as to permit free movement up, down, and horizontally.

THE BRONCHI.

The lower end of the trachea bifurcates laterally into the *bronchi* (Fig. 817), which strangely get their name from the Greek word for "throat." They pass to the right and left lungs respectively. In structure and general form they are exact continuations of the trachea, with convex front and sides, which are stiffened with cartilaginous bands embedded in fibrous tissues, a flat back, which is fibrous and muscular, and a lining of mucous membrane, whose epithelium is cylindrical, ciliated, and in layers. The *right bronchus* is the shorter (a scant inch), wider ($\frac{3}{5}$ inch), and more nearly horizontal; the *left bronchus* is the longer (about two inches), narrower ($\frac{2}{3}$ inch), and more nearly vertical. The ridge be-

tween the bronchi at the bifurcation is at the left of the median line. They are supplied by the bronchial arteries, and by nerves from the pulmonary plexus.

Relations.—The right bronchus has the superior vena cava in front, the vena azygos major behind and above. It sends a large branch above the right pulmonary artery to the uppermost of the three lobes of the right lung. This branch is called *eparterial* ("upon the artery"), the rest of this bronchus being *hyparterial* ("beneath the artery"). The left bronchus has the aortic arch above, the left pulmonary artery in front, the gullet, aorta, and thoracic duct behind. It has no eparterial branch.

THE BRONCHIA.

The air-ducts, leading from a bronchus into the depths of the lung, are called *bronchia*, *bronchial tubes*, or *bronchioles* (Fig. 861). The right bronchus gives

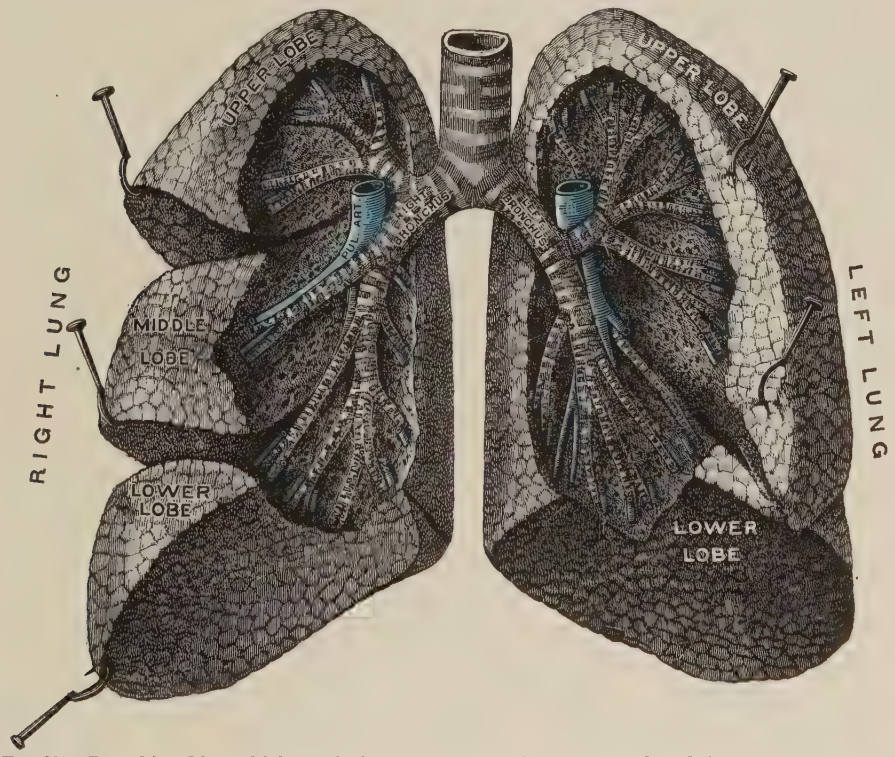

FIG. 861.—Bronchi and bronchioles. The lungs have been widely separated, and tissue cut away to expose the air-tubes. (Testut.)

three branches to its lung, the left only two. The tubes divide progressively, (sometimes dichotomously, sometimes otherwise), into smaller tubes down to the infundibula, the ducts of which are about $\frac{1}{125}$ inch in diameter. Although the bronchioles are continuous with the bronchi, as the latter are with the trachea, they have a different shape—the bronchi and windpipe being flat behind, all the other tubes perfectly cylindrical. In other words, the outline of a transverse section of every pipe concealed within the lung is circular, while that of those which are outside of the lung is convex only in front and at the sides.

The bronchioles have three coats—mucous, muscular, and fibrous. The *mucous membrane* is everywhere provided with ciliated epithelium, the lashes of which beat always toward the larger tubes, thus preventing an accumulation of mucus in the air-vesicles. Glands are numerous, except in the very small tubes. The muscle fibres of the *middle coat* are transversely arranged, and are relatively

most conspicuous in the smallest tubes. The *fibrous coat* contains not only white fibrous tissue, but also many yellow fibres. It diminishes in thickness as the tubes become smaller, and is extremely thin within the lobules. In the tubes which have a diameter of $\frac{1}{25}$ inch or more this coat is strengthened by *cartilaginous plates*, not disposed in an annular way, as in the trachea and bronchi, but irregularly scattered through the tunic.

The tubes which have no cartilages are also deficient in glands; but their lining membrane is kept moist by a smear of mucus furnished by goblet cells. The muscular tunic in these minute tubes, although scanty, is important, as it possesses the power of narrowing their calibre, and thus diminishing the size of the air-current. In asthma the exaggeration of the normal action of this coat is responsible for the difficulty in breathing.

MINUTE ANATOMY OF THE LUNGS.

Upon the walls of the minute bronchioles little bulges appear, at first rarely, but with increasing frequency as the distal end of the tube is approached. Finally the bronchium widens out and terminates in an irregular chamber, the sides and blind end of which are closely set with these little protrusions, and we have the ultimate and essential part of the respiratory apparatus—an *infundibulum*. The minute blebs on the tubes seem to be the result of an effort of nature to form an infundibulum before all of the necessary conditions are favorable. Again and again the attempt is made, always with greater results, and at last the whole remainder of the tube undergoes the transformation. The pouches are the *alveoli* (air-sacs, air-vesicles, air-cells). The infundibula are not always funnel-shaped, as the name implies, but are often very irregular in form.

Structure of an Infundibulum (Fig. 862).—The framework of an infundibulum is very thin, transparent, and composed of *fibrous tissue*, the yellow variety being conspicuous, and forming a delicate network. A few smooth *muscular fibres* are found between the air-vesicles. Next to this wall is a dense network of *capillaries*, the spaces between which are not as wide as the vessels themselves.

The lining of an infundibulum and its air-vesicles is a delicate *epithelium*, which is directly continuous with that of the mucosa of the tubes. It is chiefly composed of broad, flattened, non-ciliated cells of extreme thinness, among which are scattered here and there little clusters of small polygonal cells, like those which in the fœtus form the entire epithelium of this part. The first full expansion of the vesicle by the inrush of air after birth stretches out almost all of the cells, but leaves in their embryonic condition the few which, if enlarged like the majority, would make the lining too voluminous. The cells are so thin that the blood in the capillaries is separated from the air by so small an amount of tissue that the least possible resistance to the passage of gases back and forth is interposed. At points where the edges of several cells converge are often seen minute stomata, opening into lymph-channels of the areolar tissue.

The free edges of the air-vesicles support a fine *arteriole*, which twists in and out, now on this and then on that side of the dividing line between two adjacent alveoli, and from this tortuous encircling vessel the *capillary network* is given off to the neighboring vesicles. Those portions of this plexus which are on walls between alveoli have two surfaces exposed to air, one in one vesicle and one in another.

Two or three infundibula may start from the end of one bronchiole. The infundibula are gathered into groups of approximately uniform size, which, with the necessary vessels, nerves, and uniting areolar tissue, constitute *lobules*. The lobules at the periphery of a lung are more or less pyramidal; but the others are packed together so closely that they have become reciprocally compressed into various and fantastic forms.

Between the lobules is *areolar tissue*, which is abundant in the infant, scanty in the adult; consequently their isolation is easy in the former, and difficult or

even impossible in the latter case. This interlobular areolar tissue and also that between the alveoli after early life are the seat of a deposit of carbonaceous matter, doubtless inhaled, and carried by lymph-channels to this tissue and to lymph-

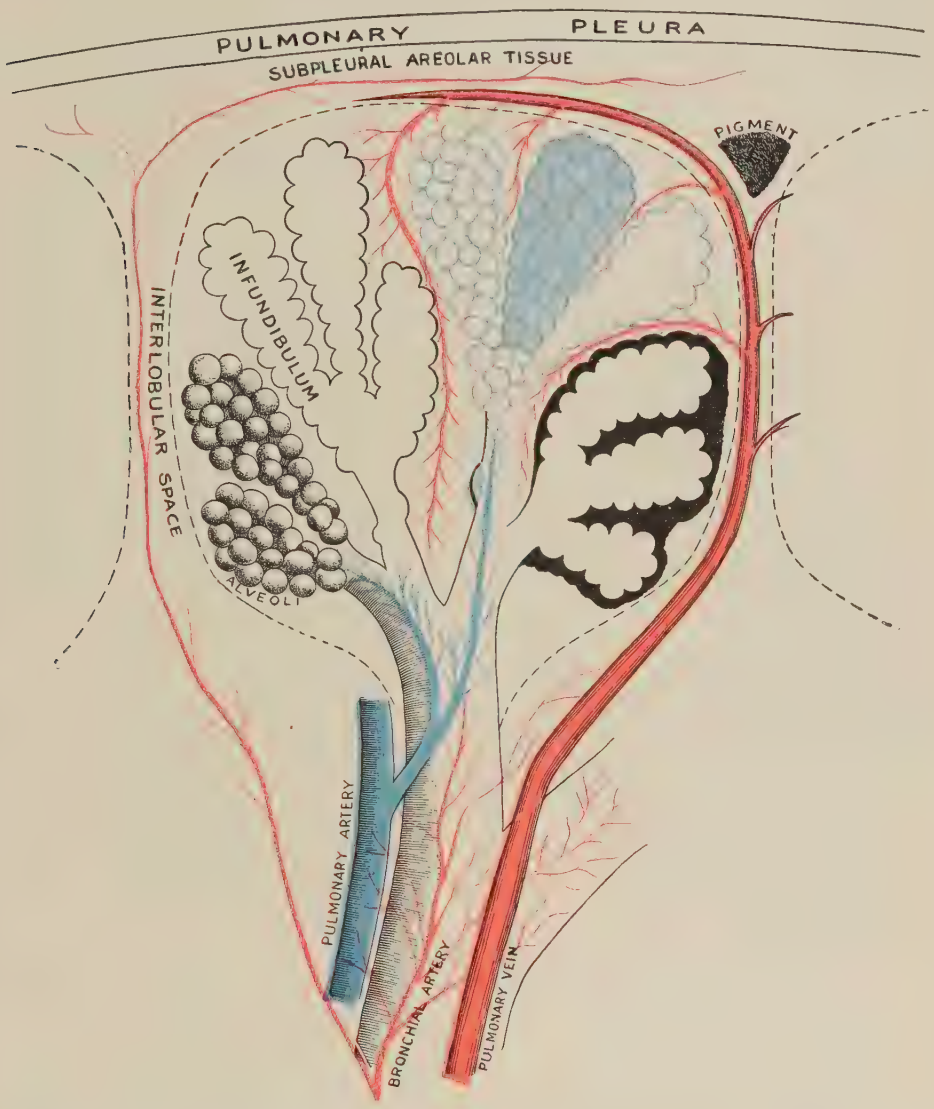

Fig. 862.—Diagram of a lobule of the lung. A bronchiole is seen dividing into two branches, one of which runs upward and ends in the lobule. In the lobule are four groups of infundibula. At the left are two infundibula the alveoli of which present their outer surfaces. Next are three infundibula in vertical section, the alveoli of each opening into the common passageway. Upon the ultimate bronchiole of this group are alveoli. In the next group the first infundibulum shows a pulmonary arteriole surrounding the opening of each alveolus, and the second gives the same with the addition of the close capillary network in the wall of each alveolus. The same arrangement of vessels is seen in the alveolus upon the bronchiole of this group. Around the fourth group is a deep deposit of pigment, such as occurs in old age, and in the lungs of those who inhale coal-dust and the like. On the bronchiole lies a branch of the pulmonary artery (blue), bringing blood to the infundibula for aëration. It also supplies nourishing blood to the tubes and other structures within the lobule. Beginning between the infundibula are the radicles of the pulmonary vein (red), a root of which lies upon the bronchiole. The bronchial artery is shown as a small vessel bringing nutrient blood to the bronchiole (outside of the lobule), the artery and vein, and all of the structures between and around the lobule. No attempt is made to show the sustentacular tissue which occupies the spaces within and around the lobule. (F. H. G.)

nodes. This deposition of pigment makes clear the outlines of the lobules and even of the bases of the infundibula.

Blood-vessels of the Lungs.—Two sets of blood-vessels are distributed to the lung and to all of its lobules—the branches of the *pulmonary artery* and those of

the *bronchial arteries*. The latter furnish nourishing blood to the organ; the former carry to it venous blood, which is to be aërated, that is to say, to be relieved of certain materials which are the result of tissue-waste, and to be loaded up from the air with oxygen—the most important of the articles of physiological income.

The *pulmonary artery* (Fig. 862), by its branches, accompanies the tubes and carries the greatest part of its blood to the capillary plexus of the alveoli; but some of it is supplied to the mucous membrane of those bronchioles which are near the infundibula—those which have air-vesicles upon them. The *pulmonary veins* (Fig. 863) begin by radicles at the margin of the capillary network of the

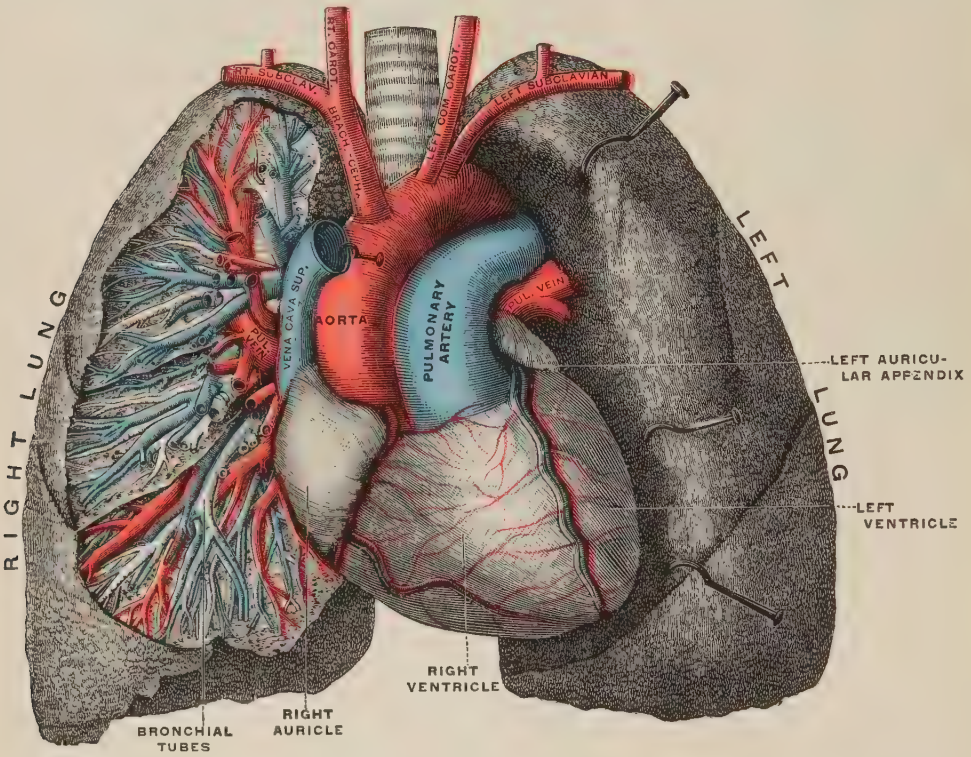

FIG. 863.—The pulmonary artery. The lungs have been pulled away from the middle line so as to expose the heart and great blood-vessels. The front part of the right lung has been removed, and the pulmonary vessels and the bronchial tubes are thus exposed. (Testut.)

alveoli and the minute tubes—that is, they take blood from the parts to which the pulmonary artery is distributed.

The *bronchial arteries* are branches of the thoracic aorta and the upper aortic intercostals. They follow the divisions of the air-tubes, and supply arterial blood to the walls of the tubes (except the smallest), the coats of the large vessels, to which they are *vasa vasorum*, the bronchial lymph-nodes, the pleura, the areolar tissue beneath the pleura, and that between the lobules. The *bronchial veins* gather the blood from all of the parts to which the bronchial artery supplies it, excepting a little, which on account of a communication of the networks on the intralobular tubes and those which form the stems of the lobules, mingles with the blood furnished by the pulmonary artery, and is, consequently, taken up by the radicles of the pulmonary vein. The bronchial veins of the right side are tributary to the vena azygos major, of the left to the superior intercostal veins.

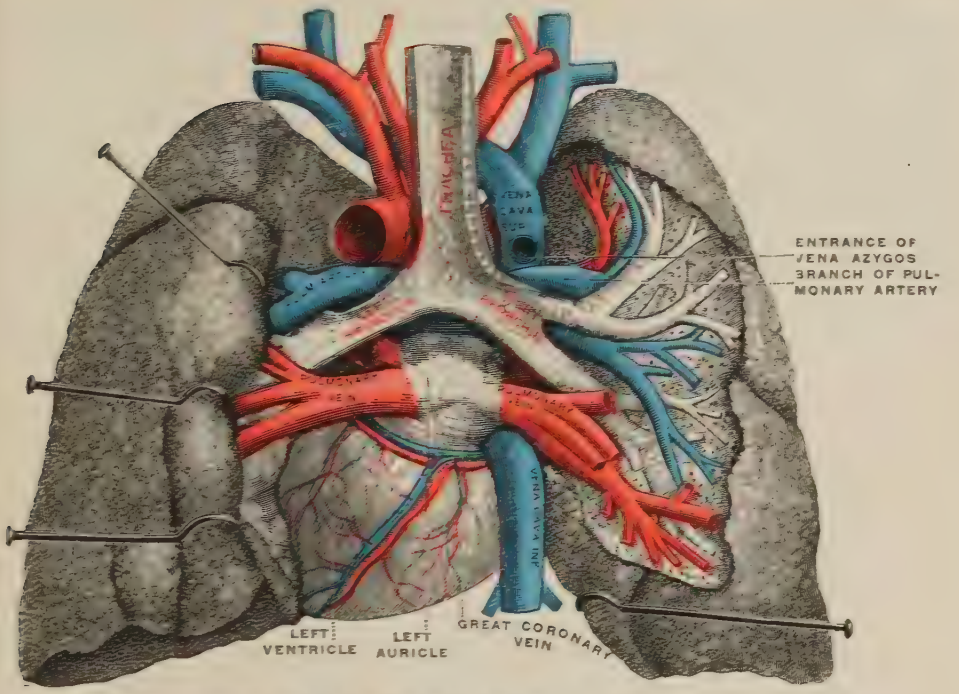

Fig. 864.—Pulmonary veins, seen in a dorsal view of the heart and lungs. The lungs have been pulled apart from the median line, and a part of the right lung has been cut away to display the air-ducts and blood-vessels. (Testut.)

GROSS ANATOMY OF THE LUNGS.

The *lungs* (Figs. 865–867) (Latin *pulmones*, from which comes "pulmonary"), are two large organs, which occupy a great part of the chest cavity, one in each

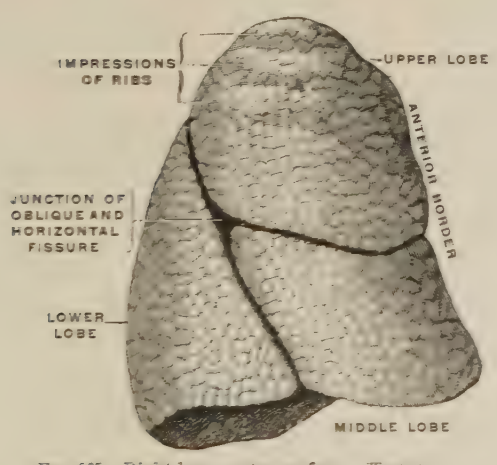

Fig. 865.—Right lung, outer surface. (Testut.)

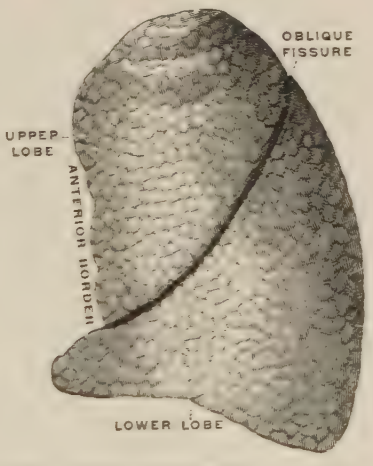

Fig. 866.—Left lung, outer surface. (Testut.)

side of it, and separated from each other by the heart, the gullet, the great blood-vessels, and other structures in the mediastinal space. Each lung presents an *outer surface*, which is convex, and adapted to the inner surface of the chest-wall of one side; an internal or *mesial surface*, which is irregularly concave and occupied by mediastinal organs; an *under surface* or base, very concave and fitting to

the upper surface of the diaphragm; a summit or *apex*, which rises an inch and a half above the level of the first rib; a *hind border*, rounded, vertical, and adjusted to the long hollow made by the bodies of the thoracic vertebræ and the proximal portion of corresponding ribs; a *front border*, thin, irregular, and sloping from above downward and outward; and a *lower border*, bevelled sharply at the expense of the lower surface, and marking the under limit of the outer surface.

On the inner surface, three-quarters way back from the front line, and about equally distant from apex and base, is a vertical notch, the *hilum*, two inches long

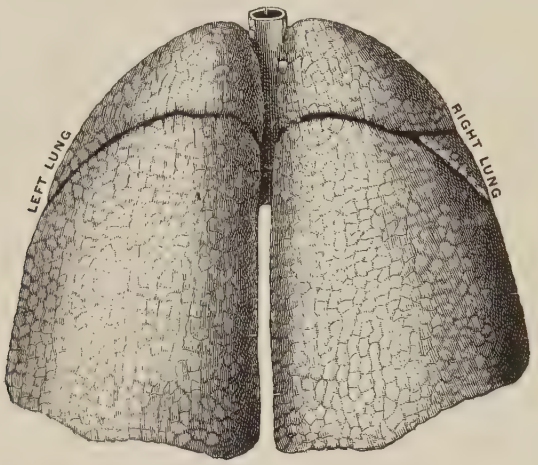

FIG. 867.—Lungs, dorsal view. (Testut.)

and an inch or more broad, which gives passage to the bronchus, pulmonary artery and veins, bronchial artery and veins, lymph-vessels, and nerves, and affords lodgment to a considerable number of lymph-nodes. These different organs in the hilum are connected by areolar tissue, united into one large fagot, which is covered by pleura, and called the *root of the lung*. The arrangement of the principal parts in the root is as follows: From before backward on each side, veins, artery, bronchus; from above downward on the right side, bronchus, artery, veins; from above downward on the left side, artery, bronchus, veins. The right root is in relation anteriorly with the superior vena cava and the right phrenic nerve, posteriorly with the right vagus, and posteriorly and superiorly with the vena azygos major. The left root passes under the transverse portion of the aortic arch, has the descending portion of the arch and the left vagus behind, and the left phrenic nerve in front.

The inner surface of the left lung is much more deeply concaved than that of the right, on account of the greater encroachment of the heart upon the space at the left of the middle line. The front border, also, for the same reason, is deeply notched.

The right lung is on a somewhat higher plane than the left, on account of the greater elevation of the right half of the diaphragm, upon which muscle the lungs rest.

Each lung is marked by a deep fissure (Fig. 868), which starts on the hind surface about three inches below the apex, and runs spirally around, terminating near the junction of the inner and lower borders. This fissure is very deep, extending inward nearly to the hilum, and dividing the lung into an *upper lobe* and a *lower lobe*. About half way of this oblique fissure on the right lung a second fissure (Fig. 869) begins and runs nearly horizontally toward the middle line, ending at the anterior border. This fissure divides the upper lobe of the right side into two, which are called the *middle lobe* and the *upper lobe*.

The left lung is taller, narrower, and more deeply excavated on its median

surface; the right is shorter, wider, less indented, and weighs about two ounces more than the left. The two together weigh about forty-two ounces.

The *relations* of the lung to the surface of the chest are somewhat different on the two sides. Behind the manubrium there is hardly any lung. Between the levels of the second and fourth costal cartilages at their sternal ends the lungs nearly meet. Below this the right lung slopes off in line with the cartilage of the sixth rib, and in the axillary line (below the middle of the armpit) it has reached the eighth rib, and descends in the dorsal region as low as the tenth rib. The left lung is traced behind the cartilage of the fourth rib, then downward across that of the fifth, curves toward the median line, and turns outward and downward behind the cartilage of the sixth rib, forming a tongue, which is called the *processus lingualis*. From this point it resembles the right lung, but is a little lower all along its inferior border.

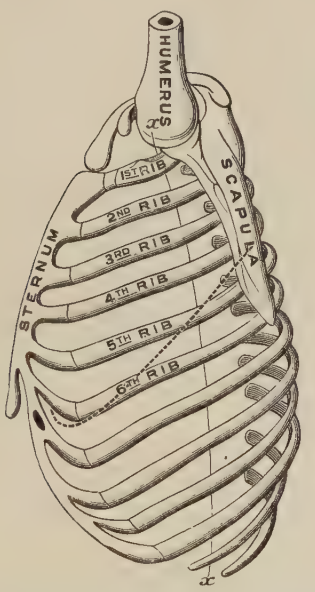

FIG. 868.—Position of the oblique fissure of the left lung with reference to the ribs. The humerus is raised. The line *xx* is the axillary line. (Testut.)

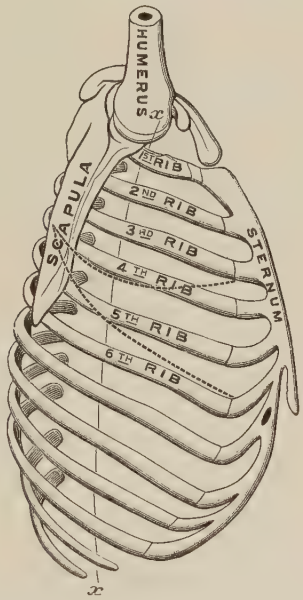

FIG. 869.—Position of the fissures of the right lung with reference to the ribs. The humerus is raised. The line *xx* is the axillary line. (Testut.)

The *volume of the lungs* varies with the amount of contained air. In a newborn child, who has not breathed, the lungs occupy but a small part of the chest, seeming to be crowded upward and backward by the diaphragm, which stands at the level of the third rib. But they quickly expand when respiration is established, and thenceforth occupy all of the chest, except the central portion, as before stated. As, however, the capacity of the thorax is constantly fluctuating, owing to the respiratory movements, the lungs, which accompany the chest-walls in all of their advances and retreats, experience coincident and corresponding variations.

The *average capacity of the lungs* is estimated to be nearly seven and a half pints. The entire respiratory surface at a moderate calculation is more than 870 square feet, and some estimates place it very much higher.

On account of the contained air the lungs are very light, and float readily in water. *Fœtal pulmonary tissue*, however, never having contained air, is not very unlike liver in its specific gravity, as well as in its appearance, and sinks in water; and the presence or absence of the capacity of floating is a ready test of the establishment of breathing, where infanticide is suspected.

The *lung substance* or parenchyma is soft and spongy, and gives a crackling

sound and a corresponding tactile sensation, when it is pressed between the finger and thumb, probably due to the crushing of the walls of the air-vesicles. The cohesive power of the lung is great, and it resists a high degree of pressure without rupturing. On account of the great figure played by the elastic tissue in the structure of the pulmonary substance, the lungs return readily to their former size immediately on the removal of the force which has caused their expansion. The yellow fibrous tissue is always on the stretch in the normal condition, but never has an opportunity to assert its full power, even after death, unless the chest-cavity is opened. At a post-mortem examination the removal of the sternum and costal cartilages is instantly followed by the sudden collapse of the lungs, which are reduced to one-third (or less) of their normal bulk, the explanation being simply this: during life the air-pressure on the inside of the lung is sufficient to prevent the full action of the elastic tissue; but, air being let in on the outer surface of the lung, the atmospheric pressure inside exactly balances that outside, and the elasticity of the pulmonary substance, being unresisted, displays its full power.

The *color of the lung* differs widely according to age. Before respiration is established, it is a deep reddish-brown; on inflation it changes to a beautiful rose-pink; in early adult life it is grayish-white; in early middle life it becomes brownish in spots and streaks; and in old age it is often bluish-black. The alteration from the antenatal hue to the postnatal is manifestly du to the distention of the lung with air—the color is diluted by distribution over a multiplied surface; but the other changes are largely caused by the deposition, in the areolar tissue between the infundibula and between the lobules, of carbonaceous particles, which have been taken up by the lymphatics. In the lungs of people who breathe air highly contaminated with such materials the changes occur much earlier in life, and are much more pronounced. This deposit makes a great deal clearer the outlines of the lobules, and upon the free lung-surface their bases may be observed, occupying irregular polygonal areas from one-quarter of an inch and upward in diameter. Within these may be seen the outlines of the air-vesicles, measuring perhaps $\frac{1}{70}$ inch across.

Lymphatics are abundant in the areolar septa and in the bronchial mucous membrane, and are said to have been traced upon the walls of the alveoli. They drain these parts into the nodes in the root of the lung.

The nerve-terminations are not known. The *nerve-supply* is from the pulmonary plexuses, anterior and posterior, derived from the vagus and the sympathetic.

THE PLEURÆ.

Each lung is invested with a serous membrane, the *pleura* (from the Greek word for "side") (Fig. 870). It is a perfectly typical shut-sac, one portion of which closely envelops the lung, entering its fissures and clothing their walls to the very bottom, and is called the visceral layer, or the *pulmonary pleura*; and the other portion lines the walls of the great space in which the lung is contained, and is called the parietal layer. Different portions of the parietal layer are distinguished by special names, which indicate their position. That which lines the ribs, costal cartilages, and intermediate muscles is the *costal pleura*; that which is attached to the diaphragm is the *diaphragmatic pleura*; that which is applied to the adjacent structures in the mediastinum is the *mediastinal pleura*; and that rising into the root of the neck and covering the dome of the lung is the *cervical pleura*.

As a general rule the pulmonary or visceral pleura is in contact with some part of the parietal pleura; but in the fissures of the lung two layers of visceral pleura are in contact, and below the sharp, inferior border of the lung the two layers of the parietal pleura come together; for, although the lung everywhere else fills the space delimited by the pleura, it does not, even in the fullest inspira-

tion, reach completely to the depths of this extra space, which is called the *pleural sinus*, or *phrenico-costal sinus* (Fig. 871). We speak of a *pleural cavity*, but this

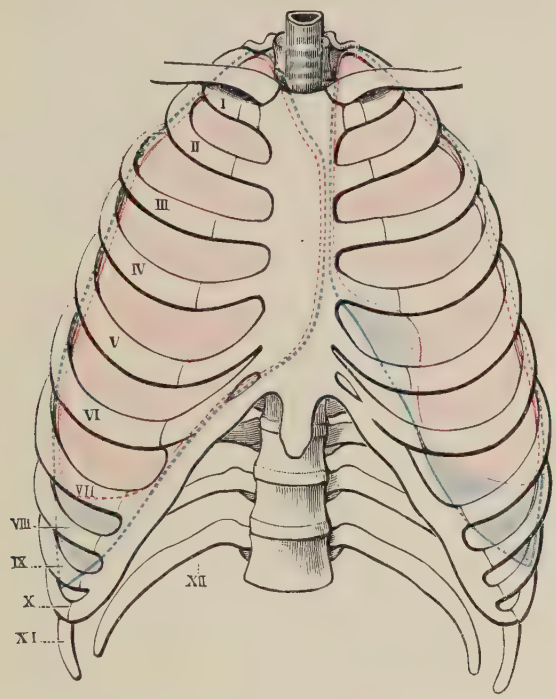

FIG. 870.—Relations of lungs (red) and pleuræ (blue) to the front walls of chest. (Testut.)

is merely a term of convenience, and is not descriptive of anything which normally exists. The pleural cavity is virtual, and becomes actual only when some

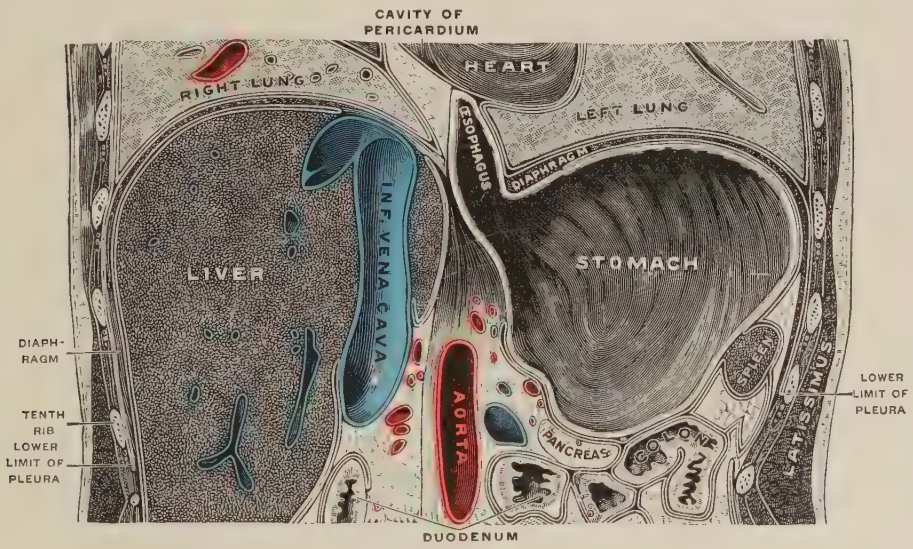

FIG. 871.—Coronal section of trunk, showing relations of thoracic and abdominal viscera.

fluid (air, serum, pus) gets between the layers as a result of accident or disease. In health only enough serous fluid is found between the layers to lubricate them and allow slipping of one upon the other with the least possible friction.

The pleural sac rises above the clavicle an inch or more, is grooved by the subclavian artery on its ventro-mesial aspect, and is bounded in front by the scalenus anterior. Beginning in front, the line of the pleura is traced on the right side from the sterno-clavicular joint to the mid line at the bottom of the manubrium, then vertically down to the level of the fourth costal cartilage, and then slightly outward to the lower end of the gladiolus. Thence it passes outward obliquely behind the cartilages that margin the thorax, and reaches the lower border of the ninth rib in the axillary line. Finally it courses backward nearly horizontally to the twelfth rib. Occasionally it descends to the level of the transverse process of the first lumbar vertebra. The left pleura follows a corresponding line as far as the union of the fifth costal cartilage with the sternum, and thence runs obliquely downward to the ventral end of the seventh rib. From this point its course is similar to that of the right pleura, except that it descends to the lower margin of the tenth rib in the axillary line.

At the hilum of the lung the pulmonary pleura from above is reflected to the root, and thence to the mediastinal pleura; the visceral layers in front of and behind the vertical plane of the hilum not only cover the root, but come together directly beneath it, and form a double-layered, triangular sheet, extending vertically from the root of the lung to the diaphragm, and laterally from the lung to the mediastinal pleura. This fold is the *broad ligament of the lung.*

The pleura upon the lung is delicate and so closely attached that it cannot be readily separated. The costal pleura is thick, and easily detached.

The visceral pleura is supplied by the bronchial arteries; the diaphragmatic and costal by the diaphragmatic and intercostal arteries; and the mediastinal by the posterior mediastinal, bronchial, internal mammary, and superior diaphragmatic. The nerves of the parietal pleura are the intercostal, pneumogastric, phrenic, and sympathetic; of the pulmonary pleura branches from the pulmonary plexus.

THE LARYNX.

The larynx is that portion of the air-passages which is so specially modified that it serves as the principal organ of voice. It connects the upper end of the trachea with the pharynx, and lies in front of the lowest segment of the latter, being itself thinly covered anteriorly by muscles, fasciæ, and skin. It is the occasion of the protrusion (*pomum Adami*) which is plainly to be felt, and in adult males generally to be seen, in the middle of the fore part of the neck. Its framework consists of a series of firm cartilages, held to each other, to the windpipe and to the hyoid bone by ligaments, which permit varying degrees of motion. Mucous membrane, continuous with that of the pharynx above, and the trachea below, lines the larynx, the cavity of which is wide at both ends, but constricted in the middle in such a way that a median, fore-and-aft cleft, the *glottis* (*rima glottidis*, "the cleft of the glottis") is produced. During ordinary, easy breathing, the cleft is wide open, and no noise is made; but, if it is narrowed, voice is caused by the forcible discharge of air from the lungs, and the pitch is determined by the degree of the narrowing, a nearly complete closure resulting in a high tone, and a large separation determining a low one. The sides of the glottis are composed of fibrous bands, which are approximated and separated by the action of the muscles which cause movements of the cartilages. These bands are known as the true vocal cords, and are the most essential portion of the organism of the larynx, the work of other parts being directed chiefly to the production of proper attitudes and degrees of tension in these cords.

Besides its conspicuous function in the production of voice, the larynx performs an important service in preventing the entrance to the air-passages below it of substances in process of being swallowed. This is accomplished mainly by the complete closure of the chink of the glottis. The same act, performed

when the lungs are full, serves to prevent the expiration of the air, and thus to fix the diaphragm and make possible such compression of certain hollow organs of the abdomen as is necessary for the expulsion of their contents, as in defecation, micturition, vomiting, parturition.

The Cartilages of the Larynx.

The principal cartilages of the larynx are the cricoid, the thyroid, the two arytenoid, and the epiglottic. Of secondary importance are the two cornicula laryngis, the two cuneiform cartilages, and the two corpora triticea.

The **cricoid cartilage** (Fig. 872) is the lowest, and a firm union exists between it and the uppermost cartilage of the trachea. It derives its name from its

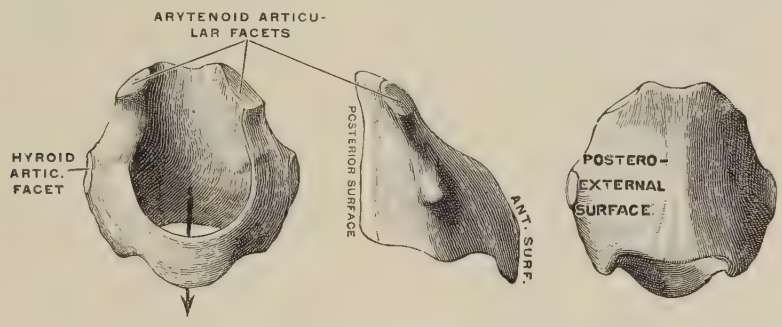

FIG. 872.—Cricoid cartilage, front, right, lateral, and rear views. (Testut.)

resemblance to a finger-ring, and it is so placed that the signet of the ring is behind, its hoop in front. It has articular facets for the arytenoid cartilages at the sides of the upper surface of the signet, and for the lower cornua of the thyroid at the outer side of the postero-external surfaces. It is also connected with the thyroid above by the crico-thyroid ligaments.

The **thyroid cartilage** (Fig. 873), so named from its resemblance to a shield, is the largest of the set, and rests upon the cricoid. At each side it presents a

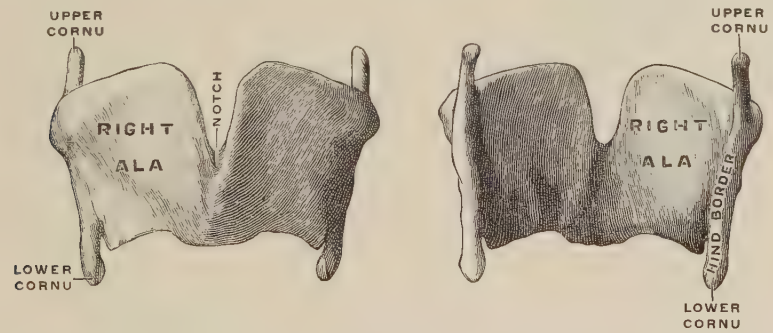

FIG. 873.—Thyroid cartilage, front and rear views. (Testut.)

squarish plate, the *ala*, and the two unite at a sharp angle in the median line at the lower half of their front edges, leaving a deep cleft, the *thyroid notch*, above their line of union. The hind border of each plate is projected downward, forward, and inward in a process, the *inferior cornu*, and upward, backward, and inward in another process, the *superior cornu*.

The lower cornu has an articular facet by which it is joined to the corresponding surface on the side of the cricoid. On the external surface of the ala is an *oblique ridge*, running from a little tubercle near the superior cornu downward and forward to another tubercle near the ventral angle and lower margin. The inner surface of the ala is somewhat concave, and is clad in mucous membrane

in its superior dorsal portion. The thyroid is connected to the hyoid bone by the thyro-hyoid ligaments, and to the cricoid by the crico-thyroid ligaments.

The **arytenoid cartilages** (Figs. 874, 875), fancifully named "pitcher-like," are irregularly pyramidal in shape, and are joined to the upper and back part of the

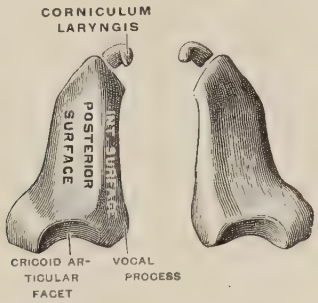

FIG. 874.—Arytenoid cartilages, hind view. (Testut.)

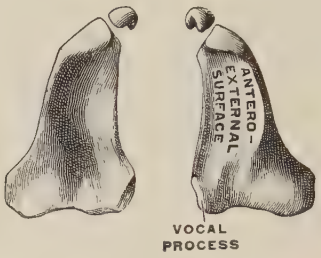

FIG. 875.—Arytenoid cartilages, front view. (Testut.)

cricoid by a movable articulation. Each presents at its base three angles—the anterior, which, from its giving attachment to the true vocal cord, is called the *vocal process;* the external, called the *muscular angle*, from its having certain muscles attached to it; and the internal. Its surfaces are posterior, internal, and antero-external. It has two internal borders, and an external. Its apex points inward and backward, and is prolonged by the addition of a small cartilage, the *corniculum laryngis* ("little horn of the larynx"), somewhat cone-shaped, and bent backward and downward.

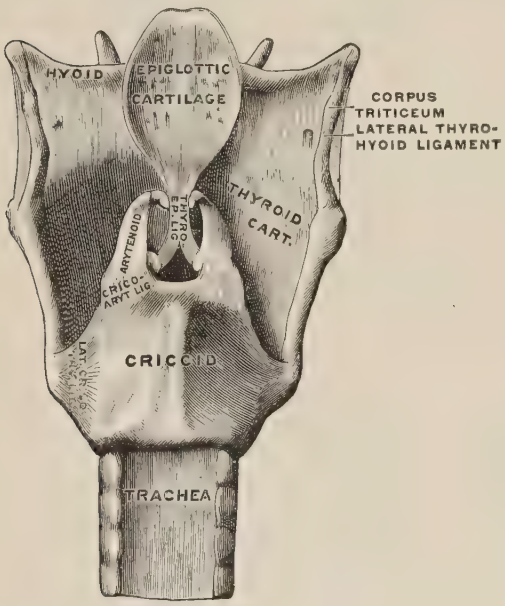

FIG. 876.—Laryngeal cartilages and ligaments from behind. (Testut.)

The **epiglottic cartilage** (Fig. 876), situated, as its name implies, upon (or over) the glottis, is shaped like an oval leaf, its stem being received in the notch between the two wings of the thyroid, where it is bound by the thyro-epiglottic ligament. Its hind surface is concave above, and is convex below this, the prominence in the centre being called the *cushion*.

The major part of its dorsal surface, and the upper portion of its ventral are clad in mucous membrane, three ridges of which, the middle and two lateral *glosso-epiglottic folds*, connect its anterior surface to the tongue, and include two depressions, the *valleculæ*, one on each side of the median line. The part of the cartilage beneath this plane is posterior to the hyoid, the middle thyro-hyoid ligament, and the thyroid cartilage.

The *cuneiform cartilages* are small masses, one on each side, embedded in the fold of mucous membrane, which connects the summit of the arytenoid to the side of the epiglottic. The *corpora triticea* are found one in each of the lateral thyro-hyoid ligaments.

The cricoid, the thyroid, and the arytenoids (except the apices of the last) are composed of true cartilage; the rest of the cartilages are of the yellow variety. The true cartilages are liable to ossify at any time after maturity is attained. At

puberty the larynx undergoes great changes of growth, which are especially marked in the male, and are prevented by castration.

The position and relations of each of the cartilages are shown in Fig. 876.

The Ligaments of the Larynx.

The cartilages of the larynx are movably articulated with one another at various points. The lower cornua of the thyroid articulate with the raised oval facets on the outer side of the cricoid; the arytenoids are jointed with the surfaces at the upper and outer parts of the signet of the cricoid; and the corniculа are usually attached to the apices of the arytenoid pyramids in such a way that motion is permitted. In all of these cases the movement is gliding, or rotary, or both, the cartilages concerned in a joint are united by a capsular ligament, and the articulation has a true synovial membrane.

In addition to these there are numerous ligamentous bands, the most of them largely composed of yellow fibrous tissue, which serve to close in the gaps between nearly related cartilages, and by their elasticity to restore the connected parts when they have been displaced by the action of muscles. The names which these ligaments bear are suggestive of situation and action, as they are mostly composed of the names of the cartilages which they connect, and usually also contain some indication of their relative position.

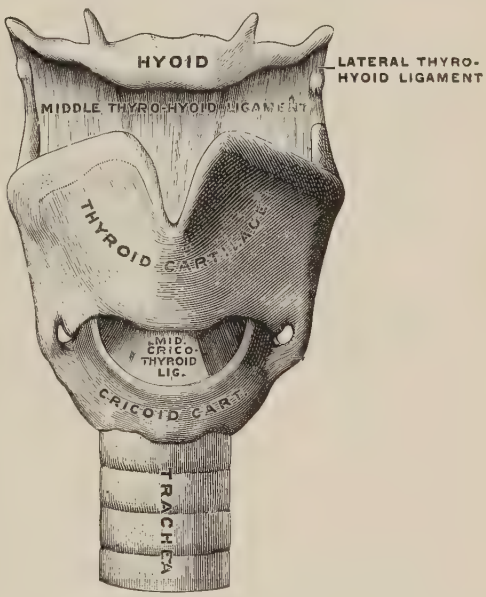

FIG. 877.—Laryngeal cartilages and ligaments from in front. (Testut.)

The *middle crico-thyroid ligament* (Fig. 877) connects in front the upper border of the cricoid with the lower border of the thyroid. On each side this ligament is prolonged backward as the *lateral crico-thyroid ligament* (Figs. 878, 879), which is attached below to the upper margin of the cricoid, but above, instead of running to the opposed edge of the thyroid, it slopes inward in its upward course, and is attached in front to the thyroid cartilage at the angle between the wings, behind to the anterior angle of the base of the arytenoid, and between these two points it is unattached. From its connections

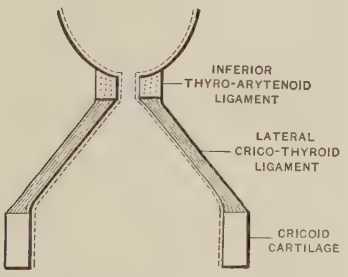

FIG. 878.—Diagram of coronal section of the lateral crico-thyroid ligaments. The mucous membrane is represented in broken lines. (F. H. G.)

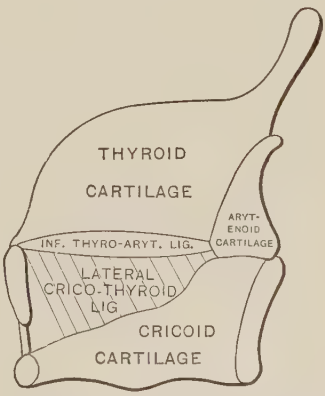

FIG. 879.—Diagram of sagittal section of larynx, showing lateral crico-thyroid ligament of right side. (F. H. G.)

it would be more descriptively named crico-thryo-arytenoid. Its free margin, stretching between the thyroid and the arytenoid, is often called the *inferior thyro-arytenoid ligament*. This last is thick, flattened toward the middle line, and sharp on the upper edge. Covered with mucous membrane it constitutes one of the *true vocal cords* (Fig. 880).

Close to the inferior is the *superior thyro-arytenoid ligament*, arising a little above it on the thyroid, and inserted upon the ridge on the front surface of the arytenoid. It is small, and with its covering of mucous membrane forms the upper or *false vocal cord* (Fig. 880).

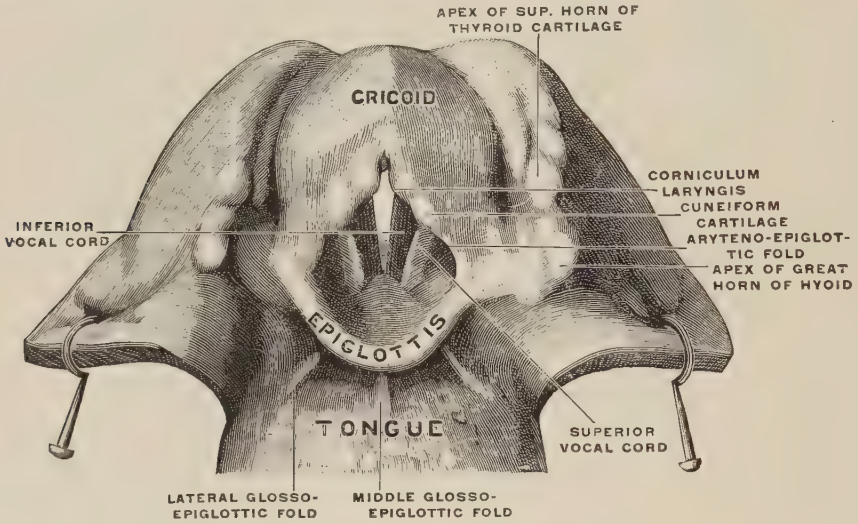

FIG. 880.—Larynx, viewed from above. (Testut.)

From the cricoid to the inner, lower, and back part of the arytenoid is the *crico-arytenoid ligament*. The epiglottic cartilage is attached to the thyroid in the angle between its alæ by the *thyro-epiglottic ligament*. Finally from the antero-external surface of the arytenoid to the lateral border of the epiglottic cartilage runs the *aryteno-epiglottic ligament*, in which is usually found a small, yellow fibro-cartilage, called the *cuneiform cartilage*.

All of these ligaments are in symmetrical pairs, except the middle crico-thyroid and the thyro-epiglottic, which are single and median, with bilateral symmetry.

Besides these ligaments, which are called "intrinsic" from their forming a part of the larynx, there are others which connect it with the hyoid bone above and the trachea below, and are named "extrinsic" on account of their situation outside of the larynx (Fig. 877). The connection between the larynx and trachea is almost precisely like that between neighboring cartilages of the latter. From the upper border of the thyroid to the posterior border of the body and great cornua of the hyoid extends the somewhat elastic *middle thyro-hyoid ligament*, perforated on each side by the superior laryngeal vessels and the internal branch of the superior laryngeal nerve; and from the superior horns of the thyroid to the rear ends of the great cornua of the hyoid stretch the very elastic *lateral thyro-hyoid ligaments*, each enclosing a little bit of cartilage, the *corpus triticeum* ("wheat-like body").

The Muscles of the Larynx.

The muscles of the larynx, like its ligaments, are divided into two groups—the extrinsic, which are outside of, but act upon, it; and the intrinsic, which are attached at both ends to parts of the larynx, and move these parts upon each other. The former are the sterno-thyroideus, thyro-hyoideus, stylo-pharyngeus,

palato-pharyngeus, and constrictor inferior pharyngis, and are described in other places. The intrinsic are the following: Crico-thyroideus, crico-arytenoideus posterior, crico-arytenoideus lateralis, thyro-arytenoideus, thyro-epiglottideus, aryteno-epiglottideus, arytenoideus.

All of these muscles are in symmetrical pairs, except the last, which is single, but bilaterally symmetrical. Their names are a guide to their situation, and suggestive of their action. They are members of the rather small class of muscles whose names are almost invariably Anglicized among English-speaking people, generally by the elimination of the terminal *eus*, and, in the case of the third, of the last two letters of *lateralis* also. They are so plainly exhibited in the figures that elaborate description is unnecessary. Normally, they always act in pairs, and their action affects three things—the width of the aperture of the glottis, the tension of the true vocal cords, and the downward movement of the epiglottis.

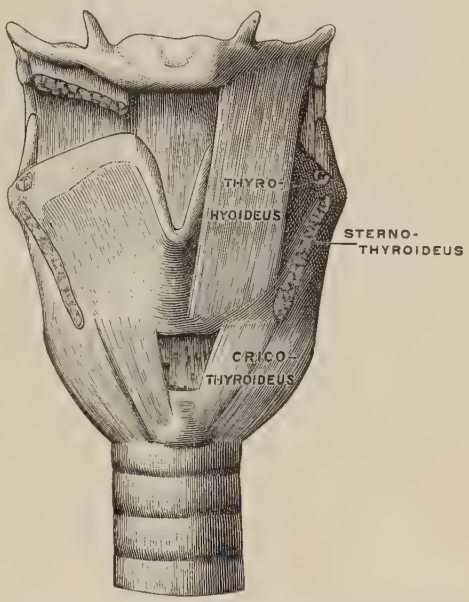

FIG. 881.—Muscles of larynx, front view. The sterno-thyroids and right thyro-hyoid have been removed. (Testut.)

The **crico-thyroid muscle** (Fig. 881) arises from the lower border of the ala of the thyroid and the front edge of its lower horn, converges downward and forward, and is inserted into the front and side of the cricoid. The thyroid being fixed, the anterior part of the pair of muscles lifts the front of the cricoid upward, and the portion of the cricoid behind the crico-thyroid articulation is, consequently, tilted downward, and, as this carries the arytenoids with it, the true vocal cords are tightened. The hind part of the muscle contributes to this result by drawing the cricoid backward. Nerve, the superior laryngeal.

The **posterior crico-arytenoid muscle** (Figs. 882, 883) arises from nearly a lateral half of the hind surface of the cricoid, and converges to the outer angle of the base of the arytenoid, into which it is inserted. The two muscles draw their points of insertion backward and toward each other, and thus cause a divergence of the anterior processes and the vocal cords which are attached to them. Nerve, the inferior laryngeal.

The **lateral crico-arytenoid muscle** (Fig. 882) arises from the side of the upper border of the cricoid, passes upward and backward, and is inserted into the external angle of the arytenoid. The two cause approximation of the vocal cords by pulling the external arytenoid angles forward and downward, thus turning the anterior angles inward. Nerve, the inferior laryngeal.

The **thyro-arytenoid muscle** (Figs. 882, 883) consists of an internal portion, which occupies the most of the triangular space included in the mucous fold enwrapping the true vocal cord; and a broad, external portion, flattened laterally against the inner surface of the thyroid ala. It arises from the lower half of the inner surface of the thyroid near its angle, and from the adjacent surface of the crico-thyroid ligament. It converges backward, outward, and upward, and is inserted (internal part) into the vocal process and (external part) into the adjacent portion of the outer surface and the outer angle of the arytenoid. The pair draws the arytenoids forward, relaxing the vocal cords. Nerve, the inferior laryngeal.

The **thyro-epiglottic muscle** (Fig. 882) arises from the thyroid, just above the thyro-arytenoid, passes upward and backward, and is inserted into the side of

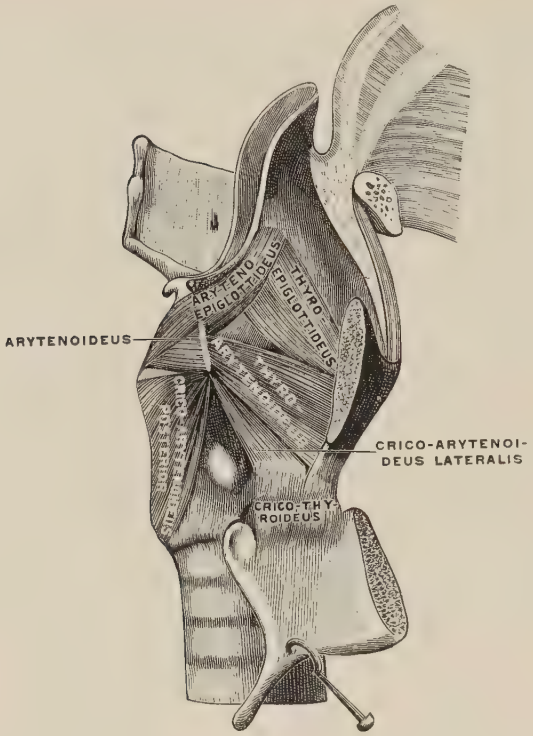

FIG. 882.—Muscles of larynx, right side. The right ala of the thyroid cartilage has been cut through and turned down. (Testut.)

the epiglottic cartilage. With its mate it depresses the epiglottis. Nerve, the inferior laryngeal.

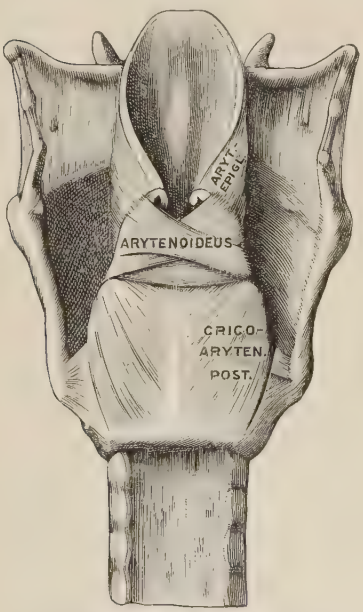

FIG. 883.—Muscles of larynx, from behind. (Testut.)

The **aryteno-epiglottic muscle** (Fig. 882) arises near the apex of the arytenoid, passes forward and upward, and is inserted into the side of the epiglottic cartilage. With its mate it draws the epiglottis backward and downward. Nerve, the inferior laryngeal.

The **arytenoid muscle** (Fig. 882) (ary-arytenoid) connects the two arytenoid cartilages, being attached to the outer half of the concavity on the back of each. The ventral fibres are transverse, but the dorsal are arranged in two oblique bundles, which cross each other, and are continued into neighboring muscles—the thyro-arytenoid, aryteno-epiglottic, and lateral crico-arytenoid—as well as inserted each into the highest part of the opposite arytenoid cartilage. The muscle draws the arytenoid cartilages together, thus closing the part of the rima glottidis included between them. Nerves, the superior and inferior laryngeal.

The *action of the intrinsic muscles* of the larynx may be summarized thus:

Tighteners of the cords—the crico-thyroids.
Relaxers of the cords—the thyro-arytenoids.
Wideners of the aperture—the posterior crico-arytenoids.
Narrowers of the aperture—the lateral crico-arytenoids and the arytenoids.
Depressors of the epiglottis—the thyro-epiglottic and the aryteno-epiglottic.

It will be observed that the arytenoid muscle has both the superior and inferior laryngeal nerves distributed to it; the crico-thyroid the superior only; and all of the other muscles the inferior only.

The Lining of the Larynx (Figs. 884, 885).

Mucous membrane lines the larynx throughout. It is continued from the mucosa of the tongue and pharynx, extends over the epiglottic cartilage and from the aryteno-epiglottic ligaments downward and inward to the superior thyro-arytenoid ligaments, which it covers on their median and under surfaces, constituting with them the superior, or false, vocal cords. The membrane is continuous below with that of the trachea, and lines the inner surface of each of the lateral crico-thyroid ligaments and the inner and upper surfaces of the inferior thyro-arytenoid ligaments, which with it compose the inferior, or true, vocal cords. Between the false and true vocal cords of each side is a narrow horizontal opening of fusiform outline, the aperture of a cavity, called the *ventricle of the larynx*, which extends outward and then bends upward just on the mesial side of the upper part of the thyro-arytenoid muscle, and is lined with mucous membrane prolonged from that of the vocal cords. From the front of the ventricle extends upward a *laryngeal pouch* (*sacculus laryngis*), which is narrow, long, and embedded in fat. It is supposed that this cavity is of service by supplying mucus for the lubrication of the true vocal cords, the secretion being squeezed out by the contraction of the muscles which surround the excavation.

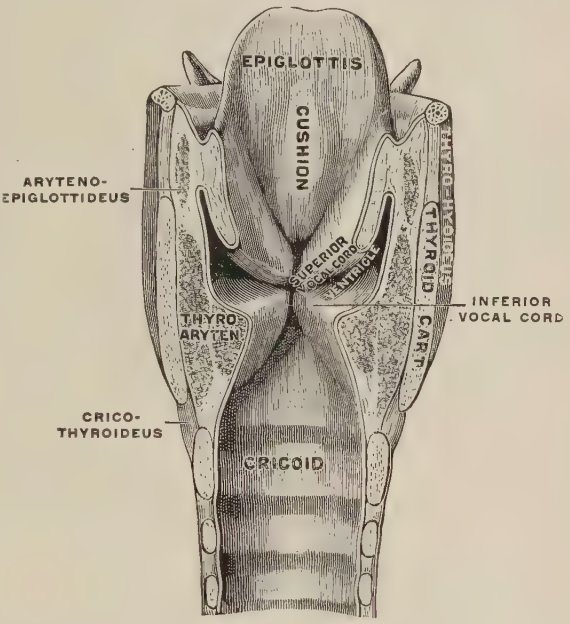

FIG. 884.—Coronal section of larynx, rear view of front half. (Testut.)

The mucosa is pale and thin, especially upon the true vocal cords. In most parts its epithelium is columnar and ciliated, but just above the false vocal cords it becomes flattened and stratified, and it is of this kind also upon the true vocal cords, and in small areas elsewhere. Beneath the membrane in the aryteno-epiglottic region is a good deal of loose areolar tissue. Mucous glands are numerous and large, excepting on and about the true vocal cords.

Viewing the larynx from above (Fig. 886), an upper opening is seen, its front wide and semicircular, its sides drifting together behind and below in an undulating curve. The anterior boundary of this aperture is made by the epiglottis, the downward-sloping sides by the aryteno-epiglottic folds of mucous membrane, which run from the sides of the epiglottis to the tops of the arytenoid cartilages, and are nodulated by the cuneiform and corniculate cartilages. Through this wide aperture are seen in front the backward projection from the surface of the epiglottis called its *cushion*; on the sides, diverging backward and outward, the upper or false vocal cords; farther down in the cavity and nearer the median line the true vocal cords, and, on a level with them, the inner margins of the bases of the arytenoid cartilages; and finally, occupying the middle line and a little space on each side of it, the rima glottidis. This chink of the glottis is about an inch in its fore-and-aft measurement, the front two-thirds of this

being bounded laterally by the true vocal cords, the hind third by the arytenoid cartilages. The portion between the vocal cords is called the vocal part, from its function in the production of voice; the portion between the arytenoids is known as the respiratory part, on account of its use in the process of breathing.

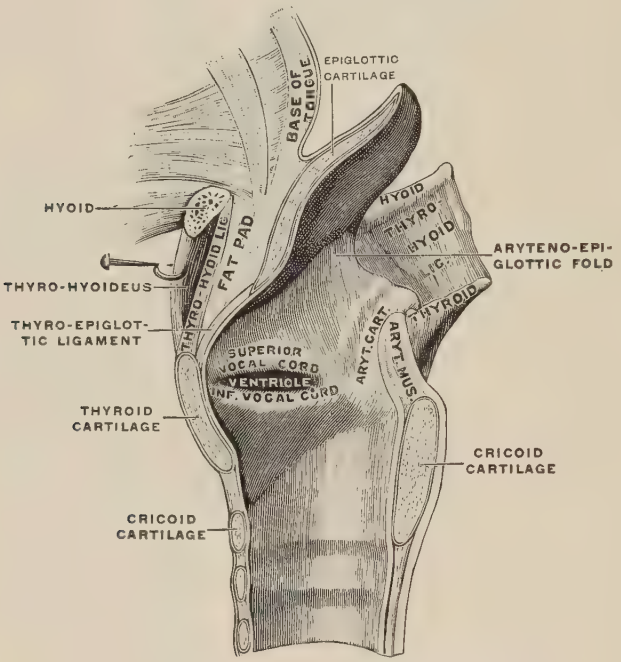

FIG. 885.—Sagittal section of larynx, right half. (Testut.)

The *arteries* of the larynx are branches of the superior and inferior thyroid; the *veins* of its upper part are radicles of the internal jugular, those of its lower

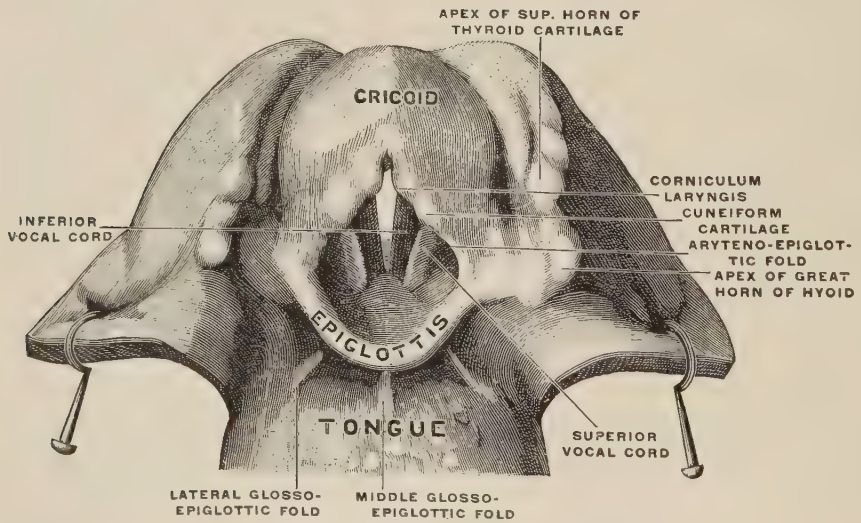

FIG. 886.—Larynx, viewed from above. (Testut.)

part run to the brachio-cephalic; its *lymphatics* are tributaries of deep cervical nodes; its *nerves* are derived from the vagus through its superior and inferior laryngeal branches, and from the sympathetic.

THE URINARY SYSTEM.

By F. H. GERRISH.

THE double function of appropriation and elimination belongs both to the alimentary and to the respiratory systems, each being concerned in the supply of new material, and also in the casting off of effete substances. But the urinary system is simply excretory: its only office is relieving the body of certain waste products, which, if allowed to remain in it, would injure the organism, and ultimately destroy life.

The organs of the urinary system are the two *kidneys*, which form the urine from materials furnished by the blood; the *ureters*, ducts which convey the urine away from the kidneys; the *bladder*, a reservoir in which the urine is stored until circumstances are convenient for its discharge; and the *urethra*, a tube through which the urine passes from the bladder, and is finally voided.

THE KIDNEYS.

The essential organs of the urinary system are the kidneys. The materials which they abstract from the blood are in solution in water, and this solution is the *urine*. The formation of this fluid is constant; and, as fast as it is produced, it is conducted to the bladder. In some details of gross anatomy the two kidneys differ slightly, as will be related subsequently; but functionally they are identical, and the physiological anatomy of one is exactly like that of the other.

A kidney is a compound, tubular gland—a vast multitude of microscopic tubes, all lined with epithelial cells, and abundantly supplied with blood-vessels. The study of a single one of these tubes reveals the physiological anatomy of the kidney, and with that it is best to begin.

A *uriniferous tube* starts as a hollow globe (the capsule); then come in regular succession a constricted part (the neck), a tortuous (the proximal convoluted tube), an undulating and twisted (the spiral tube), a long portion bent so abruptly near its middle that the two parts are parallel (the looped tube), a second twisted part (the distal spiral tube), a portion with a zig-zag contour, full of short lines and marked angles (the irregular tube), a second tortuous part (the distal convoluted tube), a short, arching part (the junctional or arched collecting tube), and, finally, a long portion (the straight collecting tube), the wide, terminal part of which is called the excretory tube.[1]

The various parts of this long tube differ not only in shape and direction, but also in diameter. All of these features will be seen in the part of Fig. 890, at the extreme left.

Structure of a Uriniferous Tube.—The tube is composed of a basement membrane and a single layer of epithelial cells, which rest upon it and vary in form according to their situation. In most narrow portions of the tube and in the capsule they are flattened; in the neck and collecting tubes they are cuboidal or columnar; and elsewhere they are somewhat cuboidal and granular toward the

[1] The capsule is called also the capsule of Bowman, the looped tube is known as Henle's, the irregular bears the name of Schachowa, and the excretory is known as the duct of Bellini.

bore (this part containing a large nucleus), and toward the membrane they look like a mass of rods and their sides are grooved. Where the tube is not very small, the lumen occupies only about one-third of the entire diameter on account of the relative thickness of the cells.

The tube is enveloped in a network of blood-vessels, from whose contents its cells abstract the ingredients of the urine. The vascular apparatus will be described later on.

Lobes of the Kidney.—It has been estimated that each kidney contains about half a million capsules, and fifteen miles of tubing. The disposition of this vast number of tubes is very intricate, and yet so regular as to produce practically invariable gross appearances in different parts of the compound organ. In some lower animals the kidney, instead of being a single, coherent mass, consists of a number of similar lobes, so slightly united that the appearance of the organ suggests a bunch of grapes. A condition approaching this obtains in the human embryo, though the independence of the lobes is not as marked (Fig. 887). The study of the naked-eye appearances of a separate lobe is necessary to an understanding of the arrangement of the tubes.

FIG. 887.—Fœtal kidney, showing lobes. (Testut.)

An Ideal Lobe.—Each lobe is like a cone whose apex has been cut off, and its place supplied by the apex of a smaller cone (Fig. 888). A vertical section through the middle of this cone brings to view a cut surface in which are seen two apparently distinct kinds of material (Fig. 889). Within is a triangular portion, red and streaked with alternating dark and light lines from base to apex; and, enclosing this, except at

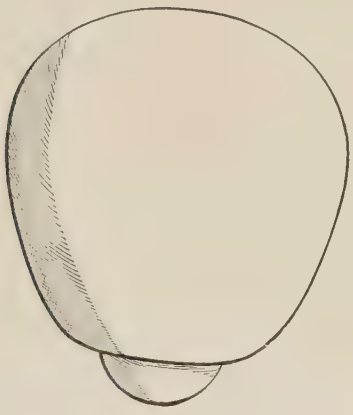

FIG. 888.—Diagram of a lobe of the kidney. (F. H. G.)

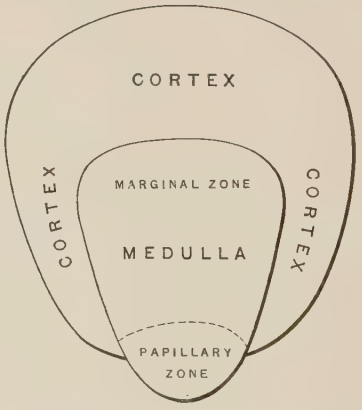

FIG. 889.—Diagram of a vertical section of a lobe of the kidney. (F. H. G.)

the apex, is a thick, lighter colored, granular part. The former is the *medulla* ("the pith"), or *medullary pyramid*; the latter is the *cortex* ("the bark"), or *cortical portion*. Reckoning from the base to the apex of the lobe, the cortex occupies a little more than a third of the distance. A fibrous capsule covers it, and a thin stratum of the cortex just beneath this is called the subcapsular layer. The pyramid is divided into two parts—a smaller called the *papillary zone*, from its including the apex (papilla), and a larger, known as the *marginal*, *boundary*, or *limiting zone*, this being darker and more distinctly striated. Intruding from

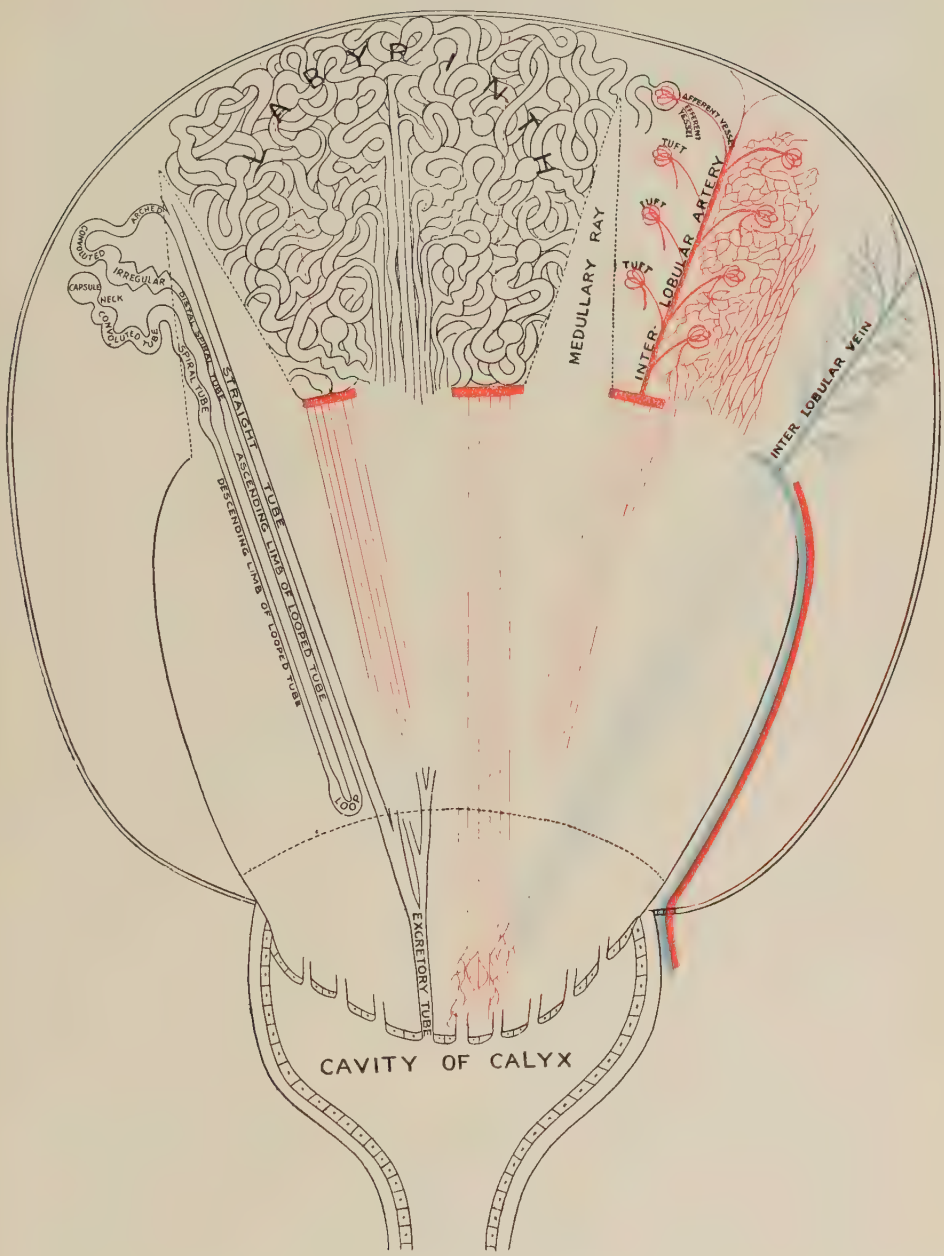

FIG. 890.—Diagram of the structure of a lobe of the kidney. The lobe is seen in vertical section, the cortex being marked off from the medulla. Four medullary rays encroach upon the cortex. At the left is shown the course of a single, continuous series of tubes -the straight and spiral tubes appearing in the medullary ray, the straight, looped, and excretory in the medulla proper, the capsule, neck, convoluted, irregular, and arched in the cortex proper. Next is seen the labyrinth, composed of a mass of tubes in the cortex, with a medullary ray for a centre. Equidistant from the ray on each side is a broken red line, marking the position of an interlobular artery. The parts between these lines constitute a lobule. Farther to the right is an interlobular artery, giving off lateral branches (afferent vessels), each of which ends in a tuft of capillaries, from which the blood is collected by an efferent vessel. The uppermost of the tufts is shown enclosed in a capsule. On the right of the interlobular artery the efferent vessels break up into a capillary network, which surrounds the (unrepresented) tubes in the cortex and ray. The lowest efferent sends vertical vessels also into the medulla. On the right the interlobular vein is seen gathering the blood from all the parts supplied by the interlobular artery. A branch of the renal artery courses upward between cortex and medulla, and forms an arch (here broken) over the base of the medulla. From it the interlobular arteries pass upward into the cortex, and straight branches go downward into the medulla, supplying its structure, and ending at the apex in the capillaries. From the last the radicles of the renal vein arise, and accompany the straight arteries to the base of the medulla, where a venous arch is formed, continuous with which is the vena comes of the entering artery. The calyx embraces the apex of the medullary pyramid. It is lined with epithelium, which continues from it over the apex, the latter being perforated with the many apertures of excretory tubes. (F. H. G.)

the medullary portion into the cortical are a number of narrow triangles, their bases resting on the base of the pyramid, and their apices reaching nearly to the subcapsular layer. They are called *medullary rays* (pyramids of Ferrein), on account of their radiation from the medulla.

The diagram (Fig. 890) will show that these various appearances are due principally to the arrangement of the different portions of the tubes. It will be seen that in the medullary rays are all of the spiral tubes, and the uppermost parts of the straight collecting tubes and of the ascending limbs of the looped tubes (distal spiral tubes), these being placed side by side in line with the chief axis of the ray, the longest being in the middle. In the remaining and greater part of

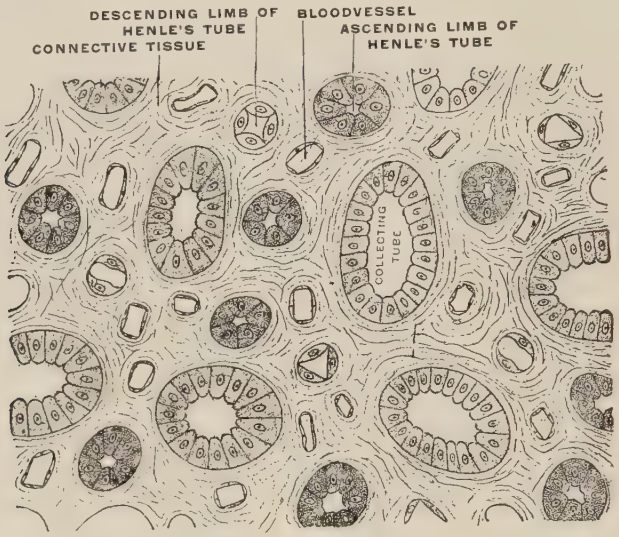

FIG. 891.—Transverse section of kidney, made in the marginal zone—greatly magnified. Observe the amount of the interstitial connective tissue. (Testut.)

the cortex are the capsules and their necks, and the convoluted, irregular, and arched collecting tubes, all so intricately intermingled as to produce the granular look of the part, and to merit the name of *labyrinth*. The medulla contains the greater part of the length of the looped and of the collecting tubes; and, as these are straight and side by side, the delicate striation of the medulla is explained. The broad alternating dark and light streaks in the pyramid are due to a vascular distribution as will presently be seen.

The Vessels of the Kidney.—The *arteries* enter the lobe in the cortical substance at the sides of the pyramid. When they reach the level of the base of the pyramid, they turn inward and run across between the medullary and cortical portions, constituting the *arterial arches*, and giving branches upward into the cortex, and, according to most authorities, branches downward into the medulla. The branches to the cortex, called *interlobular*, enter the cortex half way between the medullary rays, and give off short side-twigs, the *afferent vessels* ("the vessels carrying to"), each of which terminates in a globular bunch of capillaries, the *glomerulus*, or Malpighian tuft. This tuft is commonly described as being inside of the capsule, which is the beginning of a uriniferous tube, and, in one sense, this is correct. But, from the physiological point of view, the tuft is outside of the capsule; for it is related to it only as if it had pushed in and stretched the capsular wall at a point opposite the neck, carrying everything before it until the cavity was nearly obliterated. The cells now lining the capsule are comparable with the parietal layer of a serous membrane, and those covering the glomerulus with its visceral layer. The capsule and tuft together are called the *Malpighian body*. The blood leaves the tuft through a vessel, called *efferent* ("carrying

from"), which emerges beside the afferent. It is probably an artery, although it is often spoken of as a vein. It breaks up into a close capillary plexus, which surrounds the secreting tubes in the cortex. From this network come venous radicles, which empty into minute veins, the *interlobular*, accompanying the interlobular arteries. These veins terminate in *venous arches* between the cortex and medulla, and thence leave the lobe by the track taken by the artery in entering. The lowest efferent vessels give pencils of capillaries to the tubes in the medulla.

The branches from the under side of the arterial arches, always accompanied by corresponding radicles of the venous arches, lie between the tubes of the pyramid in regular parallel groups, producing the darker lines in the alternating series of stripes of the boundary zone. These vessels are named *vasa recta*. On their way to the papilla the arterioles give capillaries to the tubes, and at the papilla these end in venous radicles, which run straight up to the suprapyramidal venous arches.

The *vessels in the cortex*, which run vertically to the vascular arches, mark the limits of the primary lobules of the labyrinth, and hence are called "*interlobular*." A transverse section of the cortex shows the lobulation, each lobule having a circular bundle of tubes, the medullary ray in its centre, and a tangled mass of tubes around it.

At the apex of the papilla the uriniferous tubes end as the *excretory tubes* (ducts of Bellini) in from ten to eighty openings, called *foramina papillaria*, producing the appearance of the nozzle of a watering-pot, through which the urine constantly trickles. As it escapes it is received into the upper end of the excretory duct of the lobe, which is here expanded and resembles a cup, from which it is named the *calyx*. The rim of the calyx is attached around the base of the papilla. The surface of the papilla is covered with mucous membrane, which is continuous with that lining the calyx and the rest of the excretory duct.

Framework of the Kidney.—The *capsule* which covers the lobe is a condensed areolar tissue, which is continuous with that clothing the calyx, and immediately beneath it is a delicate stratum of unstriped muscular tissue. Quite a bundle of this last material surrounds the pyramid just above the attachment of the calyx.

The tubes and vessels are supported by *interstitial connective tissue*, which is small in amount, except around the Malpighian bodies and in the papillary region. It is condensed at the surface, where it is intimately connected with the true capsule.

Coalescence of the Lobes (Fig. 892).—There are from eight to twenty lobes in a kidney, and each of them answers to the foregoing description. Beginning as separate parts, they afterward coalesce at their adjacent surfaces, and the fusion is so perfect that the included portions of the tunic disappear, and the lines of contact cannot be traced. The apices of the lobes converge, and the papillæ project into a central cavity, the *sinus*. A section of the kidney after the union of its lobes shows that the pyramids are separated by masses of cortical substance, the *columns of Bertin*, and that there is more of this between the pyramids than there is elsewhere. The incongruity of calling that part of an organ its bark, which is mostly not on the outside, is not dissipated until one learns that the name "cortex" is applied primarily to the outer layer of renal substance in the individual lobes—a use of the term eminently descriptive in the circumstances—and it is not abandoned when the lobes are fused. The part of the cortex, whose title to the name in the compound kidney no one would think of disputing, presents in vertical section the appearance of curving across the base of each pyramid from one column to another, whence the name *cortical arches*.

The coalescence of the lobes often goes so far that the apices of two pyramids become fused into one, their bases continuing separate; so that in a kidney with fourteen pyramids there may be only ten papillæ.

Gross Features of the Kidney (Figs. 893, 894).—The kidney (in Latin *ren*, from which comes the adjective "renal"), made up of lobes as just described, is somewhat bean-shaped, presenting a convex front surface, and a flattened back

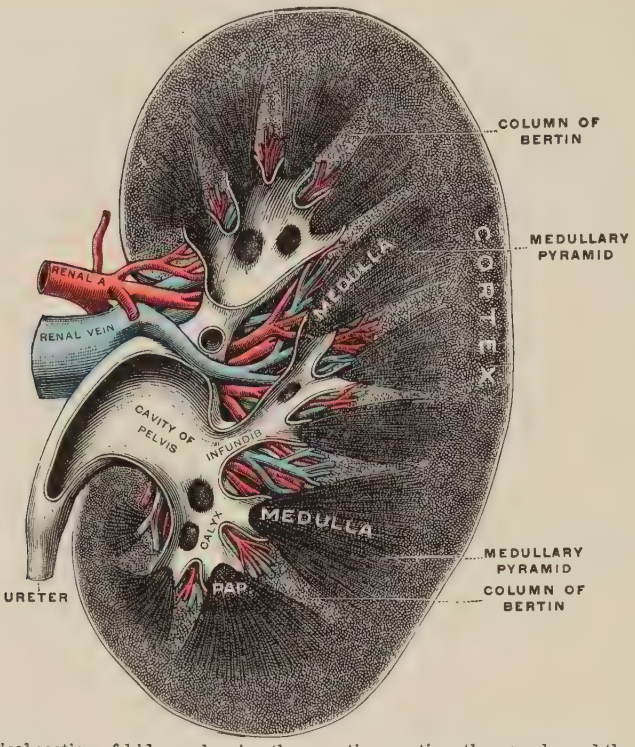

FIG. 892.—Vertical section of kidney, showing the secreting portion, the vessels, and the beginnings of the ureter. (Testut.)

surface; rounded upper and lower ends, the former being a little the larger; a convex outer border, and an inner border, which has a notch, called the *hilum*.

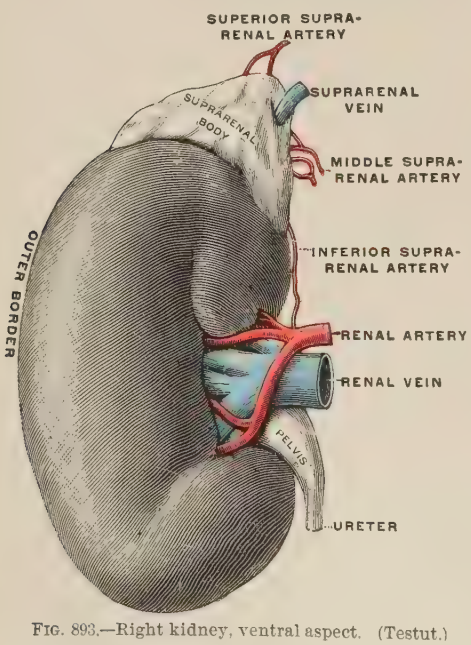

FIG. 893.—Right kidney, ventral aspect. (Testut.)

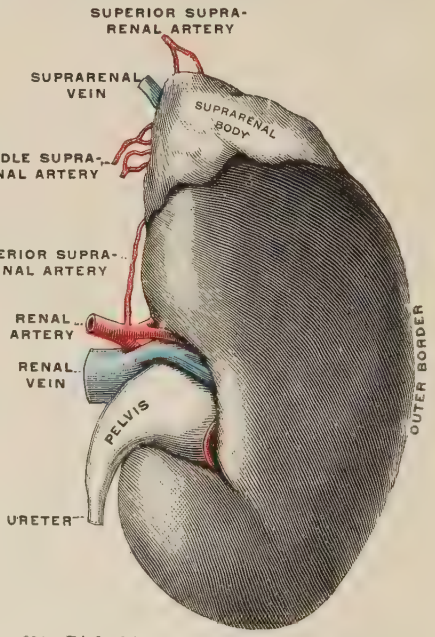

FIG. 894.—Right kidney, dorsal aspect. (Testut.)

The hilum presents a vertical cleft, with rounded front and back lips, and this is the narrowed entrance to the cavity (sinus) of the kidney. The *sinus* is a deep

excavation, flattened from before backward, and reaching half way from border to border. The papillæ project into it, and it encloses the divisions of the renal vessels, the beginnings of the excretory apparatus, lymphatic vessels and nodes, nerves, and a quantity of adipose tissue, which fills the spaces left unoccupied by these structures, and affords an elastic bed upon which they rest. The outer tunic extends into the sinus through the hilum, becomes continuous with the sheaths of the vessels, and is reflected onto the calices.

The kidney is about $4\frac{3}{4}$ inches *long*, $2\frac{3}{4}$ inches *wide*, and $1\frac{1}{4}$ inch *thick*. It *weighs* from 4 to $4\frac{1}{2}$ ounces. Its *surface* is smooth, no traces of the fœtal separation of the lobes remaining. It is of a reddish-brown *color*. It has a firmer *consistence* than either liver or spleen, but is lacerated by moderate force.

The *artery of the kidney* is the renal, and is large relatively to the size of the organ it supplies (Fig. 895). It divides into four branches, which pass into the sinus, and then break up into vessels, which enter the columns of Bertin,

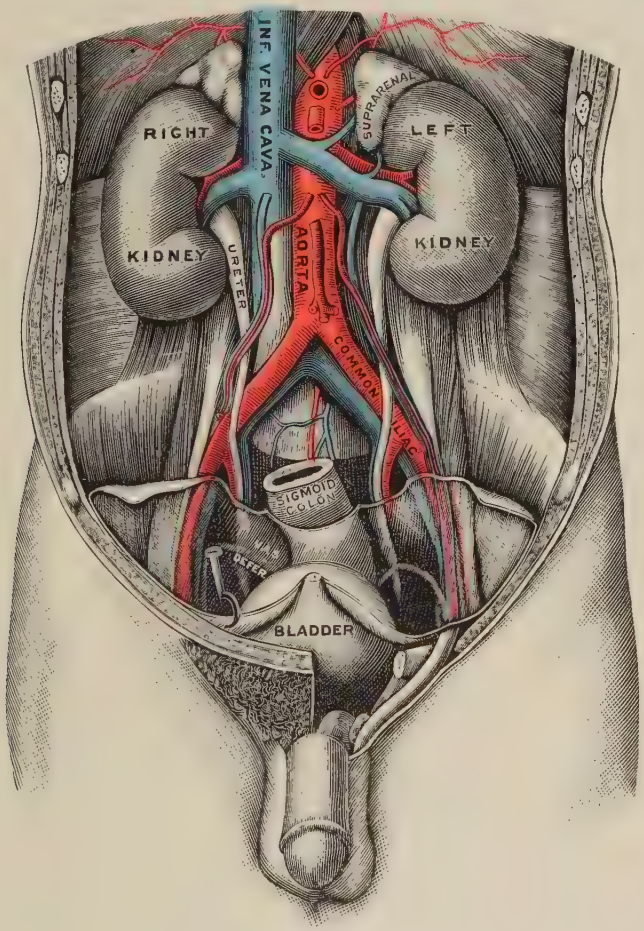

FIG. 895.—The kidneys, the ureters, and the bladder, in their normal position. (Testut.)

and pursue a course, which has already been described. The surface of the kidney receives small branches from the suprarenal, spermatic, and lumbar arteries. The *veins* accompany the arteries, and are somewhat anterior to them. They end in the vena cava inferior; and, as this vessel is at the right of the median line, and close to the right kidney, the right renal vein is very short. The *lymphatic vessels* are numerous, especially in the labyrinth, and there are several nodes in the sinus. Both the superficial and deep lymphatics are tributary to the lumbar nodes. The *renal nerves* come from the renal plexus and small splanchnic. They

accompany the arteries, but have not been traced beyond the interlobular. Some fibres from the vagus, also, have been observed.

Situation of the Kidneys.—The kidneys are situated at the back of the abdomen, one on each side of the spinal column, behind the peritoneal cavity, on a level with the bodies of the twelfth thoracic and upper two or three lumbar vertebræ, the right being about one-half inch lower than the left. The long axis of each is directed from above downward and a little outward, so that the upper ends are nearer the middle line than are the lower. Their hind surfaces look backward and inward. Their lower ends are two inches or less above the iliac crests.

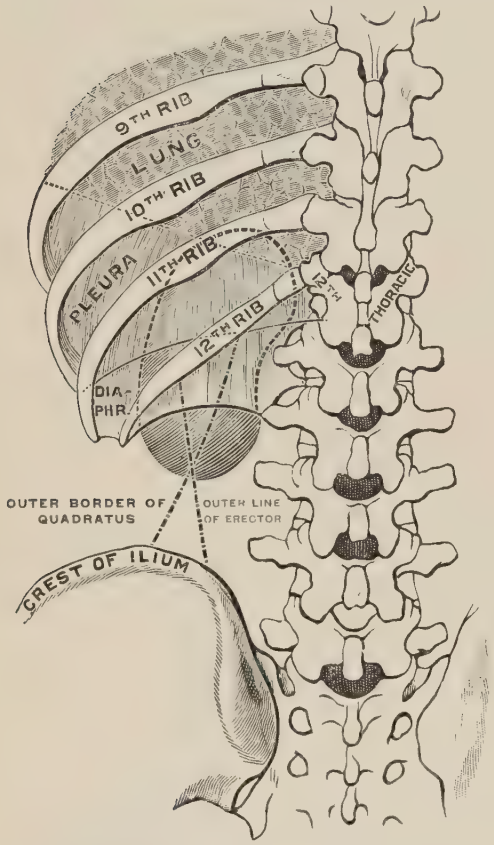

FIG. 896.—Relations of the left kidney to the lung, pleura, ribs, spine, muscles, and hip-bone. (Testut.)

Supports of the Kidneys.—The kidneys are kept in place by their vessels, the peritoneum, and the abundant fatty tissue in which they are embedded, and which constitutes the "*adipose capsule*" of some authors.

Relations of the Kidneys (Fig. 896).—The upper end of each kidney is capped by a suprarenal body, which laps over upon the front surface and inner border. The hind surface of each is in relation to the diaphragm, and the quadratus lumborum and psoas magnus muscles. The left kidney has the last two ribs behind it, the right extends no higher than the lower margin of the eleventh rib. The anterior surface of the right kidney is related from above downward to the suprarenal body, the liver, the ascending colon and its mesocolon, and the jejuno-ileum, and, near its mesial border, to the duodenum; the anterior surface of the left kidney to the suprarenal body, the spleen, the stomach, the pancreas, the splenic flexure, the descending colon, and the jejuno-ileum. Its external border is between three and four inches from the middle line. The mesial border of the right kidney is very near the vena cava inferior, that of the left is about an inch from the aorta. The lower limit of the pleura (Fig. 896) comes below the inferior margin of the twelfth rib near the vertebral column.

A portion (more than half) of the ventral surface of the kidneys is covered by peritoneum. The considerable area of the right kidney, which is in contact with the under surface of the liver, has a serous coat, and the same is true at the lower end, where the mesocolon is in relation to it. At the upper part of the left kidney is an area behind the stomach, to which the small sac of the peritoneum furnishes a tunic, and at the lower extremity is a serous area, where the mesocolon is in contact. The non-serous areas are connected with the various organs with which they are related by areolar tissue.

Peculiarities.—There may be a great difference in the size of the two kidneys; occasionally there is but one kidney, and this is likely to be considerably larger than the normal; very rarely the two kidneys are united, a band of renal tissue extending between them across the vertebral column.

THE EXCRETORY APPARATUS OF THE KIDNEYS.

The urine is conducted from the kidneys by the ureters, by them poured into the bladder, and finally discharged from this reservoir through the urethra.

The Ureters.

The ureter for each kidney begins with the *calices* which enclose the papillæ. They are somewhat fewer than the papillæ, because one calyx may embrace two or even three of them. By the convergence and union of the calices in the upper, middle, and lower regions of the sinus respectively three funnel-shaped tubes, the *infundibula*, are formed; and these focus upon and empty into a large dilatation, the *pelvis* ("basin"), which terminates in the *ureter proper*. The pelvis lies partly within and partly outside of the sinus. When seen from front or back its form is suggestive of the bowl of a tobacco-pipe, the tubular ureter standing for the stem; but it is much compressed antero-posteriorly, having to emerge from the sinus through the hilum, which, although but a narrow slit, gives passage also to the renal vessels, the latter lying in front of the pelvis, the order of arrangement being as follows: vein in front, artery next, and ureter behind and below. The ureter proper is as large as a small goose-quill, about 14 inches long, and passes downward and inward to the upper level of the sacrum, and thence forward and inward to the base of the bladder, whose outer coat it perforates, and running obliquely between this and the inner tunic for three-quarters of an inch, opens into the cavity of the bladder by a narrow slit, which is one and a half inch or less from its opposite fellow and from the beginning of the urethra (Fig. 897). The practical effect of this arrangement is to prevent the reflux of urine from the bladder; for, although the admission of the fluid is not interfered with, distension of the bladder so presses together the sides of the channel that not a drop can return to the ureter.

FIG. 897.—Diagram showing method of entrance of the ureter into the bladder. (F. H. G.)

Structure of the Ureter.—The ureter has three coats: an inner or mucous, a middle or muscular, and an outer or fibrous. The *mucous coat* is continuous with that of the bladder below and with that covering the renal papillæ above. Its epithelium is stratified, the upper layer consisting of cuboidal cells, with concavities on their attached surfaces, into which fit the blunt ends of the pyriform cells next below, the taper ends of the latter fitting in between the processes of fusiform cells underlying them, and last of all a stratum of irregular cells. There is no well-defined submucous coat. The membrane displays longitudinal folds. The *muscular tunic* has two layers, an outer longitudinal and an inner circular. The *fibrous coat* is a mixture of the white and yellow varieties; it is continuous with the renal capsule, which, entering at the hilum, is reflected upon the calices. The ureter is surrounded by areolar tissue.

Branches from the renal, spermatic, internal iliac, and inferior vesical arteries supply the ureter, its veins correspond to these, its lymphatics run to the lumbar nodes and to the receptaculum chyli, and its innervation comes through the inferior mesenteric, spermatic, and hypogastric plexuses.

In its descent the ureter is behind the peritoneum all of the way.

Relations.—The pelvis is on the level of the spine of the first lumbar vertebra. Behind the ureter proper are the psoas magnus, the common iliac artery near its bifurcation, the common iliac vein, the sacro-iliac synchondrosis, and the obturator internus. It is crossed in front by the spermatic vessels, and ves-

sels of the ascending (or descending) colon. The right ureter has the vena cava inferior at its inner side. The vas deferens runs between its lowest part and the bladder, and here the vesicula seminalis overlaps it. In the female the ureter courses beside the cervix uteri, but at the distance of half an inch, and then obliquely crosses the upper third of the vagina to the bladder, which it enters about midway between the extremities of the vagina.

The Bladder.

The bladder (*vesica urinaria*, "the urinary bladder," always being meant when the noun is not qualified) is the reservoir in which the urine is collected from the ureters, and contained until a convenient time for evacuation. It has four tunics: the mucous, which is that nearest the cavity, and then in order the areolar, the muscular, and the serous. The *mucosa* has a stratified epithelium, similar to that of the ureter, is loosely attached to the muscular coat by the areolar, is deficient in well-defined glands and in muscularis mucosæ, is smooth when spread out by accumulation of urine, but, during the empty condition is thrown into irregular rugæ, excepting in a small, triangular space (*trigonum*) between the openings of the ureters and the urethra. This little area is never wrinkled, but is marked in the median line by a slight ridge, the *uvula vesicæ*. The base of the trigone is marked by a ridge, the *plica ureterica*, extending from one ureteral orifice to the other in a line curved with its convexity forward. The *areolar tunic* connects the mucous and muscular, and permits large freedom of movement, such as is essential in an organ subject to great changes of shape and size. The *muscular tunic* has an outer, longitudinal layer, which runs sagittally; inside of this a stratum in which the fibres are intricately and irregularly criss-crossed, but have a general transverse (circular) direction, and internal to this an imperfect, thin, longitudinal layer. The middle layer is somewhat thicker about the urethral opening, and thus constitutes the *internal sphincter*. The *serous coat* is a reflection of the peritoneum, and is only a partial tunic, covering the superior surface, and the upper and hind part of the lateral surfaces, and, in the male, the upper part of the posterior surface. The thickness of the combined walls varies much within normal limits, being small in distension, great in collapse, and especially marked if there is good tone to the muscular coat.

Form, Size, and Position of the Bladder.—Without regarding several widely varying, normal circumstances, it is impossible to speak definitely of the form, size, position, and relations of the bladder. One must know the sex and approximately the age of the individual, whether the organ is empty, rather full, or distended, the condition of the muscular coat, and the fact as regards pregnancy. When the bladder is collapsed, its mucous walls fall together in such a way that a sagittal section shows the line between them in the shape of a V with unequal and widely-spread arms, the point of the V indicating the opening of the urethra (Fig. 854). This view affords a means of designation of the most important *surfaces*. The part included within the arms of the V we call *superior* or intestinal surface; that beneath the long arm the *anterior* or pubic surface; and that under the short arm, the *posterior* or rectal surface. Besides these are right and left *lateral* surfaces, which are narrow when the organ is empty.

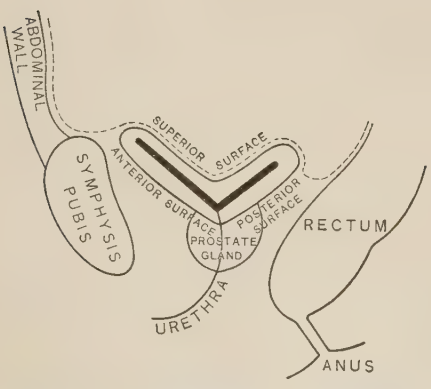

FIG. 898.—Diagram showing the shape, position, and relations of the bladder, when empty, sagittal section. (F. H. G.)

When the bladder is moderately full, its sagittal section is very different (Fig. 899). The upper surface has changed from concavity to convexity, all of the others have become rounded, and the angles between the surfaces have vanished. The bladder in these circumstances holds about eight fluidounces, and has not risen out of the pelvic cavity. But, if this amount of urine is much exceeded, the limit of comfort is passed, and pronounced distension obtains, lifting the organ above the pelvic brim to a height commensurate with the degree of fulness, and bringing it within reach of recognition by abdominal percussion. In the female the bladder is flattened from behind forward (owing to the presence of the uterus and vagina between it and the rectum), increasing the lateral and diminishing the antero-posterior diameters. In the child the bladder is somewhat pear-shaped, with its small end upward to the urachus, and is almost an abdominal organ; but, with increase of years, it sinks to its adult position in the pelvis.

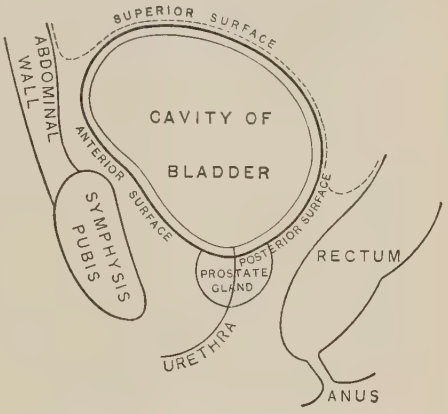

FIG. 899.—Diagram showing the shape, position, and relations of the bladder, when distended. (F. H. G.)

The orifice of the urethra is at the lowest point of the bladder, and is about an inch behind a point half way up the dorsal surface of the pubic symphysis. In old men the posterior wall is liable to sag below this level, and thus permit the retention of a portion of the urine. Enlargement of the prostate gland, which is exactly beneath the bladder, in contact partly with the pubic and partly with the rectal surface, causes a bulging into the vesical cavity, and raises the opening high above the surrounding walls. There is no constricted part of the bladder which is entitled to be called a neck: the vesical opening of the urethra (*meatus urinarius internus*) is not funnel-shaped, but occurs as an abrupt aperture.

Supports of the Bladder.—The bladder is rather freely movable, but is held within normal limits in various ways. The recto-vesical portion of the pelvic fascia is an important means of fixation. Around the lower levels of the bladder this fascia is closely united to the muscular tunic, and is sometimes spoken of as a covering of the bladder, thinning out rapidly as it stretches upward. Several parts of this fascia are conventionally described as *true ligaments of the bladder*—two anterior, two lateral, two posterior—but they are usually indistinct, and it is not important to mention more than the two anterior or pubo-prostatic, which connect the lower part of the pubic body with the front of the prostate gland and the adjacent portion of the bladder. Just beneath each of these is a prolongation of the front and lower part of the longitudinal muscular layer, called the *vesico-pubic muscle*, connecting bladder and pubis. The urachus and the obliterated hypogastric arteries extend from the junction of the upper and anterior surfaces to the umbilicus. Folds of peritoneum aid in mooring the bladder, two posterior being reflected to it from the sides of the rectum, the hollow between them being called the *recto-vesical pouch*; two lateral from the iliac fossæ; and one superior, folded over the urachus. These serous reduplications are called *false ligaments*. The continuity of the vesical, prostatic, and ureteral mucous membranes, the strong areolar and adipose connections of the bladder with all of the immediately neighboring organs, and the blood-vessels—all these are factors in the fixation of the bladder.

Relations of the Bladder.—The previous description has involved incidentally so much mention of the relations of the bladder that but little more need be said of them. Its posterior surface (Fig. 900), which is the widest, rests in

the male upon the rectum, the seminal vesicles and vasa deferentia intervening. The serous covering of the superior surface extends for a variable distance upon the posterior, and thence is reflected to the rectum. The line of its lowest attachment to the bladder forms the base of a triangle, whose sides are made by the vasa deferentia. The area thus bounded is accessible to surgical operation through the rectum; but it is unsafe to count upon more than an inch of non-serous surface in the median line between the hind limit of the prostate gland and the fold of peritoneum, though there may be double this amount. In the female the bladder has behind it the vagina and uterus.

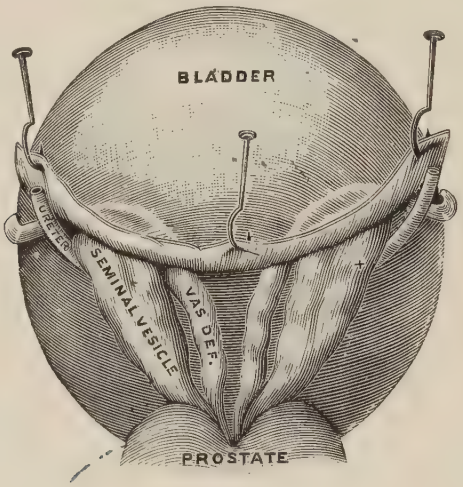

FIG. 900.—Base of the bladder, showing the vasa deferentia and seminal vesicles. The peritoneum is raised by hooks. (Testut.)

When the bladder is distended, the anterior (pubic) surface is so enlarged that it partly rises out of the pelvis, and at the same time the peritoneum is lifted away from the lower part of the abdominal wall, and stretched over the extended area of the superior surface. This leaves a space of two inches or more just above the pubic crest, in which an incision can be made without injuring the peritoneum.

The *arteries* of the bladder are the superior, middle and inferior vesical, and, in the female, the uterine and vaginal, also; its *veins* are radicles of the internal iliac; its *lymphatics* are tributary to the internal iliac nodes; and its *nerve-supply* is from the third and fourth sacral, and the hypogastric plexus of the sympathetic.

The Urethra.

The urethra is the tube by which the urine is conducted from the bladder. Its name, like "ureter," is derived from the Greek word which means "to urinate." The male and female urethræ differ so materially that a separate description of each is necessary.

The Female Urethra.

This tube (Fig. 901) begins at the meatus urinarius internus in the bladder, and ends at the meatus urinarius externus in the vulva. It runs downward and a little forward, curving with the concavity in front. It is about one inch and a half long, and its lumen is about a quarter inch across. It is situated directly in front of, and is closely associated with, the lower part of the anterior wall of the vagina, through which it can easily be felt. Its external orifice is the narrowest

part, and is located between the clitoris and the opening of the vagina. The front and rear surfaces of the tube are in contact.

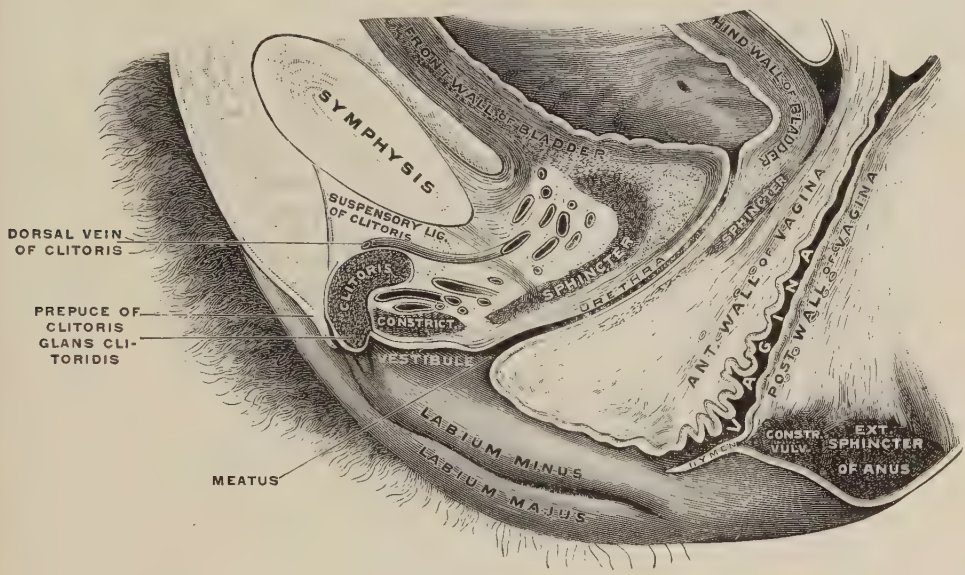

FIG. 901.—The female urethra and surrounding parts seen in sagittal section. (Testut.)

The lining is a pale mucous membrane, and it is gathered into small, longitudinal folds (Fig. 902). Its epithelium is flattened and stratified, except at the uppermost part, where it is transitional; its corium is beset with small papillæ, which are most numerous near the lower end. Mucous glands are abundant. The submucous coat is areolar, and contains an unusual proportion of yellow fibrous tissue. Outside of this is the muscular tunic in two layers, an internal longitudinal, and an external circular. At the vesical end of the tube the circular fasciculi are particularly numerous, and form a ring, which is erroneously called the sphincter of the bladder, but is properly named the *internal sphincter of the urethra*. Between the muscular layers are scattered many elastic fibres. In both layers, and especially in the longitudinal, is a great quantity of blood-vessels, the veins being far more conspicuous by their number and size, and in their arrangement highly suggestive of erectile tissue, though unlike this in being disseminated throughout the muscular coat, instead of constituting a discrete layer.

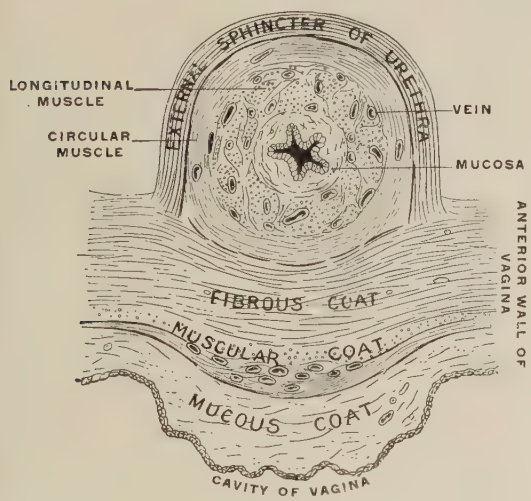

FIG. 902.—The female urethra, seen in coronal section. (Testut.)

The female urethra is very distensible, and may be dilated far beyond its usual calibre without loss of its tone.

The Male Urethra.

The male urethra (Fig. 903) is a tube which carries not only urine, but also semen, and only a small portion nearest the bladder is devoted exclusively to the former use. It extends from the meatus urinarius internus in the bladder to the

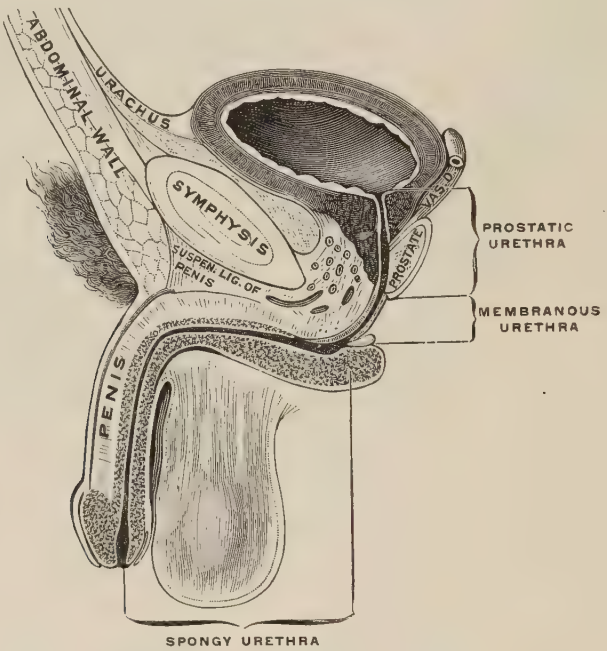

FIG. 903.—The male urethra, in sagittal section. (Testut.)

meatus urinarius externus at the distal end of the penis. It is divided into three portions: first, the *prostatic* (called also the *prostatic urethra*), named from its being contained in the prostate gland; second, the *membranous* (called also the *membranous urethra*), reaching from the distal end of the prostate to the proximal end of the spongy body, and passing through the triangular ligament of the perineum, named because, instead of being embedded in the substance of some organ, as are the other portions, it is a free tube in the greater part of its extent; and third, the *spongy portion* or the *spongy urethra*, which occupies the corpus spongiosum of the penis. The proximal inch of the spongy urethra, being contained in the bulb of the spongy body, is sometimes called the *bulbous portion*.

The *length of the urethra* varies at different times in the same individual, owing mainly to physiological changes in the condition of the erectile penis, in which the largest part of the urethra is contained. In the flaccid state it measures $6\frac{1}{2}$ inches; but this length is vastly increased by the erection of the penis. In the common operation of catheterization the urethra is stretched two inches or more. Its length is divided among its three portions as follows: prostatic $1\frac{1}{4}$ inch, membranous $\frac{3}{4}$ inch, spongy $4\frac{1}{2}$ inches. The first and second parts are not subject to great physiological changes such as characterize the third.

The urethra has two pronounced *curves*. In the prostatic portion its course is nearly perpendicularly downward; in the membranous it runs downward with a forward sweep; in the spongy it passes forward almost horizontally for two inches, and then bends sharply downward. Thus, the first and second portions describe a gentle curve which is concave forward, and the third portion has a curve (so sharp as to be almost an angle) about midway of its length (Fig. 904). This

second curve is obliterated when the body of the penis is raised, as in the introduction of an instrument to the bladder through the urethra, and also during erection. The part of the urethra between this curve and the bladder is called

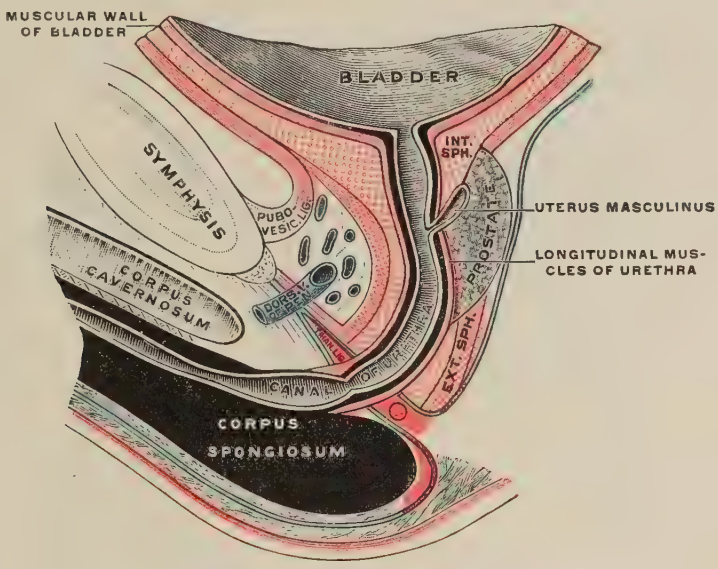

FIG. 904.—Proximal portions of urethra with surrounding parts. (After Testut.)

the fixed portion; but it is practicable for a skilled hand to pass a straight instrument into the bladder without injuring the tube or its surroundings.

The *bore of the urethra* varies in size and shape in different parts (Fig. 905). The prostatic portion has the largest calibre, measuring one-third of an inch half way of its course, and a little less at its extremities. It is also the most distensible segment. In its hind surface (the floor) is an elevation which rises gradually from behind and then descends more abruptly (Fig. 906). This is called by various names—*verumontanum*, "a mountain spit," *caput gallinaginis*, "the cock's head," *colliculus seminalis*, "the little seminal hill." From the summit of this ridge a little tubular cavity runs upward and backward for about half an inch, called *uterus masculinus*, "the male womb," because it is the homologue of the uterus of the female. It is also called *sinus pocularis*, "the cuplike hollow," and *vesicula prostatica*, "the prostatic vesicle." Upon its lateral lips open the two ejaculatory ducts, through which the semen is squirted into the urethra. On each side of this mound is a groove, the prostatic sinus, into which open the most and the largest of the ducts from the glandular masses of the prostate, the smaller ducts opening in the sides and roof (front surface) of the tube. The presence of the crest causes a transverse section of the urethra to look like an inverted U. The membranous portion has a diameter of one-fifth inch or less, which is also that of the meatus externus. The latter is the least dilatable part, and, consequently, an instrument which will pass the meatus will go through every other portion of the canal. Where the membranous urethra perforates the rigid triangular ligament it is not as readily dilated as elsewhere. The spongy urethra has a calibre between the other portions in size, and uniform except at its extremities. In front for about half an inch it is dilated and thus forms the *fossa navicularis*, "the boat-shaped pit," and behind for nearly an inch it widens in every direction, making the *pars bulbosa*, "the bulbous part."

The lowest point of the membranous urethra is about one inch beneath the pubic arch. The upper part of this portion is in close relation to the rectum.

Structure of the Urethra.—The *inner coat* of the urethra is mucous membrane, continuous above with that of the bladder, below with the skin. It is unusually rich in elastic fibres. It has, most markedly in the spongy portion, fine longitudinal folds, which are effaced during urination. The tube does not stand open, like the trachea or a severed artery, but opposite surfaces (generally the front and rear) of mucosa are in contact. The epithelium of the prostatic portion is similar to the vesical; in most other parts it is a simple columnar, but for a

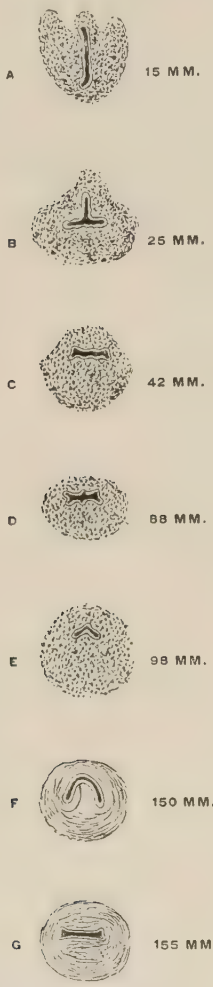

FIG. 905.—Cross sections of the male urethra at various distances from its free end, showing marked alterations of form. (Testut.)

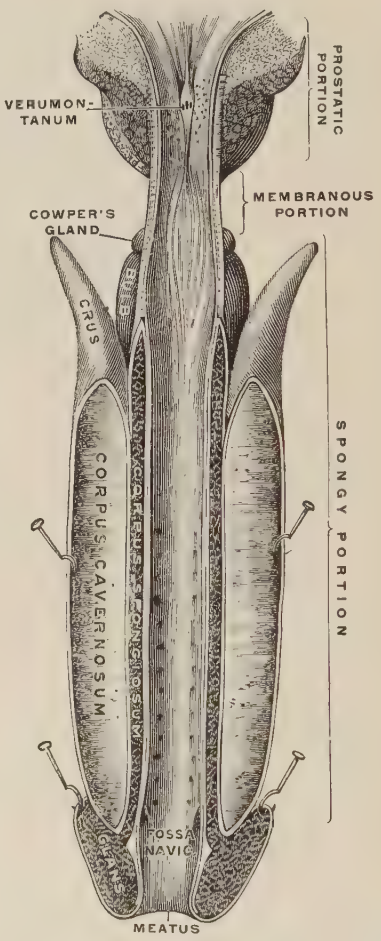

FIG. 906.—The male urethra, laid open on its anterior (upper) surface. (Testut.)

quarter inch back from the meatus it is of the flattened variety and stratified. The corium is plentifully studded with small papillæ. Mucous follicles and racemose glands are practically everywhere proximal to the navicular fossa. There are also many openings which were formerly thought to belong to glandular structures, but have been ascertained to be blind depressions obliquely set in the mucosa, their mouths always directed toward the external meatus (Fig. 907). They are *lacunæ*, "little lakes," and are found in the free spongy portion, proximal to the fossa navicularis, in two sets, large and small. The large are one-third inch deep and occur in a single, median row in the anterior (upper) wall; the small are located principally in the anterior surface and at the sides in

longitudinal rows. Half an inch or more from the meatus externus in the anterior surface is a very large depression, nearly covered by a valve-like fold, and called *lacuna magna*, "the great lacuna." In any of the larger pits the point of a fine instrument may catch, with results diagnostically misleading and therapeutically injurious. Doubtless, also, the obstinacy of gonorrhœal inflammation is often due to the concealment of the specific virus in some of these recesses, beyond the reach of topical remedies. It will be seen that there are many openings upon the surface of the membrane—those of mucous follicles, racemose glands, prostatic glands, ejaculatory ducts, the uterus masculinus, and the lacunæ; to which array must be added the mouths of the ducts of Cowper's glands, in the proximal part of the spongy urethra, the glands themselves being situated one on each side between the two layers of the triangular ligament, close to the membranous portion of the tube.

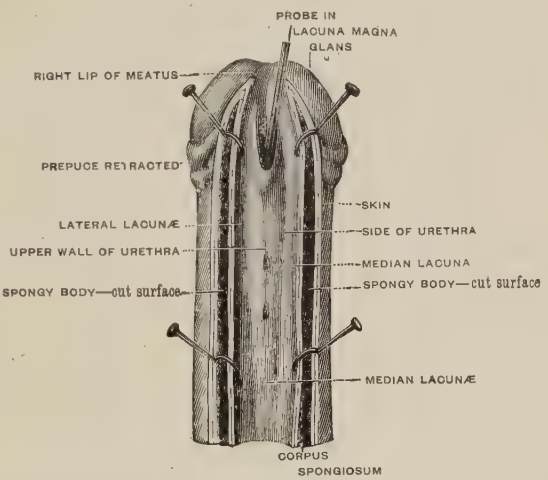

FIG. 907.—The distal portion of the male urethra, laid open on its posterior (under) surface, showing the lacunæ. (Testut.)

The mucous membrane is surrounded by an *areolar coat* of great elasticity, in the meshes of which are large numbers of convoluted vessels, mostly venous, a tissue similar to the true erectile tissues being thus constituted. Outside of this is a *coat of unstriped muscle* in two layers, the inner being longitudinal in the disposition of its fasciculi, the outer circular. The whole is enclosed in a fibrous tunic of variable thickness. In the upper part of the prostatic portion the circular muscular layer is thick, and is sometimes spoken of as the sphincter of the bladder; but it should be called the *internal sphincter of the urethra.* This should not be confounded with the structure of striped muscle which surrounds the tube just above the triangular ligament, and is the *external sphincter of the urethra.* The compressor urethræ embraces the membranous portion in the space between the two layers of this ligament.

THE DUCTLESS GLANDS.

By F. H. GERRISH.

THERE are several organs whose general, gross appearance is very similar to that of secreting glands, but which are conspicuously unlike the latter in the respect that they do not possess any duct by which their secretion is discharged. From this fact they have long been called *ductless glands*. This name involves a seeming paradox, for the word "gland" implies the capacity to form a product known as a secretion, and not only had nobody seen a secretion from one of these organs, but the absence of a channel of exit strengthened the idea that there was no such material to be discharged. With this view of the case authors endeavored to devise a name for this class of bodies, which should be more in accordance with the supposed facts. No such name, however, obtained general adoption, and the old title continued to be commonly employed, though with a mental protest by those who disliked inaccurate nomenclature.

In recent years investigations along physiological and pathological lines have shown that some of these organs have a profound influence upon nutritive changes in the body, and have established the fact of "internal secretion." In other words some of these bodies have been found to form substances out of materials brought to them in the circulation, and to discharge these products of their activity into the blood; and it is rendered highly probable that the others of the group have a similar office. Since the fact of internal secretion is so well established, it is unnecessary longer to seek for another name for this class of organs, which, though ductless, are really glands.

These glands are the spleen, the thyroid body, the thymus, the suprarenal capsules, the hypophysis, the parathyroids, and the carotid and coccygeal glands. Some writers include the tonsils and the epiphysis in the enumeration; but the former are more properly counted among the lymphatic structures, and the latter probably has no appreciable use, being an aborted attempt at the formation of a third eye.

It is not inappropriate to remark in this connection that the possession of a secretion and an excretory duct for it does not necessarily prevent an organ's having an additional function of like nature with that of the ductless glands. For example, the liver has other duties besides that of secreting the bile; and the testicles, while forming the essential elements of the semen, exert a profound impression upon the physical and mental attributes of the individual, as best shown in the arrest of development in various directions in those persons who have been castrated before reaching the age of puberty.

THE SPLEEN.

The spleen (*lien*) (Fig. 908) is the largest of the ductless glands. It is situated in the dorsal part of the epigastric and left hypochondriac regions, behind

the stomach, covering the distance from the eighth to the eleventh ribs, and lying with its long axis in line with that of the tenth rib. Its *measurements* are usually not less than five inches for length, three for breadth, and one inch for thickness, and they may be considerably more than the above without departure from the normal, so great are the variations of its size within physiologic limits. Its *weight* also differs, conformably with its size, but will generally be five ounces or more. It is purple in *color*, of a soft *consistency*, rather friable, and sags out of shape by its own weight.

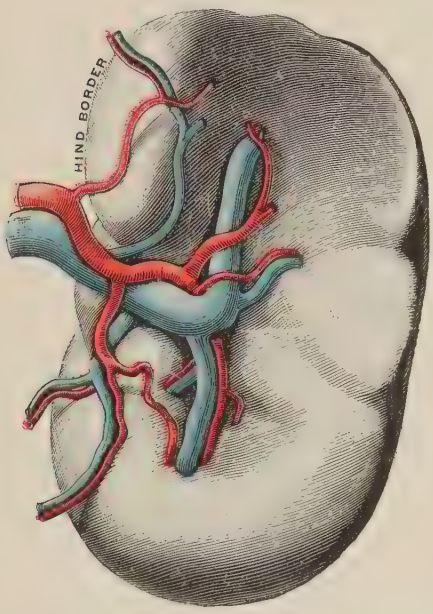

FIG. 908.—The spleen, showing the gastric and renal surfaces and the blood-vessels. (Testut.)

Surfaces and Borders.—It presents three distinct surfaces, separated by three borders. The *phrenic surface*, so called from its relation to the diaphragm, is convex, is as large as both of the others, and faces backward and to the left. The opposite (mesial) area is divided by a lengthwise ridge into a larger, anterior, concave *gastric surface*, in contact with the stomach, and a smaller, posterior, concave *renal surface*, which receives the left kidney. The lower end is blunt, and is sometimes designated as the basal surface. The *anterior border* is between the phrenic and gastric surfaces, is sharp and notched; the *posterior border* separates the phrenic and renal surfaces, and is rounded; the *internal border* is the ridge between the gastric and renal surfaces. Upon the

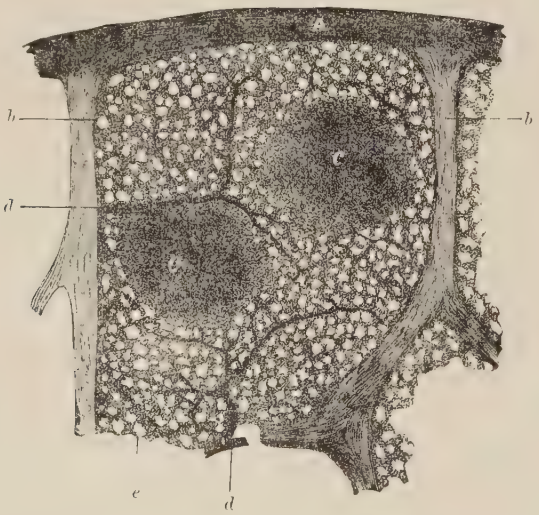

FIG. 909.—Section from human spleen: *A*, capsule; *b*, *b*, trabeculæ; *c*, *c*, Malpighian bodies (lymph-follicles), traversed by arterial twigs. In the follicle to the left, part of the arterial twig is seen in longitudinal section; in that to the right, it appears in cross-section to the right of the centre of the follicle. *d*, arterial branches; *e*, splenic pulp. The section is taken from an injected spleen. (Kölliker.)

gastric surface, close to the internal border is a notch, the *hilum*, marking the passage of the splenic vessels and nerves.

Structure of the Spleen.

The spleen has a complete serous coat (Fig. 910), which is reflected from it at the hilum, a layer passing to the stomach, as the front lamina of the *gastro-splenic omentum*, the hind lamina being contributed by the small sac of the peritoneum, and another layer passing to the kidney, as the hind lamina of the *lieno-renal ligament*, whose front lamina is furnished by the small sac of the peritoneum. From the upper end of the spleen a serous fold, the *phreno-splenic ligament*, connects it with the diaphragm.

Beneath the serous coat is the *tunica propria*, composed of mingled white and yellow fibrous tissues, the latter material being very abundant, and giving the organ great elasticity. Many cords and bands (*trabeculæ*) project into the organ from the inner surface of this tunic, and some plain muscle-cells are mixed with the fibrous elements. At the hilum the tunica propria is reflected inward upon the vessels, and forms sheaths around them. At some distance from the surface, the arteries having become smaller by branching, the character of the sheath is changed from fibrous material to lymphoid, and at frequent intervals it is thickened so as to present globular or ovoid masses, the *Malpighian corpuscles*, sometimes $\frac{1}{25}$ inch in diameter.

By the entrance of the trabeculæ in one direction and the ensheathed vessels in another, the contained room of the spleen is divided into numberless, minute, irregular, intercommunicating spaces; and these last are subdivided by delicate fibrous strands, connecting trabeculæ and vessel-sheaths, the surfaces of these little cords being covered by branched fibrous-tissue cells. The resulting areolæ

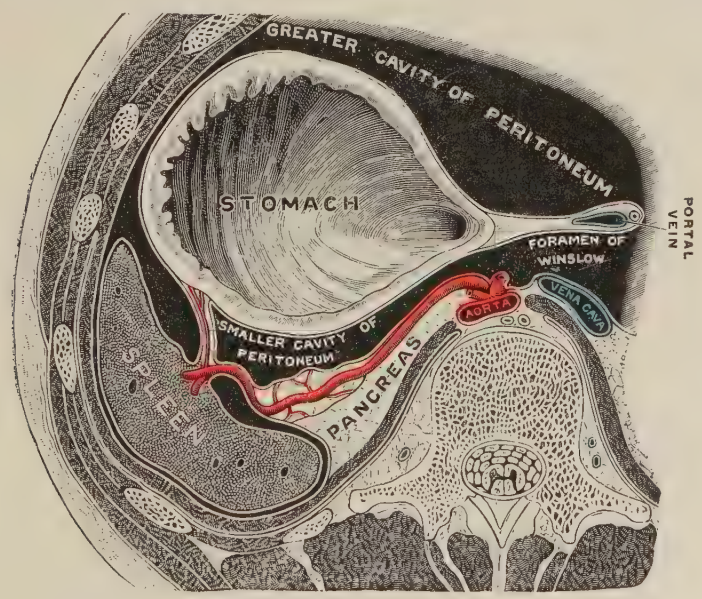

FIG. 910.—Horizontal section in the region of the spleen. (Testut.)

are occupied by the *spleen-pulp*, which is substantially blood, thickened by the addition of great numbers of leucocytes, among which are certain large corpuscles, called *splenic cells*.

The arrangement of the blood-vessels is extraordinary, and altogether peculiar to this organ. The *splenic artery*, which, judged by the standard of the arteries of other organs, is relatively very large, runs in the lieno-renal ligament, and divides into five or six branches before entering the organ. Rapidly breaking up into smaller vessels, when the minute arteriole stage is reached, which is generally succeeded by the stage of capillaries, the vessels abruptly terminate,

and the blood is poured into the wall-less spaces of the spleen-pulp, from which it is collected by venules. The Malpighian corpuscles are factories for leucocytes, and the arterial blood courses among the latter, its flow being impeded by their great number and by the filamentous framework of the pulp-spaces. The blood in the splenic vein is remarkably rich in leucocytes. It is thought that one function of the spleen is the disintegration of worn-out colored corpuscles of the blood, as the pulp contains many fragments of these cells.

The *lymphatics* run in the tunica propria, the trabeculæ, and the walls and sheaths of the vessels. They discharge into the splenic nodes, from which the lymph passes to the cœliac nodes. The *nerves* are derived from the solar plexus.

The structure of the spleen is in some respects very similar to that of the lymph-nodes. The adenoid reticular tissue, the accumulations of lymph-cells, the great relative size in children, the atrophy which occurs in old age—all suggest an immense community of lymph-nodes, especially modified by a peculiar blood-supply.

Not very infrequently *accessory spleens* (*lienculi*) are found. They are globular and small, but otherwise look like the principal spleen, near which they are situated.

THE THYROID BODY.

The thyroid body (*glandula thyroidea*) (Fig. 911) has, independently of its function of internal secretion, a claim to the name of gland, because it began its

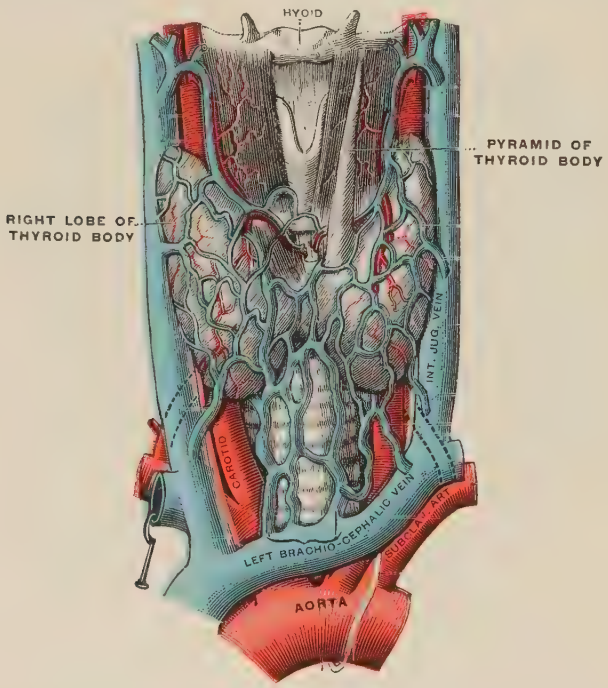

FIG. 911.—The thyroid body and the related blood-vessels. (Testut.)

career as a secreting organ with a duct. In the description of the tongue mention was made of the foramen cæcum, just at the rear of the hindmost circumvallate papilla. This blind hole is a remnant of the *thyro-glossal duct*, the channel through which the thyroid (in the early fœtal condition a compound tubular gland) communicated with the pharynx. In the process of development the duct became shrunken, and finally was nearly obliterated. The acini of the

gland, having thenceforth no excretory duct, become dilated with their secretion, which is introduced into the system doubtless through the lymphatics, perhaps also by the veins.

The thyroid gland is commonly described in connection with the organs of respiration; but this association is not justified by likeness of structure or similarity of function, and rests merely upon the circumstance of contiguity.

The thyroid consists of two *lateral lobes*, usually connected at their lower parts by an *isthmus*. The gland extends vertically from the fifth or sixth tracheal ring to the side of the thyroid cartilage, and backward to the side of the pharynx and gullet. When present, the isthmus generally lies across the second, third, and fourth rings. The lobes are broadest below and taper to a point above. They are superficially convex, and adapted to the form of the structures against which they lie. Each is about two inches long, one and a fourth inch wide at its broadest part, and three-fourths of an inch thick; but these figures are subject to great variations in different cases. During menstruation the thyroid of the female is somewhat increased in size. In infancy it is relatively larger than in the adult. The lobes are attached by fibrous tissue to the larynx and trachea, wherever in contact with these organs; and distinct *lateral ligaments* bind them to the cricoid and uppermost part of the windpipe.

Frequently a slender, tapering process, called the *pyramid* (pyramidal process, middle lobe), runs upward to the hyoid between the lateral lobes, from one of which (usually the left) or from the isthmus it arises. This is a part of the remains of the thyro-glossal duct, mentioned above. The gland is commonly of a dark red *color*, and its *weight* is an ounce or more.

The thyroid body has a strong *tunic* of fibrous tissue, from the inner surface of which *trabeculæ* are given off, incompletely dividing the parenchyma into irregular *lobules*. These lobules are composed of closed *vesicles*, which are the original, tubular acini of the gland, matured and altered by reason of the closure of their excretory ducts. The vesicles are of many shapes and various sizes, the largest not exceeding one twenty-fifth inch in diameter. They are lined with a single layer of short, columnar epithelial cells, and filled with a colloid fluid. They are held together by areolar tissue, in which course the vessels and nerves (Fig. 912).

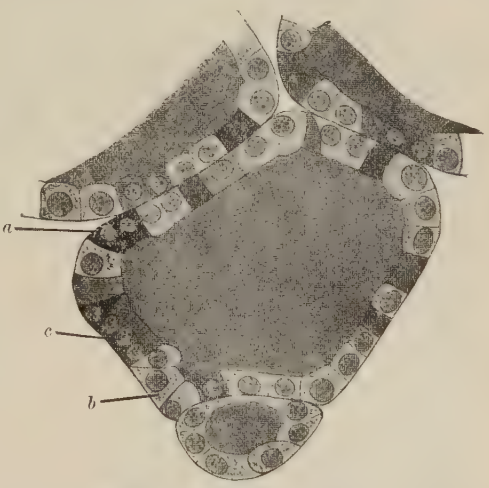

FIG. 912.—Section of a vesicle of the thyroid gland of a dog. *a*, secreting cell; *b*, reserve cell (these differ only in their states of activity); *c*, cell containing less colloid than *a*. The vesicle is full of colloid. (Schmid.)

The *arteries* of the gland are the superior thyroids, inferior thyroids, and occasionally the thyroidea ima. These vessels are of large size relatively to the volume of the gland, and make abundant anastomoses. The *capillaries* form a close plexus around the vesicles, and even penetrate between their epithelial cells. The *veins* are arranged in an intricate network on the surface of the gland, from which the blood is collected by the superior, middle, and inferior thyroid veins. The *lymphatics* begin in spaces about the vesicles, form a plexus in the capsule of the gland, and empty into the deep cervical nodes. Colloid matter, like that in the cavity of the vesicles, is found in the lymphatics. The *nerve-supply* is rather scanty, and is derived from the middle and inferior cervical ganglia of the sympathetic.

Accessory thyroid glands of small size are occasionally found in this region.

THE THYMUS.

The thymus (Fig. 913) is a temporary organ, growing somewhat rapidly until it attains a considerable size, and then gradually dwindling until it is merely vestigial.

It is *situated* in the anterior mediastinum and lower part of the neck, between

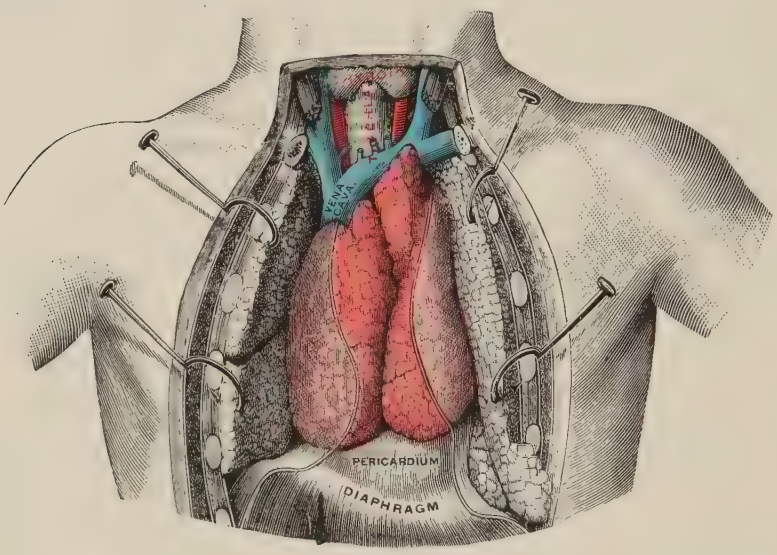

FIG. 913.—The thymus, the sternum and costal cartilages having been removed. (Testut.)

the lungs, in front of the heart, the great vessels, and trachea, and reaching upward nearly to the thyroid. It *appears* at the end of the second month of intrauterine life. At birth it measures two inches vertically, and half an inch ventro-dorsally and laterally; and it weighs a drachm and a quarter. It is largest when the child is two or three years old, and its *weight* at that time is six drachms. Thereafter it slowly and steadily *atrophies*, and has nearly disappeared by the fifteenth year, although traces of it may be discovered in old age.

It has a rosy hue in the fœtus, is grayish-pink in the infant, and later becomes yellowish. It is soft and compressible, and sags out of shape by its own weight. It is vertically elongated, and is largest below.

It has *two lobes*, approximately symmetrical—the *right lateral* and the *left lateral*—perfectly independent of one another. Each lobe has a delicate fibrous *envelop*, from whose visceral surface *partitions* extend inward, dividing the lobe into a large number of irregular, polyhedral *lobules*. If the envelop is cut between the lobules, the whole lobe can be unfolded, and the lobules are then found to be arranged around a *central cord*, close to which they are continuous with each other, but at the periphery of the lobe are free.

A lobule consists of clusters of little *nodules*, which are essentially lymphatic in character. Each nodule has a *cortical* and a *medullary* portion, the lymph-cells being more numerous in the former, and the latter containing peculiar cells (of Hassall) in nests, the large containing smaller. These medullary corpuscles are the representatives of the epithelium of which the thymus originally was largely composed, before the invasion of lymphatic tissue. A capillary network surrounds the nodule.

As the gland shrinks away the interstitial, connective tissue increases, and multitudes of fat-cells are formed, the last fact accounting for the yellow tinge of the organ during this stage.

The *arteries* of the thymus are derived from the internal mammary, the

thyroids, the subclavian, and the carotid. The *veins* run to the left brachio-cephalic. The *lymphatics* empty into the superior mediastinal nodes. The *nerves* come from the pneumogastric and the sympathetic.

THE SUPRARENAL CAPSULES.

Suprarenal bodies, adrenals, *glandulæ suprarenales*—these are the most common of the names given to the two organs, each of which surmounts a kidney, presenting an appearance suggestive of a liberty-cap, rakishly worn (Fig. 914). They are usually classed among the ductless glands, as is done here; but by some they are grouped with the organs of the central nervous system, on account of the prominence of their nerve-tissue, both fibrous and cellular. It is fairly well determined that they are essential to life, inasmuch as their complete removal is speedily followed by death, as also is their entire degeneration in disease. Their precise function is still unknown.

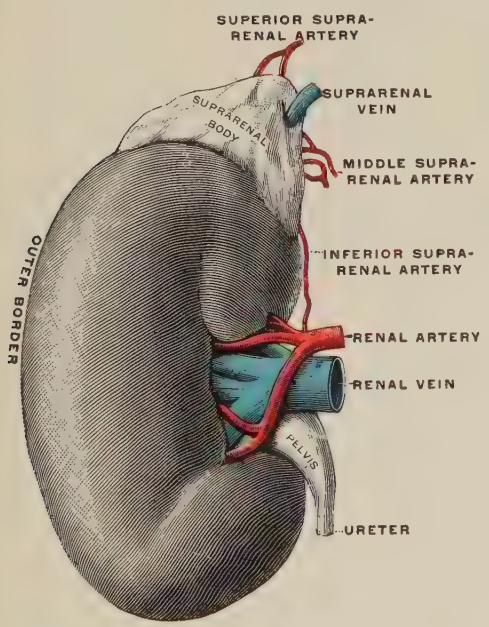

FIG. 914.—Right suprarenal capsule and kidney, viewed from in front. (Testut.)

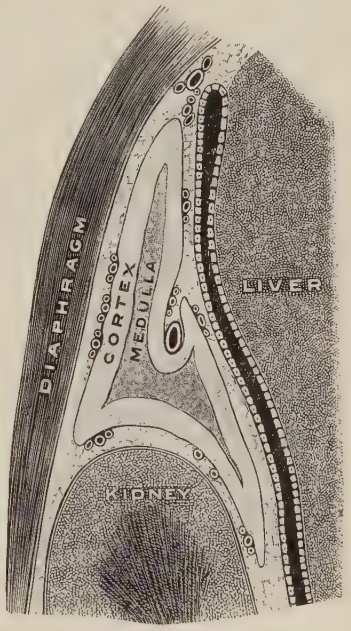

FIG. 915.—Sagittal section of the right suprarenal capsule. (Testut.)

The suprarenal capsules are *situated* in the epigastric region, resting upon the top, and the inner and front surfaces of the kidneys, to which organs they are attached by areolar tissue. They are separated by the vertebral column, the distance between them being about two and a half inches. Their *size* is variable; but the length rarely exceeds two inches, the width one inch and a fourth, and the thickness one-fourth inch. Each weighs about a drachm. The left is a little larger than the right. At birth they have nearly attained their adult size. On the anterior surface is a groove, running nearly crosswise, called the *hilum*.

The **right suprarenal body** is pyramidal. Its anterior surface is nearly covered by peritoneum. It is adherent to the liver in an impression on the under surface of that gland, at the right of the vena cava.

The **left suprarenal body** is not as tall as the right, but extends farther downward on the vertebral border of the kidney. It is in contact with the spleen, stomach, and pancreas. The upper part of its anterior surface is clothed with peritoneum of the small sac.

Structure.—Section of a suprarenal body (Fig. 915) shows it to be composed of a peripheral portion, the *cortex*, and a central portion, the *medulla*—the two being separated by loose, areolar tissue, and the whole mass enclosed in a thin, *fibrous capsule*, which sends inward numerous vertical *trabeculæ*, between which are many connecting bands. Mingled with the fibrous tissue is smooth muscular tissue. Thus are formed spaces in which are lodged the active cells of the organ.

In the *cortex*, which is of a deep yellow color, the *cells*, granular, nucleated, polyhedral, are for the most part arranged in columns, perpendicular to the surface.

The *medulla* is pulpy and dark brown, its color being principally caused by the great abundance of the blood-vessels of the part. The vessels are veins, arranged in a plexus in the fibro-muscular framework, and closely related to groups of large, irregular cells.

The *arteries*, derived from the renal, and the phrenic, as well as directly from the aorta, enter at various points of the surface, and run inward in the trabeculæ, giving off capillaries to the columns and other clusters of cells. The *veins* are nearly all gathered into the medulla, and their efferents are the radicles of a single vessel, which emerges at the hilum, and passes on the right side to the adjacent vena cava, on the left to the corresponding renal. The *lymphatics* begin in lymph-paths between the groups of cells and the framework, and run to the median lumbar nodes.

The *nerves* are derived from the solar and renal plexuses. They are very numerous, and present many ganglia before entering the organ, and ganglion-cells in the medulla.

The suprarenal capsules, like the kidneys upon which they rest, are surrounded by a quantity of adipose tissue. Quite often small accessory bodies of identical structure are found in the immediate neighborhood.

The Parathyroids.

Embedded in the surface of each lateral lobe of the thyroid body are two little masses, each about one-quarter of an inch in diameter, one on the inner and one on the outer aspect. They are called the parathyroids (*glandulæ parathyroideæ*). They are not like the thyroid in structure, being solid accumulations of epithelioid cells, among which run many blood-vessels. Each is invested with a delicate tunic of areolar tissue. Various theories concerning their function have been advanced, but we are still ignorant of their service.

The Carotid Glands.

The two *glandulæ caroticæ* are thus named because each is situated in the bifurcation of a common carotid artery. They are composed of nodules, each of which is a mass of epithelioid cells, among which are large capillaries (Fig. 916). A fibrous capsule covers the gland and sends trabeculæ between the nodules.

The Coccygeal Gland.

The *glandula coccygea* is situated in front of the tip of the coccyx. It is about one-tenth of an inch in diameter, and is composed of granular cells, probably epithelial, in intimate relation to minute blood-vessels, and embedded in fibrous tissue (Fig. 917).

The **hypophysis** has already been described.

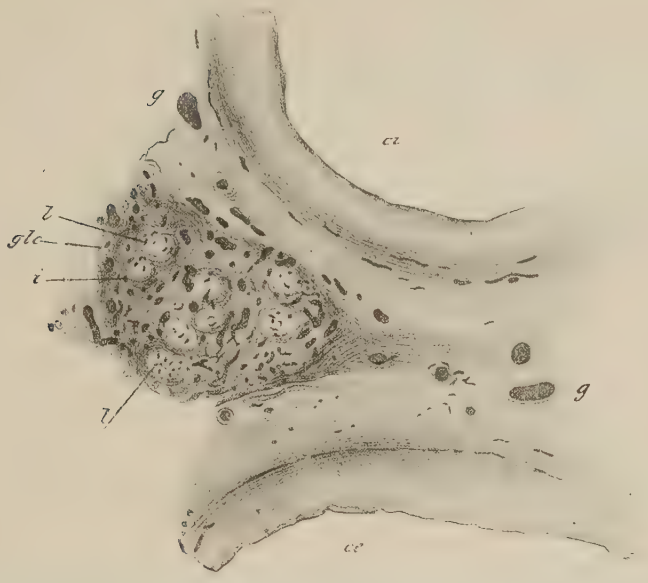

FIG. 916.—Section of the carotid gland and carotid arteries near their origin. *ci*, internal carotid; *ce*, external carotid; *glc*, carotid gland; *l*, *l*, groups of epithelial cells; *i*, fibrous tissue between the epithelial groups; *g*, blood-vessel. Numerous vessels are also seen within the gland. (Marchand.)

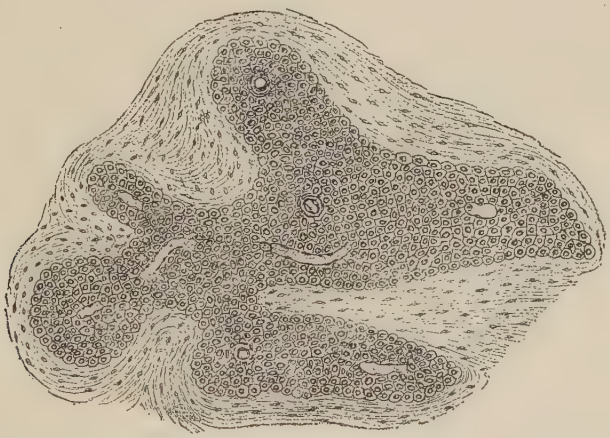

FIG. 917.—Section of the coccygeal gland. The group of cells, apparently of epithelial nature, is traversed by small blood-vessels and enclosed by fibrous tissue. (Sertoli.)

THE ORGANS OF GENERATION.

By G. D. STEWART.

THE MALE ORGANS OF GENERATION.

THE reproductive organs of the male may be divided into essential and accessory. The former are the *testicles*, two glandular organs, which produce the spermatozoa. The accessory organs are (1) a long canal from each testicle, by means of which the spermatozoa are conveyed into the vagina of the female. This canal is divided into the *vas deferens*, the *ejaculatory duct*, and the *urethra*—the last being single and also belonging to the urinary system. (2) The *seminal vesicles*, reservoirs of the semen; (3) the *prostate gland*, which adds an element to the semen as it passes outward; (4) the *bulbo-urethral glands* (Cowper's), which also contribute to the volume of the semen; (5) the *scrotum*, a pouch, consisting of a series of concentric layers, which envelop the testicles; and (6) the *penis*, the organ of copulation, which encloses the extrapelvic portion of the urethra, and which, when erect, effects the discharge of the semen into the vagina.

THE TESTICLES.

The testicles ("little witnesses" to masculinity), or *testes* (Figs. 918, 919), are two glandular organs which produce the spermatozoa, the principal element of the seminal fluid. They are suspended from the inguinal region by the spermatic cords, and are surrounded and further supported by the scrotum. The left, as a rule, is a little lower than the right, and its spermatic cord is thus a little the longer. Each gland is from one and a half to two inches in length, one and one-quarter inch in width from before backward, a little less than an inch in thickness (measured transversely), and weighs from five to eight drachms. The consistence of the testicle is peculiar, varying somewhat according to the condition of its seminiferous canals. When the latter are engorged it is firm; when they are empty, it is soft.

Each gland is divided into two parts—the testicle proper and the epididymis. The latter must be regarded as the first segment of a canal through which the spermatozoa, after leaving the testicle, must pass to reach the urethra; but it is so intimately connected with the testicle that it may be described with that structure.

The **testicle proper** is ovoid, flattened transversely, and presents two surfaces, two borders, and two extremities. The external surface is convex and turned outward and a little backward; the internal, almost flat, looks in the opposite direction. The anterior border is convex and turned slightly downward; the posterior, almost straight, is directed upward and backward and has attached along its whole length the epididymis. The superior extremity is rounded, and occupies a plane a little external and anterior to the more pointed inferior extremity. The latter gives origin to a fibro-muscular band, the *scrotal ligament*, which is attached by its distal end to the bottom of the scrotum, thus fixing the testicle to its envelops.

The **Epididymis** ("upon the testicle") is a long narrow body, which lies along the posterior border of the testicle, encroaching somewhat on its outer surface. It is composed chiefly of the convolutions of a long canal (to be described later), and is divided into an upper extremity or head, a lower extremity or tail, and an intervening portion called the body. The *head* or *globus major* ("greater globe"), the largest part of the epididymis, is round and smooth. It reposes like a hood on the upper extremity of the testicle, to which it is united by the tunica vaginalis, by an intervening layer of connective tissue, and by the vasa efferentia, which, on emerging from the testicle, immediately enter the globus major and make up the greater part of its bulk. The *body* in horizontal section resembles a comma, and presents in consequence two surfaces and two borders. The anterior surface is concave, the posterior convex. Between the former and the testicle there is a short *cul-de-sac*, the *digital fossa*, which opens outward, and is lined by the tunica vaginalis. The internal border, corresponding to the tail of the comma, is thin, and floats in the cavity of the tunica vaginalis; the external is thick, and lies immediately to the outer side of the vessels and nerves, as they enter the testicle. The tail or *globus minor* ("smaller globe"), intermediate in size between the body and head, is connected to the lower extremity of the testicle by a reflexion of the tunica vaginalis and by loose connective tissue.

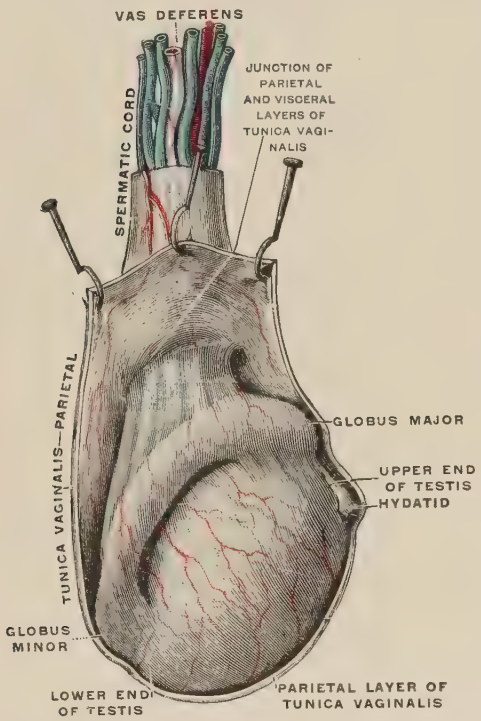

FIG. 918.—Right testicle, its external surface. (Testut.)

Migration of the Testicle.—In early fœtal life the testicle is an abdominal organ lying below the kidney and behind the peritoneum. To its lower extremity there is attached a muscular band, called the *gubernaculum testis* ("rudder of the testis"), consisting of a central bundle of unstriped muscular fibers, which passes through the inguinal canal and is attached to the dartos at the bottom of the scrotum, and of lateral bundles of voluntary muscular tissue, which are derived from the oblique muscles of the abdomen and are, therefore, attached below to the internal ring and the sides of the inguinal canal. Later the peritoneum surrounds the testicle and gubernaculum, forming a mesentery, the testicular portion of which is called the *mesorchium* ("mesentery of the testicle").

Soon there appears on the gubernaculum, at the internal ring, a pouch of peritoneum, the *processus vaginalis* ("sheathlike process"), which elongates gradually and pushes through the inguinal canal into the scrotum, carrying in front of it the subperitoneal tissue, an infundibuliform process of the fascia transversalis, a few fibres of the internal oblique (which form the cremaster muscle), and the intercolumnar fascia. This pouch is then occupied by the testicle, which leaves its abdominal position about the third month of fœtal life, reaches the internal ring about the sixth month, the external by the eighth, and shortly before birth descends into the scrotum.

The cause of this descent is uncertain. That it may be due in small part to the progressive shortening of the gubernaculum is undeniable; that it is in greater measure owing to the fact that the lumbar region grows away from the

testicle, which is fixed by the gubernaculum, is probable. It must be noted too that the peritoneal pouch precedes the testicle, and, since the former is attached to a lower point in the gubernaculum, this fact may be explained in the same way. After descent has been completed, the remains of the central gubernacular

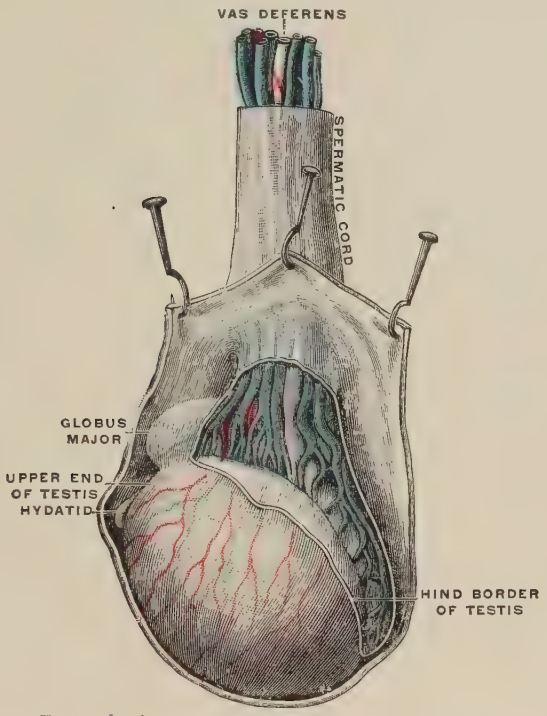

FIG. 919.—Right testicle, its internal surface. (Testut.)

band may be found in the scrotal ligament already described; the lateral bands, having ceased to act after the testicle has reached the external ring, are drawn down, and may be found in the form of scattered bundles (the internal cremaster of Henle), lying amidst the other elements of the spermatic cord.

The peritoneal sac which preceded the testicle is at first continuous with the general peritoneal cavity. Shortly before birth, however, the upper part of the tube of communication becomes closed, and this obliteration extends gradually downward to within a short distance of the testicle. That portion of the sac which surrounds the testicle is thereby completely cut off from the peritoneal cavity, and forms the tunica vaginalis. The obliterated portion of the pouch usually remains as a fibro-cellular thread, lying among the other elements of the cord. Sometimes this may be traced as a distinct band from the peritoneum at the internal ring above to the tunica vaginalis below; sometimes it is lost on the cord.

Occasionally the tube of communication remains open, and then the abdominal viscera may pass into the tunica vaginalis, forming the congenital variety of hernia. In other cases the tube contracts, and forms a very minute canal, which may be traced downward a greater or less distance on the cord. A similar minute tube of peritoneum, observed in connection with the round ligament in the female, is called the *canal of Nuck*.

One or both testicles may fail to reach the scrotum until shortly after birth, or their descent may be delayed until puberty; they may even remain permanently within the abdomen, or be arrested at any part of their course.

The **Tunica Vaginalis** ("sheathlike coat") is a closed serous sac, of peritoneal origin, which invests the testicles and lines the scrotum, and may, therefore, be divided into visceral and parietal portions.

The *visceral layer* is intimately adherent to the tunica albuginea of the testicle proper, except along the posterior border of the gland, where the epididymis is attached, and where the vessels and nerves enter or emerge. It also invests the globus major, lines the digital fossa, and covers the external border and posterior surface of the body of the epididymis, but leaves uncovered almost the whole of the globus minor.

The *parietal layer*, of greater extent than the visceral, lines the infundibuliform fascia, to which it is loosely attached by a prolongation of the subperitoneal tissue. It also covers the spermatic cord for a short distance above the testicle, extending somewhat higher on the inner than on the outer side. At the posterior border of the gland the two layers are, of course, continuous.

The inner surface of the tunica vaginalis is lined by a layer of epithelial cells, and the membrane secretes enough fluid to moisten the apposed surfaces.

Minute Structure of the Testicle.—Structurally the testicle consists of the following parts: (1) a fibrous covering, the tunica albuginea, from which is derived a framework; (2) the tubuli seminiferi; (3) certain excretory canals; (4) interstitial tissue.

The **Tunica Albuginea** ("whitish coat") is a dense, white, fibrous, inelastic capsule, about one-sixteenth of an inch in thickness. Its inner surface reposes on the parenchyma of the testicle; its outer is covered by the visceral layer of the tunica vaginalis. Behind, where the tunica albuginea covers the posterior border of the testicle, it becomes immensely thickened forming a cone-shaped body, the *corpus Highmorianum* or *mediastinum testis* ("standing in the middle of the testis"), which projects forward a varying distance into the mass of the gland. This body approaches a little nearer to the upper than to the lower extremity of the testicle, lies closer to the internal than to the external surface of that organ, and is tunnelled by the larger blood-vessels and a network of ducts, the *rete* ("net") *testis*. By its summit and lateral faces the mediastinum gives origin to a system of thin laminæ and slender trabeculæ, which radiate to become attached to the inner surface of the tunica albuginea, thus dividing the testicle into a varying number (150 to 300) of small pyramidal spaces, called *loculi* ("little places"). In these cavities are lodged the seminiferous canals and the interstitial tissue. The visceral surface of the tunica albuginea and its trabeculæ is covered by a network of minute blood-vessels, connected with the spermatic blood-vessels, and called the *tunica vasculosa*.

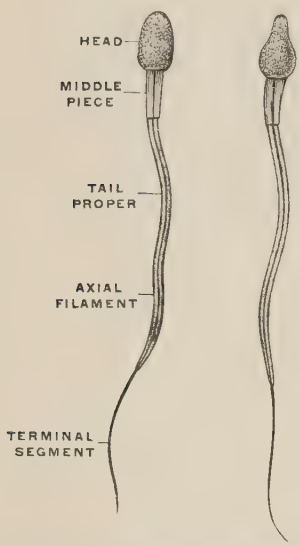

FIG. 920.—Human spermatozoa. The right one is seen in profile. (Testut.)

Histologically the tunica albuginea is composed of bundles of white fibrous tissue, which interlace in every direction, mingled with a small number of fine elastic fibres.

The **Tubuli Seminiferi** ("seed-bearing tubules"), or seminiferous canals, produce the spermatozoa (Fig. 920), and hence form the essential structure of the testicle. They occupy the loculi, and are by the latter divided into a corresponding number (150 to 300) of more or less distinct masses, called *lobules*. These, like their containing loculi, are pyramidal, their bases corresponding to the inner surface of the albuginea, their apices resting on the mediastinum. They each contain two or more seminiferous tubes, making of the latter from five to nine hundred for each testicle.

The tubes vary in diameter from $\frac{1}{100}$ to $\frac{1}{120}$ of an inch, and are so flexuous that, when uncoiled, their length is increased twenty to thirty times (over two feet). They begin near the bases of the lobules by blind extremities. In their course toward the mediastinum they give off two or three cæcal diverticula, and

exhibit frequent anastomoses, particularly near their origin, not only with the tubes of the lobule to which they belong, but with those of adjoining lobules. Near the mediastinum the canals of each lobule unite to form a single straight excretory tube, one of the *tubuli recti*.

The wall of a seminiferous tubule, on cross section, is seen to consist of several concentric layers of epithelial cells. The cells of the innermost layer are united edge to edge to form a basement membrane; the outer layers are incomplete. Within the tubule are several layers of small epithelial nucleated cells, the progenitors of the spermatozoa. (See page 77.)

The **excretory canals** (Fig. 921) of the testicle do not produce spermatozoa, but simply serve to convey the latter from the tubuli seminiferi to the canal of the epididymis. They are the tubuli recti, the rete testis, and the vasa efferentia. The *tubuli recti*, formed in the manner already indicated at the apices of the lobules, are short, straight, and of smaller calibre than the seminiferous canals from which they spring. They penetrate the mediastinum, and in its anterior

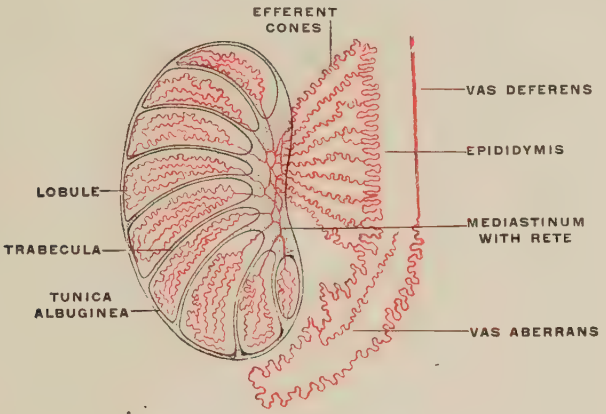

FIG. 921.—Diagram of testicle proper and epididymis. (Testut.)

portion break up into the rete testis. The walls of the straight tubules are made up of the fibrous tissue of the mediastinum, lined by a single layer of prismatic cells. The *rete testis* occupies the whole length of the mediastinum, and is composed of anastomosing vessels of irregular calibre, which vary in diameter, but are always larger than the seminiferous canals or the straight tubules. Like the latter they have no proper wall but are simply channels dug out of the fibrous tissue of the mediastinum, and lined by an epithelium which is here cylindrical, there cubical, or even of the flattened variety. At the upper and back part of the testicle these channels finally unite to form a smaller number of canals, the *vasa efferentia* ("vessels carrying from"). The latter almost immediately escape from the albuginea, and enter the globus major, with which structure they will be described.

The **interstitial tissue** is a very delicate connective tissue, which supports the seminal tubules and the smaller ramifications of the blood-vessels. It is derived from the trabeculæ, and is peculiar in that it contains, besides the ordinary cells of connective tissue, the so-called *interstitial cells*. These are large, rounded or oval corpuscles, some of which exhibit branching processes. Their protoplasm is granular, often filled with fat, and may contain a brown or yellowish pigment. They occupy divers situations, surrounding the smaller vessels and lying between the tubules, and are either a special variety of connective-tissue cells, or are derived from cells of the germinal epithelium, which have not been utilized in forming the tubes. In the spaces of this tissue the lymphatics of the testicles take birth.

Minute Structure of the Epididymis.—The *vasa efferentia*, ten to fifteen in number, carry the spermatozoa from the rete testis to the canal of the epididymis. Emerging from the testicle at its upper and back part, they are at first straight,

but soon become coiled and convoluted, forming a series of cone-shaped masses, the *coni vasculosi*. These cones, their apices turned toward the tunica albuginea, are each about one-third of an inch in length; together they constitute the *globus major*. The tube of which each is composed is about one-thirtieth of an inch in diameter near its origin, about half as large at its termination, and measures when uncoiled from six to eight inches in length. The uppermost vessel merges without line of demarcation into the canal of the epididymis, the remainder open at regular intervals into that canal. The walls of the efferent vessels are made of smooth muscular fibres, circularly arranged, and lined by a ciliated, cylindrical epithelium.

The *canal of the epididymis* takes origin in the globus major in the manner already described. Extending downward, it forms the body and globus minor, and then merges into the vas deferens. It is disposed in numerous coils, held together by areolar tissue. The length of the canal when uncoiled varies from twelve to twenty feet, and its diameter, about one-sixtieth of an inch above, gradually decreases as it approaches the globus minor, to enlarge again beyond that point. The walls are thin, and are composed of smooth muscular tissue, which near the vas may be separated into a superficial longitudinal layer and a circular one. This muscular coat is lined by a layer of ciliated, columnar epithelium. The cilia of the canal are longer than those found in the efferent vessels, but like the latter their motion is toward the vas. Beneath the fixed ends of the columnar cells is found a layer of young cells, destined later to replace the former.

Vessels and Nerves.—The *arterial supply* of the testicle is derived chiefly from the spermatic artery, which joins the other structures of the spermatic cord at the internal ring. Approaching the gland it divides into two sets of branches —testicular and epididymal. The former, at the posterior superior portion of the testicle, subdivides into two sets of branches, as follows: (1) a peripheral group which travels forward in the thickness of the albuginea; (2) a central group, which pierces the mediastinum, and breaks up into a plexus on the walls of the loculi. From this a multitude of fine branches are sent to form plexuses around the walls of the seminiferous canals. The epididymal branches, joining with the terminal twigs of the deferential artery, form a plexus around the canal of the epididymis.

The *veins* pierce the mediastinum, and unite into six or seven trunks, which form a plexus, the *pampiniform* ("tendril-shaped"), surrounding the spermatic artery, and lying in front of the vas. Farther up in the cord the veins become reduced to two or three, and these, following the artery into the abdominal cavity, finally unite to form a single trunk, the *spermatic vein*, which empties on the right into the inferior vena cava, on the left into the corresponding renal vein. The veins from the epididymis form a second group of two or three trunks only, which pass upward in the cord behind the vas, and empty into the deep epigastric veins. The *lymphatics* form a plexus around the seminiferous canals, where they begin as minute spaces lined by epithelial cells. Together with the lymphatics of the epididymis, they accompany the spermatic vessels to end in the lumbar nodes. The *nerves* are derived from the aortic, renal, and hypogastric plexuses of the sympathetic. Branches from these form a secondary plexus around the spermatic artery and the artery of the vas. Their mode of termination is not well understood.

Fœtal Remains.—The *hydatids* ("vesicles") *of Morgagni* are two small bodies —one pediculated, the other sessile—which are found in connection with the globus major and the upper extremity of the testicle. The *pediculated hydatid*, rounded or pyriform in outline, and from one-eighth to one-third of an inch in length, is attached to the head of the epididymis, and covered by the tunica vaginalis. Its cavity, lined by a cylindrical, ciliated epithelium, contains a transparent fluid. This body is not always present, and its morphological significance has not been satisfactorily explained. The *sessile hydatid*, a rounded or flattened

projection of about the same size, is seated either on the front of the globus major, the upper extremity of the testicle, or between the two. It is nearly always present, is sometimes divided into several lobes, and contains in its centre a tubular cavity or canal, which either ends in blind extremities or becomes continuous with a seminiferous canal. Morphologically, this body represents the peritoneal end of the duct of Müller, and is, therefore, homologous with the fimbriated extremity of the Fallopian tube in the female. Sometimes, indeed, it may be found as an empty orifice with fringed borders.

The *organ of Giraldès* or *paradidymis* ("beside the testicle"), a small, irregular, yellowish-white patch, which lies in front of the cord, immediately above the head of the epididymis and beneath the funicular portion of the tunica vaginalis, is made up of several small nodules, each containing a blind convoluted tube, lined with cylindrical, ciliated epithelium. It is a relic of the inferior portion of the Wolffian body.

THE VAS DEFERENS.

The vas deferens ("vessel carrying away") (Figs. 922, 923) is the prolongation of the canal of the epididymis, and extends from the tail of the latter to the base of the prostate gland. It varies in length from sixteen to twenty inches, is cylindrical in outline throughout the greater part of its course, and has an average diameter of about one-tenth of an inch. The vas travels upward in the spermatic cord, and may be divided into four portions as follows: (1) testicular; (2) funicular; (3) inguinal; (4) abdomino-pelvic.

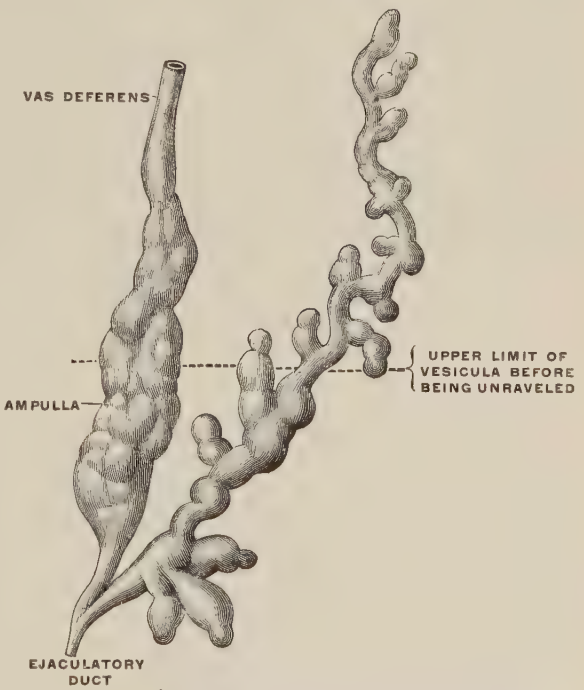

FIG. 922.—Right seminal vesicle, unraveled and viewed from behind. (Testut.)

Direction and Relations.—The *testicular portion*, markedly tortuous, runs from its origin upward and a little forward, to about the middle of the testicle. It lies to the inner side of the epididymis and behind the testicle, and is separated from both by the spermatic vessels and nerves. The *funicular portion* is straight, and is continued vertically upward to the external abdominal ring, lying behind the spermatic artery, nerves, and anterior group of veins, but in front of the posterior veins. The *inguinal portion* occupies the inguinal canal. The *abdomino-pelvic division* is, in the greater part of its course, retro-peritoneal. At the internal abdominal ring it leaves the spermatic vessels and turns inward, curving around the outer side of the deep epigastric artery. Crossing the external iliac vessels on their inner side, it then enters the pelvis close to the ilio-pubic suture, and curves downward and backward on the lateral wall of the bladder, crossing in this part of its course obliquely and to the vesical side of the obliterated hypogastric artery and the ureter. The terminal segment of this division, about two inches in length, runs forward between the bladder and the rectum. It is dilated, flattened from

before backward, sacculated, resembles the seminal vesicle, and is called the *ampulla of Henle*. The anterior surface of the latter is directly applied to the bladder wall; the posterior is separated from the rectum for a short distance above by the recto-vesical pouch of the peritoneum, below this, by the recto-vesical fascia. The external border of the ampulla lies in contact with the inner border of the corresponding seminal vesicle. The ampullæ of opposite sides are separated by a triangular space, the *interdeferential triangle*, the apex of which corresponds to the base of the prostate, and in the opening of which the bladder and rectum are in almost immediate contact, separated only by the recto-vesical fascia. Close to the base of the prostate the ampulla again becomes narrow and straight, and is joined on its outer side by the corresponding seminal vesicle, to form one of the common or ejaculatory ducts.

Minute Anatomy.—The walls of the vas consist of three coats—areolar, muscular, and mucous. The outer or *areolar coat* is composed of fibrous tissue, mixed with blood-vessels, nerves, and smooth muscular fibres, arranged parallel to the long axis of the canal. The *muscular coat* constitutes about four-fifths of the entire thickness of the wall, and gives to the vas a firm, resistant feel, by means of which it may easily be distinguished from the other elements of the cord. It is composed of smooth muscular fibres, arranged in three planes. In the superficial and deep planes the fibres are longitudinal, in the median, which is much the thickest, they are circular. The *mucous coat* is whitish, presents three or four longitudinal folds, which are effaced by distention, and is lined by cylindrical, non-ciliated epithelium. In the ampulla the walls are thinner, and the mucous membrane presents many folds, which, uniting at divers angles, give to this portion an areolar appearance, resembling the seminal vesicles. These areolæ are lined by cubical epithelium.

Vessels and Nerves.—The *artery*, a branch of the superior vesical, joins the vas near its origin, and accompanies it to the testicle, anastomosing in the latter with the spermatic artery. The *veins* empty into the vesico-prostatic plexus and the veins of the cord. The *nerves* come from the inferior hypogastric plexus.

The *vas aberrans* ("vessel wandering from") is a narrow tube which comes from the lower end of the canal of the epididymis, or from the beginning of the vas. Becoming convoluted into an irregular mass, it extends upward between the structures mentioned for an inch or more, and ends in a cæcal extremity. The tube when uncoiled measures from one and a half to fifteen inches in length. It agrees in structure with the vas, and is a relic of the upper part of the Wolffian body.

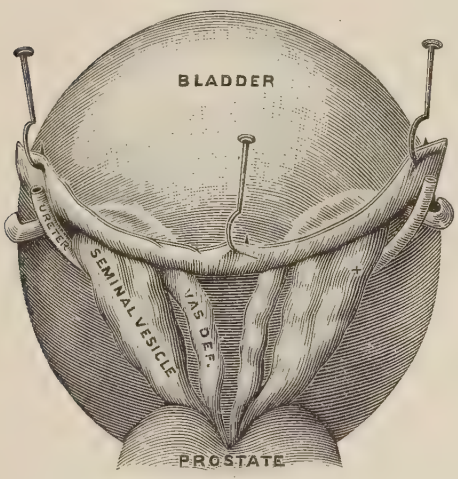

FIG. 923.—Base of the bladder, showing the seminal vesicles and the vasa deferentia. (Testut.)

THE SEMINAL VESICLES.

The seminal vesicles (Figs. 922, 923) are two lobulated pouches, serving as reservoirs for the semen, to which they add a secretion of their own. They are placed one on either side, external to the ampullæ of the vasa deferentia, and between the bladder and the rectum. Each vesicle is pyramidal in form, with the broad end directed backward, measures two inches in length, and about a half inch in breadth at its posterior and widest part, and presents two surfaces, two borders, and two extremities.

The anterior surface is attached to the base of the bladder, overlapping, for a short distance above, the ureter. The posterior surface is convex and covered

above by the recto-vesical pouch of peritoneum, below this, by the recto-vesical fascia, which alone separates it from direct contact with the rectum. The posterior extremities or bases are widely separated; the anterior converge, become narrowed, and near the base of the prostate unite on their inner sides with the corresponding vasa deferentia to form the ejaculatory ducts. Along the inner margin of each vesicle there runs the ampulla of the corresponding vas.

Each vesicle consists of a central tube, four to six inches in length, from which are given off many blind diverticula, the whole being coiled into the form just described, and held thus by dense, fibrous tissue. In minute structure it closely resembles the vas. Like the latter it has an external fibrous coat derived from the recto-vesical fascia, and containing blood-vessels, lymphatics, and nerves. Its middle or muscular coat is thin, but it is arranged in superficial and deep longitudinal layers and a middle plane of circular fibres. The mucous membrane, areolar in structure, like that of the ampulla, is lined with non-ciliated, cylindrical epithelium, beneath which is a deeper layer of polyhedral cells.

Over the posterior surfaces and extending between the two vesicles is found a certain amount of smooth muscular tissue, also some longitudinal fibres, continuous with those of the bladder wall.

THE EJACULATORY DUCTS.

The ejaculatory ducts (Fig. 924) are two in number, one right, the other left. Each is formed close to the base of the prostate by the union, at a very acute angle, of the seminal vesicle and the ampulla of the vas of one side. They convey the seminal fluid from the vesicles and vasa deferentia into the urethra. From their origins the two ducts run downward and forward, converging as they descend. After a very short course they enter the prostate, and pass forward side by side between its middle and lateral lobes, opening finally into the prostatic urethra by two small elliptical orifices, placed one on either side of the sinus pocularis. Each duct is about three-quarters of an inch in length, and its lumen, diminishing from behind forward, is so small at the urethral end as barely to admit a very fine bristle. The *walls* of this tube are very thin; the outer, areolar coat, found in the vas deferens and vesicula seminalis, has entirely disappeared; and the outer plane of longitudinal muscle-fibres becomes blended with the prostate. The muscular coat proper is therefore reduced to two layers, an outer of circular, and inner of longitudinal fibres. The mucous membrane resembles closely that found in the vas deferens.

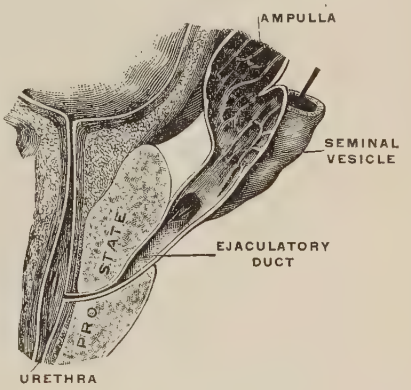

Fig. 924.—Ejaculatory duct in sagittal section. (Testut.)

Arterial branches from the inferior vesical and middle hemorrhoidal supply the seminal vesicles and the extra-prostatic portion of the ejaculatory duct. The *veins* correspond, emptying into the vesico-prostatic plexus; the *nerves* are derived from the hypogastric plexus. The intra-prostatic portion of the ejaculatory duct receives its nutrient and nervous supply from the prostate.

THE SCROTUM.

The scrotum (Fig. 925) is a pouch, which contains the testicles and a part of each spermatic cord. It consists of several layers which are from without inward as follows: (1) the integument; (2) the dartos; (3) the intercolumnar fascia; (4) the cremasteric fascia; (5) the infundibuliform fascia; (6) the sub-

peritoneal tissue; (7) the parietal tunica vaginalis. The integument forms a common covering for both testicles; the remaining layers, meeting in the median line, form the *septum scroti*, which passes inward between the two glands, giving to each a separate compartment.

The **Integument** is thin, very distensible, deeply pigmented, covered with

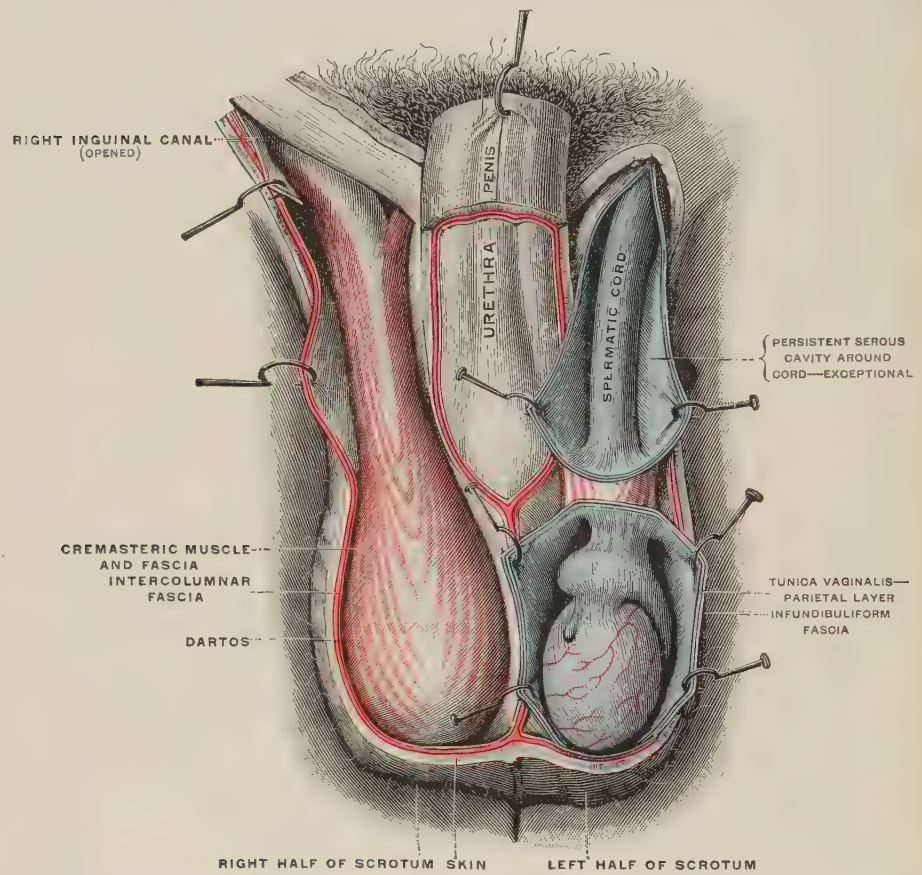

FIG. 925.—The scrotum. On the left side the cavity of the tunica vaginalis has been opened; on the right side only the layers superficial to the cremaster have been removed. (Testut.)

short hairs, and studded with numerous sudoriparous and sebaceous glands. Along its median line there runs a longitudinal ridge or *raphe*, from which numerous folds are directed transversely outward.

The **Dartos** ("flayed") is a thin, reddish, fibrillated layer, which lines and is intimately attached to the deep surface of the integument. It corresponds to the two layers of the superficial fascia, with which it is continuous over the abdomen and groin; but it differs from these in that it consists of elastic tissue, with abundant, smooth, muscular fibres, and contains no fat. The muscular fibres, mostly longitudinal in direction, are attached to the deep surface of the skin. Under the influence of cold, mental emotion, and in the healthy, they are contracted, causing the scrotum thereby to become short and corrugated; in the feeble, and under the influence of warmth, they relax, and the scrotum becomes pendulous, and its ridges almost effaced. The dartos, as such, is continued over the penis and perineum.

The **Intercolumnar Fascia** (*external spermatic*) is a thin, fatless, transparent membrane, which lines the dartos. It is continuous above with the pillars of the external abdominal ring, and with the transverse (intercolumnar) fibres connecting them.

The **Cremasteric Fascia** (*middle spermatic*) consists of two layers of thin areolar tissue, between which are placed the voluntary muscular bundles—cremaster ("supporting") muscle—derived from the internal oblique. At the bottom of the scrotum this layer blends with the dartos.

The **Infundibuliform Fascia** (*internal spermatic*) is a delicate membrane derived from the fascia transversalis. It lines the cremasteric fascia.

The **Subperitoneal Tissue** does not, properly speaking, form one of the layers of the scrotum. As a loose areolar structure continuous with the subperitoneal tissue of the abdominal wall, it lines the infundibuliform fascia, investing and forming laminæ between the different elements of the spermatic cord. Below, it connects loosely the inner surface of the infundibuliform fascia to the parietal layer of the tunica vaginalis. This with the preceding layer forms the so-called *fascia propria*.

The tunica vaginalis has already been described.

Vessels and Nerves.—The *arterial* supply of the scrotum comes from the superficial and deep external pudic, and from the superficial perineal, a branch of the internal pudic. The cremasteric artery, a branch of the deep

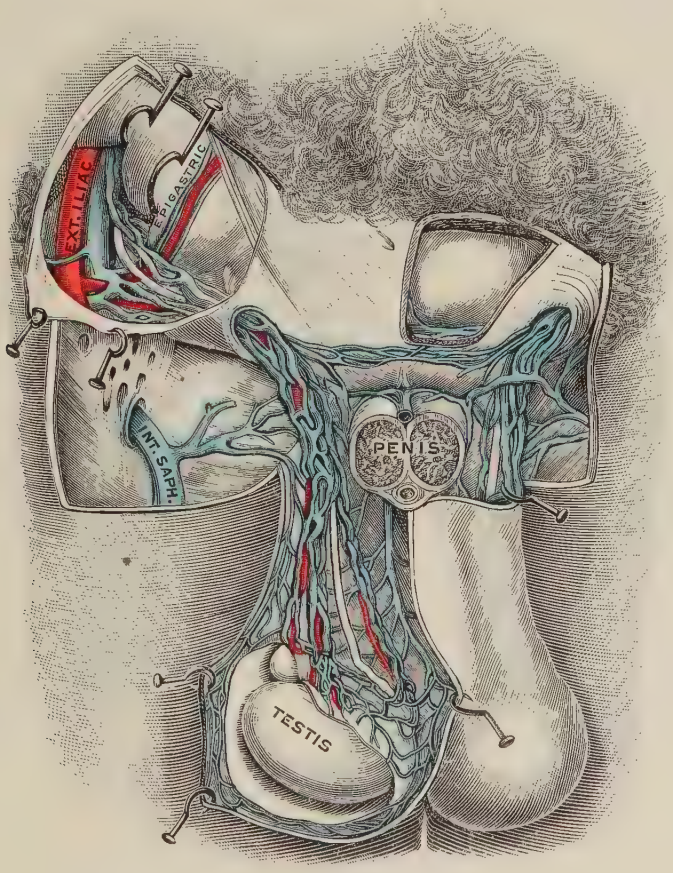

FIG. 926.—Spermatic veins. (Testut.)

epigastric, is distributed chiefly to the cremaster muscle; but it also sends branches to the deeper layers of the scrotum and anastomoses with the arteries of the testicle. The *veins* follow the corresponding arteries, and empty into the internal saphenous and internal pudic. The *lymphatics* terminate in the superficial inguinal nodes. The *nerves* are from the ilio-inguinal, the two superficial perineal, the inferior pudendal, and the genital branch of the genito-crural. The latter is distributed chiefly to the cremaster muscle.

THE SPERMATIC CORD.

The spermatic cord forms the pedicle of the testicle, and consists of the following parts: (1) the vas deferens; (2) arteries; (3) veins; (4) lymphatics; (5) nerves; (6) the processus vaginalis; (7) the internal cremaster of Henle. These are cemented together by a loose areolar tissue, continuous with the subperitoneal fascia, and are surrounded by certain layers, continuous with those found in the scrotum.

The *vas deferens* forms the nucleus of the cord. The *spermatic artery* lies in front of, the *deferential artery* is placed behind, the vas. The *veins from the testicle*, six or seven in number, form the *pampiniform plexus*, which runs upward in front of and surrounding the spermatic artery. The *veins from the epididymis* form a group of two or three trunks only, which run upward behind the vas. The *lymphatics* accompany the veins. The *nerves* run with the arteries. The *processus vaginalis* may run to the testicle or be lost at any level of the cord. The *internal cremaster of Henle*, in the form of scattered bundles, is supposed to represent the lateral bands of the gubernaculum.

The *coverings* are, from without inward, the skin, dartos or superficial fascia, intercolumnar fascia, cremasteric fascia, and infundibuliform fascia. At the level of the external ring the four outer coverings are lost. From this point the cord traverses the inguinal canal, and at the internal ring its elements diverge, the cord as such ceasing to exist.

THE PENIS.

The penis (Figs. 927–934) is the male organ of copulation. It takes origin in the perineal region between the superficial perineal fascia and the inferior

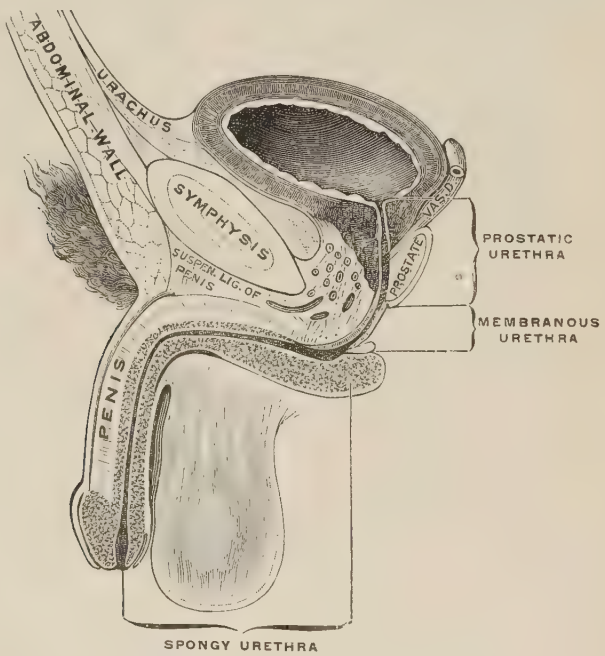

FIG. 927.—The male urethra, in sagittal section. (Testut.)

layer of the triangular ligament. Running upward and forward parallel with the ischio-pubic rami, it reaches a point above the scrotum and in front of the symphysis, where it becomes free and surrounded by a cutaneous covering. It may be divided into an anterior expanded extremity or *glans*, a posterior perineal extremity or *root*, and an intervening portion, called the *body*. The first will be

described with the corpus spongiosum from which it is derived; the other divisions will be taken up separately after the minute anatomy of the organ has been considered.

Structure.—The penis consists of three cylindrical masses of erectile tissue (two corpora cavernosa and a corpus spongiosum), and a system of envelops, which surround and hold these together.

The **Corpora Cavernosa**, each about six inches long and half an inch in diameter, make up the greater part of the body of the penis. They are placed side by side and united along the anterior three-fourths of their extent, their contiguous surfaces being somewhat flattened. Behind they diverge, and, becoming gradually narrower, terminate in pointed extremities, which are inserted, one on either side, into the middle of the ischio-pubic rami. The divergent portions, called the *crura penis* (Fig. 928), are fixed to the descending rami of the pubes by connective tissue, and invested by the ischio-cavernosi (erectores penis) muscles, which surround them more or less completely. In its course each crus presents a slight enlargement called the *bulb*. The distal extremities of the cavernous bodies, conical in outline, are received into corresponding depressions in the base of the glans, where they are firmly secured by fibrous tissue. Two longitudinal grooves, one dorsal, the other ventral, are formed by the union of these bodies. The former lodges the deep dorsal vein, the latter, much the deeper, is occupied by the corpus spongiosum.

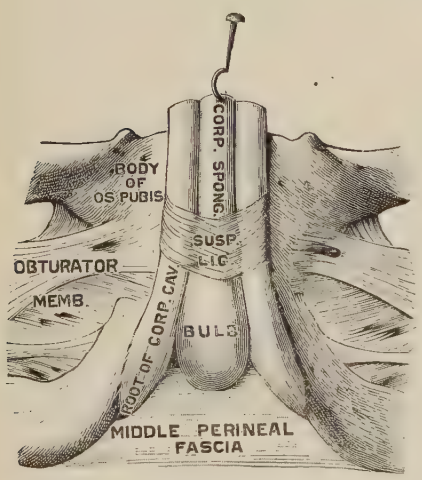

FIG. 928.—The penis, proximal portion, seen from below. (Testut.)

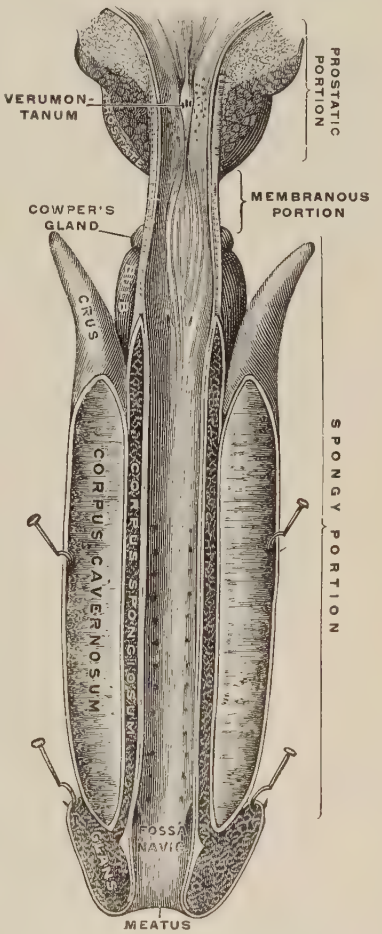

FIG. 929.—The male urethra, laid open on its anterior (upper) surface. (Testut.)

Structurally each corpus cavernosum consists of erectile tissue, invested by a sheath, the *tunica albuginea*. The latter is composed of white and yellow fibrous tissue, and is both tough and distensible. It is arranged in two layers, superficial and deep. The former, of longitudinal fibres, is common to both bodies; the latter, of circular fibres, is proper to each. In the median line, where the two bodies touch, these circular fibres blend, making a septum, dense and complete behind, but in its anterior portion interrupted by numerous vertical slits, and hence called the *septum pectiniforme* ("comb-shaped partition"). From the inner surface of

the albuginea, numerous fibro-muscular lamellated or filamentous *trabeculæ* are derived. These become smaller near the central axis of the body, and are stronger behind, in the vicinity of the crura, than in front. Crossing each other in divers directions, the trabeculæ divide the cylindrical cavity of the albuginea into an immense number of spaces, called *areolæ*. The latter communicate freely with each other, and with those of the opposite body through the fissures in the septum. They are lined by epithelial cells, resembling those found in the smallest arterial branches, and, therefore, represent widely dilated capillaries. At several points in their walls these spaces communicate with the arteries; they also give origin to the veins.

The **Corpus Spongiosum** (Fig. 929) is traversed throughout its whole extent by the urethra. Its posterior extremity, somewhat dilated, is called the *bulb*, its anterior extremity, much dilated, makes up the *glans*, while the intervening portion is known as the *body*.

The **bulb** (Fig. 928) is pear-shaped, about one and a half inches in length, and three-quarters of an inch in diameter at its widest part. It is larger than the body, and contains the bulbous portion of the urethra, which is here surrounded by a greater amount of erectile tissue than elsewhere. Its posterior extremity lies about half an inch in front of the anus. Tapering anteriorly, it soon gains the inferior groove, formed by the junction of the corpora cavernosa, and merges into the body. The superior surface of the bulb rests against the inferior layer of the triangular ligament from which it receives an investment; its inferior surface is covered by the bulbo-cavernosi (acceleratores urinæ) muscles. The urethra does not occupy the central axis of the bulb, but lies nearer to its superior surface.

The **body** is cylindrical or slightly tapering. It occupies the inferior groove formed by the junction of the cavernous bodies, and is tunnelled along its centre by the urethra.

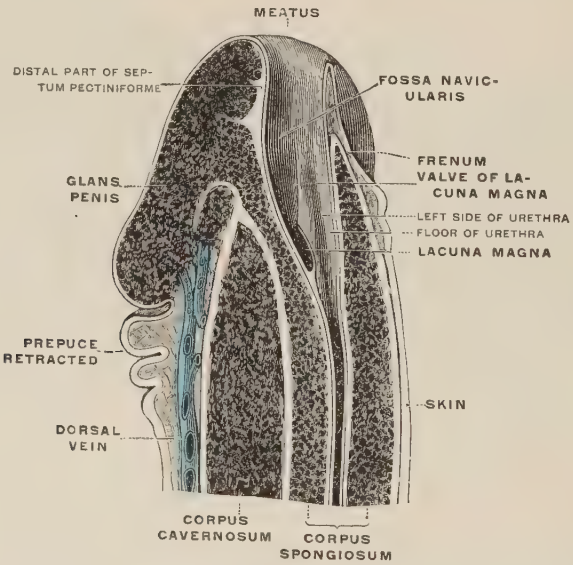

FIG. 930.—The penis, distal end, in sagittal section one-twelfth inch at left of middle line. (Testut.)

The **glans** (Figs. 930–932) forms the anterior extremity of the penis. It is conoidal in outline and presents at its summit a vertical fissure, the *meatus urinarius externus*, the anterior opening of the urethra. Its base, directed backward and hollowed to receive the tips of the cavernous bodies, as already mentioned, is not at right angles to the long axis of the penis, but so placed that it extends farther backward on the dorsal than on the ventral aspect of

that organ. The prominent border of the base is called the *corona glandis*; the constricted portion of the body behind this, the *cervix*. The external surface of the glans is smooth, and presents below a longitudinal groove which begins a little behind the meatus, extends backward, and lodges the frenum of the prepuce.

Structure.—The corpus spongiosum is composed of a thin layer of erectile tissue, which surrounds the urethra and is enclosed in a fibrous sheath. It therefore resembles the cavernous bodies; but the sheath is thinner and contains more elastic fibres, and the areolæ are smaller. The erectile layer of the bulb is thickened and prolonged backward, so as to surround the membranous and prostatic portions of the urethra. The erectile structure of the glans is continuous with that of the spongy body, from which, however, it is derived only in small part, the greater portion being developed from the integumental tissues which invest the glans (Retterer). Its trabeculæ are very coarse, its areolæ small. During erection the corpus spongiosum never attains the same degree of rigidity as the cavernous bodies.

The **Envelops of the Penis**, four in number, are concentrically arranged around the erectile cylinders. They are from without inward as follows: (1) the integument; (2) the dartos; (3) an areolar layer; (4) the fascia of the penis.

The **cutaneous envelop** (Figs. 930, 931, 934) is continuous with the integument of the pubic region and scrotum behind, and in front assists in forming the prepuce. It is thin, deeply pigmented, and free from fat; contains abundant elastic tissue; and is remarkable for its distensibility and the laxity of its attachment to the subjacent tissues. It is studded with sebaceous glands, and presents a median raphe on the under (hind) surface of the penis, continuous with that of the scrotum.

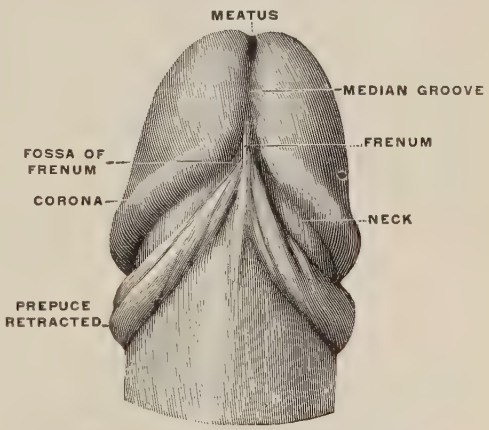

FIG. 931.—Glans penis, under surface. (Testut.)

The **prepuce**, or foreskin, is a tegumentary fold, disposed like a cuff around the glans. It is formed as follows: just behind the cervix the integument leaves the surface of the penis and is continued forward for a varying distance, forming the outer layer of the prepuce; then it turns backward within itself, forming the inner layer, and rejoins the surface at the level of the cervix. From this point the integument is reflected anew over the cervix and glans, to which it is intimately adherent, finally becoming continuous at the meatus with the mucous membrane of the urethra. Thus constituted, the prepuce presents two surfaces, outer and inner, and an anterior opening, the *preputial orifice*. Below, it is drawn forward in a median fold, the *frenum*, which occupies the ventral groove on the glans, and is attached a little behind the urinary meatus. The integument, which forms the inner surface of the prepuce and covers the cervix and glans, is so modified in character as to resemble mucous membrane. Over the cervix and corona it is studded with numerous sebaceous follicles, the *glandulæ odoriferæ*, the secretion of which, added to the desquamated epithelial cells of this vicinity, forms a whitish substance of peculiar odor, the *smegma præputii* ("unguent of the foreskin"). The integument over the glans adheres closely to the erectile tissue beneath, possesses only rudimentary sebaceous follicles, and is beset with large nervous and vascular papillæ.

The **dartos layer** is continuous with a similar structure in the scrotum, and is formed chiefly of plain muscular fibres, the great majority of which are arranged longitudinally. It extends to the preputial orifice, then like the skin

turning backward, it becomes more and more attenuated, and is finally lost on the cervix. When contracted, the dartos compresses the veins, and thus favors engorgement.

The **areolar sheath** lying beneath the dartos, is prolonged forward as far as the preputial orifice. It is loose, rich in elastic fibres, but almost devoid of fat, and contains the superficial vessels and nerves. To this layer the skin owes its mobility.

The **fascia of the penis** reposes on the erectile bodies. Anteriorly it does not enter into the formation of the prepuce, but passes directly to the base of the glans, where it fuses with the integument. Behind, it is continuous with the superficial perineal fascia and the suspensory ligament. Structurally it is composed almost entirely of elastic tissue, and it therefore acts as a compressor of the deep veins.

Conformation and Fixation.—The anterior extremity or glans penis has already been described. The *body*, when flaccid, is soft, cylindrical in outline, and hangs vertically from the front of the symphysis, forming with the root an acute angle, the *angle of the penis;* when erect, it becomes much larger, changes in direction, and is prismatic in outline with rounded borders. The *root* is made up chiefly by the diverging crura. These are held in position by their insertion into the ischio-pubic rami, and by short fibrous bands, which unite them to the pubic arch, the symphysis, and the inferior layer of the triangular ligament. The *suspensory ligament*, a triangular band of elastic tissue, also aids in securing the root. Its apex is attached to the upper part of the symphysis and the neighboring linea alba; its posterior border blends with the front of the symphysis; its anterior border is free. Below, its fibres divide into two groups, median and lateral. The former are inserted into the fascial sheath to the right and left of the dorsal vein, the latter separate to surround the cavernous bodies.

Vessels.—The *arterial supply* (Fig. 932) of the envelops is derived from the external pudic, and from the superficial perineal and dorsal artery of the penis,

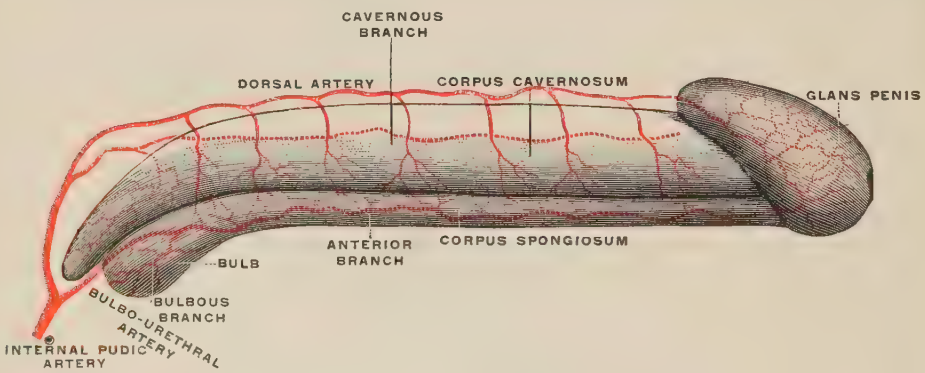

FIG. 932.—Diagram of the arteries of the penis. (Testut.)

branches of the internal pudic. Each cavernous body receives from the corresponding internal pudic a branch, which penetrates the albuginea on its inner side just behind the point where the converging crura meet. This vessel sends a recurrent branch to the crus, and then passes forward in the central axis of the body, anastomosing frequently through the fissures in the septum with its fellow. Small twigs from the dorsal artery of the penis also perforate the albuginea. The bulb and body of the corpus spongiosum are supplied by a branch (artery of the bulb) from each internal pudic. A smaller branch from the same source or from the transverse perineal also enters the dorsal surface of the bulb. The glans is supplied by the dorsal artery of the penis. In the erectile tissue the arteries are supported by the trabeculæ, and are divided into two groups—

nutritive and *functional*. The former supplies the histological elements, breaking up into capillaries, which merge into veins in the ordinary way. The latter, according to Eckhard, forms bouquets of short terminal branches, which open into the areolæ by means of small orifices. These orifices are surrounded by elastic tissue, which keep them closed when the penis is flaccid. Small convoluted twigs, called *helicine arteries*, are sometimes seen projecting into the areolæ.

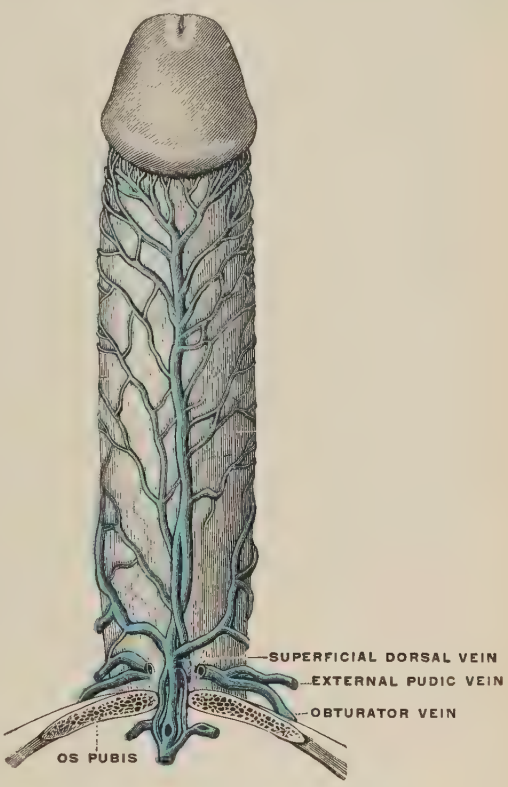

FIG. 933.—Veins of the penis. (Testut.)

The *veins* (Fig. 933) from the envelops and the prepuce converge toward the dorsum of the organ, where they form a common canal, the *superficial dorsal vein*, which follows the median line, lying in the areolar layer beneath the dartos, and ends in the external pudic and obturator veins. The veins from the corpus spongiosum emerge along its whole length. Those from the glans pass backward to the excavation at its base, where they form the *deep dorsal vein*, which runs beneath the fascial sheath, in the superior groove formed by the cavernous bodies, and perforates the triangular ligament to end in the prostatic plexus. Those from the body and bulb terminate in the same plexus or in the internal pudic veins. Small venous branches from the cavernous bodies emerge from both the superior and inferior surfaces; the former pass directly into the deep dorsal vein, the latter terminate in the same vessel after first encircling these bodies. The principal efferent trunk, however, comes from the posterior extremity of the cavernous body and perforates the triangular ligament to end in the prostatic plexus or the internal pudic veins.

The *lymphatics* from the prepuce and envelops form a single superficial dorsal trunk, which accompanies the vein of the same name, and, dividing at the root of the penis into right and left branches, terminates in the superficial inguinal nodes. The deep lymphatics take origin in the erectile structures. In the glans they communicate freely with the lymphatics of the urethra. Behind the glans they form a trunk, which follows the deep dorsal vein, and ends in the internal iliac nodes.

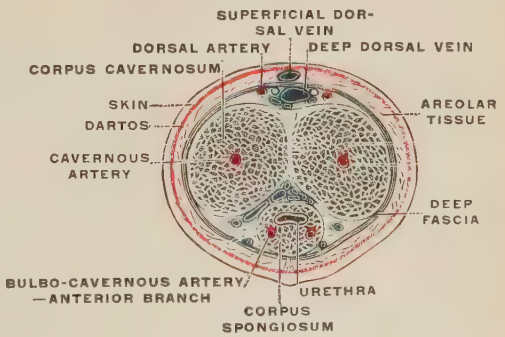

FIG. 934.—The penis in transverse section, showing the blood-vessels. (Testut.)

Nerves.—The coverings of the penis receive their nerve-supply from the genital branch of the genito-crural, and from the inferior perineal branch of the internal pudic. The erectile structures receive sympathetic branches from the hypogastric plexus, and spinal branches from the dorsal nerve of the penis and the superficial perineal.

THE PROSTATE GLAND.

The prostate ("standing in front") (Figs. 935, 936) is a glandular body, situated around the initial portion of the urethra. It develops at puberty, atrophies after castration, and in certain animals increases in size during the breeding season.

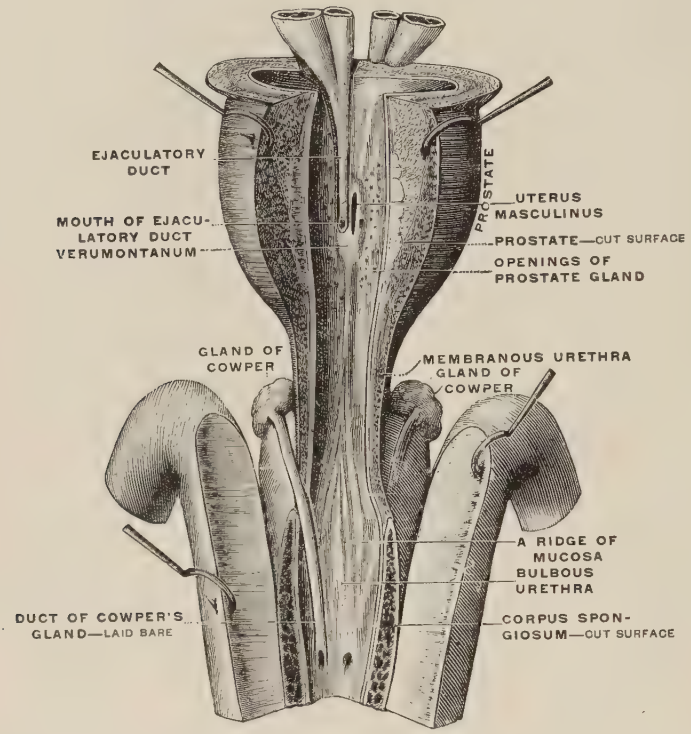

FIG. 935.—Proximal portion of the urethra, laid open by a median, anterior cut. (Testut.)

Form and Location.—It is irregularly cone-shaped, flattened from before backward, and is so directed that its central axis, running downward and forward from base to apex, makes with the vertical an angle of twenty to twenty-five degrees. It occupies the median line, lying below the bladder, above the triangular ligament, behind the symphysis, and in front of the rectal ampulla.

Volume.—In the child the prostate is only rudimentary in size; but at puberty it begins to enlarge, attaining its full development from the twentieth to the twenty-fifth year. Its size, therefore, depends on the age of the subject. In the adult it is about one inch and a quarter in length (from base to apex), one and one-half inch in width at the base, a little over an inch in thickness, and it weighs from four to six drachms. After the sixtieth year of life, often earlier, the prostate frequently becomes enlarged to double or even triple its original size; and this senile hypertrophy, which is probably always pathological, may be confined to the middle lobe, or may affect the entire organ.

Conformation and Relations.—The gland presents for description a base, an apex, an anterior, a posterior, and two lateral surfaces. The *posterior surface*, looking backward and downward, rests on the anterior wall of the rectum, through which it may be felt above the internal sphincter and below and in front of the trigone of the bladder. This surface presents along the median line a shallow groove, which indicates the division of the gland into lobes. The *anterior* or pubic face, convex, shorter, and of less extent than the posterior, is turned toward the symphysis, from which it is separated by the prostatic plexus of

veins, the pubo-prostatic ligaments, and the anterior ligament of the bladder. The *lateral surfaces* are convex, and covered by the anterior margins of the levatores ani muscles, the vesico-prostatic plexus of veins intervening. The *base* is situated immediately below the bladder, with the muscular fibers of which it is directly continuous. The *apex* rests on the upper surface of the superior layer of the triangular ligament, about half an inch behind the symphysis, and a little below the horizontal plane drawn through the highest point of the subpubic arch.

The prostate is traversed from base to apex by the first portion of the urethra, which occupies the median plane, but is nearer to its anterior than to its posterior surface. The direction of the ejaculatory ducts has already been described.

Lobes.—The prostate consists of two lateral lobes, which meet and become continuous both in front of and behind the urethra; and this bilobed condition is indicated by a posterior median groove, the prostatic fissure, which lodges the vasa deferentia and the vesiculæ seminales. On median section, however, the gland is seen to consist of three parts, one in front of and two behind the the urethra. Of the two posterior divisions that above the ejaculatory ducts is called the third or median lobe. It is, of course, continuous at the sides with the lateral lobes. When slightly enlarged the median lobe forms a projection on the middle zone of the base; greater degrees of enlargement cause the posterior wall of the vesico-urethral opening to become convex, thus changing both the length and direction of the urethra, and often interfering with micturition and the passage of sounds.

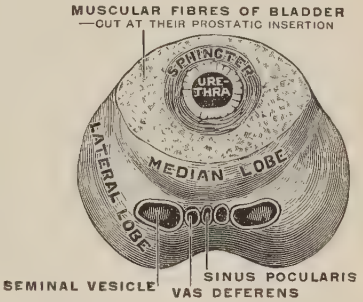

FIG. 936.—Base of the prostate gland. (Testut after Sappey.)

Minute Structure.—Structurally the prostate consists of two principal elements—stroma, and glandular tissue. The *stroma*, made up of connective tissue and smooth muscular fibres, forms for the prostate a sort of external capsule, in the thickness of which are lodged the veins of the prostatic plexus. By its outer surface this capsule is in contact and blended with the recto-vesical fascia and the superior layer of the triangular ligament. The inner surface of the capsule gives birth to a system of *trabeculæ*, which, radiating toward the verumontanum in the floor of the urethra, divide the gland into a number of triangular spaces, in which is lodged the glandular tissue. The *muscular fibres* of the stroma are abundant, constituting about one half of the entire mass of the gland. Above, they are continuous with the muscular fibres of the bladder wall, and form a strong ring surrounding the urethra; below, they are mingled with a small amount of voluntary muscular tissue, derived probably from the transverse perineal muscles.

The *glands* are of the branched or tubular variety, and number 30 or 40. They are disposed in a radiating direction around the urethra. Their ducts communicate with the urethra by minute orifices, opening into the prostatic sinuses on either side of the verumontanum. The glands are lined by a layer of columnar epithelium. They secrete a milky fluid, which at the moment of ejaculation is added to the seminal fluid.

Vessels and Nerves.—The *arterial supply* is derived from the inferior vesical and the middle hemorrhoidal arteries. These furnish branches of small calibre, which ramify in the thickness of the organ, forming capillary plexuses around the walls of the glands. The *veins* empty into the plexus (vesico-prostatic), which surrounds the prostate, terminating finally in the internal iliac vein. The *lymphatics* take origin around the glandular walls, ramify with the venous plexus, and finally end in the internal iliac nodes. The *nerves* are branches of the hypogastric plexus.

THE BULBO-URETHRAL GLANDS.

The bulbo-urethral or *suburethral glands*, more commonly called the glands of Cowper (Fig. 935), are two firm, rounded, somewhat lobulated bodies, about the size of peas. They are situated between the two layers of the triangular ligament, one on either side of the membranous urethra, and immediately above the posterior extremity of the bulb. From the last they are separated by the inferior layer of the triangular ligament, and some fibres of the constrictor urethræ muscle.

Each of these bodies is a compound racemose gland made up of several lobules, held together by fibrous tissue. The ducts of the lobules unite to form a single duct, which escapes from the gland at its anterior and superior aspect. The ducts from both glands pierce the triangular ligament, and converging, run forward beneath the mucous membrane for an inch or more, to open finally by minute orifices into the floor of the bulbous urethra. The acini of the glands are lined with pyramidal epithelium, the ducts by a finely granular epithelium disposed in two layers. The product of these glands is a viscid, transparent, albuminoid fluid, which is mixed with the seminal fluid at the moment of ejaculation.

THE MUSCLES OF THE MALE PERINEUM.

These are divided into two groups, according as they are closely related to the anal canal or to the genito-urinary organs. In the former set are the anal sphinc-

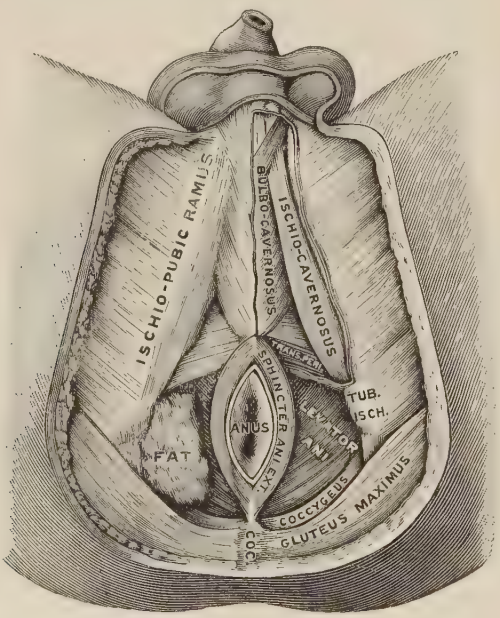

FIG. 937.—Muscles of the male perineum. (Testut.)

ters, the levatores ani, and the coccygei; in the latter are the transversi perinei, the ischio-cavernosi, the bulbo-cavernosi, and the constrictor urethræ. All are in pairs, excepting the sphincters (including the constrictor), which are bilaterally symmetrical.

About an inch in front of the anus four of these muscles—one behind, one in front, and one on each side—unite in a small, tendinous area, called the *central point of the perineum*.

The Anal Group (Fig. 937).

The *internal sphincter* has already been described in connection with the organs of digestion.

Sphincter Ani Externus, "the external sphincter of the anus," surrounds the lower part of the anal canal. It is three or four inches long and two wide. It arises from the tip of the coccyx; its lateral halves run forward, one on each side of the canal, and unite in front of it, where they presently become inserted into the central point of the perineum. It closes the anal canal. Its nerves are the fourth sacral and the inferior hemorrhoidal branch of the pudic.

Levator Ani, "the lifter of the anus," forms the greater part of the floor of the pelvic cavity on each side. It arises partly from bone, but mostly from fascia upon a line which extends from the body of the os pubis to the ischial spine. Its insertions are all at lower levels than any part of its origin, the pelvic floor sagging in the middle. Its front fibres run backward to the central point of the perineum, embracing the prostate; those at the rear pass mesially to the coccyx; and those between the front and rear, constituting the bulk of the muscle, course toward the middle line, and are inserted some into the wall of the anal canal, and some into a median raphe in front of and behind the canal. Its upper surface is covered with the recto-vesical fascia. The two muscles, like all of the perineal muscles, act in concert. Their contraction lifts the pelvic floor and tends to counteract the action of the sphincters, thus aiding in defecation. They also assist in other expulsive movements by compressing the abdomino-pelvic contents. The supplying nerves are the fourth sacral and the perineal branch of the pudic.

Coccygeus, "the coccyx muscle," completes the muscular floor of the pelvis on each side, so largely formed by the levator. It arises from the spine of the ischium, expands into a triangle, and is inserted into the margin of the coccyx and the last segment of the sacrum. It acts with the levator, and pulls the coccyx forward when it has been displaced backward, as in defecation. Its nerve is the fourth sacral.

The Genito-urinary Group (Fig. 937).

Transversus Perinei, "the transverse muscle of the perineum," is sometimes called "superficial" to distinguish it from the "deep transverse,"—a name often given to the constrictor urethræ. It arises from the mesial side of the tuber ischii, passes forward and inward, and is inserted into the central point, fusing with its opposite fellow, the external sphincter, and the bulbo-cavernosus. Its nerve is the perineal branch of the pudic. The transversi serve to fix the central point, and thus aid the action of the other muscles which are attached to it.

Ischio-cavernosus, named from its attachments, is also called *erector penis*. It arises from the mesial surface of the tuberosity and ramus of the ischium at the sides of the crus penis, thus embracing this structure. It is inserted into the external and inferior surfaces of the anterior part of the crus. It is supplied by the perineal branch of the pudic nerve. Its action, by compressing the crus, is to cause and maintain erection.

Bulbo-cavernosus is thus named from its attachments to the bulb of the corpus spongiosum and to the corpus cavernosum. It is also known as the *ejaculator urinæ*, *accelerator urinæ*, and *ejaculator seminis*. From the central point of the perineum a tendinous raphe extends forward in the mid-line upon the bulb. This and the central point give origin on each side to one of these muscles, the fibres passing obliquely forward, embracing the bulb and the part of the corpus spongiosum just in front of it. The greater part are inserted on the dorsum of the spongy body, while the foremost fibres extend around the side of the cavernous body and are inserted on its dorsum in the mid-line. The perineal branch of the pudic nerve supplies it. The two muscles compress the hind part of the spongy urethra and drive its contents forward.

Constrictor Urethræ, also named *compressor urethræ*, is enclosed between the two layers of the triangular ligament, and includes the membranous portion of the urethra, for which it acts as a sphincter. It is sometimes called the *deep transverse muscle*, because it extends across from side to side between the ischio-pubic rami. Part of it goes in front and part behind the urethra. It squeezes the membranous urethra, and thus expels its contents. The dorsal nerve of the penis supplies it.

THE FEMALE ORGANS OF GENERATION.

The female generative organs are divided into an *internal* and an *external group*. The former are contained within the pelvis and comprise the following structures: (1) the *ovaries*, two glandular organs devoted to the production of the ova; (2) the *Fallopian tubes*, canals through which the ova reach the uterine cavity; (3) the *uterus*, a single, median, hollow organ, which receives the fecundated ovum, provides it with nutrition, and expels it at maturity; (4) the *vagina*, a canal by means of which the uterine cavity communicates with the external surface of the body.

The *external organs*, grouped under the common term of *vulva* or *pudendum*, include the vulval canal and certain surrounding and contiguous structures.

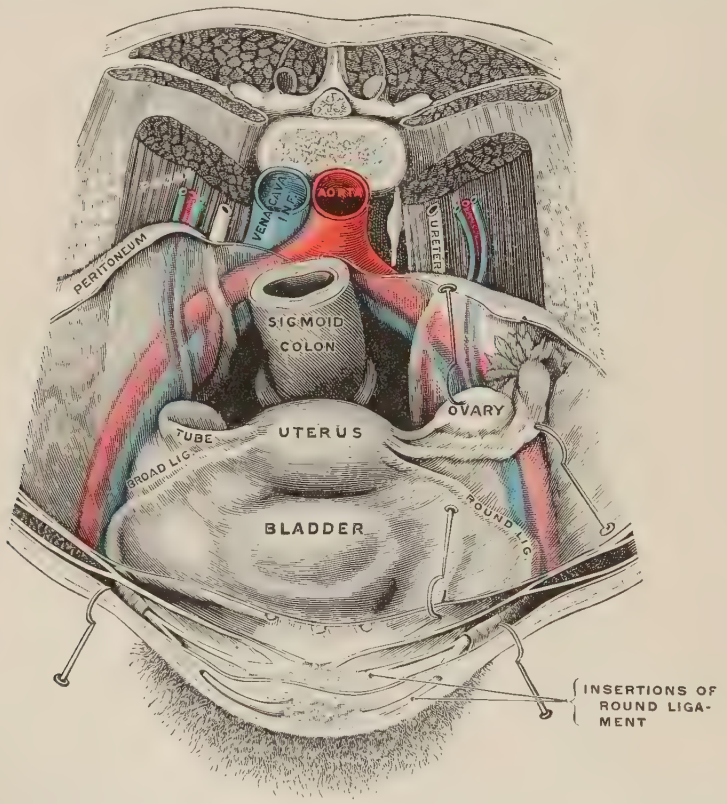

FIG. 938.—Female pelvic viscera, from above. The ovary and tube of the left side have been lifted out of place. (Testut.)

THE OVARIES.

The ovaries (Figs. 938, 939), two in number, are the essential female organs of generation. They are firm, fibrous, ovoid bodies, situated in the retro-uterine

compartment of the pelvis, where they are connected, one on either side of the uterus, with the posterior layer of the broad ligaments. On the surface of the abdominal wall, their position is indicated by the mid-point of a line drawn from the anterior superior spinous process of the ilium to the pubic symphysis.

Dimensions, Color, and Consistence.—Each ovary is about an inch and a half in length, three-quarters of an inch in breadth, from one-third to one-half an inch in thickness, and weighs from one to two drachms. During pregnancy, the gland which contains the corpus luteum is much larger than its fellow. In the child the ovaries are rosy white, in the adult they are reddish; and during menstruation, owing to the vascular engorgement, they assume a deeper tinge. They resemble the testicle in consistence, but are much less dense. In the old, the entire gland atrophies, and becomes hard and fibrous.

Conformation and Relations.—Each ovary presents for examination two surfaces, a superior or mesial, and an inferior or lateral; two borders, an anterior and a posterior; and two extremities, an external or superior, and an internal or inferior. The *superior surface*, convex and free, looks upward, forward, and inward, and is more or less covered by the fimbriæ of the Fallopian tube and the meso-salpinx. The *inferior surface*, turned toward the side wall of the pelvis, often reposes in a shallow depression, the *ovarian fossa*, which is bounded behind and below by the internal iliac vessels and the ureter, above by the external iliac vessels, and in front by the pelvic attachment of the broad ligament. The *anterior border*, almost straight, is attached to the posterior layer of the broad ligament, between the layers of which the vessels and nerves run to enter the ovary at a depression in this border, called the *hilum*. The *posterior border* is free, turned toward the rectum, and covered to a varying extent by the fimbriæ of the Fallopian tube. The *superior extremity* is rounded; the *inferior*, more pointed, does not quite reach to the pelvic floor. (The relation which the ovary bears to the Fallopian tube will be included with a description of the latter structure.)

Fixation.—The ovaries are held in position by their attached anterior borders, and by the utero-ovarian, the tubo-ovarian, and the suspensory ligaments. The

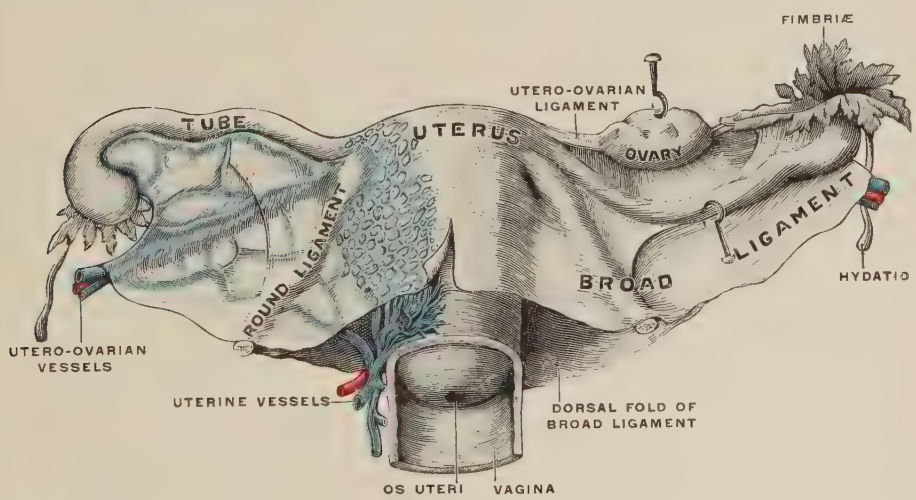

FIG. 939.—The uterus and appendages, front view. On the left side the tube is pulled down, the ovary lifted up. (Testut.)

utero-ovarian ligament is a short rounded cord somewhat over an inch in length, which, running between the folds of the broad ligament, connects the inferior extremity of the ovary with the superior angle of the uterus, where it is attached a little below and behind the origin of the Fallopian tube. It is composed of fibrous tissue and plain muscular fibres, the latter derived from the superficial

muscular layer of the uterus. The *tubo-ovarian ligament*, or *ovarian fimbria*, connects the superior extremity of the ovary with the fimbriated extremity of the Fallopian tube. The *suspensory ligament*, also called the *lumbo-ovarian ligament*, or *ligamentum infundibulo-pelvicum*, is the upper part of the external border of the broad ligament. Running downward from the brim of the pelvis, it is attached to the superior extremity of the ovary and carries between its folds the ovarian vessels and nerves.

Direction.—Usually the ovaries assume a slightly oblique direction, running downward, inward, and a little forward, so that their long axes, if extended below, would meet in front of the uterus. Their direction, however, varies widely within normal limits, and is much influenced by the fact that their ligaments are not only extensible, but two of them, the utero-ovarian and tubo-ovarian, take origin from movable points. Another important factor in determining the direction of the ovary is the condition of the neighboring organs. When the uterus deviates from the median line, the ovary of the side to which the uterus turns is vertical; while that of the opposite side, its lower extremity pulled on by the utero-ovarian ligament, is nearly or quite horizontal. A full bladder or rectum, by changing the position of the uterus, must also modify the direction of the ovary.

Structure.—The ovary consists of a framework of stroma, Graafian follicles, and an epithelial covering continuous with but differing from the peritoneum.

The *stroma* ("bed") is a connective tissue composed of abundant cells, white and yellow fibrous tissue, plain muscular fibres, blood-vessels, and nerves. Many of the cells are spindle-shaped, and are held by some anatomists to be cells of involuntary muscular tissue, while others regard them as connective-tissue cells. From the hilum there projects into the centre of the ovary a core made up wholly of stroma and called the *medullary substance*. It is very vascular and contains no Graafian follicles. From the periphery of this core numerous bands of stroma run toward the surface of the ovary, crossing and intersecting each other in every direction. Arrived at the surface, these bands reunite to form beneath the epithelial covering a thin fibrous layer, the *tunica albuginea ovarii*, which bears, however, but a faint resemblance to the tunica albuginea of the testicle, and cannot be dissected from the subjacent parenchyma. Between the tunica albuginea and the medullary substance is a thin zone called the *cortical layer*. It is only slightly vascular, and contains in various stages of development the Graafian follicles. The *epithelial covering*, composed of a single layer of columnar cells, reposes on the tunica albuginea, and is the remains of the germinal epithelium. The peritoneum, covered by flattened epithelial cells, is totally unlike this structure, which it joins at the level of the attached anterior border.

Graafian Follicles (Fig. 940).—The Graafian follicles contain the ova, and are embedded in the meshes of the ovarian stroma. Their structure depends on the degree of maturity which they have attained, and will therefore be described in several stages.

The *smallest follicles*, varying in size from $\frac{1}{800}$ to $\frac{1}{100}$ of an inch in diameter, consist of a single layer of flattened or spindle-shaped cells, which closely invest a larger cell, the *ovum*. In the young child each ovary contains about thirty-six thousand follicles of this grade.

In a second and *more advanced stage* the following structural changes are noted: (1) The surrounding stroma forms for the follicle a special wall, divisible into two layers—an outer, fibrous layer (*tunica fibrosa*), which encloses the blood-trunks and lymphatic spaces of the follicle; and an inner, vascular layer (*tunica propria*) composed of connective-tissue cells and a capillary plexus. (2) The spindle-shaped cells, which invested the ovum in the earlier stage, now become columnar and proliferate, making two layers, one of which lines the tunica propria, and is called the *membrana granulosa*, while the other invests the ovum and is known as the *discus proligerus*. (3) Between these two layers an albuminous transparent liquid, the *liquor folliculi*, is developed; and it crowds the

ovum to one side of the follicle, usually that nearest to the surface of the ovary, where the cells of the discus proligerus are continuous with those of the membrana granulosa. (4) Between the membrana granulosa and the tunica propria there appears a thin structureless membrane, the *membrana propria*.

The largest follicles are from $\frac{1}{20}$ to $\frac{1}{2}$ an inch or more in diameter. Their increased size is due mainly to an increase of the liquor folliculi. In this stage the membrana granulosa and discus proligerus each consists of several layers of

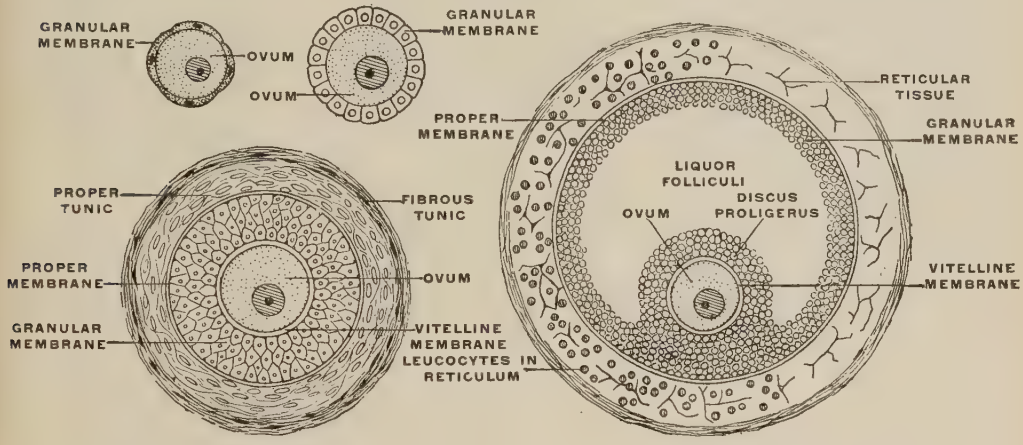

FIG. 940.—Graafian follicles, in different stages of development. Diagrammatic. (Testut.)

cells, derived by proliferation from the pre-existing cells. In the external layer, that is next to the tunica propria and the ovum, the cells retain their columnar outline, but the remaining layers are composed of irregular or rounded cells.

Origin.—In early fœtal life, the ovary is represented by a cellular mass derived from the peritoneal cover of the Wolffian body, and called the *germinal epithelium*. Among the small cells of which it is composed are certain larger, spherical, nucleated cells, the *primordial ova*. Soon, from the fibrous stroma beneath the epithelium, prolongations of connective tissue grow into the mass of cells; and coincidently the cells, themselves becoming involuted at certain points, grow into the stroma. In this way irregular tubes lined with polyhedral or rounded cells are formed. Later, bands of stroma grow across these tubes and divide them into nests of cells. These nests are the future Graafian follicles, and each contains at least one primordial ovum. From the smaller cells are developed the membrana granulosa and discus proligerus. By about the seventh month of intra-uterine life these processes cease, and thereafter the ovary is covered by the single layer of epithelium already described.

Location.—The smallest follicles are found in the outer layer of the cortical zone of the ovary, where they are so numerous as to impart to this region a granular appearance. Many of these never develop. The larger follicles (ten to twenty in each ovary) occupy the deeper layer of the cortical zone. The largest and most mature follicles are in contact with the medullary substance and nourished by its rich vascular supply. Extending entirely across the cortical layer, they project from the surface of the ovary in the form of clear vesicles, $\frac{1}{20}$ to $\frac{1}{6}$ of an inch in diameter.

At puberty a certain number of follicles become enlarged, and from that time until the climacteric new ones are being constantly developed.

Structure of the Ova.—The human ovum in the primordial stage is about $\frac{1}{1000}$ of an inch in diameter, in the mature stage its diameter is increased to $\frac{1}{150}$ of an inch. It is developed from a nucleated cell and presents the following parts: (1) an outer covering representing the cell wall, and called the *zona pellucida* or *vitelline membrane;* (2) within this a mass of protoplasm, the *vitellus* or

yolk; (3) situated excentrically in the vitellus the *germinal vesicle*, which represents the nucleus of the cell; (4) the nucleolus or *germinal spot*.

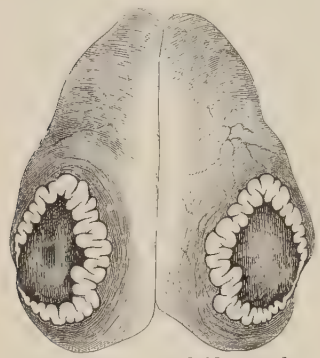

FIG. 941.—Ovary, laid open by a longitudinal cut, showing a corpus luteum three weeks after menstruation. (Dalton.)

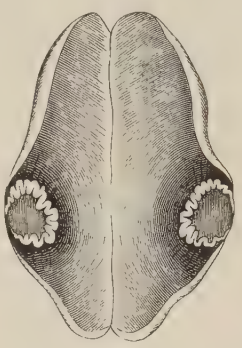

FIG. 942.—Ovary, laid open by a longitudinal cut, showing a corpus luteum four weeks after menstruation. (Dalton.)

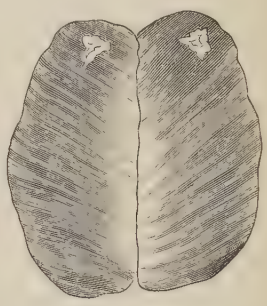

FIG. 943.—Ovary, laid open by a longitudinal cut, showing a corpus luteum nine weeks after menstruation. (Dalton.)

FIG. 944.—Ovary, laid open by a longitudinal cut, showing a corpus luteum at the end of the second month of pregnancy. (Dalton.)

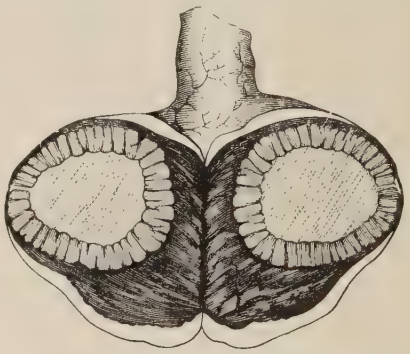

FIG. 945.—Ovary, laid open by a longitudinal cut, showing a corpus luteum at the end of the fourth month of pregnancy. (Dalton.)

The *zona pellucida*, a thick, strong and transparent membrane, forms the outer covering of the ovum. It is marked by numerous radiating striæ, and for this reason is sometimes called the *zona radiata*. The striæ are supposed to be minute canals, through which nutrition reaches the ovum, while it is still in the Graafian follicle, and through which the spermatozoa may afterward pass in the process of fecundation. The *yolk* or *vitellus* is a soft substance contained within the zona radiata. It consists of granules embedded in a fine reticulum of protoplasm. The *germinal vesicle*, $\frac{1}{1000}$ to $\frac{1}{800}$ of an inch in diameter, lies near the periphery of the ovum. It is composed of a structureless membrane, containing a fine clear matrix, in which are embedded a few granules. The *germinal spot*, or nucleolus, $\frac{1}{3600}$ to $\frac{1}{2500}$ of an inch in diameter, occupies the side of the germinal vesicle nearest to the periphery of the ovum. There may be more than one.

FIG. 946.—Ovary, laid open by a longitudinal cut, showing a corpus luteum at the end of the ninth month of pregnancy. (Dalton.)

Origin.—The primordial ova are scattered among the other cells of the germinal epithelium, and with them descend into the substance of the ovary, as already described. Some, however, remain behind, and are found among the single layer of columnar cells, which covers the surface of the ovary. These probably undergo no further development.

Discharge.—Rupture of a Graafian follicle, and sometimes more than one, occurs shortly before or during each menstrual period. It takes place at a point in the peripheral pole of the follicle called the *stigma* ("point") or *macula* ("spot") *folliculi*. The wall at this point is scantily supplied with blood-vessels, and, as the follicle nears maturity, it undergoes fatty degeneration. The ovum with the liquor folliculi and cells of the discus proligerus is discharged on the surface of the ovary.

Corpora Lutea.—A corpus luteum ("yellow body") occupies the site of each ruptured Graafian follicle, and is produced by certain changes which take place in the follicular wall. A short time before the follicle is ready to rupture, the cells of the tunica propria begin to proliferate, and the wall of the follicle is thrown into folds, into which project newly formed vascular loops. A blood-clot fills the follicle after rupture, but it is soon absorbed and the folds, growing into the cavity, take its place. In the non-pregnant the whole structure begins to shrink in about two weeks, and in a short time disappears. The corpus luteum of pregnancy differs much from that just described. It is larger and persists for a longer time. As the blood-clot disappears, a peculiar yellowish connective tissue (yellow probably because the cells are loaded with oil-globules) takes its place. After several months the corpus luteum ceases to grow, but it is still present, though much reduced in size, even at the end of pregnancy. (Figs. 941–946.)

The surface of the ovary is smooth until puberty. After that time it grows more and more uneven, due to the scarring which follows the formation of the corpora lutea.

Vessels and Nerves.—Each ovary is supplied with blood by a branch from the abdominal aorta, the *ovarian artery*, which corresponds to the spermatic in the male. This vessel is carried to the ovary between the layers of the suspensory ligament. It divides into two branches: a tubal, distributed to the Fallopian tube, and an ovarian. The latter runs in a flexuous course along the attached border of the ovary, to which it sends from ten to twelve branches, and ends by anastomosing with the uterine artery near the superior angle of the uterus. The branches to the ovary, also tortuous, end in capillary plexuses in the tunica propria of the Graafian follicles. The *veins* form in the middle of the organ a considerable mass, called the *bulb of the ovary*. Emerging from the hilum, these vessels join with some of the uterine veins to form between the layers of the broad ligament the *pampiniform* ("tendril-form") *plexus*. From this the blood is collected by a single trunk, the *ovarian vein*, which follows the course of the corresponding artery. The right ovarian vein empties into the inferior vena cava, where it is supplied with a valve. The left joins the renal vein at a right angle, and is without valves. The *lymphatics* begin as minute spaces in the tunica fibrosa of the follicles, around which they form plexuses. At the hilum they are condensed into five or six trunks; and, following the veins, they finally empty into the lumbar nodes. The *nerves* are derived from the ovarian plexus of the sympathetic. An additional supply is probably received from the uterine nerves, branches of the third and fourth sacral.

Migration.—The ovaries are situated primarily in the lumbar region, in front of the psoas, and near the kidney. About the third month of intra-uterine life they begin to descend, and at the ninth month they reach the brim of the pelvis. This descent is chiefly due to the fact that the lumbar region grows away from the ovary. Sometimes, though rarely, the gland may remain in its primitive situation, or it may descend into the inguinal canal, even passing through the external abdominal ring.

THE FALLOPIAN TUBES.

The Fallopian tubes, or *oviducts* ("egg-ducts") (Figs. 938, 939), two in number, are the excretory ducts of the ovaries and serve to convey the ova to the uterine cavity.

Location.—They are situated in the free or upper margin of the broad ligaments, between the ovaries behind and the round ligaments in front. Internally they are continuous with the superior angles of the uterus, externally each tube is attached to the superior or outer extremity of the corresponding ovary. That portion of the broad ligament below each tube, and between it and the ovary, is called the meso-salpinx ("mesentery of the tube"). The oviducts are, therefore, fixed in position by their continuity with the uterus, by their attachments to the ovaries, and by their imprisonment between the two peritoneal laminæ, of which the broad ligaments are composed.

External Conformation.—Each tube is trumpet-shaped, and increases in size from within outward. At the ovarian extremity, it expands to enclose a funnel-shaped space, the *infundibulum* or *pavilion*. It varies in length from four to five inches, and is divided into three parts as follows: (*a*) the inner extremity or interstitial portion; (*b*) the middle portion or body; (*c*) the external or fimbriated extremity. The *interstitial portion* is contained in the thickness of the uterine wall. Its canal, very narrow, is continuous with the uterine cavity through a small opening, the *ostium uterinum* ("door of womb"), which is only large enough to admit a small bristle. The *body* is subdivided into two parts, an inner or isthmus and an outer or ampulla. The *isthmus* is hard, cylindrical, straight, and nearly horizontal. It measures an inch and a half in length, and has a diameter of about one-eighth of an inch. The canal of this division is still very small, though somewhat increased as compared with that of the interstitial portion, with which it is continuous. The *ampulla* ("bottle") or *receptaculum seminis* ("reservoir of seed") extends from the isthmus to the fimbriated extremity. It is distinguished from the former by the fact that it has thinner walls, and is softer, and flattened antero-posteriorly. It is also markedly flexuous, and the diameter is almost twice that of the isthmus. Its canal, increased in size toward the outer extremity, is irregular in calibre, and large enough to admit a uterine sound.

The **fimbriated extremity** (infundibulum) opens downward, backward, and inward. It is the most movable part of the tube, and receives the ova after their discharge from the Graafian follicles. This extremity may be divided for description into an internal and an external surface, a base and a summit. The external surface, continuous with the outer surface of the tube, is smooth and covered by visceral peritoneum. The internal surface is continuous with the corresponding surface of the ampulla, and lined by a prolongation of its mucous membrane. At the summit, the infundibulum communicates with the cavity of the ampulla through a narrow opening, a line to a line and a half in diameter, called the *ostium abdominale*. The base is festooned by ten to fifteen diverging processes, called *fimbriæ* ("fringes"), which are arranged in two or three concentric circles. The bases of these are attached, their apices are free, and their edges are cut into numerous secondary fringes. The *ovarian fimbria*, longer than its fellows, runs from the lower part of the ampulla, to become attached to the superior extremity of the ovary. On its inner surface a gutter, lined by mucous membrane, extends from the ovary to the ostium abdominale. By its outer surface it is in contact with a band of smooth muscular fibres continued from the muscular tunic of the tube. Sometimes the ovarian fimbria is not quite long enough to reach the ovary; it is then attached through the medium of this muscular band, which also carries the terminal portion of the mucous gutter.

Internal Conformation.—The canal, as already stated, increases in diameter as it passes outward. Its mucous membrane is thrown into folds, making a system of longitudinal plications, which extend throughout the whole length of the canal. In the interstitial portion and isthmus these folds are simple ridges separated by shallow grooves. In the ampulla they increase in number and volume; and the larger, extending clear across the canal, may bear on their sides secondary folds. The outer ends of these plications cross the ostium abdominale and are continued on to the inner surface of the fimbriæ.

Direction.—The Fallopian tubes are freely movable particularly in their outer portion. They are pushed backward by a full bladder, depressed by intestinal folds from above, or pushed forward when the intestines occupy the retro-uterine space. They are affected, too, by any change of position in the uterus. The direction which they pursue is therefore variable. Usually each tube runs from its inner extremity transversely outward to a point opposite the middle of the ovary, a distance of half an inch to one inch. It then runs upward, also a little backward and outward, in front of the attached border of the ovary, near to and parallel with the pelvic wall. Arrived at the superior extremity of the ovary it bends backward, and, after a short course in this direction, terminates by running inward and downward. It thus forms a sort of bay whose concavity, directed downward and inward, embraces the upper end of the ovary, while the fimbriæ lie in contact with the posterior border and mesial surface of the gland.

Structure.—The tube has three tunics—serous, muscular, and mucous. The two laminæ of the broad ligament furnish the *serous covering*, and these, as they approach the tube, diverge, leaving along its lower border a narrow uncovered strip. A layer of loose areolar tissue, continuous with the subperitoneal fascia and rich in elastic fibres and blood-vessels, is found beneath the serous coat. The *muscular tunic* may be divided into two layers, longitudinal and circular. The former is superficial and continuous internally with the uterine muscle; externally it ends at the origin of the pavilion, except for the band, already mentioned, which accompanies the ovarian fimbria. The circular layer, also continuous with the uterine muscle, is thinnest near the fimbriated extremity, and ends at the ostium abdominale. In the vicinity of the uterus some longitudinal fibres are found within the circular. The *mucous coat* is continuous with the mucous lining of the uterus. Having no special submucosa, it is intimately adherent to the muscular layer. It forms the plications already described, and is lined by a single layer of columnar, ciliated epithelium, in which the ciliary motion is toward the uterus. Crossing the ostium abdominale the mucous membrane establishes itself on the inner surface of the fimbriæ. At the borders of the latter, or on their outer surfaces a little beyond the borders, it merges into the peritoneum. It has no glands.

Vessels and Nerves.—*Arteries.*—The external tubular artery is derived from the ovarian, the internal tubular from the uterine. Together these form an arcade, which travels between the layers of the meso-salpinx, and sends branches to the lower borders of the tube. The *veins* form in the meso-salpinx a plexus parallel to the axis of the tube, and finally empty through the pampiniform plexus into the utero-ovarian veins. The *lymphatics*, joining with those of the ovary and uterus, empty into the lumbar nodes. The *nerves*, derived from a plexus around the uterine and ovarian arteries, are numerous; but their course and mode of termination are not well known.

THE UTERUS.

The uterus or *womb* (Figs. 938, 939, 947), a hollow organ with thick, muscular, contractile walls, is situated in the pelvis between the bladder and the rectum. In its cavity the ovum is received, retained, and developed; and the fœtus, after reaching maturity, is expelled chiefly by the contractions of its muscular fibres.

External Conformation.—The uterus, in form, resembles a truncated cone, whose base, turned upward, reaches to or a little above the level of the pelvic brim; and whose summit, directed downward, projects into the upper extremity of the vagina. It is flattened from before backward, and divided into two parts by a slight circular constriction, called the *isthmus*, which corresponds externally and in front with the point at which the peritoneum is reflected from the uterus to the bladder, while internally it coincides with a narrowing of the uterine canal, known as the *internal os*. In virgins the isthmus is a little below the middle of

the long axis of the uterus; in women who have borne children it is placed at the junction of the middle and lower thirds. It divides the uterus into the body above and the cervix below.

The *body* presents for description two surfaces, two borders, two extremities, and two angles. The anterior surface is slightly, the posterior markedly, convex and both are covered by peritoneum. The lateral borders, also convex, converge a little as they run downward to the isthmus. The superior extremity or *fundus* (sometimes called a border) is broad, convex, and covered by the peritoneum, as

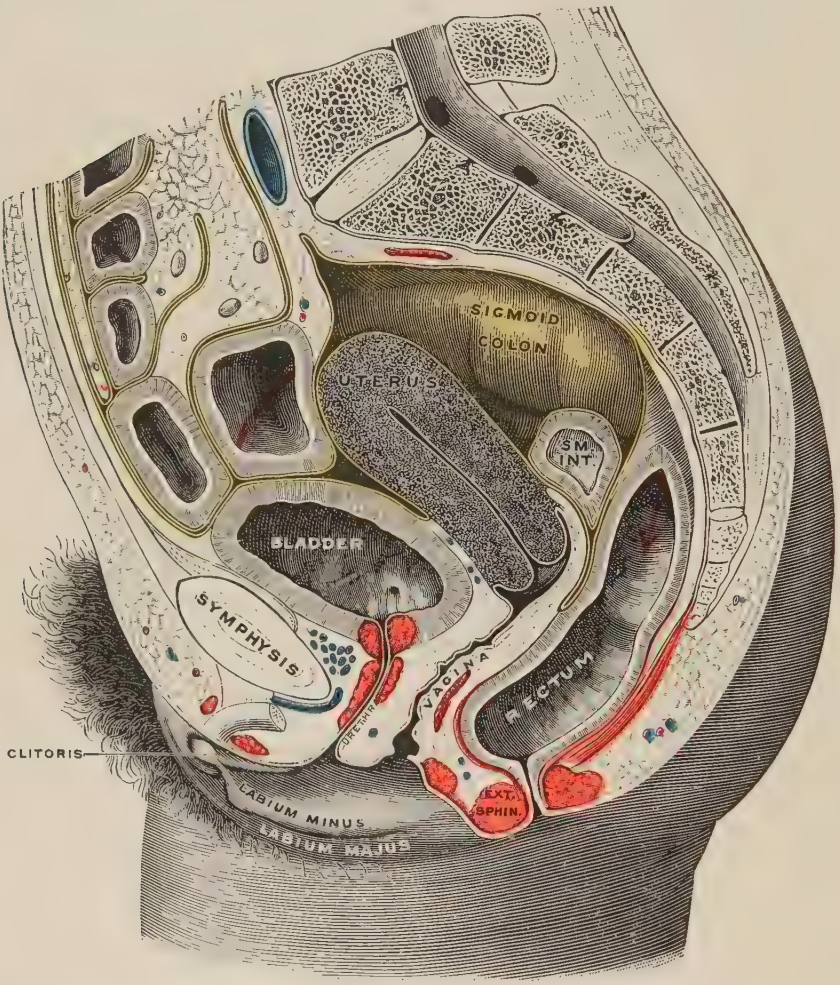

FIG. 947.—Sagittal section of the lower part of a female trunk, right segment. SM. INT., small intestine. (Testut.)

it passes from the anterior to the posterior surface. At the inferior extremity the body is continuous with the cervix. The angles, right and left, are formed by the junction of the superior extremity with the lateral borders. They are continuous with the corresponding Fallopian tubes.

The *cervix*, narrower than the body and cylindrical in form, has a slightly wider diameter in the middle than at either extremity. It is continuous above with the body, below it projects into the vagina, which is attached around its circumference somewhat higher behind than in front. That portion above the vaginal attachment (supra-vaginal segment) comprises about two-thirds of the total length of the cervix in front, about one half behind. The middle or vaginal

segment—that part to which the vagina is attached—is about one-fifth of an inch in length, and is placed obliquely. The lower or intra-vaginal segment is cone-shaped, covered by mucous membrane like that of the vagina, and presents at its summit a circular or transverse aperture, the *external os*.

Internal Conformation.—The cavity of the uterus is divided into two parts by the internal os. The upper portion belongs to the body, the lower to the cervix. The long axes of these segments may lie in the same straight line, but usually they join to form an angle, opening anteriorly, of 140° to 170° (Testut).

The **cavity of the body** (Figs. 948, 949), triangular in outline and with the

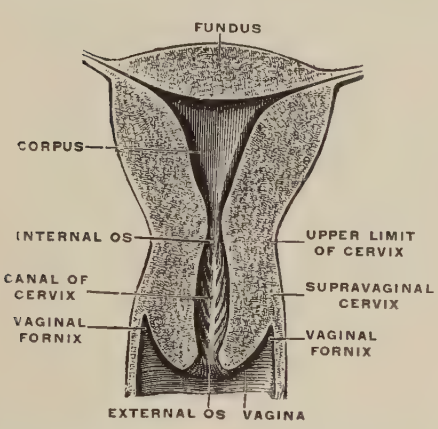

FIG. 948.—The uterus of a virgin, in coronal section.

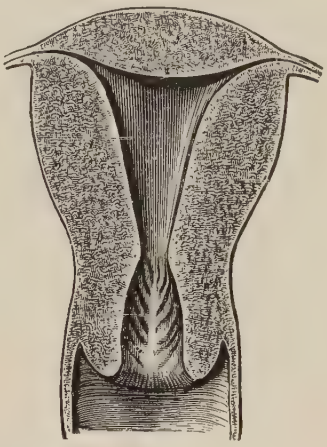

FIG. 949.—The uterus of a woman who has borne a child, in coronal section.

base uppermost, presents two surfaces, three borders, and three open angles. The surfaces, anterior and posterior, are in contact. All the borders, in the virgin, are convex internally; in women who have borne children the two lateral are straight or even concave. At the superior angles the cavity of the body communicates with the oviducts, at the inferior angle, or internal os, it is continuous with the cervical canal.

The **cavity of the cervix**, fusiform in outline, presents two surfaces, two borders, and two openings. The surfaces, distinguished as anterior and posterior, are in contact. On each may be seen a peculiar formation, the *arbor vitæ uterina* ("cedar of the womb"), consisting of a median longitudinal ridge, from which secondary and parallel ridges pass upward and outward to the lateral borders. In these ridges are smooth muscular fibres derived from the internal muscular layer of the uterine wall. The borders, situated laterally, are concave internally, thus widening the central portion of the cavity. The superior opening (*os uteri internum*) is not a simple opening, but a short canal. The inferior opening (*os uteri externum*) is usually a transverse aperture, about one-twelfth of an inch in length. It is bounded by two lips, an anterior and a posterior. The latter is the longer, due to the higher attachment of the vagina behind, but the former is placed on a lower level and hence appears on palpation to be the longer. Both are normally in contact with the posterior vaginal wall. The outline of the external os is much modified by child-bearing.

Dimensions, Consistence, and Weight.—The uterus is about three inches in length, one and one-half to two inches in breadth at the upper and widest part of the body, and nearly an inch in thickness. In women who have borne children these diameters are all increased. The walls are about three-eighths of an inch in thickness. After death they are dense and resisting, but during life they are soft enough to retain sometimes the imprint of contiguous intestinal folds. The whole organ varies in weight from seven to twelve drachms.

Direction.—The direction of the uterus is variable, and much influenced by the condition of the surrounding organs. Thus, a full bladder will push the uterus toward the sacrum, a full rectum will press it forward. When the bladder and rectum are empty, the fundus looks toward the umbilicus, and the uterus forms with the vagina a right or slightly obtuse angle. As a rule, the organ does not occupy the median line of the body, but is somewhat deflected, usually to the right. There is also present a certain amount of torsion, by means of which the left superior angle is carried a little farther forward than the right.

Peritoneum (Fig. 950).—The peritoneum is reflected from the bladder to the anterior surface of the uterus at a level which usually corresponds to the isthmus, but may be slightly above or below. It then invests in the order named the anterior surface of the body, the fundus, the posterior surface of the body, and the posterior surface of the supra-vaginal segment of the cervix. It is also continued downward over the upper fourth of the posterior vaginal wall, and is then reflected to the front and sides of the rectum. At the lateral borders of the uterus the peritoneum from the anterior surface joins with that from the posterior to make up the broad or lateral ligaments. Certain portions of the cervix have thus no peritoneal covering. They are the intra-vaginal and vaginal segments, and the anterior surface of the supra-vaginal portion. This latter rests against the bladder from which it is separated by areolar tissue, continuous with the subperitoneal fascia. Areolar tissue is also found covering the lower part of the posterior surface of the uterus, and extending outward between the layers of the broad ligaments.

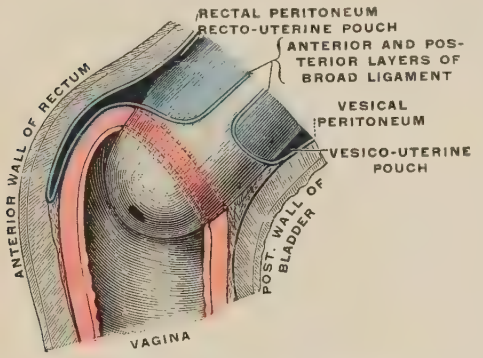

FIG. 950.—The cervix uteri and upper end of the vagina, showing their relations to the peritoneum. Diagrammatic. (Testut.)

Peritoneal Pouches.—The peritoneum, as it dips into the recess between the bladder and the uterus, forms a shallow pouch, the *utero-vesical*, which is occupied, when the bladder is empty, by coils of small intestine. Behind the uterus it forms a second and deeper pouch, the *recto-vaginal*, or *cul-de-sac of Douglas*. This is limited in front by the cervix and upper part of the vagina, behind by the rectum, and laterally by two folds of peritoneum, the *folds of Douglas*, which extend from the cervix in front to the sides of the rectum behind. The folds of Douglas, together with the smooth muscular fibres contained between their layers, constitute the utero-sacral ligaments. Coils of small intestine frequently occupy the upper, but are rarely found in the lower, part of the recto-vaginal pouch.

Ligaments.—The uterus is maintained in position by six important ligaments, arranged in three pairs. They are the broad or lateral, the round, and the utero-sacral.

The **broad or lateral ligaments**, two in number, extend from the lateral borders of the uterus and upper part of the vagina outward to the lateral walls of the pelvis, where they merge into the parietal peritoneum. They are composed of two apposed, serous laminæ, which are continuous with the peritoneum covering the anterior and posterior surfaces of the uterus. Between these laminæ are found the following structures: (*a*) the Fallopian tube; (*b*) the ovary and its ligament; (*c*) the round ligament; (*d*) blood-vessels and lymphatics; (*e*) nerves; (*f*) remains of certain fœtal structures; (*g*) smooth muscular fibres; (*h*) areolar tissue, rich in fat and continuous with the subperitoneal fascia. Each ligament has two surfaces and four borders. At the superior border, which is free, the laminæ are continuous and enfold the Fallopian tube. The inferior border

is attached to the floor of the pelvis, areolar tissue intervening between it and the recto-vesical fascia. The ureter crosses obliquely beneath this border. The external border is divided into two portions, upper and lower. The latter is firmly attached to the pelvic fascia, and transmits the uterine artery and the round ligament. The upper and shorter portion is free, and connects the fimbriated extremity of the Fallopian tube with the side of the pelvis. It is called the *ligamentum infundibulo-pelvicum*, and carries between its layers the ovarian vessels. (This is usually described as a part of the superior border.) The internal border is in relation with the side of the uterus and upper part of the vagina, and lying between its laminæ are the utero-vaginal vessels. The anterior lamina, shorter than the posterior, is in relation with the bladder. It is partially raised from the posterior by the round ligament, over which it falls in a more or less definite fold. The posterior lamina, directed toward the rectum, gives off a special extension to enclose the ovary and its ligament. The fold or extension surrounding the Fallopian tube is sometimes called the meso-salpinx; between its layers there are no muscular fibres.

The smooth muscular fibres of the broad ligaments are derived from the superficial muscular layer of the uterus. Passing outward between the laminæ, they become attached to the pelvic fascia and help to sustain the uterus. With the areolar tissue they also form a support for the blood-vessels.

The **round ligaments**, about five inches in length, are also symmetrically arranged, one on either side. Each takes origin from the corresponding superior angle of the uterus in front and a little below the attachment of the Fallopian tube. From this point it runs obliquely forward and outward to gain the internal abdominal ring. Entering this, it traverses the inguinal canal, and, after emerging from the external ring, it finally ends in the tissues of the labia majora and mons Veneris. It is divided into four portions—pelvic, iliac, inguinal, and vulvar. The direction of the pelvic portion is at first a little downward, then upward as it emerges from the pelvis. The iliac portion, lying behind the peritoneum, crosses in front of the external iliac artery and vein. At the internal ring the ligament winds around the outer side of the deep epigastric artery, and the inguinal portion gives off fibres, which are attached to the walls of the canal. The vulvar portion breaks up into numerous divergent, connective-tissue filaments, some of which are attached to the symphysis, while the remainder are lost in the tissues of the mons and labia majora. Structurally the round ligaments are composed of plain and striated muscular fibres, areolar tissue, blood-vessels, and nerves. The plain fibres are derived from the superficial muscular layer of the uterus; the striated, found only in the distal portion of the ligament, are acquired from the internal oblique and transversalis muscles and represent the cremaster in the male. They help to attach the ligament to the pillars of the external ring and the pubic spine. A tube of peritoneum, representing the processus vaginalis, accompanies the ligament into the inguinal canal. It sometimes remains pervious even in the adult, and is called the *canal of Nuck*.

The **utero-sacral ligaments** are partly serous, partly of smooth muscular fibres. The serous portions are identical with the folds of Douglas already described. They extend between the cervix and sides of the rectum, forming the lateral boundaries of the recto-vaginal pouch. The muscular fibres are continuous with the superficial muscular layer of the uterus and vagina. Running between the layers of the folds of Douglas they serve to connect the cervix and vagina with the sacrum.

The peritoneum at the bottom of the utero-vesical pouch is sometimes referred to as the *anterior ligament of the uterus*, while that which floors the recto-vaginal pouch is called the *recto-vaginal ligament*.

Minute Structure.—The uterus consists of three coats—serous, muscular, and mucous. The serous coat has already been described.

The *muscular coat* makes up the bulk of the uterine walls. It is dense and resisting, cuts with a grating sound, and is grayish on section. It is composed

of smooth muscular fibres, intermingled with areolar tissue, vessels, and nerves. The arrangement of these fibres is very complex, but in the gravid uterus they may be divided into three layers, which are, however, not entirely independent.

The *mucous membrane* lining *the body* of the uterus is intimately adherent to the internal muscular layer. It is pale and smooth, and presents the openings of numerous glands. Its external layer, or corium, is composed of embryonic connective tissue in which may be seen numerous round, spindle-shaped, or irregular cells. Lining this is a single, ciliated, columnar epithelium, the ciliary motion being from within outward. The *glands* are of the tubular variety, bounded by a basement membrane, and lined by ciliated, columnar epithelium, continuous with that found on the free surface. They pass obliquely or take a tortuous course through the corium; and their blind extremities, single, bifurcated, or even trifurcated, repose on the internal muscular layer, or penetrate between its fibres. The ciliary motion in the glands is toward the uterine cavity.

The *mucous membrane* of *the cervix* differs from that of the body. It is firmer and thrown into numerous folds, the ridges of the arbor vitæ already described. The corium has fewer cell-elements, but is richer in fibres. The epithelium in the upper part of the cervix is the same as that found in the body; below, at the level of the external os or a little higher, it changes into a laminated epithelium, continuous with that which lines the vagina and covers the external surface of the os. The *glands*, tubular and racemose in type, are numerous and open between the ridges. They are lined in their deeper portions by goblet cells, and produce a thick alkaline mucus. Sometimes by the occlusion of their openings these glands become cystic; they then appear as clear or yellowish vesicles, and are called the *ovula of Naboth*. Vascular papillæ are found in the lower part of the cavity of the cervix, and over the outer surface of its intra-vaginal segment. In the latter situation there are no glands.

Structural Modifications During Menstruation and Pregnancy.—In *menstruation* the more important changes take place in the mucous membrane of the body, which increases in vascularity and becomes thickened. Following this there are disintegration and removal of the superficial part of the membrane, the process beginning at the internal os and extending toward the fundus. Regeneration, brought about by a proliferation of the cells which remain in the deeper portions of the glands, is rapid and complete. In these changes the cervix takes little or no part. In *gestation* the whole organ becomes immensely hypertrophied, increasing in weight from an ounce to a pound and a half or even more. The muscular fibres not only increase in size, but in the early months new ones are added. The mucous membrane is at first the seat of changes similar to those which occur in menstruation, but these proceed further, and later bring about the formation of the decidua. The membrane, as soon as the ovule has been engrafted upon it, loses its cylindrical epithelium while the cells of the corium increase. The ridges of the arbor vitæ disappear; otherwise there is but little change in the cervix. At parturition the greater part of the mucous membrane is destroyed, to be restored in from twenty to twenty-five days by the same method as after menstruation.

Following parturition the uterus never returns to its former (virgin) size.

Variations Depending on Age.—In the fœtus, the uterus is contained in the abdominal cavity, the cervix is larger than the body, the fundus is undeveloped, and the ridges of the arbor vitæ are distinct. At puberty, the cervix and body are about equal in length, and the fundus has reached the level of the pelvic brim. In the old the entire organ atrophies.

Vessels and Nerves (Fig. 951).—The *arteries* which supply the uterus are arranged in three pairs—the uterine, the funicular, and the ovarian. The *uterine artery* is a branch of the anterior division of the internal iliac. From its origin it descends along the pelvic wall into the base of the broad ligament, then, taking a horizontal course, it crosses in front of the ureter and reaches the side of the cervix at the level of the vaginal insertion or a little below. From this point it is

reflected upward, running close beside the lateral border of the uterus until it reaches the superior angle, where it ends by dividing into two branches, one of which anastomoses with the ovarian artery while the other is distributed to the Fallopian tube. From the ascending portion of the vessel numerous transverse tortuous branches are given off to the anterior and posterior surfaces of the uterus. These penetrate the uterine walls, and ramify in the middle muscular layer, where they divide into two sets of branches, superficial and deep. The former return to supply the outer muscular layer and the serous coat, the latter are distributed to the mucous membrane, forming plexuses in its superficial layers and around the glands. At the level of the isthmus the transverse branches are larger than elsewhere, and, with the corresponding divisions of the opposite artery, they form on the outer surface of the uterus the arterial circle of Huguier. Several small branches to the bladder and vagina arise from the uterine artery at or near its point of reflection. The *funicular* ("pertaining to a rope") *artery*, from the superior vesical, joins the round ligament at the internal abdominal ring and divides into two branches, superior and inferior. The former accompanies the ligament to the superior angle of the uterus, where it anastomoses with the uterine and ovarian arteries; the latter follows the ligament to its distal termination,

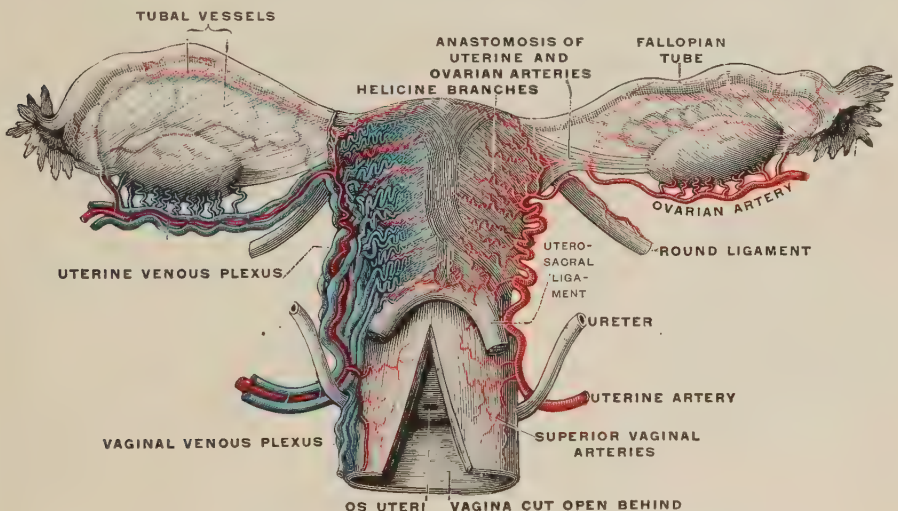

FIG. 951.—Vessels of the uterus and its appendages, rear view. (Testut.)

communicating there with the external pudic. The *ovarian artery*—described with the ovary—aids in supplying the uterus through its communications with the uterine and funicular arteries. The *veins*, which are very large, have no valves. Taking origin in the capillary plexuses, they converge to form a set of special canals, the *uterine sinuses*, which are lodged in the meshes of the middle muscular layer. From this point they are directed to the lateral borders of the uterus, where they form between the layers of the broad ligament the *uterine plexuses*, one on either side. From these the blood is collected by three trunks. One, the uterine vein, accompanying the artery of that name, empties into the internal iliac vein; a second, by its junction with the veins from the ovary and Fallopian tube, helps to make up the pampiniform plexus; while a third (unimportant) trunk follows the funicular artery. The *lymphatics* of the mucous membrane begin as minute spaces between the fibres of the corium. Joined by the lymphatics of the muscular coat, they emerge and form beneath the serous covering a rich plexus, from which the lymph is carried by three trunks. The first, collecting chiefly from the body of the uterus, the ovary, and the Fallopian tube, accompanies the ovarian vein and empties into the lumbar nodes; the second, carrying lymph from the cervix, follows the uterine vein, and ends in the internal

iliac nodes; while the third, following the uterine vein of the round ligament, ends in the superficial inguinal nodes. The *nerves*, consisting of both medullated and non-medullated fibres, are derived from the inferior hypogastric and renal plexuses of the sympathetic, and from the third and fourth sacral nerves.

The fœtal remains to be observed in connection with the uterus or its adnexa are the parovarium, the duct of Gärtner, the organ of Giraldès, and the hydatid of Morgagni.

The **parovarium** (epoöphoron, or organ of Rosenmüller) is a vestige of the Wolffian body, and represents the vasa efferentia of the testicle. It consists of twelve to twenty tubules, arranged in the form of a triangle, and contained in the thickness of the broad ligament, between the ovary and the Fallopian tube, where it may be seen by holding the ligament against the light. The apex of the triangle reaches to the attached border of the ovary, the base is turned toward the Fallopian tube. The ovarian ends of the tubules are blind; their opposite extremities open into a collecting duct which runs parallel with the outer portion of the Fallopian tube, and represents the canal of the epididymis. Both the collecting duct and the tubules are lined with a ciliated, columnar epithelium.

The **canals of Gärtner**, always present in certain animals, are the remnants of the lower portions of the Wolffian ducts. The latter, in the male, develop into the tail of the epididymis and the vas deferens; in the female they usually disappear. When persistent, however, they are found, as minute tubes or fibrous cords, one on either side of the uterus and vagina. Above, these tubes may be continuous with the collecting tubes of the parovarium; below, they may sometimes be traced to the vicinity of the urinary meatus.

The **organ of Giraldès** in the male, is represented in the female, by a few scattered tubules, remnants also of the Wolffian body, which lie between the layers of the broad ligament, nearer to the uterus than the parovarium.

The **hydatid of Morgagni**, a relic of the Müllerian duct, is usually found in the form of a small pediculated cyst, attached to one of the fimbriæ of the Fallopian tube. It is lined with ciliated, columnar epithelium, and filled with a clear fluid.

THE VAGINA.

The vagina ("sheath") (Fig. 952) is a distensible, musculo-membranous canal, which extends from the uterus to the vulva. It is the organ of copulation in the female, and in addition affords passage to the menstrual flow and the fœtus.

Location, Direction, and Dimensions.—It is situated in the median line of the pelvis, between the bladder and rectum. Running downward and forward, its lower extremity makes with the horizontal plane an angle of 60° to 70°, opening posteriorly. The axis of the canal is not straight, but presents a posterior concavity, which fits a corresponding convexity of the rectal wall. The anterior vaginal wall measures two to two and a half inches in length; the posterior varies from two and a half to three and a half inches. Continuous above with the cervix, the vagina is further fixed in position by its connections with the bladder, rectum, vulva, and perineum.

Conformation and Relations.—Above, where the vagina embraces the cervix, it is circular; below, at the vulvo-vaginal junction, it is elliptical, with the major axis antero-posterior. Between these points the anterior and posterior walls are in contact, thus reducing the canal to a mere fissure, which on transverse section is H-shaped. The vagina may therefore be divided for further description into two surfaces—the external or attached, and the internal or free; and two extremities—the upper and the lower.

The **external surface** presents two faces, an anterior and a posterior, and two lateral borders. The upper half of the anterior face is in relation with the bladder, the lower half with the urethra. The lower two-thirds of the latter is buried in the anterior vaginal wall, the upper third and the bladder are separated

from this face by areolar tissue, continuous with the subperitoneal fascia. In this fascia the terminal segment of the ureter runs obliquely, to open into the bladder wall at a point one and a quarter inches below the level of the external os. (It must not be forgotten that in the female a portion of the base of the bladder rests against the anterior surface of the cervix.) The posterior face is covered above to a varying extent (usually about one inch) by the peritoneum as it dips into the cul-de-sac of Douglas. The middle portion rests against the rectum, from which it is separated by a continuation of subperitoneal fascia. Below, it is widely separated from the termination of the rectum by the triangular perineal body. The lateral borders are in contact above with a small portion of the broad ligaments. In the upper third they are crossed obliquely by the ureters, and below this they are embraced by the anterior margins of the levatores ani muscles and the accompanying recto-vesical fascia. By the side of the upper half of each lateral border may sometimes be found a small tube, the continuation of the duct of Gärtner.

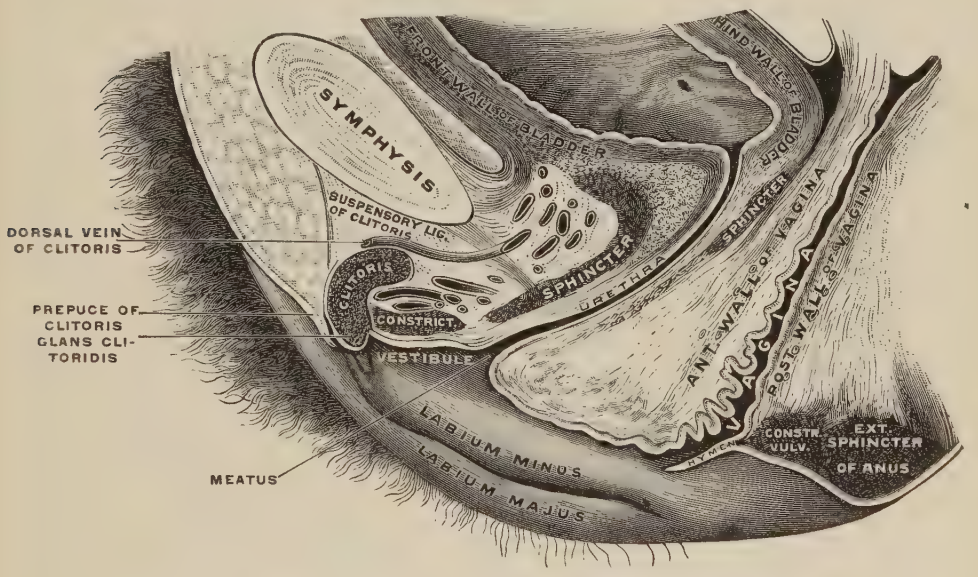

FIG. 952.—Sagittal section of the vagina and neighboring parts. (Testut.)

On the **internal** or **mucous surface** are two median longitudinal ridges, the *columns of the vagina*, situated one on the anterior, the other on the posterior wall. The latter is sometimes double. From these, numerous secondary ridges pass transversely outward to the lateral borders. Both the columns and secondary ridges are better marked in the lower portion of the vagina than above. After child-birth they diminish in prominence or entirely disappear.

The *superior extremity* is attached to the circumference of the cervix reaching higher behind than in front. With the outer surface of the intra-vaginal segment of the cervix it makes a circular pericervical trench, the *fornix*, which is deepest behind. The *inferior extremity* pierces the triangular ligament, and is the narrowest and least dilatable portion of the canal.

Structure.—The vaginal wall, about one-sixth of an inch in thickness, consists of three coats—an outer of connective tissue, a middle of muscular tissue, and an inner of mucous membrane. The *connective-tissue coat* is a thin white fibrous structure, derived from the recto-vesical fascia. It contains a few smooth muscular fibres, and carries in its meshes a plexus of veins. The *muscular coat*, of unstriped fibres, may be divided into two layers, superficial and deep. The fibres of the superficial layer, longitudinal in arrangement, are continuous with

the superficial muscular layer of the uterus. They are also continuous above with the utero-sacral ligaments, by means of which the vagina is attached to the sacrum. Below, some of the longitudinal fibres are inserted into the ischio-pubic rami, while others are lost on the triangular ligament and recto-vesical fascia. The deep layer is made up of circular fibres, which surround the canal. Near the vulvo-vaginal orifice these fibres are condensed into a ring of some strength, which forms an involuntary sphincter. The striated sphincter of the vagina is derived from the muscles of the perineum. The *mucous coat*, thrown into folds as already described, is covered with stratified epithelium, continuous with that lining the vulva below and covering the cervix above. Its deep layer or corium is closely attached to the muscular tunic, no special submucosa intervening. The lower portion of this coat is studded with numerous conical or filiform papillæ. The upper portion presents a few closed follicles; otherwise the mucous membrane is entirely devoid of glands.

Vessels and Nerves.—The *arteries* are all derived from the internal iliac or its branches. The vaginal artery, corresponding to the inferior vesical in the male, runs along the lateral borders of the vagina, supplying arteries to the anterior and posterior surfaces. A small vaginal branch from the uterine, and anastomosing branches from the remaining vesicals, middle hemorrhoidal, and internal pudic are also supplied. The *veins*, remarkable for their number and volume, direct themselves to the lateral borders, where they form the *vaginal plexuses*, one on either side. These communicate with the veins of the uterus, broad ligaments, bladder, rectum, and bulbs of the vagina, and finally empty through the uterine and vaginal trunks into the internal iliac vein. The *lymphatics* from the lower third of the vagina, joining with those from the vulva, empty into the superficial inguinal nodes; the remainder end in the internal iliac nodes. The *nerves*, derived from the hypogastric plexus, the fourth sacral, and the pudic, are distributed to the mucous and muscular tunics. Their mode of termination is unknown.

THE VULVA.

The vulva or *pudendum* (Fig. 953), ovoid in outline, is bounded in front by the anterior abdominal wall, behind by the perineum, and laterally by the inner surfaces of the thighs. It includes the following parts: (1) the mons Veneris, the labia majora, and the labia minora (all derived from the integument); (2) between the labia a median space called the interlabial or vulval cleft; (3) an erectile apparatus; (4) certain glandular structures.

The Mons Veneris.

The mons Veneris is an elevation situated in front of the upper part of the pubic symphysis. Anteriorly and above, it merges into the integument covering the lower part of the abdomen, posteriorly it is continuous with the labia majora, laterally it is limited by the right and left inguinal folds. In structure the mons consists of modified skin, deeply pigmented, and covered with hair, beneath which is a collection of areolar and adipose tissue, intersected by a series of elastic laminæ. The latter take origin deeply from the linea alba and abdominal aponeurosis, and end by becoming attached to the deep surface of the skin.

The Labia Majora.

The labia majora ("greater lips"), two longitudinal folds of modified integument, are continuous with the mons Veneris in front, and extend to within an inch of the anus behind. Each fold is about three inches in length, and presents for description two extremities, two surfaces, and two borders. The anterior extremities by their junction with the mons and with each other make up the

anterior commissure; the posterior, having become very thin, are united by the *posterior commissure* or *fourchette* ("fork"), which constitutes the thin, anterior edge of the perineum. The outer surface, separated from the corresponding thigh by the genito-crural fold, is deeply pigmented, covered with hair, and abundantly supplied with sudoriparous and sebaceous glands; the inner is in contact, when closed, in part with its fellow, in part with the labium minus of the same side. The skin, which lines this surface in the vicinity of the free border, resembles that on the outer surface; more deeply it is rosy, moist, studded with

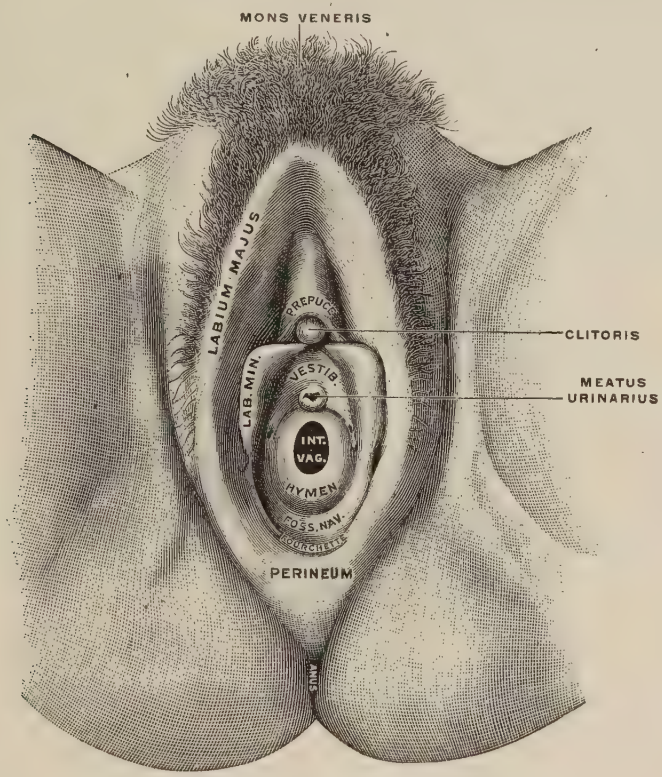

FIG. 953.—Vulva of a virgin. The labia have been widely separated. FOSS. NAV., fossa navicularis; INT. VAG., introitus vaginæ; LAB. MIN., labium minus; VESTIB., vestibule. (Testut.)

sebaceous follicles, and presents only rudimentary hairs. The superior or attached borders correspond to the ischio-pubic rami, with which they are connected by numerous fibrous bands. The inferior borders are free, and the fissure between them is called the *rima* ("crack") *pudendi*. In infants, young women, and fleshy subjects the labia majora are firm, and directly applied one to the other; in the old, the thin, and those who have borne many children, they shrivel and gape apart.

Beneath the integument of each labium majus there is found a tissue, resembling the dartos of the scrotum, but much thinner; beneath this a layer of adipose and connective tissue; and still deeper an elastic, pear-shaped sac, called *Broca's pouch*. This contains connective tissue and fat; and its mouth, applied to the external abdominal ring, may sometimes receive the termination of the canal of Nuck. Morphologically the labia majora correspond to the scrotum in the male.

The Labia Minora.

The labia minora ("smaller lips"), or *nymphæ*, are two smaller longitudinal folds, placed within the labia majora, and running from the clitoris downward

and backward for about one and one-half inch. They also present two surfaces, two borders and two extremities. The external surfaces are in contact with the labia majora, the internal with each other. The superior borders are attached, the inferior, often crenated, are free. The anterior extremities divide, each into two bands. The superior of these unite above the dorsum of the clitoris to form its prepuce; the inferior, uniting beneath the clitoris to which they are attached, form its frenum. Posteriorly each labium terminates opposite to or a little behind the middle of the rima pudendi. Rarely it is continuous farther backward, and is joined to its fellow by a slender transverse fold, placed on the anterior edge of the posterior commissure. This fold then becomes the fourchette. The nymphæ are composed of modified skin, beneath which is a connective tissue, rich in elastic and smooth muscular fibres, but containing no fat. In the young, where they are protected by the labia majora, they are rosy in color and moist, approaching in character the mucous membranes; when they project beyond the labia majora, however, they become dry and deeply pigmented. Their surfaces are free from hairs and sudoriparous glands, but are abundantly supplied with sebaceous glands, which secrete a thick, white substance, akin to the preputial smegma, and with papillæ, which contain nerves ending in tactile corpuscles.

The Interlabial Space.

The interlabial space or vulval cleft is bounded on either side by the labia majora and minora, in front by the clitoris, and behind by the posterior commissure. It receives the orifice of the vagina and the external opening of the urethra, becoming therefore the common uro-genital opening. Ordinarily, the tissues falling together, the space is obliterated, becoming merely a fissure; but, when the labia are drawn apart, it becomes broad, shallow, and elliptical in outline. Superficially, it is lined with modified skin, deeply with mucous membrane, which merges into that of the vagina and urethra. The line of demarcation between the skin and mucous membrane runs from beneath the prepuce of the clitoris backward along the inner surface and attached border of the labium minus to the outer aspect of the hymen (Hart). In the floor of the interlabial space from before backward may be seen the vestibule, meatus urinarius, orifice of the vagina, hymen, and fossa navicularis.

The **Vestibule** is a shallow triangular space, bounded laterally by the nymphæ, and behind by the orifice of the vagina. Its apex, directed forward, coincides with the clitoris.

The **Meatus Urinarius**, the external opening of the urethra, is situated in the median line, at the back part of the vestibule, about an inch behind the clitoris, and just in front of the vagina. Directly behind it there is an elevation of mucous membrane, the *vaginal tubercle*, which serves as a guide to the introduction of a catheter.

The **Inferior Orifice of the Vagina** (*introitus vaginæ*), when the hymen has been removed, is elliptical in outline. Its diameters are much greater in women who have borne children than in the nulliparous.

The **Hymen** ("a membrane") (Fig. 954) is placed at the vulvo-vaginal junction, narrowing to a greater or less degree the inferior vaginal orifice. It is composed of a double fold of mucous membrane, between the layers of which is found connective tissue, rich in elastic fibres. In shape it varies widely, the commonest forms being the falciform and the annular. In the former the hymen is semilunar in outline, with the concavity looking forward; in the latter a complete ring, usually widest posteriorly, surrounds the opening. Sometimes it forms a complete septum (imperforate hymen) or has many small openings (cribriform). The hymen is usually torn during the first coition, but may, when very elastic, escape rupture. After parturition there remain of it only some slight rounded elevations, the *carunculæ myrtiformes* ("little masses of flesh like myrtle-berries"), which occupy the site of its attached border.

The **navicular fossa** is that portion of the interlabial space, which lies behind the entrance to the vagina. It is bounded superficially by the fourchette, deeply by the superficial surface of the hymen.

FIG. 954.—Varieties of hymen. (Testut after Roze.)

Erectile Organs.

The erectile organs belonging to the vulva are the clitoris and the bulbs of the vagina.

The **Clitoris**, about one inch in length, is situated at the apex of the vestibule, between the anterior extremities of the nymphæ. It is the homologue of the penis, but has no corpus spongiosum, and no urethra. The two corpora cavernosa, of which it is mainly composed, are similar in minute structure to those of the male. Diverging behind, they constitute the crura, which are attached to the ischio-pubic rami superficial to the triangular ligament, and covered by the ischio-cavernosi (erectores clitoridis) muscles. In front the corpora cavernosa unite to form the body of the clitoris, the septum pectiniforme between them being imperfect. Their united distal extremities are surmounted by a glans, composed of very sensitive, spongy, erectile tissue. The clitoris has a prepuce and a frenum, both derived from the nymphæ, and is also provided with a suspensory ligament. It is supplied with helicine arteries and numerous anastomosing veins, agrees in structure with the erectile tissues described elsewhere, and is capable of erection.

The **Bulbi Vestibuli** (Fig. 955), or bulbs of the vagina, are two pyriform masses of erectile tissue, made up chiefly of a plexus of veins, enclosed in a thin, fibrous tunic. They are about an inch in length, and are placed one on either side of the uro-genital space, a little above the level of the nymphæ. Together they represent the bulb of the corpus spongiosum in the male. They each present two surfaces, two borders, and two extremities. The inner surfaces, covered by mucous membrane, are in close relation with the orifices of the urethra and vagina; the outer are covered by the bulbo-cavernosi muscles (acceleratores urinæ in the male), which here become the constrictors of the vagina. The upper borders are attached to the superficial layer of the triangular ligament, while the lower correspond with the attached borders of the nymphæ. The posterior extremities are rounded, and reach to the navicular fossa. The anterior pointed extremity of each is continued forward by means of a narrower plexus, the *pars intermedia*, which communicates with its fellow beneath the clitoris. The pars intermedia is homologous to that portion of the corpus spongiosum, which lies between the bulb and the glans. It receives veins from the nymphæ, and serves to connect the bulbs with the veins of the glans clitoridis and corpora cavernosa. When engorged the bulbi vestibuli narrow the vaginal orifice.

Glands.

In connection with the vulva are found: (1) the vulvo-vaginal glands; (2) the urethral and peri-urethral glands.

The **Vulvo-vaginal Glands**, or glands of Bartholin (Fig. 955), two in number, are situated one on either side of the vagina posteriorly, between the layers of the triangular ligament. They are round or oval in outline, measuring about half an inch in their longest diameter. Their ducts run forward and inward to open into the vulval canal, one on either side, in the groove between the hymen and labia minora. They are racemose, mucous glands, homologues of the glands of Cowper in the male, and their secretion lubricates the vulval canal.

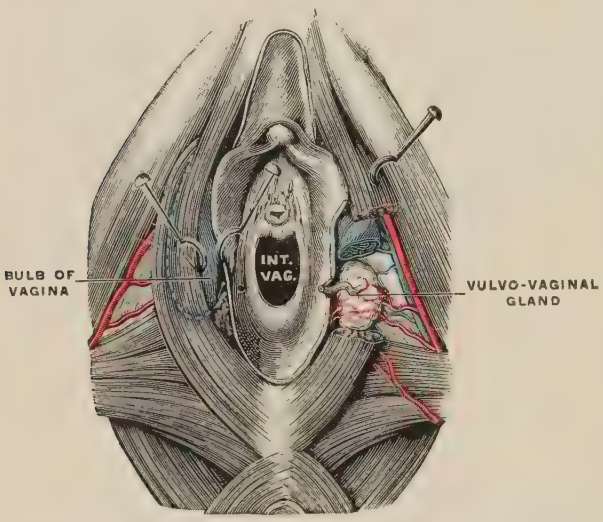

FIG. 955.—Vulvo-vaginal gland. The broken line indicates the limits of the bulb of the vagina. (Testut.)

The **Urethral Glands**, found chiefly beneath the lateral walls and floor of the urethra, vary in structure from simple inversions of the mucous membrane to racemose glands. Their openings are arranged in rows parallel with the long axis of the canal. They secrete mucus, and correspond morphologically with the prostatic glandular structure. Other glands found in the vestibule near to the urethra are designated *peri-urethral* or *glandulæ vestibulares minores*, the latter to distinguish them from the *glandulæ vestibulares majores* or glands of Bartholin.

Vessels and Nerves.—*Arteries.*—The superficial portions of the vulva are supplied by branches of the external and internal pudics; the deeper, by branches of the internal pudics alone. The clitoris and bulbi vestibuli receive branches from the internal pudics, corresponding in name to similar branches in the male. The *veins* for the most part end in trunks, which accompany the arteries. Those of the labium majus communicate freely with the veins of the round ligament at its distal extremity, while the bulbi vestibuli communicate with the vaginal plexuses, the dorsal vein of the clitoris, the veins of the corpora cavernosa, and the obturator veins. The *lymphatics* accompany the veins and empty into the superficial inguinal nodes.

Nerves.—Sympathetic nerves derived from the pelvic or inferior hypogastric plexus accompany the arteries. In addition spinal branches are supplied by the genito-crural, inferior pudendal, and internal pudic. In the nymphæ and glans clitoridis they end in the tactile corpuscles of Pacini and Meissner, and on the glans alone in the so-called genital corpuscles.

THE MUSCLES OF THE FEMALE PERINEUM.

The muscles of the female perineum (Fig. 956) are the homologues of those in the male.

The **sphincter ani externus** and **coccygeus** are identical in the two sexes.

The **transversi perinei** and **ischio-cavernosi** differ from their male counterparts

only in being smaller. The ischio-cavernosus is more frequently called the *erector clitoridis*, as it sustains the same relations to the clitoris that its enlarged masculine fac-simile does to the penis.

In the **levator ani** the anterior portion courses at the side of the vagina, and the pair of muscles probably produce some constriction of the lumen of the tube.

The **bulbo-cavernosi** are more commonly called the *sphincter vaginæ* or *compressor vaginæ*. They are smaller than in the male, and, instead of being united by a median raphe, are separated, and include in their grasp the opening of the vagina and the bulbs of the vestibule. They are inserted into the cavernous bodies of the clitoris.

The **constrictor urethræ**, or *transversus perinei profundus*, is mainly composed of unstriped muscular tissue. Its origin, as in the male, is from the ischio-pubic rami. The smaller anterior portion stretches across the subpubic arch in front

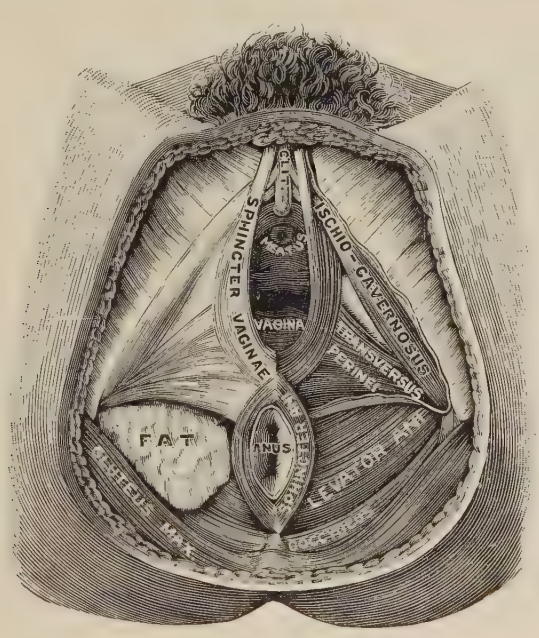

FIG. 956.—Muscles of the female perineum. (Testut.)

of the urethra. The larger, posterior portion is lost mesially in the muscular wall of the vagina.

THE MAMMARY GLANDS.

The two mammary glands, *mammæ*, or *breasts*, are accessory organs of generation, their secretion, the *milk*, serving to sustain the infant until it is capable of deriving its nourishment from other sources. Philosophically considered, each mamma is a collection of sebaceous glands, greatly enlarged, and extending far into the subcutaneous region, which here is vastly deeper than elsewhere. The secretion of the sebaceous glands is oily, and that of their prodigious congeners is of the same character, though in the one case the fluid is devoted to purposes of lubrication, in the other to nutritive uses.

Each breast is approximately hemispherical, and a little below the centre of its convexity presents a *mammilla* (nipple, teat, dug), usually shaped like a truncated cone, half an inch long, pointing forward, upward, and outward, and set in the middle of a circular area of darker skin, the *areola*.

The breast covers a nearly circular space, mostly in front of the pectoralis

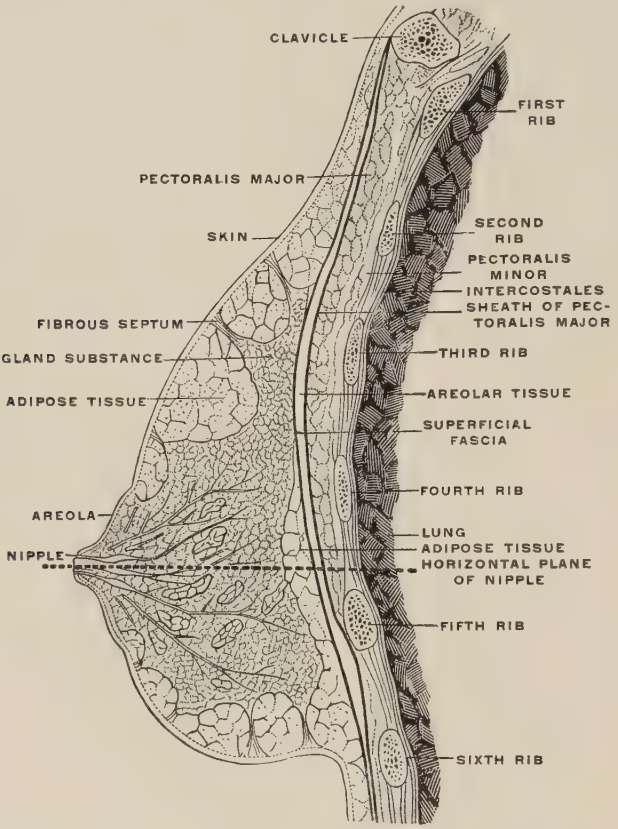

FIG. 957.—Right breast in sagittal section, inner surface of outer segment. (Testut.)

major, extending from the second to the sixth rib, and from the sternum to the border of the armpit. The location of the nipple is usually given as at the level

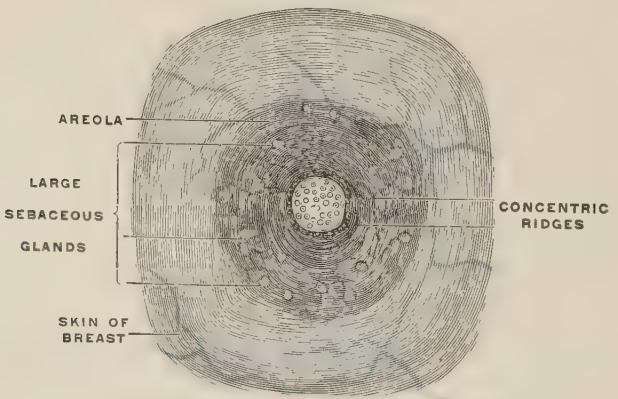

FIG. 958.—Nipple and areola of a virgin. (Testut.)

of the fourth rib; but its position is dependent upon various circumstances, such as age, pregnancy, lactation, corpulence, firmness of tissues, race, attitude of body,

(not to mention numerous diseases), so that it becomes one of the least trustworthy of landmarks.

The *weight* of the breast is usually above five ounces in the inactive condition.

The secreting structure of the breast consists of from ten to twenty separate lobes, each of which is a compound, racemose, acinous gland. Each of these glands is made up of lobules, which are colonies of alveoli, and has its own ultimate excretory duct, called *galactophorous* or *lactiferous* ("milk-carrying"). The ducts from all parts of the breast converge toward the nipple, and, when they reach the areola, each dilates into a *sinus* or *ampulla*, half an inch long and half as wide, which serves as a little reservoir for the milk. Beyond this the duct is reduced to a small calibre, and terminates at the summit of the nipple in a contracted orifice.

The alveoli and ducts are lined with a simple epithelium, partly flattened and partly cuboidal or cylindrical. The wall of the ducts is composed of mixed white and yellow fibrous tissues, arranged in longitudinal and circular bundles.

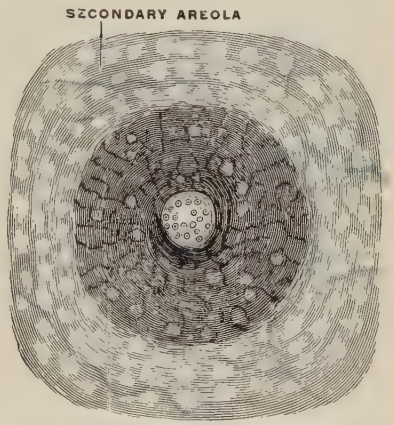

FIG. 959.—Nipple and areolæ of a pregnant woman. (Testut.)

The proper gland-substance is supported on a framework of the fibrous tissues, which also form an enclosing capsule for the organ. This capsule sends processes inward between the lobes and lobules, and processes outward to the deep surface of the skin. Among the masses of glandular material are many nodules of adipose tissue, which are of greatest size near the convex surface, though some considerable collections are found at the flat, hind surface of the gland. No fat, however, appears beneath the nipple and areola.

The *mammilla* is composed of skin, peculiarly modified, and containing the terminal portion of the milk-ducts. It is dark, wrinkled, beset with papillæ, which are extremely sensitive, but has no sweat-glands or hairs. It is very vascular, and among the vessels are many fibres of unstriped muscular tissue—an arrangement which gives it the properties of erectile tissue, so that under the stimulus of contact or even emotion, it may swell and become rigid. Its summit presents the orifices of the many lactiferous ducts.

The *areola* resembles the nipple in color and in structure, being pigmented and somewhat erectile. In addition it is dotted over with little, roundish projections, due to large, sebaceous glands in the skin, in connection with each of which is a delicate, minute hair.

Modifications.—In women who have not become pregnant the glandular tissue is but slightly developed (even though the breast may be plump and firm), and the nipple and areola are pink. But as early as the second month of pregnancy the color of these parts deepens, and may become dark brown, and the secreting structure begins to develop. A *secondary areola*, much fainter than the primary, may be observed encircling it. The breasts become very large and heavy *during the period of nursing*, but shrink when lactation is completed, and simultaneously the added pigment mostly disappears from the areola and nipple; but the delicate rosy hue of the virgin state is never restored. *After the menopause* the gland shrivels into a thin disc, incapable of function; but this diminution may not be outwardly manifest in the corpulent on account of the great accumulation of fat. *During menstruation* the breasts may swell, owing to sympathetic congestion. In some women the nipple does not project beyond the surface of the breast, and in certain cases it is even retracted, a dimple marking its situation. *In the male* the

mammary gland is rudimentary and minute. The nipple is small, and the areola presents a growth of rather strong hairs.

Very rarely women have *supernumerary mammæ*, thus imitating many of the lower animals. One case is recorded in which a woman had eight supplementary breasts, in addition to the usual pair. On the other hand there may be entire *failure of development* beyond the rudimentary condition. Very phenomenally the *male breast* ceases to be a mere rudiment, and becomes capable of furnishing milk.

Vessels and Nerves.—The *arteries* of the mamma are branches of the axillary, internal mammary, and intercostals. The *veins* correspond. The *lymphatics* run to the axillary nodes (primarily to the pectoral group, secondarily to the others) and to the sternal. The *nerves* are chiefly intercostal.

RELATIONAL ANATOMY.

By F. H. GERRISH.

IN the chapters on Systematic Anatomy much has been presented concerning the relations existing between the parts and organs described. It would doubtless be useful to have all of these statements gathered into a single section, but the prescribed limits of this work forbid such a course. The purpose of this chapter is to introduce certain matters which did not conveniently fall into line with any of the topics of Systematic Anatomy, to emphasize some of the most important points which have previously been made, and to show by methods, hitherto little employed, facts of interest and value concerning the structure of the body.

The chapter will be divided into three parts, each of which will be devoted to a different method of studying Relational Anatomy. In the first part will be presented a series of *plane sections* of the trunk and limbs; in the second part, reproductions of *photographs of the surface;* and in the third part, *skiagraphs* of every portion of the body, whose osseous structure can be profitably studied by the aid of the so-called X-rays.

However full may be the descriptions in such a chapter, its chief and essential value will always reside in the pictures; and those that are here given are so clear, and tell their own story so distinctly, that only a few words of introduction for each are needed, and the descriptive text can, therefore, be reduced to a minimum.

It is recommended that each of these pictures be studied in connection with everything else in the book which bears upon the subjects involved. For example, in considering the region of the forearm, the systematic anatomy of the bones, muscles, fasciæ, arteries, veins, lymphatics, and nerves of the part should be studied anew; next, the plane section should be examined with care, and the location of every organ fixed in mind; then the various photographs of the surface of the part should receive attention; and, finally, the corresponding skiagraphs should be regarded. By the combination of all these methods the student will be able to obtain all of the anatomical information of the locality that a text-book can afford.

I. PLANE SECTIONS.

In each of these pictures the upper surface of the lower segment resulting from the section is shown—in other words, the upper segment has been removed, and we look down upon the specimen. In the case of the sections of the limbs we may profitably imagine them to be the stumps of amputations of the opposite limbs at the same level—that is, they present such a view as would be given by the cut surface of the proximal part on the other side.

In the representations of sections of the trunk much lack of bilateral symmetry will be found, not only as concerns details, but also in the outlines of the figure. This is due to several causes. Perfect symmetry of contour on the opposite sides is practically unknown; the corresponding parts are rarely exactly

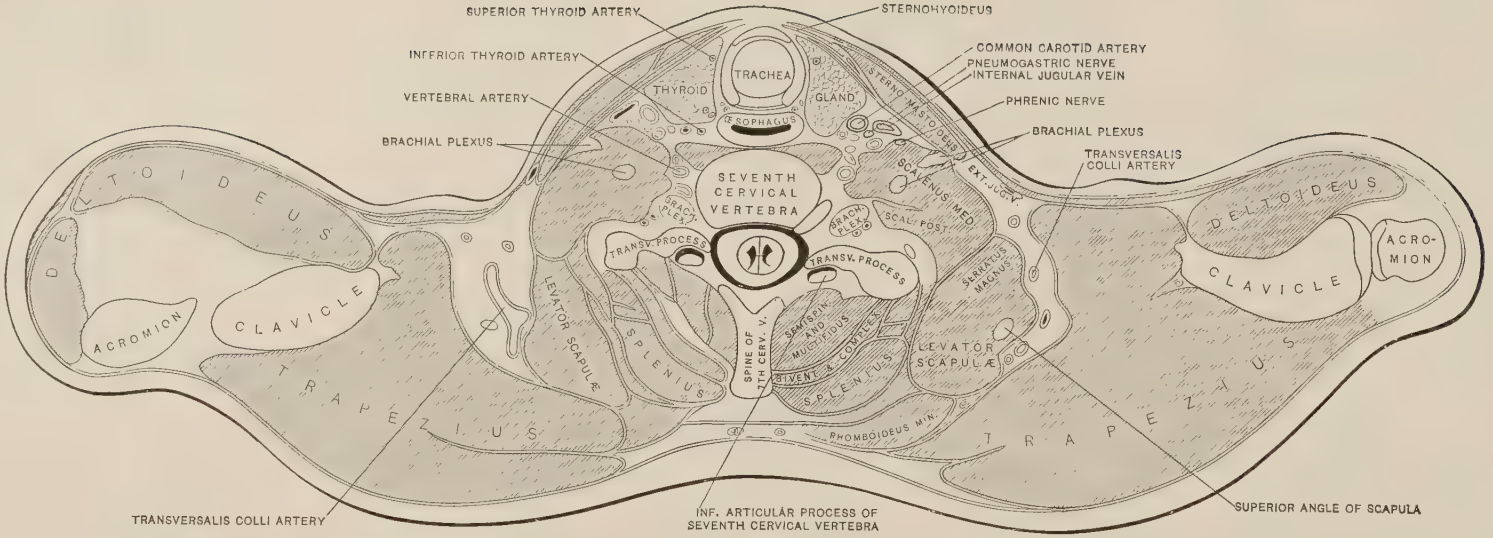

FIG. 960.—Horizontal section through the lowest part of the body of the seventh cervical vertebra, close to junction of neck and trunk. (After Braune.)

The upper cartilage of the trachea is cut, and on the front of it is a small part of the lower portion of the cricoid cartilage. The thyroid vessels are seen in and near the thyroid gland. The head of the first rib appears on the right side of the vertebral body. The transverse processes belong to the first thoracic vertebra. The muscle on the front of the body of the vertebra is the longus colli. The ventral, unlabelled part of the mass of scaleni, is the scalenus anterior. In front of the vertebral artery is the vertebral vein, and in front of the latter, on the right side, is the inferior cervical ganglion of the sympathetic. On each side, between the trachea and œsophagus, is the recurrent laryngeal nerve. The spinal accessory nerve is seen in the right trapezius, close to the clavicle; on the left side it is not drawn. On the right side the section has opened the acromio-clavicular joint; on the left it passes below it. The serratus magnus does not appear on the left. The brachial plexus is seen in three parts, ranged in a ventro-lateral line from the spinal cord.

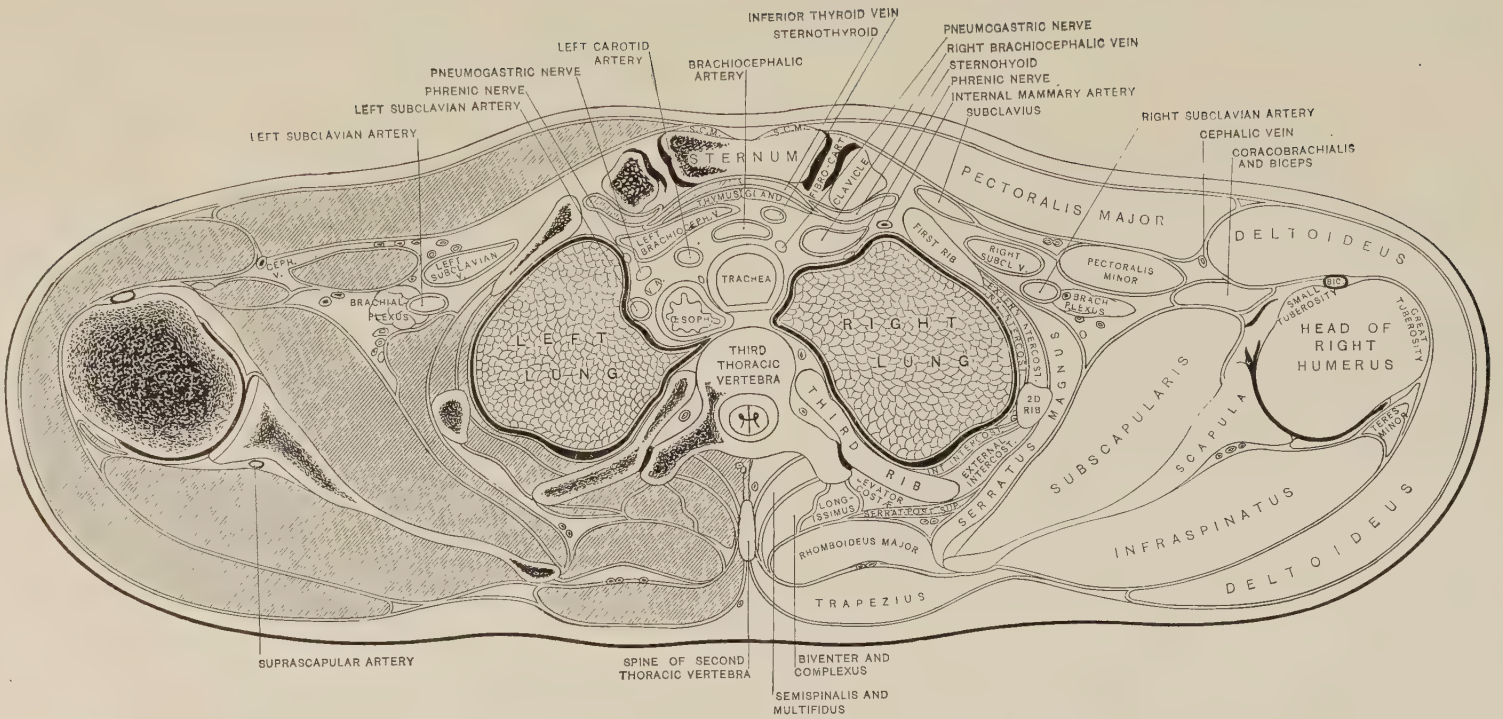

FIG. 961.—Horizontal section through the body of the third thoracic vertebra. (After Braune.)

S. C. M., sterno-cleido-mastoideus. V. A., vertebral artery. BIC., tendon of long head of biceps. The cut passes through the upper border of the sternum, the spine of the second thoracic vertebra, and the head of each humerus. Between the trachea and œsophagus is the left recurrent laryngeal nerve. Observe that the trachea is much further from the ventral surface than in Fig. 960. The brachio-cephalic artery is median, and obliquely at its left are the left carotid and left subclavian. The brachial plexus is in close relation to the subclavian artery. The apices of the lungs have been cut off.

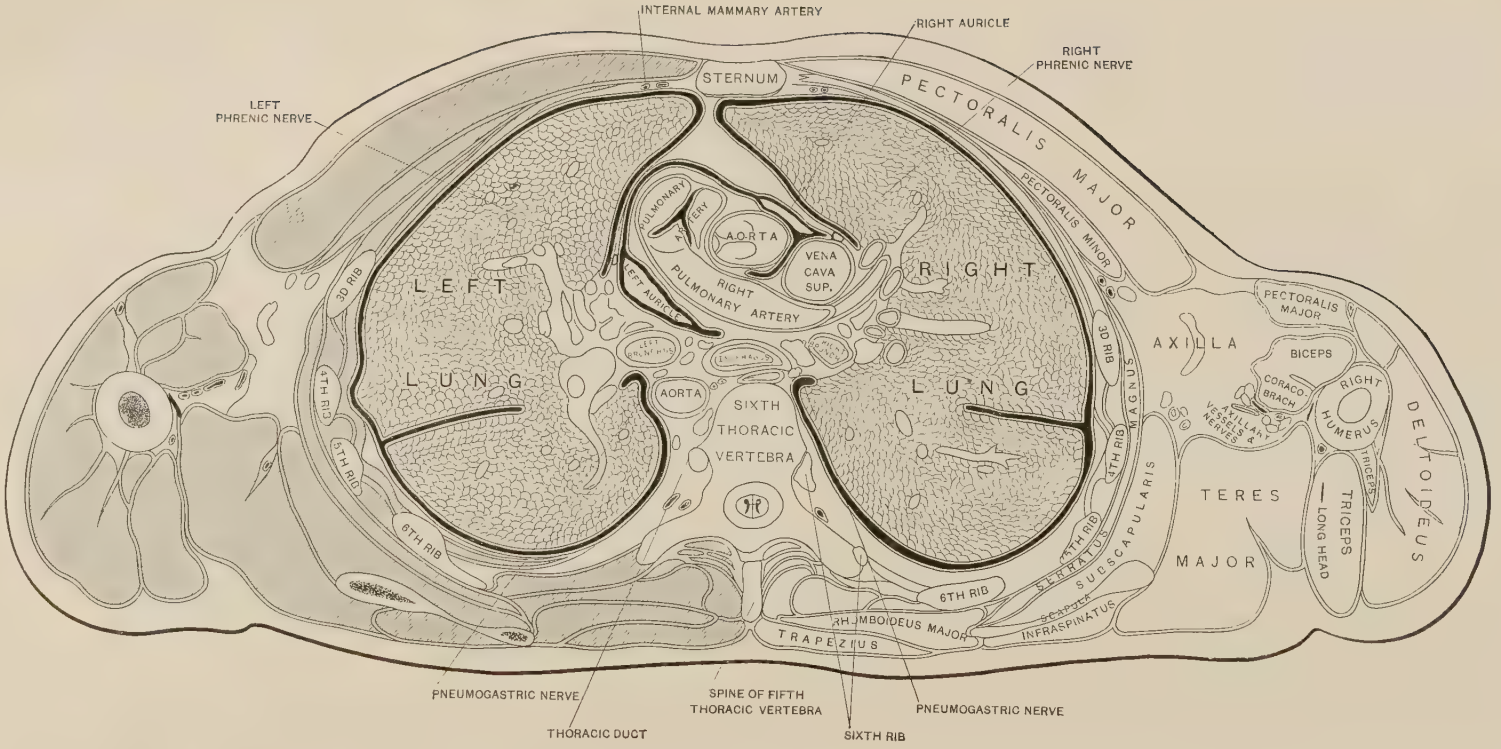

FIG. 962.—Horizontal section through the body of the sixth thoracic vertebra. (After Braune.)

The cut passes through the spine of the fifth thoracic vertebra, the body of the sternum, the humerus just below the tuberosities, and the scapula near the lower angle. The axilla, with its vessels and nerves, is opened. The lungs show their great fissure. The uppermost part of the heart has been removed, and we look down upon the pulmonary and aortic valves. Observe the pericardium and pleuræ; the descending aorta at the left of the vertebra; the thoracic duct (here double); and the pneumogastric nerves.

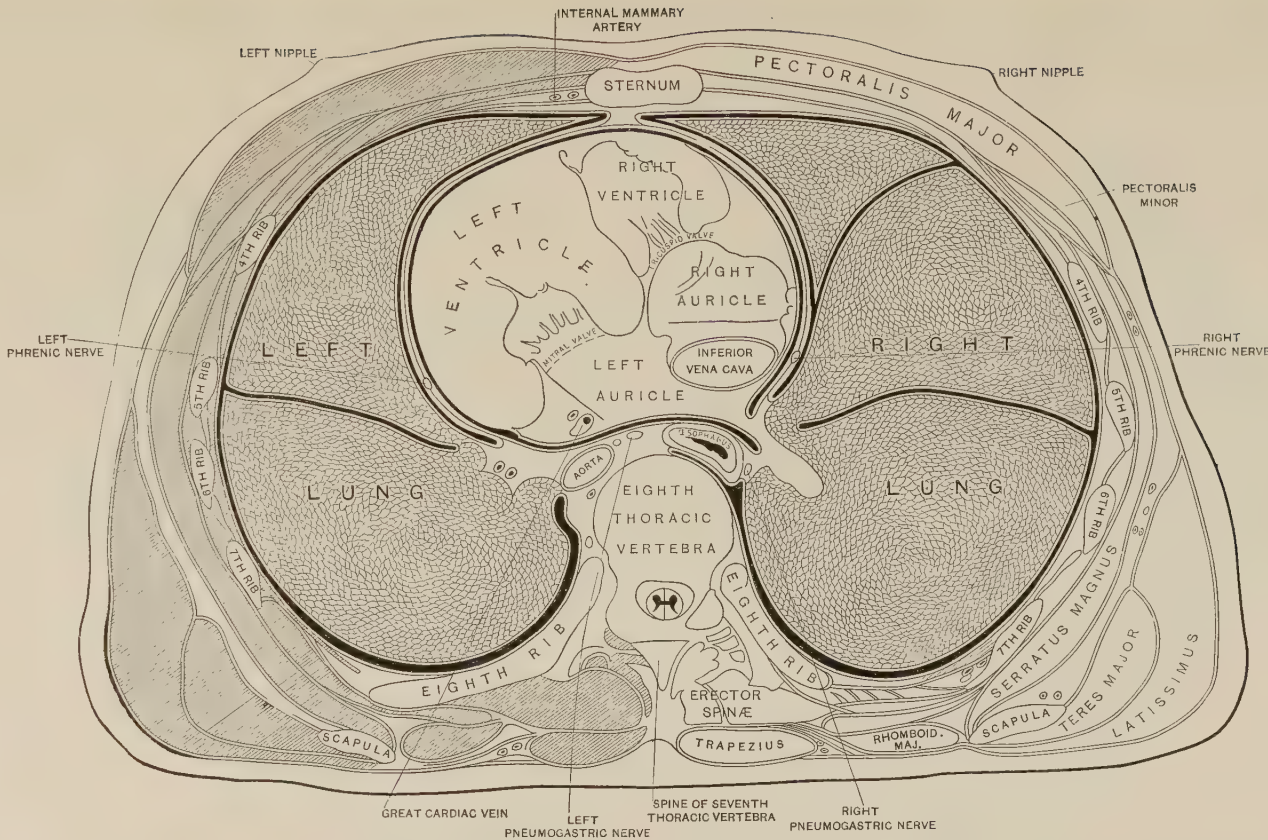

FIG. 963.—Horizontal section through the upper part of the body of the eighth thoracic vertebra. (After Braune.)

The heart has been cut so obliquely that the ventricular walls appear thicker than they are. The lungs present large surfaces, and both fissures appear in the right one. Observe the pericardium, pleuræ, and the position of the aorta and œsophagus. The section being below the axilla, the upper limbs no longer are seen.

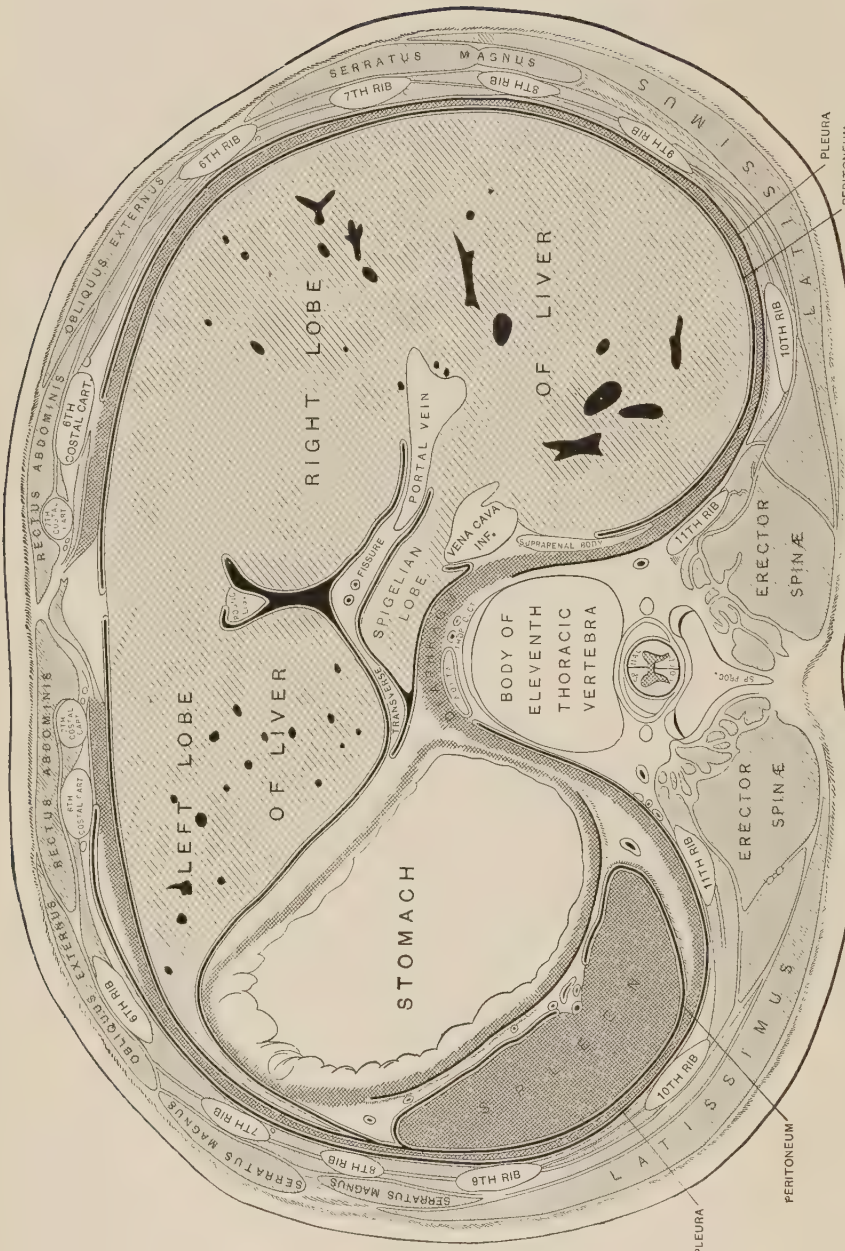

FIG. 964.—Horizontal section through the lower part of the body and arch of the eleventh thoracic vertebra. (After Braune.)

The diaphragm encircles the abdominal cavity, having peritoneum on its inner surface and the pleuræ on its outer. Observe the great space occupied by the liver, the relations of the stomach and spleen, the position of the right suprarenal body.

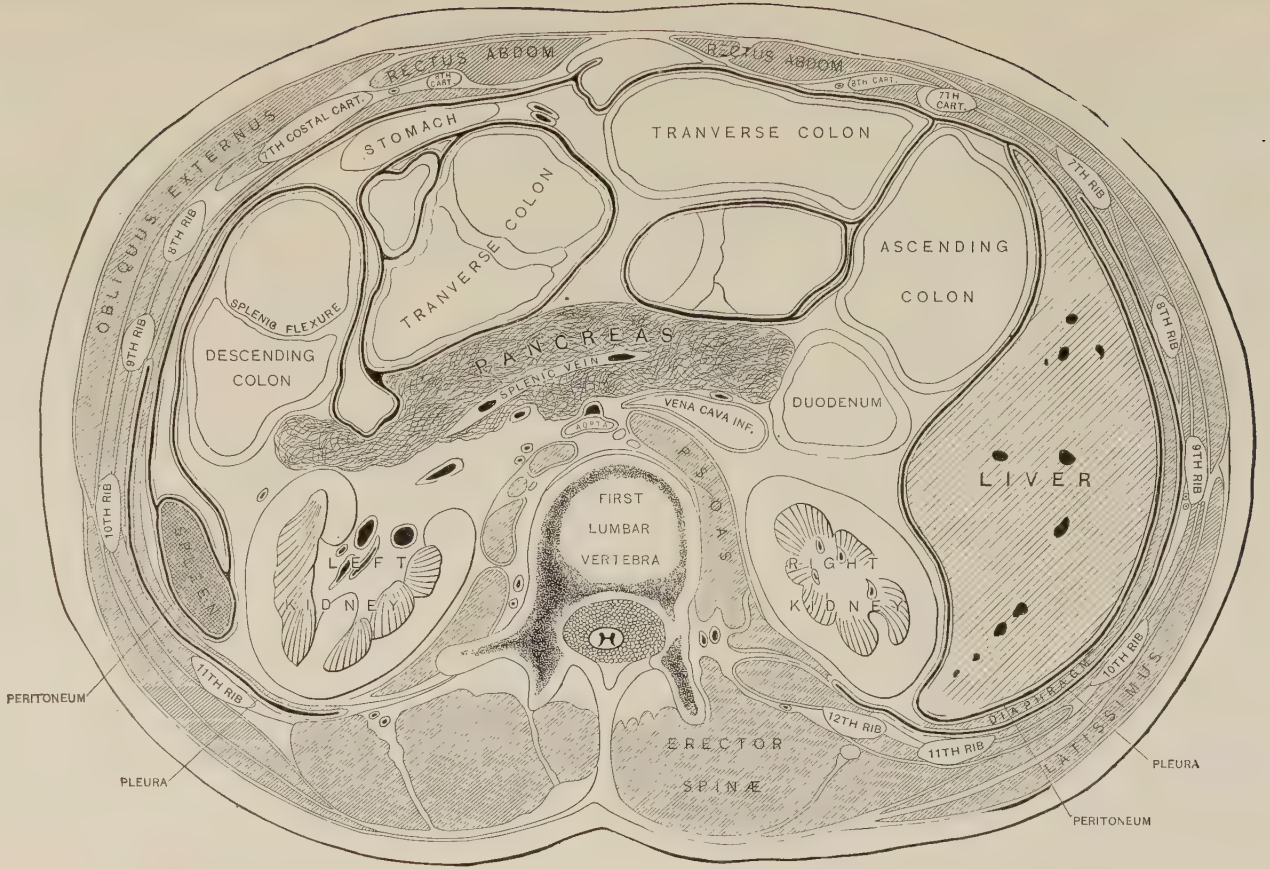

FIG. 965.—Horizontal section through the middle of the first lumbar vertebra. (After Braune.)

The twelfth rib appears on the right, but the section is below it on the left. Between the vena cava and the pancreas is the common bile duct. The lowest parts of pleura, liver, spleen, and stomach are seen. The pancreas is cut in its entire length. The right kidney is cut near its upper end, the left in the middle.

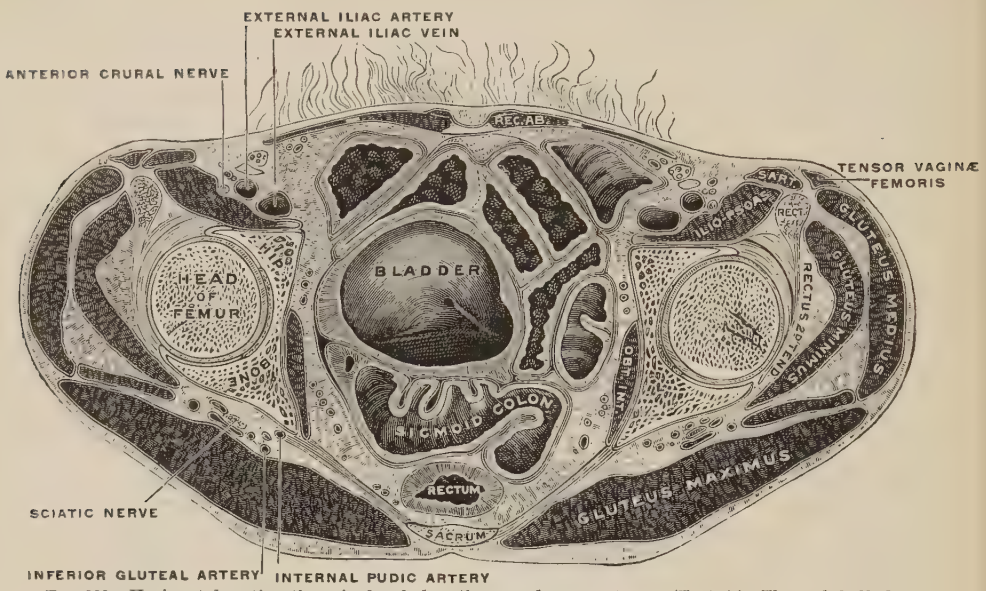

FIG. 966.—Horizontal section three inches below the sacral promontory. (Testut.) The unlabelled parts in front of and at the right of the bladder are coils of small intestine.

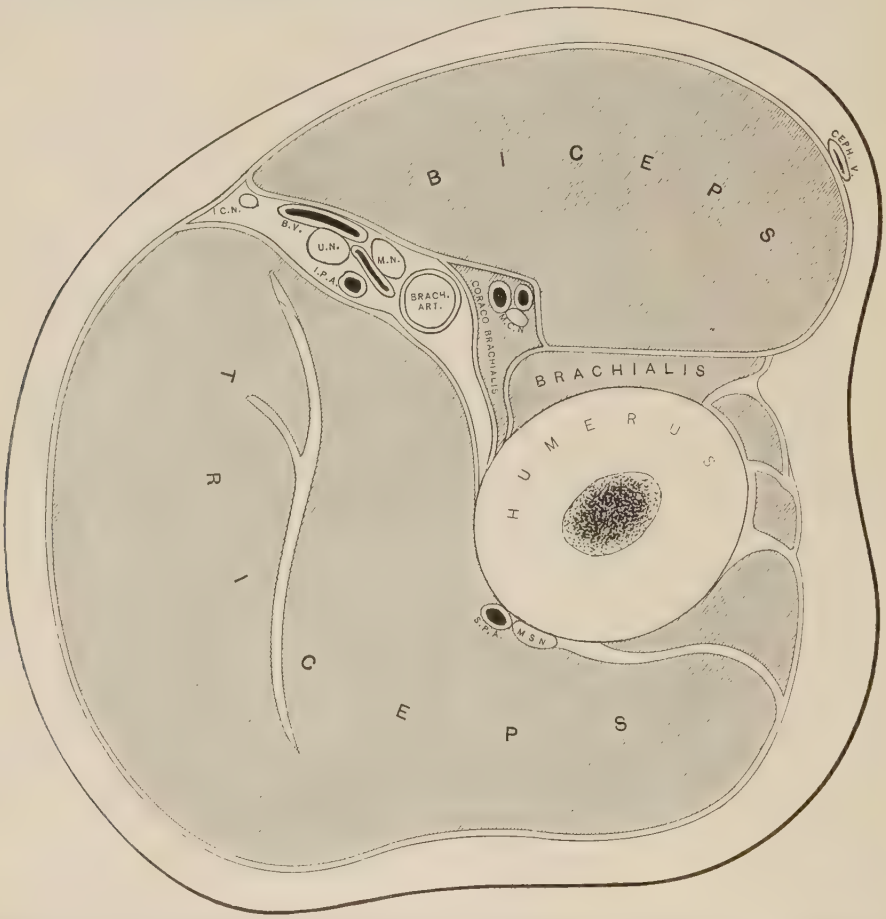

FIG. 967.—Horizontal section at middle of right arm—upper surface of lower segment. B. V., basilic vein; CEPH. V., cephalic vein; I. C. N., internal cutaneous nerve; I. P. A., inferior profunda artery; M. C. N., musculo-cutaneous nerve; M. N., median nerve; M. S. N., musculo-spiral nerve; S. P. A., superior profunda artery; U. N., ulnar nerve. (After Braune.)

mated; and, finally, it is almost impossible to carry the saw with absolute precision through all parts of the plane intended.

The subjects from which these sections were taken were particularly muscular young men, and the appearances differ considerably from those observed in poorly developed or emaciated people. This is very marked in the case of the shoulders, whose high appearance is at least partly due to the very pronounced muscularity.

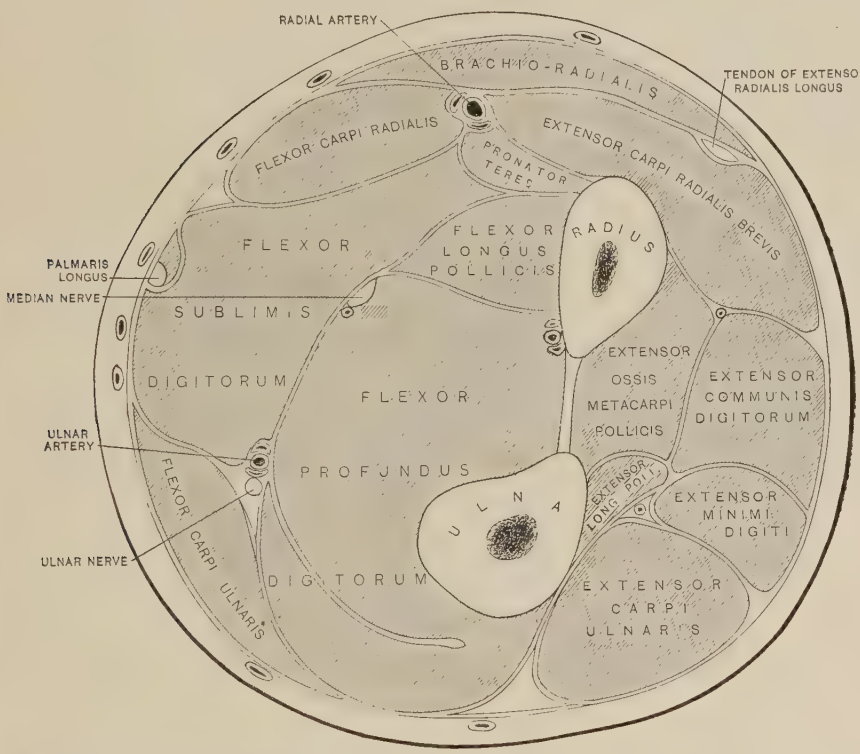

FIG. 968.—Transverse section through the middle of the right forearm, in the position of semipronation. (After Braune.)

In all of these drawings conventionalized shading is employed for the sake of clearness, and thus a somewhat diagrammatic effect is produced. But the purpose is to show relations, and not composition.

The serous and synovial (virtual) cavities are represented by heavy black lines. Only by some such exaggerated method can they be made distinct in plane sections.

Vessels and other tubes, when cut obliquely, present peculiar outlines; and these are more marked the more nearly the section is in line with the long axis of the cylinder.

In the cut surfaces of many muscles will be seen tendons embedded in their substance. This fact is referred to in the general considerations concerning myology, but was purposely omitted from the description of the individual muscles.

In some of the pictures which have substantially bilateral symmetry the parts are labelled on one side only.

The important parts are, as a rule, labelled; but in some cases this method was impracticable, and in these the legend will direct attention to the unlabelled objects.

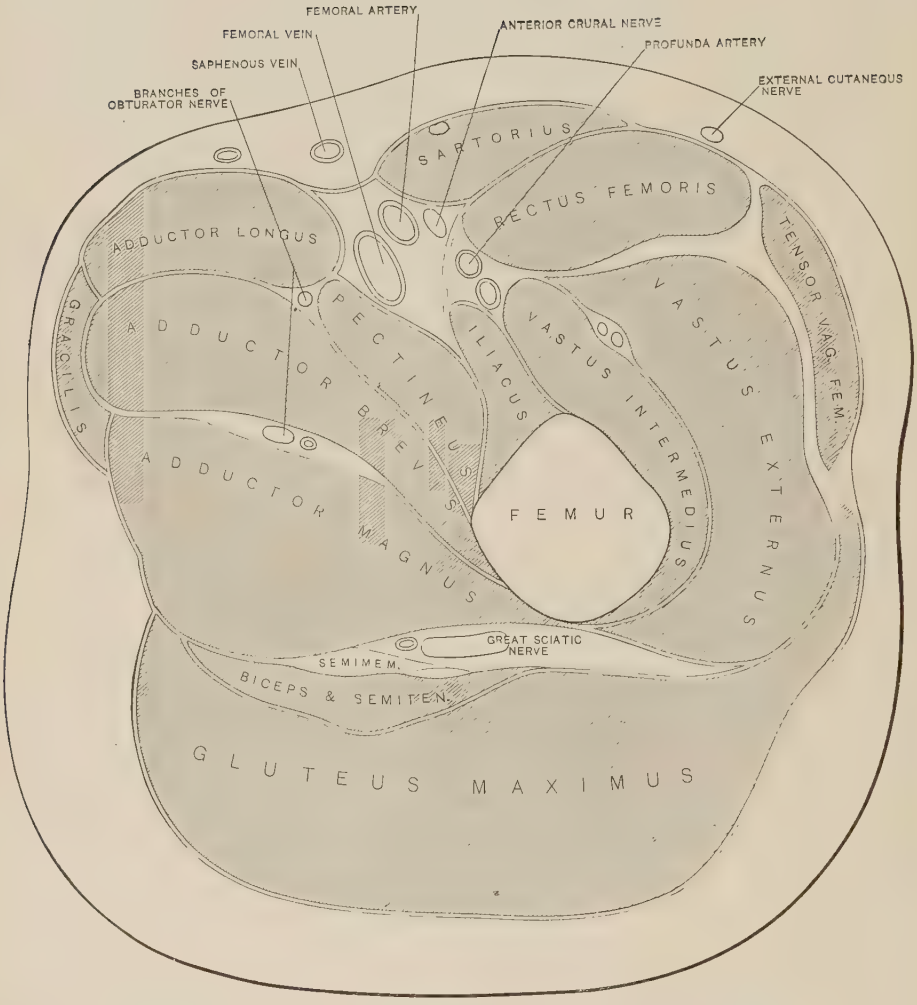

FIG. 969.—Transverse section of the thigh below the trochanter minor. (After Braune.)

FIG. 970.—Transverse section at the middle of the leg. (After Braune.) In front of the interosseous membrane are the anterior tibial vessels and nerve; in front of the soleus, the posterior tibial vessels and nerve; and close to the fibula, the peroneal vessels.

II. SURFACE ANATOMY.

The subject of the photographs, of which the series of pictures in this section are reproductions, was a young athlete of well-balanced development. It would be easy to procure representations of a man with much larger muscles, but they would be less useful in the illustration of normal anatomy. The main purpose of these engravings is to show the relations of structures, especially muscles, to the surface. The most of them are accompanied by keys, which more than supply the place of verbal description; in the remainder the principal features are sufficiently apparent without explanation other than occurs in the legend.

Every student is earnestly advised to study surface anatomy upon the living model. Each can use his chum for this purpose, if he will reciprocate such favors as he receives; and many things he can learn from his own person, particularly well in front of a large mirror. He should carry his studies in this direction much further than is attempted in this series of pictures, and in this effort he will derive all the help that he needs from the numerous cuts which embellish the pages devoted to descriptive anatomy.



Fig. 971.—The right upper limb abducted and supinated, viewed from in front.

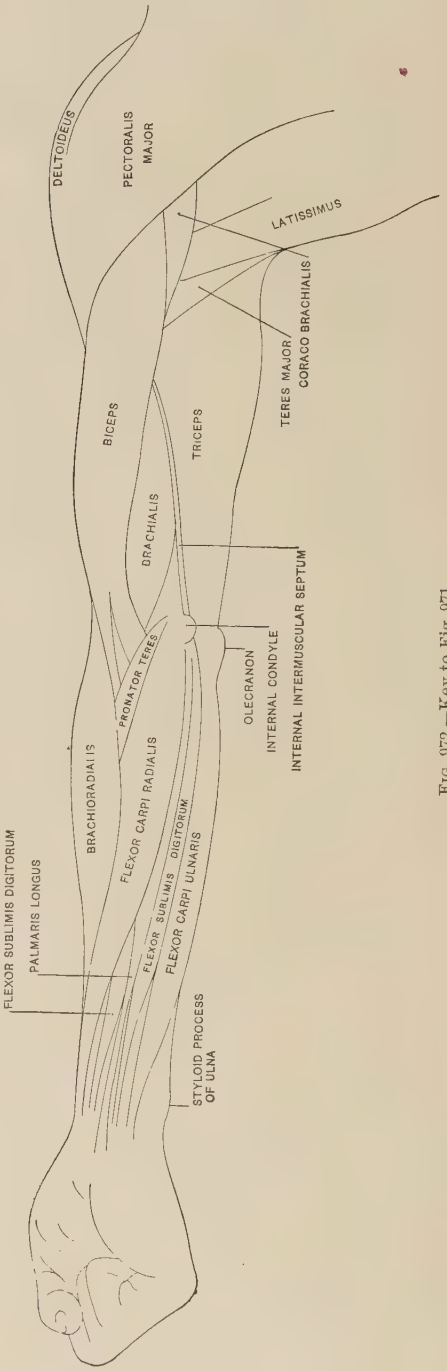

Fig. 972.—Key to Fig. 971.



FIG. 973.—The right upper limb abducted and pronated, viewed from in front.

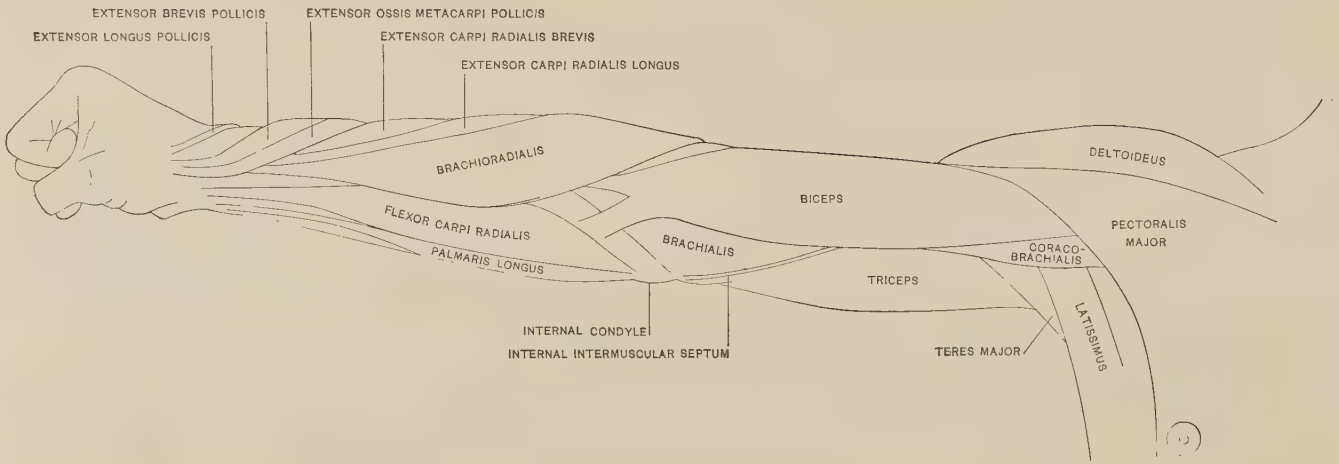

FIG. 974.—Key to Fig. 973.

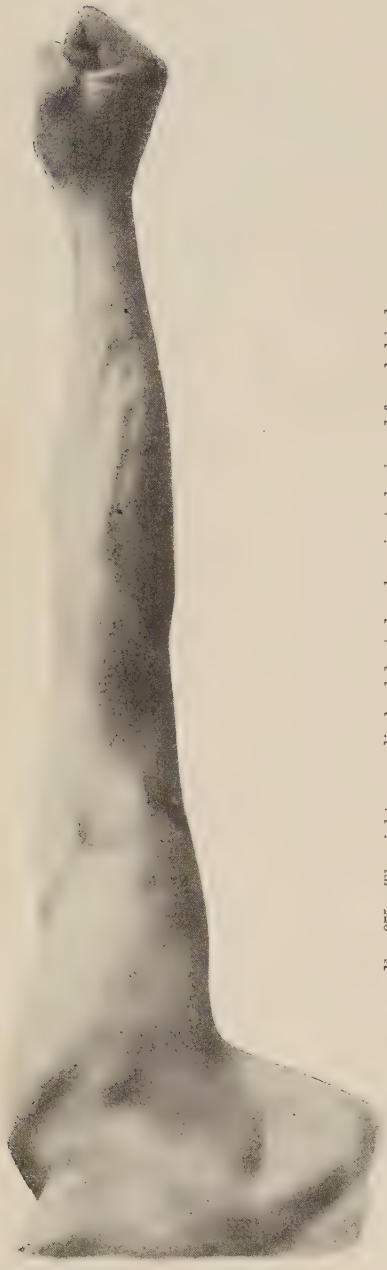

Fig. 975.—The right upper limb, abducted and supinated, viewed from behind.

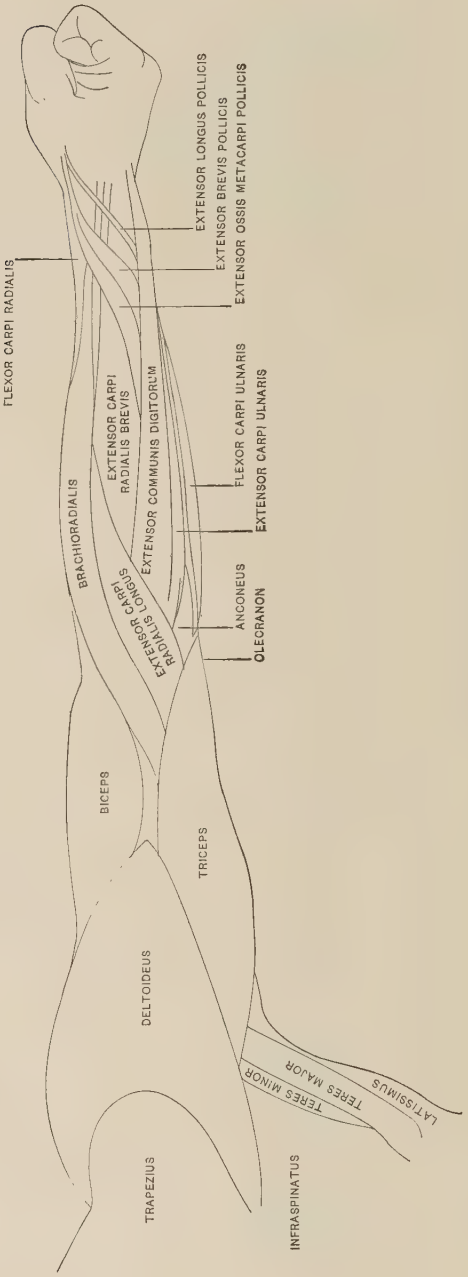

Fig. 976.—Key to Fig. 975.



Fig. 977.—The right upper limb, abducted and pronated, viewed from behind.

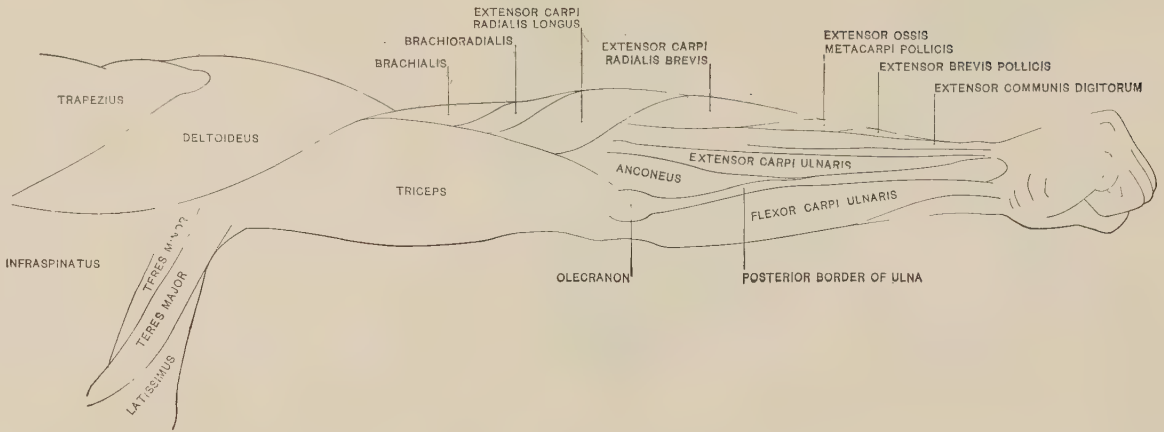

Fig. 978.—Key to Fig. 977.

FIG. 979.—Abduction of the arm with flexion of the forearm and digits.

Fig. 980.—The right lower limb, front view.

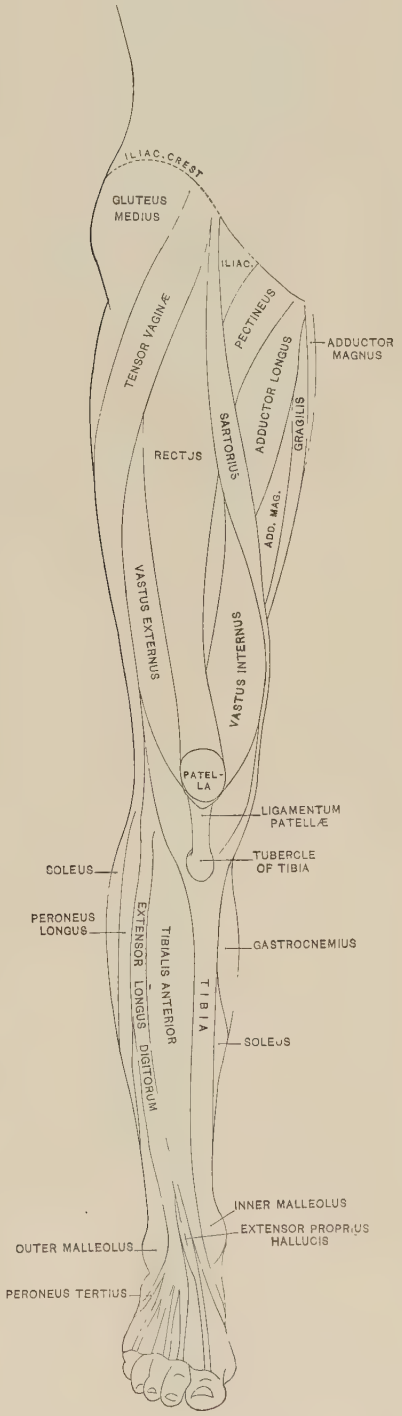

Fig. 981.—Key to Fig. 980.

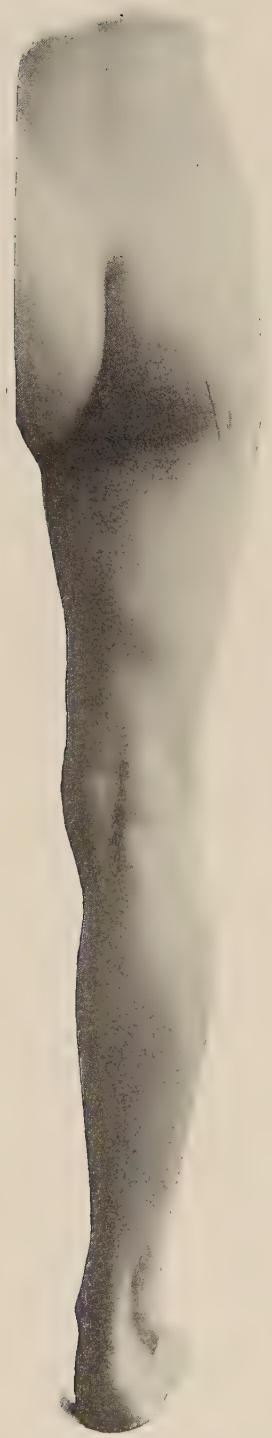

FIG. 982.—The right lower limb, rear view.

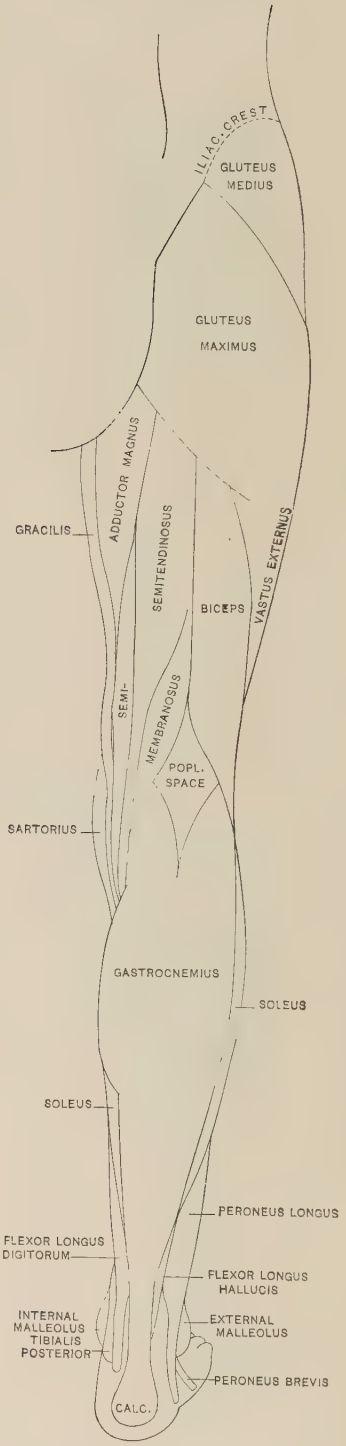

FIG. 983.—Key to Fig. 982.

FIG. 984.—The right lower limb, external lateral view.

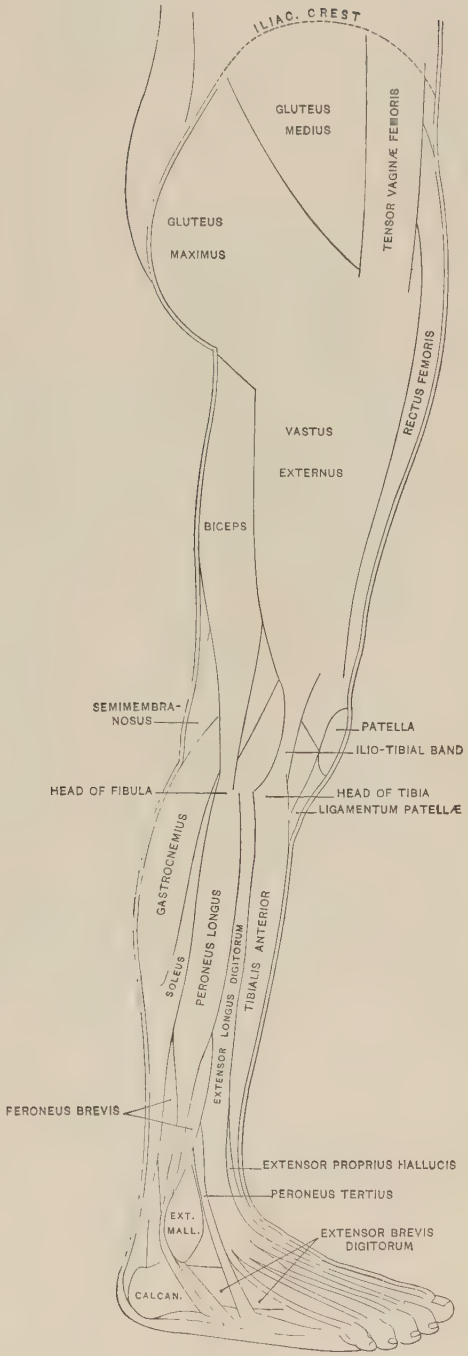

FIG. 985.—Key to Fig. 984.

Fig. 986.—The right lower limb, internal lateral view.

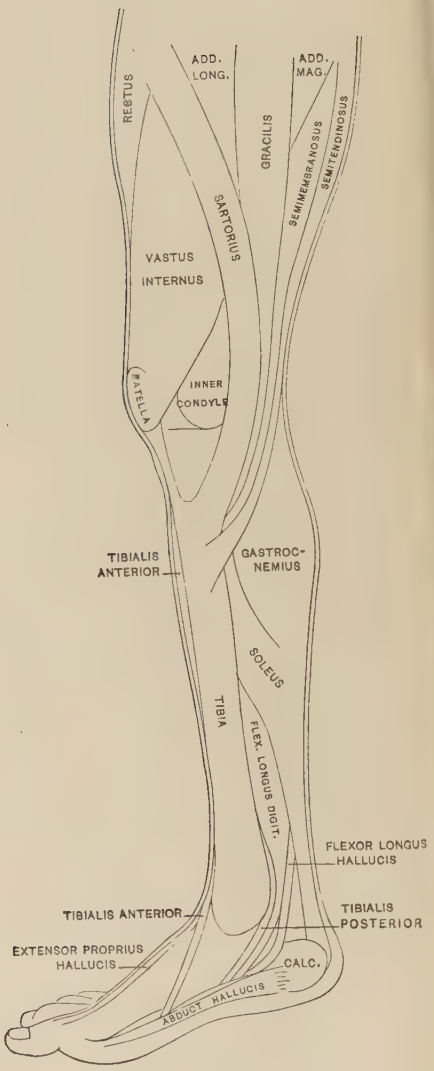

Fig. 987.—Key to Fig. 986.



FIG. 988.—Comparison of axillæ with the arm abducted and with the arm vertical. The latter attitude is seen to flatten and nearly to obliterate the pit.

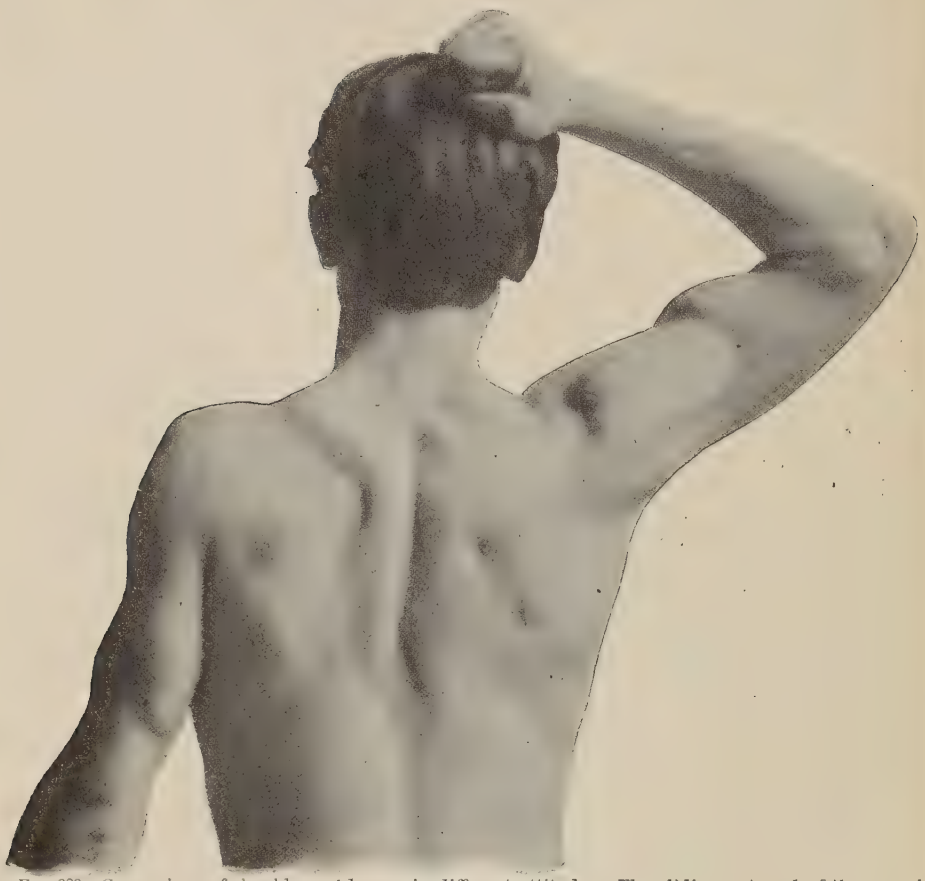

FIG. 989.—Comparison of shoulders and arms in different attitudes. The sliding outward of the scapula when the arm is raised is very marked.

FIG. 990.—The platysma muscle in contraction. The front and rear fasciculi can be brought out more prominently by forcible protrusion of the chin; but strong pressure of the forehead against a resisting object displays the whole muscle more evenly.

FIG. 991.—This figure and the next one are designed to show the capacity of the body for rotation. The feet point in one direction, the face exactly opposite. This was accomplished without previous practice.

FIG. 992.—To be compared with Fig. 991. The thighs and feet are held pointing away from the spectator, and the sitter has turned to face the camera as squarely as possible. If the effect obtained by this method be subtracted from that in Fig. 991, the amount of rotation below the movable vertebræ will be ascertained.

III. NORMAL SKIAGRAPHS.

A few years ago it was discovered that certain rays of light have the power of passing through substances which to ordinary rays are impenetrable. On account of their undetermined character they were called originally by the name of the letter which in algebraic formulæ indicates the unknown; and the title *x-rays* is still as well deserved as in the beginning. They are also called, from their discoverer, *Röntgen rays*.

The degrees of perviousness to these rays presented by different substances vary widely. Wood offers but little obstruction to their passage, glass cuts them off. Of the tissues of the body those containing lime salts stop the rays most completely; cartilage permits their passage with great readiness; and the other textures stand at various points between these extremes. The result is, that if a part of the body be suitably placed between an apparatus which generates these rays and a properly sensitized plate, shadows of the intervening structures which interfere with the rays will be cast upon the plate, and fixed there with different degrees of intensity. The plate is a negative from which photographic prints can be made, and these are called *skiagraphs* ("shadow-writings").

That this wonderful discovery could be turned to great advantage in surgery was immediately perceived, and its usefulness in the diagnosis of fractures and dislocations, and in the detection of certain foreign bodies, especially those which are metallic, in the tissues or cavities, has been abundantly demonstrated.

In order, however, to appreciate the existence and degree of the abnormal it is important to become familiar with the normal. Consequently, there are here presented skiagraphs of different portions of the body, pictures from more than one point of view being given wherever it seemed necessary to elucidate relational anatomy by this novel means. No skiagraph of the head is included, as it has not thus far been found practicable to determine anything useful anatomically from those which have been made.

In studying skiagraphs several considerations should be borne in mind, among which the following are prominent:

A more dense portion of a given tissue throws a deeper shadow than a less dense portion of the same. Thus, the expanded extremities of bones, largely composed of cancellated tissue, show lighter than the shafts, where the tissue is compact.

The thickness of the part influences the depth of the shadow. Thus, in a long bone the compact structure of the shaft gives a deeper shade at the sides than in the centre, not because the tissue is denser, but because, from a given point, the rays pass through a greater amount of it. (See the metacarpal bones in Fig. 997.)

An accumulation of tissue of the same or different kinds deepens the shadow. (See the condylar region in Fig. 996.)

The overlapping of one part by another causes a deepening of the shadow. (See the head of the radius and the coronoid process of the ulna in Fig. 996.)

As cartilage gives a ready passage to the rays, the ends of bones in movable joints seem separated by unoccupied spaces, except when a convexity of one bone is received into a concavity of another of sufficient depth to produce apparent continuity of osseous tissue; and epiphyses, not yet united to their diaphyses, are held off from them by obvious gaps.

The outline of a shadow does not necessarily represent the true size or shape of certain parts. For example, the outlines of the skiagraph of the heart, which is in constant active motion, and of the liver, which is in incessant passive motion, include greater areas than do the real shadows at any one moment of time. When such parts can be skiagraphed instantaneously, this objection will be removed.

FIG. 993.—The trunk, upper part. From a man of 28 years. The shadow of the heart and great vessels has an obscure outline, owing to their being in incessant motion. The vertebræ do not show plainly; they would be seen much more distinctly in a person in his teens. The lungs interfere very slightly with the passage of the rays.

FIG. 994.—The shoulder. From a man of 28 years. Observe the vertebral border of the scapula, faint because thin; its heavy, thick, axillary border; the coracoid process; the spine and acromion; the clavicle; the cartilaginous gap at the acromio-clavicular joint; the upper end of the humerus; the ribs; the vertebral column; and the intervertebral discs in the upper thoracic region.

FIG. 995.—The elbow-joint and adjacent parts, ventro-dorsal view. From a man of 28 years.

Fig. 996.—The arm and forearm, side view. From a man of 28 years. The forearm is in semipronation. Observe the dense shadows where the head of the radius and coronoid process of the ulna overlap, and where the condyles are most prominent.

FIG. 997.—The hand. From a man of 53 years. Observe the sesamoid bone at the metacarpo-phalangeal joint of the thumb; the different thickness of the folds of skin in the web between the thumb and index-finger; and the faint shadow of the nails, plainest in the ring-finger.

FIG. 998.—The lower part of the trunk and the upper part of the thighs. From a boy of 15 years. Observe the sacral foramina and intervertebral spaces. The hip-bones show with great distinctness. The penis is turned to one side.

FIG. 999.—The hip-joint and surrounding parts. From the same skiagraph as Fig. 998. The interference of overlapping parts of bone, the thinness of the ilium in the fossa, and the apparent deficiency between the caput femoris and the acetabulum deserve attention.

FIG. 1000.—The knee, ventro-dorsal view. From a man of 28 years. The tibia and fibula overlap.

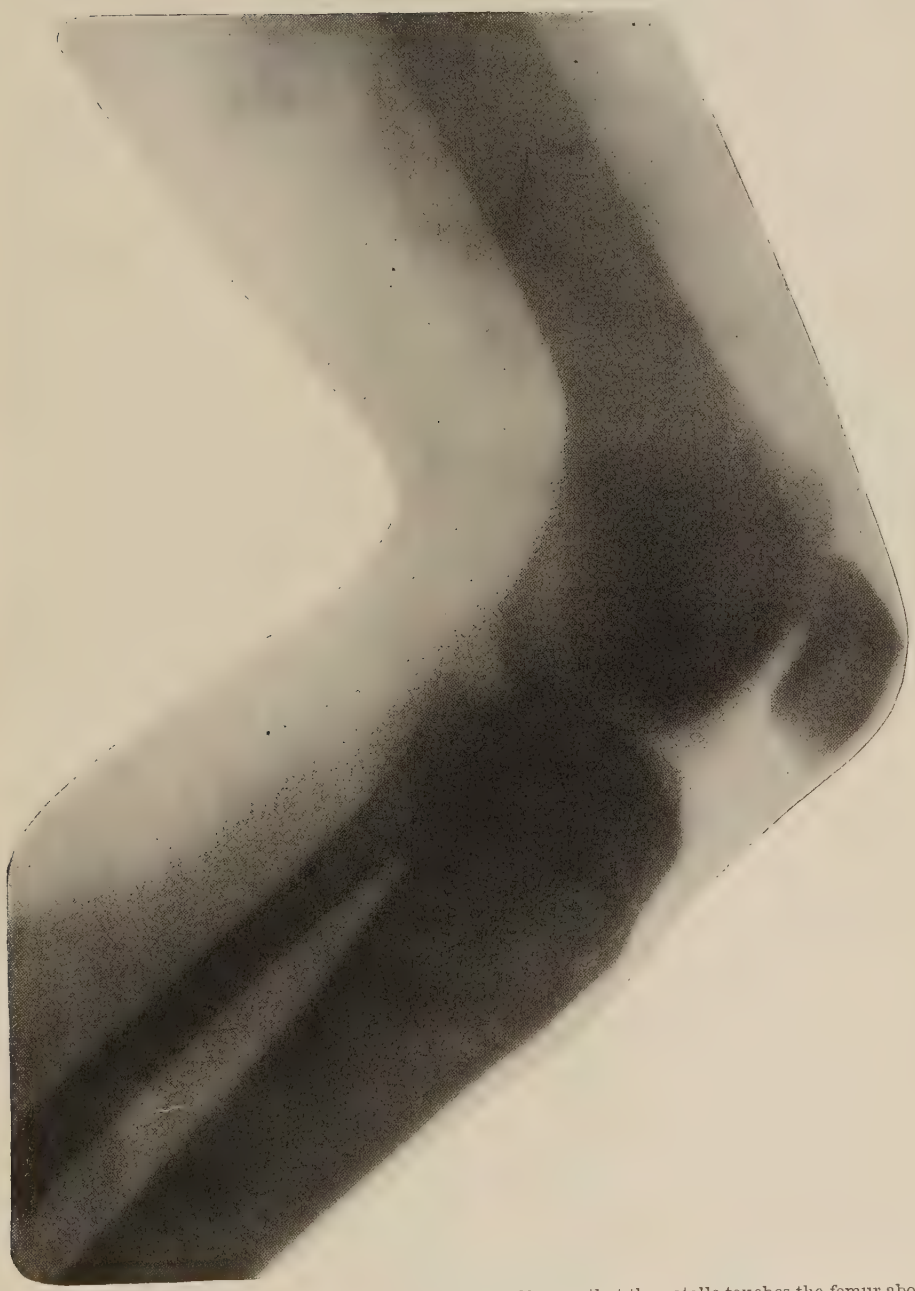

FIG. 1001.—The knee, side view. From a man of 28 years. Observe that the patella touches the femur above, but seems to stand away from it below. The ligamentum patellæ makes a slight appearance.

FIG. 1002.—The foot in full extension, dorso-plantar view. From a man of 21 years. The first and fifth toes are deformed by the wearing of pointed shoes. The deep shadow about the ankle-joint is due to the great thickness of the bony mass.

FIG. 1003.—The foot, side view. From the same man as Fig. 1002. Every bone is more or less overlapped by some other.

PRACTICAL ANATOMY.

By F. H. GERRISH.

IT is the purpose of this final chapter to give directions concerning the conduct of dissections.

Preparatory Study.—There is but little profit in attempting a dissection until one has become familiar with the appearance of the parts involved, and has learned the chief facts concerning their structure. This acquaintance should be gained by careful study of their descriptive anatomy, and by frequent inspection and handling of well-dissected parts, prepared for this very purpose of preliminary drill. Without such equipment it is impossible to follow fully the admirable precept of Oliver Wendell Holmes—"Let the eye go before the hand, and the mind before the eye."

Cooperation in Work.—The men who are dissecting on the same subject should work harmoniously. A spirit of accommodation is essential, for it is necessary that the attitude of a part and even of the whole cadaver should be changed at times, and occasionally this circumstance will oblige a student to alter his order of work temporarily, or even to suspend it altogether for a while. Those whose parts of the subject have a structural continuity or adjacency will sometimes work to best advantage at different hours.

The Taking of Pains.—All work should be done with care and deliberation. Patience and intelligence are essential to good results. Hurry is not only wasteful, but ineffective. The number of days which should be spent upon a stated part is not here prescribed, because competent men work with different degrees of speed. The task is soon enough done, when it is well enough done.

Cleaning Organs.—"The art of dissection consists in the complete removal of this [areolar] tissue from around the other structures, so as to expose the parts enwrapped therein" (Macalister). When the meshes of areolar tissue are occupied by cells of fat, dissection is much more difficult, and the result is less satisfactory. Consequently, when a choice is possible, a subject should be selected which is lean.

Every part as it comes to view should be cleaned thoroughly—that is, freed from enveloping areolar tissue.

In doing this, the cuts of the knife should be parallel with the fibres of the part, if it be muscle, nerve, or fascia; in the direction of its long axis, if it be a vessel.

The vessels and nerves should be cleaned from large trunks to small.

Finish the cleaning of one fasciculus or vessel before attempting another.

In dissecting fine vessels and nerves, the point of the scalpel may be used to advantage; but in the dissection of muscles it is ordinarily advisable to employ the belly of the blade, making long, sweeping cuts. In this way greater smoothness of dissection is obtained.

Whatever the part, it should be made tense before dissection. In the case of muscles the requisite tension may be gained by position; but in the case of a muscle whose fibres run in various directions, it is necessary to place the part in a different attitude for each of them. Blocks of wood, variously adjusted between

the thorax or abdomen and the table, assist greatly in this matter. Nerves may be made taut by the use of the hooks and chains.

Further Directions.—The under surface of a muscle should always be examined carefully to observe the arteries, veins, nerves, and deep attachments.

Every tendon should be followed to its attachment.

In cutting through a muscle in order to remove or reflect it, care must be taken not to injure a subjacent part.

If a muscle is to be reflected, it should, as a rule, be divided in the middle.

When a group of muscles is to be reflected, each should be cut at a different level from the others, as replacement can thus be accomplished more readily and accurately.

Handle parts delicately. Rough manipulation hurts them, especially the bellies of muscles. Forceps tear muscular fibres, and leave a ragged surface; fingers injure them very little, and should always be used, when practicable.

Do not finally remove any part until obliged to do so in order to reach underlying structures. By keeping parts attached a long time, opportunity is afforded for many repeated examinations.

Prevention of Drying.—Every part should be kept a little moist (but not soaked) with some antiseptic liquid. One can learn something, perhaps a good deal, from a decaying organ; nothing from a part which has been allowed to dry.

One of the best preparations for this purpose is composed as follows: Alcohol 30 per cent., glycerine 10, carbolic acid 2, and water 58.

Clearing up after Work.—After the day's dissecting is done, the dissected organs should be slightly moistened with the above fluid, and adjusted as nearly as possible in their natural relations; the edges of the skin should be fastened with a continuous suture; and the whole wrapped in cotton cloth which has been wetted with the same solution. Finally, it is desirable that the entire subject should be covered with a sheet of rubber cloth. If care is taken along these lines, a dissection may be continued a number of weeks without discomfort or offence.

The skin of a part should be saved until the dissection is completed, because it is the best covering. The original incisions should be so made as to leave large flaps of skin, as these are more easily managed.

Disposal of Waste.—As regards the disposal of waste materials: all fluids from the subject should be turned into the waste-pipe connected with the sewer; small fragments should be deposited upon a piece of paper, and the collection from each day's work placed in a box provided for the purpose, which should also receive the large masses, as they are removed. The ultimate disposition of the material will be regulated by the rules of the institution, and may be left to the janitor.

Care of the Hands.—Chaps or abrasions on the hands of the dissector should be protected by small bits of court-plaster, over and around which a coating of flexible collodion is applied. When the hands are to be brought extensively in contact with the viscera, it is well to anoint them with vaseline or some other oil.

Treatment of a Dissection Wound.—If a wound is received from a dissecting instrument or a spicule of bone, it should be encouraged to bleed by holding it in the stream from the hot water faucet, and then sucking it vigorously, so that the poison may be removed before it has a chance to be absorbed. The danger of infection from the dissection material usually provided in our schools is very small, if reasonable precautions are observed.

Cleanliness of Clothing.—In preparation for dissection the student should either clothe himself in an old suit, which thereafter will be used for no other purpose, or else cover his ordinary raiment with a dissecting gown, which reaches nearly to his feet and is gathered in at the wrists. If consideration for his own cleanliness and comfort is not sufficient to suggest some such procedure, a decent regard for the rights of others will forbid his mingling with people of common

sensitiveness with a coat which is in any degree contaminated by contact with dissecting material, however well preserved the latter may be.

Avoidance of Publicity.—The beginner in practical anatomy is usually so impressed with the novelty and interest of his work that he talks about it when among non-medical people, forgetting that to many of them the mention of such topics is offensive. In the interest of his own standing and of the repute of the profession he would far better maintain the strictest reticence in all such matters.

Dissect Often!—Finally, in way of general advice, the student is counselled to lose no opportunity to dissect, bearing in mind that the most accomplished anatomists never consider themselves so perfect in their knowledge that they cannot learn something by another dissection.

Implements Needed.—The following instruments the student should provide himself with: a *large scalpel*, a *small scalpel*, both with the cutting edge markedly convex, a *cartilage knife*, a pair of *scissors*, best curved on the flat, a *dissecting forceps*, a *tenaculum*, a *pair of hooks* connected by a chain, a *grooved director*, a small *blow-pipe*, and a foot of rubber-tubing to fit onto the large end, and a large *straight needle*. The chisel, saw, and hammer, which he will need at times, are a part of the furnishings of the dissecting-room. Additionally he should procure some coarse thread for sewing the skin over the dissection at the close of the day; a pint of the preservative mentioned elsewhere in these directions; a piece of cotton cloth, large enough to enwrap his part of the subject; an ounce of vaseline for his hands; and a good hone and strop for sharpening his knives—the strop never to be employed for other instruments after having been used for dissecting scalpels. He would do well to have his own cake of soap, nail-brush, and towels, for manifest reasons.

The instruments, especially those for cutting, should be of excellent quality. There is no economy in buying inferior tools.

After the day's dissecting is done, every instrument which has been used should be scrupulously cleansed, dried, and made ready for the next session. The hands should be washed with hot water and soap, particular attention being bestowed upon the nails.

DIVISION OF THE CADAVER.

The number of parts into which the body is divided for dissection purposes varies greatly in different schools; but the method of presentation here adopted will readily lend itself to any division which may be preferred.

The organs in a given region are mentioned in the order in which they are encountered in dissecting. The name of each is followed by a numeral which refers to the page of this book upon which it is described, with the exception that a few of the references direct attention to pictures, which are especially serviceable in dissecting, and from which the verbal descriptions can readily be turned to.

Many parts are entered more than once in the enumerations, because they occur in two or more regions.

The small branches of arteries are not generally given, as they will naturally attract attention in connection with the trunks from which they spring. The same omission is commonly made in the case of veins which are companion to arteries of the same name. Reference to a viscus is intended to include its parts, as ducts, vessels, etc.

It is assumed that the dissection is done under the personal supervision of a competent demonstrator, who will prescribe the order in which parts are to be taken, and will give all necessary instructions as to the best method of making primary incisions, reflecting and removing parts, and displaying whatever requires demonstration—points upon which equally competent teachers differ—and, therefore, specific directions on such matters are not here given.

THE THORAX AND UPPER LIMB.

Platysma, 351.
Cutaneous nerves, 624, 638, 640.
Mammary gland, 843.
Cephalic vein, 484.
Acromiothoracic artery, 427.
Deep fascia, 369, 370.
Pectoralis major, 274.
Axillary space, 426.
  Lymph-nodes, 508.
  Axillary vein, 484.
  Axillary artery, 426.
  Brachial plexus, 625.
Pectoralis minor, 270.
Costocoracoid membrane, 370.
Subclavius, 271.
Serratus magnus, 270.
Posterior thoracic nerve, 626.
Intercosto-humeral nerve, 639.
Intercostales externi, 349.
Intercostales interni, 350.
Intercostal nerves, 638.
Intercostal arteries, 425, 441.
Internal mammary artery, 424.
Superior epigastric artery, 424.
Musculophrenic artery, 424.
Sternal lymph-nodes, 510.
Triangularis sterni, 350.

Thoracic Cavity.

Pleuræ, 788.
Anterior mediastinal lymph-nodes, 510.
Lungs, 785.
Roots of lungs, 786.
Phrenic nerve, 624.
Pericardium, 393.
Thymus, 822.
Brachio-cephalic veins, 471.
Superior vena cava, 470.
Inferior vena cava, 488.
Heart, 385.
Coronary arteries, 405.
Cardiac veins, 469.
Cardiac nerves, 614, 662, 663.
Pulmonary artery, 400.
Aorta, 401.
Brachio-cephalic artery, 405.
Left common carotid artery, 406.
Left subclavian artery, 420.
Trachea, 779.
Bronchi, 780.
Pneumogastric nerves, 611.
Recurrent laryngeal nerves, 613.
Gullet, 731.
Branches of thoracic aorta, 441.
Thoracic duct, 502.
Superior mediastinal lymph-nodes, 510.
Gangliated cord of the sympathetic, 663.
Azygos veins, 485.
Posterior mediastinal lymph-nodes, 510.
Diaphragma, 348.
Costo-vertebral articulations, 223.

Front of the Arm.

Cutaneous nerves, 636.
Superficial veins in arm and at bend of elbow, 482.
Epicondylar lymph-node, 509.
Deep fascia, 371.
External and internal intermuscular septa, 371.
Brachial artery, 429.
Venæ comites of brachial artery, 484.
Internal cutaneous nerves, 631.
Median nerve, 627.
Ulnar nerve, 631.
Musculo-cutaneous nerve, 627.
Biceps, 277.
Coracobrachialis, 274.
Brachialis, 278.

Front of the Forearm.

Superficial veins, 482.
Cutaneous nerves, 636.
Deep fascia, 371.
Intermuscular septa, 372.
Pronator teres, 281.
Flexor carpi radialis, 283.
Palmaris longus, 283.
Flexor carpi ulnaris, 283.
Radial artery, 435.
Flexor sublimis digitorum, 287.
Radial and posterior interosseous nerves, 635.
Ulnar artery, 431.
Interosseous arteries, 433.
Median nerve, 627.
Flexor profundus digitorum, 288.
Flexor longus pollicis, 296.
Pronator quadratus, 281.

The Palm.

Palmaris brevis, 299.
Cutaneous nerves, 636.
Anterior annular ligament, 372.
Palmar fascia, 372.
Synovial sheaths of tendons, 373, 374.
Superficial palmar arch, 435.
Ulnar nerve, 631.

Median nerve, 627.
Abductor pollicis, 298.
Flexor ossis metacarpi pollicis, 295.
Flexor brevis pollicis, 296.
Adductor pollicis, 298.
Abductor minimi digiti, 293.
Flexor brevis minimi digiti, 289.
Flexor ossis metacarpi minimi digiti, 289.
Lumbricales, 290.
Deep palmar arch, 438.
Interossei palmares, 294.

Back of Thorax and Upper Limb.

Deep fascia, 371.
Trapezius, 267.
Latissimus, 275.
Omohyoideus, 351.
Rhomboideus minor, 269.
Rhomboideus major, 269.
Deltoideus, 272.
Circumflex arteries, 428.
Circumflex nerve, 632.
Teres major, 275.
Supraspinatus, 274.
Infraspinatus, 275.
Teres minor, 275.
Subscapularis, 277.
Suprascapular artery, 425.
Suprascapular nerve, 626.
Dorsal scapular artery, 428.

Back of the Arm.

Deep fascia, 371.
Cutaneous nerves, 637.
Triceps, 279.
Musculospiral nerve, 633.
Superior profunda artery, 430.
Ulnar nerve, 631.
Anastomotica magna and anastomoses around elbow, 430, 433.

Back of the Forearm.

Cutaneous nerves, 635, 637.
Deep fascia, 371.
Aconeus, 280.
Brachioradialis, 279.
Extensor carpi radialis longus, 283.
Extensor carpi radialis brevis, 284.
Extensor communis digitorum, 291.
Extensor minimi digiti, 292.
Extensor carpi ulnaris, 284.
Extensor ossis metacarpi pollicis, 296
Extensor brevis pollicis, 296.
Extensor longus pollicis, 296.
Extensor indicis, 292.
Posterior interosseous artery, 433.
Posterior interosseous nerve, 635.
Supinator, 282.

Back of the Hand.

Radial artery, 437, 439.
Posterior annular ligament, 372.
Digital extensors, tendons, 290.
Posterior interosseous nerve, 635
Interossei dorsales, 292.
The articulations of the upper limb:
- Sterno-clavicular joint, 228.
- Scapulo-clavicular joint, 229.
- Shoulder joint, 230.
- Elbow joint, 233.
- Wrist joint, 236.
- Joints in the hand, 237–239.

THE ABDOMEN AND LOWER LIMB.

The Abdomen.

Superficial fascia—two layers, 365.
Lymph-nodes in groin, 509.
Cutaneous nerves:
- Anterior cutaneous, 640.
- Lateral cutaneous, 640.
- Ilio-hypogastric, 642.
- Ilio-inguinal, 643.
- Last thoracic, 640.

Superficial pudic arteries, 456.
Superficial epigastric artery, 456.
Superficial circumflex iliac artery, 456.
Obliquus externus, 346.
Linea alba, 345.
External abdominal ring, 346.
Inguinal ligament, 346.
Gimbernat's ligament, 346.
Obliquus internus, 347.
Cremaster, 347.
Nerves in abdominal wall:
- Intercostals—lower six, 638.
- Last thoracic, 640.
- Ilio-hypogastric, 642.
- Ilio-inguinal, 643.

Transversalis, 347.
Rectus abdominis, 345.
Pyramidalis, 346.
Linea alba, 345.
Lumbar fascia, 374.
Transversalis fascia, 375.
Inguinal canal, 348.
Objects in anterior abdominal wall below umbilicus, 774.
Deep epigastric artery, 453.

Deep circumflex iliac artery, 453.
Superior epigastric artery, 424.
Musculo-phrenic artery, 424.
Scrotum, 835.
Spermatic cord, 838.
Testicles, 827.
Penis, 838.

Abdominal Cavity.

Abdomen Proper.

Liver, 759.
Spleen, 817.
Stomach, 733.
Gullet, 731.
Jejuno-ileum, 743.
Cæcum, 746.
Colon, 748.
Peritoneum, 769.
Foramen of Winslow, 772.
Mesentery proper, 770.
Lymph-nodes of mesentery, 512.
Superior mesenteric artery, 444.
Inferior mesenteric artery, 445.
Aortic plexus of nerves, 666.
Branches of abdominal aorta, 442.
Portal vein, 491.
Duodenum, 740.
Pancreas, 757.
Pneumogastric nerves, 611.
Solar plexus, 667.
Lumbar lymph-nodes, 512.
Kidney, 799.
Suprarenal capsules, 823.
Ureters, 807.
Diaphragma, 348.
Abdominal aorta, 404.
Receptaculum chyli, 502.
Inferior vena cava, 488.
Ganglia of sympathetic, 665.
Common iliac vessels, 447, 490.
External iliac vessels, 452, 491.
External iliac lymph-nodes, 512.
Iliac fascia, 376.
Psoas magnus, 304.
Iliacus, 305.
Quadratus lumborum, 348.
Psoas parvus, 337.
Lumbar plexus, 641.
Last thoracic nerve, 640.
Ilio-hypogastric nerve, 642.
Ilio-inguinal nerve, 643.
Genito-crural nerve, 643.
External cutaneous nerve, 643.
Anterior crural nerve, 643.

The Pelvic Cavity of the Male.

Hypogastric plexus, 667.
Pelvic fascia, 376.
Bladder, 808.
Ureters, 807.
Prostate, 844.
Rectum, 752.
Seminal vesicles, 834.
Vasa deferentia, 833.
Internal iliac artery, 448.
Obturator artery, 449.
Internal pudic artery, 449.
Sciatic artery, 451.
Ilio-lumbar artery, 452.
Gluteal artery, 451.
Lateral sacral artery, 452.
Internal iliac lymph-nodes, 512.
Superior hemorrhoidal artery, 446.
Middle sacral artery, 447.
Sacral plexus, 647.
Sacral lymph-nodes, 512.
Gangliated cord of sympathetic, 666.
Coccygeal gland, 824.
Obturator internus, 313.
Pyriformis, 312.
Deep inguinal lymph-nodes, 510.
Articulations of pelvis, 240.

The Pelvic Cavity of the Female.

(Organs not in male pelvis.)

Uterus, 855.
Broad ligaments, 858.
Ovaries, 848.
Parovaria, 862.
Fallopian tubes, 853.
Round ligaments, 859.
Urethra, 810.
Uterine artery, 449.
Vaginal artery, 449.
Ovarian artery, 447.

The Male Perineum.

Superficial fascia, 378.
Sphincter ani externus, 847.
Superficial perineal artery, 449.
Transverse perineal artery, 450.
Superficial perineal nerves, 650.
Inferior pudenal nerve, 649.
Ischio-rectal fossa, 378.
Transversus perinei, 847.
Central point of perineum, 846.
Bulbo-cavernosus, 847.
Ischio-cavernosus, 847.
Bulb of corpus spongiosum, 840.
Crura penis, 839.

Internal pudic artery, 449.
Pudic nerve, 650.
Inferior hemorrhoidal artery, 449.
Inferior hemorrhoidal nerve, 650.
Triangular ligament, 378.
Membranous urethra, 811.
Constrictor urethræ, 848.
Bulbo-urethral glands, 846.
Levator ani, 847.
Coccygeus, 847.
Anal canal, 754.
Seminal vesicles, 834.
Prostate gland, 844.

The Female Perineum.

Vulva, 864.
Vagina, 862.
Cervix uteri, 856.
Bulbs of vestibule, 867.
Vulvo-vaginal glands, 868.

Front of the Thigh.

Superficial epigastric artery, 456.
Superficial external pudic artery, 456.
Superficial circumflex iliac artery, 456.
Lymph-nodes, 509.
Internal saphenous vein, 495.
Cutaneous nerves:
  Ilio-inguinal, 643.
  Genito-crural, 643.
  Long saphenous, 644.
  External cutaneous, 643.
  Middle cutaneous, 643.
  Internal cutaneous, 644.
Fascia lata, 379.
  Ilio-tibial band, 379.
  Intermuscular septa, 379.
Saphenous opening, 379.
Inguinal ligament, 346.
Gimbernat's ligament, 346.
Femoral canal, 380.
Femoral sheath, 379.
Scarpa's triangle, 453.
Femoral artery, 453.
Profunda artery, 456.
Deep external pudic artery, 456.
Sartorius, 315.
Adductor (Hunter's) canal, 453.
Anastomotica magna artery, 458.
Femoral vein, 496.
Anterior crural nerve, 643.
External circumflex artery, 457.
Tensor vaginæ femoris, 306.
Rectus femoris, 318.
Vastus externus, 321.
Vastus internus, 321.
Vastus intermedius, 321.
Musculus articularis genu, 322.
Ligamentum patellæ, 247, 317.
Prepatellar bursa, 163.

Inner Side of the Thigh.

Adductor longus, 308.
Profunda femoris artery, 456.
Perforating arteries, 457.
Pectineus, 311.
Internal circumflex artery, 457.
Adductor brevis, 311.
Gracilis, 311.
Adductor magnus, 308.
Obturator externus, 312.
Obturator nerve, 645.
Obturator artery, 449.
Psoas magnus, 304.
Iliacus, 305.

Front of the Leg and Dorsum of the Foot.

Superficial veins, 495.
Cutaneous nerves:
  External popliteal, 655.
  External saphenous, 652.
  Internal saphenous, 644.
  Musculo-cutaneous, 656.
  Anterior tibial, 656.
Deep fascia, 380, 381.
Anterior annular ligament, 380.
Internal annular ligament, 381.
External annular ligament, 381.
Intermuscular septa, 380.
Tibialis anterior, 322.
Extensor longus digitorum, 333.
Extensor proprius hallucis, 333.
Peroneus tertius, 322.
Anterior tibial artery, 463.
Malleolar arteries, 466.
Dorsalis pedis artery, 466.
Tarsal arteries, 466.
Metatarsal arteries, 466.
Interossei dorsales, 336.
Peroneal artery, 460.
Extensor brevis digitorum, 333.
Anterior tibial nerve, 650.

Outer Side of the Leg.

Peroneus longus, 330.
Peroneus brevis, 330.
Peroneal artery, 460.
External popliteal nerve, 655.
Musculo-cutaneous nerve, 656.

Back of the Hip.

Cutaneous nerves:
- Sacral, 647.
- Lumbar, 641.
- Ilio-hypogastric, 642.
- Last thoracic, 640.
- External cutaneous of thigh, 643.
- Small sciatic, 648.

Fascia lata, 379.
Gluteus maximus, 305.
Great sciatic nerve, 650.
Internal pudic artery, 449.
Internal pudic nerve, 650.
Pyriformis, 312.
Sciatic artery, 451.
Obturator internus and gemelli, 312–315.
Quadratus femoris, 312.
Obturator externus, 312.
Internal circumflex artery, 457.
Gluteus medius, 306.
Gluteal artery, 451.
Superior gluteal nerve, 648.
Gluteus minimus, 306.

Back of the Thigh.

Cutaneous nerves, 659.
Deep fascia, 379.
Biceps flexor cruris, 315.
Semitendinosus, 315.
Semimembranosus, 315.
Great sciatic nerve, 650.
Perforating arteries, 457.
External saphenous vein, 495.
Small sciatic nerve, 648.
Popliteal space, 458.
Internal popliteal nerve, 651.
External popliteal nerve, 655.
Popliteal artery, 459.
Popliteal vein, 496.
Popliteal lymph-nodes, 510.

Back of the Leg.

Superficial veins, 495.
Cutaneous nerves, 659.
Deep fascia, 380.
Intermuscular septa, 380.
External annular ligament, 381.
Internal annular ligament, 381.
Gastrocnemius, 323.
Plantaris, 328.
Soleus, 327.
Tendo-calcaneus, 328.
Popliteal artery, 459.
Posterior tibial artery, 460.
External popliteal nerve, 655.
Posterior tibial nerve, 652.
Deep transverse fascia, 380.
Popliteus, 316.
Flexor longus hallucis, 330.
Flexor longus digitorum, 331.
Tibialis posterior, 322.
Peroneal artery, 460.

The Sole.

Internal calcaneal nerve, 653.
Plantar fascia, 381.
Abductor hallucis, 335.
Flexor brevis digitorum, 331.
Abductor minimi digiti, 335.
Internal plantar nerve, 653.
Internal plantar artery, 463.
External plantar artery, 462.
External plantar nerve, 654.
Flexor tendons, 332.
Accessorius, 331.
Lumbricales, 332.
Flexor brevis hallucis, 330.
Adductor obliquus hallucis, 336.
Adductor transversus hallucis, 336.
Flexor brevis minimi digiti, 331.
Plantar arch, 462.
Dorsalis pedis, plantar digital branch, 467
Interossei plantares, 337.
Peroneus longus tendon, 332.
Articulations of lower limb:
- Hip joint, 242.
- Knee joint, 246.
- Ankle joint, 251.
- Tarsal joints, 253.
- Tarso-metatarsal joints, 255.
- Metatarso-phalangeal joints, 256.
- Phalangeal joints, 257.

THE HEAD AND NECK.

Cranial Region.

In the superficial fascia:
- Attollens aurem, 696.
- Attrahens aurem, 697.
- Retrahens aurem, 697.
- Supratrochlear nerve, 594.
- Supraorbital nerve, 594.
- Facial nerve, temporal branches, 607.
- Orbital nerve, 596.
- Auriculo-temporal nerve, 600.
- Posterior auricular nerve, 606.
- Great auricular nerve, mastoid branch, 623.
- Small occipital, 623.

Great occipital nerve, 621.
Epicranial aponeurosis, 362.
Occipitalis, 363.
Frontalis, 363.
Temporal fascia, 366.

Inside of the Cranium.

Encephalon (to be hardened for subsequent study), 524
Dura, 576.
Venous sinuses of dura, 477.
Cranial nerves at foramina of exit, 583.
Internal carotid artery, 417.
Meningeal arteries, middle and small, 416.
Vertebral arteries, 422.
Hypophysis, 549.

Back of the Neck.

Superficial nerves :
  Great occipital, 621.
  Branches of third, fourth, and fifth cervical, 622–624.
  Small occipital, 623.
  Great auricular, 623.
Trapezius, 267.
Spinal accessory nerve, 615.
Levator scapulæ, 268.
Transverse cervical artery, 425.
Omohyoideus, posterior belly, 351.
Posterior scapular artery, 425.
Suprascapular artery, 425.
Suprascapular nerve, 626.
Vertebral fascia, 374.
Splenius cervicis, 341.
Splenius capitis, 340.
Cervicalis ascendens, 343.
Transversalis cervicis, 343.
Trachelomastoideus, 343.
Occipital artery, 413.
Complexus, 343.
Ligamentum nuchæ, 219.
Arteria princeps cervicis, 414.
Cervical spinal nerves, dorsal primary divisions, 620.
Semispinalis cervicis, 344.
Multifidus, 344.
Rectus capitis posterior major, 344.
Rectus capitis posterior minor, 345.
Obliquus capitis inferior, 345.
Obliquus capitis superior, 345.
Suboccipital nerve, dorsal primary division, 621.
Vertebral artery, 422.

Side of the Neck.

Platysma, 351.
External jugular vein, 474.
Superficial cervical lymph-nodes, 505.
Anterior jugular vein, 474.
Cervical plexus, superficial branches, 623, 624.
Facial nerve, inframandibular branch, 607.
Deep fascia, 367.
Sternocleidomastoideus, 351.
Triangles of the neck, 426.
Subclavian artery, 419.
Suprascapular artery, 425.
Transverse cervical artery, 425.
Brachial plexus, 625.
  Supraclavicular branches :
    to rhomboids, 625.
    to subclavius, 626.
    suprascapular, 626.
    posterior thoracic, 626.
Sternohyoideus, 351.
Omohyoideus, 351.
Sternothyroideus, 352.
Thyrohyoideus, 352.
Stylomandibular ligament, 368.
Digastricus, 352.
Stylohyoideus, 353.
Hypoglossal nerve, 615.
Scalenus anterior, 353.
Scalenus medius, 354.
Scalenus posterior, 354.
Subclavian artery, 419.
Vertebral artery, 422.
Thyroid axis, 424.
Inferior thyroid artery, 425.
Internal mammary artery, 424.
Seperior intercostal artery, 425.
Subclavian vein, 484.
Thoracic, or right lymphatic duct, 502.
Cervical pleura, 788.
Cervical plexus, muscular branches of, 624.
  Ramus cervicalis descendens, 624.
  Phrenic nerve, 624.
  Communicating branches, 624.
Carotid artery (common and internal), 407, 417.
Internal jugular vein, 475.
Pneumogastric nerve, 611.
Deep cervical lymph-nodes, 505.
Carotid gland, 824.
External carotid artery, 409.
  Superior thyroid artery, 410.
  Lingual artery, 411.
  Facial artery, 412.
  Occipital artery, 413.

Posterior auricular artery, 414.
Ascending pharyngeal artery, 414.
Thyroid body, 820.
Trachea, 779.
Gullet, 731.

The Face.

Platysma, 351.
Great auricular nerve, facial branch, 624.
Parotid gland, 735.
(In the parotid: external carotid, temporal, and internal maxillary arteries, temporomaxillary vein, facial, great auricular, and auriculotemporal nerves.)
Temporal artery, 414.
Orbicularis palpebrarum, 362.
Tensor tarsi, 362.
Corrugator supercilii, 362.
Eyelids, 709.
Risorius, 360.
Levator labii superioris alæque nasi, 360.
Levator labii superioris proprius, 360.
Zygomaticus minor, 360.
Zygomaticus major, 360.
Levator anguli oris, 360.
Depressor labii inferioris, 361.
Depressor anguli oris, 360.
Buccinator, 360.
Orbicularis oris, 359.
Levator labii inferioris, 361.
Nasal muscles, 361.
Facial nerve and branches, 604.
Trifacial nerve and branches, 592.
Facial artery and branches, 412.
Facial vein, 471.
Pinna, 696.
Levator palpebræ, 709.
Lachrymal gland, 712.
Lachrymal canals, 712.
Nasal duct, 684.
Nasal cartilages, 682.

Temporal and Zygomatic Fossæ.

Temporal fascia, 366.
Masseter, 356.
Temporalis, 356.
Pterygoideus externus, 357.
Pterygoideus internus, 356.
Internal maxillary artery, 415.
Internal maxillary vein, 474.
Trifacial nerve, mandibular division, 599.
Long buccal nerve, 600.
Auriculotemporal nerve, 600.
Inferior dental nerve, 601.
Lingual nerve, 602.
Chorda tympani, 606.
Otic ganglion, 603.

Mandibular Region.

Mylohyoideus, 353.
Hyoglossus, 727.
Styloglossus, 727.
Geniohyoideus, 353.
Submaxillary gland, 756.
Sublingual gland, 756.
Lingual nerve, 602.
Submandibular ganglion, 603.
Hypoglossal nerve, 615.
Genioglossus, 727.
Lingual artery, 411.

Deep Parts of the Neck.

Stylopharyngeus, 729.
Internal carotid artery, 417.
Ascending pharyngeal artery, 414.
Internal jugular vein, 475.
Glossopharyngeal nerve, 610.
Vagus nerve, 611.
Pharyngeal nerve, 613.
Superior laryngeal nerve, 613.
Inferior laryngeal nerve, 613.
Cardiac nerves, 614.
Spinal accessory nerve, 615.
Pharyngeal plexus, 615.
Hypoglossal nerve, 615.
Sympathetic ganglia of neck, 661.
Rectus capitis lateralis, 354.

Prevertebral Region.

Longus colli, 355.
Rectus capitis anterior major, 354.
Rectus capitis anterior minor, 355.
Cervical nerves, 622.
Vertebral artery, 422.

The Orbit.

Eyeball, 698.
Capsule of Tenon, 698.
Frontal nerve, 594.
Supraorbital artery, 418.
Lachrymal nerve, 594.
Nasal nerve, 594.
Lachrymal gland, 712.
Levator palpebræ superioris, 709.
Rectus superior, 708.
Obliquus superior, 708.
Optic nerve, 586.
Ophthalmic ganglion, 595.
Ophthalmic artery, 417.

Rectus externus, 708.
Rectus internus, 708.
Ligament of Zinn, 708.
Oculomotor nerve, 589.
Abducent nerve, 604.
Ciliary nerves, 594, 595.
Obliquus inferior, 709.
Rectus inferior, 708.
Orbital nerve, 596.
The ear, 686.
The mouth, 716.
  Tongue, 725.
The pharynx, 728.
  Soft palate, 718.
  Tonsils, 730.
  Eustachian tube, 694.
The larynx, 790.
The nasal fossæ, 681.

The Back.

Deep fasciæ, 374.
Muscles in third layer, 339.
Muscles in fourth layer, 341.
Muscles in fifth group, 343.
Branches of lower thoracic and upper lumbar nerves, 638–641.
Intercostal nerves, 638.
  The spinal cord, 569.
  Membranes of cord, 579.

INDEX.

A.

Abdomen, lymph-nodes of, 512
  muscles of, 345
  regions of, 732
Abdominal aorta, 404
  branches of tenth, 615
  cavity, 732
    dissection of, 914
    fascia of, 375
  ring, external, 346
    internal, 348, 376
  walls, dissection of, 913
Abducens nerve, 604
Abductor hallucis, 335
  longus pollicis, 296
  minimi digiti, 293
    pedis, 335
  pollicis muscle, 298
Accessorius ad ilio-costalem, 343
Accessory obturator nerve, 645
  olivary nuclei, 565
  spleens, 820
  thyroid glands, 821
Acetabulum, 156
Acoustic tubercle, 568
Acromio-thoracic artery, 427
Adductor brevis muscle, 311
  gracilis muscle, 311
  longus muscle, 308
  magnus muscle, 308
  obliquus hallucis, 336
  pollicis muscle, 298
  transversus hallucis, 336
Adenoid reticular tissue, 50
Adipose tissue, 49
Adrenals, 823
After-birth, 85
Aggregated lymph-nodules, 744
Agminated glands, 744
Ala, cerebellar, 559
Albicantia, corpora, 536, 550
Alimentary canal, tunics of, 715
Allantois, 83
Alveolar artery, 416
Amniotic cavity, 84
  fold, 83
Amœba, 713
Amœboid movements, 38
Amphiarthrosis, 216
Ampulla of Henle, 834
  rectal, 753
  of semicircular canal, 687
Amygdala, 541, 730
  cerebellar, 560
Amygdaloid nucleus, 541
Anal canal, 754
  columns, 754
Anastomosis, crucial, 457
  fascia, 379
Anastomotica magna of brachial, 430
  of femoral, 458
Anatomy, applied, 20
  artistic, 20
  clinical, 20
  comparative, 18
  definition of, 17
  descriptive, 18
  general, 19
  gross, 18
  macroscopic, 18
  medical, 18
  microscopic, 18
  minute, 18
  morphological, 20
  normal, 20
  pathological, 20
  philosophic, 20
  physiological, 20
  practical, 20, 909
  regional, 18
  relational, 18, 873
  surface, 883
  surgical, 18
  systematic, 18
  topographical, 18
  transcendental, 20
Anconeus muscle, 280
Angle, muscular, 792
Angular artery, 413
  gyrus, 531
  veins, 472
Ankle-joint, 251
Annular ligament of ankle, anterior, 380
    external, 381
    internal, 381
  of carpus, anterior, 372
  of forearm, posterior, 372
Annulus ovalis, 387
Ansa hypoglossi, 617
Anterior brachium, 548
  commissure, 537
  crural nerve, 643
  forceps, 534
  interosseous nerve, 629
  ligament of uterus, 859
  nares, 681
  palatine nerve, 598
  perforated space, 540
  superior dental nerves, 596
  tibial nerve, 656
Antihelix, 696
  fossa of, 696
Antitragus, 696
Antrum of Highmore, 195, 684
  mastoid, 693
  maxillary, 195, 684
  pyloricum, 735
  sphenoidal, 684
Anus, 754
Aorta, 401
  abdominal, 404
  arch of, 402
  descending, 403
Aorta, thoracic, 403
Aortic plexus, 666
  valve, 389
Aponeurosis, 259
  epicranial, 362
Apophysis, 115
Appendages of the eye, 709
Appendices epiploïcæ, 748
Appendix vermiformis, 747
Applied anatomy, 20
Aqueduct of Fallopius, 186
  of mesencephalon, 555
  region of, 553
Aqueductus cochleæ, 692
  vestibuli, 691
Aqueous humor, 707
Arachnoid of brain, 578
  of spinal cord, 580
Arantius, body of, 388
Arbor vitæ, cerebellar, 558
    uterina, 857
Arch, anterior carpal, 440
  deep crural, 376
    palmar, 441
  neural, 115
  plantar, 462
  posterior carpal, 440
  superficial palmar, 441
Arciform fibres, 564
  nuclei, 564
Area, auditory, 564, 568
  embryonic, 82
  hypoglossal, 564, 568
  opaca, 82
  pellucida, 82
  vagus, 564, 568
  vasculosa, 83
Areola of breast, 870, 871
  secondary, 871
Areolar tissue, 47
Arm, back of, dissection of, 913
  fascia of, 371
  front of, dissection of, 912
  muscles moving, 272
Arnold's nerve, 613
Arrectores pilorum, 676
Arteria centralis retinæ, 417
  princeps cervices, 414
Arteriæ receptaculi, 417
Arterial circle of Huguier, 861
Artery or arteries, 400
  acromio-thoracic, 427
  alar thoracic, 428
  alveolar, 416
  anastomotic of sciatic, 451
  anastomotica magna of brachial, 430
    of femoral, 458
  angular, 413
  anterior auricular, 414
    carpal, of radial, 436
      of ulnar, 433
    cerebral, 419

Artery or arteries, anterior choroid, 419
ciliary, 418
circumflex, 428
ethmoidal, 418
funicular, 861
inferior cerebellar, 423
intercostal, 424
interosseous, 433
meningeal, 417, 418
perforating, 463
peroneal, 460
spinal, 423
temporal, 415
tibial, 463
recurrent, 465
ulnar carpal, 433
recurrent, 432
articular, of popliteal, 459
of sciatic, 451
azygos, 459
ascending cervical, 425
palatine, 412
pharyngeal, 414
auricular, 414
anterior, 414
deep, 416
posterior, 414
axillary, 426
axis, cœliac, 442
thyroid, 424
azygos, articular, 459
basilar, 423
brachial, 429
brachio-cephalic, 405
bronchial, 441
buccal, 416
of the bulb, 450
bulbar, 423
calcaneal, external, 461
internal, 461
carotid, common, in neck, 407
external, 409
internal, 417
left, in thorax, 406
carpal, anterior, of radial, 436
of ulnar, 433
posterior, of radial, 437
of ulnar, 433
recurrent, 439
central, of retina, 417
cerebellar, anterior inferior, 423
posterior inferior, 423
superior, 423
cerebral, anterior, 419
middle, 419
posterior, 423
cervical, ascending, 425
deep, 425
superficial, 425
transverse, 425
cervicis princeps, 414
Charcot's, 419
choroid, 423
anterior, 419
ciliary, 418
circumflex, anterior, 428
external, 457
iliac, deep, 453
superficial, 456
internal, 457
posterior, 428
coccygeal, 451
cœliac axis, 442
Artery or arteries, colic, left, 446
middle, 445
right, 445
collateral, digital, 435, 462
intercostal, 441
comes nervi ischiadici, 451
common carotid, 406
in the neck, 407
femoral, 455
iliac, 447
communicating anterior, 419
dorsalis pedis, 467
peroneal, 461
posterior, 419, 439
of posterior tibial, 461
coronary, facial, 413
of the aorta, 405
corpus cavernosum, 450
cremasteric, 453
crico-thyroid, 410
cystic, of hepatic, 443
deep auricular, 416
cervical, 425
circumflex iliac, 453
epigastric, 453
external pudic, 456
palmar, of ulnar, 435
temporal, 416
dental, inferior, 416
posterior, 416
descending palatine, 416
development of, 95
digital, collateral, 435, 462
dorsal, 437, 466
of external plantar, 462
plantar, 467
of ulnar, 435
dorsal digital, 437, 466
of index, 439
interosseous, 437 466
lingual, 412
of penis, 450
scapular, 428
of thumb, 438
dorsalis hallucis, 466
indicis, 439
pedis, 466
pollicis, 438
scapulæ, 428
epigastric, deep, 453
superficial, 456
superior, 424
ethmoidal, 418
anterior, 418
external calcaneal, 461
carotid, 409
circumflex, 457
iliac, 452
malleolar, 466
obturator, 449
palpebral, 418
plantar, 462
pudic, deep external, 456
superficial, 456
external, 456
facial, 412
transverse, 414
femoral, 453
common, 455
superficial, 455
fibular, superior, 465
frontal, 418
ganglionic, 423
gastric, 442
short, 444
Artery or arteries, gastro-duodenal, 443
-epiploic, left, 444
right, 443
glandular, 410, 412, 425
gluteal, 451
inferior, 451
helicine, 843
hemorrhoidal, inferior, 449
middle, 449
superior, 446
hepatic, 442
humeral, 429
hyoid, 410, 412
ileo-colic, 446
iliac, common, 447
deep circumflex, 453
external, 452
internal, 448
superficial circumflex, 456
ilio-lumbar, 452
inferior anterior cerebellar, 423
dental, 416
gluteal, 451
hemorrhoidal, 449
labial, 413
laryngeal, 425
mesenteric, 445
pancreatico-duodenal, 445
posterior cerebellar, 423
profunda, 430
thyroid, 425
infraorbital, 416
intercostal, 441
anterior, 424
collateral, 441
superior, 425
internal calcaneal, 461
carotid, 417
circumflex, 457
iliac, 448
malleolar, 466
mammary, 424
maxillary, 415
obturator, 449
plantar, 463
pudic, 449
interosseous, anterior, 433
dorsal, 437, 466
palmar, 439
posterior, 433
recurrent, 433
of radial, 437
of ulnar, 433
intestinal, 445
labial, inferior, 413
lachrymal, 418
laryngeal, inferior, 425
superior, 410
lateral nasal, 413
sacral, 452
spinal, 422
left carotid, in the thorax, 406
colic, 445
gastro-epiploic, 444
lenticulo-striate, 419
lingual, 410
dorsal, 412
long ciliary, 418
thoracic, 428
lumbar, 447
malleolar, external, 466
internal, 466
mammary, internal. 424

Artery or arteries, mandibular, 416
masseteric, 416
mastoid, 414
maxillary, internal, 415
median, 433
mediastinal, 424
posterior, 441
meningeal, 414
anterior, 417
middle, 416
posterior, 423
small, 416
mental, 416
mesenteric, inferior, 445
superior, 444
metatarsal, 466
middle cerebral, 419
colic, 445
hemorrhoidal, 449
meningeal, 416
sacral, 447
temporal, 414
musculo-phrenic, 424
nasal, 418
lateral, 413
naso-palatine, 417
nutrient, of brachial, 430
to clavicle, 425
to fibula, 460
to ilium, 449
to tibia, 461
to ulnar and radius, 433
obturator, 449
external, 449
internal, 449
occipital, 413
œsophageal, 425, 441
of bulb, 450
of cerebral hemorrhage, 419
of small intestine, 445
ophthalmic, 417
orbital, 414
ovarian, 447
palatine, 414
ascending, 412
descending, 416
palmar, deep, of ulnar, 435
interosseous, 439
palpebral, 418
external, 418
pancreatic, 444
pancreatico-duodenalis, inferior, 445
superior, 443
perforating, 424
anterior, 463
of profunda, 457
of radial, 439
posterior, 463
pericardial, 424, 441
perineal, superficial, 449
transverse, 450
peroneal, 460
anterior, 460
posterior, 461
pharyngeal, 414
ascending, 414
phrenic, 447
superior, 424
plantar, digital, 467
external, 462
internal, 463
pontal, 423
popliteal, 459
Artery or arteries, posterior auricular, 414
carpal, 437
of radial, 437
of ulnar, 433
cerebral, 423
circumflex, 428
communicating, 419, 439
dental, 416
inferior cerebellar, 423
interosseous, 433
recurrent, 433
mediastinal, 441
meningeal, 423
perforating, 463
peroneal, 461
radial carpal, 437
scapular, 425
spinal, 423
temporal, 415
tibial, 460
recurrent, 465
ulnar carpal, 433
recurrent, 433
prevertebral, 414
princeps cervicis, 414
hallucis, 467
pollicis, 439
profunda femoris, 456
inferior, 430
superior, 430
pterygoid, 416
pterygo-palatine, 416
pubic, 449, 453
deep external, 456
internal, 449
superficial external, 456
pulmonary, 400
pyloric, 443
radial, 435
recurrent, 436
radialis indicis, 439
ranine, 412
receptacular, 417
recurrent, anterior tibial, 465
carpal radial, 436, 439
posterior interosseous, 433
tibial, 465
radial, 436
ulnar, anterior, 432
posterior, 433
renal, 446
right colic, 445
gastro-epiploic, 443
sacral, lateral, 452
middle, 447
scapular, dorsal, 428
posterior, 425
sciatic, 451
short ciliary, 418
gastric, 444
sigmoid, 446
small meningeal, 416
spermatic, 446
spheno-palatine, 417
spinal, 441
anterior, 423
lateral, 422
posterior, 423
splenic, 444
sternal, 424
sterno-mastoid, 410, 414
stylo-mastoid, 414
subclavian, 419
subcostal, 441
Artery or arteries, sublingual, 412
submental, 412
subscapular, 425, 428
superficial cervical, 425
circumflex iliac, 456
epigastric, 456
external pudic, 456
femoral, 455
perineal, 449
temporal, 414
volar, 437
superior cerebellar, 423
epigastric, 424
fibular, 465
hemorrhoidal, 446
intercostal, 425
laryngeal, 410
mesenteric, 444
pancreatico-duodenalis, 443
phrenic, 424
profunda, 430
thoracic, 427
thyroid, 410
supra-acromial, 425
supraorbital, 418
suprarenal, 446
suprascapular, 425
suprasternal, 425
sural, 459
Sylvian, 419
systemic, 401
tarsal, 466
temporal, 414
anterior, 415
deep, 416
middle, 414
posterior, 415
thoracic, alar, 428
long, 428
superior, 427
thyroid axis, 424
inferior, 425
superior, 410
thyroidea ima, 406
tibial, anterior, 463
posterior, 460
recurrent, anterior, 465
posterior, 465
tonsillar, 412
tracheal, 425
transversalis colli, 425
transverse, 423
cervical, 425
facial, 414
perineal, 450
tympanic, 414, 416, 417
ulnar, 431
carpal, anterior, 433
posterior, 433
deep palmar, 435
digital, 435
recurrent, anterior, 432
posterior, 433
of upper extremity, 419
uterine, 449
vaginal, 449
vertebral, 422
vesical, 449
Vidian, 416
Articular synovial membrane, 70
Articulations, 215
acromio-clavicular, 229
of astragalus, 253

Articulations between articular processes of vertebræ, 219
atlas and occipital bone, 222
axis and atlas, 220
and occipital bone, 221
bodies of vertebræ, 217
pisiform and cuneiform, 237
calcaneo-cuboid, 254
carpal, 237
carpo-metacarpal, 238
chondro-sternal, 224
coraco-clavicular, 229
costo-chondral, 224
-vertebral, 223
cubo-cuneiform, 255
-scaphoid, 254
of head, 217
interchondral, 225
intercoccygeal, 240
intercuneiform, 255
intermetacarpal, 238
intermetatarsal, 256
interphalangeal, 239
of lower limb, 242
medio-carpal, 237
metacarpo-phalangeal, 239
metatarso-phalangeal, 256
of pelvis, 240
with last lumbar vertebra, 240
radio-carpal, 236
-ulnar, 235
inferior, 235
middle, 235
superior, 235
sacro-coccygeal, 240
-iliac, 240
scapho-cuneiform, 255
scapulo-clavicular, 229
sternal, 225
sterno-clavicular, 228
tarso-metatarsal, 255
of tarsus, 253
temporo-mandibular, 226
of thorax, 223
tibio-fibular, 250
inferior, 250
superior, 250
transverse carpal, 237
of trunk, 217
of upper extremity, 228
of vertebral column, 217
Articularis genu muscle, 322
Aryteno-epiglottideus, 796
Arytenoid cartilages, 792
Arytenoideus, 796
Ascending colon, 748
vena cava, 488
Association fibres in cerebrum, 535
Astragalus, 168
Atlas, 116
Atrium of right auricle, 387
Attolens aurem, 696
Attrahens aurem, 697
Auditory area, 568
meatus, external, 695
nerve, 608, 692
distribution of, in labyrinth, 690
organ, development of, 108
Auricle, left, of heart, 389
right, 387
atrium of, 387
Auricular artery, 414
anterior, 414
posterior, 414
nerve, posterior, 606
of tenth, 613
veins, anterior, 474
posterior, 474
Auricularis, anterior, 697
posterior, 697
superior, 696
Auriculotemporal nerve, 600
Axilla, 426
suspensory ligament of, 370
Axillary artery, 426
fascia, 369
lymph-nodes, 508
space, 426
veins, 484
Axis, 117
cerebro-spinal, 513
cœliac, 442
thyroid, 424
Azygos uvulæ, 719
veins, great, 485
left lower, 486
lower left, 486
right, 485
small, 486

B.

Back, dissection of, 919
fascia of, 374
muscles of, 339
Band, ilio-pectineal, 380
ilio-tibial, 379
moderator, 389
Bartholin, glands of, 868
Basal commissure, gray, 550
white, 533
Basement membrane, 41
Basilar artery, 423
membrane, 688
plexus, 480
sinus, 480
Basilic vein, 483
median, 483
Bauchstiel, 83
Bell, nerve of, 626
Bellini, ducts of, 803
Belly-stalk, 81
Bertin, columns of, 803
Biceps flexor cruris, 315
cubiti, 277
Bicuspid teeth, 721
valve, 389
Bile-ducts, 760, 767
Biventer cervicis muscle, 344
Bladder, false ligaments of, 809
gall-, 767
ligaments of, 377
trigonum of, 808
urinary, 808
development of, 102
Blandin, gland of, 755
Blood, 57
circulation of, 386
islands, 83
-vascular system, 385
-vessels, development of, 93
of lungs, 783
physiological anatomy of, 395
Body-cavity, 80
ciliary, 702
Body-cavity, Malpighian, of kidney, 802
restiform, 562
thyroid, 820
Wolffian, 99
Bone or bones, 113
astragalus, 168
atlas, 116
axis, 117
calcaneum, 168
carpal, 145
clavicle, 133
coccyx, 123
composition of, 113
cranium, 177
cuboid, 169
cuneiform, of carpus, 147
of tarsus, 171
development of, 113
ethmoid, 192
extremities, development of, 93
of face, 193
femur, 159
fibula, 166
of foot, 167
frontal, 181
functions of, 113
of hand, 146
of hip, 152
humerus, 138
hyoid, 202
ilium, 153
innominate, 152
internal arrangement of, 113
ischium, 155
lachrymal, 198
of lower limb, 152
malar, 199
maxillary, inferior, 200
superior, 193
metacarpal, 151
of metatarsus, 172
nasal, 198
navicular, 169
number of, 113
occipital, 177
os calcis, 168
innominatum, 152
magnum, 150
pubis, 156
outward forms of, 113
palate, 196
parietal, 180
patella, 163
pelvic, 157
phalanges of foot, 173
of hand, 152
pisiform, 148
pyramidal, of carpus, 147
radius, 144
ribs, 129
sacrum, 120
scaphoid, of carpus, 146
of tarsus, 169
scapula, 135
semilunar, 146
sesamoid, 259
sphenoid, 188
sternum, 127
of tarsus, 168
temporal, 184
tibia, 163
trapezium, 148
trapezoid, 149

Bone or bones, turbinate, inferior, 198
tympanic, 188
ulnar, 142
of upper limb, 133
unciform, 151
vertebra prominens, 117
vertebræ, cervical, 116
lumbar, 119
peculiar, 119
sacral, 120
thoracic, 118
vomer, 197
Wormian, 203
Bony cochlea, 691
Borders of liver, 765
Bowman, glands of, 685
Brachial artery, 429
fascia, 371
plexus, 625
Brachialis muscle, 278
Brachio-cephalic artery, 405
vein, 471
-radialis muscle, 279
Brachium, anterior, 548
posterior, 548
Brain, 513
arachnoid of, 578
diagrammatic description of, 521
dura of, 576
infundibulum of, 549
membranes of, 576
pia of, 578
-sand, 551, 579
veins of, 481
ventricles of, development of, 103
Branchial cleft, 85
Breast, male, 871
Breasts, 869
Broad ligament of lung, 790
of uterus, 858
Broca, pouch of, 865
Bronchi, 780
Bronchia, 781
Bronchial artery, 441
lymph-nodes, 512
tubes, 781
veins, 486
Bronchioles, 781
Brunner, glands of, 742
Buccal artery, 416
glands, 717
lymph-nodes, 507
nerve, 607
long, 600
veins, 473
Buccinator fascia, 366
muscle, 360
Bulb, artery of, 450
of corpus spongiosum, 840
of crus penis, 839
end, 673
olfactory, 585
in posterior horn of lateral ventricle, 543
spinal, 562
Bulbi vestibuli, 867
Bulbo-cavernosus muscle, 847, 869
-urethral glands, 846
Bundle, posterior longitudinal, 555
of Vicq-d'Azyr, 537
Burdach, tract of, 575
Bursa, pharyngeal, 728
Bursæ, synovial, 382
Bursal synovial membrane, 70

C.

Cacumen, 559
Cadaver, division of, 911
Cæcum, 746
Calamus scriptorius, 564
Calcaneal artery, internal, 461
Calcaneo-plantar nerve, 653
Calcaneum, 168
Calcar, 543
Calcarine fissure, 527
Callosal fissure, 527
Calloso-marginal fissure, 527
Callosum, 532
peduncles of, 535
Calvaria, 209
Canal or canals, alimentary, tunics of, 715
anal, 754
central, of spinal cord, development of, 103
of cochlea, 687
of Corti, 690
crural, 379
femoral, 380
of Gärtner, 862
development of, 100
Hunter's, 456
inguinal, 348
lachrymal, 710
of Nuck, 829
of Petit, 707
of Schlemm, 701
semicircular, 687, 691
spinal, 125
Stenson's, 684
of Stilling, 707
Canalis reuniens, 688
utriculo-sacculari, 687
Canine teeth, 721
Canthi, 709
Capsule, external, 552
of Glisson, 765
internal, 552
suprarenal, 823
of Ténon, 698
Caput coli, 747
gallinaginis, 813
Cardia of stomach, 735
Cardiac nerves, 662, 663
cervical, 614
thoracic, 614
plexus, 667
veins, 469
anterior, 470
great, 469
middle, 470
posterior, 470
smallest, 470
Carotid artery, external, 409
internal, 417
glands, 824
plexus, 662
Carpal arch, posterior, 440
artery of radial, anterior, 436
posterior, 437
of ulnar, anterior, 433
posterior, 433
Cartilage, arytenoid, 792
costal, 131
Cartilage, cricoid, 791
cuneiform, 794
epiglottic, 792
hyaline, 51
Meckel's, 92
nasal, 682
reticular, 52
thyroid, 791
true, 51
white fibro-, 51
yellow fibro-, 52
Caruncula lachrymalis, 710
myrtiformes, 866
Cauda equina, 576
Caudate lobe, 764
nucleus, 539
Cavernous plexus, 662
sinus, 480
Cavities opening into nasal fossæ, 684
in sustentacular tissues, membrane lining, 69
Cavity, abdominal, 732
amniotic, 84
body-, 80
of cerebro-spinal axis, 515
membrane lining, 69
general ventricular, 519
nasal, 681
Cavum oris, 717
Cells, 37
chalice, 44
of Claudius, 690
of Deiters, 690
ethmoidal, 684
goblet, 44
hepatic, 761
mastoid, 693
prickle, 43
reproduction, 39
Cement, 87
Central canal of spinal cord, 572
lobe, 526
point of perineum, 846
Centrosome, 78
Centrum, 115
Cephalic vein, 484
Cephalo-rachidian fluid, 514
Cerebellar ala, 559
amygdala, 560
arbor vitæ, 558
artery, posterior inferior, 423
corpus dentatum, 560
dorsal tuber, 560
folia, 558
lingula, 559
nodule, 560
peduncles, 558
pyramid, 560
trapezium, 558
uvula, 560
veins, inferior, 482
superior, 482
Cerebellum, 557
development of, 104
hemispheres of, 557
Cerebral artery, anterior, 419
middle, 419
hemisphere, arteries of, 545
peduncles, 554
veins, anterior, 482
deep, 482
inferior, 482
middle, 482
superficial, 481

Cerebral veins, superior, 481
Cerebro-spinal axis, 513
cavity of, 515
membranes of, 576
walls of, 519
fluid, 514
nerve, typical, 581
Cerebrum, 524
surface of, 524
Cerumen, 696
Ceruminous glands, 696
Cervical artery, ascending, 425
deep, 425
superficial, 425
cardiac nerves, 614
curves of spinal cord, 570
enlargements of spinal cord, 570
fascia, 367
ganglion, inferior, 663
middle, 663
superior, 661
lymph-nodes, deep, 505
superficial, 505
nerves, 622
first, 621
superficial, 624
plexus, 622
vein, deep, 477
transverse, 474
vertebræ, 116
Cervicalis ascendens, 343
Cervicofacial division of seventh nerve, 607
Cervix of uterus, 856
Chalice cells, 44
Chamber, aqueous, 707
Cheeks, 717
Chiasma, optic, 586
Chink of glottis, 790, 797
Choanæ, 681
Chondroglossus, 728
Chorda tympani, 695
Chordæ tendineæ, 389
Chorio-capillaris, 702
Chorion, 83, 84
Choroid, 702
anterior, 419
fissure, 543
plexuses, 541
of fourth ventricle, 563
veins, 482
Chyle, 57
Chyli, receptaculum, 502
Cilia, 710
Ciliary arteries, 704
artery, anterior, 418
long, 418
short, 418
body, 702
ganglion, 595
muscle, 702
nerves, 704
processes, 703
zone, 702
Ciliated epithelium, 43
Cinereum, tuber, 549
Circle of Willis, 423
Circular fissure, 529
sinus, 480
Circulation of the blood, 386
fœtal, 497
Circulus major iridis, 704
Circumflex artery, anterior, 428
external, 457
Circumflex artery, internal, 457
posterior, 428
nerve, 632
Circumvallate papillæ, 678
Cisternæ arachnoidales, 579
Clarke, column of, 572
Classes of tissues, 41
Claudius, cells of, 690
Claustrum, 540
Clavicle, 133
Clavi-coraco-axillary fascia, 370
Clavi-pectoral fascia, 370
Clefts, branchial, 85, 87
structures derived from, 87
Clinical anatomy, 20
Clitoris, 867
development of, 102
Clivus, 559
Cloaca, 102
Coccygeal artery, 451
gland, 824
nerves, 646, 658
Coccygeus muscle, 847
Coccyx, 123
Cochlea, bony, 691
canal of, 687
Cœliac axis, 442
lymph-nodes, 512
plexus, 665
Cœlom, 81
Colic artery, 445
ileo-, 445
left, 446
middle, 445
right, 445
Collar-bone, 133
Collateral fissure, 528
Colliculus seminalis, 813
Colon, 748
ascending, 748
descending, 749
sigmoid, 749
transverse, 749
Column of Clarke, 572
lateral, of oblongata, 562
muscle, 61
vertebral, 115
Columna nasi, 681
Columnæ carneæ, 388
Columnar epithelium, 42
Columns, anal, 754
of Bertin, 803
of spinal cord, 571
Commissure, anterior, 537
basal, gray, 550
white, 533
middle, 548
optic, 586
posterior, 550
of spinal cord, gray, 572
white, 572
of vulva, anterior, 865
posterior, 865
Common bile duct, 767
Commune anterius foramen, 550
Communicans hypoglossi nerve, 616
Communicating artery, anterior, 419
posterior, 419
Comparative anatomy, 18
Complexus muscle, 343
Compressor naris muscle, 361
narium minor, 362
urethræ muscle, 848
Conarium, 550
Concha, 696
Conduction paths in spinal cord, 572
Conductor sonorus, 556
Cone, terminal, of spinal cord, 570
Coni vasculosi, 832
Conjoined tendon, 347
Conjunctiva, 711
fornix of, 712
Connective tissue, 46
Constrictor, inferior, 729
medius, 729
superior, 729
Coraco-brachialis muscle, 274
Cord, spermatic, 838
spinal, 513
arachnoid of, 569
central canal of, 572
cervical curve of, 570
enlargement of, 570
conduction paths in, 572
dura of, 579
gray commissure of, 572
length of, 571
lumbar enlargement of, 570
pia of, 580
terminal cone of, 570
thoracic curve of, 570
weight of, 570
white commissure of, 572
umbilical, 83
vocal, false, 794
true, 794
Corium, 671
Cornea, 700
Corniculum laryngis, 792
Corona ciliaris, 703
glandis, 841
radiata, 552
Coronary ligament of liver, 766
plexus, 667
sinus, 469, 480
veins, 469
right, 470
small, 470
Corpora albicantia, 536, 550
cavernosa, 839
geniculata, 548
quadrigemina, 554
development of, 105
Corpus Arantii, 388
callosum, 532
genu of, 533
rostrum of, 533
cavernosum, arteries of, 450
dentatum, cerebellar, 560
fimbriatum, 536
Highmorianum, 830
luteum, 853
spongiosum, 840
bulb of, 840
striatum, 538
subthalamicum, 552
triticeum, 794
Corpuscles, Malpighian, 819
muscle, 61
Pacinian, 673
salivary, 730
touch, 672
Corrugator supercilii muscle, 362
Corti, canal of, 690
organ of, 689
development of, 109

Corti, rods of, 689
Costal cartilages, 131
Costo-colic ligament, 771
-coracoid ligament, 370
membrane, 370
Cowper, glands of, 846
Cranial cavity, floor of, 209
nerves, 583
nuclei of, 587
region, dissection of, 916
Cranium, bones of, 177
cerebral lobes in, 532
inside of, dissection of, 917
interior of, 209
Cremaster of Henle, 838
muscle, 347
Cremasteric artery, 453
fascia, 347, 837
Cribriform fascia, 379
Crico-arytenoideus lateralis, 795
posterior, 795
-thyroid artery, 411
-thyroideus, 795
Cricoid cartilage, 791
Crista acustica, 687
vestibuli, 691
Cross-striped muscular tissue, 59
Crucial anastomosis, 457
Crura cerebri, 554
penis, 839
Crural arch, deep, 376
canal, 379
nerve, anterior, 643
sheath, 375
Crurale septum, 380
Crusta, 554
Crypts of Lieberkühn, 739
Cuboid bone, 169
Cucullaris muscle, 267
Cul-de-sac of Douglas, 858
Culmen, 559
Cuneiform bone of the carpus, 147
external, 172
internal, 172
middle, 172
of tarsus, 171
cartilage, 794
Cuneus, 531
Cupola, 692
Curve, cervical, of spinal cord, 570
thoracic, of spinal cord, 570
Cushion of epiglottis, 792, 797
Cutaneous membrane, 74
nerve of anterior crural, internal, 644
middle, 643
internal, 631
perforating, 649
small internal, 631
of thigh, external, 643
Cuticle, 670
Cutis vera, 671
Cystic duct, 767

D.

Dartos, 836
Decidua reflexa, 84
serotina, 84
vera, 84
Deciduous teeth, 721
Decussation of pyramids, 562
sensory, 566
Deep fasciæ, 366
lymph-vessels, 502
temporal nerve, 599
Deiters, cells of, 690
Delimitations of surface parts, 21
Deltoid fascia, 371
Deltoideus muscle, 272
Dental artery, inferior, 416
nerve, inferior, 601
shelf, 86
Dentate gyrus, 532
nucleus, 565
Denticulate ligament, 580
Dentine, 56
Depressor alæ nasi, 361
anguli oris, 360
labii inferioris, 361
Derma, 671
Descemet, membrane of, 700
Descendens hypoglossi nerve, 616
Descending colon, 749
vena cava, 470
Development of arteries, 95
of blood-vessels, 93
of bones, 113
of extremities, 93
of canals of Gärtner, 100
of central canal of spinal cord, 103
of cerebellum, 104
of clitoris, 102
of cloaca, 102
of corpora quadrigemina, 105
of diaphragm, 97
of ear, 108
early stages of, 79
of enamel, 86
of epencephalon, 104
of epididymis, 101
of excretory organs, 98
of eye, 107
of eyelids, 108
of Fallopian tubes, 100
of gubernaculum, 102
of the gustatory organs, 106
of heart, 93
of hydatid of Morgagni, 100
of insula, 106
of intestines, 88
of labia majora, 103
minora, 103
of lachrymal duct, 108
glands, 108
of liver, 90
of lungs, 88
of lymphatic vessels, 98
of medulla oblongata, 104
of mesenteries, 88
of metencephalon, 104
of muscular system, 98
of nervous system, 103
of neuroglia, 103
of oblongata, 104
of olfactory organs, 106
of optic thalamus, 105
of organ of Corti, 109
of Giraldes, 101
of ovaries, 99
of pancreas, 91
of paroöphoron, 100
of parovarium, 100
of penis, 102
of perineum, 102
of placenta, 83, 85
Development of pons, 104
of prosencephalon, 105
of quadrigemina, 105
of reproductive organs, 98
of rhinencephalon, 106
of ribs, 92
of round ligament, 100
of scrotum, 102
of sinus pocularis, 101
of skeleton, 91
of skull, 92
of spleen, 98
of sternum, 127
of stomach, 90
of suprarenal bodies, 98
of the sympathetic system, 106
of the tactile organs, 106
of teeth, 86
of testes, 100
of thalamencephalon, 105
of thymus, 88
of thyroid gland, 88
of tongue, 88
of trachea, 88
of tunica vaginalis, 101
of urachus, 102
of ureters, 99, 102
of urethra, 102
of urinary bladder, 102
of urogenital sinus, 102
of uterus, 100
masculinus, 101
of vagina, 100, 103
of vas deferens, 101
of veins, 96
of ventricles of brain, 103
of vertebræ, 91
Diaphragm, development of, 97
of sella, 577
Diaphragma muscle, 348
Diaphragmatic plexus, 665
Diaphysis, 114
Diarthrosis, 216
Diatela, 541
Digastric lobe, 560
Digestion, organs of, 713
Digital arteries of ulnar, 435
fossa, 828
nerves of foot, 654
Dilatator naris, anterior, 362
posterior, 362
Diploë, veins of, 477
Discus proligerus, 850
Dissection of abdomen and lower limb, 913
of abdominal cavity, 914
walls, 913
of back, 919
of arm, 913
of hand, 913
of hip, 916
of leg, 916
of neck, 917
of thigh, 916
of thorax and upper limb, 913
of cranial region, 916
of deep parts of the neck, 918
of face, 918
of female perineum, 915
of front of arm, 912
of forearm, 912
of leg and dorsum of foot, 915
of thigh, 915

Dissection of head and neck, 916
of inner side of thigh, 915
of inside of cranium, 915
of male perineum, 914
of mandibular region, 918
of orbit, 918
of outer side of leg, 915
of palm, 912
of pelvic cavity of female, 914
of male, 914
of prevertebral region, 918
of side of neck, 917
of sole, 916
of temporal and zygomatic fossæ, 918
of thoracic cavity, 912
of thorax and upper limb, 912
Distribution of spinal nerves, mode of, 619
Division of cadaver, 911
Divisions, anterior primary, of spinal nerves, 622
dorsal primary, of first cervical nerve, 621
of spinal nerves, 620
Dorsal artery of penis, 450
of thumb, 438
nerve of penis, 650
pyramid, 563
tuber, cerebellar, 560
veins of penis, 494
Dorsalis hallucis artery, 466
pedis artery, 466
pollicis artery, 438
Dorsum of foot, dissection of, 915
Douglas, cul-de-sac of, 858
folds of, 858
Drum of ear, 692
Ductless glands, 817
Ducts of Bellini, 803
bile, 767
common, 767
cystic, 767
ejaculatory, 835
hepatic, 767
lachrymal, development of, 108
of liver, 760
lymphatic, left, 502
right, 502
Müllerian, 99
nasal, 684, 712
pancreatic, 758
of Stenson, 755
thoracic, 502
of Wharton, 756
Wolffian, 98
Ductus arteriosus, 96, 400
cochlearis, 688
communis choledochus, 767
endolymphaticus, 687
venosus fissure, 764
Duodenal glands, 742
Duodenum, 740
Dura mater of brain, 576
of spinal cord, 579

E.

Ear, 686
development of, 108
drum of, 692
external, 695
internal, 686
labyrinth of, 686
Ear, middle, 692
Ectoderm, 80
organs derived from, 103
Eighth nerve, 608
Ejaculatory ducts, 835
Elastic tissues, 47
Elbow-joint, 233
Elementary tissues, 37
Eleventh nerve, 615
nuclei of, 609
Embryology, 77
Embryonic area, 82
shield, 80
vesicle, 80
Eminentia collateralis, 543
teres, 556, 568
Emissary veins, 477
Enamel, development of, 86
organ, 86
second, 87
Encephalic vesicles, 514
Encephalon, 513
weight of, 569
End bulbs, 673
Endocardium, 386
Endoderm, 80
organs derived from, 86
Endomysium, 61
Endoneurium, 64
Endosteum, 53
Endothelium, 41
End-plate, motorial, 65
Endyma, 514
Enlargement of spinal cord, cervical, 570
lumbar, 570
Ensiform process, 127
Epencephalon, 555
development of, 104
Ependyma, 514
Epicardium, 394
Epicondylar, lymph-node of, 509
Epidermis, 670
Epididymis, 828, 831
canal of, 832
development of, 101
Epidural space, 580
Epigastric artery, deep, 453
superficial, 456
superior, 424
plexus, 667
veins, superficial, 495
Epiglottic cartilage, 792
Epimysium, 61
Epineurium, 64
Epiphyses, 114, 550
Epithelium, 41
ciliated, 43
columnar, 42
flattened, 42
glandular, 44
neuro-, 43
pigmented, 43
prickle cell of, 43
sensory, 43
simple, 44
stratified, 44
transitional, 44
Epoöphoron, 862
Erector penis muscle, 847
spinæ, 341
Eruption of teeth, 721
Ethmoid bone, 192
Ethmoidal arteries, 418
anterior, 418
Ethmoidal cells, 684
Eustachian tube, 694
valve, 388
Excretory organs, development of, 98
Expression, muscles of, 358
Extensor brevis digitorum, 333
pollicis, 296
carpi radialis brevis, 284
longus, 283
ulnaris, 284
communis digitorum, 291
indicis, 292
longus digitorum, 333
hallucis, 333
pollicis, 296
minimi digiti, 292
ossis metacarpi pollicis, 296
primi internodii pollicis, 296
proprius hallucis, 333
secundi internodii pollicis, 296
External anterior thoracic nerve, 627
auditory meatus, 695
capsule, 552
cutaneous nerve of musculospiral, 634
of thigh, 643
ear, 695
laryngeal nerve, 613
medullary lamina, 540
os, 857
palatine nerve, 599
plantar nerve, 654
popliteal nerve, 655
pterygoid nerve, 600
respiratory nerve, 626
spermatic fascia, 836
superficial petrosal nerve, 606
Extraspinal veins, 486
Extremities of liver, 765
Eye, 698
appendages of, 709
development of, 107
Eyeball, muscles of, 708
Eyelashes, 710
Eyelids, 709
development of, 108

F.

Face, bones of, 193
dissection of, 918
coronary arteries of, 413
Facial artery, 412
transverse, 414
nerve 604
region of skull, 207
vein, 471
anterior, 471
common, 472
deep, 473
posterior, 473
transverse, 474
Falciform ligament of liver, 766
lobe, 528
process, 379
Fallopian tubes, 853
development of, 100
fimbriæ of, 854
fimbriated extremity of, 854
Fallopius, aqueduct of, 186
False ligaments of bladder, 809
ribs, 129
vertebræ, 115

False vocal cords, 794
Falx cerebelli, 577
cerebri, 577
Fascia or fasciæ, 365
of the abdominal cavity, 375
anal, 379
of the arm, 371
axillary, 369
of the back, 374
brachial, 371
buccinator, 366
cervical, 367
inner, 368
middle, 368
outer, 367
clavi-coraco-axillary, 370
-pectoral, 370
cremasteric, 837
cribriform, 379
deep, 366
transverse, 380
deltoid, 371
dentata, 532
dorsal, of hand, 373
external spermatic, 836
of foot, 381
of forearm, 371
of hand, 372
of head, 366
of hip and thigh, 379
iliac, 376
infraspinous, 371
infundibuliform, 376, 837
intercolumnar, 347, 836
intercostal, 370
external, 370
internal, 370
spermatic, 837
ischiorectal, 379
lata, 379
of leg, 379
lumbar, 374
masseteric, 366
middle spermatic, 837
obturator, 376
palmar, 372
parotid, 366
pectoral, 369
pelvic, 376
of perineum, 377
plantar, 381
prevertebral, 368
propria, 837
pyriformis, 377
recto-vesical, 377
of shoulder, 370
subscapular, 371
superficial, 365
supraspinous, 371
temporal, 366
thoracic, 369
transversalis, 375
vertebral, 374
Fasciculus cuneatus, 564
gracilis, 564
Fatty tissue, 49
Fauces, isthmus of, 718
Female perineum, dissection of, 915
Femoral artery, 453
common, 455
superficial, 455
canal, 380
ring, 376, 380
sheath, 375
Femoral vein, 496
Femur, 159
Fenestra ovalis, 691, 693
rotunda, 692, 693
Ferrein, pyramids of, 802
Fibres, arciform, 564
association, 535
of Sharpey, 54
Fibro-cartilage, white, 51
yellow, 52
Fibrous tissues, white, 46
yellow, 47
tunic of eye, 700
Fibula, 166
Fibular nerve, 653
Fifth nerve, 592
ophthalmic division of, 593
sacral, 658
Filiform papillæ, 679
Fillet, 567
Filum terminale, 570
Fimbria, 536
ovarian, 850, 854
Fimbriæ of Fallopian tube, 854
Fimbriated extremity of Fallopian tube, 854
Fingers, muscles moving, 286
First nerve, 585
cervical, 621
Fissure, calcarine, 527
callosal, 527
calloso-marginal, 527
central, 525, 527
choroid, 543
circular, 529
collateral, 528
ductus venosus, 764
gall-bladder, 763
of Glaser, 184
hippocampal, 532
intraparietal, 530
longitudinal, of cerebrum, 525
olfactory, 530
parallel, 531
parieto-occipital, 526, 527
partial, 525
portal, 763
precentral, 529
precuneal, 528
pterygo-maxillary, 204
Rolandic, 525
spheno-maxillary, 204
of spinal cord, 571
supraorbital, 530
Sylvian, 525
total, 525
transverse, 543, 763
umbilical, 763
vena caval, 764
Flattened epithelium, 42
Flexor accessorius, 331
brevis digitorum, 331
hallucis, 330
minimi digiti, 289
pedis, 331
pollicis, 296
carpi radialis, 283
ulnaris, 283
longus digitorum, 331
hallucis, 330
pollicis, 296
ossis metacarpi minimi digiti, 287
pollicis, 295
perforans muscle, 288
Flexor perforatus digitorum pedis, 331
muscle, 287
profundus digitorum, 288
sublimus digitorum, 287
Flexure, hepatic, 749
splenic, 749
Flocculus, 560
Fluid, cephalo-rachidian, 514
cerebro-spinal, 514
Fœtal circulation, 497
Fold, amniotic, 83
of Douglas, 858
glosso-epiglottic, 792
Folia, cerebellar, 558
Follicle, Graafian, 850
hair, 675
Fontana, spaces of, 701
Fontanelles, 203
Foot, bones of, 167
dorsum of, dissection of, 915
fasciæ of, 381
muscle moving the whole, 322
phalanges of, 173
as a whole, 175
Foramen cæcum of oblongata, 562
of tongue, 725
commune arterius, 550
epiploïcum, 772
of Key and Retzius, 564
of Magendie, 519, 564
of Monro, 550
obturator, 157
ovale, 387
of Winslow, 772
Foramina Thebesii, 387
Forceps, anterior, 534
posterior, 534
Forearm, fascia of, 371
muscles moving outer part of, 280
whole, 277
Forehead, muscles of, 362
Foreskin, 841
Form of liver, 761
Formatio reticularis, 555
Fornix, 535
of conjunctiva, 712
Fossa of antihelix, 696
digital, 828
of helix, 696
ischio-rectal, 378
nasal, 208, 682
navicular, 867
navicularis of urethra, 813
ovalis, 387
patellaris, 707
spheno-maxillary, 204
temporal, 203
dissection of, 918
zygomatic, 204
dissection of, 918
Fourchette, 865
Fourth nerve, 592
sacral, 657
ventricle, 568
Fovea centralis, 705
hemielliptica, 691
hemispherica, 691
inferior, 568
superior, 556, 568
Frænum labii, 717
linguæ, 726
præputii, 841

Framework organs, 32
Frenulum, 559
Frontal artery, 418
bone, 181
gyri, 529
lobe, 526
nerve, 594
sinuses, 684
veins, 473, 477
Frontalis muscle, 363
Fronto-nasal process, 86
Fundus of uterus, 856
Fungiform papillæ, 679
Furrow, spinal, 124

G.

Galactophorous ducts, 871
Galen, veins of, 470, 482
Gall-bladder, 767
fissure, 763
Ganglia of the hemisphere, 537
of nerves, 65
sporadic, of fifth nerve, 594
Gangliated cord, lumbar portion of, 665
thoracic portion of, 663
Ganglion, aortico-renal, 667
cervical, inferior, 663
middle, 663
superior, 661
ciliary, 595
Gasserian, 592
geniculate, 604
impar, 666
jugular, 610
lenticular, 595
mesenteric, superior, 667
ophthalmic, 595
otic, 603
petrous, 610
semilunar, 592
of sympathetic, 667
spiral, 692
submandibular, 603
submaxillary, 603
Gärtner, canals of, 862
development of, 100
Gasserian ganglion, 592
Gastric artery, 442
short, 444
veins, 493
Gastrocnemius muscle, 323
Gastro-colic omentum, 772
-duodenal artery, 443
-epiploïc artery, left, 444
right, 443
Gelatinous tissues, 50
Gemellus muscle, inferior, 315
superior, 312
Generation, organs of, 827
female, 848
male, 827
Geniculata, corpora, 548
Geniculate ganglion, 604
Genioglossus, 727
Genio-hyoideus muscle, 353
Genito-crural nerve, 643
Genu of callosum, 533
Germinal epithelium, 851
spot, 852
vesicle, 852
Gimbernat's ligament, 346
Gingivæ, 725
Giraldès, organ of, 833, 862
Giraldès, organ of, development of, 101
Gladiolus, 127
Gland or glands, 75
agminated, 744
of Bartholin, 868
of Blandin, 755
of Bowman, 685
of Brunner, 742
buccal, 717
bulbo-urethral, 846
carotid, 824
ceruminous, 696
coccygeal, 824
of Cowper, 846
ductless, 817
duodenal, 742
intestinal, 739
labial, 717
lachrymal, 712
development of, 108
mammary, 869
Meibomian, 710
molar, 717
palatine, 717
parotid, 755
periurethral, 868
pineal, 550
pituitary, 549
prostate, 844
salivary, 755
development of, 86, 87
sebaceous, 676
solitary, 740
sublingual, 756
submaxillary, 756
suburethral, 846
sweat, 677
thyroid, 820
urethral, 868
vulvo-vaginal, 868
of Weber, 755
Glandulæ odoriferæ, 841
Pacchionii, 579
vestibulares majores, 868
minores, 868
Glandular artery, 412
epithelium, 44
Glans penis, 840
Glaser, fissure of, 184
Glisson, capsule of, 765
Globus major, 828
minor, 828
pallidus, 540
Glosso-epiglottic folds, 792
Glossopharyngeal nerve, 610
Glottis, chink of, 790, 797
Gluteal artery, 451
lines, 154
lymph-nodes, 510
nerve, inferior, 648
superior, 648
veins, 494
Gluteus maximus muscle, 305
medius muscle, 306
minimus muscle, 306
Goblet cells, 44
Goll, tract of, 575
Gowers, tract of, 573
Graafian follicles, 850
Gracilis muscle, 311
Gray commissure, basal, 550
of spinal cord, 572
matter of spinal cord, 571
Great deep petrosal nerve, 597
Great occipital nerve, 621
omentum, 772
sciatic nerve, 650
splanchnic nerve, 664
superficial petrosal nerve, 597, 606
Groove, lateral, of mesencephalon, 554
vertebral, 124
Gross anatomy, 18
of lungs, 785
features of kidney, 803
Gubernaculum, 102
testis, 828
Gullet, 731
Gums, 725
Gustatory organs, development of, 106
Gyri, frontal, 529
limbic, 531
occipital, 531
operti, 527
parietal, 530
temporal, 531
Gyrus, angular, 531
dentate, 532
hippocampal, 531
marginal, 530
paracentral, 530
postcentral, 531
precentral, 530
subcalcarine, 531
subcollateral, 531
superior parietal, 531
supramarginal, 531
uncinate, 532

H.

Hair follicle, 675
papilla, 676
Hairs, 674
Hand, back of, dissection of, 913
bones of, 145
fascia of, 372
muscles moving whole, 283
phalanges of, 152
Hard palate, 717
Haustrum, 745
Haversian system, 53
Head, articulations of, 217
fascia of, 366
lymph-nodes of, 505
muscles of, 356
and neck, dissection of, 916
veins of, 471
Heart, 385
apex of, 393
development of, 93
external configuration of, 391
grooves, 391
infundibulum of, 388
surfaces of, 391
thickness of walls of, 387
tissues of, 386
veins of, 469
Helicine arteries, 843
Helicotrema, 692
Helix, 696
fossa of, 696
Hemispheres of cerebellum, 557
Hemorrhoidal artery, inferior, 449
middle, 449
superior, 446
nerve, inferior, 650

Hemorrhoidal plexus, 494, 668
Henle, cremaster of, 838
layer of, 675
Hepatic artery, 442, 766
cells, 761
duct, 767
flexure, 749
veins, 760
Hepato-duodenal ligament, 771
Herophilus, torcular of, 178, 478
Hiatus semilunaris, 684
Highmore, antrum of, 195
Hilum of kidney, 804
of liver, 763
of lung, 786
Hip, back of, dissection of, 916
-bone, 152
fascia of, 379
-joint, 242
Hippocampal gyrus, 531
Hippocampus major, 544
minor, 543
Histology, 19
Homologies of bones of the limbs, 176
Horn of lateral ventricle, middle, 543
posterior, 543
Horny layer, 671
Houston, valves of, 754
Huguier, arterial circle of, 861
Humerus, the, 138
Humor, aqueous, 707
vitreous, 707
Hunter, canal of, 453
Huxley, layer of, 675
Hyaline cartilage, 51
Hyaloid membrane, 707
Hyaloplasm, 38
Hydatid of Morgagni, 832, 862
development of, 100
Hymen, 866
Hyoglossus, 727
Hyoid artery, 410, 412
bone, 202
Hypogastric plexus, 667
Hypoglossal area, 568
nerve, 616
Hypophysis, 549

I.

Ideal lobe of kidney, 800
Ileo-cæcal valve, 747
-colic valve, 747
artery, 445
Iliac artery, common, 447
deep circumflex, 453
external, 452
internal, 448
superficial circumflex, 456
fascia, 376
lymph-nodes, external, 512
internal, 512
veins, common, left, 490
right, 490
external, 491
internal, 493
superficial circumflex, 495
Iliacus muscle, 305
Iliocostalis muscle, 341
Iliohypogastric nerve, 642
Ilioinguinal nerve, 643
-lumbar artery, 452
veins, 490
Ilio-pectineal band, 380
-psoas muscle, 305
-tibial band, 379
Ilium, 153
Incisor teeth, 721
Incus, 694
Indusium, 535
Inferior cervical ganglion, 663
dental nerve, 601
fovea, 568
gluteal nerve, 648
hemorrhoidal nerve, 650
laryngeal nerve, 613
maxillary division of fifth nerve, 599
mesenteric plexus, 666
palpebral nerve, 596
petrosal sinus, 475
pudendal nerve, 649
vena cava, 488
vermis, 558
Infracostales muscles, 350
Inframandibular nerve, 607
Infraorbital artery, 416
nerve, 596
of seventh, 607
Infraspinatus muscle, 275
Infraspinous fascia, 371
Infratrochlear nerve, 594
Infundibula of ureter, 807
Infundibuliform fascia, 376, 837
Infundibulum of brain, 549
of heart, 388
of lung, 782
of nose, 684
Inguinal canal, 348
ligament, 346
lymph-nodes, deep, 510
superficial, 509
Innominate veins, 471
Insula, 526, 528
development of, 106
Intercavernous sinus, 480
Interclavicular notch, 127
Intercolumnar fascia, 347, 836
Intercostal arteries, 441
anterior, 424
superior, 425
fascia, 370
external, 370
internal, 370
lymph-nodes, 510
nerves, 638
veins, 486
superior, 485
Intercostales externi muscles, 349
interni muscles, 350
Interdeferential triangle, 834
Interlabial space, 866
Interlobular veins, 760
Internal abdominal ring, 348
anterior thoracic nerve, 627
capsule, 552
cutaneous nerve, 631
of anterior crural, 644
of musculo-spiral, 634
laryngeal nerve, 613
medullary lamina, 540
os, 855, 857
plantar nerve, 653
popliteal nerve, 651
saphenous nerve, 644
secretion, organs of, 32
spermatic fascia, 837
sphincter, 754
Internal sphincter of urethra, 811, 815
structure of oblongata, 564
Interossei dorsalis pedis, 336
manus, 292
palmares, 294
plantares, 337
volares muscle, 294
Interosseous artery, anterior, 433
posterior, 433
of radial, 437
of ulnar, 433
membrane, 250
nerve, anterior, 629
posterior, 635
Interpeduncular space, 549
Interspinales muscles, 344
Intertransversales muscles, 344
Interventricular vein, posterior, 470
Intestinal arteries, 445
glands, 739
Intestine, large, 744
tunics of, 744
small, 737
tunics of, 737
Intestines, development of, 88
Intestinum tenue, 737
Intralobular veins, 760
Intraparietal fissure, 530
Intraspinal veins, 486
Introitus vaginæ, 866
Iris, 703
Ischio-cavernosus muscle, 847, 868
-rectal fascia, 379
fossa, 378
Ischium, 155
Island of Reil, 526
Islands, blood, 83
substance, 83
Isthmus cerebri, 553
of fauces, 718
of thyroid, 821

J.

Jacobson, nerve of, 610
organ of, 684, 685
Jejuno-ileum, 743
Jelly, Whartonian, 83
Joint, elbow-, 233
kinds of, 216
shoulder-, 230
Jugular ganglion, 610
nerve, 662
sinus, 475
veins, anterior, 474
external, 474
internal, 475
posterior external, 474
Juice canals, 499
channels, 499

K.

Karyokinesis, 39
Key and Retzius, foramen of, 564
Kidneys, 799
gross features of, 803
hilum of, 804
labyrinth of, 802
lobes of, 800
sinus of, 803
situation of, 806

Kidneys, vessels of, 802
Knee-joint, 246
Krause, membrane of, 60

L.

Labia majora, 864
development of, 103
minora, 865
development of, 103
Labial artery, inferior, 412
glands, 717
nerve, superior, 597
Labyrinth of ear, 686
of kidney, 802
membranous, 686
Lachrymal artery, 418
bone, 198
canal, 710
duct, development of, 108
gland, 712
development of, 108
nerve, 594
sac, 710
Lactiferous ducts, 871
Lacuna magna, 815
Lacunæ of urethra, 814
Lacunar ligament, 346
Lamina cinerea, 550
cribrosa, 700
external medullary, 540
internal medullary, 540
quadrigemina, 555
reticular, 690
spiralis, 691
terminalis, 550
vitreous, 702
Lanugo, 674
Large intestine, 744
tunics of, 744
Laryngeal artery, inferior, 425
superior, 411
nerve, external, 613
inferior, 613
recurrent, 613
superior, 613
pouch, 797
Laryngo-pharynx, 728
Larynx, 790
cartilages of, 791
ligaments of, 793
lining of, 797
muscles of, 794
ventricle of, 797
Lateral column of oblongata, 562
groove of mesencephalon, 554
ligaments of liver, 766
nasal nerve, 597
sinus, 478
tract of oblongata, 562
ventricle, horn of, middle, 543
posterior, 543
Latissimus muscle, 275
Layer of Henle, 675
horny, 671
of Huxley, 675
Malpighian, 670
Least splanchnic nerve, 665
Left lobe of liver, 763
Leg, back of, dissection of, 916
fasciæ of, 380
front of, dissection of, 915
muscles moving, 315
Leg, outer side of, dissection of, 915
Lemniscus, 555, 567
Lens, 707
suspensory ligament of, 707
Lenticular ganglion, 595
nucleus, 540
Leucocytes, 57
Levator anguli oris, 360
ani muscle, 847, 869
labii inferioris, 361
superioris alæque nasi, 360
proprius, 360
palati, 719
palpebræ superioris, 709
proprius alæ nasi, anterior, 362
posterior, 362
scapulæ, 268
Levatores costarum muscle, 350
Lieberkühn, crypts of, 739
Lienculi, 820
Lieno-pancreatic ligament, 771
-renal ligament, 771
Ligament or ligaments, annular, of ankle, anterior, 380
external, 381
internal, 381
of axilla, suspensory, 370
of bladder, false, 809
true, 377
of carpus, anterior, 372
costo-colic, 771
coracoid, 370
of forearm, posterior, 372
Gimbernat's, 346
hepato-duodenal, 771
inguinal, 346
lacunar, 346
of larynx, 793
of lens, suspensory, 707
lieno-pancreatic, 771
-phrenic, 819
-renal, 771
of liver, coronary, 766
falciform, 766
lateral, 766
round, 766
suspensory, 766
lumbo-ovarian, 850
palpebral, 362, 711
peritoneal, 771
phreno-colic, 771
-splenic, 819
Poupart's, 346
pterygo-mandibular, 360
round, development of, 100
of scapula, 230
scrotal, 827
spiral, 692
stylo-mandibular, 366
superficial transverse, 373
suspensory, of ovary, 850
of penis, 842
tube-ovarian, 850
uniting neural arches, 219
of urethra, triangular, 378
utero-ovarian, 849
of uterus, anterior, 859
broad, 858
recto-vaginal, 859
round, 859
triangular, 346
of urethra, 378
utero-sacral, 859
Ligament or ligaments of uterus, vaginal, of hand, 373
of Zinn, 708
Ligamentum denticulatum, 580
infundibulo-pelvicum, 850, 859
pectinatum iridis, 700
Ligula, 564
Limb, lower, articulations of, 242
bones of, 152
upper, articulations of, 228
bones of, 133
classification of muscles of, 266
movements of, 265
Limbic gyri, 531
lobe, 528
Limbus, 692
Line, white, 377
Lines, gluteal, 154
Lingua, 725
Lingual artery, 411
dorsal, 412
lymph-nodes, 508
nerve of ninth, 611
of seventh, 606
of vagus, 616
Lingualis, 726
Lingula, cerebellar, 559
Lining of the larynx, 797
Lips, 717
Liquid tissues, 57
Liquor folliculi, 850
Liver, 759
borders of, 765
broad ligament of, 766
development of, 90
extremities, 765
form of, 761
hilum of, 763
lobule of, 759
relations of, 769
situation of, 768
size of, 768
surfaces of, 762
tunics of, 765
vessels of, 760, 766
weight of, 768
Lobe or lobes, central, 526
digastric, 560
on external cerebral surface, 526
falciform, 528
frontal, 526
of kidney, 800
ideal, 800
limbic, 528
of liver, caudate, 764
left, 763
quadrate, 763
right, 763
Spigelian, 763
of mesial and tentorial surfaces, 527
occipital, 526
parietal, 526
slender, 560
temporal, 526
Lobule of ear, 696
of liver, 759
Loculi, 830
Locus ceruleus, 556, 568
lachrymalis, 710
niger, 554

Long buccal nerve, 600
saphenous nerve, 644
Longissimus dorsi muscle, 343
Longitudinal bundle, posterior, 555
fissure of cerebrum, 525
sinus, inferior, 478
superior, 477
Longus colli muscle, 355
Lubbe, veins of, 482
Lumbar arteries, 447
enlargement of spinal cord, 570
fascia, 374
lymph-nodes, lateral, 512
median, 512
nerves, 641
plexus, 641
portion of gangliated cord, 665
veins, 489
ascending, 490
Lumbo-ovarian ligament, 850
Lumbricales manus, 290
pedis, 332
Lungs, blood-vessels of, 783
broad ligament of, 790
development of, 88
gross anatomy of, 785
hilum of, 786
infundibulum of, 782
minute anatomy of, 782
Lunula, 674
Lymph, 57
Lymphadenoid structures, 502
tissue, 502
diffuse, 502
Lymphatic duct, left, 502
right, 502
system, 499
vessels, development of, 98
Lymph-chambers, 501
Lymph-node or lymph-nodes, 502
of abdomen, 512
anterior mediastinal, 510
axillary proper, 508
bronchial, 512
buccal, 507
cervical, deep, 505
superficial, 507
cœliac, 512
deep cervical, 505
inguinal, 510
epicondylar, 509
external iliac, 512
gluteal, 510
of head and neck, 505
iliac, external, 512
internal, 512
inguinal, deep, 510
superficial, 509
intercostal, 510
internal iliac, 512
maxillary, 507
lateral lumbar, 512
lingual, 508
of the lower limb, 509
lumbar, lateral, 512
median, 512
mastoid, 507
maxillary, internal, 507
median lumbar, 512
mediastinal, anterior, 510
posterior, 510
superior, 510
Lymph-node or lymph-nodes, mesenteric, 512
mesocolic, 512
parotid, 507
pectoral, 508
popliteal, 510
posterior mediastinal, 510
postpharyngeal, 507
rectal, 512
sacral, 512
sternal, 510
subclavian, 508
submaxillary, 507
suboccipital, 507
subscapular, 508
superficial cervical, 505
inguinal, 509
superior mediastinal, 510
suprahyoid, 507
of thorax, 510
of upper limb, 508
vena-caval, 512
Lymph-nodules, aggregated, 744
solitary, 740
Lymph-vessels, 499
deep, 502
structure of, 501
superficial, 501
Lyra, 536

M.

Macroscopic anatomy, 18
Macula acustica, 686, 687
folliculi, 853
lutea, 705
Magendie, foramen of, 519, 564
Magnum, os, 150
Malar bone, 199
of seventh nerve, 607
Male perineum, dissection of, 914
muscles of, 846
Malleus, 694
Malpighian body of kidney, 802
corpuscles, 819
layer, 671
Mammæ, 869
supernumerary, 872
Mammary artery, internal, 424
glands, 869
veins, internal, 484
Mandible, 200
Mandibular, division of fifth nerve, 599
process, 86
region, dissection of, 918
Manubrium, 127
Marginal gyrus, 530
veins, left, 470
right, 470
Marrow, 53, 55
-cavity, 52
Marshall, vein of, 469
Masseter muscle, 356
internal, 356
Masseteric artery, 416
fascia, 366
nerve, 599
veins, 473
Mastication, muscles of, 356
Mastoid antrum, 693
cells, 693
lymph-nodes, 507
Matrix of nail, 674
Maxilla, 193
Maxillary antrum, 684
artery, internal, 415
division of fifth nerve, 596
inferior, 599
lymph-nodes, internal, 507
process, 86
vein, anterior internal, 473
internal, 474
Meatus, external auditory, 695
inferior, 682
middle, 682
superior, 683
urinarius externus, 840
female, 866
internus, 809
Meckel, cartilage of, 92
Median nerve, 627
vein, basilic, 483
cephalic, 483
Mediastinal arteries, 424
posterior, 441
lymph-nodes, anterior, 510
posterior, 510
superior, 510
Mediastinum, 394
testis, 830
Medical anatomy, 18
Medulla oblongata, 562
Medullary lamina, external, 540
internal, 540
Meibomian glands, 710
Membrana granulosa, 850
suprachoroidea, 702
tympani, 693
Membrane or membranes, 65
basement, 41
basilar, 688
of the brain, 576
of cerebro-spinal axis, 576
costo-coracoid, 370
cutaneous, 74
of Descemet, 700
fibro-serous, 67
hyaloid, 707
interosseous, 250
of Krause, 60
lining cavity of cerebro-spinal axis, 69
cavities in sustentacular tissues, 69
vascular system, 68
mucous, 61
gastro-pulmonary, 71
genito-urinary, 72
pituitary, 684
of Reissner, 688
Schneiderian, 684
serous, 66
proper, 68
of spinal cord, 579
synovial, 69
articular, 70
bursal, 70
vaginal, 70
tectorial, 690
typical, 66
vitelline, 851
Membranous labyrinth, 686
Meningeal artery, 414
anterior, 418
middle, 416
posterior, 423
small, 416
nerve of ninth, 610
of tenth, 616

Meningo-rachidian veins, 486
Mesencephalon, 553
aqueduct of, 555
lateral groove of, 554
nates of, 554
testes of, 554
Mesenchyme, 91
Mesenteric artery, inferior, 445
superior, 444
lymph-nodes, 512
plexus, inferior, 666
superior, 666
vein, inferior, 493
superior, 493
Mesenteries, 770
development of, 88
Mesentery, 737
Mesial surface of cerebrum, 527
Mesocolic lymph-nodes, 512
Mesoderm, 81
organs derived from, 91
Mesodermal somites, 82
Mesogastrium, 772
Mesonephros, 99
Mesorchium, 828
Mesosternum, 127
Mesothelium, 91
Metacarpal bones, 151
Metanephros, 99
Metapore, 564
Metasternum, 127
Metatarsal artery, 466
Metatarsus, bones of, 172
Metatela, 564
Metencephalon, development of, 104
Methods of study, 33
Microscopic anatomy, 18
Mid-brain, 553
Middle cervical ganglion, 663
commissure, 548
cutaneous nerve of anterior crural, 643
ear, 692
horn of lateral ventricle, 543
spermatic fascia, 837
superior dental nerve, 596
Migration of testicle, 828
Milk-teeth, 721
Minute anatomy, 18
of the lungs, 782
Mitral valves, 389
Moderator band, 389
Modiolus, 691
Molar glands, 717
teeth, 721
Monro, foramen of, 546
sulcus of, 548
Mons veneris, 864
Monticulus, 558
Morgagni, hydatid of, 832, 862
development of, 100
Morphological anatomy, 20
Morphology of skull, 212
of vertebræ, serial, 126
Morula, 79
Motion, organs of, 32
Mouth, 716
Movement, kinds of, in joints, 217
amœboid, 38
Mucous membranes, 71
gastro-pulmonary, 71
genito-urinary, 72
Mucus, 73
Müllerian duct, 99
Multifidus muscle, 344
Muscle or muscles of the abdomen, 345
abductor hallucis, 335
longus pollicis, 296
minimi digiti, 293
pedis, 335
pollicis, 298
accessorius ad ilio-costalem, 343
accelerator urinæ, 847
adductor brevis, 311
gracilis, 311
longus, 308
magnus, 308
obliquus hallucis, 336
pollicis, 298
transversus hallucis, 336
affecting the orifice of the mouth, 359
anconeus, 280
articularis genu, 322
of back, 339
biceps flexor cruris, 315
cubiti, 277
biventer cervicis, 344
brachialis, 278
brachio-radialis, 279
buccinator, 360
bulbo-cavernosus, 847, 869
cervicalis ascendens, 343
ciliary, 702
classification of, 264
coccygeus, 847
-column, 61
complexus, 343
compressor naris, 361
narium minor, 362
urethræ, 848
vaginæ, 869
constrictor urethræ, 848, 869
coraco-brachialis, 274
-corpuscles, 61
corrugator supercilii, 362
cremaster, 347
cucullaris, 267
deep transverse, 848
deltoideus, 272
depressor alæ nasi, 361
anguli oris, 360
labii inferioris, 361
diaphragma, 348
digastricus, 352
dilatator naris anterior, 362
posterior, 362
of dorsum of neck, 339
ejaculator seminis, 847
urinæ, 847
erector spinæ, 341
of penis, 847
of expression, 358
extensor brevis digitorum, 333
pollicis, 296
carpi radialis brevis, 284
longus, 283
ulnaris, 284
communis digitorum, 291
indicis, 292
longus digitorum, 333
hallucis, 333
pollicis, 296
minimi digiti, 292
ossis metacarpi pollicis, 296
primi internodii pollicis, 296
Muscle or muscles, extensor proprius hallucis, 333
secundi internodii pollicis, 296
of eyeball, 708
of female perineum, 868
in fifth group of back, 343
flexor accessorius, 331
brevis digitorum, 331
hallucis, 330
minimi digiti, 289
pedis, 331
pollicis, 296
carpi radialis, 283
ulnaris, 283
longus digitorum, 331
hallucis, 330
pollicis, 296
ossis metacarpi minimi digiti, 289
pollicis, 295
perforans, 288
perforatus, 287
digitorum pedis, 331
profundus digitorum, 288
sublimis digitorum, 287
of forehead, 362
in fourth layer of back, 341
of front and side of neck, 351
frontalis, 363
gastrocnemius, 323
gemellus inferior, 315
superior, 312
general considerations, 259
genio-hyoideus, 353
gluteus maximus, 305
medius, 306
minimus, 306
gracilis, 311
of head, 356
iliacus, 305
ilio-costalis, 341
ilio-psoas, 305
infracostales, 350
infraspinatus, 275
intercostales externi, 349
interni, 350
interossei dorsales manus, 292
pedis, 336
palmares, 294
plantares, 337
volares, 294
interspinales, 344
intertransversales, 344
ischio-cavernosus, 847, 868
of larynx, 794
latissimus, 275
levator anguli oris, 360
ani, 847, 869
labii alæque nasi, 360
inferioris, 361
superior proprius, 360
proprius alæ nasi anterior, 362
posterior, 362
scapulæ, 268
levatores costarum, 350
longissimus dorsi, 343
longus colli, 355
of lower limb, 301
classification of, 302
lumbricales manus, 290
pedis, 379
of male perineum, 846
masseter, 356

Muscle or muscles, masseter, internal, 356
of mastication, 356
mind, 358
moving arm, 272
digits of foot, 330
fifth metacarpal bone, 286
fingers, 286
outer part of forearm, 280
the leg, 315
shoulder, 267
thigh, 303
thumb, 294
whole foot, 322
forearm, 277
hand, 283
multifidus, 344
mylo-hyoideus, 353
of neck, 351
nomenclature of, 262
of nose, 361
obliquus capitis inferior, 345
superior, 345
externus abdominis, 346
internus abdominis, 347
obturator externus, 312
internus, 313
occipitalis, 363
occipito-frontalis, 362
omo-hyoideus, 351
opponens minimi digiti, 289
pollicis, 295
orbicularis oris, 359
palmaris brevis, 299
longus, 283
palpebrarum, 362
papillary, 388
pectineus, 311
pectoralis major, 274
minor, 270
peroneus brevis, 330
longus, 330
tertius, 322
of pharynx, 729
of pinna, 696
plantaris, 328
platysma, 351
popliteus, 316
pronator quadratus, 281
teres, 281
psoas magnus, 304
parvus, 337
pterygoideus externus, 357
internus, 356
pyramidalis, 346
nasi, 361
pyriformis, 312
quadratus femoris, 312
lumborum, 348
plantæ, 331
quadriceps extensor cruris, 317
rectus abdominis, 345
capitis anterior major, 354
minor, 355
lateralis, 354
posterior major, 344
minor, 345
femoris, 318
rhomboideus major, 269
minor, 269
risorius, 360
rotatores, 344
sacro-lumbalis, 343
sartorius, 315
Muscle or muscles, scalenus, anterior, 353
medius, 354
posterior, 354
semimembranosus, 315
semispinalis capitis, 343
cervicis, 344
dorsi, 344
semitendinosus, 315
serratus magnus, 270
posterior, inferior, 340
superior, 339
of soft palate, 718
soleus, 327
sphincter ani externus, 847
vaginæ, 869
spinalis dorsi, 343
splenius capitis, 340
cervicis, 341
colli, 341
sterno-cleido-mastoideus, 351
-hyoideus, 351
-thyroideus, 352
stylo-hyoideus, 353
subclavius, 271
subcostales, 350
suboccipital, 344
subscapularis, 277
superficial, of head, 356
supinator, 282
supraspinatus, 274
suspensory, 742
tarsi, 362
temporalis, 356
tensor fasciæ latæ, 306
vaginæ femoris, 306
teres major, 275
minor, 275
in third layer of back, 339
of thorax, 348
thyro-hyoideus, 352
tibialis anterior, 322
posterior, 322
trachelo-mastoideus, 343
transversalis abdominis, 347
cervicis, 343
transversus pedis, 336
perinei, 847, 868
thoracis anterior, 350
trapezius, 267
triangularis sterni, 350
triceps extensor cubiti, 279
suræ, 328
of trunk, 339
of tympanum, 695
of upper limb, 265
vastus externus, 321
intermedius, 321
internus, 321
lateralis, 321
medialis, 321
vesico-pubic, 377, 809
zygomaticus major, 360
minor, 360
Muscular angle, 792
system, development of, 98
tissue, cardiac, 61
cross-striped, 57
plain, 58
Musculi pectinati, 388
Musculo-cutaneous nerve, 627
of leg, 656
-phrenic artery, 424
-spiral nerve, 633
Myelon, 513, 569
Mylo-hyoideus muscle, 353
Myocardium, the, 387

N.

Naboth, ovula of, 860
Nails, 674
matrix of, 674
Nares, anterior, 681
posterior, 681
Nasal artery, 418
lateral, 413
bone, 198
cartilages, 682
cavity, 681
duct, 684, 712
fossæ, 682
cavities opening into, 684
nerve, 594
lateral, 597
superior, 598
vein, transverse, 473
Naso-palatine nerve, 598
Naso-pharynx, 728
Nates of mesencephalon, 554
Navicular bone, 169
fossa, 867
Neck, back of, dissection of, 917
deep dissection of, 918
dorsum of, muscles of, 339
and head, dissection of, 916
lymph-nodes of, 505
muscles of, 351
side of, dissection of, 917
sympathetic nerves in, 661
triangles of, 426
veins of, 471
Nerve or nerves, 581
abdominal, 615
abducent, 604
accessory obturator, 645
afferent, 65
anterior crural, 643
interosseus, 629
palatine, 598
superior dental, 596
tibial, 656
of Arnold, 613
auditory, 608, 692
distribution in labyrinth, 690
auricular, great, 623
posterior, 606
of tenth, 613
auriculo-temporal, 600
of Bell, 626
buccal, 607
long, 600
calcaneo-plantar, 653
cardiac, 662, 663
cervical, 614
thoracic, 614
cerebro-spinal, 581
typical, 581
cervical, 622
cardiac, 614
superficial, 624
chorda tympani, 606
ciliary, 704
short, 595
circumflex, 632
coccygeal, 646, 658
communicans hypoglossi, 616
cranial, 583
deep origins, 584
superficial origins, 583

Nerve or nerves, crural, anterior, 643
cutaneous, external, 643
of musculo-spiral, 634
internal, 631
of anterior crural, 644
of musculo-spiral, 634
middle of anterior crural, 643
perforating, 649
small internal, 631
deep temporal, 599
dental, anterior superior, 596
inferior, 601
middle superior, 596
posterior superior, 596
descendens hypoglossi, 616
digital, of foot, 654
dorsal, of penis, 650
efferent, 65
eighth, 608
eleventh, 615
nuclei of, 609
external anterior thoracic, 627
cutaneous, 643
of musculo-spiral, 634
laryngeal, 613
palatine, 599
plantar, 654
popliteal, 655
pterygoid, 600
respiratory, 626
superficial petrosal, 606
facial, 604
fibular, 653
fifth, 592
mandibular division of, 599
maxillary division of, 596
inferior, 599
sacral, 658
sporadic ganglia of, 594
first, 585
cervical dorsal, primary division of, 621
fourth, 592
sacral, 657
frontal, 594
ganglia of, 65
genito-crural, 643
glosso-pharyngeal, 610
gluteal, inferior, 648
superior, 648
great auricular, 623
deep petrosal, 597
occipital, 621
palatine, 598
sciatic, 650
splanchnic, 664
superficial petrosal, 597, 606
hemorrhoidal, inferior, 650
hypoglossal, 615
iliohypogastric, 642
ilioinguinal, 643
inferior dental, 601
gluteal, 648
hemorrhoidal, 650
laryngeal, 613
palpebral, 596
pudendal, 649
inframandibular, 607
infraorbital, 596
of seventh, 607
infratrochlear, 594
intercostal, 638
internal anterior thoracic, 627
Nerve or nerves, internal cutaneous, 631
of anterior crural, 644
of musculo-spiral, 634
laryngeal, 613
plantar, 653
popliteal, 651
pterygoid process, 599
saphenous, 644
interosseous, anterior, 629
posterior, 635
of Jacobson, 610
jugular, 662
labial, superior, 597
lachrymal, 594
laryngeal, internal, 613
superior, 613
lateral nasal, 597
least splanchnic, 665
lingual, 602
of ninth, 610
of seventh, 606
of vagus, 616
long buccal, 600
saphenous, 644
lumbar, 641
malar, of seventh, 607
masseteric, 599
median, 627
external terminal division, 630
internal terminal division, 631
meningeal, of ninth, 610
of tenth, 616
middle cutaneous, of anterior crural, 643
superior dental, 596
musculo-cutaneous, 627
of leg, 656
-spiral, 633
nasal, 594
lateral, 597
superior, 598
nasopalatine, 598
ninth, 610
nuclei of, 609
obturator, 645
accessory, 645
occipital, great, 621
small, 623
third, 622
oculo-motor, 589
œsophageal, 615
olfactory, 585
optic, 586
palatine, anterior, 598
external, 599
great, 598
posterior or small, 599
palmar, cutaneous, of median, 630
of ulnar, 631
palpebral, inferior, 596
patellar, 645
perforating cutaneous, 649
perineal, 650
peroneal, 655
petrosal, external superficial, 606
great deep, 597
superficial, 597, 606
small deep, 610
superficial, 606
pharyngeal, of ninth, 610
Nerve or nerves, pharyngeal, of sympathetic, 662
of tenth, 613
of Vidian, 599
phrenic, 624
plantar, external, 654
internal, 653
pneumogastric, 611
popliteal, external, 655
internal, 651
posterior auricular, 606
interosseous, 635
palatine, 598
superior dental, 596
thoracic, 626
tibial, 652
pterygoid, external, 600
pudendal, inferior, 649
pudic, 650
pulmonary, 614
radial, 635
recurrent laryngeal, 613
respiratory, external, 626
rhomboid, 625
-roots, spinal, 576
sacral, 646
fifth, 658
fourth, 657
sciatic, great, 650
small, 648
second, 586
seventh, 604
branches of, below base of skull, 606
in petrous bone, 606
cervicofacial division of, 607
pars intermedia of, 604
temporofacial division of, 607
short ciliary, 595
sixth, 604
of skin, 672
small deep petrosal, 610
internal cutaneous, 631
occipital, 623
sciatic, 648
splanchnic, 665
superficial petrosal, 606
spheno-palatine, 596
spinal, 617
accessory, 615
dorsal, anterior primary divisions of, 622
primary divisions of, 620
mode of distribution of, 619
splanchnic, great, 664
least, 665
small, 665
subclavius, 626
suboccipital, 621
subscapular, 627
superficial cervical, 624
temporal, 601
superior gluteal, 648
labial, 597
laryngeal, 613
nasal, 598
supramandibular, 607
suprascapular, 626
supratrochlear, 594
sympathetic, 658
in the neck, 661
temporal, deep, 599
of seventh, 607
superficial, 601
temporo-malar, 596

Nerve or nerves, tenth, 611
nuclei of, 609
third, 589
occipital, 622
thoracic, 638
cardiac, 614
external anterior, 627
internal anterior, 627
posterior, 626
twelfth, 640
tibial, anterior, 656
posterior, 652
tonsillar, of ninth, 610
trifacial, 592
trochlear, 592
twelfth, 615
thoracic, 640
tympanic, 610
ulnar, 631
vagus, 611
Vidian, 597
of Wrisberg, 631
Nervi nervorum, 64
vasorum, 396
Nervous system, development of, 103
tunic of eye, 704
Neural arch, 115
ligaments uniting, 219
Neurilemma, 63
Neuroblasts, 103
Neuro-epithelium, 43
Neuroglia, 50
development of, 103
Neuromeres, 104
Neuron, 62
Neuroplasm, 64
Ninth nerve, 610
nuclei of, 609
Nodes of Ranvier, 63
Nodule, cerebellar, 560
Nomenclature of muscles, 262
Normal anatomy, 20
skiagraphs, 896
Nose, 681
infundibulum of, 684
muscles of, 361
Nostrils, 681
Notch, interclavicular, 127
sacro-sciatic, great, 154
small, 155
Notochord, 81, 91
Nourishment, organs supplying, 31
Nuck, canal of, 829
Nuclei, accessory olivary, 565
arciform, 565
of cranial nerves, 587
Nucleolus, 38
Nucleus, 38
ambiguus, 566
amygdaloid, 541
arciform, 564
caudate, 539
cuneatus, 564
dentate, 565
emboliformis, 560
fastigii, 560
globosus, 560
gracilis, 564
lenticular, 540
of olive, 565
red, 555
Nymphæ, 865

O.

Obex, 564
Obliquus capitis, inferior, 345
superior, 345
externus abdominis, 346
internus abdominis, 347
Oblongata, 562
development of, 104
foramen cæcum of, 562
lateral column of, 562
tract of, 562
olive of, 562
Obturator artery, 449
external, 449
internal, 449
externus muscle, 312
fascia, 376
internus muscle, 313
foramen, 157
nerve, 645
accessory, 645
veins, 494
Occipital artery, 413
bone, 177
gyri, 531
lobe, 526
nerve, great, 621
small, 623
third, 622
sinus, 479
veins, 474, 477
Occipitalis muscle, 363
Occipito-frontalis muscle, 363
Oculi, tendo, 362
Oculo-motor nerve, 589
Odontoblasts, 86
Œsophageal artery, 425, 441
nerves, 615
Œsophagus, 731
Olfactory bulb, 585
fissure, 530
nerve, 585
organs, development of, 106
tract, 585
Olivary nuclei, accessory, 565
Olive of oblongata, 562
Omenta, 770
Omentum, gastro-colic, 772
great, 772
Omo-hyoideus muscle, 351
Oögenesis, 78
Opening, auriculo-ventricular, left, 389
right, 387
saphenous, 379
Operculum, 527
Ophthalmic artery, 417
division of fifth nerve, 593
ganglion, 595
veins, common, 481
inferior, 481
superior, 481
Opponens minimi digiti, 289
pollicis muscle, 295
Optic chiasma, 586
commissure, 586
nerve, 586
tract, 586
Ora serrata, 705
Oral sinus, 86
Orbicularis oris muscle, 359
palpebrarum muscle, 362
Orbits, 207
dissection of, 918
Organ or organs, auditory, development of, 108
of Corti, 689
development of, 109
derived from ectoderm, 103
from endoderm, 86
of digestion, 713
enamel, 86
framework, 32
generative, 827
female, 848
male, 827
of Giraldès, 833, 862
development of, 101
gustatory, development of, 106
of internal secretion, 32
of Jacobson, 684, 685
of motion, 32
olfactory, development of, 106
of relation, 32
removing waste matters, 30
of reproduction, 33
of respiration, 777
physiological anatomy, 777
of Rosenmüller, 862
of special senses, 669
supplying nourishment, 31
systems of, 29
tactile, development of, 106
of taste, 680
Orifice, pyloric, 735
Oro-pharynx, 728
Os calcis, 168
external, 857
internal, 855, 857
innominatum, 152
magnum, 150
pubis, 156
Osseous labyrinth, 690
tissue, 52
cancellous, 53
spongy, 53
Ossicles of ear, 694
Ossicula auditus, 694
Ossification of sternum, 129
of vertebræ, 125
Ostium abdominale, 854
uterinum, 854
Otic ganglion, 603
Otoliths, 687
Ovarian artery, 447
fimbria, 824
plexus, 665
veins, 489
Ovaries, 848
development of, 99
Oviducts, 853
Ovula of Naboth, 860

P.

Pacchioni, glandules of, 579
Pachymeninx, 576
Pacinian corpuscles, 673
Palate bone, 196
hard, 717
pillars of, 718
soft, 718
Palatine artery, ascending, 412
descending, 416
glands, 717
nerve, anterior, 598
external, 599
posterior, 599
Palatoglossus, 719

Palatopharyngeus, 718
Palatum durum, 717
molle, 718
Palm, dissection of, 912
Palmar arch, deep, 441
superficial, 435
artery of ulnar, deep, 435
cutaneous nerve of median, 630
of ulnar, 631
fascia, 372
Palmaris brevis muscle, 299
longus muscle, 283
Palpebræ, 709
Palpebral arteries, 418
ligaments, 362, 711
nerve, inferior, 596
veins, inferior, 473
Pampiniform plexus, 489, 832, 838
Pancreas, 757
development of, 91
Pancreatic artery, 444
duct, 758
Pancreatico-duodenal artery, inferior, 445
superior, 443
Papilla, hair, 676
lachrymalis, 710
Papillæ, circumvallate, 678
filiform, 679
fungiform, 679
Papillary muscles, 388
Paracentral gyrus, 530
Paradidymis, 833
Parathyroids, 824
Parietal bones, 180
gyri, 530
lobe, 526
Parieto-occipital fissure, 526
Paroöphoron, development of, 100
Parotid fascia, 366
gland, 755
lymph-nodes, 507
veins, 473, 474
Parovarium, 862
development of, 100
Pars ciliaris retinæ, 705
intermedia of seventh nerve, 604
iridica retinæ, 705
Patches of Peyer, 744
Patella, 163
Patellar nerve, 645
Pathological anatomy, 20
Paths, conduction, in spinal cord, 572
Pectineus muscle, 311
Pectoral fascia, 369
lymph-nodes, 508
Pectoralis major, 274
minor, 270
Peduncles of callosum, 535
cerebellar, 558, 560
cerebral, 554
Pelvic cavity of female, dissection of, 914
of male, dissection of, 914
fascia, 376
plexus, 668
Pelvis, 157
articulations of, 240
of ureter, 807
veins of, 493
Penis, 838
development of, 102
dorsal artery of, 450
nerve of, 650
veins of, 494
suspensory ligament of, 842
Perforated space, anterior, 540
Perforating artery, posterior, 463
of radial, 439
cutaneous nerve, 649
Pericardial arteries, 441
Pericardium, 393
Perimysium, 61
Perineal artery, superficial, 449
transverse, 450
nerves, 650
Perineum, central point of, 846
development of, 102
fascia of, 378
female, dissection of, 915
male, dissection of, 914
muscles of female, 868
Perineurium, 64
Periosteum, 52
Peritoneal ligaments, 771
Peritoneum, 769
Periurethral glands, 868
Peroneal artery, 460
nerve, 655
Peroneus brevis muscle, 330
longus muscle, 330
tertius muscle, 322
Pes anserinus, 607
hippocampi, 544
Petit, canal of, 707
Petrosal nerve, external superficial, 606
great deep, 597
superficial, 606
small deep, 610
superficial, 606
sinus, inferior, 480
superior, 480
Petro-squamous sinus, 480
Petrous ganglion, 610
Peyer, patches of, 744
Phalanges of foot, 173
of hand, 151
ungual, 152
Pharyngeal artery, 414
ascending, 414
bursa, 728
nerve of ninth, 610
of sympathetic, 662
of tenth, 613
plexus, 475
tonsil, 728
Pharyngoglossus, 729
Pharynx, 728
muscles of, 729
Philosophic anatomy, 20
Phrenic artery, 447
superior, 424
nerve, 624
plexus, 665
Phreno-colic ligament, 771
-splenic ligament, 819
Physiological anatomy, 20
Pia mater, 514
of brain, 578
of spinal cord, 580
Pigmented epithelium, 43
Pillars of palate, 718
Pineal gland, 550
Pinna, 696
Pinna, muscles of, 696
Pisiform bone, 148
Pituitary gland, 549
membrane, 684
Placenta, development of, 83, 85
Plain muscular tissue, 58
Plantar arch, 462
artery, external, 462
internal, 463
fascia, 381
nerve, external, 654
Plantaris muscle, 328
Platysma muscle, 351
Pleuræ, 789
Plexus or plexuses, aortic, 666
basilar, 480
brachial, 625
cardiac, 667
carotid, 662
cavernous, 662
cervical, 622
choroid, 541
of fourth ventricle, 563
cœliac, 665
coronary, 667
diaphragmatic, 665
epigastric, 667
hemorrhoidal, 494, 668
hypogastric, 667
inferior mesenteric, 666
lumbar, 641
mesenteric, inferior, 666
superior, 666
ovarian, 494, 665
pampiniform, 489, 832, 838
patellæ, 645
pelvic, 668
pharyngeal, 475
phrenic, 665
prostatic, 494, 668
pterygoid, 474
renal, 665
sacral, 647
solar, 667
spermatic, 665
subsartorial, 646
superior mesenteric, 666
suprarenal, 665
uterine, 494, 668, 861
vaginal, 494, 668
vesical, 494, 668
Plica recti, 754
semilunaris, 712
sigmoidea, 745
Pneumogastric nerve, 611
Pomum Adami, 790
Pons, development of, 104
Varolii, 555
Popliteal artery, 459
lymph-nodes, 510
nerve, external, 655
internal, 651
space, 458
vein, 496
Popliteus muscle, 316
Porta, 550
Portal fissure, 763
system of veins, 491, 760
Porus opticus, 705
Postcentral gyrus, 531
Posterior auricular nerve, 606
brachium, 548
commissure, 550
forceps, 534
horn of lateral ventricle, 543

Posterior interosseous nerve, 635
longitudinal bundle, 555
nares, 681
palatine nerve, 599
perforated space, 549
superior dental nerve, 596
thoracic nerve, 626
tibial nerve, 652
Post-pharyngeal lymph-nodes, 507
Pouch of Broca, 865
laryngeal, 797
recto-vesical, 809
utero-vesical, 858
Poupart's ligament, 346
Practical anatomy, 909
Precentral fissure, 529
gyrus, 530
Precuneal fissure, 528
Precuneus, 531
Prepuce, 841
Prevertebral artery, 414
fascia, 368
region, dissection of, 918
Prickle cells, 43
Primitive streak, 81
Primordial ova, 851
Princeps pollicis artery, 439
Process, ensiform, 127
falciform, 379
fronto-nasal, 86
mandibular, 86
maxillary, 86
vocal, 792
xiphoid, 127
Processes, ciliary, 703
Processus reticularis, 572
vaginalis, 828, 838
Profunda artery, inferior, 430
superior, 430
Pronator quadratus, 281
teres, 281
Pronephros, 98
Prosencephalon, development of, 105
Prostate gland, 844
Prostatic plexus, 494, 668
Protoplasm, 38
Psoas magnus muscle, 304
parvus muscle, 337
Pterygoid artery, 416
nerve, external, 600
plexus, 474
Pterygoideus externus, 357
internus, 356
Pterygomandibular ligament, 360
Pterygo-maxillary fissure, 204
-palatine artery, 416
Pubic artery, 453
Pudendal nerve, inferior, 649
Pudendum, 864
Pudic artery, deep external, 456
internal, 449
superficial external, 456
nerve, 650
veins, external, 495
internal, 494
Pulmonary arterial system, 400
nerves, 614
valve, 388
veins, 468
Pulvinar, 548
Punctum lachrymale, 710
Pupil, 703
Putamen, 540
Pyloric artery, 443
orifice, 735
veins, 493
Pylorus, 735
Pyramid, cerebellar, 560
decussation of, 562
dorsal, 563
of Ferrein, 802
of tympanum, 693
ventral, 562
Pyramidal bone of carpus, 147
Pyramidalis muscle, 346
nasi muscle, 361
Pyriformis fascia, 377
muscle, 312

Q.

Quadrate lobe of liver, 763
Quadratus femoris muscle, 312
lumborum muscle, 348
plantæ muscle, 331
Quadriceps extensor cruris, 317
Quadrigemina, development of, 105

R.

Radial artery, 435
nerve, 635
recurrent artery, 436
vein, 483
Radialis indicis artery, 439
Radius, 144
Ramus cervicalis descendens, 624
communicans peronei, 655
descendens hypoglossi, 616
Ranine artery, 412
vein, 475
Ranvier, nodes of, 63
Receptaculum chyli, 502
seminis, 854
Recess, spheno-ethmoidal, 683
Rectal ampulla, 753
lymph-nodes, 512
Recto-vaginal ligament, 859
-vesical fascia, 377
pouch, 809
Rectum, 752
semilunar valves of, 754
Rectus abdominis muscle, 345
capitis anterior major, 354
minor, 355
lateralis, 354
posterior major, 344
minor, 345
femoris muscle, 318
Recurrent carpal artery, 439
laryngeal nerve, 613
Red nucleus, 555
Region of aqueduct, 553
subthalamic, 551
of third ventricle, 546
Regional anatomy, 18
Regions of abdomen, 732
Reil, island of, 526
Reissner, membrane of, 688
Relation of lobes to parts of lateral ventricle, 532
organs of, 32
Relational anatomy, 18
Renal artery, 446
plexus, 665
Reproduction cell, 39
Reproduction, organs of, 33
Reproductive organs, development of, 98
Respiratory nerve, external, 626
Restiform body, 563
Restis, 563
Rete testis, 830
Reticula, 572
Reticular cartilage, 52
lamina, 690
Retina, 704
Retrahens aurem, 697
Rhinencephalon, development of, 106
Rhomboid nerve, 625
Rhomboideus major, 269
minor, 269
Ribs, 129
asternal, 129
development of, 92
false, 129
peculiar, 130
sternal, 129
true, 129
typical, 129
Right lobe of liver, 763
Rima glottidis, 790, 797
pudendi, 865
Ring, external abdominal, 346
femoral, 376, 380
internal abdominal, 348, 376
tonsillar, 731
Risorius muscle, 360
Rods of Corti, 689
Rolandic fissure, 525
Röntgen rays, 896
Root of lung, 786
Rosenmüller, organ of, 862
Rostrum of callosum, 533
Rotatores muscles, 344
Round ligament, development of, 100
of liver, 766
ligaments of uterus, 859

S.

Sac, lachrymal, 710
Saccule, 687
Sacculus laryngis, 797
Saccus endolymphaticus, 687
Sacral artery, lateral, 452
middle, 447
lymph-nodes, 512
nerves, 646
fifth, 658
fourth, 657
plexus, 647
veins, lateral, 494
middle, 490
Sacro-sciatic notch, great, 154
small, 155
-lumbalis muscle, 343
Sacrum, 120
Salivary corpuscles, 730
glands, 755
Sand, brain-, 551, 579
Saphenous opening, 379
veins, external, 495
internal, 495
long, 495
short, 495
Sarcolemma, 61
Sarcoplasm, 60
Sartorius muscle, 315

Scala media, 688
tympani, 692
vestibuli, 692
Scalenus muscle, anterior, 353
medius, 354
posterior, 354
Scaphoid bone of the carpus, 146
of tarsus, 169
Scapula, 135
ligaments of, 230
Scapular artery, posterior, 425
Scarpa, triangle of, 453
Schlemm, canal of, 701
Schneiderian membrane, 684
Sciatic artery, 451
nerve, great, 650
small, 648
Scleral sulcus, 700
Sclerotic, 700
Scrotal ligament, 827
Scrotum, 835
Sebaceous glands, 676
Second nerve, 586
Sections, plane, 873
Sella, diaphragm of, 577
Semicircular canals, 687
Semilunar, the, of the carpus, 146
valves of rectum, 754
Semimembranosus muscle, 315
Seminal vesicles, 834
Semispinalis capitis muscle, 343
cervicis muscle, 344
dorsi muscle, 344
Semitendinosus muscle, 315
Sensory epithelium, 43
Septa, intermuscular, of arm, external, 371
internal, 371
of leg, 380
of thigh, 379
Septum auricularum, 387
crurale, 380
lucidum, 537
pectiniforme, 839
posterius, 580
transversum, 687
Serratus magnus, 270
posterior, inferior, 340
superior, 339
Sets of teeth, 721
Seventh nerve, 604
Sharpey, fibres of, 54
Sheaths, crural, 375
fascial, of tendons of hand, 373
femoral, 375
Shelf, dental, 86
Shield, embryonic, 80
Shoulder, fascia of, 370
-joint, 230
muscles moving, 267
Sigmoid artery, 446
colon, 749
sinus, 479
Simple epithelium, 44
Sinus or sinuses, basilar, 480
cavernous, 480
circular, 480
coronary, 469, 480
frontal, 684
inferior longitudinal, 478
petrosal, 480
intercavernous, 480
jugular, 475
of kidney, 803, 804
Sinus or sinuses, lateral, 478
longitudinal, inferior, 478
superior, 477
occipital, 479
oral, 86
petrosal, inferior, 480
superior, 480
petro-squamous, 480
pocularis, 813
development of, 101
of portal vein, 491
præcervicalis, 87
sigmoid, 479
spheno-parietal, 480
straight, 478
superior longitudinal, 477
petrosal, 480
transverse, 480
urogenital, 102
uterine, 861
of Valsalva, 388
venous, 469
of cranium, 477
Sixth nerve, 604
Skeleton, development of, 91
Skiagraphs, normal, 896
Skin, 669
nerves of, 672
true, 671
Skull, 176
base of, 209
development of, 92
exterior of, 203
externally, 205
facial region of, 207
morphology of, 212
sutures of, 203
temporal region of, 203
various forms of, 213
as a whole, 203
Slender lobe, 560
Small deep petrosal nerve, 610
internal cutaneous nerve, 631
intestine, 737
tunics of, 737
occipital nerve, 623
sciatic nerve, 648
splanchnic nerve, 665
superficial petrosal nerve, 606
Smegma preputii, 841
Soft palate, 718
muscles of, 718
Solar plexus, 667
Sole, dissection of, 916
Soleus muscle, 327
Solitary glands, 740
lymph-nodules, 740
Somatopleure, 80
Somites, mesodermal, 82
Sonorus, conductor, 556
Space, axillary, 426
epidural, 580
of Fontana, 701
interlabial, 866
interpeduncular, 549
perforated, anterior, 540
posterior, 549
popliteal, 458
sublingual, 726
undefended, 389
Special senses, organs of, 669
Spermatic artery, 446
cord, 838
plexus, 665
veins, 489
Spermatids, 77
Spermatocytes, 77
Spermatogenesis, 77
Spermatogones, 77
Spermatozoa, 77
Spheno-ethmoidal recess, 683
-maxillary fissure, 204
fossa, 204
-palatine artery, 417
nerve, 596
-parietal sinus, 480
Sphenoid bone, 188
Sphenoidal antrum, 684
Sphincter ani externus, 847
internal, 754
of urethra, 811
iridis, 704
vaginæ, 869
Spigelian lobe, 763
Spinal accessory nerve, 615
arteries, 441
anterior, 423
lateral, 422
posterior, 423
bulb, 562
canal, 125
cord, 513, 569
arachnoid of, 580
central canal of, development of, 103
columns of, 571
conduction paths in, 572
dura of, 579
fissures of, 571
gray matter of, 571
membranes of, 579
pia of, 580
topographical anatomy of, 619
tracts of, 572
veins of, 487
furrow, 124
nerve-roots, 576
nerves, 617
veins, dorsal, 486
longitudinal, anterior, 486
posterior, 487
Spinalis dorsi muscle, 343
Spine, 115
veins of, 486
as a whole, 124
Spiral ganglion, 692
ligament, 692
Spitzka-Lissauer tract, 575
Splanchnic nerve, great, 664
least, 665
small, 665
Splanchnopleure, 80
Spleen, 817
accessory, 820
development of, 98
pulp, 819
Splenic artery, 444
flexure, 749
veins, 493
Splenium, 533
Splenius capitis muscle, 340
cervicis muscle, 341
colli muscle, 341
Spongioblasts, 103
Spongioplasm, 38
Sporadic ganglia of fifth nerve, 594
Spot, germinal, 852
yellow, 705

Stapedius, 695
Stapes, 694
Stenson, duct of, 755
Stenson's canal, 684
Sternal lymph-nodes, 510
Sterno-cleido-mastoideus muscle, 351
-hyoideus muscle, 351
-mastoid artery, 410
-thyroideus muscle, 352
Sternum, 127
development of, 129
ossification of, 129
Stilling, canal of, 707
Stomach, 733
coronary veins of, 493
development of, 90
tunics of, 735
Stomodæum, 86
Straight sinus, 478
Stratified epithelium, 44
Stratum corneum, 671
dorsale, 552
granulosum, 671
intermedium, 555
lucidum, 671
Streak, primitive, 81
Striæ acusticæ, 564
longitudinales, 535
Striatum, corpus, 538
Structure of tongue, 726
Study, methods of, 33
Styloglossus, 727
Stylo-hyoideus muscle, 353
-mandibular ligament, 368
-mastoid artery, 414
-pharyngeus, 729
Subarachnoid space, 578
Subcalcarine gyrus, 531
Subclavian artery, 419
lymph-nodes, 508
vein, 484
Subclavius muscle, 271
nerve, 626
Subcollateral gyrus, 531
Subcostales muscles, 350
Subdural space, 578
Sublingual artery, 412
gland, 756
space, 726
Sublobular veins, 761
Submandibular ganglion, 603
Submaxillary ganglion, 603
gland, 756
lymph-nodes, 507
Submental artery, 412
Suboccipital lymph-nodes, 507
muscles, 344
nerve, 621
Subsartorial plexus, 646
Subscapular artery, 425, 428
fascia, 371
lymph-nodes, 508
nerves, 627
Subscapularis muscle, 277
Substantia gelatinosa, 572
Subthalamic region, 551
Suburethral glands, 846
Sulcus longitudinalis medianus, 556
of Monro, 548
scleral, 700
spiralis, 690
Superficial cervical nerves, 624
fascia, 365
Superficial lymph-vessels, 501
temporal nerve, 601
veins, 469
Superior cervical ganglion, 661
fovea, 568
gluteal nerve, 648
labial nerve, 597
laryngeal nerve, 613
mesenteric plexus, 666
nasal nerves, 598
parietal gyrus, 531
tela choroidea, 541
vena cava, 470
Supra-acromial artery, 425
Suprahyoid lymph-nodes, 507
Supramandibular nerve, 607
Supramarginal gyrus, 531
Supraorbital artery, 418
fissure, 530
veins, 473
Suprarenal artery, 446
bodies, development of, 98
capsules, 823
plexus, 665
Suprascapular artery, 425
nerve, 626
Supraspinatus muscle, 274
Supraspinous fascia, 371
Suprasternal artery, 425
Supratrochlear nerve, 594
Surcingle, 539
Surface anatomy, 883
mesial, of cerebrum, 527
parts, delimitations of, 21
names of, 21
tentorial, of cerebrum, 527
Surfaces of heart, 391
of liver, 762
Surgical anatomy, 18
Suspensory ligament of lens, 707[e]
of liver, 766
of ovary, 850
of penis, 842
muscle, 742
Sustentacular tissues, 45
Sustentaculum tali, 168
Sutures, 216
of skull, 203
Sweat-glands, 677
Sweetbread, 757
Sylvian fissure, 525
veins, deep, 482
Sympathetic nerves, 658
system, development of, 106
Symphysis pubis, 156, 242
Synarthrosis, 216
Synovia, 69
Synovial membranes, 69
articular, 70
bursæ, 382
bursal, 70
vaginal, 70
System, absorbent, 499
blood-vascular, 385
Haversian, 53
lymphatic, 499
urinary, 799
vascular, 30
Systematic anatomy, 18
Systemic veins, 469
Systems of organs, 29
functions of, 29

T.

Tactile organs, development of, 106
Tænia semicircularis, 539
Tarsal artery, 466
Tarsi, tensor, muscle, 362
Tarsus, 710
bones of, 168
joints of, 253
Taste-buds, 679
organs of, 680
Tectorial membrane, 690
Teeth, 720
bicuspid, 721
canine, 721
deciduous, 721
development of, 86
eruption of, 721
incisor, 721
milk, 721
molar, 721
sets of, 721
temporary, 721
Tegmentum, 554
Tela, 541
choroidea, inferior, 564
superior, 541
Temporal artery, 414
anterior, 415
middle, 414
posterior, 415
bones, 184
fascia, 366
fossa, 203
dissection of, 918
gyri, 531
lobe, 526, 531
nerve, deep, 599
superficial, 601
region of skull, 203
of seventh nerve, 607
veins, anterior, 477
common, 473
middle, 473
posterior, 477
superficial, 473
Temporalis muscle, 356
Temporary teeth, 721
Temporo-facial division of seventh nerve, 607
-malar nerve, 596
-maxillary veins, 473
Tendon, conjoined, 347
Tendons, general considerations of, 259
Tendo oculi, 362, 711
Tenia tecta, 535
Tenon, capsule of, 698
Tensor fasciæ latæ, 306
palati, 719
tarsi, 362
tympani, 695
vaginæ femoris, 306
Tenth nerve, 611
nuclei of, 609
Tentorial surface, 527
Tentorium, 576
of hypophysis, 577
Teres major, 275
minor, 275
Terminal cone of spinal cord, 570
Testes, 827
development of, 100

Testes of mesencephalon, 554
Testicles, 827
migration of, 828
Thalami optici, 547
Thalamencephalon, 546
development of, 105
Thalamus, optic, development of, 105
Thebesius, veins of, 470
Thigh, back of, dissection of, 916
fascia of, 379
front of, dissection of, 915
inner side of, dissection of, 915
muscles moving, 303
Third nerve, 589
occipital nerve, 622
ventricle, region of, 546
Thoracic aorta, 403
artery, acromio-, 427
alar, 428
long, 428
superior, 427
cardiac nerves, 614
cavity, dissection of, 912
duct, 502
fascia, 369
portion of gangliated cord, 663
nerve, 638
external anterior, 627
internal anterior, 627
posterior, 626
twelfth, 640
wall, veins of, 484
Thorax, 127
articulations of, 223
back of, dissection of, 913
lymph-nodes of, 510
muscles of, 348
and upper limb, dissection of, 912
as a whole, 131
Thumb, muscles moving, 294
Thymus, 822
development of, 88
Thyro-arytenoideus, 795
-epiglottideus, 795
-glossal duct, 820
-hyoideus muscle, 352
Thyroid artery, inferior, 425
axis, 424
body, 820
cartilage, 791
gland, 820
accessory, 821
development of, 88
isthmus of, 821
veins, inferior, 476
middle, 476
superior, 476
Tibia, 163
Tibial artery, anterior, 463
posterior, 460
recurrent artery, anterior, 465
posterior, 465
nerve, anterior, 656
posterior, 652
Tibialis muscle, anterior, 322
posterior, 322
Tissues, adenoid reticular, 50
adipose, 49
areolar, 47
cardiac muscular, 61
cartilaginous, 51
classes of, 41
connective, 46
Tissues, dentinal, 56
elastic, 47
elementary, 37
epithelial, 41
fatty, 49
gelatinous, 50
of the heart, 386
liquid, 57
muscular, 58
cross-striped, 59
plain, 58
nervous, 62
osseous, 52
cancellous, 53
spongy, 53
sustentacular, 45
white fibrous, 46
yellow fibrous, 47
Tongue, 678, 725
development of, 88
structure of, 726
Tonsils, 730
pharyngeal, 729
tubal, 728
Tonsillar artery, 412
nerve of ninth, 610
ring, 731
Topics, order of, 33
Topographical anatomy, 18
of spinal cord, 619
Torcular Herophili, 178, 478
Touch-corpuscles, 672
Trachea, 779
development of, 88
Tracheal artery, 425
Trachelo-mastoideus muscle, 343
Tract of Burdach, 575
of Goll, 575
of Gowers, 573
lateral, of oblongata, 562
olfactory, 585
optic, 586
Spitzka-Lissauer, 575
uveal, 701
Tragus, 696
Transcendental anatomy, 20
Transitional epithelium, 44
Transversalis abdominis muscle, 347
cervicis muscle, 343
colli artery, 425
fascia, 375
Transverse cervical artery 425
colon, 749
fissure, 543, 763
sinus, 480
Transversus pedis muscle, 336
perinei muscle, 847, 868
thoracis muscle, anterior, 350
Trapezium, 148
cerebellar, 558
pontile, 557
Trapezius muscle, 267
Trapezoid, 149
Triangle interdeferential, 834
Scarpa's, 453
Triangles of the neck, 426
Triangular ligament, 346
Triangularis sterni muscle, 350
Triceps extensor cubiti, 279
suræ muscle, 328
Tricuspid valve, 388
Trifacial nerve, 592
Trigonum of bladder, 808
Trochlear nerve, 592
Trolard, veins of, 482
True cartilage, 51
ribs, 129
skin, 671
vertebræ, 115
vocal cords, 794
Trunk, articulations of, 217
muscles of, 339
Tuba auditiva, 694
Tubal tonsil, 728
Tube, Eustachian, 694
Tuber annulare, 555
cinereum, 549
cochleæ, 693
dorsal, cerebellar, 560
Tubercle, acoustic, 568
of Lower, 388
Tubes, bronchial, 781
Fallopian, 853
development of, 100
uriniferous, 799
Tubo-ovarian ligament, 850
Tubuli recti, 831
seminiferi, 830
Tunica albuginea, 830, 839
ovarii, 850
vaginalis, 829
development of, 101
vasculosa, 830
Tunic or tunics, of alimentary canal, 715
of eye, fibrous, 701
nervous, 704
vascular, 701
of liver, 765
of small intestine, 737
of stomach, 735
Turbinate bone, inferior, 198
Twelfth nerve, 616
thoracic nerve, 640
Tympanic artery, 416
bone, 188
nerve, 610
Tympanum, 692
muscles of, 695
Typical cerebro-spinal nerve, 581

U.

Ulna, 142
Ulnar artery, 431
recurrent, 432, 433
nerve, 631
veins, anterior, 483
common, 483
posterior, 483
Umbilical cord, 84
fissure, 763
vesicle, 84
Umbilicus, 26, 84
Unciform, 151
Uncinate gyrus, 532
Undefended space, 394
Ungual phalanges, 152
Urachus, 102
Ureters, 807
development of, 99, 102
infundibula of, 807
pelvis of, 807
Urethra, 810
development of, 102
female, 810
internal sphincter of, 811
male, 812

Urethra, membranous, 812
prostatic, 812
spongy, 812
triangular ligament of, 378
Urethral glands, 868
Urinary bladder, 807
system, 799
Uriniferous tube, 799
Urogenital sinus, 102
Uterine artery, 449
plexus, 494, 668, 861
sinuses, 861
Utero-ovarian ligament, 849
-sacral ligaments, 859
-vesical pouch, 858
Uterus, 855
cervix of, 856
development of, 100
fundus of, 856
masculinus, 813
development of, 101
Utricle, 686
Uveal tract, 701
Uvula, 718
cerebellar, 560
vesicæ, 808

V.

Vagina, 862
development of, 103
Vaginal arteries, 449
plexus, 494, 668
synovial membrane, 70
Vagus area, 568
nerve, 611
Vallecula, 558, 792
Valsalva, sinus of, 388
Valve, aortic, 389
bicuspid, 389
Eustachian, 388
of Houston, 754
ileo-cæcal, 747
-colic, 747
mitral, 389
pulmonary, 388
semilunar, of rectum, 754
tricuspid, 388
of Vieussens, 556
Valvula, 556
Valvulæ conniventes, 739
Varolius, bridge of, 555
Vas aberrans, 834
Vascular system, 30
membrane lining, 68
tunic of eye, 701
Vas deferens, 833
development of, 101
Vasa efferentia, 831
vasorum, 396
Vastus externus muscle, 321
intermedius muscle, 321
internus muscle, 321
lateralis muscle, 321
medialis muscle, 321
Vein or veins of abdomen, 488
anastomotic, great, 482
posterior, 482
angular, 472
anterior auricular, 474
cardiac, 470
facial, 473
internal maxillary, 473
jugular, 474
temporal, 477
Vein or veins, auricular, anterior, 474
posterior, 474
axillary, 484
azygos, great, 485
left lower, 486
lower, left, 486
right, 485
small, 486
basilic, 483
median, 483
brachio-cephalic, 471
of brain, 481
bronchial, 486
buccal, 473
cardiac, 469
anterior, 470
great, 469
middle, 470
posterior, 470
smallest, 470
cephalic, 484
median, 483
cerebellar, inferior, 482
superior, 482
cerebral, anterior, 482
deep, 482
inferior, 482
middle, 482
superficial, 481
superior, 481
cervical, deep, 477
transverse, 474
choroid, 482
circumflex iliac, superficial, 495
common facial, 473
iliac, 490
temporal, 473
ulnar, 483
coronary, 469
right, 470
small, 470
of stomach, 493
deep, 469
cerebral, 482
cervical, 477
facial, 472
Sylvian, 482
of upper limb, 484
development of, 96
digital, of foot, dorsal, 495
of diploë, 477
dorsal digital, of foot, 495
of penis, 494
spinal, 486
emissary, 477, 481
epigastric, superficial, 495
external iliac, 491
jugular, 474
pudic, 495
saphenous, 495
extraspinal, 486
facial, 471
anterior, 471
common, 472
posterior, 473
transverse, 474
femoral, 496
frontal, 473, 477
of Galen, 470, 482
gastric, 493
gluteal, 494
great anastomotic, 482
cardiac, 469
Vein or veins of head and neck, 471
of heart, 469
hepatic, 761
iliac, common, left, 490
right, 490
external, 491
internal, 493
superficial circumflex, 495
ilio-lumbar, 490, 493
inferior mesenteric, 493
palpebral, 473
striate, 482
thyroid, 476
innominate, 471
intercostal, 486
superior, 485
interlobular, 760
internal jugular, 475
mammary, 484
maxillary, 474
anterior, 473
pudic, 494
saphenous, 495
interventricular, posterior, 470
intralobular, 761
intraspinal, 486
jugular, anterior, 474
external, 474
posterior, 474
internal, 475
posterior external, 474
lateral sacral, 494
left marginal, 470
long saphenous, 495
of lower limb, deep, 496
superficial, 495
of Lubbe, 482
lumbar, 489
ascending, 490
mammary, internal, 484
marginal, left, 470
right, 470
of Marshall, 469
masseteric, 473
maxillary, anterior, internal, 473
basilic, 483
cephalic, 483
internal, 474
median, 483
meningo-rachidian, 486
mesenteric, inferior, 493
superior, 493
middle cardiac, 470
sacral, 490
temporal, 473
thyroid, 476
nasal transverse, 473
oblique, 469
obturator, 494
occipital, 474, 477
ophthalmic, 481
common, 481
inferior, 481
superior, 481
ovarian, 489
palpebral, inferior, 473
parotid, 473, 474
of pelvis, 493
phrenic, 489
popliteal, 496
portal, 491, 760
system of, 491
posterior anastomotic, 482

Vein or veins, posterior auricular, 474
cardiac, 470
facial, 471
interventricular, 470
temporal, 477
ulnar, 483
pudic, external, 495
internal, 494
pulmonary, 468
pyloric, 493
radial, 483
ranine, 475
renal, 489
right coronary, 470
marginal, 470
sacral, lateral, 494
middle, 490
saphenous, external, 495
internal, 495
long, 495
short, 495
sciatic, 494
short saphenous, 495
small coronary, 470
spermatic, 489
of spinal cord, 487
of spine, 486
anterior longitudinal, 486
dorsal, 486
longitudinal anterior, 486
posterior, 487
posterior longitudinal, 487
splenic, 493
striate, inferior, 482
subclavian, 484
subcutaneous, 469
sublobular, 761
superficial, 469
circumflex iliac, 495
epigastric, 495
temporal, 473
superior intercostal, 485
mesenteric, 493
thyroid, 476
supraorbital, 473
suprarenal, 489
suprascapular, 474
of surface of cranium and face, 471
Sylvian, deep, 482
systemic, 469
temporal, anterior, 477
common, 473
middle, 473
posterior, 477
superficial, 473
temporo-maxillary, 473
of thoracic wall, 484
thyroid, inferior, 476
middle, 476
superior, 476
transverse cervical, 474
facial, 474
nasal, 473
of Trolard, 482
of upper limb, deep, 484
superficial, 482
Vein or veins, ulnar, anterior, 483
common, 483
posterior, 483
vertebral, 476
anterior, 476
bodies, 486
posterior, 477
Velum interpositum, 541
pendulum palati, 718
Vena azygos major, 485
minor, 486
cava, ascending, 488
descending, 470
inferior, 488
superior, 470
-caval fissure, 764
hemiazygos, 486
accessoria, 486
portæ, 491
Venæ basis vertebrarum, 486
comites, 469
cordis minimæ, 470
Thebesii, 470
vorticosæ, 700
Ventral pyramids, 562
Ventricle or ventricles of brain, development of, 103
fourth, 568
of larynx, 797
right, 388
Ventricular cavity, general, 519
Vermis, 558
inferior, 559
superior, 558
Vertebra dentata, 117
prominens, 117
typical, 115
Vertebræ, cervical, 116
development of, 91
false, 115
lumbar, 119
ossification of, 125
peculiar, 119
sacral, 120
serial morphology of, 126
thoracic, 118
true, 115
Vertebral artery, 422
bodies, veins of, 486
column, 115
articulations of, 217
fascia, 374
grooves, 124
veins, anterior, 476
posterior, 477
Verumontanum, 813
Vesica fellea, 767
Vesical arteries, 449
plexus, 494, 668
Vesicle, embryonic, 80
encephalic, 514
germinal, 852
seminal, 834
umbilical, 84
Vesico-pubic muscle, 809
Vesicula prostatica, 813
Vessels of liver, 760, 766
Vestibule, 866
of nose, 681
of osseous labyrinth, 691
Vestibulum oris, 717
Vibrissæ, 681
Vicq-d'Azyr, bundle of, 537
Vidian artery, 416
nerve, 597
Vieussens, valve of, 556
Villi, 739
chorionic, 84
Vitelline membrane, 851
veins, 93
Vitellus, 852
Vitreous humor, 707
lamina, 702
Vocal cords, false, 794
true, 794
process, 792
Vomer, 197
Vulva, 864
Vulvo-vaginal glands, 868

W.

Walls of cerebro-spinal axis, 519
Weber, gland of, 755
Wharton, duct of, 756
White commissure, basal, 533
of spinal cord, 572
fibro-cartilage, 51
fibrous tissues, 46
Willis, circle of, 423
Windpipe, 779
Winslow, foramen of, 772
Wolffian body, 99
duct, 98
Womb, 855
Worm, 558
Wormian bones, 203
Wrisberg, nerve of, 631
Wrist-joint, 236

X.

Xiphoid process, 127
X-rays, 896

Y.

Yellow fibro-cartilage, 52
fibrous tissue, 47
spot, 705

Z.

Zinn, ligament of, 708
zonula of, 707
Zona incerta, 552
pellucida, 852
Zone, ciliary, 702
Zonula of Zinn, 707
Zygoma, 184
Zygomatic fossa, 204
dissection of, 918
Zygomaticus muscle, major, 360
minor, 360